Ophthalmol Ther (2021) 10:413–428
https://doi.org/10.1007/s40123-021-00354-1

REVIEW

A Review of Aflibercept Treatment for Macular Disease

Rodrigo Anguita · Anastasia Tasiopoulou · Syed Shahid · Janice Roth · Sing Yue Sim · Praveen J. Patel

Received: February 8, 2021 / Accepted: May 19, 2021 / Published online: June 13, 2021
© The Author(s) 2021, corrected publication 2021

ABSTRACT

Aflibercept is a fully human recombinant fusion protein that includes the second domain of human VEGF receptor 1 and the third domain of human VEGF receptor 2. Despite the important role played by VEGF in maintaining the physiological condition of the retina under normal conditions, dysregulation of VEGF can result in pathological alterations including hyperpermeability of the retinal capillaries and migration and proliferation of retinal endothelial cells. Over the years, a number of studies have evaluated the use of intravitreal aflibercept in different retinal diseases. In this review, we aim to summarize the scientific evidence and recommendations for use of intravitreal aflibercept in neovascular age-related macular degeneration, diabetic macular oedema, macular oedema associated with retinal vein occlusion, and myopic choroidal neovascularization.

R. Anguita · A. Tasiopoulou · S. Shahid · J. Roth · S. Y. Sim · P. J. Patel (✉)
National Institute of Health Research Biomedical Research Centre at Moorfields Eye Hospital and UCL Institute of Ophthalmology, London, UK
e-mail: praveen.patel1@nhs.net

A. Tasiopoulou
Royal Devon and Exeter Hospital, Exeter, UK

Keywords: Aflibercept; VEGF; Neovascular age-related macular degeneration; Diabetic macular oedema; Macular oedema associated with vein occlusion; Myopic choroidal neovascularization

Key Summary Points

- It has been almost 10 years since aflibercept received FDA approval for treatment of neovascular age-related macular degeneration (nAMD).
- During the past decade, numerous randomized clinical trials have been carried out, and the widespread use of aflibercept has enabled the publication of multiple real-world evidence studies (REW).
- This article reviews the best evidence available in the literature including randomized controlled trials and RWE as well as treatment practice guidelines in different macular diseases.
- Intravitreal aflibercept has been safe and effective, showing favorable functional and anatomical outcomes in AMD, diabetic macular oedema, retinal vein occlusion and myopic choroidal neovascularization.

FORMYCON-1092

DIGITAL FEATURES

This article is published with digital features, including a summary slide, to facilitate understanding of the article. To view digital features for this article go to https://doi.org/10.6084/m9.figshare.14611902.

INTRODUCTION

Aflibercept, also known as vascular endothelial growth factor (VEGF) Trap-eye (Eylea®, Regeneron, Rensselaer, NY, USA) is a fully humanized recombinant protein that acts as a soluble decoy receptor that binds to VEGF-A, VEGF-B and placental growth factor (PIGF), thereby stopping the binding and activation of VEGF receptors [1]. Since its approval by the Food and Drug Administration (FDA) for use in neovascular age-related macular degeneration [2] (nAMD) following the landmark VIEW1 and VIEW2 studies [3, 4], intravitreal aflibercept has been approved for a variety of other pathologies. In this review, we summarize the evidence for the use of intravitreal aflibercept in retinal diseases including nAMD, diabetic macular oedema (DMO), macular oedema secondary to retinal vein occlusion (RVO) and myopic choroidal neovascularization (CNV). We will discuss indications and outcomes of randomized controlled trials and real-world data.

METHODS

A literature search was conducted on the PubMed database for publications between the years 2008 and 2021 with the words "Aflibercept", "Diabetic Macular Oedema", "Age-related macular Degeneration", "Retinal Vein Occlusion" and "Myopic Choroidal Neovascularization", with additional filters including "Clinical trial", "Meta-Analysis", "Randomized Controlled Trial" and "Observational Study", yielding a total of 212 articles. Articles in languages other than English, studies in animal models and those combining surgical procedures were excluded, as well as small case series. The remaining abstracts and articles were reviewed by two authors (RA and SYS) and were included based on their relevance to this review article.

This study is based on previously conducted studies and does not contain any studies with human participants or animals performed by any of the authors.

NEOVASCULAR AGE-RELATED MACULAR DEGENERATION

Age-related macular degeneration (AMD) is a progressive, degenerative disease of the macula that occurs with increasing frequency among people aged 55 years and older [5]. There are two main types of AMD, referred to as non-neovascular or dry AMD and neovascular or wet AMD (nAMD). The non-neovascular form is characterized by yellow deposits under the retina (drusen), changes in the retinal pigment epithelium (RPE) and geographic atrophy [6]. The neovascular form is characterized by CNV or macular neovascularization (MNV)—the new definition coined by the Neovascular Age-Related Macular Degeneration Nomenclature Study Group (CONAN [7]. Associated clinical manifestations of nAMD include subretinal fluid (SRF), intraretinal fluid (IRF), and retinal, subretinal, or sub-RPE haemorrhage [6].

The global prevalence of any type of AMD is estimated at 8.69% (95% confidence interval (CI) 4.2–17.40%) among people age 45–85 years [8]. Although neovascularization occurs in only 10% of cases, it accounts for 80% of AMD patients with severe visual loss [5]. Without treatment, nAMD can cause severe vision loss (20/200 or worse) in the majority of eyes [9], significantly impacting on the functional independence and quality of life of individuals. In addition, AMD imposes a significant economic burden on the state, with an estimated cumulative cost of £16.4 billion in the UK from 2010 to 2020 [10–12].

Randomized Clinical Trials

The Vascular Endothelial Growth Factor (VEGF) Trap-Eye: Investigation of Efficacy and Safety in Wet Age-Related Macular Degeneration (AMD)

(VIEW)1 and VIEW2 [3, 4] studies were the largest randomized controlled trials (RCTs) comparing the efficacy and safety of intravitreal aflibercept and ranibizumab in patients with nAMD. Both were double-masked trials of similar design carried out in different centres: VIEW1 in the United States and Canada, and VIEW2 in Europe, the Middle East, the Asia–Pacific region and Latin America.

Patients (1217 participants VIEW1 and 1240 in VIEW2) were randomly assigned to four groups: 0.5 mg aflibercept every 4 weeks (0.5q4), 2 mg aflibercept every 4 weeks (2q4), 2 mg aflibercept every 8 weeks (2q8) following three monthly loading injections, and the control group of 0.5 mg ranibizumab every 4 weeks (Rq4). The primary treatment lasted 52 weeks and the follow-up period was from weeks 52 to 96. During the follow-up phase, all groups were switched from a fixed monthly or bimonthly regimen to an as-needed or pro re nata (PRN) regime.

The studies showed that aflibercept 2 mg every 8 weeks (2q8) produced non-inferior efficacy to monthly ranibizumab, and efficacy remained at 96 weeks [13, 17]. Patients in this group (2q8) gained +7.6 letters from baseline at week 96 compared with +8.4 letters at week 52. Patients in the ranibizumab group gained +7.9 letters from baseline at week 96 compared with +8.7 letters at week 52. Over 2 years, patients in group (2q8) received an average of 11.2 injections, while patients treated with ranibizumab had an average of 16.5 injections over the same period. Thus, patients in group (2q8) had an average of five fewer injections by 96 weeks. In VIEW1, at 52 weeks, the proportion of fluid-free eyes on optical coherence tomography (OCT) was 61% in group (2q8) and 63.6% in the ranibizumab group. Similarly, in VIEW2, at 52 weeks, 64.4% in group (2q8) and 55.7% in the ranibizumab group had no fluid. This benefit remained at 96 weeks (combined data from VIEW1 and VIEW2), with 49.8% of participants in group (2q8) and 45.5% of participants in the ranibizumab group. Aflibercept was well tolerated, with no differences between any groups for ocular treatment-emergent and injection-related adverse events and for non-ocular systemic adverse events.

For patients enrolled in VIEW1, there was an extension study up to 212 weeks [13], with a modified quarterly dosing amended to treatment every 8 weeks. The mean number of injections between weeks 96 and 212 was 12.9, and visual acuity (VA) gains were largely maintained during the extension period, with +7.1 letters.

Another significant RCT published in 2017, ALTAIR, evaluated two different treat-and-extend (T&E) regimens of aflibercept in a Japanese population with nAMD for 96 weeks [14]. In total, 247 patients were treated with three initial monthly loading doses of aflibercept 2 mg and were then randomly assigned to two groups: 2-week group with aflibercept (AFB-2 W) T&E and adjustment of intervals by 2 weeks (124 patients), and 4-week group with aflibercept (AFB-4 W) T&E and adjustment of intervals by 4 weeks (123 patients). The mean change in VA from baseline to week 52 was 9.0 letters in the AFB-2 W group and 8.4 in the AFB-4 W group. In the same period, the mean change in central retinal thickness (CRT) was −134.4 μm in AFB-2 W and −126.1 μm in AFB-4 W. Functional and anatomical outcomes were maintained to week 96. From baseline to week 96, the mean changes in VA were 7.6 (AFB-2 W) and 6.1 (AFB-4 W) letters and mean changes in CRT were −130.5 μm (AFB-2 W) and −125.3 μm (AFB-4 W). The mean number of aflibercept injections was the same in the two groups (10.4) from baseline to week 96. The overall safety profile of aflibercept was consistent with previous studies. These findings underscore the efficacy of the aflibercept T&E regimen with 2- or 4-week adjustments, thereby reducing the treatment burden for both patients and healthcare providers [15].

Real-World Evidence Studies

Several studies have evaluated the efficacy of aflibercept in real-world clinical settings given the broader diversity of treatment cohorts in the real world compared to necessarily homogeneous demographics in RCTs. In 2016, the UK Aflibercept Users Group reported visual outcomes of aflibercept treatment achieved in 16

UK National Health Service (NHS) hospitals at 1 year based on the VIEW studies protocol. Visual outcomes were comparable to the landmark trials. A total of 1840 treatment-naïve eyes of 1682 patients were enrolled and received a median of eight injections over a median of eight visits. Early visual gain after the monthly injection loading phase was maintained through 1 year, and the largest visual gains at 1 year occurred in eyes with the worst baseline vision. The proportion of eyes achieving 70 letters or more increased from 16.4% at baseline to 33.7% at 1 year [16].

Another significant real-world evidence (RWE) study investigated 2-year, 3-year and 4-year outcomes of aflibercept treatment at Moorfields Eye Hospital NHS Foundation Trust [17–19]. The 2-year study included 109 treatment-naïve eyes from 102 patients, with data from 94 eyes of 88 patients. Patients received fixed doses of aflibercept in year 1 as per the VIEW study protocol, which was switched to T&E in year 2. Over 2 years, the mean visual gain was 5.1 ± 14.9 letters with a mean of 11.4 injections per eye. Ninety-five percent of patients achieved VA maintenance at the end of year 1 and 90.4% at the end of year 2, which is comparable to the outcomes in the VIEW studies. The mean decrease in central subfield macular thickness (CMT) was 79 μm, with absence of macular fluid in 72.7% of the eyes. In the 3-year study, patients received fixed dosing of aflibercept in year 1 followed by a T&E approach. These patients were found to have good visual and anatomical outcomes. Over 3 years, 88.9% achieved VA maintenance and 30.5% eyes experienced a gain in VA. The mean visual gain was 6.6 letters achieved with a mean of 15.9 injections. The reduction in CMT was 77.9 ± 101.4 μm, with absence of macular fluid in 71% of eyes. Ninety-four eyes of 89 patients completed 4-year follow-up. Thirty-three percent of eyes gained ≥ 15 ETDRS letters at the end of 4 years, and 66 (70%) eyes had no macular fluid at the end of the follow-up. The mean number of aflibercept injections received over 4 years was 19.3. The results suggest that good long-term morphological and functional treatment outcomes can be achieved using intravitreal aflibercept for nAMD in a real-life clinical setting.

In the past few years there have also been reports of nAMD treatment outcomes from global registries. One such registry is the Fight Retinal Blindness! (FRB!), which was developed with the aim of tracking outcomes of anti-VEGF treatment for nAMD in Australia, New Zealand and Switzerland from 2007 onwards [20]. The FRB! investigators reported 24-month outcomes in 136 eyes of 123 patients with nAMD treated with an aflibercept T&E regimen. Over 24 months, VA gain was +6.0 letters (98% with VA 70 letters or more at baseline maintained this VA up to 24 months). Both the mean number of injections and visits decreased from year 1 to year 2 for eyes receiving treatment for 24 months. The mean visual gain over 24 months with the T&E dosing regimen from the start was similar to previous RWE. In the FRB! study, mean VA before treatment initiation was at least 5 letters greater than other studies and visual outcomes were better. These better visual outcomes support the rationale for earlier treatment intervention and/or consideration of a T&E dosing regimen in year 1.

Practical Guidance

In 2020, a panel of UK retinal experts released practical guidance and recommendations to optimize the aflibercept T&E pathway for nAMD patients that could be implemented in clinical practice [21] (Fig. 1). According to their report, treatment-naïve nAMD patients should receive three consecutive monthly loading aflibercept injections. VA should be assessed at each visit during the loading phase and OCT (optional) obtained at visit 1 and visit 3, so as to provide early treatment response data. The fourth aflibercept dose is administered 8 weeks after the third loading dose (VA and OCT should be checked at visit 4 and at every subsequent visit, to assess the length of the next treatment interval). After the fourth injection, the treatment interval is either maintained with active disease or extended by 2 or 4 weeks with inactive disease. After the fifth injection, the treatment interval can be reduced, maintained

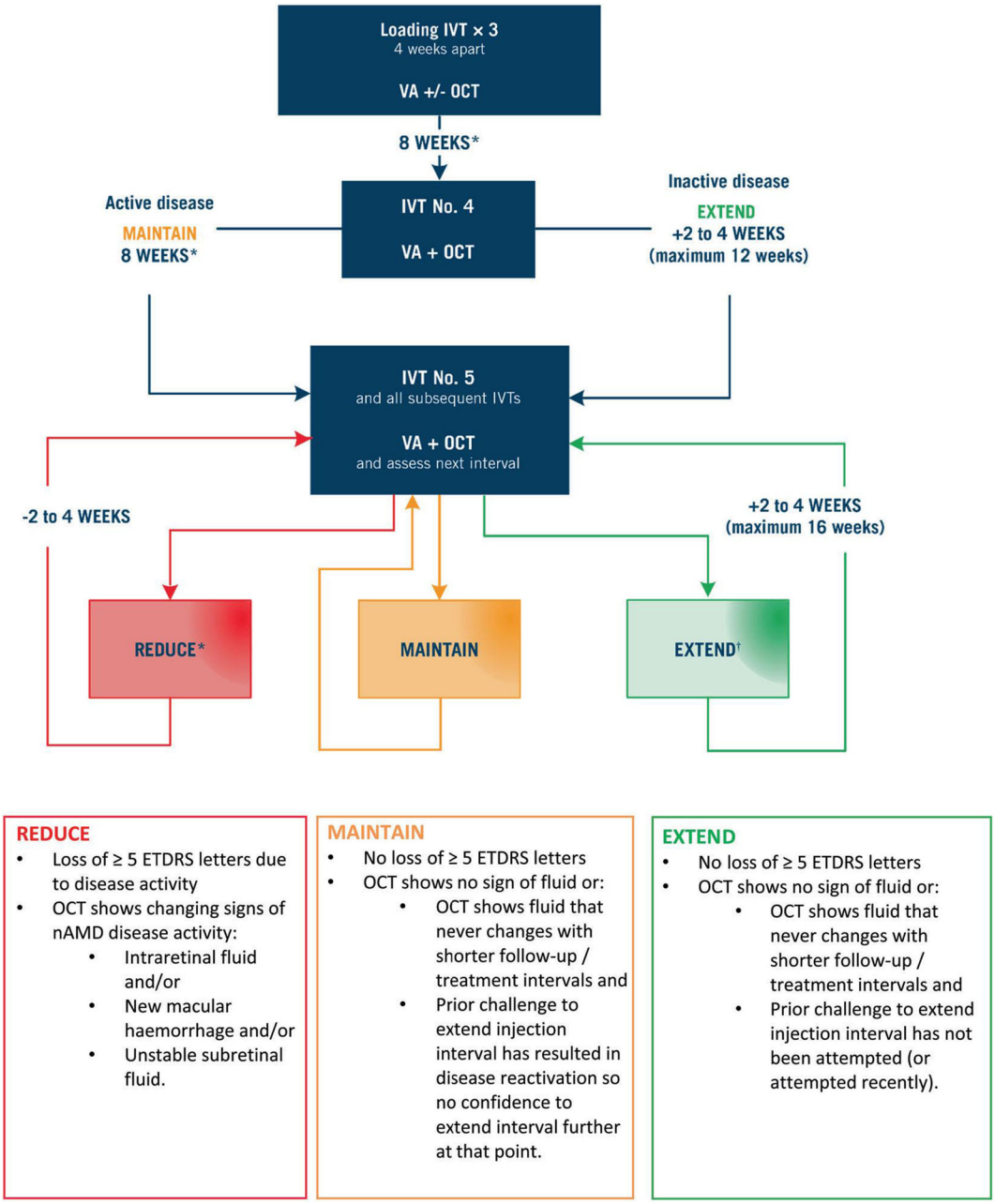

Fig. 1 The recommended aflibercept treat-and-extend protocol by the UK panel of retinal experts for nAMD

or extended, according to specific criteria (loss of 5 ETDRS letters or more due to disease activity, IRF and/or new macular haemorrhage and/or unstable SRF).

In PRN protocols, patients receive treatment injections in response to signs of disease activity, necessitating regular close monitoring. In real-world clinical settings, this is often difficult due to burden of visits on patients and healthcare services, leading to consequent undertreatment and poorer visual outcomes compared with landmark trials. The unpredictable nature of reactive rather than proactive treatment complicates capacity-planning in AMD services, leading to potential treatment delays. Conversely, the T&E dosing regimen

involves regular injections with the aim of minimizing risk of recurrence whilst individualizing patient care based on visual and anatomical response to treatment. Compared with fixed dosing, the T&E regimen involves a lower number of injections and visits in total but results in superior outcomes. Future challenges in the management of AMD include better use of multimodal imaging to improve our understanding of this disease entity, correlating imaging biomarkers with functional outcomes, and individualizing treatment to the patient in front of us.

DIABETIC RETINOPATHY AND MACULAR OEDEMA

The physiopathology of diabetic retinopathy (DR) and DMO is complex and still not well understood [22]. High levels of VEGF-A have been identified in the retina and vitreous of patients with DMO and DR [23]. This signal protein increases vascular permeability and progression from non-proliferative diabetic retinopathy (NPDR) to proliferative diabetic retinopathy (PDR) [23, 24]. Anti-VEGF drugs can successfully inhibit this protein and prevent the aforementioned consequences.

Randomized Clinical Trials

The efficacy and safety of intravitreal aflibercept for DMO compared with laser photocoagulation was demonstrated in the Da Vinci [25] trial, which was an industry-sponsored, randomized, double-masked, multicentre, phase 2 clinical trial comparing laser photocoagulation with monthly, bimonthly and PRN intravitreal aflibercept regimens. A total of 221 eyes with DMO were randomized in a 1:1:1:1:1 ratio to one of five treatment groups: aflibercept 0.5 mg every 4 weeks; 2 mg every 4 weeks; 2 mg every 8 weeks after three initial monthly doses; 2 mg dosing as needed after three initial monthly doses; or macular laser photocoagulation. At 24 weeks, eyes treated with aflibercept gained 8.6, 11.4, 8.5 and 10.3 letters in the respective groups, compared to a 2.5-letter gain in the laser group ($P \leq 0.0085$). At 1 year, the differences between the aflibercept groups and the laser group persisted, showing a mean VA gain in the aflibercept groups of 11.0, 13.1, 9.7 and 12.0 letters for the different dosing regimens, respectively, versus 1.3 letters for the laser group ($P \leq 0.0001$). At the end of the study, the mean reductions in CRT in the aflibercept groups were 165.4 μm, 227.4 μm, 187.8 μm and 180.3 μm, versus 58.4 μm in the laser group ($P < 0.0001$ vs laser). No significant differences in serious adverse events were observed among the different groups.

FDA approval of aflibercept for the treatment of DMO was based on two parallel clinical trials. VISTA ($N = 466$) and VIVID [26] ($N = 406$) were twin multicentre, randomized, double-masked, phase 3 clinical trials comparing the safety and efficacy of aflibercept (plus sham laser) in two different doses, 2 mg every 4 weeks (2q4) and 2 mg every 8 weeks (2q8), after five initial monthly doses compared to focal laser photocoagulation (with sham intraocular injections) in patients with visual loss due to DMO. Patients were randomized 1:1:1 to the different groups. The mean change in VA at 52 weeks was similar between the 2q4 (+10.5 letters, VISTA; +12.5 letters, VIVID) and 2q8 (+10.7 letters, VISTA and VIVID) groups, which was superior to macular laser (+0.2 letters, VISTA; +1.2 letters, VIVID). In both studies, more than 30% of patients in the aflibercept groups experienced an improvement in VA of ≥ 15 ETDRS letters at week 52, compared to 8–9% of patients in the laser groups. Moreover, the percentage of eyes in the laser group losing ≥ 15 letters of VA was 9.1% and 10.6% in VISTA and VIVID, respectively, compared to < 1% in the aflibercept groups.

In terms of CRT, in VISTA the mean CRT values were 185.9 μm and 183.1 μm in the aflibercept groups versus 73.3 μm in the laser group ($P < 0.0001$), and 195.0 μm and 192.4 μm versus 66.2 μm in the laser group ($P < 0.0001$) in VIVID. In addition, a proportion of eyes were observed to have ≥ 2-step improvement from baseline in the Diabetic Retinopathy Severity Scale (DRSS) score in both aflibercept groups compared to laser, implying regression of the underlying DR beyond the macula. The mean

number of injections received in the 2q4 and 2q8 groups was 11.8 and 8.4 in VISTA, and 12.2 and 8.7 in VIVID, respectively. Eyes in the laser group received an average of 2.7 and 2.1 laser treatments in VISTA and VIVID, respectively. The incidence of ocular and non-ocular adverse events was similar across treatment groups. It is important to highlight that in both VISTA and VIVID, the significant improvement in VA and CRT with aflibercept versus laser control was sustained through weeks 100 and 148, with similar efficacy, in both aflibercept groups [27, 28]. Sixty patients who completed the 3-year VISTA trial were enrolled in a phase IV, 2-year, open-label extension study. The main objective of the ENDURANCE [29] extension study was to evaluate the efficacy and safety of 2.0 mg intravitreal aflibercept retreatment for DMO through the fifth year of management with a PRN dosing regime. Twenty-five percent of patients required no retreatment, and of the patients who received at least one aflibercept treatment, the mean number of injections over 2 years was 9.5. Visual and CRT improvements achieved in VISTA were maintained with the PRN regime during ENDURANCE. However, 10% of eyes progressed from NPDR to PDR for the first time, with new PDR occurring approximately 1 year after the previous aflibercept injection. After 5 years of treatment, the majority of patients would still require ongoing clinical evaluation with repeat treatments, although a minority may be stable without ongoing anti-VEGF.

Protocol T [30] was a multicentre RCT designed by the DRCR.net study group to compare the efficacy of ranibizumab, aflibercept and bevacizumab for the treatment of patients with visual loss secondary to DMO. A total of 660 anti-VEGF treatment-naïve patients with baseline VA between 20/32 and 20/320 were recruited and randomized to receive injections of aflibercept 2 mg ($n = 224$), bevacizumab 1.25 mg ($n = 218$) or ranibizumab 0.3 mg ($n = 218$) every 4 weeks. For the first 24 weeks, injections were administered every 4 weeks unless VA was 20/20 or better with normal CRT and no improvement or deterioration in VA and CRT. After 24 weeks, injections were continued until VA and OCT were stable after two consecutive injections. Treatment could be resumed if the VA letter score or the retinal thickness worsened. Focal/grid laser treatments were initiated at or after 24 weeks only if persistent DMO did improve after at least two injections.

In terms of VA, primary outcome results at 1 year showed that all three drugs resulted in significant improvement in VA. When baseline vision was 20/32 to 20/40, there was no statistical difference among the three drugs. The mean improvement was 8.0 VA letter score with aflibercept, 7.5 with bevacizumab and 8.3 with ranibizumab ($P > 0.50$). When the baseline VA was 20/50 or worse, the mean improvement was 18.9 with aflibercept, 11.8 with bevacizumab and 14.2 with ranibizumab ($P < 0.001$ for aflibercept vs bevacizumab, $P = 0.003$ for aflibercept vs ranibizumab, and $P = 0.21$ for ranibizumab vs bevacizumab). The mean decrease in CST was 169 ± 138 µm with aflibercept, 101 ± 121 µm with bevacizumab, and 147 ± 134 µm with ranibizumab, with aflibercept and ranibizumab shown to be superior to bevacizumab ($P < 0.001$). The median number of injections was 9 in the aflibercept group, 10 in the bevacizumab group and 10 in the ranibizumab group ($P = 0.045$ for overall comparison). Laser photocoagulation was performed at least once between 24 and 48 weeks in 37% of aflibercept-treated eyes, 56% of bevacizumab-treated eyes and 46% of ranibizumab-treated eyes ($P < 0.001$ for overall comparison). No difference was observed in terms of serious adverse events.

At 2 years [31], the superior visual outcomes of aflibercept over ranibizumab that had been noted at 1 year were no longer present (18.1 letters aflibercept vs 16.1 ranibizumab, $P = 0.18$). Nevertheless, the superiority of aflibercept over bevacizumab was still present in eyes with 20/50 or worse baseline VA (18.1 letters aflibercept vs 13.3 bevacizumab, $P = 0.02$). CRT decreased on average by 171 ± 141 µm with aflibercept, 126 ± 143 µm with bevacizumab and 149 ± 141 µm with ranibizumab (aflibercept vs bevacizumab, $P < 0.001$; aflibercept vs ranibizumab, $P = 0.08$; ranibizumab vs bevacizumab, $P < 0.001$). No significant difference in the number of intravitreal injections

was noted across all three treatment groups, with 15, 16 and 15 over the full 2 years and 5, 6 and 6 in the second year alone in the aflibercept, bevacizumab and ranibizumab groups, respectively. The observed reduction in the need for anti-VEGF treatment for DMO was consistent with results from Protocol I [32]. Over 2 years, 41% of eyes required laser treatment in the aflibercept group compared with 64% for bevacizumab and 52% for ranibizumab (global $P < 0.001$).

The Protocol T 5-year follow-up study [33] explored standard care treatment distributions along with functional and anatomical outcomes 3 years after Protocol T participation ended. Participants were managed at the clinicians' discretion and recalled for a 5-year visit to assess clinical outcomes and characterize follow-up treatments for DMO. In total, 317 participants completed the 5-year visit. Between years 2 and 5, 68% of study eyes received at least one anti-VEGF treatment (median, 4). At 5 years, mean VA improved from baseline by 7.4 letters but decreased by 4.7 letters between 2 and 5 years. When baseline VA was 20/50–20/320, mean 5-year VA was 11.9 letters better than baseline but 4.8 letters worse than 2 years. When baseline VA was 20/32–20/40, mean 5-year VA was 3.2 letters better than baseline but 4.6 letters worse than 2 years. Mean CST decreased from baseline to 5 years by 154 µm and was stable between 2 and 5 years. It was not possible to compare pure treatment groups through 5 years since follow-up and treatment outside the study were not standardized, and about half of the eyes received an anti-VEGF agent that was different from the randomized treatment. The anti-VEGF agent received during the first 2 years did not lead to any statistically significant treatment group differences in VA at 5 years. The discordance between mean changes in VA and CST from years 2 to 5 does not appear to be explained by cataract formation.

Protocol V [34] was the first major multicentre randomized clinical trial evaluating patients with centre-involving DMO and good VA (20/25 or better). Eyes were randomly assigned to 2 mg of intravitreal aflibercept ($n = 226$) every 4 weeks, focal/grid laser photocoagulation ($n = 240$) treated at baseline with retreatment at 13 weeks if indicated, or observation ($n = 236$). Aflibercept was the rescue therapy for eyes in the laser photocoagulation or observation groups that had decreased VA from baseline by at least ≥ 2 lines on an eye chart at any visit or by 5–9 letters (1–2 lines) at two consecutive visits. At 2 years, the percentage of eyes with at least a 5-letter decrease in VA was 16%, 17% and 19% in the aflibercept, laser photocoagulation and observation groups, respectively. These rates of VA loss did not differ significantly between groups. Three-quarters of the eyes in the laser group and two-thirds of the eyes in the observation group did not receive anti-VEGF injections over the 2 years of follow-up.

A Cochrane meta-analysis [35] of anti-VEGF treatment in DMO was published in 2017. RCTs which compared anti-VEGF injections, another treatment, sham or no treatment in DMO were included. They found that aflibercept, bevacizumab and ranibizumab were all more effective than laser at improving vision by three or more lines after 1 year (high-certainty evidence). On average there was no change in VA with laser after 1 year, compared with a gain of one or two lines with anti-VEGF treatment. People receiving ranibizumab were less likely to gain three or more lines of VA at 1 year compared with aflibercept (moderate-certainty evidence). On average, people receiving ranibizumab had worse VA at 1 year (moderate-certainty evidence) and higher CRT (low-certainty evidence) compared with aflibercept.

Real-World Evidence Studies

The efficacy of intravitreal aflibercept in the treatment of centre-involving DMO in a real-world setting at 12 months has been previously described [36]. Ninety-nine eyes were analysed, with patients initiated on five monthly loading doses of intravitreal aflibercept injections, followed by PRN injections at the clinicians' discretion. At 12 months, the mean number of aflibercept injections received was 6.92, which is lower than the mean number of 9.2 in Protocol T. The mean change in VA was +9.9 letters while in Protocol T it was +13 letters in the

aflibercept group. The mean change in CRT was −128 µm compared to −169 µm in the aflibercept-injected eyes. The results of 36 months of RWE of aflibercept in patients with DMO have also been published [37]. This retrospective cohort included 64 eyes that received a loading phase of five monthly aflibercept injections, followed by injections if needed at the clinicians' discretion. The mean number of aflibercept injections received was 12.59 at month 36. The mean change in VA was +6.89 letters from baseline: subgroup analysis by baseline VA showed statistically greater improvement in vision in eyes with worse baseline VA, whilst maintaining stable vision in the subgroup with better baseline VA. The mean change in CRT was −119 µm at the end of the 36-month follow-up. The cohort gained statistically significant improvement in VA and anatomical outcomes over 3 years of treatment.

Another retrospective RWE study from the FRB! Registry [38] compared ranibizumab and aflibercept for DMO at 12 months for each drug in routine clinical practice. A total of 383 eyes were included (ranibizumab, $n = 166$ eyes; aflibercept, $n = 217$ eyes). Aflibercept and ranibizumab both improved vision and reduced macular thickness. Eyes receiving aflibercept tended to have lower mean VA and thicker CRT when they started treatment. In addition, greater reductions in CRT were observed with aflibercept as well as greater VA gains when baseline VA was 20/50 or worse. Treatment switches occurring within 12 months were uncommon (5%) and were more frequent from ranibizumab to aflibercept than vice versa.

A recent RWE study, APOLLON [39], described outcomes in patients with DMO following 12 months of intravitreal aflibercept monotherapy. Among the 147 patients included, 77 were treatment-naïve and 70 had been previously treated (laser, steroids or other anti-VEGF). The mean number of aflibercept injections at 12 months was 7.6 for treatment-naïve patients and 7.6 for previously treated patients. Treatment-naïve patients achieved better visual outcomes (+7.8 letters) than previously treated patients (+5.0 letters), even though mean baseline VA letter scores were similar between the two treatment cohorts. This study suggests that early and effective treatment is crucial for achieving the best visual outcomes.

Practical Guidance

A UK expert panel recently published a practical approach translating evidence into practice [40]. Three different aflibercept dosing regimens can be used in DMO: (1) The licensed posology, which is an intensive proactive dosing, 2 mg injection every month for five consecutive doses, followed by one injection every 2 months. After the first 12 months, the treatment interval may be extended. The monitoring schedule should be determined by the treating ophthalmologist (Fig. 2).

(2) The Protocol T regime which is characterized by PRN with 4-weekly monitoring in year 1 (with extension of intervals once stability has been reached), and monitor and extend in year 2 (Fig. 2). The loading phase plays a crucial role and the importance of intensive loading is supported by post hoc analysis of pooled VIVID and VISTA results, in which the proportion of eyes gaining ≥ 5 letters increased with each subsequent aflibercept injection.

(3) Treat-and-extend: there is currently limited evidence available on the use of the aflibercept T&E regime in DMO. Currently the benefits are under investigation in the VIOLET trial comparing the efficacy of this regimen,

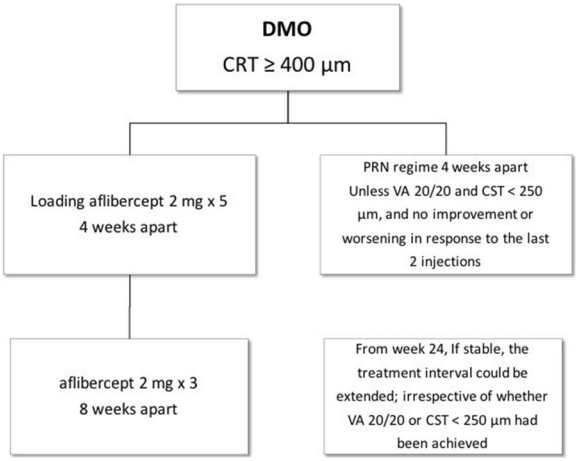

Fig. 2 The UK expert panel recommendations for DMO treatment with aflibercept

PRN, versus fixed dosing every 2 months (NCT02818998).

RETINAL VEIN OCCLUSION

Retinal vein occlusion includes central retinal vein occlusion (CRVO), branch retinal vein occlusion (BRVO) and less commonly hemiretinal vein occlusion (HRVO). CRVO is a result of impaired venous drainage with a resultant increase in venous pressure, reduced arterial perfusion and retinal ischaemia [41]. The estimated prevalence of CRVO worldwide is 2.5 million [41, 42]. The Beaver Dam population study revealed a cumulative 15-year incidence of 0.5% [43]. BRVO is a common retinal vascular disorder and second only to DR in prevalence, usually occurring at an arteriovenous crossing with arterial compression of the vein [44]. RVO is associated with increasing age, systemic hypertension, cardiovascular disease, diabetes mellitus, hyperviscosity syndromes and glaucoma [45, 46]. The most common cause of progressive loss of vision from vein occlusions is macular oedema [47]. VEGF is a cytokine released by hypoxic cells. It increases vascular permeability and leads to the development of macular oedema in vein occlusions [42, 48].

Randomized Clinical Trials

The COPERNICUS trial [49] was a landmark phase III RCT in the United States and included CRVO patients with centre-involving macular oedema with CRT of ≥ 250 microns. A total of 189 patients were included in the study and randomized to receive either aflibercept 2 mg monthly or sham injections for 24 weeks. Beyond this period, patients received PRN aflibercept if they had an increase in retinal thickness of > 50 microns, new or persistent intraretinal or SRF, or loss of ≥ 5 letters from best previous measurement with any increase in CRT. The proportion of patients who gained ≥ 15 letters compared to baseline was 56.1% versus 12.3% at week 24 in the aflibercept group; this extended to 55.3% versus 30.1% at week 52 and 49.1% versus 23.3% at week 100. The increase in the proportion of patients with visual gain at week 52 and week 100 in the sham group included those patients who received aflibercept due to the retreatment criteria explained above [49–51]. The mean change in CRT was −144.8 μm in the sham group versus −457.2 μm in the aflibercept group at 24 weeks. The mean change improved in the sham group when switched to receiving aflibercept post-24 months, to −343.3 μm at 100 weeks [49–51]. The study concluded that monthly aflibercept injections resulted in a 21-letter visual gain at 24 weeks compared to sham ($P = 0.001$) [49] and that a delay in treatment of 24 weeks in patients in the sham group resulted in worse visual outcomes when compared to the aflibercept group at 52 weeks and 100 weeks [50, 51]. Over 52 weeks, no patients in the aflibercept arm developed neovascularization, compared to five patients (6.8%) in the sham arm [51]. The safety profile of aflibercept in the treatment of CRVO was comparable to other anti-VEGF agents such as bevacizumab and ranibizumab.

The GALILEO trial [52] was a similar phase III randomized study conducted in Europe and Australia evaluating the effect of aflibercept in treating macular oedema secondary to CRVO. VA and CRT inclusion criteria were similar to the COPERNICUS trial. The study recruited a total of 177 patients, who were randomized to monthly aflibercept 2 mg ($n = 106$) or sham intravitreal injections ($n = 71$). The results were similar to those of the COPERNICUS trial, with the proportion of patients who gained ≥ 15 letters at 24 weeks totalling 60.2% in the aflibercept group versus 22.1% in the sham group [52]. The difference was statistically significant and was maintained through 52 weeks and 76 weeks despite visual gain after the introduction of aflibercept at week 24 in the sham group [52–54]. The mean change in CRT was −448.6 μm in the aflibercept group versus −169.3 μm in the sham group at 24 weeks, and this improved in the sham group to −306.4 μm at 76 weeks after the introduction of PRN aflibercept at 24 weeks as described above [52–54]. Within 52 weeks, 5.8% of patients in the PRN aflibercept arm developed neovascularization versus 8.8% in the sham group [53].

The conclusions of the study were similar to those found in the COPERNICUS trial.

The VIBRANT study [55] was a randomized phase III trial that evaluated the efficacy of monthly aflibercept injections versus macular laser photocoagulation in the treatment of macular oedema secondary to BRVO. A total of 183 patients were randomized to receive either monthly aflibercept 2 mg for 6 months followed by 8-weekly injections until week 48, or macular laser photocoagulation followed by sham injections for 48 weeks. The primary outcome was the proportion of eyes that gained ≥ 15 ETDRS letters from baseline, and secondary outcomes included change in vision from baseline and CRT. Rescue injections were available to the photocoagulation group from week 24 if specific criteria were met. The results showed that at 24 weeks, 52.7% of eyes in the aflibercept group gained ≥ 15 ETDRS letters compared to 26.7% in the photocoagulation group. This improved to 57.1% in the aflibercept group at 52 weeks compared to 41.1% in the photocoagulation group, with 80.7% in the laser group requiring rescue injections between 24 and 48 weeks. The mean change in letters was 17.0 versus 6.9 at 24 weeks and 17.1 versus 12.2 at 52 weeks in the aflibercept versus laser groups, respectively. In terms of CRT, the mean change was −280.5 versus −128 at 24 weeks and −283.9 versus −249.3 in the aflibercept and laser groups, respectively. These landmark trials proved the efficacy of aflibercept in the treatment of RVO.

Real-World Evidence Studies

A number of real-world studies have confirmed the efficacy of aflibercept in treatment-naïve patients with macular oedema from RVO, but also in cases that have been refractory to other previous anti-VEGF therapy. A recent prospective study [56] recruited 29 patients who were previously treated with ranibizumab without reduction in IRF following an average of 4.5 injections. Aflibercept was given on a PRN basis, with a considerable reduction in CRT from 633.67 μm to 234.62 μm and improvement in BCVA from 1.34 ± 0.66 logMAR to 0.91 ± 0.73 logMAR. The average number of aflibercept injections needed was 2.19. A prospective multicentre trial in Spain looked to evaluate the safety and efficacy of an aflibercept T&E regimen in patients with macular oedema secondary to CRVO [57]. A total of 24 eyes from 24 patients were treated with monthly aflibercept 2 mg for 3 months, after which treatment was individualized with a T&E regimen. Mean BCVA improved significantly in the 12-month follow-up period ($P = 0.0001$). Twelve patients (50%) gained ≥ 15 ETDRS letters. The study showed an improvement in VA in patients with a T&E regimen of aflibercept for macular oedema secondary to CRVO.

Current Anti-VEGF Guidelines for Treatment of Retinal Vein Occlusion

The European Society of Retina Specialists (EURETINA) guidelines [58] based on the literature and expert opinion in RVO recommend that intravitreal aflibercept in the treatment of macular oedema secondary to RVO should be started early for optimal outcomes. After fixed initial monthly injections, visual gain can largely be maintained with either extended intertreatment intervals or a PRN regimen. Intravitreal aflibercept lowers the risk of neovascularization in ischaemic CRVO, but long-term monitoring for this and macular oedema is advised.

MYOPIC CHOROIDAL NEOVASCULARIZATION

The physiopathology of myopic CNV is not fully understood; however, risk factors have been identified and described, including patchy retinal atrophy, lacquer cracks, and choroidal thinning and delays in angiographic choroidal filling [59].

Randomized Clinical Trials

The MYRROR study [60] was a phase III, multicentre, randomized, double-masked, sham-controlled study carried out in Asia. The main

objective was to evaluate the efficacy and safety of intravitreal aflibercept 2 mg for myopic CNV. A total of 122 patients were randomized 3:1 to aflibercept 2 mg or sham injection. In the intravitreal aflibercept arm, patients received one injection at baseline and PRN in the case of CNV persistence or recurrence at monthly visits. In the sham arm, patients received sham injections until week 20. At week 24, the aflibercept group gained 12.1 and the sham group lost 2 letters ($P < 0.0001$). At that stage the sham group was switched to receiving one intravitreal aflibercept and then PRN with monthly assessment until week 44. At the end of the follow-up, the aflibercept group gained 13.5 letters compared with 3.9 letters in the original sham groups ($P < 0.0001$). The aflibercept group received a median of two injections during the first 12 weeks and no injections thereafter. In the sham + intravitreal aflibercept group, the median number of injections was 2 and 1 in the third and fourth quarters, respectively. Intravitreal aflibercept showed important visual and anatomical benefits with a limited number of injections given.

Real-World Evidence Studies

Limited case series of myopic CNV treated with aflibercept in a real-world clinical setting have been published. Bruè et al. described a retrospective series of 38 treatment-naïve eyes with myopic CNV which were treated with an intravitreal aflibercept injection PRN regime and were followed for at least 18 months. The mean logMAR VA improved from 0.69 at baseline to 0.15 at 18 months ($P < 0.01$). The mean improvement in VA was significantly greater in the eyes of the younger myopic CNV group compared with those aged $\geq$ 50 years (0.21 vs 0.35; $P < 0.05$). Over half of the treated eyes obtained resolution with one aflibercept injection; 18.4% received two injections, 10.5% received three injections, 15.8% received four injections, and 5.3% received five injections [61]. Erden et al. compared anatomical and functional outcomes of intravitreal aflibercept and ranibizumab in the treatment of myopic CNV at 1 year. A total of 30 eyes were randomized to a aflibercept or ranibizumab PRN protocol. At 1 year, the two treatment modalities led to comparable anatomical outcomes, but aflibercept had better visual outcomes (0.69 logMar vs 0.09 logMar *P*:0.006) [62].

Practical Guidance

Anti-VEGF therapy should be considered as a first-line therapy [63]. A single injection of aflibercept 2 mg with additional PRN injections is required [59]. It is important to highlight that a delay in the treatment can affect visual outcomes, as was shown in the MYRROR study [61]. For the first 3 to 6 months. patients should be strictly monitored, and the decision to treat should be based on symptoms (metamorphopsia), reduction in VA and OCT findings [59].

ACKNOWLEDGEMENTS

During the peer review process, the manufacturer of the agent under review was offered an opportunity to comment on the article. Changes resulting from comments received were made by the author based on their scientific and editorial merit.

Funding. No funding or sponsorship was received for this study or publication of this article.

Authorship. All named authors meet the International Committee of Medical Journal Editors (ICMJE) criteria for authorship for this article, take responsibility for the integrity of the work as a whole, and have given their approval for this version to be published.

Authors' Contributions. Concept and design: Praveen J. Patel and Rodrigo Anguita; data analysis/interpretation: Rodrigo Anguita, Anastasia Tasiopoulou, Syed Shahid and Janice Roth; drafting of manuscript: Rodrigo Anguita, Anastasia Tasiopoulou, Syed Shahid, Janice Roth, Sing Yue Sim; critical revision of manuscript: Rodrigo Anguita, Anastasia Tasiopoulou, Syed Shahid, Janice Roth, Sing Yue Sim and

Praveen J. Patel; supervision: Praveen J. Patel. All authors read and approved the final manuscript.

Disclosures. Rodrigo Anguita, Anastasia Tasiopoulou, Syed Shahid, Janice Roth, Sing Yue Sim have nothing to disclose. Praveen J. Patel has lecturing, advisory board and travel grants from Bayer UK and has particpated in advisory boards with Novartis UK and lecturing fees from Roche UK.

Compliance with Ethics Guidelines. This study is based on previously conducted studies and does not contain any studies with human participants or animals performed by any of the authors.

Open Access. This article is licensed under a Creative Commons Attribution-NonCommercial 4.0 International License, which permits any non-commercial use, sharing, adaptation, distribution and reproduction in any medium or format, as long as you give appropriate credit to the original author(s) and the source, provide a link to the Creative Commons licence, and indicate if changes were made. The images or other third party material in this article are included in the article's Creative Commons licence, unless indicated otherwise in a credit line to the material. If material is not included in the article's Creative Commons licence and your intended use is not permitted by statutory regulation or exceeds the permitted use, you will need to obtain permission directly from the copyright holder. To view a copy of this licence, visit http://creativecommons.org/licenses/by-nc/4.0/.

REFERENCES

1. Eylea(aflibercept) injection, for intravitreal use [prescribing information]. Tarrytown, NY: Regeneron Pharmaceuticals; 2019

2. Regeneron announces FDA approval of EYLEA (aflibercept) injection for the treatment of wet age-related macular degeneration [press release]. Tarrytown, NY: Regeneron Pharmaceuticals, Inc; 2011.

3. 3.Regeneron Pharmaceuticals Vascular Endothelial Growth Factor (VEGF) Trap-Eye: Investigation of Efficacy and Safety in Wet Age-Related Macular Degeneration (AMD) (VIEW 1) ClinicalTrials gov [website on the Internet] Bethesda, MD: US National Library of Medicine; 2007[updated December 20, 2012]. http://clinicaltrials.gov/ct2/show/NCT00509795NLMidentifer:NCT00509795. Accessed 13 Nov 2012.

4. 4.Bayer Vascular Endothelial Growth Factor (VEGF) Trap-Eye: Investigation of Efficacy and Safety in Wet Age-Related Macular Degeneration (AMD) (VIEW 2) ClinicalTrialsgov [website on the Internet] Bethesda, MD: US National Library of Medicine; 2008[updated February 27, 2012]. http://clinicaltrials.gov/ct2/show/NCT00637377NLMidentifer:NCT00637377. Accessed 13 Nov 2012.

5. Congdon N, O'Colmain B, Klaver CC, et al. Eye Diseases Prevalence Research Group, Causes and prevalence of visual impairment among adults in the United States. Arch Ophthalmol. 2004;122: 477–85.

6. Bird AC, Bressler NM, Bressler SB, Chisholm IH, Coscas G, Davis MD, et al. An international classification and grading system for age-related maculopathy and age-related macular degeneration. The International ARM Epidemiological Study Group. Survey Ophthalmol. 1995;39(5):367–74 ([**PubMed: 7604360**]).

7. Spaide RF, Jaffe GJ, Sarraf D, et al. Consensus nomenclature for reporting neovascular age-related macular degeneration data: consensus on neovascular age-related macular degeneration nomenclature study group. Ophthalmology. 2020;127(5): 616–36. https://doi.org/10.1016/j.ophtha.2019.11.004 (**Epub 2019 Nov 14**).

8. Wong WL, Su X, Li X, Cheung CMG, Klein R, Cheng CY, et al. Global prevalence of age-related macular degeneration and disease burden projection for 2020 and 2040: a systematic review and meta-analysis. Lancet Glob Health. 2014;2(2): e106–16 (**PubMed: 25104651**).

9. Wong TY, Chakravarthy U, Kelin R, Mitchell P, Zlateva G, Buggage R, et al. The natural history and prognosis of neovascular age-related macular degeneration: a systematic review of the literature and meta-analysis. Ophthalmology. 2008;115(1): 116–26 (**PubMed: 17675159**).

10. Soubrane G, Cruess A, Lotery A, et al. Burden and health care resource utilization in neovascular age-related macular degeneration: findings of a multi-country study. Arch Ophthalmol. 2007;125(9): 1249–54. https://doi.org/10.1001/archopht.125.9.1249.

11. Brown MM, Brown G, Sharma S, et al. The burden of age-related macular degeneration: a value-based analysis. Curr Opin Ophthalmol. 2006;17(3): 257–66. https://doi.org/10.1097/01.icu.0000193079.55240.18.

12. Minassian D, Reidy A. Future sight loss UK 2: an epidemiological and economic model for sight loss in the decade 2010–2020. In: EpiVision and RNIB. 2009.

13. Kaiser P, Singer M, Tolentino M, Vitti R, Erickson K, Saroj N, et al. Long-term safety and visual outcome of intravitreal aflibercept in neovascular age-related macular degeneration. Ophthalmology Retina. 2017;1(4):304–13. https://doi.org/10.1016/j.oret.2017.01.004.

14. Ohji M, for the ALTAIR Investigators, et al. Efficacy and safety of intravitreal aflibercept treat-and-extend regimens in exudative age-related macular degeneration: 52- and 96-week findings from ALTAIR. Adv Ther. 2020;37:1173–87. https://doi.org/10.1007/s12325-020-01236-x.

15. Koh A, Lanzetta P, Lee WK, et al. Recommended guidelines for use of intravitreal aflibercept with a treat-and-extend regimen for the management of neovascular age-related macular degeneration in the Asia-Pacific region: report from a consensus panel. Asia-Pac J Ophthalmol. 2017;6:296–302.

16. Talks JS, United Kingdom Aflibercept Users Group, et al. First-year visual acuity outcomes of providing aflibercept according to the VIEW study protocol for age-related macular degeneration. Ophthalmology. 2016;123:337–43.

17. Eleftheriadou M, et al. Long-term outcomes of aflibercept treatment for neovascular age-related macular degeneration in a clinical setting. Am J Ophthalmol. 2017;174:160–8. https://doi.org/10.1016/j.ajo.2016.09.038.

18. Eleftheriadou M, et al. Three-year outcomes of aflibercept treatment for neovascular age-related macular degeneration: evidence from a clinical setting. Ophthalmol Ther. 2018;7:361–8. https://doi.org/10.1007/s40123-018-0139-5.

19. Lukic M, Eleftheriadou M, Hamilton R, Rajendram R, Bucan K, Patel P. Four-year outcomes of aflibercept treatment for neovascular age-related macular degeneration: Results from real-life setting. Eur J Ophthalmol. 2020. https://doi.org/10.1177/1120672120938565.

20. Gillies MC, et al. Efficient capture of high-quality data on outcomes of treatment for macular diseases: the Fight Retinal Blindness! Project Retina. 2014;34: 188–95.

21. Ross AH, et al. Recommendations by a UK expert panel on an aflibercept treat-and-extend pathway for the treatment of neovascular age-related macular degeneration. Eye. 2020. https://doi.org/10.1038/s41433-019-0747-x.

22. Stitt A, Lois N, Medina R, Adamson P, Curtis T. Advances in our understanding of diabetic retinopathy. Clin Sci. 2013;125(1):1–17. https://doi.org/10.1042/cs20120588.

23. Falcao M, Falcao-Reis F, Rocha-Sousa A. Diabetic retinopathy: understanding pathologic angiogenesis and exploring its treatment options. Open Circ Vasc Journal. 2010;3(2):30–42. https://doi.org/10.2174/1877382601003020030.

24. Ciulla T, Amador A, Zinman B. Diabetic retinopathy and diabetic macular edema: pathophysiology, screening, and novel therapies. Diabetes Care. 2003;26(9):2653–64. https://doi.org/10.2337/diacare.26.9.2653.

25. Do DV, Nguyen QD, Boyer D, et al. One-year outcomes of the da Vinci study of VEGF trap-eye in eyes with diabetic macular edema. Ophthalmology. 2012;119(8):1658–65.

26. Korobelnik JF, Do DV, Schmidt-Erfurth U, et al. Intravitreal aflibercept for diabetic macular edema. Ophthalmology. 2014;121:2247–54.

27. Brown D, Schmidt-Erfurth U, Do D, Holz F, Boyer D, Midena E, et al. Intravitreal aflibercept for diabetic macular edema. Ophthalmology. 2015;122(10): 2044–52. https://doi.org/10.1016/j.ophtha.2015.06.017.

28. Heier J, Korobelnik J, Brown D, Schmidt-Erfurth U, Do D, Midena E, et al. Intravitreal aflibercept for diabetic macular edema. Ophthalmology. 2016;123(11):2376–85. https://doi.org/10.1016/j.ophtha.2016.07.032.

29. Wykoff C, Ou W, Khurana R, Brown D, Lloyd Clark W, Boyer D. Long-term outcomes with as-needed aflibercept in diabetic macular oedema: 2-year outcomes of the ENDURANCE extension study. Br J Ophthalmol. 2017;102(5):631–6. https://doi.org/10.1136/bjophthalmol-2017-310941.

30. Wells JA, Glassman AR, Ayala AR, Jampol LM, Aiello LP, Antoszyk AN, Arnold-Bush B, Baker CW, Bressler NM, Browning DJ, Elman MJ. Aflibercept, bevacizumab, or ranibizumab for diabetic macular edema. N Engl J Med. 2015;372(13):1193–203. https://doi.org/10.1056/nejmoa1414264.

31. Wells J, Glassman A, Ayala A, Jampol L, Bressler N, Bressler S, et al. Aflibercept, bevacizumab, or ranibizumab for diabetic macular edema.

Ophthalmology. 2016;123(6):1351–9. https://doi.org/10.1016/j.ophtha.2016.02.022.

32. Elman M, Ayala A, Bressler N, et al. Intravitreal ranibizumab for diabetic macular edema with prompt versus deferred laser treatment—5-year randomized trial results. Ophthalmology. 2015;122:375–81.

33. Glassman A, Wells J, Josic K, Maguire M, Antoszyk A, Baker C, et al. Five-year outcomes after initial aflibercept, bevacizumab, or ranibizumab treatment for diabetic macular edema (Protocol T Extension Study). Ophthalmology. 2020. https://doi.org/10.1016/j.ophtha.2020.03.021.

34. Baker C, Glassman A, Beaulieu W, Antoszyk A, Browning D, Chalam K, et al. Effect of initial management with aflibercept vs laser photocoagulation vs observation on vision loss among patients with diabetic macular edema involving the center of the macula and good visual acuity. JAMA. 2019;321(19):1880. https://doi.org/10.1001/jama.2019.5790.

35. Virgili G, Parravano M, Evans J, Gordon I, Lucenteforte E. Anti-vascular endothelial growth factor for diabetic macular oedema: a network meta-analysis. Cochrane Database Syst Rev. 2017. https://doi.org/10.1002/14651858.cd007419.pub5.

36. Lukic M, Williams G, Shalchi Z, Sim D, Patel P, Keane P, et al. Intravitreal aflibercept for diabetic macular oedema: Moorfields' real-world 12-month visual acuity and anatomical outcomes. Eur J Ophthalmol. 2019;30(3):557–62. https://doi.org/10.1177/1120672119833270.

37. Lukic M, Williams G, Shalchi Z, Patel P, Hykin P, Hamilton R, Rajendram R. Intravitreal aflibercept for diabetic macular oedema in real-world: 36-month visual acuity and anatomical outcomes. Eur J Ophthalmol. 2020. https://doi.org/10.1177/1120672120925034.

38. Bhandari S, Nguyen V, Fraser-Bell S, Mehta H, Viola F, Baudin F, et al. Ranibizumab or aflibercept for diabetic macular edema. Ophthalmology. 2020;127(5):608–15. https://doi.org/10.1016/j.ophtha.2019.11.018.

39. Korobelnik JF, Daien V, Faure C, et al. Real-world outcomes following 12 months of intravitreal aflibercept monotherapy in patients with diabetic macular edema in France: results from the APOLLON study. Graefes Arch Clin Exp Ophthalmol. 2020;258:521–8. https://doi.org/10.1007/s00417-019-04592-9.

40. Pearce I, Bailey C, Fletcher E, Ghanchi F, Rennie C, Santiago C, et al. Translating evidence into practice: recommendations by a UK expert panel on the use of aflibercept in diabetic macular oedema. Eye. 2020;34(5):969–81. https://doi.org/10.1038/s41433-019-0615-8.

41. Yang LPH, McKeage K. Intravitreal aflibercept (Eylea®): a review of its use in patients with macular oedema secondary to central retinal vein occlusion. Drugs Aging. 2014. https://doi.org/10.1007/s40266-014-0176-2 (**Published online**).

42. Rogers S, McIntosh RL, Cheung N, et al. The prevalence of retinal vein occlusion: pooled data from population studies from the United States, Europe, Asia, and Australia. Ophthalmology. 2010. https://doi.org/10.1016/j.ophtha.2009.07.017 (**Published online**).

43. Liesegang, T. (2001). The epidemiology of retinal vein occlusion: The Beaver Dam Eye Study. Klein R,**Department of Ophthalmology and Visual Sciences, University of Wisconsin Medical School, Madison WI 53705. Klein BEK, Moss SE, Meuer SM. Tr Am Ophth Soc 2000;98:133–143. *American Journal Of Ophthalmology*, *131*(4), 538. https://doi.org/10.1016/s0002-9394(01)00903-5.

44. Spooner K, Hong T, Fraser-Bell S, Chang AA. Current outcomes of anti-VEGF therapy in the treatment of macular oedema secondary to branch retinal vein occlusions: a meta-analysis. Ophthalmologica. 2019. https://doi.org/10.1159/000497492 (**Published online**).

45. Kolar P. Risk factors for central and branch retinal vein occlusion: a meta-analysis of published clinical data. J Ophthalmol. 2014. https://doi.org/10.1155/2014/724780 (**Published online**).

46. Jiang Y, Mieler WF. Update on the use of anti-VEGF intravitreal therapies for retinal vein occulsion. Asia-Pac J Ophthalmol. 2017. https://doi.org/10.22608/APO.2017459 (**Published online**).

47. Sangroongruangsri S, Ratanapakorn T, Wu O, Anothaisintawee T, Chaikledkaew U. Comparative efficacy of bevacizumab, ranibizumab, and aflibercept for treatment of macular edema secondary to retinal vein occlusion: a systematic review and network meta-analysis. Expert Rev Clin Pharmacol. 2018. https://doi.org/10.1080/17512433.2018.1507735 (**Published online**).

48. Rhoades W, Dickson D, Nguyen QD, Do DV. Management of macular edema due to central retinal vein occlusion - The role of aflibercept. Taiwan J Ophthalmol. 2017. https://doi.org/10.4103/tjo.tjo_9_17 (**Published online**).

49. Boyer D, Heier J, Brown DM, et al. Vascular endothelial growth factor Trap-Eye for macular edema secondary to central retinal vein occlusion: six-month results of the phase 3 COPERNICUS

study. Ophthalmology. 2012. https://doi.org/10.1016/j.ophtha.2012.01.042 (**Published online**).

50. Brown DM, Heier JS, Clark WL, et al. Intravitreal aflibercept injection for macular edema secondary to central retinal vein occlusion: 1-year results from the phase 3 COPERNICUS study. Am J Ophthalmol. 2013. https://doi.org/10.1016/j.ajo.2012.09.026 (**Published online**).

51. Heier JS, Clark WL, Boyer DS, et al. Intravitreal aflibercept injection for macular edema due to central retinal vein occlusion: two-year results from the COPERNICUS study. Ophthalmology. 2014. https://doi.org/10.1016/j.ophtha.2014.01.027 (**Published online**).

52. Holz FG, Roider J, Ogura Y, et al. VEGF Trap-Eye for macular oedema secondary to central retinal vein occlusion: 6-Month results of the phase III GALILEO study. Br J Ophthalmol. 2013. https://doi.org/10.1136/bjophthalmol-2012-301504 (**Published online**).

53. Korobelnik JF, Holz FG, Roider J, et al. Intravitreal aflibercept injection for macular edema resulting from central retinal vein occlusion: one-year results of the phase 3 GALILEO study. Ophthalmology. 2014. https://doi.org/10.1016/j.ophtha.2013.08.012 (**Published online**).

54. Ogura Y, Roider J, Korobelnik JF, et al. Intravitreal aflibercept for macular edema secondary to central retinal vein occlusion: 18-month results of the phase 3 GALILEO study. Am J Ophthalmol. 2014. https://doi.org/10.1016/j.ajo.2014.07.027 (**Published online**).

55. Campochiaro PA, Clark WL, Boyer DS, et al. Intravitreal aflibercept for macular edema following branch retinal vein occlusion: the 24-week results of the VIBRANT study. Ophthalmology. 2015. https://doi.org/10.1016/j.ophtha.2014.08.031 (**Published online**).

56. Konidaris V, Al-Hubeshy Z, Tsaousis KT, Gorgoli K, Banerjee S, Empeslidis T. Outcomes of switching treatment to aflibercept in patients with macular oedema secondary to central retinal vein occlusion refractory to ranibizumab. Int Ophthalmol. 2018. https://doi.org/10.1007/s10792-017-0512-8 (**Published online**).

57. Garcia-Arumi J, Gómez-Ulla F, Amparo N, et al. Efficacy and safety of an aflibercept treat-and-extend regimen in treatment-naïve patients with macular oedema secondary to Central Retinal Vein Occlusion (CRVO): a prospective 12-month, single-arm, multicentre trial. J Ophthalmol. 2018. https://doi.org/10.1155/2018/8310350 (**Published online**).

58. Schmidt-Erfurth U, Garcia-Arumi J, Gerendas B, Midena E, Sivaprasad S, Tadayoni R, et al. Guidelines for the management of retinal vein occlusion by the European Society of Retina Specialists (EURETINA). Ophthalmologica. 2019;242(3):123–62. https://doi.org/10.1159/000502041.

59. Cheung C, Arnold J, Holz F, Park K, Lai T, Larsen M, et al. Myopic choroidal neovascularization. Ophthalmology. 2017;124(11):1690–711. https://doi.org/10.1016/j.ophtha.2017.04.028.

60. Ikuno Y, Ohno-Matsui K, Wong T, Korobelnik J, Vitti R, Li T, et al. Intravitreal aflibercept injection in patients with myopic choroidal neovascularization. Ophthalmology. 2015;122(6):1220–7. https://doi.org/10.1016/j.ophtha.2015.01.025.

61. Bruè C, Pazzaglia A, Mariotti C, Reibaldi M, Giovannini A. Aflibercept as primary treatment for myopic choroidal neovascularisation: a retrospective study. Eye. 2015;30(1):139–45. https://doi.org/10.1038/eye.2015.199.

62. Erden B, Bölükbaşı S, Baş E, Çakır A. Comparison of intravitreal aflibercept and ranibizumab for treatment of myopic choroidal neovascularization: one-year results—a retrospective, comparative study. J Ophthalmol. 2019;2019:1–6.

63. WangChen EY. Intravitreal anti-vascular endothelial growth factor for choroidal neovascularization secondary to pathologic myopia. Retina. 2013;33(7):1375–92. https://doi.org/10.1097/iae.0b013e31827d260a.