RISKS OF INTRAVITREOUS INJECTION: A COMPREHENSIVE REVIEW

RAMA D. JAGER, MD, MBA,* LLOYD PAUL AIELLO, MD, PHD,* SAMIR C. PATEL, MD,† EMMETT T. CUNNINGHAM, JR., MD, PHD, MPH‡

Purpose: To evaluate the prevalence of the most common serious adverse events associated with intravitreous (IVT) injection.

Methods: A systematic search of the literature via PubMed from 1966 to March 1, 2004, was conducted to identify studies evaluating the safety of IVT injection. Data submitted in New Drug Applications to the U.S. Food and Drug Administration for drugs administered into the vitreous were included where available. Serious adverse events reported in each study were recorded, and risk per eye and risk per injection were calculated for the following serious adverse events: endophthalmitis, retinal detachment, iritis/uveitis, intraocular hemorrhage, ocular hypertension, cataract, and hypotony. Rare complications also were noted.

Results: Data from 14,866 IVT injections in 4,382 eyes were analyzed. There were 38 cases of endophthalmitis (including those reported as pseudoendophthalmitis) for a prevalence of 0.3% per injection and 0.9% per eye. Excluding cases reported specifically as pseudoendophthalmitis, the prevalence of endophthalmitis was 0.2% per injection and 0.5% per eye. Retinal detachment, iritis/uveitis, ocular hypertension, cataract, intraocular hemorrhage, and hypotony were generally associated with IVT injection of specific compounds and were infrequently attributed by the investigators to the injection procedure itself. Retinal vascular occlusions were described rarely in patients after IVT injection, and it was unclear in most cases whether these represented true injection-related complications or chance associations.

Conclusion: The risk of serious adverse events reported after IVT injection is low. Nevertheless, careful attention to injection technique and appropriate postinjection monitoring are essential because uncommon injection-related complications may be associated with permanent vision loss.

RETINA 24:676–698, 2004

Over the last 2 decades, the use of intravitreous (IVT) injection has gained increasing acceptance in the therapeutic management of many intraocular diseases, particularly disorders affecting the posterior segment. A highly effective and frequently used means of administering antiviral agents in the treatment of cytomegalovirus (CMV) retinitis, direct injection of antiviral agents into the vitreous of patients with acquired immunodeficiency syndrome maximizes intraocular drug levels while minimizing the risk of toxicity associated with systemic administration of these agents.[1–11] In addition, IVT injection of various gases has been used as a less-invasive alternative to scleral buckling for the management of retinal detachment in the setting of pneumatic retinopexy[12–14] and for the administration of tissue plasminogen activator ([TPA] Retavase; Centocor, Malvern, PA)[15,16] in the treatment of submacular hem-

From *the Beetham Eye Institute, Joslin Diabetes Center and Department of Ophthalmology, Harvard Medical School, Boston, Massachusetts; the †Department of Ophthalmology and Visual Science, University of Chicago, Chicago, Illinois; and the ‡Department of Ophthalmology, New York University School of Medicine, New York, New York.

Samir C. Patel and Emmett T. Cunningham, Jr., are employees of Eyetech Pharmaceuticals, Inc., New York, NY.

Although the term "intravitreal" is used colloquially quite often, we have used "intravitreous" as the grammatically correct and preferred term in this review.

Reprints: Dr. Emmett T. Cunningham, Jr., Eyetech Pharmaceuticals, Inc., 3 Times Square, 12th Floor, New York, NY 10036; e-mail: emmett.cunningham@eyetech.com

1 FORMYCON-1094

orrhage and acute central retinal vein occlusion. Needle aspiration of the vitreous—procedurally similar to IVT injection—is used routinely to biopsy the vitreous. In addition to the long-standing practices of vitreous Gram staining, microbial culture, and sensitivity analysis in the setting of suspected endophthalmitis,[17] vitreous sampling may also be used to obtain DNA for polymerase chain reaction–based analyses for patients suspected of having necrotizing herpetic retinitis[18–22] or toxoplasmic retinochoroiditis.[23]

Recent investigations into the treatment of retinal neovascularization, retinal edema, and posterior segment inflammation have led to the development of new biologic and pharmacologic agents that are optimally administered directly into the vitreous. IVT injection of these compounds is being investigated, both as a method of achieving vitreous concentrations beyond those obtainable with systemic administration and as a means of avoiding potential systemic adverse effects. Several of these investigational agents, such as the therapeutic aptamer oligonucleotide pegaptanib sodium (Macugen; Eyetech Pharmaceuticals, New York, NY)[24–26] and the monoclonal antibody fragment ranibizumab (Lucentis; Genentech, San Francisco, CA),[27,28] are currently undergoing clinical evaluation for the treatment of neovascular age-related macular degeneration (AMD) and, in the case of pegaptanib sodium, for diabetic macular edema and retinal vein occlusion. In addition, the off-label use of IVT triamcinolone acetonide (Kenalog; Bristol-Myers Squibb, New York, NY) injection is under investigation for a number of disorders, including macular edema[29,30] and retinal neovascularization.[31–34]

Because the potential advantages of IVT injection have become more widely appreciated and the number of possible applications has grown, questions have arisen regarding risks associated with this route of administration. Several potential complications of IVT injection, such as endophthalmitis, retinal detachment, traumatic cataract, and intraocular hemorrhage, can be vision threatening. A sufficient body of literature now exists to support a thorough review of the risks associated with IVT injection in managing ocular diseases. To that end, as background, we present a brief historical overview of the use of IVT injection in humans over the last century and a synopsis of recently published studies on the pharmacokinetic properties of agents administered directly into the vitreous. We then present the results of a comprehensive, systematic review of the literature from which we calculated prevalence estimates for the most common complications associated with IVT injection.

The analyzed reports of IVT injection varied considerably in size, design, and indication, and in most instances, the reported rates of the various complications were quite low. Although efforts were made to distinguish the risks associated with the specific agents being administered from the risks related to the IVT injection procedure per se, in some instances, such distinctions were difficult to make. Together, these factors limit to some extent the generalizability of cross-study comparisons and analyses. Despite these inherent shortcomings, to our knowledge, this review represents the most extensive assessment of the risks associated with IVT injection compiled to date.

A Historical Perspective on the Use of IVT Injection

IVT injection has been used in the treatment of human ocular disease for nearly a century. Figure 1[24,25,27,28,34–48] presents a timeline of important advances in the use of this technique from its earliest therapeutic application through the present. Although this timeline is intended to highlight some of the major achievements in the development of IVT therapeutics, it is not meant to be an exhaustive compilation or to acknowledge the many excellent investigative studies that served as a foundation for these advances. Initially reported in 1911 by Ohm[35] as a means to introduce air for retinal tamponade and repair of detachment, the IVT administration of pharmaceutical agents was pioneered in the mid-1940s with the use of penicillin to treat endophthalmitis.[36,37] Unfortunately, at that time drug administration often was delayed for days or even weeks after the infection became established, making most of these early attempts unsuccessful. The technique was used infrequently, therefore.

During the 1950s and 1960s, the use of IVT injection still was limited to the administration of air[38] or silicone oil[39] in the treatment of retinal detachment. By the 1970s, the advent of newer antimicrobial agents, combined with the continued poor success of alternative treatment options, led to renewed interest in IVT therapy for endophthalmitis. Animal studies demonstrating the safety of this route of administration[49,50] were followed by the publication of two case series describing successful treatment of endophthalmitis using IVT injection in patients.[40,41] Although still considered experimental at that time,[51] wider use of IVT injection to treat endophthalmitis was being advocated due to the poor treatment outcomes reported with systemic administration of antibiotics, which generally produced suboptimal drug levels in the vitreous.[52]

The development of IVT injection for the treatment of ophthalmic conditions other than endophthalmitis and retinal detachment lagged even further behind,

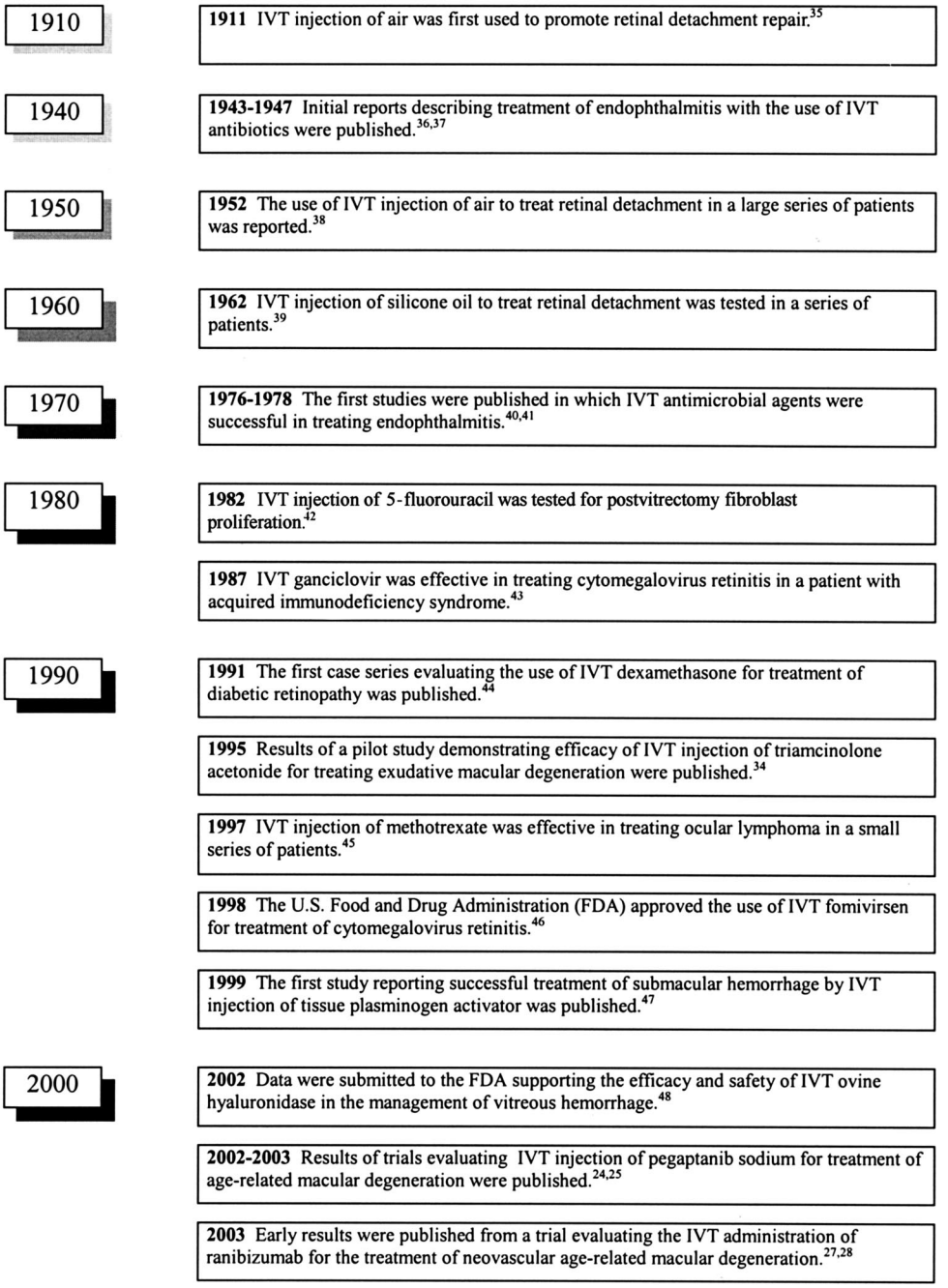

Fig. 1. A timeline of important advances in the use of intravitreous (IVT) injections to treat human ocular diseases.

perhaps because of perceived risks related to the procedure and because endophthalmitis and retinal detachment generally have the greatest likelihood for acute and irreversible vision loss. Although IVT injection of corticosteroids was evaluated in an animal model of ocular inflammation in the early 1980s,[53,54] there were no publications describing the use of IVT corticosteroids in humans until the 1990s. The first new application for IVT injection was not tried until 1982, when a pilot study assessing the efficacy and safety of 5-fluorouracil delivered as an IVT injection for the prevention of postvitrectomy fibroblast proliferation in patients with proliferative retinopathy was initiated.[42] This was followed in 1987 by the use of IVT ganciclovir sodium (Cytovine; Roche Pharmaceuticals, Nutley, NJ) in the treatment of CMV retinitis in a patient with acquired immunodeficiency syndrome.[43]

The gradually increasing confidence in the safety of IVT injection that emerged as a result of these studies led to the evaluation of IVT administration of a number of other agents throughout the 1990s. Blankenship[44] demonstrated in 1991 that dexamethasone was well tolerated but of no therapeutic value for postvitrectomy treatment of diabetic retinopathy. Penfold et al[34] in a pilot study demonstrated that triamcinolone acetonide, a longer-acting corticosteroid, was well tolerated in patients with exudative AMD. Other novel applications of IVT injection in the 1990s included the use of methotrexate for treatment of ocular lymphoma[45] and the injection of TPA for the management of submacular hemorrhage.[47] In 1998, fomivirsen sodium (Vitravene; Isis Pharmaceuticals, Carlsbad, CA), an antisense compound used to treat active CMV retinitis, was the first compound to be approved specifically for IVT injection by the U.S. Food and Drug Administration, representing a milestone achievement in the use of IVT therapy (Fig. 1).[46]

The pace of development of new applications for IVT injection continues to accelerate, with three new investigational drug products in clinical trials in the early 2000s. These include the vascular endothelial growth factor inhibitors ranibizumab[27]and pegaptanib sodium[24–26] for the treatment of neovascular AMD and ovine hyaluronidase (Vitrase; ISTA Pharmaceuticals, Irvine, CA),[48] which was recently approved by the U.S. Food and Drug Administration as a dispersion agent for other injected drugs and is still seeking approval for the treatment of vitreous hemorrhage.[55] The use of IVT injection as a method for localized adenovirus vector–mediated gene transfer to treat retinitis pigmentosa and AMD is also being explored.[56,57] With numerous novel ophthalmic therapies currently poised to enter into clinical trials, it is likely that the number of drugs under development for IVT injection will continue to increase rapidly.

Pharmacokinetic Characteristics of Compounds Injected Into the Vitreous

Drug concentrations in the vitreous are determined not only by the amount of drug given but also by the distribution and clearance of such compounds.[58,59] As with other routes of drug administration, pharmacokinetic characteristics are dependent on both the anatomical and physiologic features at the site of administration[58–60] and the physicochemical properties of the agent administered.[61,62] Although several investigators have explored the pharmacokinetic properties of the IVT injection of selected compounds in animal models[58–60,62,63] and to a limited extent in humans[64–66] over the past 2 decades, this topic remains complex and incompletely understood.

The composition of the vitreous is unique in that it is a highly hydrated, avascular, gelatinous body containing 98% water. Vitreous structural elements composed of type II collagen and hyaluronic acid occupy <1% of the total volume.[61] The human eye contains 3 mL to 4 mL of vitreous humor.[67] The vitreous can move during eye motion, particularly in the elderly who normally have a more liquefied vitreous than younger individuals.[61] By 80 years of age, approximately one half of the vitreous in most people is estimated to exist in a liquid state.[68] Although little is known about the effect of age on the disposition of compounds administered directly into the vitreous, such age-related changes in vitreous characteristics merit consideration because many indications for IVT injection affect elderly patients disproportionately.

Although there is a relative barrier between the anterior and the posterior segments of the eye, injected substances move throughout the vitreous fairly readily by either diffusion or bulk flow. Whereas bulk flow tends to be the primary means of movement when the vitreous is formed, when the vitreous body is partly removed, degenerated, or collapsed, the exchange movement tends to be due largely to diffusion. Gradients exist in both directions between the vitreous and plasma. These gradients are a result of several mechanisms, including diffusion and bulk flow processes within the vitreous body as mentioned above, the presence of physiologic blood–ocular barriers vis-à-vis active and passive transport, and metabolism within the eye itself.[69]

Alterations of the normal anatomy and physiology of the eye and the size of the administered compound have been demonstrated to be factors that impact the distribution and elimination of drugs from the vitreous in animal studies. A history of vitrectomy, aphakia, or pseudophakia has been shown to increase the rate of distribution and clearance of amphotericin B, for example. Radiolabeled amphotericin B elimination from aphakic, vitrectomized rabbit eyes occurred in 1.8 days compared with 15.1 days for normal rabbit eyes.[59] A similarly rapid clearance of triamcinolone acetonide in aphakic, vitrectomized rabbit eyes (6.5 days) compared with clearance from aphakic, nonvitrectomized eyes (16.8 days) and normal, phakic, nonvitrectomized eyes (41 days) was reported by Schindler et al.[60] In this latter study, high-performance liquid chromatography was unable to detect the drug in 5 of 6 normal rabbit eyes at 21 days after IVT injection. Uptake of triamcinolone acetonide by ocular tissues is apparently quite slow, because <1% of the compound was found in the iris ciliary body, lens,

retina, pigment epithelium, and sclera at 72 hours after injection.[63]

The pharmacokinetic properties of compounds in the vitreous have been observed to change in the setting of inflammation or infection, such as endophthalmitis. Using a rabbit model, Coco et al[58] estimated that the half-life of vancomycin in normal, uninflamed eyes was ≈62 hours, compared with 14 hours in eyes in which endophthalmitis had been experimentally induced by injecting *Staphylococcus aureus* into the vitreous, a >4-fold increase. The reverse was true for plasma concentrations. These data led the investigators to suggest that the elimination of vancomycin was enhanced in the setting of inflammation or infection, most probably due to breakdown of the blood–retinal barrier, which when intact acts to limit drug clearance.[58]

The size of the administered compound has been shown to affect the half-life in the vitreous. Full-length radiolabeled humanized monoclonal antibodies (molecular weight, ≈150 kd) injected into the vitreous of rhesus macaques were found not to penetrate the inner limiting membrane of the retina, while Fab antibody fragments (molecular weight, ≈50 kd) diffused through the neural retina to the retinal pigment epithelial layer within 1 hour.[62] Consequently, the half-life in the vitreous was 5.6 days for the full-length antibody and 3.2 days for the Fab antibody fragment.[62]

Specific pharmacokinetic profiling of compounds administered into the vitreous in humans has been limited. Two studies have evaluated the duration of detectable concentrations of triamcinolone acetonide in aqueous humor samples.[64,65] Neither study attempted to identify the route of elimination of triamcinolone acetonide from the eye or the levels of compound that could be achieved in various ocular compartments after IVT injection. Pharmacokinetic studies of pegaptanib sodium injected into the vitreous humor of rhesus monkeys have shown that vitreous humor and plasma concentrations were linearly related to the dose administered with a half-life of ≈4 days. In addition, pegaptanib sodium sampled from the vitreous at 28 days was fully active.[67]

Recent computer simulations have suggested that both anterior and posterior routes of elimination may be important in the clearance of drugs from the vitreous.[61] Although the crystalline lens is highly impermeable to water and to many drugs, the anterior hyaloid membrane, which separates the vitreous from the aqueous, is thin and porous, offering little resistance to diffusion. Because aqueous turnover is very rapid, with a residence time in the eye of ≈2.5 hours,[61] in aphakic and pseudophakic patients aqueous clearance can represent a major route of elimination of compounds injected into the vitreous. In contrast, elimination by the posterior route is facilitated by active unidirectional drug transport at the posterior vitreous surface, as demonstrated by studies in which fluorescein movement through the vitreous was monitored.[66] The computer model predicts that a relatively small molecule will be quickly cleared from the vitreous by absorption through the retina or by release into the aqueous.[61] In contrast, a larger molecule would diffuse more slowly, relying on bulk flow to transverse the vitreous, and clearance will occur primarily through the retina and not the aqueous.[61] Although these findings are largely hypothetical in the absence of empirical data, they do suggest that the pharmacokinetic properties of compounds administered into the vitreous can be complex and influenced by a number of factors.

Assessment of Complications Associated With the Use of IVT Injection

Methods

A systematic review of the literature via PubMed from 1966 to March 1, 2004, using the search terms "intravitreous," "intravitreal," and "endophthalmitis" was conducted to identify studies and case series reporting the safety of IVT injection. The search was limited to primary reports published in English. Publications also were retrieved using the "related articles" function of PubMed, and bibliographies from all articles selected for analysis were reviewed to identify additional citations. More than 220 references were reviewed.

The following types of reports were included: (a) all randomized, controlled human clinical trials using IVT injection; (b) prospective or retrospective case series that included ≥20 eyes; and (c) safety data from U.S. Food and Drug Administration New Drug Applications for compounds not yet approved for use in the United States where adverse events related to IVT injection were reported. The following types were excluded: (a) reports in which compounds were administered into the vitreous through sclerotomy incisions during vitrectomy; (b) reports in which compounds were administered by IVT injection in conjunction with other ocular procedures, such as scleral buckling or vitrectomy; (c) reports in which IVT injections were administered in eyes as a treatment for endophthalmitis; and (d) reports that, in the opinion of the authors, lacked relevant data, provided data of unacceptable quality, or duplicated data sets found in more-comprehensive publications. There were no exclusions based on the length of the follow-up period.

The following information was extracted from each report: (a) information on study design; (b) indication for IVT injection; (c) description, dose, and volume of substance injected; (d) injection procedure and any preinjection preparation, such as the use of topical antibiotics; (e) number of eyes in which IVT injections were administered; (f) total number of injections administered; (g) any complications or serious adverse events noted; and (h) duration of follow-up. The rate, or prevalence, of seven serious adverse events—endophthalmitis, retinal detachment, iritis/uveitis, intraocular hemorrhage, ocular hypertension, cataract, and hypotony—was recorded. Both prevalence per eye and prevalence per injection were then calculated. Other rare, but potentially serious, adverse events deemed by the reviewers to be possibly related to IVT injection also were noted.

Results

Publications identified via the literature search on IVT injection that met the study criteria outlined under Methods are summarized in Table 1,[1–8,10,11,70] Table 2,[29–34,71–73]and Table 3,[12–16,25,48,74–76] and results of combined analyses are presented in Table 4. CMV retinitis in patients with acquired immunodeficiency syndrome was the indication that yielded the greatest number of publications analyzed, with a total of 10 (Table 1). The antiviral compounds cidofovir (Vistide; Gilead Sciences, Foster City, CA),[4–7] ganciclovir (with or without intravenous foscarnet sodium [Foscavir; AstraZeneca Pharmaceuticals, Wilmington, DE]),[1–3,10,11] and fomivirsen[8,70] were used in 909 eyes. There were no reports describing IVT administration of foscarnet sodium alone with sufficient numbers of eyes to meet the inclusion criteria for this review. Treatment of CMV retinitis entailed administering multiple IVT injections, usually once every week or every other week for extended periods, resulting in both the greatest number of total injections (n = 10,839) and the greatest number of injections per eye. It should be noted, however, that patients with CMV retinitis are at greatly increased risk for retinal detachment due to the presence of large areas of retinal necrosis. Whether acquired immunodeficiency syndrome–associated immunosuppression per se predisposes human immunodeficiency virus–positive patients to procedure-related bacterial infections is largely unknown.

Another common use for IVT therapy was triamcinolone acetonide in the off-label treatment of retinal neovascularization[29,31–34] and macular edema,[29,71–73] with nine publications reporting treatment complications. These included three prospective studies,[31,33,34] two case series,[30,32] and four retrospective chart reviews (Table 2).[29,71–73] In these reports, a total of 1,703 eyes received 1,739 injections of triamcinolone acetonide. The three largest retrospective chart reviews were conducted specifically to investigate the prevalence of endophthalmitis and provided information on 1,442 eyes and 1,466 injections.[71–73]

The remaining published prospective studies and case series covered the use of IVT injection for a spectrum of indications (Table 3), including IVT injection of gas during pneumatic retinopexy to treat retinal detachment,[12–14,74,75] IVT injection of hyaluronidase[48] and TPA[15] for vitreous hemorrhage and submacular hemorrhage, respectively, IVT injection of TPA for retinal vein occlusion,[16] IVT injection of a vascular endothelial growth factor–blocking agent for choroidal neovascularization in patients with neovascular AMD,[25] and IVT injection of methotrexate to treat ocular lymphoma.[76]

Sufficient data were available from the literature search to estimate individually the prevalence of complications associated with IVT injection of antiviral compounds and triamcinolone acetonide, while data for all other indications for IVT injection were grouped together. Complications considered the most serious and thereby warranting specific scrutiny included endophthalmitis, retinal detachment, iritis/uveitis, ocular hypertension, intraocular hemorrhage, cataract, and hypotony. Whenever possible, complications caused by the IVT injection procedure were distinguished from those attributable to the condition being treated or those related to the administration of specific therapeutic compounds. The following section provides an estimation of the prevalence of each complication and includes a brief discussion of each complication within the context of overall risk of IVT injection.

Endophthalmitis

Reports of endophthalmitis associated with administration of antiviral agents. The prevalence of endophthalmitis in eyes with CMV retinitis treated with IVT therapy was estimated from the studies listed in Table 1 to be 1.3% (12/909) per eye and 0.1% (12/10,839) per injection. In the largest clinical trial reviewed, two cases of endophthalmitis were reported in association with 1,791 IVT injections of fomivirsen in 330 eyes.[8] In the second largest trial reviewed, a case series involving 156 eyes and 2,890 IVT injections of ganciclovir, endophthalmitis was diagnosed in four eyes, two of which were lost to total retinal necrosis.[1] Microbial culture results were not presented in either report. Two other series involving patients receiving IVT ganciclovir also identified cases of endophthalmi-

Table 1. SAEs Reported from Studies Involving IVT Administration of Antiviral Compounds*

Study	Study Type	Indication	Compound/Dose/Follow-up	No. Eyes	No. Injections†	EO	RD	I/U	HE	OH‡	CT	HP	Other SAEs/Comments
Baudouin, 1996[1]	CS	CMV retinitis	Ganciclovir/350 μg/19.8 ± 2.9 wk (mean), 1 wk–32 mo (range)	156	2,890	4	1						
Cochereau-Massin, 1991[2]	POS	CMV retinitis	Ganciclovir/400 μg/9 wk (mean), 1–39 wk (range)	64	710		5		2				5 optic disk atrophy, 7 nonocular CMV infection
Hodge, 1996[3]	POS	CMV retinitis	Ganciclovir/400 μg/53.1 wk (mean), 6–156 wk (range)	57	3,027	1	5						RD at areas of retinal necrosis
Kirsch, 1995[4]	CS	CMV retinitis	Cidofovir/20 μg/87.8 d (mean), 38–186 d (range)	24	37		2	5				2	1 choroidal detachment
Rahhal, 1996[5]	CS	CMV retinitis	Cidofovir/20 μg/15 wk (mean), 0–58 wk (range)	53	168		1	29				4	2 transient and 2 irreversible HP; 1 macular scarring; 2 extraocular CMV infection
Taskintuna, 1997[6]	CS	CMV retinitis	Cidofovir/10 μg/65.3 d (mean), 17–140 d (range)	27	46			1					
Taskintuna, 1997[7]	CS	CMV retinitis	Cidofovir/20 μg/177 d (mean), 31–674 d (range)	93§	246		4‖	18			10	16	13 transient and 3 irreversible HP; 18 posterior synechiae
Vitravene, 2002[8, 70]	RCT	CMV retinitis	Fomivirsen/165 or 330 μg/1–1,024 d (range)	330	1,791	2	33	126	21¶	54	33	6	4 CME; 3 RAO; 5 retinal tears; 1 RVO; 4 macular degeneration; 1 optic atrophy; 1 orbital cellulitis
Young, 1992[11]	RS	CMV retinitis	Ganciclovir/2 mg/20.4 wk (mean), 2–59 wk (range)	31	341	2			1				Subfoveal HE secondary to increased volume injected
Young, 1998[10]	CS	CMV retinitis	Ganciclovir/2 mg/8–132 wk (range)	74	1,583	3	3				1		
Total				909	10,839	12	54	179	24	54	44	28	
Prevalence per eye (%)						1.3	5.9	19.7	2.6	5.9	4.8	3.1	
Prevalence per injection (%)						0.1	0.5	1.7	0.2	0.5	0.4	0.3	

* Blank spaces indicate no reported events.
† One injection per eye was counted when the number of administered injections was not provided.
‡ Includes intraocular pressure elevations that were reported on a patient-specific basis.
§ A total of 115 eyes were administered injections; safety data were presented only for 93 eyes that had at least 1 month of follow-up.
‖ Six RDs were reported: two occurred subsequent to vitrectomy and were not counted, and four did not occur immediately after the procedure and were considered by the authors to be unrelated to the injection but were included.
¶ Includes 20 retinal HEs and 1 hyphema.
SAEs, serious adverse events; IVT, intravitreous; EO, endophthalmitis; RD, retinal detachment; I/U, iritis/uveitis/vitritis/anterior chamber inflammation; HE, hemorrhage; OH, ocular hypertension; CT, cataract; HP, hypotony; CS, case series; CMV, cytomegalovirus; POS, prospective open study; RCT, randomized, controlled trial; CME, cystoid macular edema; RAO, retinal artery occlusion; RVO, retinal vein occlusion; RS, retrospective study.

Table 2. SAEs Reported from Studies Involving IVT Administration of TCA*

Study	Study Type	Indication	Compound/Dose/ Follow-up	Total No. Eyes (Phakic Eyes)	No. Injections†	EO	RD	I/U	HE	OH‡	CT	HP	Other SAEs/Comments
Bakri, 2003[29]	RS	DME, CNV, other	TCA/4 mg/12 wk (min)	43 (18)	43					21			
Danis, 2000[31]	RCT	AMD	TCA/4 mg/6–12 mo (min)	16 (7)	16					4	4		
Gillies, 2003[33]	RCT	AMD	TCA/4 mg/12 mo (min)	75 (56)	75					31	4		1 HRVO
Jonas, 2003[32]	CS	AMD	TCA 25 mg/1st Inj: 7.46 mo (mean), 3.1–19.57 mo (range); 2nd Inj: 5.7 mo (mean), 3.9–8.9 mo (range); 3rd Inj: 5.7 mo (mean)	71 (48)	78					35	NR§		
Jonas, 2003[30]	CS	DME	TCA/25 mg/6.64 ± 6.1 mo (mean)	26 (18)	27					9	NR§		
Penfold, 1995[34]	POS	AMD	TCA/4 mg/3–18 mo (range)	30 (NR)	34						5		
Subtotal				261 (147)	273					100	13		
The following studies are used in calculating the prevalence of EO only.‖¶													
Moshfeghi, 2003[71]	RS	CME, DME, CNV	TCA/4 mg/1–9 mo (range)	922	922	8	—	—	—	—	—	—	0 P-EO; 8 culture positive
Nelson, 2003[72]	RS	DME, CME, CRVO	TCA/4 mg/2–9 mo (range)	416	440	9	—	—	—	—	—	—	7 P-EO; 2 culture positive
Roth, 2003[73]	RS	DME, CME	TCA/1 or 4 mg/NR	104	104	7	—	—	—	—	—	—	7 P-EO; 0 culture positive
Total				1,703	1,739	24					100	13	
Prevalence per eye (%)						1.4				38.3	9.9**		
Prevalence per injection (%)						1.4				36.6	9.9**		
Prevalence per eye excluding P-EO (%)						0.6							14 P-EO; 10 culture positive
Prevalence per injection excluding P-EO (%)						0.6							14 P-EO; 10 culture positive

* Blank spaces indicate no events reported. Dashes indicate data excluded from calculations.
† One injection per eye was counted when the number of administered injections was not provided.
‡ Includes intraocular pressure elevations that were reported on a patient-specific basis.
§ CT reported as a mean index (of opacification) that increased significantly in patients receiving TCA injection.
‖ Retrospective chart reviews designed to determine the frequency of EO after TCA injection. Data were not obtained for other adverse events. The eyes and injections were not included in calculating the prevalence of the other adverse events.
¶ Culture-positive infectious EO was distinguished from noninfections EO/pseudo-EO in these studies. The prevalence of EO was calculated with and without cases of noninfectious ED/pseudo-EO.
** Included were studies in which the number of CTs (n = 8) and the number of phakic eyes (n = 81) only were reported.
SAEs, serious adverse events; IVT, intravitreous; TCA, triamcinolone acetonide; EO, endophthalmitis; RD, retinal detachment; I/U, iritis/uveitis/vitritis/anterior chamber inflammation; HE, hemorrhage; OH, ocular hypertension; CT, cataract; HP, hypotony; RS, retrospective study; DME, diabetic macular edema; CNV, choroidal neovascularization; RCT, randomized, controlled trial; AMD, age-related macular degeneration; HRVO, hemiretinal vein occlusion; CS, case series; Inj, injection; NR, not reported; POS, prospective, open study; CME, cystoid macular edema; P-EO, noninfectious endophthalmitis/pseudoendophthalmitis; CRVO, central retinal vein occlusion; ME, macular edema.

Table 3. SAEs Reported from Studies Involving IVT Administration of Other Compounds*

Study	Study Type	Indication	Compound/Dose/Follow-up	No. Eyes	No. Injections†	EO	RD	I/U	HE	OH‡	CT	HP	Other SAEs/Comments
Eyetech Study Group, 2003[25]	POS	AMD	Pegaptanib sodium/3 mg/ 3 mo (min)	21	61			7		1			
Friberg, 1988[75]	CS	RD	Sulfur hexafluoride gas/ 6 mo (min)	22	22								3 vitreous extrusions
Friberg, 2001[74]	CS	RD	Sulfur hexafluoride or perfluoropropane gas/ 1–5 y (range)	40	40								5 new retinal breaks
Hattenbach, 2001[15]	CS	Submacular hemorrhage	TPA (50 μg) + sulfur hexafluoride gas/6 mo (mean), 4–18 mo (range)	43	52§				3	2			1 choroidal neovascular membrane
Hilton, 1987[12]	CS	RD	Sulfur hexafluoride or perfluoropropane gas/6 mo (min)	100	100			2	1				1 detachment of the pars plana epithelium; 7 new missed retinal breaks; 3 proliferative vitreoretinopathy 3 macular pucker
Lahey, 1999[16]	CS	RVO	TPA/65 100 μg/6 mo (min)	26	26								3 ME; 1 CRVO; 10 iris neovascularization; 2 small exudative retinal detachments
Sebag, 1993[13]	CS	RD	Air/17.1 ± 8.6 mo (mean), 6–33 mo (range)	45	46								Postoperative premacular membrane; proliferative vitreoretinopathy
Smith, 2002[76]	RS	Ocular lymphoma	Methotrexate/400 μg/6–35 mo (range)	26	494‖	1¶			2				Maculopathy; 73% had CT progression
Tornambe, 1989[14]	RCT	RD	Sulfur hexafluoride or perfluoropropane gas/ 6–12 mo (min)	103	103	1		1**	3	1	1		A case of "malignant glaucoma" is listed as OH; 24 retinal breaks††; 5 choroidal detachment; 2 vitreous incarcerations in paracentesis site; 2 anterior hyaloidal gas injections; 1 anterior lens capsule touch; 2 subretinal gas; 3 proliferative vitreoretinopathy (grade C or D)
Subtotal excluding ovine hyaluronidase				426	944			10	9	4	1		
Vitrase, 2004[48]	RCT	Vitreous hemorrhage	Ovine hyaluronidase/335.4 d (mean), 1–1,412 d (range)	1,344	1,344	2	62	650	143	7	185	5	31 macular edema; 14 maculopathy; 6 posterior capsule opacification; 1 eyelid ptosis; 2 macular degeneration; 5 strabismus, 5 blindness; 1 transient blindness; 3 toxoplasmal eye infections; 3 retina scars; 1 RVO; HEs included 123 vitreous, 17 hyphema, 3 retinal
Total				1,770	2,288	2	62	660	152	11	186	5	
Prevalence per eye (%)						0.1	3.5	37.3	8.6	0.6	10.5	0.3	
Prevalence per injection (%)					0.1	2.7	28.8	6.6	0.5	8.1	0.2		
Prevalence per eye (%)‡‡							0.0	2.4	2.1		0.2		
Prevalence per injection (%)‡‡							0.0	1.1	1.0		0.1		

* Blank spaces indicate no events reported.

† One injection per eye was counted when the number of administered injections was not provided.

‡ Includes intraocular pressure elevations that were reported on a patient-specific basis.

§ The two injections administered consecutively at each visit were counted as one event because complications resulting from the separate injections were indistinguishable.

‖ Based on median number of injections.

¶ This case was reported by the authors as "sterile endophthalmitis" based on negative microbial isolation and resolution of the inflammation after corticosteroid therapy. Local and systemic antibiotic therapy had been instituted before corticosteroid administration; it was included in this analysis.

** Anterior chamber inflammation (flare) was reported as a mean index score (0.9) that resolved in an average of 4.4 days; these data were not included in the calculation of iritis/uveitis.

†† These were listed as "new or missed" retinal breaks. A greater number of these events occurred in the eyes treated with pneumatic retinopexy (24/103 or 23%) than in eyes treated with scleral buckle (12/95 or 13%; $P = 0.05$).

‡‡ Because a large number of certain events were reported with the use of ovine hyaluronidase that were not common with other compounds (RD, I/U, CT, HE), the prevalence of these events was calculated with and without inclusion of the ovine hyaluronidase data.

SAEs, serious adverse events; IVT, intravitreous; EO, endophthalmitis; RD, retinal detachment; I/U, iritis/uveitis/vitritis/anterior chamber inflammation; HE, hemorrhage; OH, ocular hypertension; CT, cataract; HP, hypotony; AMD, age-related macular degeneration; CS, case series; TPA, tissue plasminogen activator; RVO, retinal vein occlusion; ME, macular edema; CRVO, central retinal vein occlusion; RS, retrospective study; RCT, randomized clinical trial.

Table 4. Compilation of Prevalence Data From Tables 1, 2, and 3*

Prevalence Calculation	EO	RD	I/U	HE	OH	CT	HP
Studies involving antiviral compounds[1–8, 10, 11, 70]							
Prevalence per eye (%)	1.3	5.9	19.7	2.6	5.9	4.8	3.1
Prevalence per injection (%)	0.1	0.5	1.7	0.2	0.5	0.4	0.3
Studies involving triamcinolone acetonide[29–34, 71–73]							
Prevalence per eye (%)	1.4	0	0	0	38.3	9.9†	0
Prevalence per injection (%)	1.4	0	0	0	36.6	9.9†	0
Studies involving other indications[12–16, 25, 48, 74–76]							
Prevalence per eye (%)	0.1	3.5	37.3	8.6	0.6	10.5	0.3
Prevalence per injection (%)	0.1	2.7	28.8	6.6	0.5	8.1	0.2
All indications combined							
Total number of events	38	116	839	176	165	243	33
Eyes evaluated for event	4,382	2,940	2,940	2,940	2,940	2,760	2,940
Injections evaluated for event	14,866	13,400	13,400	13,400	13,400	13,208	13,400
Prevalence per eye (%)	0.9	3.9	28.5	6.0	5.6	8.8	1.1
Prevalence per injection (%)	0.3	0.9	6.3	1.3	1.2	1.8	0.3
Excluding confounding data							
EO prevalence per eye (%), excluding cases of noninfectious EO/pseudo-EO[72, 73] (events = 24)	0.5						
EO prevalence per injection (%), excluding cases of noninfectious EO/pseudo-EO[72, 73] (events = 24)	0.2						
I/U prevalence per eye (%), excluding studies involving cidofovir,[4–7] fomivirsen,[70] ovine hyaluronidase[48] (eyes = 1,069; events = 10)‡			0.9				
I/U prevalence per injection (%), excluding studies involving cidofovir,[4–7] fomivirsen,[70] ovine hyaluronidase[48] (injections = 9,768; events = 10):			0.1				

* Blank spaces indicate no events reported.
† Calculation based on phakic eyes only.
‡ Excludes the EO prevalence studies that did not report other adverse events.[71–73]
EO, endophthalmitis; RD, retinal detachment; I/U, iritis/uveitis/vitritis/anterior chamber inflammation; HE, hemorrhage; OH, ocular hypertension; CT, cataract; HP, hypotony.

tis.[10,11] These included three cases (2, coagulase-negative *Staphylococcus*; 1, culture negative) resulting from 1,583 injections in 74 eyes in one series[10] and one case of bilateral *Staphylococcus epidermidis* endophthalmitis after 341 IVT injections in 31 eyes in an earlier series by the same investigator.[11] A study in which 57 eyes received 3,027 IVT injections of ganciclovir reported one case of *S. epidermidis* endophthalmitis that was effectively treated (restoring vision to preinjection levels) with antibiotics and vitrectomy.[3] Endogenous endophthalmitis related to an indwelling catheter was suspected in one eye in a case series of 246 IVT injections of cidofovir administered in 93 eyes.[7] Another case series involving 53 eyes and 168 injections of cidofovir reported endogenous endophthalmitis believed to be unrelated to the IVT injection in 1 eye.[5] The organisms were not identified in either of these reports. These two cases of presumed endogenous endophthalmitis are not reported in Table 1 and were not included in the combined analysis for injection-related endophthalmitis.

Reports of endophthalmitis associated with the off-label administration of triamcinolone acetonide. From the studies and case series presented in Table 2, the estimated prevalence of endophthalmitis after IVT administration of triamcinolone acetonide was 1.4% (24/1,703) per eye and 1.4% (24/1,739) per injection, including suspected cases of "noninfectious" endophthalmitis, "sterile" endophthalmitis, or "pseudoendophthalmitis" as designated by the authors of each report. Excluding cases specifically reported as "noninfectious," "sterile," or "pseudoendophthalmitis," the prevalence was 0.6% (10/1,703) per eye and 0.6% (10/1,739) per injection. The review of 6 prospective studies and case series evaluating the use of IVT triamcinolone acetonide found no reports of endophthalmitis after the administration of 273 injections in 261 eyes.[29–34] In contrast, three large recently published retrospective studies identified 24 cases of endophthalmitis in 1,442 eyes treated with 1,466 injections of triamcinolone acetonide.[71–73] Only 10 (42%) of the 24 cases were culture positive. Two eyes were infected with *S. epidermidis* in one study,[72] while

eight eyes in another study were infected with various organisms (2, coagulase-negative *Staphylococcus*; 2, *Streptococcus parasanguis*; 1, *Streptobacillus*; 1, *Streptococcus intermedius*; 1, *Mycobacterium chelonae*; and 1, unidentified intracellular gram-positive cocci).[71]

All of the 14 culture-negative cases of endophthalmitis in patients receiving IVT triamcinolone acetonide occurred in two studies and were attributed by the authors to "noninfectious" endophthalmitis or "pseudoendophthalmitis."[72,73] In one of these studies,[73] seven eyes described by the authors as having "noninfectious" endophthalmitis or "pseudoendophthalmitis" developed acute, painless loss of vision within 2 days of the injection. Extensive inflammation with anterior chamber cell and flare and posterior segment vitritis ensued, and hypopyon was present in four of the eyes. Six of these eyes were treated for presumed infectious endophthalmitis despite negative microbial cultures. Culture for an additional eye with a similar presentation was not performed, and this eye recovered after conservative treatment with topical corticosteroids. The occurrence of these cases within a 5-week time frame suggested that the causative agent was a toxic contaminant of the medication. After replacement of the existing stock of triamcinolone acetonide injection with new vials, no additional cases were reported.[73] In the second study,[72] the authors described seven eyes of six patients as having suspected "noninfectious" endophthalmitis or "pseudoendophthalmitis," characterized by hypopyon and a decrease in visual acuity, within 2 days after IVT injection of triamcinolone acetonide. Microbial cultures were not performed, and the hypopyon and visual acuity resolved without intervention. One patient with no lens capsule separating the anterior and posterior segment was noted to have steroid particles in the anterior chamber 30 minutes after injection. The authors suggested that this case was an example of "pseudoendophthalmitis." In other patients, triamcinolone particles were difficult to differentiate from inflammatory cells. Another recent case report described the occurrence of an "endophthalmitislike" reaction in four eyes after IVT injection of triamcinolone acetonide.[77] The findings of the one microbial culture were negative, and all four cases spontaneously resolved without antibiotic therapy. These eyes lacked pain and swelling and did not have extensive anterior or posterior segment inflammation as in some of the cases described above.[73]

Endophthalmitis manifests as severe inflammation usually after ocular trauma or surgery or in the setting of a known endogenous source for infection. The publications analyzed in this report have characterized endophthalmitis by a variety of terms, such as "infectious," "noninfectious," "sterile," "pseudoendophthalmitis," and "endophthalmitislike." Unfortunately, some of these terms have been used inconsistently and sometimes interchangeably, leading to difficulty in data interpretation. Because of such inconsistent terminology, the cases for which authors have used the terms "noninfectious," "sterile," "endophthalmitislike," and "pseudoendophthalmitis" were grouped separately in our analysis from those that were designated by the authors as "infectious."

Defining and distinguishing between these terms will be essential for accurate future data interpretation. Use of the term "pseudoendophthalmitis" is suggested for cases where the injected agent, such as triamcinolone acetonide, creates the appearance of inflammation without actually producing inflammation, as can occur when triamcinolone acetonide crystals migrate from the vitreous to the anterior chamber and layer to form a pseudohypopyon. In contrast to pseudoendophthalmitis, the terms "noninfectious" endophthalmitis and "sterile" endophthalmitis should be reserved for cases of true inflammation as a result of IVT injection and not from an infectious process.

It is important to note that culture-negative endophthalmitis does not necessarily imply sterile or noninfectious endophthalmitis, because infectious endophthalmitis after IVT injection can often be culture negative. A post hoc analysis of visual outcomes after endophthalmitis treatment discussed in detail in Table 5[78–88] determined that 69% of all endophthalmitis cases reported were culture positive. These rates are similar to those found in the Endophthalmitis Vitrectomy Study,[17] in which ≈70% of cases were culture positive with an additional 13% having equivocal results and 18% having no growth. Distinguishing culture-negative cases of infectious endophthalmitis from sterile and noninfectious endophthalmitis can be difficult. In those cases associated with the IVT administration of triamcinolone acetonide, however, the fact that the clinical manifestations resolved without antibiotic treatment supports the notion that at least some of these cases resulted from sterile inflammation or misinterpretation of anterior chamber corticosteroid crystals as inflammation.

Reports of endophthalmitis associated with the administration of other therapeutic agents. Endophthalmitis was reported very rarely after IVT injection of gas or compounds other than antiviral agents and triamcinolone acetonide, with a combined prevalence of 0.1% (2/1,770) per eye and 0.1% (2/2,288) per injection for all other compounds (Table 3). These two cases occurred in different settings, consistent with the

Table 5. Studies Reporting Outcomes After Treatment for Endophthalmitis*

Study/Type	No. Eyes	Microbial Isolates		BCVA				Loss of Eye‡	Comments
		Yes	Most Commonly Isolated Organisms	20/20 to 20/50	20/60 to 20/200	20/400 to LP	NLP†		
Aaberg, 1998/RS[88]	36	83%	*S. epidermidis* (37%), *S. aureus* (20%), *Streptococcus* species (13%)	39%	19%	25%§	16%	None reported	All postoperative
Bartz-Schmidt, 1996/RS[95]	65	54%	*S. epidermidis* (31%), *Streptococcus* species (11%), *S. aureus* (11%)	18%	35% (20/60 to 20/400)	31% (20/800 to LP)	15%	6%	62% postoperative, 20% posttraumatic, 18% endogenous
Bohigian, 1986/RS[96]	82	62%	*S. epidermidis* (29%), *Streptococcus* species (25%), *S. aureus* (18%)	30% (20/20 to 20/70)	12% (20/100 to 20/200)	39%	18%	6%	Most postoperative; "some" related to trauma or other intraocular procedures
Eifrig, 2002/RS[78]	17	88%	*S. epidermidis* (47%), *Staphylococcus* (other) (20%), *P. aeruginosa* (13%)	29%	18%	24%	29%	None reported	All postoperative
Endophthalmitis Vitrectomy Study Group, 1995/RCT[79]	394	69%	Gram positive, coagulase negative (70%), other gram positive (24%), gram negative (5%)	61%	19%	15%	5%	4%	All postoperative
Hassan, 1992/RS[80]	47	87%	Coagulase-negative *Staphylococcus* (32%), *P. aeruginosa* (20%), *S. aureus* (15%)	Not stratified	Not stratified	Not stratified	57%	23%	60% postoperative, 15% posttraumatic, 11% systemic infections, 15% ocular/periocular infections
Olson, 1983/RS[81]	40	73%	*S. epidermidis* (38%), *Streptococcus* species (28%), *S. aureus* (6%)	35%	13%	28%§	25%	None reported	All postoperative
Puliafito, 1982/RS[82]	36	100%	*S. epidermidis* (50%), *Streptococcus* species (14%), *S. aureus* (6%)	8%	25%	22%	44%	19%	78% postoperative, 17% posttraumatic, 6% endogenous
Sandvig, 2003/RS[83]	105‖	75% (107 eyes)	Coagulase-negative *Staphylococcus* (40%), *Enterococcus* (14%), *S. pneumoniae* (10%)	47% (BCVA, 0.70–0.30)	13% (BCVA, 0.29–0.10)	24% (CF to LP)	16%	None reported	All postoperative
Shane, 2003/RS[84]	24	71%	*S. epidermidis* (41%), *S. aureus* (24%), *Streptococcus* species (24%)	4%	8%	46%	42%	None reported	All received ganciclovir implants; patients were immunodeficient
Shrader, 1990/RS[85]	105¶	75%	*S. epidermidis* (38%), *Streptococcus* species (23%), *S. aureus* (10%)	Not stratified	Not stratified	Not stratified	20%	9%	76% postoperative, 11% posttraumatic, 11% endogenous, 4% periocular infection
Somani, 1997/RS[86]	137**	60% (164 eyes)	Coagulase-negative *Staphylococcus* (60%), *S. aureus* (11%), *P. acnes* (7%)	37%	26%	25%	12%	3%	All postoperative
Wong, 2004/RS[87]	31††	62% (34 eyes)	Coagulase-negative *Staphylococcus* (35%), *Streptococcus* species (9%), *S. aureus* (6%)	48%	18%	15%	12%	None reported	All postoperative
Events‡‡		796		431	188	220	166	53	
No. eyes	1,119	1,151		967	967	967	1,119	1,119	
Mean		69%		44.6%	19.4%	22.8%	14.8%	4.7%	

* In some instances, reported BCVA data were stratified using different groupings than used here. For the purposes of these calculations, such data were listed in the column that most closely represented the reported data, and the grouping used in the publication is indicated in parenthesis below the reported percentages. In other instances, data were adjusted to fit these categories (e.g., 10/200 was extrapolated to 20/400). Therefore, data in this table are approximate. Some publications described eyes that were lost as also having NLP, while others did not. For consistency, in this table, eyes lost were included in the NLP category as well as the eyes lost category.

† Eyes that were lost due to enucleation, evisceration, or phthisis were also included under NLP.

‡ Includes enucleation, evisceration, or phthisis.

§ Includes one eye with BCVA reported as 20/300.

‖ Although 111 eyes with endophthalmitis were identified, BCVA was reported only for 105 eyes, and cultures were performed only for 107 eyes.

¶ Although 114 eyes with endophthalmitis were described, BCVA and microbial isolation were reported only for 105 eyes.

** Although cultures were performed for 164 eyes, BCVA was reported only for 137 eyes.

†† Although 34 eyes with endophthalmitis were described, BCVA was reported only for 31 eyes.

‡‡ The total number of events was obtained by adding actual data (from those studies reporting individual patient data) to estimated data (from studies reporting percentages only).

BCVA, best-corrected visual acuity; LP, light perception; NLP, no light perception; RS, retrospective study; RCT, randomized clinical trial; CF, counting fingers.

notion that endophthalmitis is a rare, sporadic event. One case of culture-negative endophthalmitis occurred after a series of multiple IVT injections (mean, 19 injections per eye) of methotrexate administered to 26 eyes as therapy for ocular lymphoma.[76] IVT injection of sulfur hexafluoride or perfluoropropane gas for retinal detachment in 103 eyes was associated with a single case of *S. epidermidis* endophthalmitis.[14] The authors of this latter report suggested that the infection was most likely due to the inadvertent use of a suboptimal concentration of povidone–iodine in the preoperative procedure.

Overall prevalence of endophthalmitis after IVT injection. Table 4 details the prevalence estimates of endophthalmitis per eye and per injection from studies involving IVT injection of antivirals, triamcinolone acetonide, and all other compounds. Overall, the prevalence of endophthalmitis, including those cases reported as noninfectious or pseudoendophthalmitis, was 0.9% (38/4,382) per eye and 0.3% (38/14,866) per injection. Excluding cases reported as noninfectious, sterile, or pseudoendophthalmitis, the overall prevalence was 0.5% (24/4,382) per eye and 0.2% (24/14,866) per injection. The prevalence of endophthalmitis per eye associated with the administration of different compounds was 1.3% (12/909) for antivirals, 0.6% (10/1,703) for triamcinolone acetonide excluding cases of noninfectious endophthalmitis or pseudoendophthalmitis, and 0.1% for all other agents analyzed. On a per-injection basis, the prevalence was 0.1% (12/10,839) for antivirals, 0.6% (10/1,739) for triamcinolone acetonide excluding cases of noninfectious endophthalmitis or pseudoendophthalmitis, and 0.1% for all other indications. The higher prevalence of endophthalmitis per eye observed with IVT antiviral administration compared with the rates reported with other agents was undoubtedly related to the requirement in patients with CMV retinitis for once weekly to twice monthly injections to control the disease.The risk of developing endophthalmitis after a single IVT injection appears to be similar to risks reported for other intraocular procedures. A study of endophthalmitis after various surgical procedures in the United States reported the following rates for endophthalmitis: cataract extraction, 0.04%; glaucoma surgery, 0.2%; penetrating keratoplasty, 0.08%; pars plana vitrectomy, 0.03%; and secondary intraocular lens placement, 0.2%.[78] The prevalence of endophthalmitis after cataract removal surgery in a Canadian study was 0.22% for extracapsular cataract extractions and 0.3% for phacoemulsification.[86] The prevalence of endophthalmitis after cataract surgery for an Australian population remained fairly constant at 0.2% over a period spanning nearly 2 decades[89] and was similar to rates reported in Norway (0.16%)[83] and Sweden (0.26%).[90]

Endophthalmitis after procedures that involve penetration of the globe is generally attributed to the inoculation of normal flora present on the ocular surface and adnexa.[91–94] Certain conditions have been suggested to be associated with increased risk of developing endophthalmitis after surgical procedures, including preexisting ocular infectious and inflammatory conditions, contact lens wear, host immunosuppression, diabetes mellitus, and upper respiratory tract infections.[91,94] A study seeking to identify risk factors for developing endophthalmitis in patients receiving IVT injection of corticosteroids[71] reported a history of non–insulin-dependent diabetes mellitus (n = 5), obtaining the IVT injection agent from a multiple-use vial (n = 2), a history of filtering blebs (n = 1), and a history of blepharitis (n = 1) as possible predisposing factors in these patients. None of these purported risk factors has been studied in a rigorously controlled clinical trial, however.

Outcomes after treatment of endophthalmitis. Unless treated effectively, endophthalmitis can rapidly lead to severe vision loss or blindness. To provide a risk estimate for a patient developing these extreme outcomes, a post hoc literature analysis was conducted using the search term "endophthalmitis." Inclusion was limited to primary reports published in English. Studies that reported visual acuity stratified according to levels of severity after treatment for endophthalmitis were identified. Studies for which visual acuity data or numbers of eyes followed were not extractable were excluded.

The search yielded 13 reports (12 chart reviews and 1 prospective clinical trial) published between 1982 and 2004 (Table 5), of which eight were restricted to postsurgical endophthalmitis.[78,79,81,83,84,86–88] The remaining studies included posttraumatic and endogenous endophthalmitis in addition to postsurgical endophthalmitis.[80,82,85,95,96] For the purposes of this analysis, the results of best-corrected visual acuity measurements were segregated into four categories based on the severity of impairment: mild (20/20 to 20/50); moderate (20/60 to 20/200); severe (20/400 to light perception only); and no light perception (NLP). Best-corrected visual acuity measurements presented by a few authors were categorized or reported slightly differently than specified herein. In these instances, data were listed in the most similar category. Thus, this analysis, while useful, provides only an approximation of visual outcomes after treatment of endophthalmitis. Where reported, data were also collected on

the percentage of eyes that progressed to NLP or were lost to enucleation, evisceration, or phthisis.

Visual outcomes after treatment of endophthalmitis varied widely. The percentage of eyes progressing to NLP in these reports ranged from a low of 5% of patients in the Endophthalmitis Vitrectomy Study[79] to 57% of patients in a 1992 chart review by Hassan et al.[80] The percentage of eyes lost from enucleation, evisceration, and phthisis ranged from none in six reports[78,81,83,84,87,88] to 23% in the 1992 review.[80] To gain a clearer perspective of expected outcomes, the sample-size weighted mean percentages were calculated for each of the best-corrected visual acuity categories. Two studies[80,85] did not stratify visual outcomes for eyes with residual vision but provided percentages of eyes with NLP and loss of eye. Therefore, data from these studies were included in the calculations for NLP and loss of eye (with data for 1,119 eyes) but not for the other best-corrected visual acuity categories (with data for 967 eyes). In this analysis, the percentages of eyes in each category were as follows: 20/20 to 20/50, 44.6% (431/967 eyes); 20/60 to 20/200, 19.4% (188/967 eyes); 20/400 to light perception, 22.8% (220/967 eyes); and NLP, 14.8% (166/1,119 eyes). Of note, these totals exceed 100% slightly due to rounding of data. The percentage of eyes lost to enucleation, evisceration, and phthisis was 4.7% (53/1,119). Despite the wide range of visual outcomes after treatment of endophthalmitis, microbial isolation results were very similar across the reports, with both rates of microbial isolation (range, 54% to 100%) and organisms identified (*S. epidermidis* was the most frequently isolated organism) varying little between studies (Table 5). Thus, the disparity in outcomes reported among studies is not likely to be solely attributed to differences in the virulence of the infectious agent.

The preceding information describing outcomes after treatment of predominantly postsurgical endophthalmitis is provided to approximate the outcomes that might occur after treatment of endophthalmitis subsequent to IVT injection. Reports of endophthalmitis after IVT injection are so sporadic that very little information is available with which to compile a separate assessment for visual outcomes. Combining all indications, only 24 reports of endophthalmitis after IVT injection (excluding events reported as noninfectious endophthalmitis or pseudoendophthalmitis) were identified. There was no report of outcomes for four of these eyes.[8,14,70,76] Five eyes (21%) were described only as having recovered their vision,[1,3,10] while vision was reported as lost or characterized as having a poor outcome in five eyes (21%).[1,10,11] One of these eyes resolved with treatment but progressed to retinal detachment after IVT injection of cidofovir.[10] Of 10 eyes for which visual acuity data were reported after treatment,[71,72] none had a visual acuity of 2/20 to 2/50, 3 (30%) had a visual acuity of 20/60 to 20/200, and 7 (70%) had a visual acuity of 20/400 to light perception. None were described as having NLP. No eyes were described as lost to enucleation, evisceration, or phthisis in these studies.

Retinal detachment

Retinal detachment was uncommon after IVT injection, with an overall prevalence of 3.9% per eye and 0.9% per injection (Table 4). The cases identified by this review appeared to be largely related to the underlying retinal condition, principally CMV retinitis and vitreous hemorrhage in the setting of diabetic retinopathy, and were only rarely related to IVT injection for other indications. Combining data from reports listed in Table 1, retinal detachment occurred in 5.9% (54/909) of eyes (0.5% [54/10,839] per injection) with CMV retinitis that received IVT injection of antiviral compounds. In one case series,[7] 10% of patients developed retinal detachment 7 to 130 days after IVT injection of cidofovir. The postinjection delay in the development of retinal detachment in this population led the authors to conclude that the complication was secondary to destruction of the retina by the CMV infection and was not a result of the IVT injection itself.[7] Retinal detachment also was described in 4.6% (62/1,344) of eyes treated with IVT ovine hyaluronidase for vitreous hemorrhage (Table 3).[48] Patients with vitreous hemorrhage are already at increased risk of retinal detachment,[97] however, suggesting that the high prevalence of retinal detachment reported with the administration of ovine hyaluronidase may be a sequela of the underlying pathologic condition in eyes with vitreous hemorrhage rather than a result of the IVT injection itself.

Iritis/uveitis

The overall prevalence of intraocular inflammation (categorized in the analysis as iritis/uveitis but including any events in the reports described as iritis, uveitis, vitritis, and/or anterior chamber inflammation) was 28.5% (839/2,940) per eye and 6.3% (839/13,400) per injection (Table 4). An uncommon complication of IVT injection in general, iritis/uveitis was reported most frequently after administration of cidofovir, fomivirsen, and ovine hyaluronidase (Table 1). Intraocular inflammatory reactions were observed in 26.9% (53/197) of eyes with CMV retinitis treated with IVT cidofovir[4–7] and in 38.2% (126/330) of eyes treated with IVT fomivirsen.[70] In one of these reports,[7] there

was also a high prevalence of intraocular inflammatory reactions in the fellow (untreated) eyes of some patients, many of whom previously had been treated with systemic antiviral agents. Moreover, acute intraocular inflammation has been reported to occur after intravenous administration of cidofovir.[98] Taken together, these findings suggest that the occurrence of noninfectious intraocular inflammation in patients receiving IVT cidofovir is most probably a consequence of the therapeutic agent itself and not the IVT injection. Another confounding factor in identifying the cause of intraocular inflammation in patients receiving cidofovir is that immune recovery uveitis is common in patients with CMV retinitis who are receiving systemic antiviral therapies and may be difficult to distinguish from uveitis related to the IVT injection.[99,100] Of note, iritis/uveitis was not reported by investigators who used IVT ganciclovir[1,2,10,11] alone or in combination with intravenous foscarnet. The prevalence of intraocular inflammation calculated without inclusion of the events associated with the use of cidofovir, fomivirsen, and ovine hyaluronidase was 0.9% (10/1,069) per eye and 0.1% (10/9,768) per injection.

Iritis/uveitis was most commonly described in patients receiving IVT injection of ovine hyaluronidase for the treatment of vitreous hemorrhage,[48] with 48.4% (650/1,344) of eyes being affected (Table 3). The high prevalence of inflammation among these patients strongly suggests that the ovine compound, not the IVT injection procedure, was the causative factor. For this reason, the prevalence of intraocular inflammation was calculated with and without inclusion of the ovine hyaluronidase study findings (Table 3). Aside from experiences with ovine hyaluronidase, "mild uveitis" was described in one patient who underwent pneumatic retinopexy,[14] while mild anterior chamber inflammation was observed in seven patients receiving pegaptanib sodium (Table 3).[25]

Ocular hypertension.—Increases in intraocular pressure (IOP) after IVT injection may be transient or sustained. Although transient IOP responses to IVT injection were described inconsistently in many reports, sustained ocular hypertension was associated primarily with the administration of triamcinolone acetonide, affecting 38.3% (100/261) of eyes (Table 2). The high prevalence of ocular hypertension after IVT injection of triamcinolone acetonide was not surprising because ocular hypertension also occurs commonly after systemic and topical corticosteroid therapy, and in general, treatment with topical ocular hypertensive agents for several months was sufficient to restore IOP to normal in the affected eyes.[29,101] Excluding IVT injection of triamcinolone acetonide, the prevalence of ocular hypertension was 2.4% (65/2,679) per eye and 0.4% (65/13,127) per injection, with most (n = 54) of these events having been reported in association with fomivirsen.[8,70]

Transiently elevated IOP, in contrast, is common and may occur after IVT administration of any agent. Although most studies made no mention of transient ocular hypertension, such data were available in selected studies (Table 3), including 4.7% (2/43) of eyes receiving IVT expansible gas and TPA[15] and 4.8% (1/21) of eyes receiving pegaptanib sodium.[25] One case (1%) of transient "malignant glaucoma" developed in 103 eyes injected with perfluoropropane gas after pneumatic retinopexy.[14]

Because transient increases in IOP may cause mild discomfort and can be associated in rare instances with irreversible damage to retinal ganglion cells and/or retinal vascular occlusion,[1] many investigators reported using prophylactic and/or therapeutic measures to prevent increases in IOP after IVT injection. These have included the use of aqueous paracentesis,[5,13,15,16,29,32,71,75] preoperative treatment with pressure-lowering agents,[2,33,34,75] and digital massage or the use of a Honan IOP reducer.[13,33,75]

Intraocular hemorrhage

Intraocular hemorrhage (i.e., retinal hemorrhage, vitreous hemorrhage, or hyphema) was reported occasionally after IVT injection, and although the etiology was unclear, in most instances, it was probably attributable to the underlying pathologic condition for which the injection was administered and not the IVT injection procedure per se. Several cases of intraocular hemorrhages were described after IVT injection in patients receiving therapy for intraocular hemorrhage (Table 3). For example, three cases of mild breakthrough hemorrhage were described in three eyes (7.0%) that were administered IVT injections of TPA to treat submacular hemorrhage.[15] Similarly, 143 cases of intraocular hemorrhage (123, vitreous; 3, retinal; and 17, hyphema) (10.6%) occurred in 1,344 eyes receiving IVT ovine hyaluronidase to treat vitreous hemorrhage. Two cases of intraocular hemorrhage (3.1%) were described in 64 eyes treated with IVT ganciclovir in patients who were severely thrombocytopenic at the time of the procedure (Table 1).[2] Intraocular hemorrhage also occurred in 21 (20, retinal hemorrhage; and 1, hyphema) (6.4%) of 330 eyes after administration of IVT fomivirsen.[70] Three case of intraocular hemorrhage (1, vitreous; 1, subretinal; and 1, hyphema) (2.9%) were described in 103 eyes undergoing pneumatic retinopexy,[14] and two cases of vitreous hemorrhage (7.7%) occurred in 26 eyes re-

ceiving IVT methotrexate for intraocular lymphoma (Table 3).[76] The overall prevalence of intraocular hemorrhage reported with IVT injection was 6.0% (176/2,940) per eye and 1.3% (176/13,400) per injection (Table 4).

Cataract

Cataract development and/or progression has been reported rarely after IVT injection, with the exception of eyes treated with triamcinolone acetonide, fomivirsen, cidofovir, and methotrexate. The greatest number of studies reporting cataract were those evaluating the off-label use of IVT injection of triamcinolone acetonide, with a prevalence of 9.9% (8/81) per eye when the analysis was restricted to phakic eyes (Table 2). This analysis is very limited in that not all studies reported the number of phakic eyes. Moreover, two case series by Jonas et al[30,32] were excluded from this prevalence estimate because cataract progression was reported as mean cataract index. In one series in which data were reported for 48 phakic eyes receiving IVT triamcinolone acetonide, the degree of cataract increased significantly in all layers of the lens examined (mean posterior subcapsular cataract index increased from 0.15 to 0.77 relative units, mean cortical cataract index increased from 1.38 to 1.79 relative units, and mean nuclear sclerosis cataract index increased from 1.48 to 1.98 relative units) in eyes receiving IVT triamcinolone injections.[32] In the other series in which data were reported for 18 phakic eyes also receiving IVT triamcinolone acetonide, the degree of lens opacification increased slightly, but the change was not statistically significant.[30] Overall, patients receiving triamcinolone acetonide in these studies were followed up for 30 to 587 days (average, 350 days).

The findings of two studies suggest that the prevalence of cataract in eyes receiving IVT injections of triamcinolone acetonide increases when patients are followed up for longer periods.[102,103] In an 18-month follow-up[103] of an earlier study[34] in which patients received IVT injection of 4 mg of triamcinolone acetonide for treatment of AMD with choroidal neovascularization, 30 eyes of 28 patients were evaluated after a minimum of 18 months. Three (75%) of four patients receiving two injections had rapid progression of cataracts within 2 months and underwent cataract surgery within one year. Of eyes receiving a single injection, 1 (3%) had progression of cataract resulting in severe visual loss and six (22%) had progression of nuclear sclerosis necessitating cataract surgery after 18 to 24 months.[103] Gillies et al[102] provided longer-term follow-up of a study population who received IVT injection of 4 mg of triamcinolone acetonide for treatment of AMD with choroidal neovascularization.[33] Of the original 75 eyes receiving injections, 16 (28.6%) of 56 eyes followed up for at least 12 months underwent cataract surgery, compared with 2 (5%) of 40 eyes in the placebo group. Of those patients evaluated at 24 months, eight (24.2%) of 33 developed cataract progression by two or more Age-Related Eye Disease Study grades, compared with none of 22 placebo-treated eyes ($P = 0.02$).[102] Tornambe et al[104] reported that after 2 years, 19% of the 53 phakic eyes (of the original 103) that underwent pneumatic retinopexy had cataract progression, with two eyes having cataract surgery after 2 years. This rate of cataract progression appeared to be lower than that for a similar group of patients who were treated with scleral buckling, suggesting that pneumatic retinopexy did not increase the risk of cataract in this study.

Cataract was also common in eyes treated with IVT antiviral agents, with a prevalence of 4.8% (44/909) per eye and 0.4% (44/10,839) per injection (Table 1). Most of these cases were reported after IVT fomivirsen administration in a single study.[70] Overall, patient follow-up in studies reporting cataract ranged from 1 day to 924 days.

Similarly, IVT methotrexate administration was associated with an increased prevalence of cataract. A case series involving 494 IVT injections of methotrexate in 26 eyes described cataract progression in 19 eyes (73%) (Table 3) when followed for 180 to 1,050 days.[76] It was not described whether these were newly formed or existing cataracts; however, 12 of these eyes had undergone vitrectomy before initial IVT methotrexate therapy, and four additional eyes underwent vitrectomy before a repeated course of IVT chemotherapy. Cataract is a recognized complication of vitrectomy, and thus the significance of cataract progression in these eyes is unclear. These eyes were therefore neither recorded in Table 3 nor included in calculating the prevalence of cataract after IVT injection. A high prevalence of cataract (185/1,344 or 13.8%) also was reported after IVT injection of ovine hyaluronidase[48] in the U.S. Food and Drug Administration Integrated Summary of Safety, which listed cataract in several different categories that may not have been mutually exclusive (68 reports of subcapsular cataract, 60 reports of nuclear cataract, and 57 reports of cortical cataract). Patients in this study were followed up for a mean of 335.4 days (range, 1 to 1,412 days). Events categorized as "posterior capsule opacification" and "lenticular opacities" also may have represented cataract. Due to difficulties in interpreting the results of this report and the unusually high prevalence of cataract in this study, the overall prev-

Table 6. Intravitreous Injection Procedures*

Study	Indication	Compound	Preoperative Procedure	Needle; Volume	Technique	Postoperative Procedure	Comments
Bakri, 2003[29]	Macular edema, CNV	TCA	1 drop ofloxacin; subconjunctival anesthesia NOS	27-gauge 0.5 in; 100 μL	3.5 mm posterior to the limbus	Ofloxacin QID for 3 d	Anterior chamber tap after injection
Baudouin, 1996[1]	CMV retinitis	Ganciclovir	0.4% oxybuprocaine; 10% povidone–iodine	30-gauge; 50 μL	2–5 mm from corneoscleral junction through pars plana; no lid speculum or forceps		
Cochereau-Massin, 1991[2]	CMV retinitis	Ganciclovir	(1) 125 mg acetazolamide 1 h before, (2) 0.5% tropicamide, (3) 0.4% oxybuprocaine; 10% povidone–iodine	30-gauge; 100 μL	Lid speculum used; 4 mm from limbus; injections in the nasal or temporal superior quadrant		
Danis, 2000[31]	AMD	TCA	Several drops of proparacaine, "a drop" of 5% povidone–iodine	30-gauge; 100 μL	Lid stabilized with non-dominant hand"; "6 o'clock" pars plana, 4 mm from limbus		Topical glaucoma medication if IOP >25 mmHg
Eyetech Study Group, 2003[25]	AMD	Pegaptanib sodium	Topical anesthesia and povidone–iodine or topical anesthetic NOS	27-gauge; 100 μL	3.5 to 4.0 mm posterior to limbus in phakic eyes and 3.0 to 3.5 mm posterior in aphakic or pseudophakic eyes	Antibiotic ointment NOS BID for 2 d	
Friberg, 1988[75]	Retinopexy	Sulfur hexafluoride gas	IOP reduced by digital massage or Honan IOP reducer; acetazolamide 500 mg and 0.5% timolol given 30 min prior; 0.5% proparacaine + 3% gentamicin topically	30-gauge 5/8 in; 0.3–0.4 mL gas	3.5 mm posterior to limbus, generally in the infratemporal quadrant	One drop of gentamicin	Retrobulbar block with 3 mL 2% lidocaine given to 4 patients; paracentesis performed if central retinal artery closed for >3 min (3 patients)
Gillies, 2003[33]	AMD	TCA	20 μL 0.25% apraclonidine + several applications of 40 μL 5% povidone–iodine + 20 μL 0.1% tetracaine; a "small amount" of 2% lidocaine administered subconjunctivally; IOP reduced by digital massage	27-gauge; 100 μL	Not specified	1% chloramphenicol topical ointment	
Hattenbach, 2001[15]	Submacular hemorrhage, AMD	TPA, sulfur hexafluoride gas	Retrobulbar 2% lidocaine; povidone–iodine applied to lids and periorbita; eye irrigated with sterile saline followed by neomycin sulfate drops	30-gauge; 50 μL TPA and 0.5 mL hexafluoride gas	Pars plana, 3 mm posterior to the limbus in pseudophakic patients and 3.5 mm posterior to limbus in phakic patients		Aqueous tap to remove pressure before injection of hexafluoride gas
Jonas, 2003[32]	AMD	TCA	Topical anesthesia NOS	200 μL, in Ringer solution	3–3.5 mm from limbus, by transconjunctival injection		Preoperative paralimbal paracentesis (puncturing the aqueous) to reduce IOP
Lahey, 1999[16]	CRVO	TPA	Topical anesthesia NOS; povidone–iodine in the cul-de-sac	30-gauge; 65–100 μL	3 mm from the limbus	Aspirin after procedure for 6 mo or heparin BID SQ for 3 d after procedure	Pre-operative paracentesis to decrease IOP
Moshfeghi, 2003[71]	Various	TCA	0.5% proparacaine plus 4% topical lidocaine, 10% povidone–iodine	27-, 29-, or 30-gauge; 100 μL	Lid speculum used; 3 mm from limbus in pseudophakic patients and 4 mm in phakic patients; inferior or inferotemporal quadrant	One drop of topical antibiotic after procedure QID for 5–7 d	Aqueous paracentesis and tap performed as necessary
Nelson, 2003[72]	Various	TCA	Topical or subconjunctival anesthesia NOS; 5% povidone–iodine applied for 5 min	27- or 30-gauge, 100 μL	3.5 mm posterior to the limbus in pseudophakic eyes and 4 mm in phakic eyes	Topical antibiotic QID for 5–7 d	
Penfold, 1995[34]	AMD	TCA	(1) 1% tropicamide, (2) 10% phenylephrine, (3) 0.5% amethocaine topically + 0.1 mL 2% lignocaine subconjunctivally; 5% povidone–iodine	30-gauge 1.2 cm; 100 μL	Superotemporal, pars plana injection, 4.5 mm from limbus	Topical chloromycetin after	

Table 6. *Continued**

Study	Indication	Compound	Preoperative Procedure	Needle; Volume	Technique	Postoperative Procedure	Comments
Rahhal, 1996[5]	CMV retinitis	Cidofovir	Topical anesthesia and povidone–iodine, followed by 2% lidocaine, with epinephrine 1:1,000 subconjunctivally	28.5- or 30-gauge; 100 μL	Trans pars plana midvitreous injection	Topical polymyxin B sulfate BID for 3 d; 1% cyclopentolate BID for 7–10 d; 1% prednisolone acetate QID for 7–10 d	If central retinal artery perfusion not observed in 1 min, anterior chamber paracentesis performed; probenecid at 3 h before and 2 and 8 h after operation
Roth, 2003[73]	Various	TCA	Topical or subconjunctival lidocaine; 5% or 10% povidone–iodine and ciprofloxacin hydrochloride	30-gauge; 100 μL	Wire lid speculum used; inferotemporal pars plana injection	Topical ciprofloxacin for 2 d	
Sebag, 1993[13]	Retinopexy	Air	Honan balloon applied for 30 min; retrobulbar anesthesia with 4% lidocaine	30-gauge; 0.8 mL	Stab incision through pars plana, 3.5–4.0 mm posterior to limbus		Anterior chamber paracentesis performed; in some cases, a second paracentesis was performed as well
Taskintuna, 1997[6] 1997[7]	CMV retinitis	Cidofovir	Subconjunctival anesthesia NOS	30-gauge; 50–100 μL	Pars plana injection NOS	Topical antibiotic ointment BID for 3 d; topical 1% cyclopentolate BID for 7–10 d; topical 1% prednisolone acetate QID for 7–10 d	

* Studies lacking an adequate description of the intravitreous injection procedure were not included.
CNV, choroidal neovascularization; TCA, triamcinolone acetonide; NOS, not otherwise specified; QID, four times daily; CMV, cytomegalovirus; AMD, age-related macular degeneration; IOP, intraocular pressure; BID, twice daily; TPA, tissue plasminogen activator; CRVO, central retinal vein occlusion; SQ, subcutaneously.

alence estimate was calculated both with and without inclusion of these data.

Hypotony

Hypotony, defined as an IOP of <4 mmHg, occurred rarely after IVT injection and was primarily limited to eyes receiving IVT antiviral therapy with cidofovir and fomivirsen (Table 1). Specifically, hypotony was described in 3.1% (28/909) of eyes treated with IVT antiviral therapy, including 22 cases reported after administration of cidofovir[4,5,7] and six cases reported after administration of fomivirsen.[70] Hypotony was not described in any eyes receiving ganciclovir with or without intravenous foscarnet. Cidofovir is known to have a direct toxic effect on the ciliary body, which may explain the occurrence of hypotony in patients receiving IVT injection of this compound. Consistent with this hypothesis, hypotony also has been reported to occur in patients treated with intravenous cidofovir.[98] Hypotony was not reported after IVT injection for other indications, with the exception of 0.4% (5/1,344) of eyes injected with ovine hyaluronidase (Table 3).[48]

Other uncommonly reported serious complications

Other serious complications occurred rarely after IVT injection, making it difficult, in most instances, to determine whether these were truly injection-related or simply sporadic, unrelated comorbidities. Hemiretinal vein occlusion occurred in an eye receiving IVT triamcinolone acetonide.[33] Retinal vein occlusion (not otherwise specified) was observed in one eye receiving IVT fomivirsen (Table 1)[70] and in one eye after IVT injection of ovine hyaluronidase (Table 3).[48] Three retinal artery occlusions were reported after IVT injection of fomivirsen (Table 1).[70] Although vascular complications appear to be rare, they have the potential to result in significant vision loss.[105]

Optic disk atrophy was described in five eyes treated with ganciclovir,[2] a complication not reported with other compounds. Similarly, a large number of eyes treated with IVT methotrexate developed corneal epitheliopathy (15/26 eyes or 57.7%) and/or maculopathy (11/26 eyes or 42.3%), but these complications did not occur with other compounds.[76] Direct methotrexate toxicity or disruption of the blood–brain barrier caused by concurrently administered chemotherapeutic agents may have contributed to the development of maculopathy.[76] The only other description of maculopathy was in 14 (1.0%) of 1,344 eyes treated with ovine hyaluronidase.[48]

Iatrogenic traumatic cataract can be a risk of IVT injection if the needle contacts or penetrates the lens

capsule. It also can occur after anterior paracentesis to restore normal IOP in patients with elevated IOP after IVT injection. A potential complication that merits mention is the occurrence of an anaphylactic reaction to compounds administered into the vitreous. Although anaphylaxis was not reported in the studies or case series presented herein, at least one report exists in the literature in which anaphylaxis occurred after IVT administration of cefazolin.[106] The occurrence of anaphylaxis in this patient highlights the fact that agents administered via IVT injection are eventually eliminated from the eye and often enter the systemic circulation, albeit at low doses.

Discussion

Risk assessment of IVT injection is complex. Studies reporting risks for IVT injection cross a number of indications and underlying pathologic conditions, ranging from the treatment of viral retinitis in relatively young immunosuppressed patients to the treatment of vascular occlusion, diabetic retinopathy, or AMD in elderly patients. Moreover, the occurrence of complications directly related to the toxicity of administered compounds confounds estimations of the prevalence of complications related to the IVT injection procedure itself. The most common serious complications appeared to be primarily related to specific indications or conditions. These included iritis/uveitis in the cases of administration of cidofovir, fomivirsen, and ovine hyaluronidase; ocular hypotony associated with the use of cidofovir; and sustained ocular hypertension, cataract progression, and pseudoendophthalmitis after the off-label use of IVT triamcinolone acetonide.

It is important to note that most compounds administered by IVT injection have not been approved for this purpose. To date, fomivirsen is the only drug approved for IVT injection. Agents labeled for other routes of administration may provide suboptimal formulations of the therapeutic compound, may contain harmful excipients, may be improperly pH balanced, or may include unacceptably high levels of contaminants, such as endotoxin. Endotoxin, which is a component of bacterial cell walls that is often present during pharmaceutical manufacturing processes, induces a severe inflammatory reaction when injected into the vitreous that is characterized by hyperemia of the iris blood vessels, intense flare in the aqueous, and hypopyon.[107] Cataract, noninfectious endophthalmitis, and pseudoendophthalmitis are comparatively common after triamcinolone acetonide injection and may be related to endotoxin or other contaminants present in this preparation. Available triamcinolone acetonide preparations were not intended, and are not labeled, for intraocular injection. Moreover, triamcinolone acetonide suspensions for IVT injection generally are prepared by the physician immediately before the injection procedure, using sterile solutions and materials that may not have been tested for endotoxin levels. Endotoxin is a common contaminant of ophthalmic viscosurgical devices,[108] and even filtered distilled water and sterilizer reservoirs may contain levels of endotoxin sufficient to provoke ocular inflammation.[109] Endotoxin contamination of surgical instruments has also been implicated in diffuse lamellar keratitis after laser-assisted in situ keratomileusis, documenting the ubiquitous nature of this contaminant.[109]

Particulate contaminants present in a drug, in a syringe, or in or on materials used at the time of injection also may have the potential to induce detrimental effects when injected into the vitreous. This has been demonstrated in the case of glove lubricants, which are highly inflammatory when injected into the posterior ocular chamber.[110]

To assess commonly used IVT injection techniques, information from studies offering descriptions was compiled in Table 6.[1,2,5–7,13,15,16,25,29,31–34,71–73,75] Descriptions of techniques or procedures used in studies involving IVT injection were frequently absent or inadequate in the reports that were analyzed. Variables in the injection procedure may include the use of preoperative prophylactic antibiotic therapy, the implementation of preoperative or postoperative procedures to control elevations in IOP (digital massage, Honan balloon, or paracentesis), preparation of the injection site (anesthetics, antibiotics, mydriatics, or antiseptics), location of the injection site (quadrant or distance from limbus), immobilization of the eye (the use of forceps, digits, or lid specula), and postoperative therapy (antibiotics or ocular antihypertensives).

The preoperative administration of prophylactic antibiotics apparently is not routine, with only 4[15,29,73,75] (23.5%) of 17 studies reporting their use (Table 6). Postoperative antibiotics were administered in 10[5–7,25,29,33,34,71–73,75] (58.8%) of 17 studies. All studies used similar-sized needles, with a 30-gauge needle being the most common and with a few studies using needles with a slightly larger bore (27 or 28.5 gauge). The volume of administered compound was quite consistent, with only a few studies using >0.1 mL (generally those injecting gas during pneumatic retinopexy). The perception that 0.1 mL is the largest safe volume seems widely held, although there is little evidence to specifically support this amount. The use of a standardized volume also does not take into account the variability in volume of the human vitre-

ous, which is affected by the size of the eye and is reduced with age.[68]

The location of the needle penetration into the vitreous in these studies varied between 2 mm and 5 mm from the corneoscleral limbus, with 3 mm to 4 mm being used most frequently (Table 6). Some studies reported using a slightly more anterior location in aphakic or pseudophakic eyes than in phakic eyes.[15,25,71,72] Most studies did not report quadrant location information, but among those that did, there was no consensus in the site used. Little attention seems to have been paid to the orientation of the needle toward a specific location within the vitreous. This may be important because it has been demonstrated experimentally that the location of the injected material may profoundly affect distribution of the compound within the vitreous, with implications for bioavailability and retinal toxicity.[111] More importantly, the needle must be appropriately oriented to minimize the risk of trauma to the lens.

Several studies reported regular postoperative monitoring of IOP and visual assessment of retinal perfusion.[5,13,29,31,71,75] If these parameters were not within safe limits during a defined time span, rescue procedures, including paracentesis, aqueous tap, or administration of topical therapy, were undertaken.

Several authors have suggested a variety of approaches that may reduce the prevalence of serious adverse events after IVT injection. However, conclusive data supporting their effectiveness is lacking in most cases. Suggestions have included the following: (a) using povidone–iodine and topical antibiotics before IVT injection to reduce the rate of endophthalmitis; (b) lowering concentrations of triamcinolone to reduce the rate of ocular hypertension; (c) decreasing the injection volume from 0.1 mL to 0.05 mL to reduce transient elevations in IOP; and (d) using smaller gauge needles to reduce the discomfort and to minimize the risk of reflux. The variability of IVT injection procedures between studies further confounds evaluation of the relative benefits of specific procedures and suggests that increased standardization of injection technique may be required to achieve greater consistency of results and best evaluate the likelihood of serious complications.

When applying these findings to patient care, it is important to recognize the limitations of the data collected and analyzed herein. Although the literature reviewed represents the state of the art, many of the reports from which data were extracted were retrospective collections that lacked randomization or controls. Systematic assessment of adverse events was absent, possibly resulting in underreporting of the true prevalence of any given complication.

Summary

The use of IVT injection offers distinct advantages over other methods of administering drugs to the posterior segment, most notably the ability to maximize intraocular concentrations while limiting systemic exposure. There are, however, potential risks associated with the use of IVT injection, some of which are vision threatening. Our review of 14,866 IVT injections from the peer-reviewed literature and from drug-specific safety databases posted by the U.S. Food and Drug Administration confirms that most risks associated with IVT injections are transient and/or treatable. Nonetheless, careful attention to injection technique is important because isolated cases of postinjection endophthalmitis, retinal detachment, or intraocular hemorrhage may result in severe visual loss. A number of new therapies that use IVT injection as a means of delivery to the posterior segment are currently under development and offer hope for patients with vision-threatening conditions for whom therapeutic options otherwise would be limited or unavailable. For such patients, the benefits of IVT therapy often far exceed the risks related to the injection procedure.

Key words: complications, cataract, endophthalmitis, eye hemorrhage, hypotony, injection, intravitreal, iritis, ocular hypertension, pneumatic retinopexy, uveitis, intraocular hemorrhage.

Acknowledgment

The authors thank Linda Whetter, DVM, PhD (Zola Associates), for her editorial assistance.

References

1. Baudouin C, Chassain C, Caujolle C, Gastaud P. Treatment of cytomegalovirus retinitis in AIDS patients using intravitreal injections of highly concentrated ganciclovir. Ophthalmologica 1996;210:329–335.
2. Cochereau-Massin I, Lehoang P, Lautier-Frau M, et al. Efficacy and tolerance of intravitreal ganciclovir in cytomegalovirus retinitis in acquired immune deficiency syndrome. Ophthalmology 1991;98:1348–1355.
3. Hodge WG, Lalonde RG, Sampalis J, Deschênes J. Once-weekly intraocular injections of ganciclovir for maintenance therapy of cytomegalovirus retinitis: clinical and ocular outcome. J Infect Dis 1996;174:393–396.
4. Kirsch LS, Arevalo JF, Chavez de la Paz E, et al. Intravitreal cidofovir (HPMPC) treatment of cytomegalovirus retinitis in patients with acquired immune deficiency syndrome. Ophthalmology 1995;102:533–543.
5. Rahhal FM, Arevalo JF, Munguia D, et al. Intravitreal cidofovir for the maintenance treatment of cytomegalovirus retinitis. Ophthalmology 1996;103:1078–1083.
6. Taskintuna I, Rahhal FM, Arevalo JF, et al. Low-dose intravitreal cidofovir (HPMPC) therapy of cytomegalovirus

retinitis in patients with acquired immune deficiency syndrome. Ophthalmology 1997;104:1049–1057.
7. Taskintuna I, Rahhal FM, Rao NA, et al. Adverse events and autopsy findings after intravitreous cidofovir (HPMPC) therapy in patients with acquired immune deficiency syndrome (AIDS). Ophthalmology 1997;104:1827–1837.
8. The Vitravene Study Group. Safety of intravitreous fomivirsen for treatment of cytomegalovirus retinitis in patients with AIDS. Am J Ophthalmol 2002;133:484–498.
9. The Vitravene Study Group. Randomized dose-comparison studies of intravitreous fomivirsen for treatment of cytomegalovirus retinitis that has reactivated or is persistently active despite other therapies in patients with AIDS. Am J Ophthalmol 2002;133:475–483.
10. Young S, Morlet N, Besen G, et al. High-dose (2000-microgram) intravitreous ganciclovir in the treatment of cytomegalovirus retinitis. Ophthalmology 1998;105:1404–1410.
11. Young SH, Morlet N, Heery S, et al. High dose intravitreal ganciclovir in the treatment of cytomegalovirus retinitis. Med J Aust 1992;157:370–373.
12. Hilton GF, Kelly NE, Salzano TC, et al. Pneumatic retinopexy. A collaborative report of the first 100 cases. Ophthalmology 1987;94:307–314.
13. Sebag J, Tang M. Pneumatic retinopexy using only air. Retina 1993;13:8–12.
14. Tornambe PE, Hilton GF. The Retinal Detachment Study Group. Pneumatic retinopexy. A multicenter randomized controlled clinical trial comparing pneumatic retinopexy with scleral buckling. Ophthalmology 1989;96:772–784.
15. Hattenbach LO, Klais C, Koch FH, Gümbel HO. Intravitreous injection of tissue plasminogen activator and gas in the treatment of submacular hemorrhage under various conditions. Ophthalmology 2001;108:1485–1492.
16. Lahey JM, Fong DS, Kearney J. Intravitreal tissue plasminogen activator for acute central retinal vein occlusion. Ophthalmic Surg Lasers 1999;30:427–434.
17. Doft BH, Kelsey SF, Wisniewski SR, the EVS Study Group. Additional procedures after the initial vitrectomy or tap-biopsy in the Endophthalmitis Vitrectomy Study. Ophthalmology 1998;105:707–716.
18. Liu W, Shum C, Martin DF, et al. Prevalence of antiviral drug resistance in untreated patients with cytomegalovirus retinitis. J Infect Dis 2000;182:1234–1238.
19. Smith IL, Taskintuna I, Rahhal FM, et al. Clinical failure of CMV retinitis with intravitreal cidofovir is associated with antiviral resistance. Arch Ophthalmol 1998;116:178–185.
20. Knox CM, Chandler D, Short GA, Margolis TP. Polymerase chain reaction-based assays of vitreous samples for the diagnosis of viral retinitis. Use in diagnostic dilemmas. Ophthalmology 1998;105:37–44.
21. Ganatra JB, Chandler D, Santos C, et al. Viral causes of the acute retinal necrosis syndrome. Am J Ophthalmol 2000; 129:166–172.
22. Bodaghi B, LeHoang P. Testing ocular fluids in uveitis. Ophthalmol Clin North Am 2002;15:271–279.
23. Grigg ME, Ganatra J, Boothroyd JC, Margolis TP. Unusual abundance of atypical strains associated with human ocular toxoplasmosis. J Infect Dis 2001;184:633–639.
24. The Eyetech Study Group. Preclinical and phase 1A clinical evaluation of an anti-VEGF pegylated aptamer (EYE001) for the treatment of exudative age-related macular degeneration. Retina 2002;22:143–152.
25. The Eyetech Study Group. Anti-vascular endothelial growth factor therapy for subfoveal choroidal neovascularization secondary to age-related macular degeneration: phase II study results. Ophthalmology 2003;110:979–986.
26. Gragoudas ES, for the VEGF Inhibition Study in Ocular Neovascularization (V.I.S.I.O.N.) Clinical Trial Group. A prospective, randomized controlled clinical trial of pegaptanib, an anti-VEGF aptamer, for neovascular age-related macular degeneration. New Engl J Med 2004: in press.
27. Chang TS, Tonnu IQ, Globe DR, Fine J. Longitudinal changes in self-reported visual functioning in AMD patients in a randomized controlled phase I/II trial of Lucentis (ranibizumab; rHuFAV v2). Invest Ophthalmol Vis Sci 2004;45:E-Abstract 3098.
28. Heier J, Sy J, McCluskey E, rhuFab V2 Study Group. RhuFab V2 in wet AMD - 6 month continued improvement following multiple intravitreal injections. Invest Ophthalmol Vis Sci 2003;44.
29. Bakri SJ, Beer PM. The effect of intravitreal triamcinolone acetonide on intraocular pressure. Ophthalmic Surg Lasers Imaging 2003;34:386–390.
30. Jonas JB, Kreissig I, Söfker A, Degenring RF. Intravitreal injection of triamcinolone for diffuse diabetic macular edema. Arch Ophthalmol 2003;121:57–61.
31. Danis RP, Ciulla TA, Pratt LM, Anliker W. Intravitreal triamcinolone acetonide in exudative age-related macular degeneration. Retina 2000;20:244–250.
32. Jonas JB, Kreissig I, Hugger P, et al. Intravitreal triamcinolone acetonide for exudative age related macular degeneration. Br J Ophthalmol 2003;87:462–468.
33. Gillies MC, Simpson JM, Luo W, et al. A randomized clinical trial of a single dose of intravitreal triamcinolone acetonide for neovascular age-related macular degeneration: one-year results. Arch Ophthalmol 2003;121:667–673.
34. Penfold PL, Gyory JF, Hunyor AB, Billson FA. Exudative macular degeneration and intravitreal triamcinolone. A pilot study. Aust N Z J Ophthalmol 1995;23:293–298.
35. Ohm J. Über die behandlung der netzhautablösung durch operative entleerung der subretinalen flüssigkeit und einspritzung von luft in den glaskörper. Albrecht von Graefes Arch Ophthalmol 1911;79:442–450.
36. Schneider J, Frankel SS. Treatment of late postoperative intraocular infections with intraocular injection of penicillin. Arch Ophthalmol 1947;37:304–307.
37. Rycroft B. Penicillin and the control of deep intraocular infection. Br J Ophthalmol 1945;29:57–87.
38. Rosengren B. 300 cases operated upon for retinal detachment; method and results. Acta Ophthalmol (Copenh) 1952; 30:117–122.
39. Cibis PA, Becker B, Okun E, Canaan S. The use of liquid silicone in retinal detachment surgery. Arch Ophthalmol 1962;68:590–599.
40. Forster RK, Zachary IG, Cottingham AJ Jr, Norton EWD. Further observations on the diagnosis, cause, and treatment of endophthalmitis. Am J Ophthalmol 1976;81:52–56.
41. Peyman GA, Vastine DW, Raichand M. Experimental aspects and their clinical application. Ophthalmology 1978; 85:374–385.
42. Blumenkranz M, Hernandez E, Ophir A, Norton EWD. 5-Fluorouracil: new applications in complicated retinal detachment for an established antimetabolite. Ophthalmology 1984;91:122–130.
43. Henry K, Cantrill H, Fletcher C, et al. Use of intravitreal ganciclovir (dihydroxy propoxymethyl guanine) for cyto-

megalovirus retinitis in a patient with AIDS. Am J Ophthalmol 1987;103:17–23.
44. Blankenship GW. Evaluation of a single intravitreal injection of dexamethasone phosphate in vitrectomy surgery for diabetic retinopathy complications. Graefes Arch Clin Exp Ophthalmol 1991;229:62–65.
45. Fishburne BC, Wilson DJ, Rosenbaum JT, Neuwelt EA. Intravitreal methotrexate as an adjunctive treatment of intraocular lymphoma. Arch Ophthalmol 1997;115: 1152–1156.
46. Vitravene® Injection (fomivirsen sodium intravitreal injectable). Approval letter, pages 1–4. Vol 2004. U.S. Food and Drug Administration Web site. Available at: www.fda.gov/cder/foi/nda/98/20961_Vitravene_Approv.pdf. Accessed April 29, 2004.
47. Hassan AS, Johnson MW, Schneiderman TE, et al. Management of submacular hemorrhage with intravitreous tissue plasminogen activator injection and pneumatic displacement. Ophthalmology 1999;106:1900–1907.
48. Vitrase® (ovine hyaluronidase for intravitreal injection). NDA 21–414 clinical data, pages 134–135. Vol 2004. U.S. Food and Drug Administration Web site. Available at: http://www.fda.gov/ohrms/dockets/ac/03/briefing/3929B1_01_ISTA-Vitrase.pdf. Accessed September 25, 2003.
49. Peyman GA, Nelsen P, Bennett TO. Intravitreal injection of kanamycin in experimentally induced endophthalmitis. Can J Ophthalmol 1974;9:322–327.
50. Peyman GA, Paque JT, Meisels HI, Bennett TO. Postoperative endophthalmitis: a comparison of methods for treatment and prophylaxis with gentamicin. Ophthalmic Surg 1975;6:45–55.
51. Baum JL. The treatment of bacterial endophthalmitis. Ophthalmology 1978;85:350–356.
52. Barza M, Kane A, Baum J. Oxacillin for bacterial endophthalmitis: subconjunctival, intravenous, both, or neither? Invest Ophthalmol Vis Sci 1980;19:1348–1354.
53. McCuen BW 2nd, Bessler M, Tano Y, et al. The lack of toxicity of intravitreally administered triamcinolone acetonide. Am J Ophthalmol 1981;91:785–788.
54. Tano Y, Chandler D, Machemer R. Treatment of intraocular proliferation with intravitreal injection of triamcinolone acetonide. Am J Ophthalmol 1980;90:810–816.
55. Vitrase® (hyaluronidase for injection). Approval letter for NDA 21–640, pages 1–2. U.S. Food and Drug Administration Web site. Available at: www.fda.gov/cder/foi/appleletter/2004/21640/ltr.pdf. Accessed May 30, 2004.
56. Hauswirth WW, Li Q, Raisler B, et al. Range of retinal diseases potentially treatable by AAV-vectored gene therapy. Novartis Found Symp 2004;255:179–188.
57. GenVec. PEDF program—a new approach to prevent blindness. Available at: www.genvec.com/products_gene_therapy_pedf.asp. Accessed May 30, 2004.
58. Coco RM, López MI, Pastor JC, Nozal MJ. Pharmacokinetics of intravitreal vancomycin in normal and infected rabbit eyes. J Ocul Pharmacol Ther 1998;14:555–563.
59. Wingard LB Jr, Zuravleff JJ, Doft BH, et al. Intraocular distribution of intravitreally administered amphotericin B in normal and vitrectomized eyes. Invest Ophthalmol Vis Sci 1989;30:2184–2189.
60. Schindler RH, Chandler D, Thresher R, Machemer R. The clearance of intravitreal triamcinolone acetonide. Am J Ophthalmol 1982;93:415–417.
61. Stay MS, Xu J, Randolph TW, Barocas VH. Computer simulation of convective and diffusive transport of controlled-release drugs in the vitreous humor. Pharm Res 2003;20:96–102.
62. Mordenti J, Cuthbertson R, Ferrara N, et al. Comparisons of the intraocular tissue distribution, pharmacokinetics, and safety of ^{125}I-labeled full-length and Fab antibodies in rhesus monkeys following intravitreal administration. Toxicol Pathol 1999;27:536–544.
63. Scholes GN, O'Brien WJ, Abrams GW, Kubicek MF. Clearance of triamcinolone from vitreous. Arch Ophthalmol 1985;103:1567–1569.
64. Jonas JB. Concentration of intravitreally injected triamcinolone acetonide in aqueous humour. Br J Ophthalmol 2002; 86:1066.
65. Beer PM, Bakri SJ, Singh RJ, et al. Intraocular concentration and pharmacokinetics of triamcinolone acetonide after a single intravitreal injection. Ophthalmology 2003;110: 681–686.
66. Moldow B, Sander B, Larsen M, Lund-Andersen H. Effects of acetazolamide on passive and active transport of fluorescein across the normal BRB. Invest Ophthalmol Vis Sci 1999;40:1770–1775.
67. Drolet DW, Nelson J, Tucker CE, et al. Pharmacokinetics and safety of an anti-vascular endothelial growth factor aptamer (NX1838) following injection into the vitreous humor of rhesus monkeys. Pharm Res 2000;17:1503–1510.
68. Sebag J. Age-related changes in human vitreous structure. Graefes Arch Clin Exp Ophthalmol 1987;225:89–93.
69. Lund-Andersen H, Sander B. The vitreous. In: Kaufman PL, Alm A, eds. Adler's Physiology of the Eye. 10th ed. St. Louis, MO: Mosby; 2003:293–316.
70. Vitravene® (fomivirsen sodium intravitreal injectable). Medical Officer's Review of NDA 20–961, pages 37–38. Vol 2004. U.S. Food and Drug Administration Web site. Available at: http://www.fda.gov/cder/foi/nda/98/20961_vitravene_medr.pdf. Accessed September 25, 2003.
71. Moshfeghi DM, Kaiser PK, Scott IU, et al. Acute endophthalmitis following intravitreal triamcinolone acetonide injection. Am J Ophthalmol 2003;136:791–796.
72. Nelson ML, Tennant MT, Sivalingam A, et al. Infectious and presumed noninfectious endophthalmitis after intravitreal triamcinolone acetonide injection. Retina 2003;23:686–691.
73. Roth DB, Chieh J, Spirn MJ, et al. Noninfectious endophthalmitis associated with intravitreal triamcinolone injection. Arch Ophthalmol 2003;121:1279–1282.
74. Friberg TR, Eller AW. Laser pneumatic retinopexy for repair of recurrent retinal detachment after failed scleral buckle—ten years experience. Ophthalmic Surg Lasers 2001;32:13–18.
75. Friberg TR, Eller AW. Pneumatic repair of primary and secondary retinal detachments using a binocular indirect ophthalmoscope laser delivery system. Ophthalmology 1988;95:187–193.
76. Smith JR, Rosenbaum JT, Wilson DJ, et al. Role of intravitreal methotrexate in the management of primary central nervous system lymphoma with ocular involvement. Ophthalmology 2002;109:1709–1716.
77. Sutter FK, Gillies MC. Pseudo-endophthalmitis after intravitreal injection of triamcinolone. Br J Ophthalmol 2003; 87:972–974.
78. Eifrig CW, Flynn HW Jr, Scott IU, Newton J. Acute-onset postoperative endophthalmitis: review of incidence and vi-

sual outcomes (1995–2001). Ophthalmic Surg Lasers 2002; 33:373–378.
79. Endophthalmitis Vitrectomy Study Group. Results of the Endophthalmitis Vitrectomy Study. A randomized trial of immediate vitrectomy and of intravenous antibiotics for the treatment of postoperative bacterial endophthalmitis. Arch Ophthalmol 1995;113:1479–1496.
80. Hassan IJ, MacGowan AP, Cook SD. Endophthalmitis at the Bristol Eye Hospital: an 11-year review of 47 patients. J Hosp Infect 1992;22:271–278.
81. Olson JC, Flynn HW Jr, Forster RK, Culbertson WW. Results in the treatment of postoperative endophthalmitis. Ophthalmology 1983;90:692–699.
82. Puliafito CA, Baker AS, Haaf J, Foster CS. Infectious endophthalmitis. Review of 36 cases. Ophthalmology 1982; 89:921–929.
83. Sandvig KU, Dannevig L. Postoperative endophthalmitis: establishment and results of a national registry. J Cataract Refract Surg 2003;29:1273–1280.
84. Shane TS, Martin DF, for the Endopthalmitis-Ganciclovir Implant Study Group. Endophthalmitis after ganciclovir implant in patients with AIDS and cytomegalovirus retinitis. Am J Ophthalmol 2003;136:649–654.
85. Shrader SK, Band JD, Lauter CB, Murphy P. The clinical spectrum of endophthalmitis: incidence, predisposing factors, and features influencing outcome. J Infect Dis 1990; 162:115–120.
86. Somani S, Grinbaum A, Slomovic AR. Postoperative endophthalmitis: incidence, predisposing surgery, clinical course and outcome. Can J Ophthalmol 1997;32:303–310.
87. Wong TY, Chee SP. The epidemiology of acute endophthalmitis after cataract surgery in an Asian population. Ophthalmology 2004;111:699–705.
88. Aaberg TM Jr, Flynn HW Jr, Schiffman J, Newton J. Nosocomial acute-onset postoperative endophthalmitis survey. A 10-year review of incidence and outcomes. Ophthalmology 1998;105:1004–1010.
89. Semmens JB, Li J, Morlet N, Ng J. Trends in cataract surgery and postoperative endophthalmitis in Western Australia (1980–1998): the Endophthalmitis Population Study of Western Australia. Clin Exp Ophthalmol 2003;31:213–219.
90. Montan PG, Koranyi G, Setterquist HE, et al. Endophthalmitis after cataract surgery: risk factors relating to technique and events of the operation and patient history: a retrospective case-control study. Ophthalmology 1998;105: 2171–2177.
91. Kresloff MS, Castellarin AA, Zarbin MA. Endophthalmitis. Surv Ophthalmol 1998;43:193–224.
92. Speaker MG, Milch FA, Shah MK, et al. Role of external bacterial flora in the pathogenesis of acute postoperative endophthalmitis. Ophthalmology 1991;98:639–649.
93. Bannerman TL, Rhoden DL, McAllister SK, et al. The source of coagulase-negative staphylococci in the Endophthalmitis Vitrectomy Study. A comparison of eyelid and intraocular isolates using pulsed-field gel electrophoresis. Arch Ophthalmol 1997;115:357–361.
94. Ta CN. Minimizing the risk of endophthalmitis following intravitreous injections. Retina 2004;24:699–705.
95. Bartz-Schmidt KU, Bermig J, Kirchhof B, et al. Prognostic factors associated with the visual outcome after vitrectomy for endophthalmitis. Graefes Arch Clin Exp Ophthalmol 1996;234(suppl 1):S51–S58.
96. Bohigian GM, Olk RJ. Factors associated with a poor visual result in endophthalmitis. Am J Ophthalmol 1986;101:332–341.
97. Sarrafizadeh R, Hassan TS, Ruby AJ, et al. Incidence of retinal detachment and visual outcome in eyes presenting with posterior vitreous separation and dense fundus-obscuring vitreous hemorrhage. Ophthalmology 2001;108:2273–2278.
98. Davis JL, Taskintuna I, Freeman WR, et al. Iritis and hypotony after treatment with intravenous cidofovir for cytomegalovirus retinitis. Arch Ophthalmol 1997;115:733–737.
99. Robinson MR, Reed G, Csaky KG, et al. Immune-recovery uveitis in patients with cytomegalovirus retinitis taking highly active antiretroviral therapy. Am J Ophthalmol 2000; 130:49–56.
100. Cunningham ET Jr. Uveitis in HIV positive patients (editorial). Br J Ophthalmol 2000;84:233–235.
101. Carnahan MC, Goldstein DA. Ocular complications of topical, peri-ocular, and systemic corticosteroids. Curr Opin Ophthalmol 2000;11:478–483.
102. Gillies MC, Simpson JM, Billson FA, et al. Safety of an intravitreal injection of triamcinolone: results from a randomized clinical trial. Arch Ophthalmol 2004;122:336–340.
103. Challa JK, Gillies MC, Penfold PL, et al. Exudative macular degeneration and intravitreal triamcinolone: 18 month follow up. Aust N Z J Ophthalmol 1998;26:277–281.
104. Tornambe PE, Hilton GF, Brinton DA, et al. Pneumatic retinopexy. A two-year follow-up study of the multicenter clinical trial comparing pneumatic retinopexy with scleral buckling. Ophthalmology 1991;98:1115–1123.
105. Recchia FM, Brown GC. Systemic disorders associated with retinal vascular occlusion. Curr Opin Ophthalmol 2000;11: 462–467.
106. Kraushar MF, Nussbaum P, Kisch AL. Anaphylactic reaction to intravitreal cefazolin. Retina 1994;14:187–188.
107. Mo J-S, Streilein JW. Immune privilege persists in eyes with extreme inflammation induced by intravitreal LPS. Eur J Immunol 2001;31:3806–3815.
108. Dick HB, Augustin AJ, Pakula T, Pfeiffer N. Endotoxins in ophthalmic viscosurgical devices. Eur J Ophthalmol 2003; 13:176–184.
109. Peters NT, Iskander NG, Anderson Penno EE, et al. Diffuse lamellar keratitis: isolation of endotoxin and demonstration of the inflammatory potential in a rabbit laser in situ keratomileusis model. J Cataract Refract Surg 2001;27:917–923.
110. Park HS, Kim MS. The inflammatory potential of surgical glove lubricants: Biosorb, Keoflo, calcium carbonate and Hydrocote after intravitreal injection. Korean J Ophthalmol 1997;11:51–59.
111. Friedrich S, Cheng YL, Saville B. Drug distribution in the vitreous humor of the human eye: the effects of intravitreal injection position and volume. Curr Eye Res 1997;16:663–669.