Daniel Rothamel
Frank Schwarz
Martin Sager
Monika Herten
Anton Sculean
Jürgen Becker

Biodegradation of differently cross-linked collagen membranes: an experimental study in the rat

Authors' affiliations:
Daniel Rothamel, Frank Schwarz, Monika Herten, Jürgen Becker, Department of Oral Surgery, Heinrich Heine University, Düsseldorf, Germany
Martin Sager, Animal Research Institute, Heinrich Heine University, Düsseldorf, Germany
Anton Sculean, Department of Operative Dentistry and Periodontology, Johannes-Gutenberg University, Mainz, Germany

Correspondence to:
Dr Daniel Rothamel
Department of Oral Surgery
Westdeutsche Kieferklinik
Heinrich Heine University
D-40225 Düsseldorf
Germany
Tel.: +49 211 8118149
Fax: +49 211 811 6550
e-mail: rothamel@med.uni-duesseldorf.de

Key words: animal study, biodegradation, collagen membrane, cross-linking, GBR, GTR

Abstract: The aim of the present study was to compare the biodegradation of differently cross-linked collagen membranes in rats. Five commercially available and three experimental membranes (VN) were included: (1) BioGide® (BG) (non-cross-linked porcine type I and III collagens), (2) BioMend® (BM), (3) BioMendExtend® (BME) (glutaraldehyde cross-linked bovine type I collagen), (4) Ossix® (OS) (enzymatic-cross-linked bovine type I collagen), (5) TutoDent® (TD) (non-cross-linked bovine type I collagen, and (6–8) VN(1–3) (chemical cross-linked porcine type I and III collagens). Specimens were randomly allocated in unconnected subcutaneous pouches separated surgically on the back of 40 wistar rats, which were divided into five groups (2, 4, 8, 16, and 24 weeks), including eight animals each. After 2, 4, 8, 16, and 24 weeks of healing, the rats were sacrificed and explanted specimens were prepared for histologic and histometric analysis. The following parameters were evaluated: biodegradation over time, vascularization, tissue integration, and foreign body reaction. Highest vascularization and tissue integration was noted for BG followed by BM, BME, and VN(1); TD, VN(2), and VN(3) showed prolongated, while OS exhibited no vascularization. Subsequently, biodegradation of BG, BM, BME and VN(1) was faster than TD, VN(2), and VN(3). OS showed only a minute amount of superficial biodegradation 24 weeks following implantation. Biodegradation of TD, BM, BME, VN(2), and VN(3) was associated with the presence of inflammatory cells. Within the limits of the present study, it was concluded that cross-linking of bovine and porcine-derived collagen types I and III was associated with (i) prolonged biodegradation, (ii) decreased tissue integration and vascularization, and (iii) in case of TD, BM, BME, VN(2), and VN(3) foreign body reactions.

The technique of guided bone regeneration (GBR) and guided tissue regeneration (GTR) is based on the concept of preventing the apical downgrowth of gingival epithelium inside the wound area by means of membrane barriers and by favoring the proliferation of regenerative potential cells to predictably obtain wound healing with a desired type of tissue (Gottlow et al. 1986; Dahlin et al. 1988; Karring et al. 1993; Hämmerle & Karring 1998; Hämmerle & Lang 2001). A material which is used as a barrier for GBR/GTR procedures has to meet certain design criteria to provide for biocompatibility, tissue integration, cell-occlusivity, nutritient transfer, space-making ability and also ease of use in the clinic (Hardwick et al. 1994). Several drawbacks were associated with the first generation of membranes mostly made from non-resorbable materials such as expanded polytetrafluorethylene: the need for a second surgery to retrieve the barrier at the end of the healing period and early spontaneous exposure to the oral environment and subsequent bacterial colonization, which could necessitate their premature retrieval (Selvig et al. 1992; Tempro & Nalbandian 1993; Hardwick et al. 1994). A variety of bioabsorbable

Date:
Accepted 25 May 2004

To cite this article:
Rothamel D, Schwarz F, Sager M, Herten M, Becker J. Biodegradation of differently cross-linked collagen membranes: an experimental study in the rat.
Clin. Oral Impl. Res. **16**, 2005; 369–378
doi: 10.1111/j.1600-0501.2005.01108.x

Copyright © Blackwell Munksgaard 2005

LifeNet Exhibit 2021
Embody, et al. v. LifeNet, IPR2025-00249
Page 1

membranes composed of dura-mater, polylactic acid, polyglycolic acid, and polyurethane were introduced to overcome these problems (Magnusson et al. 1988; Greenstein & Caton 1993; Hutmacher et al. 1996; Kohal et al. 1998). Recently, many investigations reported on the use of products derived from types I and III porcine or bovine collagen (for a review see Bunyaratavej & Wang 2001). Collagen has been reported to be superior to other materials, since it plays an active role in coagulum formation, is chemotactic for periodontal ligament (PDL) fibroblasts and gingival fibroblasts, and is a major component of the periodontal connective tissue (Postlethwaite et al. 1978; Yaffe et al. 1984; Hutmacher et al. 1996; Locci et al. 1997). In recent years, collagen membranes have been proven to significantly enhance periodontal and bone regeneration in various animal and human clinical studies (Pitaru et al. 1988; Blumenthal & Steinberg 1990; Becker et al. 1992; Sevor et al. 1993; Yukna & Yukna 1996; Mattson et al. 1999). However, a major drawback of native collagen is the fast biodegradation by the enzymatic activity of macrophages and polymorphonuclear leucocytes resulting in a poor membrane resistance to collapse allowing undesirable cell types entering the secluded wound area (Tatakis et al. 1999). The collapse may be prevented by means of implantation of bone grafts or bone graft substitutes into the defect to support the membrane preserving its original position. In order to prolong biodegradation, several cross-linking techniques such as ultraviolet light, glutaraldehyde, diphenylphosphorylazide or hexmethylenediisocyanate have been used (Kodama et al. 1989; Minabe et al. 1989; Quteish & Dolby 1992; Brunel et al. 1996; Zahedi et al. 1998; Bunyaratavej & Wang 2001). Recent results from animal studies have demonstrated that the degradation of cross-linked collagen membranes was significantly slower compared with non-cross-linked membranes (Pitaru et al. 1988; Paul et al. 1992). However, a recent *in vitro* study has pointed out that native as well as cross-linked membranes derived from bovine or porcine types I and III collagens limited attachment and proliferation of human PDL fibroblasts and human SaOs-2 osteoblasts compared with cells plated on the culture dish. Moreover, cross-linking with glutaraldehyde even inhibited the attachment and proliferation of both cell types (Rothamel et al. 2004). Although chemical cross-linking of collagen seems to be nowadays a commonly used procedure, it still remains unknown to what extent the physicochemical properties of the membrane get altered. Therefore, the aim of the present study was to examine biodegradation over time, foreign body reaction, tissue integration, and vascularization of different commercially available and also experimental collagen membranes after subcutaneous implantation in rats.

Material and methods

Animals

Forty albino rats of the wistar strain (age 3 ± 0.5 months, weight 350 ± 20 g) were used in the study. Animal selection, management, and surgery protocol were approved by the Animal Care and Use Committee of the Heinrich Heine University, Düsseldorf, Germany. The animals were divided into five groups (2, 4, 8, 16, and 24 weeks), including eight rats each.

Membranes examined

Five commercially available and three experimental (VN) GBR/GTR collagen membranes were included: (1) BioGide® (BG) (Geistlich Biomaterials, Wolhusen, Switzerland) (non-cross-linked porcine type I and III collagens, bilayered), (2) BioMend® (BM) (Sulzer Medica, Colla-Tec Inc., Plainsboro, NJ, USA) (glutaraldehyde cross-linked bovine type I collagen), (3) BioMendExtend® (BME) (Sulzer Medica, Colla-Tec Inc.) (glutaraldehyde cross-linked bovine type I collagen), (4) Ossix® (OS) (3i, Colbar R&D Ltd, Ramat Husharon, Israel) (enzymatic-cross-linked bovine type I collagen), (5) TutoDent® (TD) (Tutogen, Carlsbad, CA, USA) (non-cross-linked bovine type I collagen, bilayered), (6) VN(1), (7) VN(2), and (8) VN(3) (Geistlich Biomaterials) (1, 3, 4 × chemical cross-linked porcine type I and III collagens, bilayered, respectively). In order to expose only the cell occlusive surface of the bilayered collagen membranes, each specimen was folden, trimmed to an uniform size (octagon shaped specimens of 1.7 cm^2), and separated by a non-resorbable polycarbonate spacer (Isopore®, Millipore Corporate, Billerica, MA, USA) in the middle. Furthermore, all membranes were sutured circumferentially using non-resorbable sutures to avoid an ingrowth of the

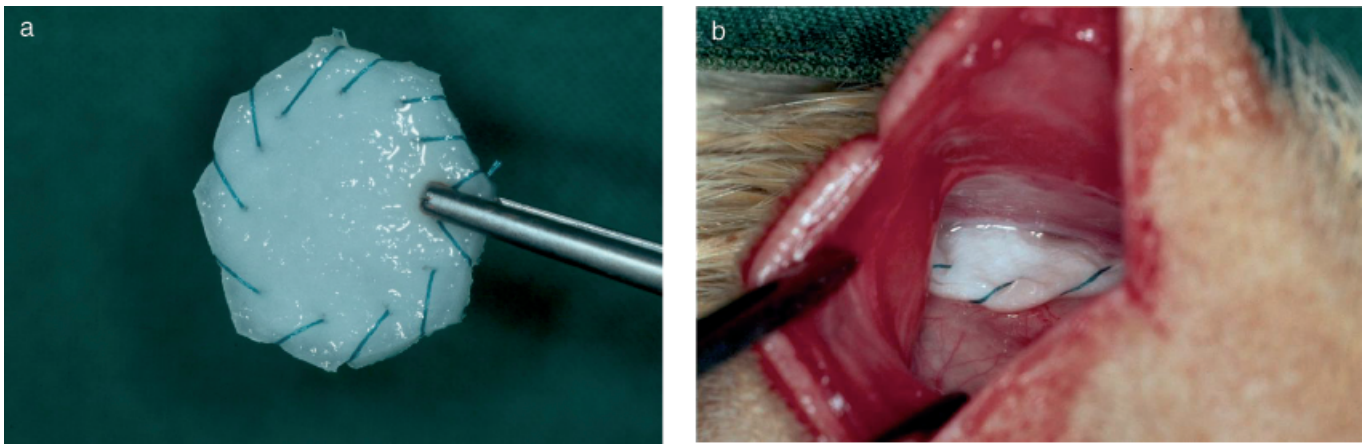

Fig. 1. (a) To expose the cell occlusive surface of the bilayered membranes, each specimen was folden, trimmed to an uniform size (octagon-shaped specimens of approximately 1.7 cm^2), separated by a nonresorbable polycarbonate spacer in the middle, and sutured circumferentially to avoid an ingrowth of the surrounding tissue. (b) Collagen membranes were randomly allocated in unconnected subcutaneous pouches separated surgically on the back of the rats.

LifeNet Exhibit 2021
Embody, et al. v. LifeNet, IPR2025-00249
Page 2

16000501, 2005, 3, Downloaded from https://onlinelibrary.wiley.com/doi/10.1111/j.1600-0501.2005.01108.x by Rice University, Wiley Online Library on [23/10/2025]. See the Terms and Conditions (https://onlinelibrary.wiley.com/terms-and-conditions) on Wiley Online Library for rules of use; OA articles are governed by the applicable Creative Commons License

surrounding tissue (Polyester®, Resorba, Nürnberg, Germany) (Fig. 1a). Ten minutes prior to implantation, each membrane was rehydrated in sterile 0.9% physiological saline (Braun, Melsungen, Germany).

Surgical procedure

The animals were anesthesized by intraperiotoneal injection of 9 mg/kg ketamine 10% (Ketanest®, Pfizer GmbH, Karlsruhe, Germany) and 5 mg/kg xylazine 2% (Sedaxylan®, Pfizer GmbH). An area of approximately 8 cm in length and 4 cm in width was depilated on the back of each rat using an electric shaver and a razor blade. Following disinfection with polyvidone iodine (Betaisodona®, Mundipharma, Limburg/Lahn, Germany), a skin incision was made right paramedian along the vertebral column followed by the separation of four unconnected subcutaneous pouches. The membranes were randomly allocated in the resulting 160 pouches (Fig. 1b). Primary wound closure was achieved using horizontal mattress 3.0 Polyester® sutures (Resorba). During the experiment, the animals were fed *ad libitum* with standard laboratory food pellets. Animals were sacrificed in a carbon dioxide euthanasia chamber after 2, 4, 8, 16, and 24 weeks. Residues of the membranes were removed with the surrounding connective tissue and fixed in 10% formalin.

Histomorphometry

All specimens were embedded in paraffin. Serial sections of 4 μm thickness were stained with Goldner Trichrome stain. From each specimen, three sections were systematically, uniformly randomly sampled for analysis. For image acquisition a digital camera (Nikon D100, Nikon GmbH, Düsseldorf, Germany) was mounted on a binocular light microscope (Olympus BX50, Olympus, Hamburg, Germany). Digital images (original magnification ×40) were evaluated using a software program (ImageJ®, Scion Corp., Frederick MD, USA). Thickness of the membrane body was measured linearly at 18 fields selected at random. All measurements were performed by one blinded and calibrated examiner. Additionally, the following parameters were evaluated descriptively: vascularization of the membrane body, tissue integration, and foreign body reaction (i.e. presence of multinucleated giant cells).

Statistical analysis

A software package (SPSS 11.0, SPSS Inc., Chicago, IL, USA) was used for the statistical analysis. Mean values and standard deviations were calculated for membrane thickness of each group. Analysis of variance (ANOVA) and post hoc testing using Bonferroni's correction for multiple comparisons was used for comparisons within groups. Results were considered statistically significant at $P<0.05$.

Results

Postoperative healing

Three wistar rats had to be euthanized prematurely because of severe wound infection (groups: 2, 8, and 24 weeks). In all other cases, postoperative wound healing was uneventful (i.e. no abscesses, no allergic reactions).

Histometric analysis

Thickness of the membrane body for each group at different time points is presented in Fig. 2a–h. Histometric analysis revealed that membrane thickness of BG was significantly reduced between 2 and 4 weeks following implantation ($P<0.001$) (Fig. 2a). Compared with the 2-week scores, no significant changes could be observed for the rest of the observation period ($P>0.05$). BM, BME, TD, VN(1), and VN(2) showed significant changes of membrane thickness 8 weeks following implantation ($P<0.01$, $P<0.001$, $P<0.001$, $P<0.05$, respectively). For the rest of the study period, no statistically significant changes were noted for BM, BME, and VN(1) (Fig. 2b, c and f). In contrast, 8 weeks following implantation, TD and VN(2) exhibited approximately 60% of membrane thickness measured after 2 weeks. A significant reduction of membrane thickness was observed after 16 and 24 weeks ($P<0.001$, respectively) (Fig. 2e and g). Histometric analysis of VN(3) showed that membrane thickness was reduced 16 and 24 weeks following implantation (Fig. 2h). However, compared with the 2 week scores, these values were statistically nonsignificant ($P>0.05$, respectively). Histometric analysis failed to demonstrate a reduction of membrane thickness for OS during the entire study period of 24 weeks ($P>0.05$, respectively) (Fig. 2d).

Histological analysis

Two-week specimens

Histological analysis revealed obvious differences in the structure of each membrane examined. The membrane body of BG, TD, and VN(1–3) seemed to be structured like an interconnective porous system (Fig. 3a); however, TD appeared to be more compact (Fig. 4a). In contrast, BM and BME had a more stratified appearance (Fig. 3b) with large interstices, whereas OS exhibited a dense membrane body without the presence of any cognizable interstices (Fig. 3c). Histological analysis 2 weeks following implantation revealed a nearly complete vascularization of the membrane body of BG (Fig. 3a), since blood vessels also reached the non-exposed surface of the membrane. Within the same time period, merely half of the membrane body of TD and VN(1–3) were vascularized. BM and BME showed only a slight superficial vascularization of the exposed portion of the membrane (Fig. 3b). However, there were no signs of any vascularization noted for OS (Fig. 3c). The most obvious tissue integration showed BG, TD, VN(1), and VN(2). In contrast, BM, BME, and OS were clearly separated from the adjacent connective tissue by a split, which in case of BM and BME was invaded by some blood vessels (Fig. 3b and c). Infiltration of inflammatory cells was seen in the tissue adjacent to the external surface of TD, BM, BME, VN(2), and VN(3).

Four-week specimens

After 4 weeks, vascularization captured nearly the complete membrane body of BM, BME, TD, VN(1), and VN(2) (Fig. 4a). Histological analysis showed an entire organization of BG resulting in a nearly complete biodegradation of this membrane (Fig. 4b). Within the same time period, half of the membrane body of VN(3) seemed to be vascularized (Fig. 4c). No signs of vascularization were observed for OS. There was still a split noted for OS separating the membrane from the surrounding tissue. However, the formation of a

LifeNet Exhibit 2021
Embody, et al. v. LifeNet, IPR2025-00249
Page 3

16000501, 2005, 3, Downloaded from https://onlinelibrary.wiley.com/doi/10.1111/j.1600-0501.2005.01108.x by Rice University, Wiley Online Library on [23/10/2025]. See the Terms and Conditions (https://onlinelibrary.wiley.com/terms-and-conditions) on Wiley Online Library for rules of use; OA articles are governed by the applicable Creative Commons License

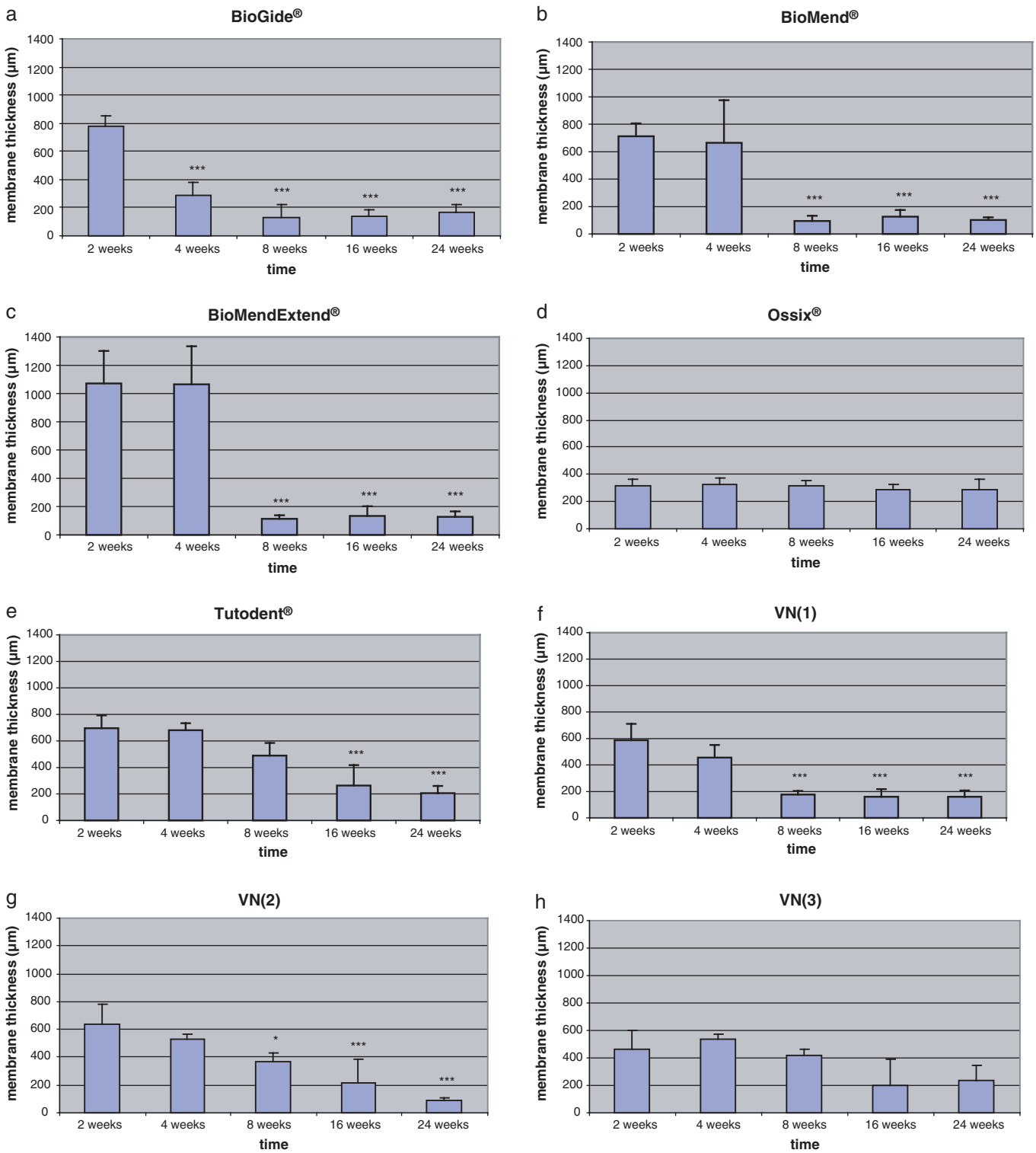

Fig. 2. (a–h) Membrane thickness (µm) ± SD as evaluated 2, 4, 8, 16 and 24 weeks following implantation. The stars indicate statistically significant differences within groups at each time point compared with baseline (2 week scores) (ANOVA; $^{*}P<0.05$, $^{**}P<0.01$, $^{***}P<0.001$).

connective tissue capsule around the membrane could not be observed. Inflammatory cells could still be observed in the tissue adjacent to the external surface of TD, BM, BME, VN(2), and VN(3) (Fig. 4c). Some single multinucleated giant cells could also be identified in the membrane body of TD, VN(2), and VN(3).

Eight-week specimens

After 8 weeks, the entire organization of BM, BME, and VN(1) resulted in a nearly complete biodegradation of the membrane body (Fig. 5a). Histological analysis revealed a vascularization of approximately 75% of the membrane body of VN(3) (Fig. 5b). There were still no signs of any vascularization or biodegradation noted for OS.

LifeNet Exhibit 2021
Embody, et al. v. LifeNet, IPR2025-00249
Page 4

16000501, 2005, 3, Downloaded from https://onlinelibrary.wiley.com/doi/10.1111/j.1600-0501.2005.01108.x by Rice University, Wiley Online Library on [23/10/2025]. See the Terms and Conditions (https://onlinelibrary.wiley.com/terms-and-conditions) on Wiley Online Library for rules of use; OA articles are governed by the applicable Creative Commons License

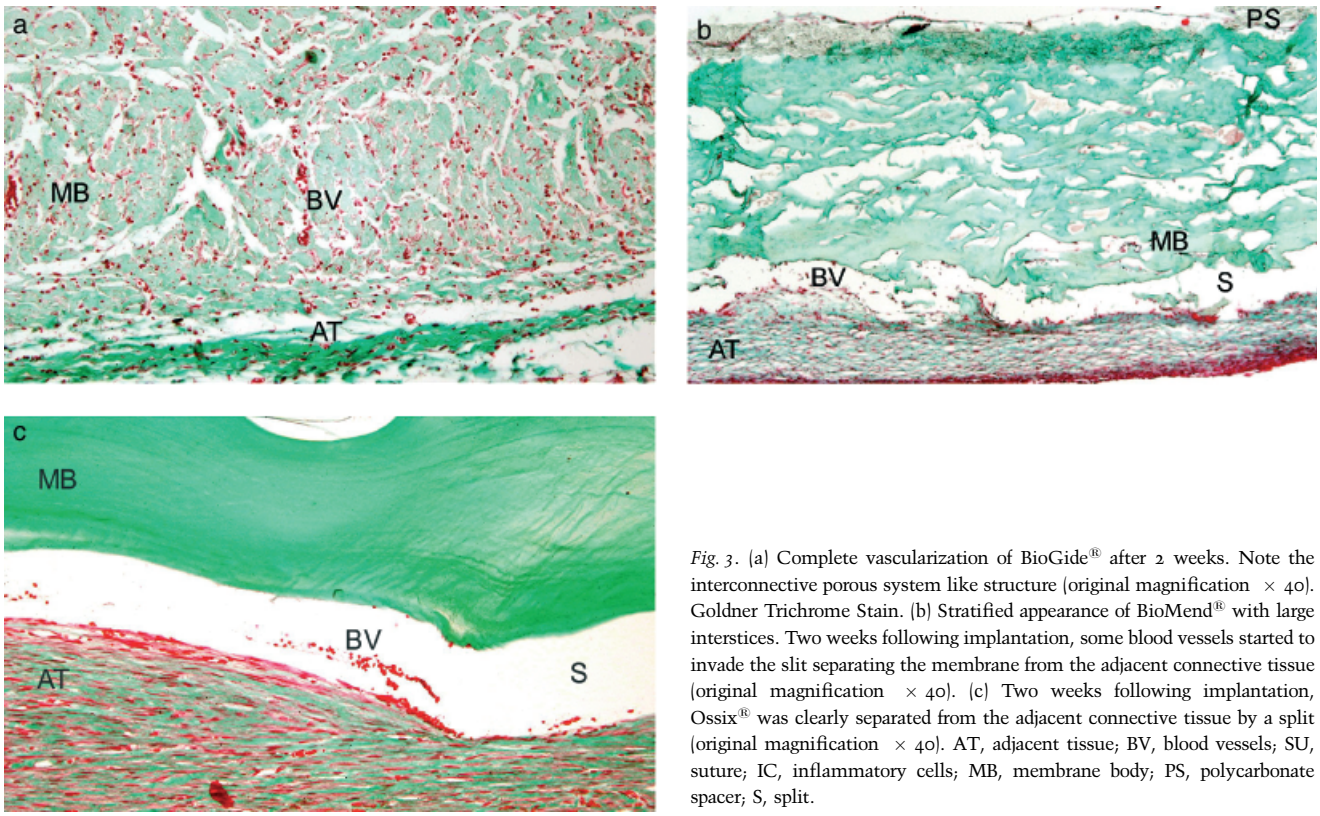

Fig. 3. (a) Complete vascularization of BioGide® after 2 weeks. Note the interconnective porous system like structure (original magnification × 40). Goldner Trichrome Stain. (b) Stratified appearance of BioMend® with large interstices. Two weeks following implantation, some blood vessels started to invade the slit separating the membrane from the adjacent connective tissue (original magnification × 40). (c) Two weeks following implantation, Ossix® was clearly separated from the adjacent connective tissue by a split (original magnification × 40). AT, adjacent tissue; BV, blood vessels; SU, suture; IC, inflammatory cells; MB, membrane body; PS, polycarbonate spacer; S, split.

However, some blood vessels started to invade the split separating the OS membrane from the adjacent tissue (Fig. 5c). The infiltration of inflammatory cells observed 2 and 4 weeks after implantation in the tissue adjacent to the external surface of TD, BM, BME, VN(2), and VN(3) was markedly reduced. However, some multinucleated giant cells could be identified in the membrane body of TD, VN(2), and VN(3).

Sixteen-week specimens

After 16 weeks, vascularization reached most areas of the membrane body of VN(3). However, in contrast to TD and VN(2), which were almost entirely organized and replaced by newly formed connective tissue (Fig. 6), the collagen structure of VN(3) could still be indentified. No signs of vascularization or biodegradation could be noted for OS, whereas blood vessels had completely filled the split separating the membrane from the surrounding connective tissue. Some multinucleated giant cells were still involved in the degradation process of TD, VN(2), and VN(3) (Fig. 6).

Twenty-four-week specimens

Histological analysis after 24 weeks revealed a nearly complete biodegradation and substitution of TD and VN(2) by newly formed connective tissue (Fig. 7a). Although VN(3) was completely vascularized, the collagen structure of this membrane could still be distinguished from the surrounding tissue. OS exhibited a slight superficial vascularization of the exposed portion of the membrane (Fig. 7b). Some single multinucleated giant cells could still be identified in the membrane body of VN(3).

The results of the histological and histometric analysis are summarized in Fig. 8.

Discussion

The present animal study was designed to evaluate the influence of different cross-linking techniques on biodegradation, vascularization, tissue integration and foreign body reaction of commercially available and experimental GBR/GTR collagen membranes. Within its limits, the results have shown that non-cross-linked porcine-derived collagen types I and III exhibited a perfect tissue integration and thereby fast vascularization, resulting in a nearly complete biodegradation 4 weeks following implantation without observable foreign body reactions. This is in accordance with a previous study evaluating resorption of BG randomly inserted and secured into surgical pouches of mongrel dogs. Moderate-to-severe degradation of this collagen membrane could be observed 4–8 weeks following implantation (Owens & Yukna 2001). The fast vascularization and subsequent degradation might be explained by the porous membrane properties noted for BG. However, when applying this membrane for GBR/GTR procedures, this specific structure may also allow for a nutrient transfer across the membrane, which in turn may improve the environment for bone regeneration (Hurley et al. 1959). Indeed, several histologic studies have shown that the use of BG in combination with porous bone mineral matrix has the capacity to stimulate substantial new bone and cementum formation with Sharpey's fiber attachment (Camelo et al. 1998, 2001; Yamada et al. 2002). In contrast, vascularization and biodegradation of non-cross-linked bovine type I collagen seemed to be prolonged. This might be explained

LifeNet Exhibit 2021
Embody, et al. v. LifeNet, IPR2025-00249
Page 5

16000501, 2005, 3, Downloaded from https://onlinelibrary.wiley.com/doi/10.1111/j.1600-0501.2005.01108.x by Rice University, Wiley Online Library on [23/10/2025]. See the Terms and Conditions (https://onlinelibrary.wiley.com/terms-and-conditions) on Wiley Online Library for rules of use; OA articles are governed by the applicable Creative Commons License

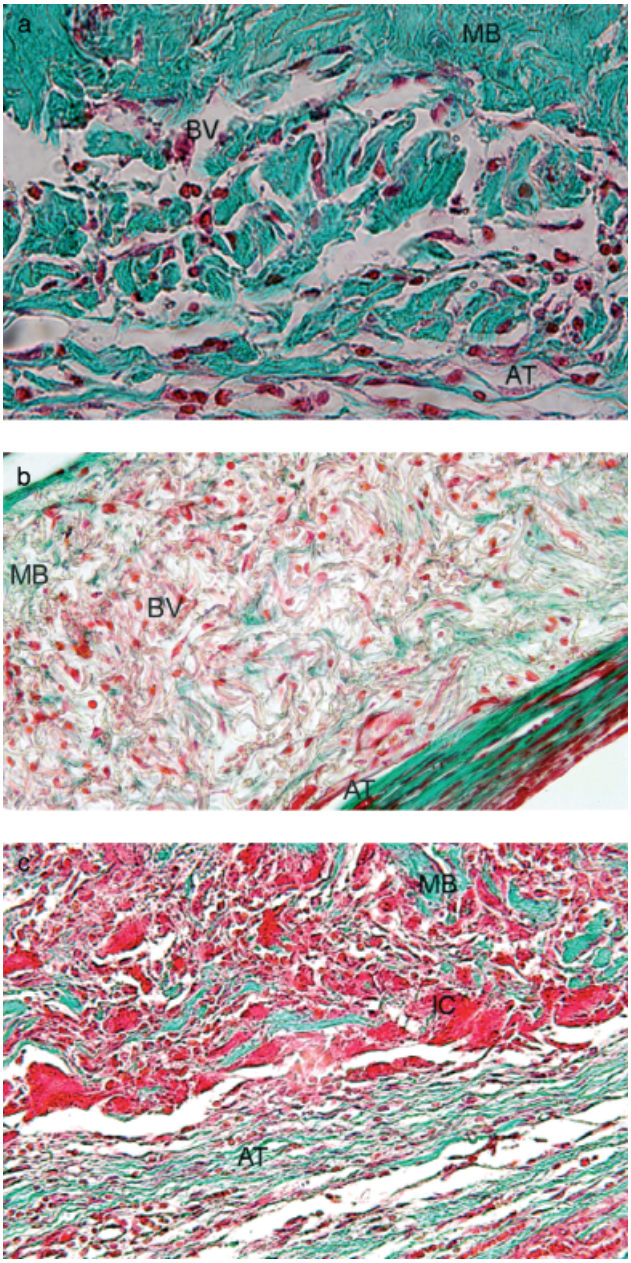

Fig. 4. (a) Nearly complete vascularization of TutoDent® after 4 weeks. Note the interconnective porous system like structure (original magnification × 200). (b) Entire organization and biodegradation of BioGide® 4 weeks following implantation (original magnification × 40). (c) Infiltration of inflammatory cells in the connective tissue adjacent to the external surface of VN(3) was observed after 4 weeks (original magnification × 200).

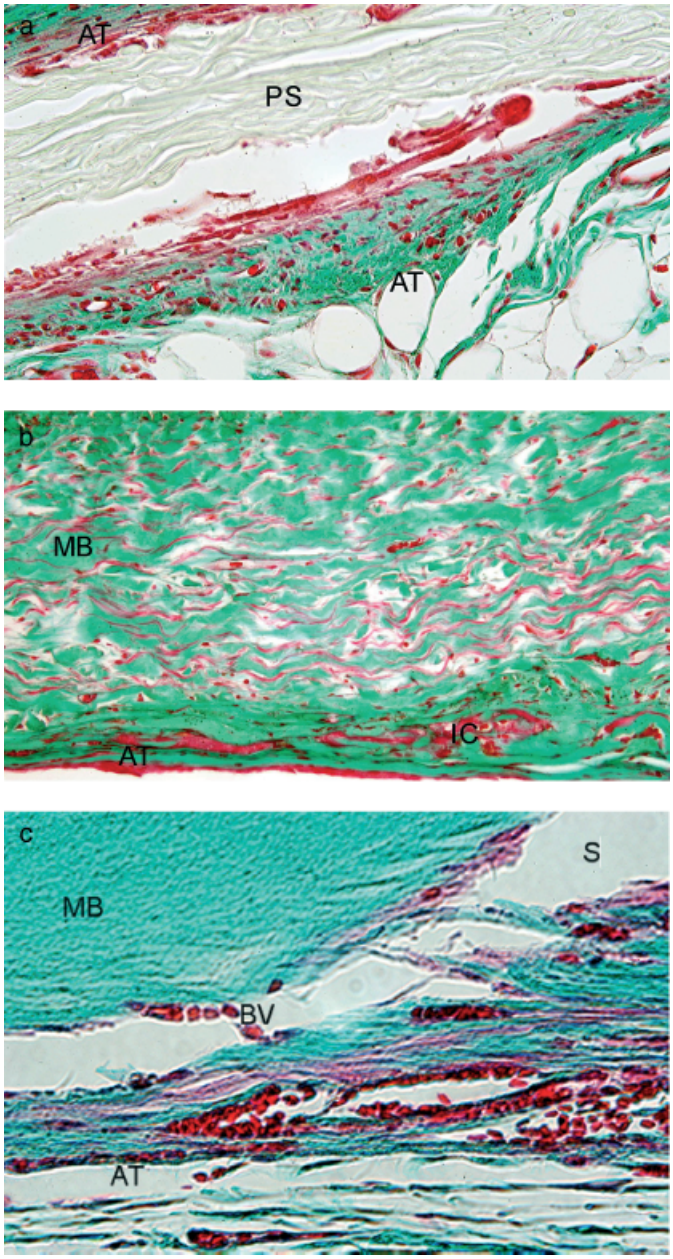

Fig. 5. (a) Entire organization and biodegradation of Bio MendExtend® 8 weeks following implantation (original magnification × 40). (b) Vascularization of approximately 75% of the membrane body of VN(3) 8 weeks following implantation (original magnification × 40). (c) Eight weeks following implantation, some blood vessels have started to invade the split separating the Ossix® membrane from the surrounding connective tissue (original magnification × 200).

by the compact structure of TD, offering more resistance to invading blood vessels. However, a previous study evaluating resorption of non-cross-linked type I bovine collagen after subcutaneous implantation in rats reported that this material was also replaced by normal connective tissue within 42 days (Unsal et al. 1997). Furthermore, Paul et al. (1992) have demonstrated that no residuals of intentionally exposed non-cross-linked type I bovine collagen was noted 1 week following implantation in humans. In this context, it must be queried whether data obtained from an *in vivo* study performed subcutaneously can be applied to the human oral cavity, since several periodontal pathogens such as *Porhyromonas gingivalis* and *Treponema denticola* have been reported to be capable of producing collagenase, promoting a premature degradation of the membrane (Sela et al. 2003). The present results have also demonstrated that vascularization and biodegradation of chemical and enzymatic cross-linked collagen membranes were obviously slower compared with non-cross-linked membranes. This is in line with previous results from animal studies demonstrating that degradation of cross-linked collagen membranes was signifi-

LifeNet Exhibit 2021
Embody, et al. v. LifeNet, IPR2025-00249
Page 6

16000501, 2005, 3, Downloaded from https://onlinelibrary.wiley.com/doi/10.1111/j.1600-0501.2005.01108.x by Rice University, Wiley Online Library on [23/10/2025]. See the Terms and Conditions (https://onlinelibrary.wiley.com/terms-and-conditions) on Wiley Online Library for rules of use; OA articles are governed by the applicable Creative Commons License

cantly slower compared with native collagen (Pitaru et al. 1988; Paul et al. 1992). However, in cases of BM, BME and OS this was accompanied by a limited tissue integration, and is observed as a split separating the membrane from the adjacent connective tissue. When interpreting the present results, it is also to be noted that histologic processing might have enhanced separation of the connective tissue because of a minimal degree of attachment to the occlusive structure. On the other hand, results from a recent *in vitro* study have shown that BM appeared to be incompatible with attachment and proliferation of both human PDL fibroblasts and human SaOs-2 osteoblasts (Rothamel et al. 2004). This is also in agreement with previous studies emphasizing that cross-linking with glutaraldehyde resulted in a decreased membrane biocompatibility because of cytotoxic effects (Speer et al. 1980; Wiebe et al. 1988). However, results from a recent histologic study, evaluating BG and BME for the treatment of implant dehiscence defects in dogs, have shown that both collagen membranes significantly enhanced bone regeneration (Oh et al. 2003). Regarding enzymatic cross-linking, results obtained from a recent *in vitro* study have demonstrated that OS exhibited comparable cellular attachment and proliferation as BG and TD (Rothamel et al. 2004). However, the present histologic analysis revealed a limited tissue integration of OS, outlining that cellular attachment seemed to be impaired under *in vivo* conditions. The observation that a slight superficial vascularization of the exposed portion of OS was only noted after 24 weeks raises the question of biodegradation of this collagen membrane. In this context, it is important to point to the results of a recent clinical and histologic study in humans evaluating OS for GBR procedures in combination with deproteinized bovine bone mineral (Friedmann et al. 2001). It was reported that collagen layers of the barrier could still be observed 7 months following healing. However, histologic observation revealed direct apposition of fibrous and bone tissues on the membrane surface. These findings are in line with the present observation that tissue integration of OS was markedly improved 24 weeks following implantation. Furthermore, it is important to emphasize that occurrence of barrier exposure was followed by complete secondary epitheliazation (Friedmann et al. 2001, 2002). All these data taken together seem to indicate that from a clinical point of view, OS might be a valuable collagen membrane for GBR procedures. To the best of our knowledge, these are the first data evaluating degradation pattern of chemical cross-linked porcine-derived collagen types I and III. It was observed that the resorption rate was directly related to the degree of cross-linking (i.e., the higher the degree of cross-linking, the longer the resorption rate). Indeed, compared with non-cross-linked BG, chemical cross-linking of VN(1–3) resulted in a prolonged degradation time. However, in cases of VN(2) and VN(3), inflammatory cells seemed to be involved in the process of biodegradation. Nevertheless, foreign body reactions were also observed for BM, BME and TD. In this context, it must be em-

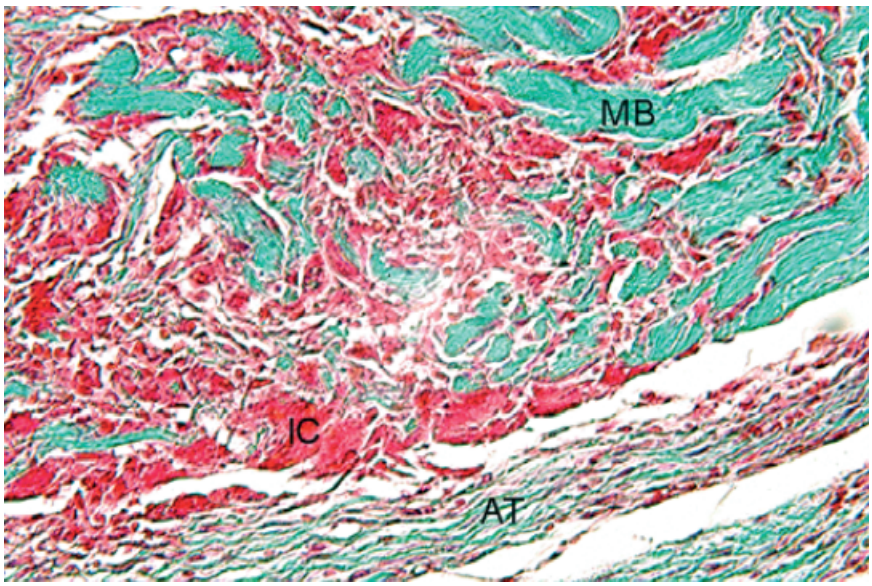

Fig. 6. Inflammatory cells could also be identified in the membrane body of VN(2), which was almost entirely organized 16 weeks following implantation (original magnification × 200).

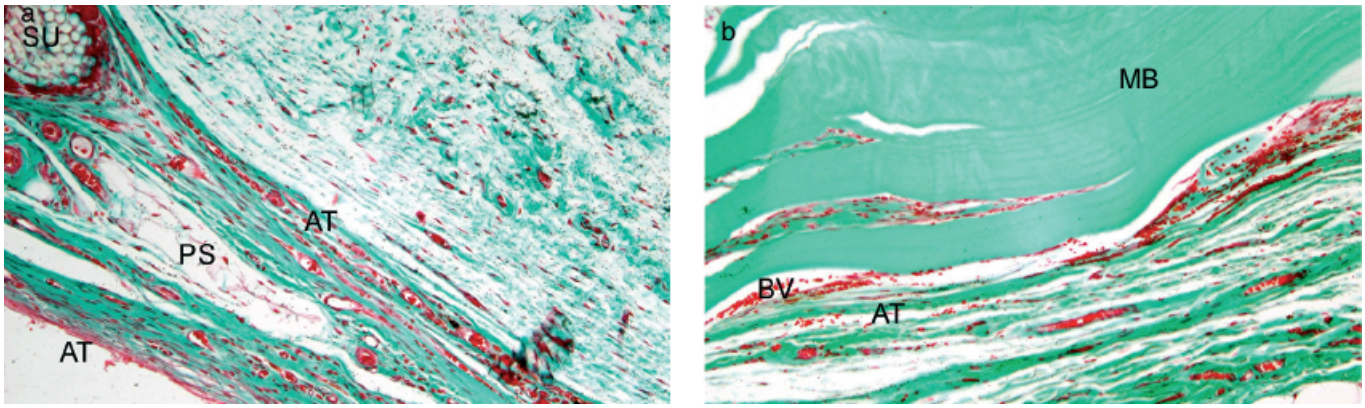

Fig. 7. (a) Histological analysis after 24 weeks revealed a nearly complete biodegradation of TD (original magnification × 40). (b) Twenty four weeks following implantation, Ossix® exhibited a slight superficial vascularization of the exposed portion of the membrane (original magnification × 40).

LifeNet Exhibit 2021
Embody, et al. v. LifeNet, IPR2025-00249
Page 7

16000501, 2005, 3, Downloaded from https://onlinelibrary.wiley.com/doi/10.1111/j.1600-0501.2005.01108.x by Rice University, Wiley Online Library on [23/10/2025]. See the Terms and Conditions (https://onlinelibrary.wiley.com/terms-and-conditions) on Wiley Online Library for rules of use; OA articles are governed by the applicable Creative Commons License

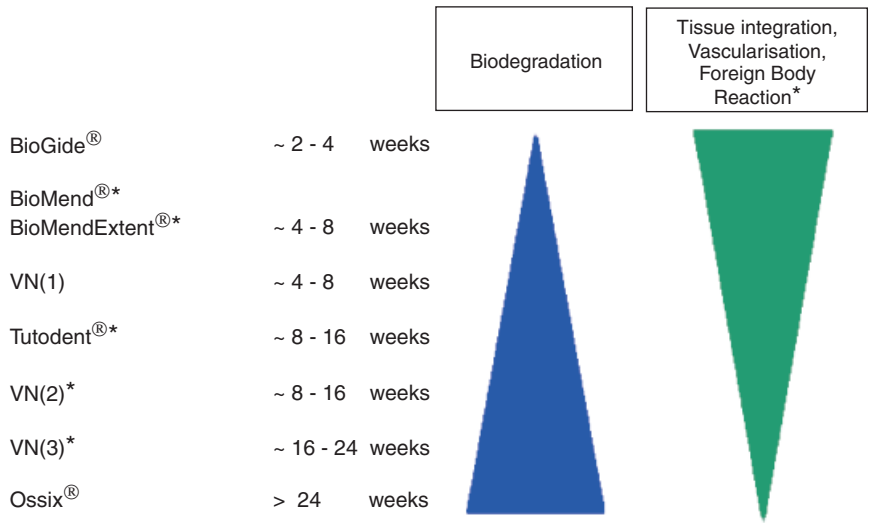

Fig. 8. Prolonged biodegradation seemed to be associated with decreased tissue integration, vascularization and also foreign body reactions.

phasized that pronounced foreign-body reaction may prevent or compromise connective tissue integration, since attachment and proliferation of fibroblasts have been reported to be necessary precursors to deposition of collagen and subsequent tissue integration (Somerman et al. 1991). When interpreting the present results it must also be noted that spacemaking duration has been reported to be another important factor strongly influencing the outcome of GBR/GTR procedures (Hardwick et al. 1994). Further studies using controlled experimental *in vivo* models are needed to evaluate the influence of different membrane requirements such as biocompatibility, barrier function, vascularization (nutrition transfer), foreign body reaction, tissue integration, and spacemaking ability on the outcome of healing following GBR/GTR procedures.

Within the limits of the present study, it was concluded that cross-linking of bovine- and porcine-derived collagen types I and III was associated with (i) prolonged biodegradation, (ii) decreased tissue integration and vascularization, and (iii) in case of TD, BM, BME, VN(2), and VN(3) with foreign body reactions.

Acknowledgements: We kindly appreciate the skills and commitment of Ms Brigitte Beck in the preparation of the histological specimens. The study materials were kindly provided by Geistlich Biomaterials, Sulzer Medica, Colla-Tec, Inc.; 3i, Colbar R&D Ltd., USA.

Résumé

Le but de cette étude a été de comparer la biodégradation de différentes membranes collagène croisé chez les rats. Cinq membranes disponibles dans le commerce et trois expérimentales (VN) ont été inclues : 1) Biogide® (BG) collagène de types I et III porcin non-croisé, 2) BioMend® (BM), 3) BioMendExtend® (BME) collagène type I bovin croisé glutaraldehyde, 4) Ossix® (OS) collagène type I bovin croisé enzymatique, TutoDent® (TD) collagène type I bovin non-croisé et (6–8) VN (1–3) : collagène type I et III porcin croisé chimique. Des spécimens ont été classés de manière randomisée dans des petits sacs sous-cutanés non-connectés, séparés chirurgicalement dans le dos de 40 rats Wistar qui ont été divisés en cinq groupes (2,4,8,16 et 24 semaines) incluant huit animaux chacun. Après deux , quatre, huit, seize et 24 semaines de guérison, les rats ont été euthanasiés et des spécimens ont été explantés et préparés pour les analyses histologique et histométrique. Les paramètres suivants ont été évalués : biodégradation avec le temps, vascularisation, intégration tissulaire et réaction du corps étranger. La vascularisation et l'intégration tissulaire les plus importantes ont été notées pour BG suivi par BM, BME et VN (1); TD, VN (2) VN (3) montraient une vascularisation prolongée tandis que OS n'en montrait aucune. La biodégradation de BG, BM BME et VN (1) était plus rapide que TD, VN (2) et VN (3). OS ne montrait qu'une toute petite quantité de biodégradation superficielle 24 semaines après l'implantation. La biodégradation de TD, BM, BME, VN(2) et VN (3) était associée à la présence de cellules inflammatoires. Dans les limites de l'étude présente les collagènes de types I et III du porcin et bovin croisés étaient associés à une biodégradation prolongée, une vascularisation et intégration tissulaire diminuant et, dans les cas de TD, BM, BME, VN (2) et VN (3), à des réactions aux corps étrangers.

Zusammenfassung

Das Ziel dieser Studie war, an Ratten den biologischen Abbau von biochemisch verschiedenartig verknüpften Kollagenmembranen zu untersuchen und zu vergleichen. Man untersuchte fünf im Handel erhältliche und drei experimentelle (VN) Membranen: (1) BioGide® (BG) (nicht kreuzvernetztes Kollagen Typ I und Typ III vom Schwein), (2) BioMend® (BM), (3) BioMendExtend® (BME) (jeweils Glutaraldehyd- kreuzvernetztes Kollagen Typ I vom Rind), (4) Ossix® (OS) (enzymatisch kreuzvernetztes Kollagen Typ I vom Rind), (5) TutoDent® (TD) (nicht kreuzvernetztes Kollagen Typ I vom Rind), und (6-8) VN (1-3) (chemisch kreuzvernetztes Kollagen Typ I und Typ III vom Schwein). Die Prüfstücke wurden rein zufällig in einander nicht berührende subkutane Taschen, die zuvor chirurgisch auf dem Rücken von 40 Wistar-Ratten präpariert worden waren, hineingesteckt. Die Ratten waren auf fünf Gruppen (2, 4, 8, 16 und 24 Wochen) mit je 8 Tieren aufgeteilt. Nach einer Heilungszeit von 2, 4, 8, 16 und 24 Wochen wurden die Ratten geopfert, die Prüfstücke explantiert und für die histologische und histometrische Analysen aufbereitet. Man untersuchte die folgenden Parameter: Biologischer Abbau im Verlauf der Zeit, Vaskularisation, Gewebsintegration und Fremdkörperreaktion. Die ausgedehnteste Vaskularisation und beste Gewebsintegration wurde für BG gefunden, gefolgt von BM, BME und VN (1); TD, VN (2) und VN (3) zeigten eine verzögerte, OS gar keine Vaskularisation. Daher war der biologische Abbau von BG, BM, BME und VN (1) rascher als bei TD, VN (2) und VN (3). OS zeigte 24 Wochen nach der Implantation lediglich eine minime oberflächliche biologische Zerfallserscheinung. Der biologische Abbau von TD, BM, BME, VN (2) und VN (3) ging einher mit dem Auftreten von Entzündungszellen. Mit den nötigen Einschränkungen bezüglich Aussagekraft dieser Studie schloss man daraus, dass kreuzvernetztes Kollagen Typ I und Typ III mit Ursprung vom Rind oder Schwein verbunden war mit (i) einer verlängerten biologischen Abbauzeit, (ii) verringerter Gewebsintegration und Vaskularisation und (iii) in den Fällen von TD, BM BME, VN (2) und VN (3) mit einer Fremdkörperreaktion.

Resumen

La intención del presente estudio fue comparar la biodegradación de diferentes membranas de colágeno interrelacionadas en ratas. Se incluyeron cinco membranas disponibles comercialmente y tres experimentales (VN): (1) BioGide® (BG) (colágeno porcino tipo I y III sin interrelación), (2) BioMend® (BM), (3) BioMendExtend® (BME) (colágeno bovino tipo I interrelacionado con glutaraldehido, respectivamente), (4) Ossix(OS) (colágeno bovino tipo I interrelación enzimática), (5) TutoDent® (TD) (colágeno bovino tipo I no interrelacionado), y (6–8) VN

LifeNet Exhibit 2021
Embody, et al. v. LifeNet, IPR2025-00249
Page 8

16000501, 2005, 3, Downloaded from https://onlinelibrary.wiley.com/doi/10.1111/j.1600-0501.2005.01108.x by Rice University, Wiley Online Library on [23/10/2025]. See the Terms and Conditions (https://onlinelibrary.wiley.com/terms-and-conditions) on Wiley Online Library for rules of use; OA articles are governed by the applicable Creative Commons License

(1–3) (colágeno porcino tipo I y III interrelacionado químicamente). Los especímenes se asignaron aleatoriamente a huecos subcutáneos no conectados separados quirúrgicamente en la espalda de 40 ratas wistar, que se dividieron en cinco grupos (2, 4, 8, 16 y 24 semanas), incluyendo 8 animales cada uno. Tras 2, 4, 8, 16 y 24 semanas de cicatrización, las ratas se sacrificaron y los especímenes explantados se prepararon para análisis histológicos e histométricos. Se evaluaron los siguientes parámetros: biodegradación a lo largo del tiempo, vascularización, integración tisular, reacción de cuerpo extraño. La mayor vascularización e integración tisular se observó para BN seguida por BM, BME y VN(1); TD, VN(2), y VN(3) se mostraron mas duración, mientras que OS no exhibió vascularización. Subsecuentemente, la biodegradación de TD, BM, BME y VN(1) fue más rápida que TD, VN(2), y VN(3). La OS mostró solo una mínima cantidad de degradación superficial a las 24 semanas de la implantación. La biodegradación de TD, BM, BME, VN(2), y VN(3) se asoció con la presencia de células inflamatorias. Dentro de los límites del presente estudio, se concluye que la interrelación de derivados colágenos bovino y porcino tipos I y III se asoció con (i) biodegradación prolongada, (ii) integración tisular y vascularización disminuida, y (iii) en el caso de TD, BM, BME, VN(2), y VN(3) con reacciones de cuerpo extraño.

要旨

本研究はラットにおいて異なる架橋重合のコラーゲン・メンブレンの生分解を比較した。市販メンブレン５つと実験用メンブレン（ＶＮ）３つを調べた；すなわち（１）BioGide®（非架橋重合、豚１型及び３型コラーゲン）、（２）BioMend ®（BM）、（３）（BioMendExtend®（BME）（各々グルタルアルデヒド架橋重合、ウシ１型コラーゲン）、（４） Ossix ®（OS）（酵素架橋重合、ウシ１型コラーゲン）、（５）TutoDent®(TD)(非架橋重合ウシ１型コラーゲン)、（６－８）VN（1-3）（化学架橋重合、豚１型及び３型コラーゲン）。これらの標本は、各群８匹ずつ合計４０匹のウィスター・ラットの背中に外科的に形成した非結合の皮下パウチに無作為に割り付けた。治癒２、４、８、１６、２４週間後にラットを屠殺し、摘出した標本を処理して、組織学的および組織計測学的分析を行った。以下のパラメータを評価した；経時的な生分解、血管新生、組織結合および異物反応。血管新生と組織結合は、ＢＧ、ＢＭ、ＢＭＥとＶＮ（１）の順に顕著であった。ＴＤ、ＶＮ（２）、ＶＮ（３）では遅延しており、他方ＯＳでは血管新生が認められなかった。次にＢＧ、ＢＭ、ＢＭＥとＶＮ（１）の生分解は、ＴＤ、ＶＮ（２）およびＶＮ（３）より速かった。ＯＳは埋入後２４週間後にわずかな表層の生分解を示すのみであった。ＴＤ、ＢＭ、ＢＭＥ、ＶＮ（２）、ＶＮ（３）の生分解には炎症細胞が存在していた。本研究の制約範囲内において、ウシと豚由来の１型および３型コラーゲンの架橋重合は（i）生分解の遅延、（ii）組織結合と血管新生の減少、（iii）ＴＤ、ＢＭ、ＢＭＥ、ＶＮ（２）とＶＮ（３）の場合は異物反応と関連していると結論される。

References

Becker, J., Neukam, F.W. & Schliephake, H. (1992) Restoration of the lateral sinus wall using a collagen type I membrane for guided tissue regeneration. *International Journal of Oral and Maxillofacial Surgery* **21**: 243–246.

Blumenthal, N. & Steinberg, J. (1990) The use of collagen membrane barriers in conjunction with combined demineralized bone–collagen gel implants in human infrabony defects. *Journal of Periodontology* **61**: 319–327.

Brunel, G., Piantoni, P., Elharar, F., Benque, E., Marin, P. & Zahedi, S. (1996) Regeneration of rat calvarial defects using a bioabsorbable membrane technique: influence of collagen cross-linking. *Journal of Periodontology* **67**: 1342–1348.

Bunyaratavej, P. & Wang, H.L. (2001) Collagen membranes: a review. *Journal of Periodontology* **72**: 215–229.

Camelo, M., Nevins, M.L., Lynch, S.E., Schenk, R.K., Simion, M. & Nevins, M. (2001) Periodontal regeneration with an autogenous bone–Bio-Oss composite graft and a Bio-Gide membrane. *International Journal of Periodontics & Restorative Dentistry* **21**: 109–119.

Camelo, M., Nevins, M.L., Schenk, R.K., Simion, M., Rasperini, G., Lynch, S.E. & Nevins, M. (1998) Clinical, radiographic, and histologic evaluation of human periodontal defects treated with Bio-Oss and Bio-Gide. *International Journal of Periodontics & Restorative Dentistry* **18**: 321–331.

Dahlin, C., Linde, A., Gottlow, J. & Nyman, S. (1988) Healing of bone defects by guided tissue regeneration. *Plastic and Reconstructive Surgery* **81**: 672–676.

Friedmann, A., Strietzel, F.P., Maretzki, B., Pitaru, S. & Bernimoulin, J.P. (2001) Observations on a new collagen barrier membrane in 16 consecutively treated patients. Clinical and histological findings. *Journal of Periodontology* **72**: 1616–1623.

Friedmann, A., Strietzel, F.P., Maretzki, B., Pitaru, S. & Bernimoulin, J.P. (2002) Histological assessment of augmented jaw bone utilizing a new collagen barrier membrane compared to a standard barrier membrane to protect a granular bone substitute material. *Clinical Oral Implants Research* **13**: 587–594.

Gottlow, J., Nyman, S., Lindhe, J., Karring, T. & Wennström, J. (1986) New attachment formation in the human periodontium by guided tissue regeneration. Case reports. *Journal of Clinical Periodontology* **13**: 604–616.

Greenstein, G. & Caton, J.G. (1993) Biodegradable barriers and guided tissue regeneration. *Periodontology 2000* **1**: 36–45.

Hämmerle, C.H. & Karring, T. (1998) Guided bone regeneration at oral implant sites. *Periodontology 2000* **17**: 151–175.

Hämmerle, C.H. & Lang, N.P. (2001) Single stage surgery combining transmucosal implant placement with guided bone regeneration and bioresorbable materials. *Clinical Oral Implants Research* **12**: 9–18.

Hardwick, R., Scantlebury, T.V., Sanchez, R., Whitley, N. & Ambruster, J. (1994) Membrane design criteria for guided bone regeneration of the alveolar ridge. In: Buser, D., Dahlin, C. & Schenk, R.K., eds. *Guided bone regeneration in implant dentistry*, 101–136. Chicago: Quintessenz Publishing.

Hurley, L.A., Stinchfield, F.E., Bassett, A.L. & Lyon, W.H. (1959) The role of soft tissues in osteogenesis. An experimental study of canine spine fusions. *American Journal of Orthopedics* **41-A**: 1243–1254.

Hutmacher, D., Hürzeler, M.B. & Schliephake, H. (1996) A review of material properties of biodegradable and bioresorbable polymers and devices for GTR and GBR applications. *International Journal of Oral & Maxillofacial Implants* **11**: 667–678.

Karring, T., Nyman, S., Gottlow, J. & Laurell, L. (1993) Development of the biological concept of guided tissue regeneration-animal and human studies. *Periodontology 2000* **1**: 26–35.

Kodama, T., Minabe, M., Hori, T. & Watanabe, Y. (1989) The effect of various concentrations of collagen barrier on periodontal wound healing. *Journal of Periodontology* **60**: 205–210.

Kohal, R.J., Mellas, P., Hürzeler, M.B., Trejo, P.M., Morrison, E. & Caffesse, R.G. (1998) The effects of guided bone regeneration and grafting on implants placed into immediate extraction sockets. An experimental study in dogs. *Journal of Periodontology* **69**: 927–937.

Locci, P., Calvitti, M., Belcastro, S., Pugliese, M., Guerra, M., Marinucci, L., Staffolani, N. & Becchetti, E. (1997) Phenotype expression of gingival fibroblasts cultured on membranes used in guided tissue regeneration. *Journal of Periodontology* **68**: 857–863.

Magnusson, I., Batich, C. & Collins, B.R. (1988) New attachment formation following controlled tissue regeneration using biodegradable membranes. *Journal of Periodontology* **59**: 1–6.

Mattson, J.S., Gallagher, S.J. & Jabro, M.H. (1999) The use of 2 bioabsorbable barrier membranes in the treatment of interproximal intrabony periodontal defects. *Journal of Periodontology* **70**: 510–517.

Minabe, M., Kodama, T., Kogou, T., Tamura, T., Hori, T., Watanabe, Y. & Miyata, T. (1989) Different cross-linked types of collagen implanted in rat palatal gingiva. *Journal of Periodontology* **60**: 35–43.

Oh, T.J., Meraw, S.J., Lee, E.J., Giannobile, W.V. & Wang, H.L. (2003) Comparative analysis of collagen membranes for the treatment of implant dehiscence defects. *Clinical Oral Implants Research* **14**: 80–90.

Owens, K.W. & Yukna, R.A. (2001) Collagen membrane resorption in dogs: a comparative study. *Implant Dentistry* **10**: 49–58.

Paul, B.F., Mellonig, J.T., Towle, H.J. 3rd & Gray, J.L. (1992) Use of a collagen barrier to enhance healing in human periodontal furcation defects. *International Journal of Periodontics & Restorative Dentistry* **12**: 123–131.

Pitaru, S., Tal, H., Soldinger, M., Grosskopf, A. & Noff, M. (1988) Partial regeneration of periodontal tissues using collagen barriers. Initial observations

LifeNet Exhibit 2021
Embody, et al. v. LifeNet, IPR2025-00249
Page 9

16000501, 2005, 3, Downloaded from https://onlinelibrary.wiley.com/doi/10.1111/j.1600-0501.2005.01108.x by Rice University, Wiley Online Library on [23/10/2025]. See the Terms and Conditions (https://onlinelibrary.wiley.com/terms-and-conditions) on Wiley Online Library for rules of use; OA articles are governed by the applicable Creative Commons License

in the canine. *Journal of Periodontology* **59**: 380–386.

Postlethwaite, A.E., Seyer, J.M. & Kang, A.H. (1978) Chemotactic attraction of human fibroblasts to type I, II, and III collagens and collagen-derived peptides. *Proceedings of the National Academy of Sciences of the United States of America* **75**: 871–875.

Quteish, D. & Dolby, A.E. (1992) The use of irradiated-crosslinked human collagen membrane in guided tissue regeneration. *Journal of Clinical Periodontology* **19**: 476–484.

Rothamel, D., Schwarz, F., Sculean, A., Herten, M., Scherbaum, W. & Becker, J. (2004) Biocompatibility of various collagen membranes in cultures of human PDL fibroblasts and osteoblast-like cells. *Clinicial Oral Implants Research* **15**: 443–449.

Sela, M.N., Kohavi, D., Krausz, E., Steinberg, D. & Rosen, G. (2003) Enzymatic degradation of collagen-guided tissue regeneration membranes by periodontal bacteria. *Clinical Oral Implants Research* **14**: 263–268.

Selvig, K.A., Kersten, B.G., Chamberlain, A.D., Wikesjo, U.M. & Nilveus, R.E. (1992) Regenerative surgery of intrabony periodontal defects using ePTFE barrier membranes: scanning electron microscopic evaluation of retrieved membranes versus clinical healing. *Journal of Periodontology* **63**: 974–978.

Sevor, J.J., Meffert, R.M. & Cassingham, R.J. (1993) Regeneration of dehisced alveolar bone adjacent to endosseous dental implants utilizing a resorbable collagen membrane: clinical and histologic results. *International Journal of Periodontics & Restorative Dentistry* **13**: 71–83.

Somerman, M.J., Sauk, J.J., Foster, R.A., Norris, K., Dickerson, K. & Argraves, W.S. (1991) Cell attachment activity of cementum: bone sialoprotein II identified in cementum. *Journal of Periodontal Research* **26**: 10–16.

Speer, D.P., Chvapil, M., Eskelson, C.D. & Ulreich, J. (1980) Biological effects of residual glutaraldehyde in glutaraldehyde-tanned collagen biomaterials. *Journal of Biomedical Materials Research* **14**: 753–764.

Tatakis, D.N., Promsudthi, A. & Wikesjö, U.M. (1999) Devices for periodontal regeneration. *Periodontology 2000* **19**: 59–73.

Tempro, P.J. & Nalbandian, J. (1993) Colonization of retrieved polytetrafluoroethylene membranes: morphological and microbiological observations. *Journal of Periodontology* **64**: 162–168.

Unsal, B., Kurtis, B., Ozcan, G., Özdemir, A. & Karaoz, E. (1997) An investigation of resorption and tissue reaction after subcutaneous implantation of collagen based membrane materials in rats. *Journal of Marmara University Dental Faculty* **2**: 609–615.

Wiebe, D., Megerman, J., L'Italien, G.J. & Abbott, W.M. (1988) Glutaraldehyde release from vascular prostheses of biologic origin. *Surgery* **104**: 26–33.

Yaffe, A., Ehrlich, J. & Shoshan, S. (1984) Restoration of periodontal attachment employing enriched collagen solution in the dog. *Journal of Periodontology* **55**: 623–628.

Yamada, S., Shima, N., Kitamura, H. & Sugito, H. (2002) Effect of porous xenographic bone graft with collagen barrier membrane on periodontal regeneration. *International Journal of Periodontics & Restorative Dentistry* **22**: 389–397.

Yukna, C.N. & Yukna, R.A. (1996) Multi-center evaluation of bioabsorbable collagen membrane for guided tissue regeneration in human Class II furcations. *Journal of Periodontology* **67**: 650–657.

Zahedi, S., Legrand, R., Brunel, G., Albert, A., Dewe, W., Coumans, B. & Bernard, J.P. (1998) Evaluation of a diphenylphosphorylazide-cross-linked collagen membrane for guided bone regeneration in mandibular defects in rats. *Journal of Periodontology* **69**: 1238–1246.

LifeNet Exhibit 2021
Embody, et al. v. LifeNet, IPR2025-00249
Page 10

16000501, 2005, 3, Downloaded from https://onlinelibrary.wiley.com/doi/10.1111/j.1600-0501.2005.01108.x by Rice University, Wiley Online Library on [23/10/2025]. See the Terms and Conditions (https://onlinelibrary.wiley.com/terms-and-conditions) on Wiley Online Library for rules of use; OA articles are governed by the applicable Creative Commons License