ResearchGate

See discussions, stats, and author profiles for this publication at: https://www.researchgate.net/publication/49665472

Skin-Derived Tenocyte-like Cells for the Treatment of Patellar Tendinopathy

Article *in* The American Journal of Sports Medicine · December 2010

DOI: 10.1177/0363546510387095 · Source: PubMed

CITATIONS
146

READS
1,804

6 authors, including:

Tim P Morris
University College London
188 PUBLICATIONS **8,004** CITATIONS

SEE PROFILE

David Connell
University of Tennessee at Knoxville
75 PUBLICATIONS **6,688** CITATIONS

SEE PROFILE

All content following this page was uploaded by Tim P Morris on 22 March 2016.

The user has requested enhancement of the downloaded file.

EMBZIM EX1206

AJSM PreView, published on December 7, 2010 as doi:10.1177/0363546510387095

Skin-Derived Tenocyte-like Cells for the Treatment of Patellar Tendinopathy

Andrew W. Clarke,*† FRANZCR, Faisal Alyas,† FRCR, Tim Morris,‡
Claire J. Robertson,§ MSc, PGCE, MCSP, Jonathan Bell,‖ FRCS(Orth), and
David A. Connell,† FRANZCR
Investigation performed at Royal National Orthopaedic Hospital, Stanmore, United Kingdom

Background: Recent research of lateral elbow tendinopathy has led to the use of laboratory-amplified tenocyte-like cells.

Hypothesis: Ultrasound-guided injection of autologous skin-derived tendon-like cells are effective compared with other injectable therapies for the treatment of refractory patellar tendinosis.

Study Design: Randomized controlled trial; Level of evidence, 1.

Methods: From 60 patellar tendons in 46 patients with refractory patellar tendinopathy, a 4-mm skin biopsy was sampled to grow tenocyte-like collagen-producing cells. Patients were allocated into 2 groups: (1) injection with laboratory-prepared, amplified collagen-producing cells derived from dermal fibroblasts and suspended in autologous plasma from centrifuged autologous whole blood or (2) injection with autologous plasma alone. Injections were made into the sites of hypoechogenicity, intrasubstance tears, and fibrillar discontinuity within the patellar tendon. The Victorian Institute of Sport Assessment (VISA) score was used to assess pain, severity, and functional disability. Ultrasound was performed to assess structural and blood flow changes, evaluating 4 criteria: tendon thickness, hypoechogenicity, intrasubstance tears, and neovascularity.

Results: In the cell group, mean VISA scores improved from 44 ± 15 before treatment to 75 ± 17 at 6 months; in the plasma group, from 50 ± 18 to 70 ± 14. Estimated average difference between groups was 8.1, a significantly higher score in the cell group. Patients treated with collagen-producing cells also had significantly faster improvement and a highly significant effect of treatment, with the difference between groups estimated as 2.5 per unit increase in $1/\sqrt{\text{time}}$. One patient treated with cell therapy had a late rupture and progressed to surgery; histopathology showed normal tendon structure.

Conclusion: Ultrasound-guided injection of autologous skin-derived tendon-like cells can be safely used in the short term to treat patellar tendinopathy, with faster response of treatment and significantly greater improvement in pain and function than with plasma alone.

Keywords: patellar tendinopathy; tenocyte-like cells; fibroblasts; cell therapy; plasma; tissue engineering

Patellar tendinopathy, also known as patellar tendinosis or jumper's knee, refers to the clinical entity of anterior knee pain typically localized to the inferior pole of the patella, with characteristic imaging and histologic findings. This entity has similar histologic findings to other chronic tendon disorders characterized by collagen fibrillar degeneration and angiofibroblastic proliferation.[29] Previous references to tendinitis are discouraged because it is well recognized that the process is associated with disruption of collagen fibers, with few inflammatory cells seen.[18,29]

This condition causes significant morbidity, and it may be refractory to nonoperative treatment.[27] Furthermore, there is no current consensus on the best surgical treatment,[15] and long-term follow-up of surgical treatment has shown minimal benefit over nonoperative measures.[3] A variety of nonoperative treatments have been assessed for treatment of patellar tendinopathy, with eccentric loading exercises[28] showing a likely positive effect, but specific protocols are debated.[33]

Ultrasound-guided interventional procedures have recently received attention, including sclerosant injection of neovessels[11] and dry needling/autologous blood injection.[13] Much more recently, the advent of tissue engineering using stem cells,[4] including skin-derived fibroblasts, has led to tendon regeneration in animal models.[8,21,24] Injection of stem cells is increasingly being used to treat tendon injury in race horses.[30] Ongoing debate centers on which tissue source should be used and which cells are preferable, undifferentiated or differentiated. However, a pilot study using skin-derived fibroblasts showed this to be safe and of therapeutic benefit.[6]

*Address correspondence to Andrew W. Clarke, Department of Radiology, Royal National Orthopaedic Hospital NHS Trust, Brockley Hill, Stanmore, Middlesex, London HA7 4LP United Kingdom (e-mail: david.connell@googlemail.com).

†Department of Radiology, Royal National Orthopaedic Hospital NHS Trust, London, United Kingdom.

‡MRC Clinical Trials Unit, London, United Kingdom.

§University of London, London, United Kingdom.

‖Kingston Hospital NHS Trust, Surrey, United Kingdom.

The authors declared that they had no conflicts of interest in their authorship and publication of this contribution.

The American Journal of Sports Medicine, Vol. XX, No. X
DOI: 10.1177/0363546510387095
© 2010 The Author(s)

EMBZIM EX1206

The current study aims to evaluate the efficacy of ultrasound-guided injection of autologous skin-derived, tenocyte-like cells for the treatment of refractory patellar tendinosis, using a double-blind randomized controlled trial. A randomized double-blind injection technique was used to allocate patients into 2 groups: Either (1) laboratory-prepared, amplified collagen-producing cells derived from dermal fibroblasts and suspended in autologous plasma from centrifuged autologous whole blood or (2) autologous plasma alone was injected into the sites of hypoechogenicity, intrasubstance tears, and fibrillar discontinuity within the patellar tendon under ultrasonographic guidance. A true placebo could not be used, because of ethical limitations. Plasma is necessary as a suspension agent for the cells and was therefore included in the control group.

METHODS

Study Design

We performed a prospective double-blind randomized controlled trial in an outpatient setting. Forty-nine consecutive patients were enrolled in the study after institutional review board and local ethics committee approval. Three patients were excluded after response to physiotherapy. There was computerized randomization of 60 patellar tendons in 41 men and 5 women (14 bilateral; 33 right, 27 left) with a mean age of 36 years (range, 20 to 51 years) and a diagnosis of patellar tendinopathy—clinically (point tenderness, pain on resisted knee extension) and sonographically (hypoechogenecity and loss of normal fibrillar architecture, with or without intrasubstance tears, neovascularity, and tendon thickening). The mean duration of symptoms was 11.1 months (range, 6 to 39 months). Inclusion criteria consisted of clinical and ultrasound diagnosis of patellar tendinopathy; duration longer than 6 months; and failure of nonoperative treatment, including rest, analgesia, acupuncture, and physiotherapy. Exclusion criteria consisted of no previous injectable treatment, no previous surgery, no bleeding diasthesis, no known allergies.

All patients underwent clinical review by sports physicians, orthopaedic surgeons, or rheumatologists and had a diagnosis of possible refractory patellar tendinopathy. Magnetic resonance imaging (MRI) was used to exclude any significant intra-articular pathologic abnormalities, including chondral flaps and defects and no fat pad impingement, as followed by ultrasound confirmation of the diagnosis by a musculoskeletal radiologist with 12 years' experience. Informed consent was obtained from all patients. At this point (labeled *screening*), pain and functional disability were assessed using a validated outcome measure, the Victoria Institute of Sport Assessment (VISA) questionnaire.[32] Patients then underwent physiotherapy assessment and treatment using a standardized protocol for 6 weeks as supervised by a registered physiotherapist. Patients then underwent repeat ultrasound assessment and outcome measure (labeled *baseline*). Patients who improved were excluded from the study. Those with refractory conditions then underwent skin biopsy. The tissue samples were anonymized and sent to an Austrian laboratory certified in good manufacturing practice (Innovacell, Innsbruck, Austria) for randomization and cell isolation and amplification. Based on a spreadsheet-created randomization list, the biopsy sample was selected for cell expansion or discarded. Patients with bilateral disease were randomized to either cells or plasma in each tendon, as decided by coin toss. After amplification, these cells were then injected into the tendon abnormality using a double-barreled syringe with associated autologous plasma (labeled *implant*). Those patients not randomized to cells received just plasma, as isolated from centrifuged autologous whole blood (8 mL) taken from the patient's antecubital fossa using a 21-gauge needle and 1-mL syringe. The blood was centrifuged for 5 minutes using the same unit (LC6, Sarstedt AG and Co, Numbrecht, Germany). The injector and patients were blind to who received cells. Plasma is necessary as a suspension agent for the cells and was therefore included in the control group.

Patients then continued with the physiotherapy protocol and were assessed with repeat outcome measure and ultrasound at 6 weeks, 3 months, and 6 months.

Clinical Assessment

Clinical diagnosis of patellar tendinopathy was based on symptoms of anterior knee pain on running or descending stairs and signs of point tenderness at the lower pole of the patella, with or without exacerbation on squatting. Failure of nonoperative therapy established the condition as refractory.

Outcome Measures. The patients' pain and function were recorded using the VISA questionnaire,[32] a validated index of patellar tendinopathy. At each stage (screening, baseline, implant, 6 weeks, 3 months, 6 months), the patient filled in the questionnaire before an ultrasound or an intervention was performed. The VISA questionnaire assesses symptoms, simple tests of function, and ability to play sport or other physical activity. Symptoms and function are assessed with 6 questions scored on a visual analog scale from 0 to 10, with 10 representing optimal health. Questions include pain at rest and walking down stairs, knee extension, squatting, and lunging. The final 2 questions assess the ability to perform sport or other physical activity and measure how that performance is affected. The maximal VISA score for an asymptomatic, fully performing individual is 100 points, and the theoretical minimum is 0 points. Appendix 1 summarizes the questionnaire (available in the online version of this article at http://ajs.sagepub.com/supplemental/).

Physiotherapy Protocol. Patients were reviewed by 2 physiotherapists and given a standardized program of increased eccentric loading and stretching exercises over 6 months based on work by Purdam et al.[28] Appendix 2 outlines the progression of exercises before and after injection.

Sonographic Technique

Either a musculoskeletal radiologist with 12 years' experience or a musculoskeletal radiology fellow examined all patients. A linear transducer (15-8 Mhz) on a Siemens

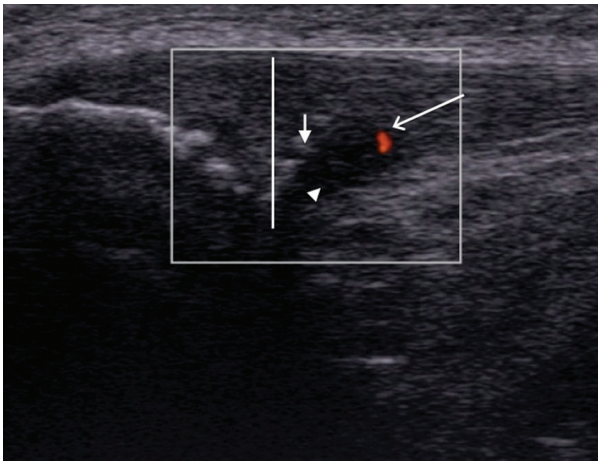

Figure 1. Ultrasound of the right patellar tendon in the longitudinal plane showing hypoechogenicity graded 5 (arrowhead), fibrillar discontinuity consistent with a 3-mm intrasubstance tear (short arrow), thickness of 8 mm (line), and neovascularity graded 6 (long arrow).

2000 ultrasound machine (Siemens, Erlangen, Germany) was used on all patients with a standardized superficial musculoskeletal preset. Examination was performed at time of recruitment (screening); after 6 weeks of physiotherapy at time of skin biopsy (baseline); at injection; and at 6 weeks, 3 months, and 6 months after injection. All images were recorded in static and dynamic formats for review and consensus of findings.

Patients were recumbent on an examination bed with the knee bent at 30° and the quadriceps muscles relaxed. The patellar tendon was examined in longitudinal and axial planes using both grayscale and color Doppler imaging with minimal pressure exerted.

Assessment was made of 4 ultrasound criteria: overall tendon thickness, echotexture, intrasubstance tears, and neovascularity.[17]

Echotexture was evaluated by identifying areas of hypoechoic change within the tendon. A semiquantitative score of 1 to 10 was assigned, with 0 representing a normal tendon echogenicity and 10 representing diffuse hypoechoic change seen throughout the entire tendon origin (Figure 1).

Discrete tears within the tendon were identified as focal areas of anechoic change with no intact fibers or as distinct hypoechoic planes of fibril discontinuity. The number and size of these tears were recorded (Figure 1).

Proximal tendon thickness was measured by placing 1 marker on the tendon surface and another marker at the deep tendon edge adjacent to infrapatellar fat. For the purpose of reproducibility, this was performed 5 mm from the inferior patellar bony margin (Figure 1). The distal tendon thickness, approximately 5 mm from the tendon insertion into the tibia, was also measured.

Neovascularity was assessed with maximum number of color pixels occupying the tendon origin, as scored between 1 and 10, with 0 representing no vessels (normal tendon) and 10 indicating 10 blood vessels or more.

Figure 2. Punch biopsy device and 4-mm biopsy specimen.

Image Interpretation

One musculoskeletal radiologist and 1 radiology fellow with 20 years' combined experience performed image interpretation and scoring. Scoring was performed from anonymized static images. Overall tendon thickness, echotexture intrasubstance tears, and neovascularity were scored using the scoring system outlined in the previous section. Tendon thickness was measured to the nearest millimeter. After review, scores were settled by consensus.

Cell Preparation

A 4-mm skin sample was obtained from the lateral side of the hip using a 4-mm punch biopsy needle (Figure 2) after infiltration of the skin with local anesthetic (lidocaine 1%, Xylocaine, AstraZeneca, London, United Kingdom) under aseptic technique. Once obtained, the skin sample was placed in cell transport medium (DMEM/F12 plus gentamicin) and sent to the laboratory under standard conditions of 4°C to 10°C. Based on a randomization list, the biopsy samples were selected for cell expansion or discarded.

Ten milliliters of whole blood was also collected from the antecubital fossa and sent for exclusion of syphilis, hepatitis B and C, and HIV as per regulatory guidelines. A barcoded computer tracking system was used to ensure that there was no mix-up of patient-derived material. Within the laboratory, the sample container was opened within a biosafety chamber, and a sterility test was performed. The skin sample was washed in phosphate buffered saline and underwent mechanical disintegration, after which the connective tissue was digested by adding a HEPES-containing medium—that is, 4-(2-hydroxyethyl)-1-piperazineethanesulfonic acid—with collagenase type 1 and fetal calf serum. Phosphate buffered saline was added the next day (ranging 14 to 24 hours from the time of sampling), and the connective tissue cells were isolated by centrifuge. The cell pellet was resolved by adding fibroblast medium to each 50-mL tube. The medium with the connective tissue

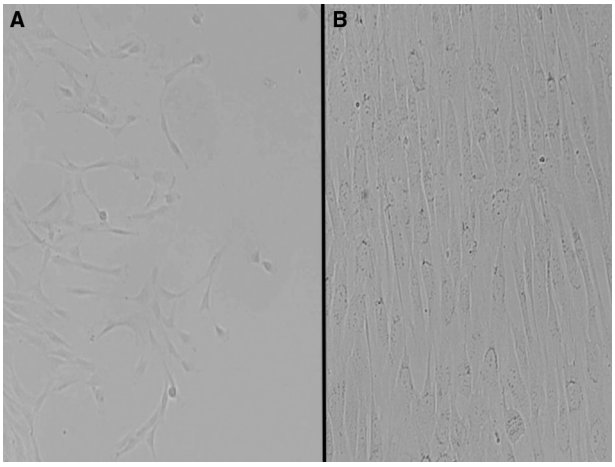

Figure 3. Skin-derived fibroblast growth at 5 days (A) and 14 days (B).

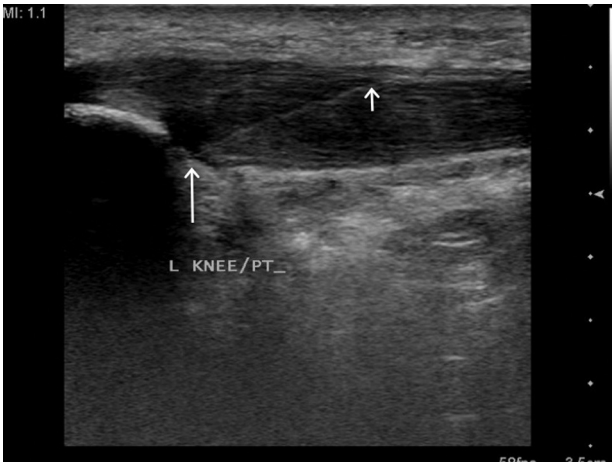

Figure 4. Ultrasound of the right patellar tendon in the longitudinal plane showing needle tip position at the deep proximal paratenon within hypoechogenic abnormality (long arrow) from an anterior approach (short arrow).

cells was transferred to tissue culture flasks, which were incubated in an incubator (5% CO_2, 37°C). Fetal calf serum serves as a medium additive for the propagation of the connective tissue cells. The serum originates from a bovine spongiform encephalopathy–free country and is covered by a European Drug Quality Directorate certificate.

In the laboratory, tenocyte-like cells were successfully grown in culture (Figure 3). These tenocyte-like cells showed exponential growth in cell medium culture and a mean number of 17.3 million (range, 10 to 28 million) were grown over a 4-week period in each preparation. The expanded fibroblasts showed a tenocyte-like behavior in an ex vivo linear stretching model (expression of collagen type I and III). Additional hematoxylin and eosin staining on this artificial tendon demonstrated a preservation of the collagen framework and a high amount of extracellular matrix.

One day before the injection, the cells were suspended in injection media (DMEM/F12) and transported under refrigeration (2°C to 8°C) to the clinical rooms. For the control arm of the study, injection media without cells were transported. The time between biopsy and injection (cell arm and control arm) was approximately 4 weeks in all cases. All samples were used within 36 hours.

Ultrasound-guided Injection Technique

All ultrasound assessment and injections were performed by a musculoskeletal radiologist with more than 12 years' experience (D.A.C.). Ultrasound was used to identify hypoechogenic abnormality, including intrasubstance tears and clefts within the tendon. Local anesthesia was used with 5 milliliters of bupivacaine (Marcaine 0.25%, AstraZeneca) infiltrated along the deep surface of the tendon using a 21-gauge needle. After this, the cell preparation was slowly introduced into the site of tendinosis and fibril discontinuity (Figure 4). This was performed using a double-chambered delivery system containing an equal amount (2 mL) of cell preparation injectate or media without cells in 1 chamber and autologous centrifuged plasma in the other chamber. The delivery system was prepared by a laboratory technician (study nurse), with both syringe chambers covered with tape to ensure blinding. Both radiologist and patient were blinded to the injectate. The side of injection and the number of the label was documented by the study nurse.

The total procedure time was kept to a minimum, ranging from 5 to 10 minutes. Immediately after injection, the patient was kept in a supine position without flexing the knee for 5 minutes. Patients were sent home with instructions to limit their use of the leg for the next 24 hours, avoiding stairs if possible. The use of nonsteroidal medication and any pain-provoking activities were prohibited, although acetaminophen was allowed. The patient was then reviewed by the physiotherapist 1 week later and supervised while continuing the eccentric-loading physiotherapy program.

Statistical Analysis

Sample size calculation was performed by independent statisticians as part of ethics committee approval. Based on 5% significance and 80% power to detect a clinically important difference (assumed as 5 points on an 100-point pain and function outcome measure; ie, VISA), sample size was calculated at 25 in each group. A CONSORT diagram is provided (Figure 5).

Statistical analysis of results was performed by an independent statistician from the MRC Clinical Trials Unit (London, United Kingdom). Two analyses were run to answer 2 questions, the difference in VISA scores at 6 months and change in VISA over time. Results are presented as estimate (95% confidence interval [CI]; P value). The first analysis simply looked at 6-month VISA scores of cells and plasma groups as an outcome, adjusted for baseline VISA and biopsy VISA (both collected before randomization) via analysis of

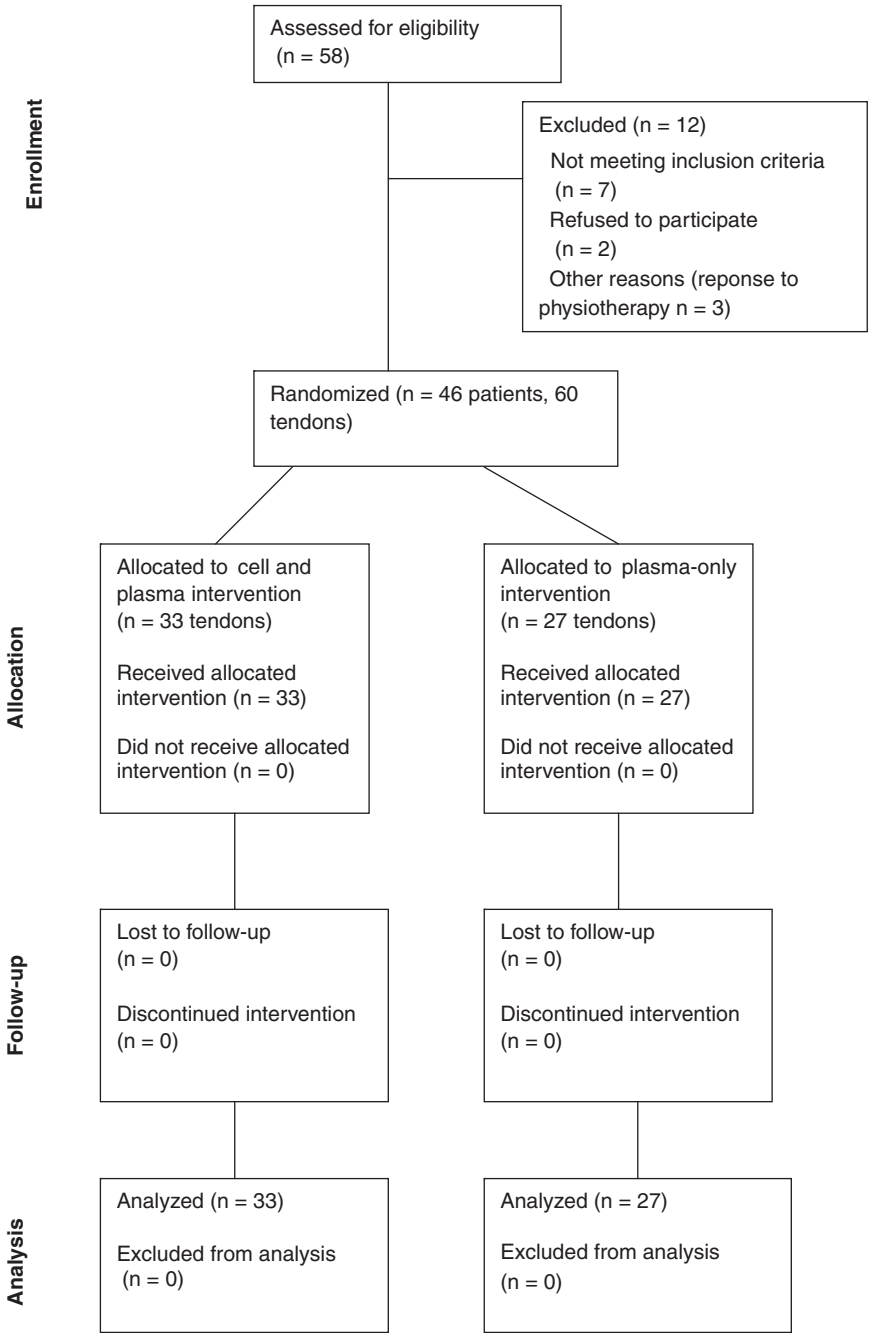

Figure 5. CONSORT diagram.

covariance. Standard errors (and, therefore, 95% CI) were estimated using robust variance estimators.[12]

In the second analysis, change over time was estimated using linear mixed models, which allows efficient modeling of outcomes by accounting for the longitudinal structure of measurements. Adjustment was made for baseline VISA to increase precision and help equalize the effects of any baseline imbalance. The VISA scores appeared to be normally distributed and so remained untransformed. Fractional polynomial powers were used to find the best-fitting expression of time. The model included random intercepts and slopes, along with an unstructured covariance matrix. As a corollary, this model naturally accounted for the within-person correlation caused by inclusion of bilateral knees. A difference in VISA scores of 5 points was considered statistically significant. Bilateral knees (1 injected with plasma, 1 with cells) were compared as a separate analysis because such patients effectively had a control to compare with.

All statistical analyses and graphics were produced in Stata 10 (StataCorp, College Station, Texas). Statistical

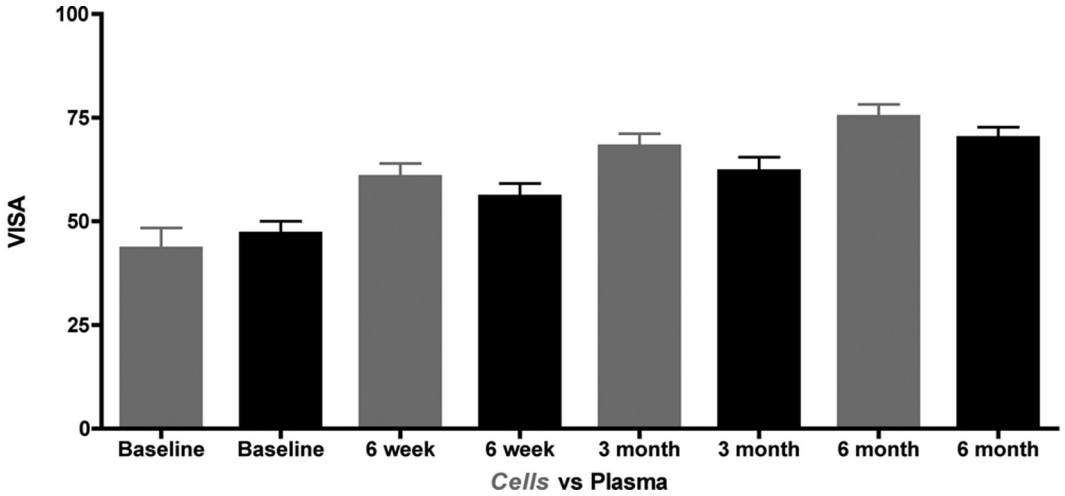

Figure 6. Baseline, 6-week, 3-month, and 6-month postinjection Victoria Institute of Sport Assessment (VISA) scores in all knees within cell and plasma groups. The top of the bar represents the mean; the line represents the 95% confidence interval.

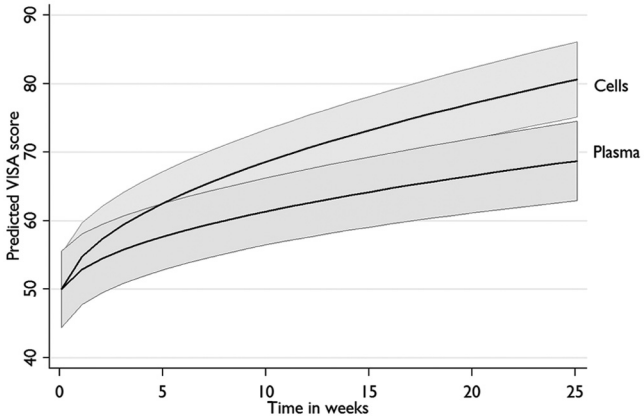

Figure 7. Representation of the expected improvement of Victoria Institute of Sport Assessment (VISA) scores over time (weeks) in cells and plasma groups from a hypothetical pretreatment score of 50.

results were reviewed by a second independent statistician based in another country, who concurred with the results.

RESULTS

Between July 2007 and July 2009, 46 patients were referred for assessment, having met the clinical inclusion and exclusion criteria. All met criteria for diagnosis and signed consent forms after a comprehensive explanation process. There was no loss to follow-up. Overall, 60 patellar tendons were assessed (14 bilateral; 33 right, 27 left) in 46 patients (41 men and 5 women; mean age, 36; range, 20 to 51 years). None of the patients were positive for blood-borne pathogens. With use of computerized randomization, 33 knees were entered into the cell and plasma group and 27 into the plasma only group.

Each patient had only 1 cell or control injection per injected knee. In the cell group, 29 of 33 patients expressed satisfaction with both the procedure and the outcome, and all 29 were ready to undergo the procedure again if needed. In the plasma group, 19 of 29 patients expressed satisfaction with both the procedure and the outcome.

One patient in the cell group had late tendon rupture after significant trauma during football where a player fell on his knee and he had to undergo surgical repair. One patient needed suture material removed from the biopsy site at 3 weeks, after it had undergone hypertrophic but not infective response. No significant skin scarring was reported at 6 months. No other complications were encountered.

VISA Scores

Figure 6 shows the distribution of VISA scores before injection and at 26 weeks (6 months) for the cell and plasma groups. This box-and-whisker graph shows mean scores within a box representing the upper and lower quartiles, with the whiskers representing the range.

In the cell group, mean VISA scores improved from 44 ± 15 before treatment to 75 ± 17 at 6 months. In the plasma group, mean VISA scores before treatment were 50 ± 18, improving to 70 ± 14 at 6 months.

Two outcomes were assessed statistically: 6-month VISA scores and change in VISA over time. Mean difference in VISA between cell and plasma groups was 8.1 (95% CI, 2.4 to 13.7; P = .006), adjusted for VISA as baseline and biopsy and demonstrating a significantly higher VISA score in the cell group (and, therefore, superior pain decrease and increased function).

The difference in speed of VISA improvement between the 2 groups was also calculated. Change in VISA was approximately linear in $1/\sqrt{\text{time}}$ (estimated using fractional polynomial curves). Again, there was a highly significant effect of treatment, with the difference between groups estimated as 2.5 per unit increase in $1/\sqrt{\text{time}}$ (95% CI, 0.9 to 4.1; P = .002). To make this result easier to visualize, a graph is provided with the estimated effect

TABLE 1
Ultrasound Results[a]

	Thickness		Hypoechogenicity		Tear Size		Neovascularity	
	Baseline	6 Months	Baseline	6 Months	Baseline	6 Months	Baseline	6 Months
Plasma								
Minimum	4.6	4.2	2	1	0	0	0	0
25th percentile	7	6.1	5	2.5	4.3	0	0	0.5
Median	8.1	7.4	6	3.95	7.7	2.05	2	2
75th percentile	10.1	8.85	8	5	13	3.35	3	3.5
Maximum	14.4	11.4	9	7	22	4.3	9	7
Mean	8.513	7.517	6.261	3.828	8.613	1.822	2.304	2.353
SD	2.282	1.822	1.959	1.79	4.977	1.686	2.754	2.149
SE	0.4759	0.4295	0.4085	0.4219	1.038	0.3973	0.5743	0.5212
Lower 95% CI, mean	7.526	6.611	5.414	2.938	6.461	0.9839	1.113	1.248
Upper 95% CI, mean	9.5	8.423	7.108	4.718	10.77	2.661	3.495	3.458
P		.1386		.0002		.0072		.6508
Cells								
Minimum	4.8	5.2	4	0	3.1	0	0	0
25th percentile	8.1	7.4	5	3	5.2	0	0	0
Median	9.2	7.9	7	4	8.8	2.7	2	3
75th percentile	10	9.2	8	5	13.85	4.2	4	3
Maximum	13	9.6	9	8	35	6.4	8	10
Mean	9.146	7.913	6.52	4.13	10.47	2.414	2.28	2.696
SD	1.666	1.368	1.584	2.302	7.146	2.194	2.227	2.687
SE	0.3267	0.2852	0.3169	0.4801	1.429	0.4679	0.4454	0.5603
Lower 95% CI, mean	8.473	7.322	5.866	3.135	7.518	1.441	1.361	1.534
Upper 95% CI, mean	9.819	8.505	7.174	5.126	13.42	3.387	3.199	3.858
P		.0072		.0001		< .0001		.7248

[a]CI, confidence interval.

of cells and fibroblasts over time; this represents the predicted effect for a sample patient with a VISA score of 50 at randomization (Figure 7).

Ultrasound

Table 1 summarizes the change in ultrasound appearances from baseline to 6 months in the plasma and cell groups, which both showed a significant ($P < .05$) decrease in hypoechogenicity and tear size. In the cell group, there was also a significant decrease in tendon thickness. No significant change was identified in neovascularity.

Surgical Specimen

Histopathologic correlation of the repaired tendon was available in 1 patient undergoing open surgery for rupture (Figure 8). This shows almost-normal-appearing tenocyte-like cells in the area of rupture, thereby supporting the hypothesis that injected cells produce collagen and re-create normal tendon.

DISCUSSION

Patellar tendinopathy is a common condition, with incidence estimated at up to 20% in athletic populations.[25] Furthermore, the condition is particularly debilitating, with as many as a third of athletes with the condition unable to return to sport after 6 months.[7] The condition was initially seen in primarily jumping sports and thought to be secondary to abnormal loading of the extensor mechanism—hence, the term *jumper's knee*.[5] Mechanical overload is the most frequently reported extrinsic factor,[34] and there is increased incidence in jumping sports; however, the condition is seen in other sports, supporting the involvement of intrinsic factors. Multiple intrinsic etiologic factors have been proposed, such as leg length discrepancy,[22] impingement,[14] malalignment, patellar alta, muscular tightness, and imbalance.[36]

The exact pathogenesis is still unknown. Matrix-mediated changes, where repetitive heavy loading leads to microtrauma and failed healing, are thought to predominate. However, cellular-triggered pathologic changes have been more recently proposed, with stress-activated protein kinases identified.[1] The identification of increased apoptosis in patellar tendinosis supports cell-mediated pathologic changes.[23] Histologically, the condition is degenerative and noninflammatory and is similar to other tendon overuse injuries. There is a lack of neutrophils and macrophages, as well as disorganized collagen and increased vascularity, and fatty, mucoid, or hyaline degeneration predominates. Inflammation is not a feature, and the term *tendinitis* has been abandoned.[19] The features of fibroblastic hyperplasia, vascular hyperplasia, and abnormal collagen production are thought to be hallmarks of failed tendon healing.[20]

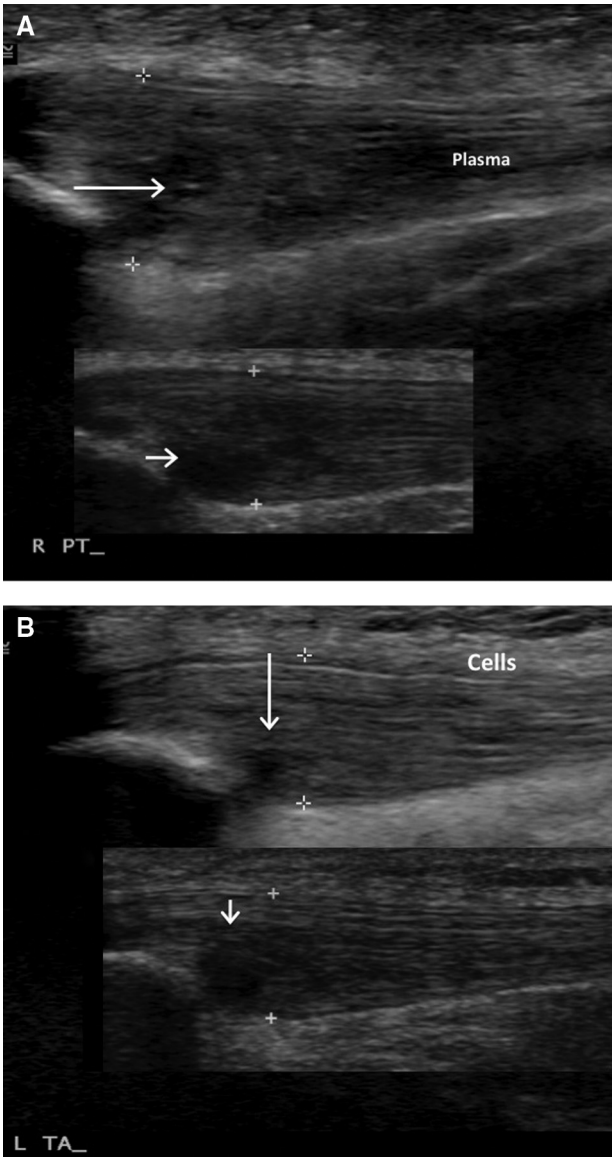

Figure 8. A, ultrasound of the right patellar tendon in the longitudinal plane showing patellar tendon before (inset) and after treatment with plasma only. The large arrow shows echogenic scarring within the initial hypoechogenic abnormality (small arrow). B, ultrasound of the left patellar tendon in the longitudinal plane of the other knee of the same patient treated with plasma and cells shows almost complete replacement of the initial hypoechogenic abnormality (inset; small arrow) with normal-appearing fibrillar tendon material (large arrow).

Patellar tendinopathy is essentially a clinical diagnosis, but the accuracy of ultrasound in assessing structural (tendon thickening, hypoechogenicity, intrasubstance tears) and blood flow changes or neovascularity is well described.[31,35] Spatial resolution is superior to MRI. However, reported ultrasound sensitivity and specificity vary, with variable correlation between severity of symptoms and grading systems.[34] Symptomatic assessment with a pain and



Figure 9. Histopathologic specimen of cell-injected tendon at 19 500× magnification showing almost-normal-appearing tendon-like cells.

function scale is therefore useful in assessing response to treatment.[32]

Current treatment involves nonoperative measures in general, related to rest or some form of eccentric loading physical therapy, injection therapy, or surgery. Because this condition is often refractory to nonoperative measures[27] and surgery is used for severe or last-resort cases, attention has turned to injectable treatment of failed tendon healing. Corticosteroids, although providing some short-term analgesia, may inhibit collagen synthesis and decrease tendon strength.[16] Sclerosant injection may reduce pain by targeting nerve fibers associated with neovessels; however, this does not seem to address the underlying pathologic changes. No association was identified with change in VISA scores and neovascularization in a recent study.[10] Dry needling or barbotage has shown some efficacy.[13] Injection therapy with autologous blood[13] and platelet-rich plasma[26] have shown encouraging results; these may work by recruiting tenocytes/collagen-producing cells to the site, which can then lay down collagen. There may also be a degree of inflammation induced, thereby leading to fibrosis and scarring.

Another strategy is to place cells directly into a site of tendinosis and collagen rupture for these cells to lay down collagen type I and III fibers. The source of these cells (ie, tendon, marrow, or skin) is controversial, as is whether they should be differentiated or not. Undifferentiated cells run the risk that they may not mature into the desired cell type. Using differentiated tendon cells derived from normal tendon runs the risk of damaging normal tendon.[2]

Tendon regeneration using tenocyte-like fibroblast cells[8,21,24] has been reported. Skin represents an abundant and accessible source of cells that can be used for cell therapy. In vitro, these skin-derived fibroblasts can be driven toward tenocyte differentiation[37] by being immersed in a tendon environment and subjected to mechanical forces.[9] A pilot study in humans recently showed this treatment to

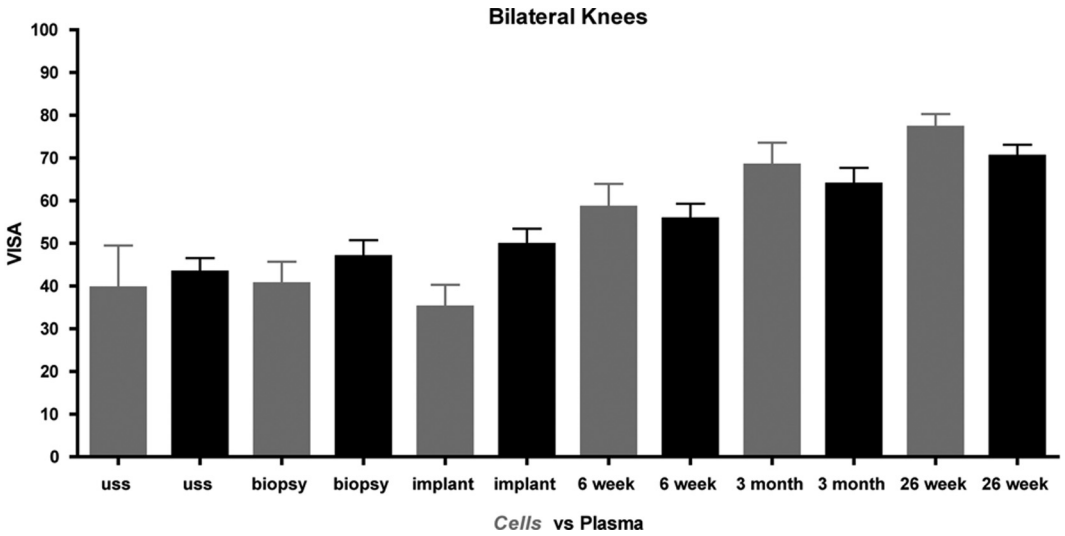

Figure 10. Bar graph showing Victoria Institute of Sport Assessment (VISA) scores in cells and plasma groups in patients with bilateral treatment (1 knee, cell; 1 knee, plasma). The top of the bar represents the mean score at each stage; the line represents the 95% confidence interval.

be safe and suggestive of therapeutic benefit.[6] This study aimed to assess the safety and efficacy of skin-derived and amplified fibroblasts and plasma in treating patellar tendinosis in comparison to plasma alone.

The results showed a significantly greater improvement in pain and function scores in the cell group, with an estimated average difference of 8.1 VISA points. The design of the study was such that although the control and treatment groups contained plasma and needle injection (with each having shown some treatment effect in previous papers), the addition of cells showed a significant improvement in VISA scores. Both groups showed a treatment effect; however, the cell group showed a greater response. This is assumed to be clinically important, although the original VISA study did not specify an exact figure. Further statistical analysis showed a faster increase immediately after injection in the cell group, as represented by a steeper initial rise in the cell curve in Figure 7. This suggests that initial collagen production occurs more quickly than in the plasma group alone, possibly because the cells are physically present within the site of tendon injury, which may allow for more rapid repair. No evidence is available to support this supposition, however. This study assessed only a one-off injection; multiple, staggered injections may maintain or amplify this initial response. Furthermore, we do not know the optimal number of cells that should be injected. These may well vary according to the degree of tendon damage and the size of the tear. A cost-effectiveness analysis has not been performed; however, the current costs involved are comparable to surgery in the country where the research was performed (United Kingdom).

Ultrasound assessment showed improvement in structural changes in both groups, in keeping with the treatment effect identified in both. No statistically significant difference was identified between the 2 treatment groups. However, ultrasound images showed subjective qualitative improvements in the tendon of the cell therapy group, with restoration of a "more normal" echogenic fibrillar pattern. Figure 8 shows the patellar tendons in 1 patient with bilateral tendinopathy. Ultrasound showed a decrease in hypoechogenic defect in both tendons; however, in the plasma tendon (Figure 8B), there is echogenic scarlike material seen, whereas in the cell tendon (Figure 8A), the superior aspect of the defect has almost been completely replaced with normal-appearing tendon.

Histologic analysis of the patient with late rupture showed normal-appearing tenocytes where features of tendinosis were expected (Figure 9). As a solitary case, this adds support to our hypothesis that skin-derived fibroblasts—as injected into a tendon and then eccentrically loaded—can be driven to tenocyte differentiation and collagen production and so ultimately help repair the area of tendinosis. Intuitively, this seems to be a better repair than fibrosis and scarring, with improved tensile strength. For confirmation of this supposition, histologic analysis would have been needed for each patient, but this was deemed unethical in the context of this study.

Of interest in patients with bilateral tendinosis, 9 of 14 patients had VISA improvements of >5 points in their cell-injected knee compared with the plasma-injected knee. Only 1 patient reported a lower VISA score in the cell knee, which suggests a less inflammatory response to the injectate, although no histologic confirmation of this was possible. Also, knees injected with cells had a greater initial VISA response after injection (Figure 10), as shown by the rapid rise in mean cell VISA scores from implant to 6 weeks. Anecdotally, 1 patient in the cell therapy cohort had been unable to run for 3 years but then completed a 150-mile (241-km) run across the Sahara within 6 months of the treatment.

Limitations of this study included the difficulties in quantifying structural changes after treatment (despite

the use of high-quality ultrasound) and the lack of histopathologic correlation. Histopathologic assessment of the tendons was considered ethically inappropriate. Also, only short-term follow-up of 6 months was performed.

This study suggests that treatment of tendinopathy with skin-derived collagen-producing cells is safe and effective in the short term. The application of the technique, including the number of injections and use in other tendon overuse conditions, will need further assessment. The exact healing mechanism remains uncertain. Other issues include the substantial time lag (4 weeks), cell transport issues, and expense involved in cell amplification.

CONCLUSION

Ultrasound-guided injection of autologous skin-derived tendon-like cells can be safely used to treat patellar tendinopathy with, in the short term, faster response of treatment and significantly greater improvement in pain and function than injection of plasma alone.

REFERENCES

1. Arnoczky SP, Tian T, Lavagnino M, Gardner K, Schuler P, Morse P. Activation of stress-activated protein kinases (SAPK) in tendon cells following cyclic strain: the effects of strain frequency, strain magnitude, and cytosolic calcium. *J Orthop Res*. 2002;20(5):947-952.
2. Awad HA, Butler DL, Boivin GP, et al. Autologous mesenchymal stem cell-mediated repair of tendon. *Tissue Eng*. 1999;5(3):267-277.
3. Bahr R, Fossan B, Loken S, Engebretsen L. Surgical treatment compared with eccentric training for patellar tendinopathy (jumper's knee): a randomized, controlled trial. *J Bone Joint Surg Am*. 2006;88(8):1689-1698.
4. Bianco P, Robey PG. Stem cells in tissue engineering. *Nature*. 2001;414(6859):118-121.
5. Blazina ME, Kerlan RK, Jobe FW, Carter VS, Carlson GJ. Jumper's knee. *Orthop Clin North Am*. 1973;4(3):665-678.
6. Connell D, Datir A, Alyas F, Curtis M. Treatment of lateral epicondylitis using skin-derived tenocyte-like cells. *Br J Sports Med*. 2009;43(4):293-298.
7. Cook JL, Khan KM, Harcourt PR, Grant M, Young DA, Bonar SF. A cross sectional study of 100 athletes with jumper's knee managed conservatively and surgically: the Victorian Institute of Sport Tendon Study Group. *Br J Sports Med*. 1997;31(4):332-336.
8. Deng D, Liu W, Xu F, et al. [In vitro tendon engineering using human dermal fibroblasts]. *Zhonghua Yi Xue Za Zhi*. 2008;88(13):914-918.
9. Ge Z, Goh JC, Lee EH. Selection of cell source for ligament tissue engineering. *Cell Transplant*. 2005;14(8):573-583.
10. Hoksrud A, Ohberg L, Alfredson H, Bahr R. Color Doppler ultrasound findings in patellar tendinopathy (jumper's knee). *Am J Sports Med*. 2008;36(9):1813-1820.
11. Hoksrud A, Ohberg L, Alfredson H, Bahr R. Ultrasound-guided sclerosis of neovessels in painful chronic patellar tendinopathy: a randomized controlled trial. *Am J Sports Med*. 2006;34(11):1738-1746.
12. Huber P. *The Behaviour of Maximum Likelihood Estimates Under Nonstandard Conditions*. Berkeley, CA: University of California Press; 1967.
13. James SL, Ali K, Pocock C, et al. Ultrasound guided dry needling and autologous blood injection for patellar tendinosis. *Br J Sports Med*. 2007;41(8):518-521.
14. Johnson DP, Wakeley CJ, Watt I. Magnetic resonance imaging of patellar tendonitis. *J Bone Joint Surg Br*. 1996;78(3):452-457.
15. Kaeding CC, Pedroza AD, Powers BC. Surgical treatment of chronic patellar tendinosis: a systematic review. *Clin Orthop Relat Res*. 2007;455:102-106.
16. Kapetanos G. The effect of the local corticosteroids on the healing and biomechanical properties of the partially injured tendon. *Clin Orthop Relat Res*. 1982;163:170-179.
17. Khan KM, Bonar F, Desmond PM, et al. Patellar tendinosis (jumper's knee): findings at histopathologic examination, US, and MR imaging. Victorian Institute of Sport Tendon Study Group. *Radiology*. 1996;200(3):821-827.
18. Khan KM, Cook JL, Bonar F, Harcourt P, Astrom M. Histopathology of common tendinopathies: update and implications for clinical management. *Sports Med*. 1999;27(6):393-408.
19. Khan KM, Cook JL, Kannus P, Maffulli N, Bonar SF. Time to abandon the ''tendinitis'' myth. *BMJ*. 2002;324(7338):626-627.
20. Kraushaar BS, Nirschl RP. Tendinosis of the elbow (tennis elbow): clinical features and findings of histological, immunohistochemical, and electron microscopy studies. *J Bone Joint Surg Am*. 1999;81(2):259-278.
21. Kryger GS, Chong AK, Costa M, Pham H, Bates SJ, Chang J. A comparison of tenocytes and mesenchymal stem cells for use in flexor tendon tissue engineering. *J Hand Surg Am*. 2007;32(5):597-605.
22. Kujala UM, Friberg O, Aalto T, Kvist M, Osterman K. Lower limb asymmetry and patellofemoral joint incongruence in the etiology of knee exertion injuries in athletes. *Int J Sports Med*. 1987;8(3):214-220.
23. Lian O, Scott A, Engebretsen L, Bahr R, Duronio V, Khan K. Excessive apoptosis in patellar tendinopathy in athletes. *Am J Sports Med*. 2007;35(4):605-611.
24. Liu W, Chen B, Deng D, Xu F, Cui L, Cao Y. Repair of tendon defect with dermal fibroblast engineered tendon in a porcine model. *Tissue Eng*. 2006;12(4):775-788.
25. Maffulli N, Wong J, Almekinders LC. Types and epidemiology of tendinopathy. *Clin Sports Med*. 2003;22(4):675-692.
26. Mishra A, Pavelko T. Treatment of chronic elbow tendinosis with buffered platelet-rich plasma. *Am J Sports Med*. 2006;34(11):1774-1778.
27. Peers KH, Lysens RJ. Patellar tendinopathy in athletes: current diagnostic and therapeutic recommendations. *Sports Med*. 2005;35(1):71-87.
28. Purdam CR, Jonsson P, Alfredson H, Lorentzon R, Cook JL, Khan KM. A pilot study of the eccentric decline squat in the management of painful chronic patellar tendinopathy. *Br J Sports Med*. 2004;38(4):395-397.
29. Sharma P, Maffulli N. Tendon injury and tendinopathy: healing and repair. *J Bone Joint Surg Am*. 2005;87(1):187-202.
30. Smith RK. Mesenchymal stem cell therapy for equine tendinopathy. *Disabil Rehabil*. 2008;30(20-22):1752-1758.
31. Terslev L, Qvistgaard E, Torp-Pedersen S, Laetgaard J, Danneskiold-Samsoe B, Bliddal H. Ultrasound and power Doppler findings in jumper's knee: preliminary observations. *Eur J Ultrasound*. 2001;13(3):183-189.
32. Visentini PJ, Khan KM, Cook JL, Kiss ZS, Harcourt PR, Wark JD. The VISA score: an index of severity of symptoms in patients with jumper's knee (patellar tendinosis). Victorian Institute of Sport Tendon Study Group. *J Sci Med Sport*. 1998;1(1):22-28.
33. Visnes H, Bahr R. The evolution of eccentric training as treatment for patellar tendinopathy (jumper's knee): a critical review of exercise programmes. *Br J Sports Med*. 2007;41(4):217-223.
34. Warden SJ, Brukner P. Patellar tendinopathy. *Clin Sports Med*. 2003;22(4):743-759.
35. Weinberg EP, Adams MJ, Hollenberg GM. Color Doppler sonography of patellar tendinosis. *AJR Am J Roentgenol*. 1998;171(3):743-744.
36. Witvrouw E, Bellemans J, Lysens R, Danneels L, Cambier D. Intrinsic risk factors for the development of patellar tendinitis in an athletic population: a two-year prospective study. *Am J Sports Med*. 2001;29(2):190-195.
37. Zhang AY, Chang J. Tissue engineering of flexor tendons. *Clin Plast Surg*. 2003;30(4):565-572.

For reprints and permission queries, please visit SAGE's Web site at http://www.sagepub.com/journalsPermissions.nav

View publication stats