Chemical Peels, Dermabrasion, and Laser Therapy

Sara Friedman, MD, and Jonathan Lippitz, MD

History

In a variety of ancient cultures, the art of beauty arose independently of the practice of cosmetics. Beauty was believed to have both physical and practical purposes; many beautification techniques taught cleanliness and a healthier way of life. In 3000 BCE, the Egyptians were particularly concerned with physical appearance and held bathing ceremonies where they received manicures and adorned their faces with both makeup and tattoos. Egyptian papyrus records recommend a variety of methods to augment beauty with ointments derived from the fat or blood of reptiles and other animals.[1] By 1500 BCE, the Egyptians began dermabrasion, whereby the healers used a form of sandpaper to even out scars.[1] According to the Old Testament, when the Jews left Egypt, they received laws from God related to food, hygiene, and bathing habits. A section of the Talmud provides further evidence of divine hygiene: a decree that a husband is obliged to provide his wife 10 dinars for her cosmetic needs.[2]

Different cultures established different techniques for beautification. In 100 BCE, the Roman poet Ovid devised a recipe for a facial mask in *The Art of Love*. His facial mask included barley, bean flour, eggs, hartshorn, narcissus bulbs, balsam, Tuscany seed, and honey.[2] The Arabic physicians designed their own facial mask in the 9th century composed of crushed rice grains, seashells, marble, crystal, limes, eggs, beans, and ground lentils, which was rubbed onto the face to produce a superficial dermabrasion.[2]

In the early 20th century, the medical community began to re-embrace beautification techniques and, in 1905, Kromayer became the first to utilize the mechanical dermabrasion technique using wheels and rasps.[3] Sixty years later, the technique of skin peeling arose in the medical community, and, since the 1990s, CO_2 has been one of the main agents used to resurface the skin.[3] Our modern beautification techniques are reminiscent of these ancient techniques in that they rely on resurfacing

Dis Mon 2009;55:223-235
0011-5029/2009 $36.00 + 0
doi:10.1016/j.disamonth.2008.12.004

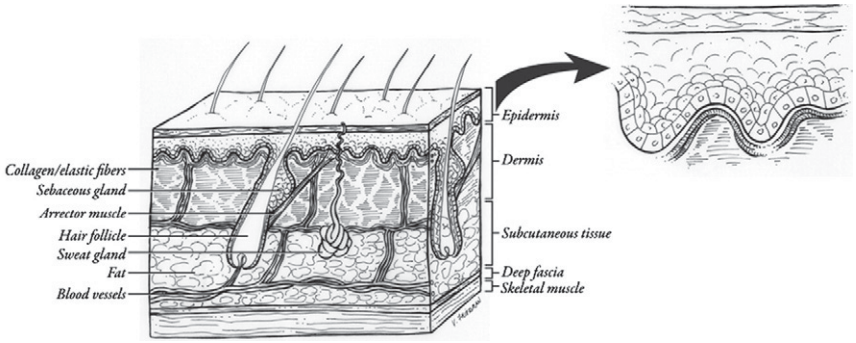

FIG 1. Cross section of all skin layers. (Figure provided courtesy of Vicki Friedman.)

techniques and peels to decrease scars, wrinkles, and other forms of photo- and chemical skin damage.

Mechanisms and Degrees of Photodamage

Several natural and environmental causes of skin damage have prompted the innovation of beautification techniques. Aging, photodamage, and chemicals result in wrinkles and scars; photodamage alters the structure and function of the skin via ultraviolet radiation. The overall thinning of the dermis is a result of both intrinsic factors—such as aging, which alters the skin's collagen—and extrinsic factors such as cigarette smoke and ultraviolet rays. These extrinsic factors cause an increase in collagenase and gelatinase that hastens collagen degradation. Further, they cause an acute decrease in capillary and arteriolar blood flow in the skin, decreasing skin integrity, causing thinning and wrinkling.[4]

Skin is composed of three primary layers as shown in Fig 1: the epidermis, which serves as a barrier to infection; the dermis, which is a location for the appendages of the skin; and the hypodermis, which is the layer of subcutaneous adipose tissue.

The epidermis contains no blood vessels and is made up of keratinocytes with melanocytes and Landerhan's cells. The epidermis is divided into the corneum, granulosum, spinosum, and basale. Cells are formed through mitosis at the basale layer, which regenerates and forms new skin every 12-14 days.

The dermis consists of connective tissue and is connected to the epidermis via the basement membrane. It is divided into a papillary region (superficial) and a reticular region (deep). The papillary region has papillae that strengthen the connection between the epidermis and the

dermis. The reticular region is much thicker and is composed of dense irregular connective tissue. The reticular region houses the roots of the hair, sebaceous gland, sweat glands, nerve receptors, nails, and blood vessels.

The hypodermis lies below the dermis and attaches the skin to the underlying bone and muscles. It consists of loose connective tissue and elastin and is made of fibroblasts, macrophages, and adipocytes.[5]

Modern medical facial resurfacing techniques include both skin peeling and dermabrasion. Skin peeling agents include light to deep chemical peels and are often paired with laser treatment, dermabrasion, or dermasanding, all of which we discuss below. The treatment utilized depends on the degree of damage, often quantified by the Glogau system.

The Glogau system quantifies the degree of damage from light and natural aging and thereby helps stratify patients into risk and treatment strategy. This system classifies severity of photodamage based on the degree of epidermal and dermal degeneration, ranging I through IV. Category I is characterized by a minimal degree of photodamage. The patient shows mild, early photoaging with minimal wrinkles and is often treated with dermabrasion or light chemical peeling, both of which we discuss below. Category II patients have deeper degrees of photodamage and show wrinkles that appear when making facial gestures. The patient shows early to moderate photoaging and requires medium-depth chemical peeling to achieve cosmetic improvement. Category III patients have wrinkles that exist at rest and require medium-depth chemical peel for cosmetic results. Category IV patients have only wrinkles with skin discoloration and require a deep peel or resurfacing procedure plus a cosmetic surgical intervention is recommended.[6]

The degree of photodamage correlates with depth of wound through the skin layers. Superficial wounding extends into the stratum granulosum or papillary dermis; medium-depth extends into the upper reticular dermis, and deep wounding extends into the midreticular dermis.

Skin Peels for Photodamage and Aging

A *chemical skin peel* applies a variety or combination of acids to denature the protein framework of the skin, wounding the papillary/upper reticular dermis in a medium peel and the mid-reticular dermis in a deep peel. All peeling acids provide a means to exfoliate the outer layer of the skin, the most common acids being alpha-hydroxy acid and tricholoroacetic acid (TCA). Alpha-hydroxy acid penetrates into the outermost layer of the skin and reduces cell adhesion to promote exfoliation. TCA

is used in concentrations of 30-50% and is often combined with other wounding agents to increase penetration. For deeper peels, a phenol is often utilized—in the Baker-Gordon solution a phenol is combined with croton oil and Septisol.[7]

Many of the products currently on the market are combination products designed to increase the concentration and penetration of the TCA while decreasing the scarring associated with concentrations greater than 50%.[8] One common example is Jessner's solution, a combination of 70% glycolic acid and solid carbon dioxide with 35% TCA.[6] Moreover, it can be used prior to the 35% TCA to break the epidermal cells and allow for greater penetration of the TCA.[6] Application of 70% glycolic acid prior has a similar efficacy as Jessner's solution.[9]

The choice of acids and peeling treatment should consider the skin type; some types have a greater ability to withstand chemical damage, whereas others will exaggerate the damage based on poor barrier function or exaggerated inflammatory reactions. Fitzpatrick skin typing is a manner to characterize the skin type to decide candidates for skin peels. Skin typing is graded 1-6, where grades 1-3 are white skin and 4-6 progress to dark black skin. The best candidates for skin peels are 1-3 because they are less prone to scar and have pigment changes.[6]

For all types of peels, postoperative edema, erythema, and desquamation are to be expected. The healing stages are inflammation, coagulation, re-epithelialization (day 3-14), and fibroplasia. For all procedures, the general healing time is 7-10 days and can be used for mild to moderate photoaging including pigmentary changes.[8]

Light- and Medium-Depth Chemical Peels

Light- and medium-depth chemical peels are used for patients with Glogau categories I, II, or III. The technique includes the three following main steps: cleansing the skin, applying TCA, and augmenting the healing process.

Cleansing the Skin. The skin is first cleansed with Septisol, a surfactant that decreases skin tension to allow for greater penetration and to remove oils. The second cleansing agent is an acetone, applied to debride oil and scale the surface of the skin. Finally, the physician applies Jessner's solution to further increase the penetration of TCA.

Applying TCA. The peel itself is a 35% solution of TCA. The depth of the peel is based on the amount and percentage of the TCA solution. A white frost from the TCA application appears in the treated area within 30 seconds to 2 minutes. All TCA chemical peels are characterized by the

color of the skin (levels I-III) during the acid application, which corresponds to dermal penetration. During a light chemical peel, an erythema with a blotchy frosting appears (level I). A medium-depth peel develops a white-coated frosting with surrounding erythema (level II). A deep peel, discussed further below, penetrates the papillary dermis and is characterized by solid white enamel frosting with little to no erythema (level III).

Augmenting the Healing Process. After applying TCA, cool saline compresses are applied to cool the skin and thereby decrease the inflammatory response. After treatment, the patient applies a mild emollient cream and 0.25% acetic acid soaks to further expedite healing.[6] The patient should maintain regular follow-ups with the physician to assess the healing and identify signs of infection.

Deep Chemical Peels

Deep chemical peels entail either the use of TCA 50% or the Baker-Gordon phenol peel. Historically, physicians utilized the TCA 50% solution but now favor the Baker-Gordon phenol peel or combination treatments because application of over 45% TCA is associated with scarring and infection.

The Baker-Gordon peel was first described in 1961 and since then has been widely successful. The peel includes the following components: phenol USP 88%: 5 mL 47%; distilled water: 4 mL 49%; croton oil: 3 guttas 1.2%; Septisol: 8 guttas, 2.6%. This peel requires sedation, an IV line for hydration, and an electrocardiogram for monitoring—its goal is to increase phenol absorption through the skin while decreasing the phenol concentration in the serum.[6] The phenol is diluted to 50%, triggering keratolysis and keratocoagulation and increasing penetration. The treatment spans 60-90 minutes of constant IV hydration to dilute the serum phenol concentration.

This peel has recently suffered a decline in usage, partly due to associated risks. First, the phenol component of the peel can be absorbed systemically, resulting in cardiac abnormalities in up to 23% of patients.[10,11] Phenol is directly toxic to the myocardium and can lead to ectopic beats such as premature atrial conduction (PACs), premature ventricular conduction (PVCs), or potentially life-threatening ventricular tachycardia. In a study by Landau in 2007, she looked at 181 patients treated with a full-face deep chemical peel. In 6.6% of the patients, cardiac arrhythmias including bigeminy and polytopic extrasystole were recorded during the procedure. Cardiac arrhythmias were more common in patients with diabetes, hypertension, and depression.[10,11] Slow application of the peel with a pause of 10 to 15 minutes between each cosmetic

unit and proper ventilation has decreased the incidence of cardiac abnormalities. Any patient with a history of cardioarrhythmia, a history of hepatic or renal compromise, or on medications for arrhythmia should not undergo the Baker-Gordon phenol peel.[7] The setbacks of this technique prompted the advent of newer combination peels.

Combination Peels

Other combination peels include alternative acids or a CO_2 laser to increase TCA penetration through the epidermis. Brody used CO_2 with acetone to freeze the epidermis prior to applying 35% TCA, which further broke the epidermal barrier. The CO_2 laser has recently gained popularity due to its minimal thermal injury and precise depth control.[12]

A study of 20 female patients in 1999 by Chew and coworkers compared the efficacy of the CO_2 laser versus traditional Baker's phenol chemical peel. The subjects were randomly treated with Baker's phenol on one side of the upper lip and the CO_2 laser on the other side. The Baker-Gordon chemical peel proved more effective in reducing wrinkles than the CO_2 laser technique—at 6 months after treatment, the laser-treated regions' wrinkle score decreased from 4.30 to 1.11 versus a decrease of 4.2 to 0.47 for the Baker-Gordon regions.[13] Conversely, the erythema varied across the two patient groups—35% of the patients developed erythema on their Baker-Gordon region versus 10% of patients on their laser-treated region. Persistent erythema of the upper lip was treated with BID gel and was not present at 6 months in any participants, on either region.[4]

Dermabrasion

Dermabrasion mechanically removes the epidermis and upper dermis to reduce or remove moderate wrinkles, acne scars, and uneven skin surfaces. The central equipment is a high-speed rotary device with an abrasive tip that physically resurfaces the skin.[14]

Microdermabrasion, a more superficial variation of dermabrasion, uses a device that sprays a fine beam of aluminum oxide microcrystals to peel the skin surface while simultaneously removing the tissue debris.[15] Microdermabrasion produces a superficial ablation of the epidermis, making it ineffective for wrinkles and scars that originate in the dermis. The advantages are that it can be repeated at short intervals, is painless, and does not require anesthesia, but it has low effect and does not treat deep wrinkles. Microdermabrasion will work for patients who are willing to have multiple treatments and early photodamage. If patients are not

willing to commit to a series of treatments, they will not see significant results.

A variety of microdermabraders are currently available on the market. All microdermabraders include a pump that generates a stream of aluminum oxide or salt crystals with a hand piece and vacuum to remove the crystals and exfoliate the skin. It is theorized that the repetitive intraepidermal injury will invoke fibroblast proliferation and collagen production, therefore, improving the appearance of wrinkles.[16] Usually two treatments separated by cleansing are performed per session with the desired endpoint of erythema. There are few complications associated with microdermabrasion but it is often ineffective especially for full-thickness wrinkles.

In 2001 Tan and coworkers assessed the effectiveness of microdermabrasion on 10 subjects and demonstrated a subjective mild improvement in the majority of subjects and histologically dramatic vascular changes in the reticular dermis.[17] Another study in 2001 assessed microdermabrasion by both physical exam and skin biopsy in 10 volunteers after six treatments. They found histologic improvement including thickening of the epidermis and dermis with newly deposited collagen in the areas that were treated with microdermabrasion.[18] Currently, a physician, nurse, or aesthetician can perform microdermabrasion and, since there are few side effects, it has become a common procedure for partial thickness wrinkles.

Dermabrasion is performed under local anesthesia or general anesthesia if full-face dermabrasion is performed. A motorized hand piece rotates a wire brush or diamond fraise. Historically, the hand piece was made of aluminum oxide or sodium bicarbonate crystals, but diamond tips have replaced these hand pieces to increase accuracy and decrease irritation. The hand piece removes the upper layers of the skin, resulting in a raw partial-thickness wound that heals by epithelialization within 7-10 days, reducing scarring and wrinkling of the skin. There often is small pinpoint bleeding of the raw wound that subsides with appropriate wound care. The recovery from dermabrasion is 2 to 3 weeks—the skin often weeps in the first 10-12 days but stops once the surface layers are restored.[15] Patients with darker skin complexions may experience permanent skin discoloration or blotchiness.

Laser Treatment and CO_2

Recently developed techniques utilize other technologies such as lasers and carbon dioxide to exfoliate the skin and may be used individually or in conjunction with dermabrasion for superior results. Lasers are used as a precise energy that can ablate selected tissue while the remaining tissue

stays unharmed. There are multiple types of lasers, which differ in their wavelength, intensity, and duration of action. One of the key differences is the wavelength. The wavelength of light dictates the heat generation and therefore the tissue destruction.[19] Carbon dioxide lasers are ideal for cosmetic resurfacing of the skin because they are particularly absorbed by water, which is abundant in cutaneous tissue. This, combined with their fine hemostasis and precise control, has increased their use in the treatment of fine rhytides. The Erb:YAG laser is a more superficial laser and is an alternative to the carbon dioxide laser.

Laser emits high-energy microsecond pulses of energy, which may be used to vaporize the epidermal layer and superficial layers of the upper papillary dermis. The JetPeel passes a mixture of sterile saline and oxygen through a narrow channel to target and exfoliate a specific area of skin.[3] A 2005 study group of 50 healthy adult patients compared the JetPeel to dermabrasion and skin peeling. The patients received oral acyclovir prior to the procedure and throughout the 7- to 14-day healing process, and the results were compared by skin biopsy. Side effects included the following: one case of herpes simplex virus (HSV), treated with acyclovir and an antibiotic to prevent scarring; three cases of hyperpigmentation, treated with hydroquinone and isotretinoin; and one case of subcutaneous emphysema of the lower eyelid, which subsided in 2-3 hours without sequelae.[3] This study concluded that the use of JetPeel has similar efficacy and side effects to dermabrasion.

The use of specialized pulsed CO_2 lasers has increased significantly in recent years. These lasers restrict the laser-tissue interaction time to less than 1 millisecond, minimizing thermal diffusion. In a 1999 study, 20 female patients with moderate to severe upper lip wrinkles received manual tumescent dermabrasion on one side of their lip and CO_2 laser treatment on the other side. Post treatment wrinkle scores showed significant improvement in both CO_2 laser and dermabrasion but no statistically significant improvement between the two groups. Additionally, the side effects were very similar between the groups: 1 month after treatment, 85% of participants exhibited mild erythema on the upper lip; 10% experienced high-intensity erythema on the laser-treated side, compared with 5% on the dermabraded side.[13]

In 2000, Kitzmiller and colleagues recruited 20 females to assess the CO_2 laser and dermabrasion. They treated half of the perioral area with dermabrasion and half with the UltraPulse CO_2 laser. The photographs were compared by board-certified plastic surgeons that were blinded to the treatment procedure. The laser treatment had higher erythema score at 1 month and a small but significantly greater improvement in

wrinkle score at 6 months. The participants found equivalence in the two treatments.[20]

Similarly, Holmkvist and Rogers in 2000 found no statistical difference between dermabrasion and laser in 15 female volunteers. The difference in wrinkle score at 2 months was not statistically significant.[21] In all of the studies, erythema was higher with CO_2 laser but was not always statistically significant.[4]

The Er:YAG laser has been compared with other laser treatments in various studies. Both CO_2 and Er:YAG lasers produce a de-epithelialized thermal wound that penetrates to the lower papillary/upper reticular dermis and heals in 7-10 days. One of the limitations of the CO_2 laser is the adverse side effect such as prolonged erythema. The Er:YAG laser is used because it decreases the thermal damage because its wavelength is more absorbed by water and re-epithelializes earlier.[22] Khatri and coworkers compared Er:YAG and CO_2 laser treatments, and concluded that the post treatment erythema was higher on the CO_2 treatments than Er:YAG treatments at 2, 8, and 24 weeks. In 2001, Khatri assessed whether lengthening pulse time of the Er:YAG would improve the efficacy of the treatment without increasing the length of erythema and found that increased pulse duration did not increase the maximum reported residual thermal damage and would not lengthen recovery time, while still improving hemostasis.[23]

In 2000, Newman and coworkers studied 42 treatment sites on 21 patients and compared the Er:YAG and CO_2 efficacy by evaluating after treatment of the upper lip with CO_2 on one side and Er:YAG on the other side. They found that the Er:YAG reduced the duration of crusting to 3.4 days, compared with 7.7 days with CO_2. Conversely, 63% of patients had an improvement with CO_2 and 54% had an improvement with Er:YAG after 2 months of treatment.[24]

In 2001, Ross and coworkers found no statistically significant differences between Er:YAG and CO_2 laser with regard to wrinkle reduction. The erythema was more severe in the Er:YAG patients at 2 weeks, but this difference resolved by 6 weeks. They also found that a single pass of CO_2 can mimic a moderately aggressive Er:YAG laser treatment.[25]

Combined laser techniques have been shown to decrease healing time and improve efficacy of treatment. Laserbrasion is the combination of CO_2 laser and dermabrasion in a single procedure. In a study to assess the efficacy and side effects of laserbrasion, a nonrandomized study of 90 patients with Glogau IV wrinkles underwent either laserbrasion or CO_2 laser. Patient photographs were taken preoperatively and at 3 months after treatment, revealing a 95% clinical improvement of perioral wrinkles with

laserbrasion compared with a 75% improvement in patients with CO_2 laser alone. Moreover, laserbrasion healing time was 9 days compared to 12 days after use of the CO_2 laser alone. There was no significant hypopigmentation, infection, or scarring with either treatment. A subset of 26 patients was followed for a year, and all maintained good results with no additional hypopigmentation.[26] This study demonstrates that the combined effect of laserbrasion decreases the healing time and increases the aesthetic improvement.

Fraxel Therapy

The CO_2 and Er:YAG lasers both act by complete epidermal ablation, which can result in a prolonged recovery time. Fractional photothermolysis (Fraxel) is a nonablative laser that was introduced by Huzaira and colleagues in 2003 to overcome the drawbacks of CO_2 and Er:YAG lasers. Fractional photothermolysis uses a midinfrared laser with precise columns of thermal injury, leading to epidermal necrosis, and collagen denaturation, leading to improved rhytide appearance and rapid recovery time.[27] Compared with other approaches, Fraxel therapy has little recovery time, no open wound, few nonresponders, and few complications. Rather than creating a global tissue effect, it creates injury in a fraction of the skin by coagulating small columns of tissue through the epidermis and dermis.[28]

Fraxel therapy is administered as four to six treatments. First, the area is exfoliated with an abrasive scrub and cleansed with isopropyl alcohol. Next the skin is stained with the blue dye (OptiGuide Blue) that comes with the disposable hand-piece tips. The optical mouse in the laser hand piece recognizes subtle differences in the density of the blue dye to allow for an even placement of MTZs. Prior to the procedure, the operator applies an anesthetic gel (7% lidocaine/7% tetracaine) for pain control.[28] Forced air cooling is used concurrently with the laser treatment to increase the patients comfort. The energy density used for the treatment varies based on the treatment. For example, for mild to moderate rhytides (glogau II-III) the operator should use 8-10 mJ, whereas for severe rhytides (glogau IV) the operator should use 15 mJ. After the procedure, the blue dye is removed with a foam-based skin cleanser.[29]

Manstein and colleagues assessed the use of Fraxel therapy in 2004 and found a 90% visible improvement in wrinkles after four weekly treatments. After each treatment the patients were able to return to work, demonstrating the low side-effect profile.[30] In 2005, Dover and Alam studied the treatment of Fraxel lasers in 70 patients. After treatment the

skin showed a decrease in rhytides with minimal downtime for the patient.[30] In 2007 Wanner et al studied Fraxel lasers to assess wrinkle improvement at 3, 6, and 9 months. She found a 51 and 75% improvement of facial and nonfacial photodamage at 9 months with no prolonged pigmentary changes or scarring.[27]

The side-effect profile of fraxel therapy is much less severe than with CO_2 lasers or Er:YAG. In addition to the decrease in recovery time, fraxel therapy treatment does not carry the risks or pigmentary alteration, infection, or scarring. There is a 10-12% risk of postinflammatory pigmentary alteration. This is most common in patients of darker skin types. Therefore, following treatment, patients should adhere to strict sun protection.[29]

Complications in Resurfacing Techniques

As illustrated above, resurfacing techniques such as dermabrasion and chemical peels produce a controlled injury that penetrates into the papillary layer of the upper dermis. Since they produce this de-epithelialized wound, infections can occur that may interfere with normal healing and may result in permanent scarring.[14]

The majority of these complications occur during the healing stages. After skin peels, patients should follow-up with their physician to diagnose infection, dermatitis, and other systemic concerns. Presence of granulation tissue beyond 10 days indicates delayed healing and may result in scarring. This may be caused by infection, contact dermatitis, or other systemic factors.

Most complications following skin peels alone are due to incorrect or accidental solution misplacement or expired solutions.[6] Saline and bicarbonate should be available to dilute the TCA or neutralize the glycolic acid if inappropriately placed in the wrong area.

Infectious complications include viral, bacterial, or fungal pathogens. Often the patient will present the 3rd to 10th postoperative day with vesicopustules that quickly evolve to erosions and are associated with either pain or itching. Bacterial infection rates range from 4.3 to 12% and fungal infections (*Candida albicans*) range from 1.8 to 2.2%. These rates include patients who have received prophylactic antibiotics.[14] Reactivation of HSV-1 is one of the more common complications of laser resurfacing. Infection with HSV-1 may impede healing and increase the risk of secondary bacterial infection and lead to scarring. One study of 907 patients undergoing aesthetic CO_2 laser surgery reported an incidence for acute HSV infection of 3.0% that was reduced to less than 1% following acyclovir prophylaxis.[31] Because of the concern for HSV

reactivation, which exists in patients without a history of HSV, prophylactic oral antiviral therapy is indicated for all patients who undergo laser facial resurfacing.[14]

The best deterrent for postoperative infection is the continuous use of soaks to debride crusting and necrotic material. Streptococcus and staphylococcus can grow under the biosynthetic membranes, leading to infection and therefore scarring. This can be avoided by use of ¼% acetic acid soaks and frequent postoperative visits to recognize any chance of infection. Delayed wound healing may respond to physician debridement if an infection is present or to steroids if due to a dermatitis.[8]

REFERENCES

1. Stuzin JM. Phenol peeling and the history of phenol peeling. Clin Plast Surg 1998;25:1.
2. Blanco-Davila F. Beauty and the body: the origins of cosmetics. J Am Soc Plast Reconstruct Surg 2000;105(3):1196-204.
3. Golan J, Hai N. JetPeel: a new technology for facial rejuvenation. Ann Plast Surg 2005;54(4):369-74.
4. Brooke S, Griffiths J. Interventions for photodamaged skin. Cochrane Database Syst Rev 2005;1:CD001782.
5. Fitzpatrick TB, Eisen AZ, Wolff K, et al (eds): Dermatology in General Medicine, 3rd ed. 2 vol. New York, NY: McGraw-Hill, 1987.
6. Monheit G. Chemical peels. Skin Ther Lett 2004;9(2):6-11.
7. Sapijaszko J. Chemical peels—a re-emerging act. Cosmetic Surgery Procedures Guide 2005. Available from http://www.cosmeticprocedureguide.ca/chemical_peels.html.
8. Brody HJ. Chemical Peeling and Resurfacing. 2nd ed. St. Louis, MO: Mosby-Year Book, 1997.
9. Coleman WP 3rd, Futrell JM. The glycolic acid trichloroacetic acid peel. J Dermatol Surg Oncol 1994;20(1):76-80.
10. Landau M. Chemical peels. Clin Dermatol 2008;26:200-8.
11. Landau M. Exogenous factors in skin aging. Curr Probl Dermatol 2007;35:1-13.
12. Brody HJ. Trichloracetic acid application in chemical peeling, operative techniques. Plast Reconstr Surg 1996;2(2):127-8
13. Chew J, Gin I, Rau K, et al. Treatment of upper lip wrinkles: a comparison of 950 usec dwell time carbon dioxide laser with unoccluded baker's phenol chemical peel. Dermatol Surg 1999;25(4):262-6.
14. Gilbert S. Improving the outcome of facial resurfacing—prevention of herpes simplex virus type 1 reactivation. J Antimicrob Chemother 2001;47:29-34.
15. Cowan B. Dermabrasion. Cosmetic Surgery Procedures Guide 2005. Available from http://www.cosmeticprocedureguide.ca/dermabrasion.html.
16. Shpall R, Beddingfield FC, Watson D, et al. Microdermabrasion: a review. Facial Plast Surg 2004;20(1):47-50.
17. Tan MH, Spencer JM, Pires LM, et al. The evaluation of aluminum oxide crystal microdermabrasion for photodamage. Dermatol Surg 2001;27(11):943-9.

18. Freedman BM, Rueda-Pedraza E, Waddell SP. The epidermal and dermal changes associated with microdermabrasion. Dermatol Surg 2001;27(12):1031-3.
19. American Society of Plastic and Reconstructive Surgeons. Position paper, ASPRS socioeconomic and policy development. Cutaneous laser surgery. Plastic Surgery News 2008;June:27-35.
20. Kitzmiller J, Visscher M, Page D, et al. A controlled evaluation of dermabrasion versus CO_2 laser resurfacing for the treatment of perioral wrinkles. Plast Reconstruct Surg 2000;106(6):1366-72.
21. Holmkvist K, Rogers G. A comparison of dermabrasion and superpulsed carbon dioxide laser. Arch Dermatol 2000;136:725-31.
22. Khatri K, Ross V, Grevelink J, et al. Comparison of erbium:YAG and carbon dioxide lasers in resurfacing of facial rhytides. Arch Dermatol 1999;135:391-397.
23. Khatri K. The effects of variable pulse width of Er:YAG laser on facial skin. Dermatol Surg 2001;27(4):332-4.
24. Newman J, Lord J, Ash K, et al. Variable pulse erbium:YAG laser skin resurfacing of perioral rhytides and side-by-side comparison with carbon dioxide laser. Lasers Surg Med 1999;25(2):208-14.
25. Ross V, Miller C, Meehan K, et al. One-pass CO_2 versus multiple-pass er:yag laser resurfacing in the treatment of rhytides: a comparison side-by-side study of pulsed CO2 and Er:YAG lasers. Dermatol Surg 2001;27(8):709-15.
26. Fezza J. Laserbrasion: the combination of carbon dioxide laser and dermasanding. Plast Reconstruct Surg 2006;118(5):1217-21.
27. Wanner M, Tanzi E, Alster T. Fractional photothermolysis: treatment of facial and nonfacial cutaneous photodamage with a 1,550-nm Erbium-doped fiber laser. Dermatol Surg 2007;33:23-8.
28. Bass L. Rejuvenation of the aging face using fraxel laser treatment. Aesthet Surg J 2005;25(3):307-9.
29. Dover J, Alam M. Topical treatments for melasma and postinflammatory hyperpigmentation fractional laser treatment for pigmentation and texture improvement. Adv Dermatolog Surg 2006;11:1-6.
30. Manstein D, Herron GS, Sink RK, et al. Fractional photothermolysis: a new concept for cutaneous remodeling using microscopic patterns of thermal injury. Lasers Surg Med 2004;34:426-38.
31. Roberts TL, Weinstein C, Alexandidies JK, et al. Aesthetic CO_2 laser surgery: evaluation of 907 patients. Aesthet Surg J 1997;17:293-303.