STUDY

Molecular Analysis of Aggressive Microdermabrasion in Photoaged Skin

Darius J. Karimipour, MD; Laure Rittié, MS, PhD; Craig Hammerberg, MS, PhD; Victoria K. Min, BA; John J. Voorhees, MD; Jeffrey S. Orringer, MD; Dana L. Sachs, MD; Ted Hamilton, MS; Gary J. Fisher, PhD

Objective: To investigate dermal remodeling effects of crystal-free microdermabrasion on photodamaged skin.

Design: Biochemical analyses of human skin biopsy specimens following microdermabrasion treatment in vivo.

Setting: Academic referral center.

Participants: Volunteer sample of 40 adults, aged 50 to 83 years, with clinically photodamaged forearms.

Intervention: Focal microdermabrasion treatment with diamond-studded handpieces of varying abrasiveness on photodamaged forearms and serial biopsies at baseline and various times after treatment.

Main Outcome Measures: Quantitative polymerase chain reaction, immunohistochemistry, and enzyme-linked immunosorbent assay were used to quantify changes in inflammatory, proliferative, and remodeling effectors of normal wound healing. Type I and type III procollagen served as the main outcome marker of dermal remodeling.

Results: Coarse-grit microdermabrasion induces a wound healing response characterized by rapid increase in induction of cytokeratin 16 and activation of the AP-1 transcription factor in the epidermis. Early inflammation was demonstrated by induction of inflammatory cytokines, antimicrobial peptides, and neutrophil infiltration in the dermis. AP-1 activation was followed by matrix metalloproteinase–mediated degradation of extracellular matrix. Consistent with this wound-healing response, we observed significant remodeling of the dermal component of the skin, highlighted by induction of type I and type III procollagen and by induction of collagen production enhancers heat shock protein 47 and prolyl 4-hydroxylase. Dermal remodeling was not achieved when microdermabrasion was performed using a medium-grit handpiece.

Conclusions: Microdermabrasion using a coarse diamond-studded handpiece induces a dermal remodeling cascade similar to that seen in incisional wound healing. Optimization of these molecular effects is likely the result of more aggressive treatment with a more abrasive handpiece.

Trial Registration: clinicaltrials.gov Identifier: NCT00111254

Arch Dermatol. 2009;145(10):1114-1122

MICRODERMABRASION IS A popular procedure for skin rejuvenation. It has been suggested that microdermabrasion can improve the appearance of wrinkles,[1] atrophic acne scars,[2] dyspigmentation,[3] and other signs of aging skin. The proposed mechanism by which microdermabrasion exerts these effects is through remodeling the dermis with elaboration of new collagen and other matrix components.[1,3,4]

Author Affiliations:
Department of Dermatology, University of Michigan (Drs Karimipour, Rittié, Hammerberg, Voorhees, Orringer, Sachs, and Fisher and Mr Hamilton), and University of Michigan Medical School (Ms Min), Ann Arbor.

CME available online at www.jamaarchivescme.com

Karimipour et al[5] demonstrated that aluminum oxide microdermabrasion activates a dermal remodeling cascade involving cytokines, transcription factors, and matrix metalloproteinases (MMPs). However, stimulation of new collagen synthesis occurred in only a few subjects and was not statistically significant. A possible explanation for the lack of significant collagen production might relate to the minimal wounding of microdermabrasion.[6] In fact, aggressive ablative resurfacing procedures characteristically result in significant collagen production.[7,8]

Hence, the objective of this study was to investigate whether microdermabrasion could be improved through more aggressive (but still nonablative) perturbation of the epidermis. We hypothesized that increasing the wounding stimulus might enhance dermal remodeling, as observed with other aggressive procedures,[7,8] and thereby elicit consistent induction of collagen production. To test this hypothesis, we used a diamond-studded handpiece with varying roughness as a wounding stimulus.

©2009 American Medical Association. All rights reserved.

Downloaded From: on 07/18/2018

EUNSUNG 1026

The microdermabrasion system used (DiamondTome; Altair Instruments, Camarillo, California) offers a unique way to vary the abrasive stimulus. The system differs from standard microdermabrasion systems that use aluminum oxide crystals as corundum. The system uses a handpiece that has diamond fragments embedded in the contact point of the wand with the skin. The wand's roughness is controlled by the size of the diamond particles at the contact point.

We assessed the ability of medium-grit and coarse-grit handpieces to elicit molecular responses that occur during normal wound healing. Collagen production was quantified.

METHODS

HUMAN SUBJECT DESCRIPTION, TREATMENT, AND TISSUE PROCUREMENT

This study was approved by the University of Michigan Medical School Institutional Review Board for Human Subjects Research. All subjects provided written informed consent. Forty subjects (26 males and 14 females), aged 50 to 83 years, received a single microdermabrasion treatment with the diamond-studded handpiece to photodamaged forearm skin using a medium-grit (100-µm particle size) or coarse-grit (125-µm particle size) wand. In each subject, three 2×2-cm areas of photodamaged forearm skin were treated with microdermabrasion. The microdermabrasion device was set at −25 inches mercury, and the microdermabrasion wand was applied in horizontal, vertical, and oblique directions for a total of 3 passes. For this study, 3 passes represents 1 microdermabrasion treatment. Each pass was characterized as a back-and-forth motion lasting approximately 15 seconds to "paint" the test area in sequential rows; the handpiece was not lifted off the skin during each pass. This procedure is similar to how we perform microdermabrasion on a daily basis in our clinic. The treatment resulted in mild erythema in all subjects that would typically last less than 2 hours.

Punch biopsy specimens (4 mm) were obtained from treated and untreated (control) skin at different intervals ranging from 4 hours to 14 days after treatment. Each subject's baseline (no treatment) biopsy specimen served as his or her control. Immediately after biopsy, skin specimens were embedded in optimal cutting temperature (OCT) embedding medium (Tissue-Tek OCT compound; Miles, Naperville, Illinois), frozen in liquid nitrogen, and stored at −80°C until processing.

RNA EXTRACTION AND REAL-TIME REVERSE TRANSCRIPTION–POLYMERASE CHAIN REACTION

RNA extraction from skin biopsy specimens, reverse transcription, and messenger RNA (mRNA) quantification by real-time reverse transcription–polymerase chain reaction were performed as previously described.[9] Custom primers and probes were used for type I procollagen (*COL1A1*) (GenBank Z74615), type III procollagen (*COL3A1*) (GenBank X15332), and the housekeeping gene *36B4* (GenBank AB007187). All other primer-probe sets were validated gene expression assays (TaqMan; Applied Biosystems, Foster City, California). Results are presented as fold change in treated vs untreated skin samples (normalized to transcript levels of *36B4*) or as fold change vs *36B4* ($2^{-[CTtarget-CT36B4]}$, where *CT* indicates cycle threshold and is the end point of the real-time polymerase chain reaction).

IMMUNOHISTOCHEMISTRY

Frozen tissue embedded in OCT medium was cut into 7-µm-thick sections. Immunohistochemical staining was performed using the following primary antibodies: cytokeratin 16 (Novocastra; Leica Microsystems, Bannockburn, Illinois), cJun (Abtransduction Laboratories, Lexington, Kentucky), JunB (Santa Cruz Biotechnology, Santa Cruz, California), MMP type 1 (MMP1), prolyl 4-hydroxylase, type I procollagen (Chemicon, Temecula, California), neutrophil elastase (DAKO, Carpinteria, California), heat shock protein 47 (HSP47; BioGenex, San Ramone, California), and fibroblast activation protein (Bender Medsystems, Burlingame, California). Tissue-bound primary antibody was visualized with a secondary antibody–peroxidase complex,[10] and the amount of staining was quantified using commercially available software (Image-Pro; Media Cybernetics, Inc, Bethesda, Maryland). To assess the specificity of staining, substitution of isotype γ-globulin for the primary antibody was used. There was no staining visualized with any isotype γ-globulin.

PROTEIN EXTRACTION AND TYPE I PROCOLLAGEN ENZYME-LINKED IMMUNOSORBENT ASSAY

Frozen sections (50 µm thick) were collected from OCT-embedded skin samples onto polyethylene naphthalate foil-coated slides (Leica Microsystems). For each sample, the dermal area was measured using software associated with the laser capture microdissection microscope (Leica AS LMD), and skin sections were isolated from surrounding OCT by microdissection. Samples were collected into ice-cold protein extraction buffer (50mM Tris hydrochloride [pH 7.4], 0.15M sodium chloride, 1% Triton X-100, and protease inhibitors [Complete Mini; Roche Diagnostics, Indianapolis, Indiana]). Extraction products were centrifuged for 5 minutes at 10 000*g* at 4°C, and supernatants were assayed for type I procollagen using an enzyme-linked immunosorbent assay kit (Panvera, Madison, Wisconsin). Type I procollagen protein concentrations were normalized to sample volumes.

STATISTICAL ANALYSIS

Changes in biomarkers over time compared with baseline levels were statistically evaluated using repeated-measures analysis of variance. Dunnett multiple comparisons procedure was used to test the significance of specific comparisons. The type I error rate was set at .05 for a 2-tailed hypothesis. Descriptive statistics included means, ranges, and standard errors. These data were analyzed using commercially available statistical software (SAS; SAS Institute, Inc, Cary, North Carolina).

RESULTS

We demonstrate that aggressive nonablative microdermabrasion is an effective procedure to stimulate collagen production in human skin in vivo. The beneficial molecular responses, with minimal downtime, suggest that aggressive microdermabrasion may be a useful procedure to stimulate remodeling and to improve the appearance of aged human skin.

COARSE-GRIT MICRODERMABRASION INDUCES EARLY EPIDERMAL INJURY RESPONSE

Induction of cytokeratin 16 by interfollicular keratinocytes is a well-characterized response to epidermal injury.[11] A single microdermabrasion treatment with the

©2009 American Medical Association. All rights reserved.

Downloaded From: on 07/18/2018

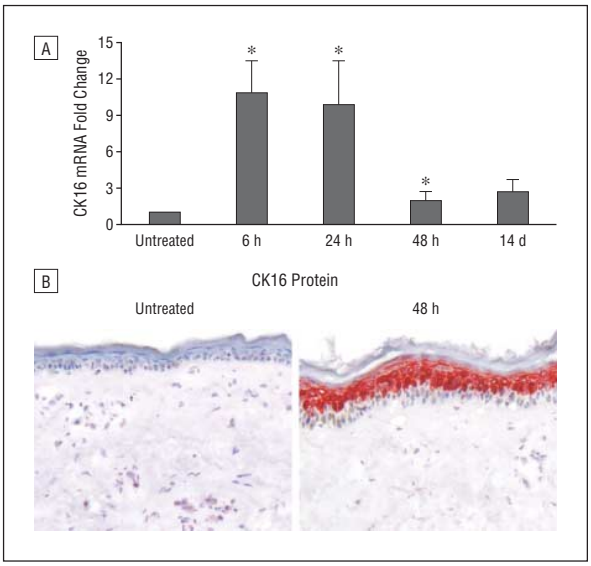

Figure 1. Coarse-grit microdermabrasion induces cytokeratin 16 (CK16) messenger RNA (mRNA) and protein expression in human skin in vivo. Photodamaged forearm skin was treated with coarse-grit microdermabrasion. Samples were obtained at the indicated times from untreated and treated skin sites. A, Cytokeratin 16 mRNA levels were quantified by real-time reverse transcription–polymerase chain reaction. $*P<.05$ vs untreated control. B, Skin samples from untreated sites (left) and from sites 48 hours after treatment (right) were immunostained for cytokeratin 16. Positive staining appears red, and hematoxylin counterstaining appears blue. Images are representative of 20 subjects. Original magnification ×120.

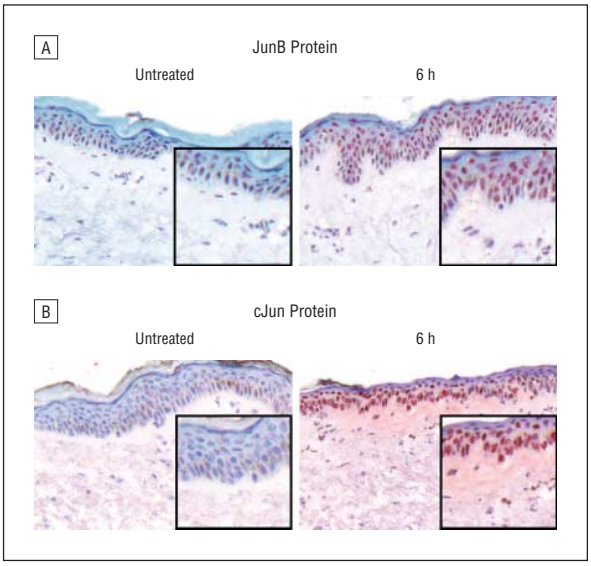

Figure 2. Coarse-grit microdermabrasion induces JunB and cJun protein expression in human skin in vivo. Photodamaged forearm skin was treated with coarse-grit microdermabrasion. Samples were obtained at the indicated times from untreated and treated skin sites. Protein expression was determined for JunB (A) and cJun (B) by immunohistochemistry. Positive staining appears red, and hematoxylin counterstaining appears blue. Images are representative of 20 subjects (JunB) and 4 subjects (cJun). Insets represent original magnification ×120.

coarse-grit handpiece resulted in 11-fold induction of cytokeratin 16 gene expression (GenBank NM004084.2) 6 hours after treatment ($P<.05$). Cytokeratin gene expression was still elevated 24 hours after treatment (10-fold vs untreated skin, $P<.05$) and decreased slowly over

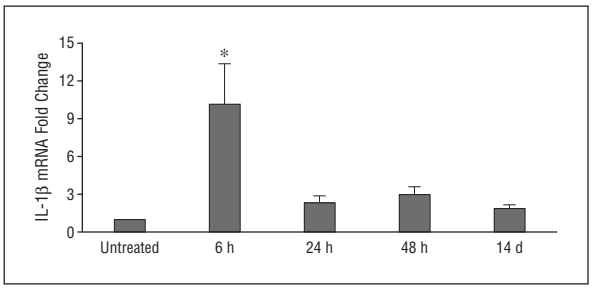

Figure 3. Coarse-grit microdermabrasion induces primary cytokine interleukin (IL) 1β gene expression in human skin in vivo. Photodamaged forearm skin was treated with coarse-grit microdermabrasion. Samples were obtained at the indicated times from untreated and treated skin sites. Interleukin 1β messenger RNA (mRNA) levels were quantified by real-time reverse transcription–polymerase chain reaction (n=20).$*P<.05$ vs untreated control.

the ensuing 48 hours (**Figure 1**A). At the protein level, cytokeratin 16 was not detectable at baseline and was readily detectable in the suprabasal layers of the epidermis 24 and 48 hours after treatment (Figure 1B).

JunB and cJun are components of the AP-1 transcription factor complex.[12] They control several important gene products involved in the regulation of epidermal wound response and epidermal differentiation, including MMPs, cytokeratin 16, and inflammatory mediators.[13,14] JunB and cJun protein expression was dramatically induced within 6 hours after a single coarse-grit microdermabrasion treatment (**Figure 2**A and B). JunB and cJun protein expression was induced in keratinocytes throughout the epidermis and localized in cell nuclei. JunB and cJun protein expression levels returned to baseline levels 24 hours after treatment (data not shown).

COARSE-GRIT MICRODERMABRASION INDUCES EARLY INFLAMMATORY CYTOKINES INTERLEUKIN 1β AND INTERLEUKIN 8

Primary proinflammatory cytokine interleukin (IL) 1β mRNA (GenBank NM00576.2) was induced 10-fold ($P<.05$) 6 hours after a single treatment with the coarse-grit wand (**Figure 3**). Microdermabrasion did not induce gene expression of the primary cytokine tumor necrosis factor (GenBank NM000594.2) (data not shown). Interleukin 1β can stimulate induction of other cytokines that are involved in wound healing. Interleukin 8 is one such cytokine and is a potent neutrophil chemoattractant. A single microdermabrasion treatment using the coarse-grit handpiece resulted in statistically significant increases in IL-8 gene expression (GenBank NM000584.2). Interleukin 8 gene expression was maximally induced 64-fold 6 hours after a single treatment ($P<.05$) (**Figure 4**).

One of the early inflammatory cellular events following epidermal injury is neutrophil infiltration into the wound site.[15] Neutrophil elastase was used as a marker for infiltrating neutrophils. Neutrophil elastase protein expression was not detectable at baseline but was readily detectable 6 and 24 hours after coarse-grit microdermabrasion treatment (**Figure 5**). Neutrophil elastase expression was induced throughout the reticular dermis. Increased neutrophil infiltration into the skin is consistent with observed elevations in IL-8 level.

©2009 American Medical Association. All rights reserved.

Downloaded From: on 07/18/2018

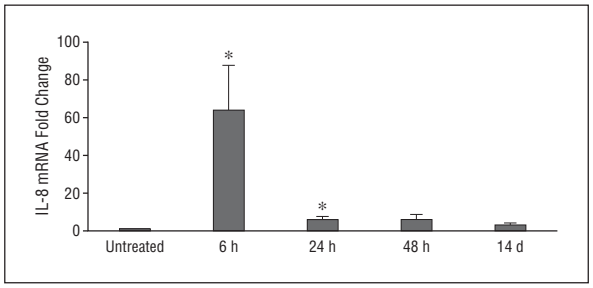

Figure 4. Coarse-grit microdermabrasion induces neutrophil chemoattractant interleukin (IL) 8 gene expression in human skin in vivo. Photodamaged forearm skin was treated with coarse-grit microdermabrasion. Samples were obtained at the indicated times from untreated and treated skin sites, and IL-8 messenger RNA (mRNA) levels were quantified by real-time reverse transcription–polymerase chain reaction (n=20). *$P<.05$ vs untreated control.

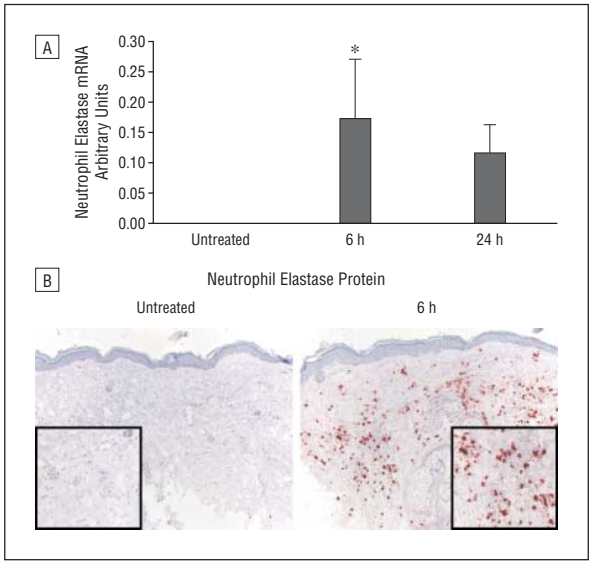

Figure 5. Coarse-grit microdermabrasion induces infiltration of neutrophils in human skin in vivo. Photodamaged forearm skin was treated with coarse-grit microdermabrasion. A, Samples were obtained at the indicated times from untreated and treated skin sites. *$P<.05$. B, Neutrophils were stained by immunohistochemistry using the marker neutrophil elastase. Images are representative of 20 subjects. Insets represent original magnification ×60. mRNA indicates messenger RNA.

COARSE-GRIT MICRODERMABRASION INDUCES ANTIMICROBIAL PEPTIDES

Antimicrobial peptides constitute a large diverse group of small-molecular-weight proteins that function in host defense against infection by directly killing microorganisms and by modulating innate and adaptive immunity.[16] Recent studies[17,18] have demonstrated altered expression of antimicrobial peptides in inflammatory skin diseases and following skin injury. A single treatment with coarse-grit microdermabrasion stimulated gene expression of antimicrobial peptides human defensin α1 (DEFA1) (GenBank NM004084.2), human β-defensin 2 (HBD2) (GenBank NM004942.2), and human β-defensin 3 (HBD3) (GenBank NM018661.3). Defensin α1 mRNA was near the limit of detection in untreated skin and was increased approximately 33-fold 6 hours after treatment ($P<.05$) (**Figure 6**A). Defensin α1 mRNA levels remained elevated 19-fold for at least 24 hours ($P<.05$). *HBD2* and

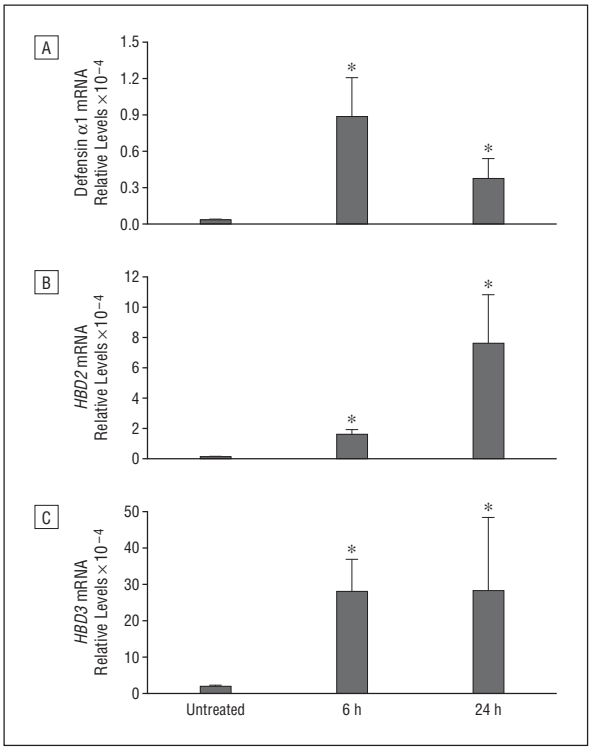

Figure 6. Coarse-grit microdermabrasion induces antimicrobial peptide gene expression in human skin in vivo. Photodamaged forearm skin was treated with coarse-grit microdermabrasion. Samples were obtained at the indicated times from untreated and treated skin sites. Messenger RNA (mRNA) levels for defensin α1 (A), *HBD2* (B), and *HBD3* (C) were quantified by real-time reverse transcription–polymerase chain reaction. Images are representative of 8 subjects. *$P<.05$ vs untreated control.

HBD3 mRNA expression was also rapidly induced following a single coarse-grit microdermabrasion treatment. *HBD2* (Figure 6B) and *HBD3* (Figure 6C) mRNA levels were elevated 15-fold 6 hours after treatment ($P<.05$); gene expression of both antimicrobial peptides remained elevated 24 hours after treatment (76- and 15-fold vs untreated skin, respectively; $P<.05$).

COARSE-GRIT MICRODERMABRASION INDUCES DERMAL REMODELING MMPs AND FIBROBLAST ACTIVATION PROTEIN

Matrix metalloproteinases break down structural proteins that comprise the dermal extracellular matrix (ECM) and are critical for dermal remodeling during wound healing.[19-21] We examined 3 MMPs that are known to be inducible in human skin. Interstitial collagenase (MMP1) initiates collagen degradation by generating 2 smaller fragments, which are then further degraded by stromelysin 1 (MMP3) and gelatinase B (MMP9). A single coarse-grit microdermabrasion treatment resulted in 333-fold induction of *MMP1* mRNA (GenBank NM002421.2) at 6 hours and 99-fold induction at 24 hours ($P<.05$) before trending toward baseline values (**Figure 7**A). MMP1 protein induction was localized in the papillary dermis (Figure 7A). Similarly, *MMP3* gene expression (GenBank NM002422.3) increased 345-fold 6 hours and 39-fold 24 hours after a single treatment ($P<.05$) (Figure 7B). *MMP9*

©2009 American Medical Association. All rights reserved.
Downloaded From: on 07/18/2018

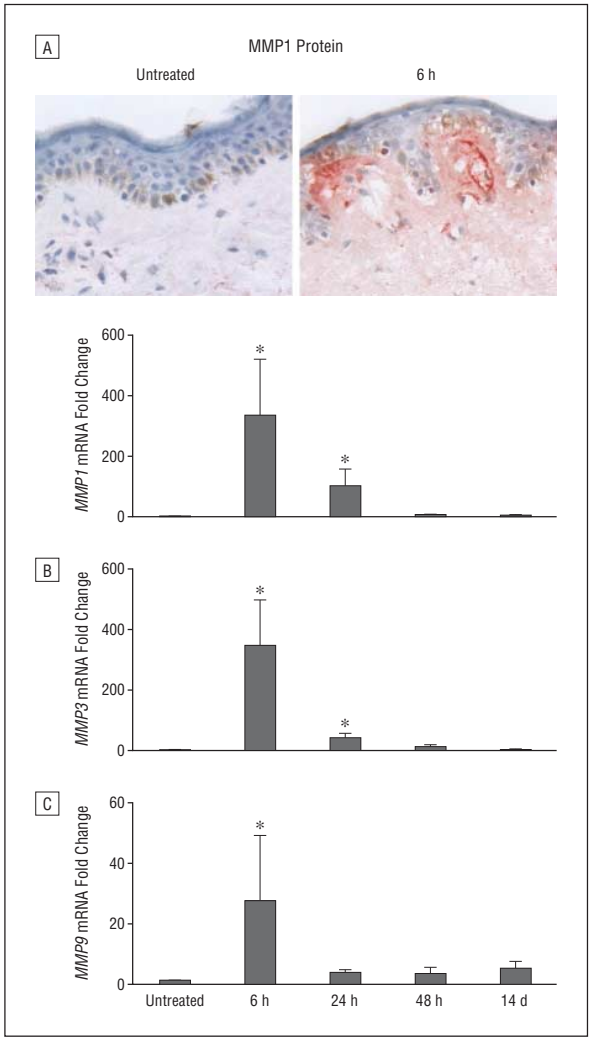

Figure 7. Coarse-grit microdermabrasion induces matrix metalloproteinases (MMP), messenger RNA (mRNA) and protein expression in human skin in vivo. Photodamaged forearm skin was treated with coarse-grit microdermabrasion. Samples were obtained at the indicated times from untreated and treated skin sites. Messenger RNA levels were quantified by real-time reverse transcription–polymerase chain reaction, and protein expression was determined by immunohistochemistry. A, *MMP1* protein expression (original magnification ×240) and mRNA levels. B, *MMP3* mRNA levels. C, *MMP9* mRNA levels. Images are representative of 20 subjects. *$P<.05$ vs untreated control.

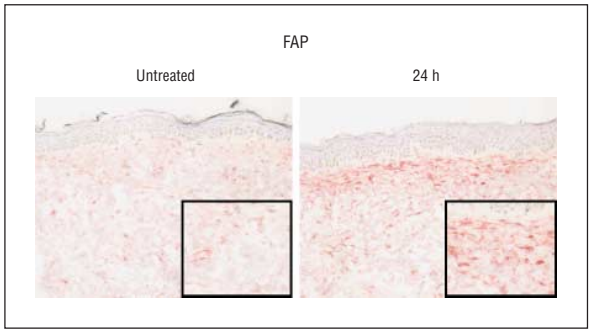

Figure 8. Coarse-grit microdermabrasion induces FAP expression in human skin in vivo. Photodamaged forearm skin was treated with coarse-grit microdermabrasion. Frozen skin sections were stained for FAP protein expression by immunohistochemistry. Specimens are representative of 20 subjects. Insets represent original magnification ×120.

gene expression (GenBank NM004994.2) followed a similar course, with 27-fold induction 6 hours after treatment ($P<.05$), dropping close to baseline within 24 hours after treatment (Figure 7C).

Fibroblast activation protein (FAP) is a membrane-bound serine protease that can degrade denatured collagen fragments.[22,23] It is involved in matrix remodeling and cell motility. A single microdermabrasion treatment with the coarse-grit handpiece dramatically induced FAP protein expression 6 hours (3.9-fold) and 24 hours (4.6-fold) after treatment (**Figure 8**).

COARSE-GRIT MICRODERMABRASION INDUCES COLLAGEN BIOSYNTHETIC PATHWAYS

Microdermabrasion with the coarse-grit wand induced collagen biosynthetic pathways. HSP47 is a molecular chaperone protein necessary for intracellular transport and processing of procollagen within dermal fibroblasts.[24] Microdermabrasion with the coarse-grit wand resulted in significant increases in HSP47 protein expression. HSP47 protein staining was increased 7.5-fold ($P<.05$) throughout the dermis (**Figure 9**A) 14 days after microdermabrasion treatment with the coarse-grit wand. Prolyl 4-hydroxylase catalyzes hydroxylation of proline residues within procollagen. Hydroxylation of proline is necessary to stabilize the triple helix structure of procollagen.[25] Prolyl 4-hydroxylase protein expression was near the limit of detection at baseline but was readily detectable throughout the reticular and papillary dermis 14 days after treatment (Figure 9B).

Consistent with elevated expression of HSP47 and prolyl 4-hydroxylase, coarse-grit microdermabrasion induced type I and type III procollagen expression. Type I and type III procollagen transcripts were induced 3.2-fold and 2.6-fold, respectively, 14 days after a single microdermabrasion treatment ($P<.05$) (**Figure 10**A and B). Type I procollagen protein expression was induced 3.7-fold 14 days after treatment as measured by enzyme-linked immunosorbent assay ($P<.01$) (Figure 10C). Type I procollagen production was induced throughout the papillary and deeper dermis 14 days after treatment (Figure 10D).

MEDIUM-GRIT MICRODERMABRASION FAILS TO STIMULATE REPAIR RESPONSES

Microdermabrasion with the medium-grit handpiece did not result in statistically significant changes in any of the evaluated molecular components of the wound response or dermal remodeling cascade. In untreated and medium-grit microdermabrasion–treated forearm skin, the transcript level or protein expression was quantified at the various times after treatment for the following: *MMP1*, *MMP3*, *MMP9*, cytokeratin 16, type I and type III procollagen, and cytokines IL-1β and tumor necrosis factor. Medium-grit microdermabrasion did not result in protein production or significantly alter mRNA levels in any of these genes (n=20) (data not shown).

©2009 American Medical Association. All rights reserved.
Downloaded From: on 07/18/2018

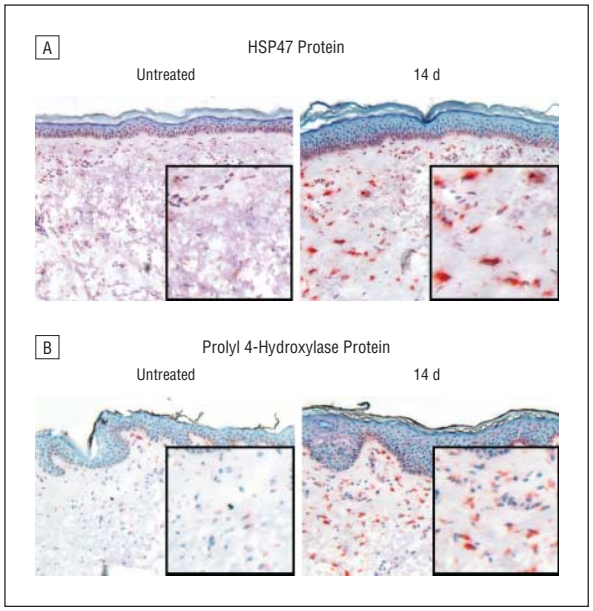

Figure 9. Coarse-grit microdermabrasion induces expression of HSP47 and prolyl 4-hydroxylase proteins involved in collagen synthesis in human skin in vivo. Photodamaged forearm skin was treated with coarse-grit microdermabrasion, and immunohistochemistry was performed for HSP47 (n=20) (A) and prolyl 4-hydroxylase (n=10) (B). Insets represent original magnification ×120.

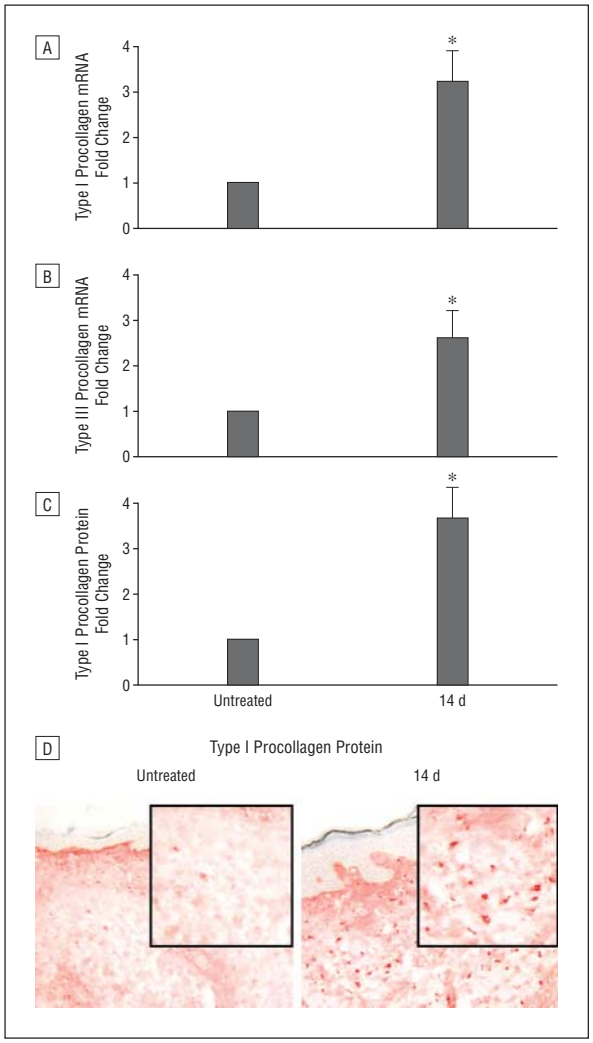

Figure 10. Coarse-grit microdermabrasion induces type I and type III procollagen expression in human skin in vivo. Photodamaged forearm skin was treated with coarse-grit microdermabrasion. Samples were obtained at the indicated times from untreated and treated skin sites. A, Type I procollagen messenger RNA (mRNA) levels were quantified by real-time reverse transcription–polymerase chain reaction. *$P<.005$ vs untreated control. B, Type III procollagen mRNA levels were quantified by real-time reverse transcription–polymerase chain reaction. *$P<.01$ vs untreated control. C, Type I procollagen protein levels were determined by enzyme-linked immunosorbent assay. *$P<.01$. D, Type I procollagen protein expression was localized by immunohistochemistry. Images are representative of 20 subjects. Insets represent original magnification ×120.

COMMENT

As the population ages, skin rejuvenation has become an area of significant interest. Patients prefer cosmetic procedures that require minimal disruption of their normal lifestyle.[26] Microdermabrasion is a popular method of superficial skin resurfacing that is used to treat various cosmetic ailments, including wrinkles, atrophic scars, and dyspigmentation.[1-3] It is associated with minimal morbidity, making it an ideal procedure for patients who want treatment that does not require prolonged healing.[27] Karimipour et al[5] demonstrated that aluminum oxide microdermabrasion stimulates a dermal remodeling cascade involving AP-1, MMPs, and cytokines; however, the procedure failed to consistently induce collagen production.

Type I collagen is the major structural protein in the dermis, accounting for approximately 90% of dermal mass.[25] Fragmentation of collagen fibrils with concomitant impairment of structural integrity is a characteristic feature of photoaged and aged skin.[28,29] In addition, stimulation of collagen production seems to be a prerequisite for effective treatments that objectively improve the wrinkled appearance of skin.[7,30] Therefore, the failure of aluminum oxide microdermabrasion to reliably induce new collagen production suggests a minimal clinical effect. We investigated whether microdermabrasion can be improved to provide reliable remodeling with increased collagen production, while retaining the characteristic "minimal downtime." We hypothesized that increasing the wounding stimulus might enhance activation of the dermal remodeling cascade and result in increased collagen generation.

Wound healing involves several overlapping phases.[15] Microdermabrasion with aluminum oxide crystals or a diamond-tipped wand triggers molecular responses that are observed during wound healing and should be considered a form of superficial wound. In previous work, we suggested that minimal barrier disruption combined with physical movement of the skin by vacuum is likely responsible for generating a wound healing response.[5,31]

Treatment with coarse-grit microdermabrasion results in cytokeratin 16 induction. Cytokeratin 16 is a well-characterized marker of injury to the epidermis and epidermal barrier disruption.[32] Cytokeratin 16 promotes reorganization of cytoplasmic keratin filaments that precedes keratinocyte migration into a wound site.[11] Cytokeratin 16 induction may serve as a useful marker of sufficient epidermal injury to induce repair pathways in response to regen-

©2009 American Medical Association. All rights reserved.
Downloaded From: on 07/18/2018

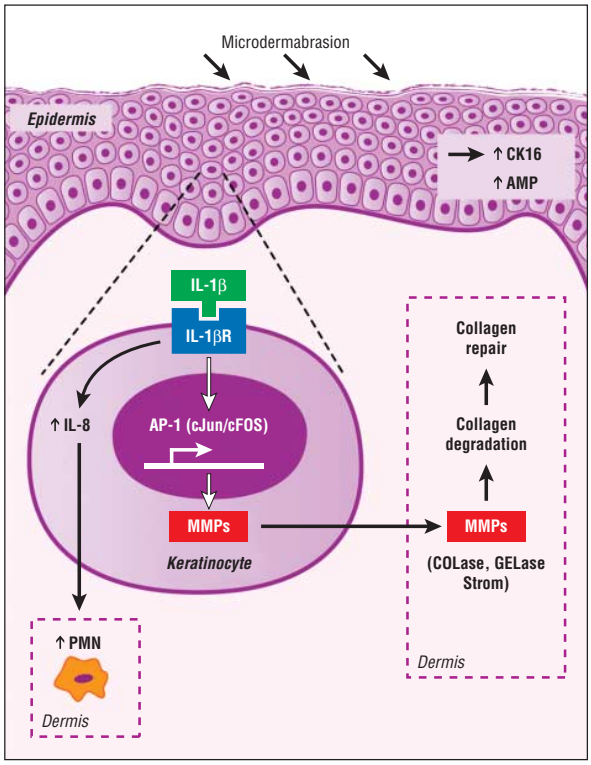

Figure 11. Schematic of the wound-healing cascade induced by microdermabrasion using a coarse-grit diamond-studded handpiece. Stratum corneum is preserved, and there is generation of cytokeratin 16 (CK16), antimicrobial peptide (AMP), cytokines, and presumed leakage of epidermal matrix metalloproteinases (MMPs) into the dermis, with resultant dermal remodeling. COLase indicates collagenase; GELase, gelatinase B; IL, interleukin; Strom, stromelysin 1; and PMN, polymorphonuclear leukocyte.

erative aesthetic procedures. In our study, medium-grit microdermabrasion did not induce cytokeratin 16 expression nor did it induce other components of the repair pathways. Subjects with the largest increases in cytokeratin 16 expression also demonstrated a trend toward some of the largest increases in type I collagen expression.

Keratinocytes may serve as initiators of inflammation because they elaborate proinflammatory cytokines under many different conditions. Nickoloff and Naidu[32] demonstrated that injury of the epidermis by tape stripping resulted in cytokeratin 16 gene expression and the induction of several epidermal-derived cytokines. We observed induction of IL-1β following treatment of the skin with the coarse-grit wand, as was also observed with aluminum oxide microdermabrasion.[5] Interleukin 1β is a primary cytokine that can stimulate the elaboration of other cytokines, including IL-8. Interleukin 8 is a potent chemoattractant for neutrophils, which are important phagocytic cells that participate in the early phases of wound healing.[15] We found statistically significant elevated levels of IL-8 and neutrophil elastase, a marker of neutrophil infiltration, in skin after microdermabrasion treatment with the coarse-grit handpiece. Elevation of neutrophil chemoattractants and neutrophil products after coarse-grit microdermabrasion suggests a role for neutrophils in the wound-healing response after microdermabrasion that is similar to the healing response to an incisional wound.

cJun and JunB components of AP-1 were induced within 6 hours after treatment with the coarse-grit diamond-studded handpiece wand. cJun expression is rapidly induced by various injurious stimuli and is a key mediator in a wide array of cellular responses.[12] cJun is also involved in the regulation of cytokeratin 16 expression.[14] Wang et al[13,14] demonstrated that epidermal growth factor stimulation of protein kinases mediates phosphorylation of the cJun component of AP-1, which then stimulates cytokeratin 16 induction. In addition to its role in cytokeratin 16 regulation, AP-1 is well known to be involved in the induction of inflammatory cytokines (such as IL-1β) and MMPs.[19,21]

Matrix metalloproteinases are responsible for degradation of ECM that comprises the structural material of connective tissue. The substrates of MMPs are collagens, fibronectin, proteoglycans, and other ECM proteins.[19] We measured the effects of microdermabrasion on 3 important MMPs known to be regulated by AP-1, namely, MMP1, MMP3, and MMP9. Coarse-grit microdermabrasion induced expression of all 3. Less aggressive therapy with the medium-grit wand failed to induce significant increases in the expression of MMPs. Matrix metalloproteinase activity is important in wound healing to facilitate the motility of inflammatory cells and to enhance the availability of inflammatory mediators to set the stage for healing.[19]

FAP is an inducible membrane-bound glycoprotein that possesses serine protease activity. FAP is expressed by activated fibroblasts in reactive stroma during wound healing and tumor invasion. FAP has the unique ability to cleave prolyl residues in peptide substrates.[22,23,33] This activity has led to the suggestion that FAP works in concert with MMPs to further break down partially degraded collagen, as collagen contains a large number of prolyl residues. FAP expression was induced after a single microdermabrasion treatment, indicating activation of dermal fibroblasts. A role for MMPs and FAP can be envisioned in cosmetic regenerative procedures. Photoaged skin is characterized by partially degraded cross-linked collagen fragments.[34-36] Evidence suggests that this partially degraded collagen impairs the structural integrity of the dermal ECM, which in turn causes fibroblasts to produce less collagen and more MMPs. FAP may complement the activities of MMPs to more completely remove collagen fragments and to better excavate the dermal ECM, providing a better foundation before deposition of new collagen.

Collagen production is likely to be a substantial benefit in any cosmetic procedure used to improve wrinkles or skin contour irregularities.[7,8] New collagen could "fill in" defects that arise due to collagen fragmentation or loss. In addition, deposition of new collagen not only improves the structural integrity of the dermal ECM but also promotes fibroblasts to produce more collagen, as already described. Our study demonstrated that microdermabrasion with a diamond-studded coarse-tipped wand significantly increases type I and type III procollagen. These data are in contrast to microdermabrasion treatment using a medium-grit wand and aluminum oxide–based microdermabrasion, neither of which significantly induces procollagen production.

Data presented herein support the concept that minor epidermal injury occurs during the microdermabrasion procedure, which initiates a remodeling cascade. This cascade parallels normal wound healing with inflammatory, proliferative, and remodeling phases (**Figure 11**).

©2009 American Medical Association. All rights reserved.
Downloaded From: on 07/18/2018

Stimulation of the wound-healing response may be responsible for the beneficial effects noted after microdermabrasion.[2,37] Our findings add to the growing body of evidence that epidermal damage is sufficient to initiate dermal repair.[5,7] Because of the practical limitations of facial biopsies, we studied photodamaged forearm skin. Although fundamental wound-healing mechanisms are similar among different anatomic sites, we do not know whether subtle differences exist in molecular responses to diamond-studded microdermabrasion treatment. Further rigorous studies are necessary to determine whether the molecular alterations that are obtained with aggressive microdermabrasion translate into improvements in the physical appearance of wrinkles or atrophic scars in vivo. While coarse-grit microdermabrasion demonstrates the ability to cause molecular changes in vivo, these changes may not be quantitatively sufficient to cause significant improvement in the clinical setting. Orringer et al[7,38] demonstrated that the use of carbon dioxide (10 600 nm) or Nd:YAG (1320 nm) lasers can also stimulate a remodeling response with collagen production. The molecular responses seen following coarse-grit microdermabrasion are quantitatively less than those seen with carbon dioxide resurfacing but are quantitatively far superior to the results of nonablative resurfacing lasers like the 1320-nm Nd:YAG and aluminum oxide microdermabrasion.[5,38] Ablative carbon dioxide laser resurfacing clearly yields significant clinical photorejuvenation, while nonablative resurfacing lasers demonstrate less, if not questionable, efficacy.

To the extent that molecular changes can predict clinical outcome, aggressive coarse-grit microdermabrasion should elicit significant skin rejuvenation. Further studies will determine whether microdermabrasion, if performed aggressively, has the capacity to become a worthwhile resurfacing procedure that results in noticeable cosmetic improvement while minimizing patient morbidity and downtime.

Accepted for Publication: March 25, 2009.
Correspondence: Darius J. Karimipour, MD, Department of Dermatology, University of Michigan, 1500 E Medical Center Dr, 1910 Taubman Center, Ann Arbor, MI 48109 (dariusjk@umich.edu).
Author Contributions: Drs Karimipour, Rittié, Hammerberg, and Fisher had full access to all the data in the study and take responsibility for the integrity of the data and the accuracy of the data analysis. *Study concept and design:* Karimipour, Voorhees, Orringer, Sachs, and Fisher. *Acquisition of data:* Karimipour, Rittié, Hammerberg, Min, and Fisher. *Analysis and interpretation of the data:* Karimipour, Voorhees, Hamilton, and Fisher. *Drafting of the manuscript:* Karimipour, Hammerberg, and Fisher. *Critical revision of the manuscript for important intellectual content:* Rittié, Hammerberg, Min, Voorhees, Orringer, and Sachs. *Statistical analysis:* Hamilton. *Obtained funding:* Karimipour. *Study Supervision:* Karimipour, Voorhees, Orringer, Hamilton, and Fisher.
Financial Disclosure: None reported.
Funding/Support: This study was supported by a Dermatology Foundation Clinical Career Development Award in Dermatologic Surgery to Dr Karimipour and by a University of Michigan Human Appearance Research Fund to the Department of Dermatology.
Role of the Sponsors: Altair Instruments donated a DiamondTome microdermabrasion system and handpieces for use in the study. They had no role in the design or conduct of the study; in the collection, analysis, or interpretation of the data; or in the preparation, review, or approval of the manuscript.
Additional Contributions: Suzan Rehbine, RN, performed microdermabrasion and obtained skin biopsy specimens, and Laura Vangoor, BFA, designed the figures used herein. Diane Fiolek, BS, provided administrative support.

REFERENCES

1. Coimbra M, Rohrich RJ, Chao J, Brown SA. A prospective controlled assessment of microdermabrasion for damaged skin and fine rhytides. *Plast Reconstr Surg.* 2004;113(5):1438-1444.
2. Tsai RY, Wang CN, Chan HL. Aluminum oxide crystal microdermabrasion: a new technique for treating facial scarring. *Dermatol Surg.* 1995;21(6):539-542.
3. Shim EK, Barnette D, Hughes K, Greenway HT. Microdermabrasion: a clinical and histopathologic study. *Dermatol Surg.* 2001;27(6):524-530.
4. Freedman BM, Rueda-Pedraza E, Waddell SP. The epidermal and dermal changes associated with microdermabrasion. *Dermatol Surg.* 2001;27(12):1031-1034.
5. Karimipour DJ, Kang S, Johnson TM, et al. Microdermabrasion: a molecular analysis following a single treatment. *J Am Acad Dermatol.* 2005;52(2):215-223.
6. Bernard RW, Beran SJ, Rusin L. Microdermabrasion in clinical practice. *Clin Plast Surg.* 2000;27(4):571-577.
7. Orringer JS, Kang S, Johnson TM, et al. Connective tissue remodeling induced by carbon dioxide laser resurfacing of photodamaged human skin. *Arch Dermatol.* 2004;140(11):1326-1332.
8. Nelson BR, Majmudar G, Griffiths CE, et al. Clinical improvement following dermabrasion of photoaged skin correlates with synthesis of collagen I. *Arch Dermatol.* 1994;130(9):1136-1142.
9. Rittié L, Kang S, Voorhees JJ, Fisher GJ. Induction of collagen by estradiol: difference between sun-protected and photodamaged human skin in vivo. *Arch Dermatol.* 2008;144(9):1129-1140.
10. Fisher GJ, Choi H, Bata-Csorgo Z, et al. Ultraviolet irradiation increases matrix metalloproteinase–8 protein in human skin in vivo. *J Invest Dermatol.* 2001; 117(2):219-226.
11. Paladini RD, Takahashi K, Bravo NS, Coulombe PA. Onset of re-epithelialization after skin injury correlates with a reorganization of keratin filaments in wound edge keratinocytes: defining a potential role for keratin 16. *J Cell Biol.* 1996; 132(3):381-397.
12. Shaulian E, Karin M. AP-1 as a regulator of cell life and death. *Nat Cell Biol.* 2002; 4(5):E131-E136.
13. Wang YN, Chen YJ, Chang WC. Activation of extracellular signal–regulated kinase signaling by epidermal growth factor mediates c-Jun activation and p300 recruitment in keratin 16 gene expression. *Mol Pharmacol.* 2006;69(1):85-98.
14. Wang YN, Chang WC. Induction of disease-associated keratin 16 gene expression by epidermal growth factor is regulated through cooperation of transcription factors Sp1 and c-Jun. *J Biol Chem.* 2003;278(46):45848-45857.
15. Falanga V. Mechanisms of cutaneous wound repair. In: Freedberg I, Eisen A, Wolff K, eds, et al. *Fitzpatrick's Dermatology in General Medicine.* New York, NY: McGraw-Hill; 2003:236-246.
16. Steinstraesser L, Koehler T, Jacobsen F, et al. Host defense peptides in wound healing. *Mol Med.* 2008;14(7-8):528-537.
17. Butmarc J, Yufit T, Carson P, Falanga V. Human β-defensin-2 expression is increased in chronic wounds. *Wound Repair Regen.* 2004;12(4):439-443.
18. de Jongh GJ, Zeeuwen PL, Kucharekova M, et al. High expression levels of keratinocyte antimicrobial proteins in psoriasis compared with atopic dermatitis. *J Invest Dermatol.* 2005;125(6):1163-1173.
19. Herouy Y. Matrix metalloproteinases in skin pathology (review). *Int J Mol Med.* 2001;7(1):3-12.
20. Parks WC. Matrix metalloproteinases in repair. *Wound Repair Regen.* 1999;7(6): 423-432.
21. Matrisian LM. The matrix-degrading metalloproteinases. *Bioessays.* 1992;14(7): 455-463.
22. Park JE, Lenter MC, Zimmermann RN, Garin-Chesa P, Old LJ, Rettig WJ. Fibro-

©2009 American Medical Association. All rights reserved.
Downloaded From: on 07/18/2018

blast activation protein, a dual specificity serine protease expressed in reactive human tumor stromal fibroblasts. *J Biol Chem*. 1999;274(51):36505-36512.
23. Christiansen VJ, Jackson KW, Lee KN, McKee PA. Effect of fibroblast activation protein and α_2-antiplasmin cleaving enzyme on collagen types I, III, and IV. *Arch Biochem Biophys*. 2007;457(2):177-186.
24. Koide T, Asada S, Takahara Y, Nishikawa Y, Nagata K, Kitagawa K. Specific recognition of the collagen triple helix by chaperone HSP47: minimal structural requirement and spatial molecular orientation. *J Biol Chem*. 2006;281(6):3432-3438.
25. Uitto J, Pulkkinen L, Chu M. Collagen. In: Freedberg I, Eisen A, Wolff K, eds, et al. *Fitzpatrick's Dermatology in General Medicine*. New York, NY: McGraw-Hill; 2003:165-179.
26. D'Amico RA, Saltz R, Rohrich RJ, et al. Risks and opportunities for plastic surgeons in a widening cosmetic medicine market: future demand, consumer preferences, and trends in practitioners' services. *Plast Reconstr Surg*. 2008;121(5):1787-1792.
27. Shpall R, Beddingfield FC III, Watson D, Lask GP. Microdermabrasion: a review. *Facial Plast Surg*. 2004;20(1):47-50.
28. Fligiel SE, Varani J, Datta SC, Kang S, Fisher GJ, Voorhees JJ. Collagen degradation in aged/photodamaged skin in vivo and after exposure to matrix metalloproteinase–1 in vitro. *J Invest Dermatol*. 2003;120(5):842-848.
29. Fisher GJ, Varani J, Voorhees JJ. Looking older: fibroblast collapse and therapeutic implications. *Arch Dermatol*. 2008;144(5):666-672.
30. Wang F, Garza LA, Kang S, et al. In vivo stimulation of de novo collagen production caused by cross-linked hyaluronic acid dermal filler injections in photodamaged human skin. *Arch Dermatol*. 2007;143(2):155-163.
31. Karimipour DJ, Kang S, Johnson TM, et al. Microdermabrasion with and without aluminum oxide crystal abrasion: a comparative molecular analysis of dermal remodeling. *J Am Acad Dermatol*. 2006;54(3):405-410.
32. Nickoloff BJ, Naidu Y. Perturbation of epidermal barrier function correlates with initiation of cytokine cascade in human skin. *J Am Acad Dermatol*. 1994;30(4):535-546.
33. O'Brien P, O'Connor BF. Seprase: an overview of an important matrix serine protease. *Biochim Biophys Acta*. 2008;1784(9):1130-1145.
34. Bailey AJ. Molecular mechanisms of ageing in connective tissues. *Mech Ageing Dev*. 2001;122(7):735-755.
35. Varani J, Dame MK, Rittie L, et al. Decreased collagen production in chronologically aged skin: roles of age-dependent alteration in fibroblast function and defective mechanical stimulation. *Am J Pathol*. 2006;168(6):1861-1868.
36. Varani J, Schuger L, Dame MK, et al. Reduced fibroblast interaction with intact collagen as a mechanism for depressed collagen synthesis in photodamaged skin. *J Invest Dermatol*. 2004;122(6):1471-1479.
37. Tan MH, Spencer JM, Pires LM, Ajmeri J, Skover G. The evaluation of aluminum oxide crystal microdermabrasion for photodamage. *Dermatol Surg*. 2001;27(11):943-949.
38. Orringer JS, Voorhees JJ, Hamilton T, et al. Dermal matrix remodeling after nonablative laser therapy. *J Am Acad Dermatol*. 2005;53(5):775-782.

Call for Papers

Notable Notes

We invite authors to submit manuscripts for the Notable Notes feature. Notable Notes will appear in each issue as space is available. They are intended to feature humanity items, such as historical notes of interest, practice pearls, or definitions of dermatologic terms and signs. This form of rapid communication may also be used to note uses of the *Archives of Dermatology* Web site. These very short notes should not exceed 450 words and should not contain more than 3 references. They may have 1 figure and 1 legend or a link to a video on our Web site. Notable Notes must include a title page and a copyright transfer statement when submitted. Please include the word count on the title page.

All manuscripts will undergo our usual editorial review process. Authors are encouraged to consult the *Archives* instructions for authors at http://www.archdermatol.com for guidelines on preparing and submitting manuscripts via our manuscript submission Web site at http://manuscripts.archdermatol.com.

June K. Robinson, MD
Editor
Jeffery P. Callen, MD
Associate Editor

©2009 American Medical Association. All rights reserved.

Downloaded From: on 07/18/2018