Prostate Cancer and Prostatic Diseases (2016), 1–8
© 2016 Macmillan Publishers Limited All rights reserved 1365-7852/16
www.nature.com/pcan

REVIEW

PET imaging of prostate-specific membrane antigen in prostate cancer: current state of the art and future challenges

SP Rowe[1], MA Gorin[2], ME Allaf[2], KJ Pienta[2,3], PT Tran[2,3,4], MG Pomper[1,3,4], AE Ross[2] and SY Cho[1,5]

BACKGROUND: Prostate-specific membrane antigen (PSMA) is a cell surface enzyme that is highly expressed in prostate cancer (PCa) and is currently being extensively explored as a promising target for molecular imaging in a variety of clinical contexts. Novel antibody and small-molecule PSMA radiotracers labeled with a variety of radionuclides for positron emission tomography (PET) imaging applications have been developed and explored in recent studies.
METHODS: A great deal of progress has been made in defining the clinical utility of this class of PET agents through predominantly small and retrospective clinical studies. The most compelling data to date has been in the setting of biochemically recurrent PCa, where PSMA-targeted radiotracers have been found to be superior to conventional imaging and other molecular imaging agents for the detection of locally recurrent and metastatic PCa.
RESULTS: Early data, however, suggest that initial lymph node staging before definitive therapy in high-risk primary PCa patients may be limited, although intraoperative guidance may still hold promise. Other examples of potential promising applications for PSMA PET imaging include non-invasive characterization of primary PCa, staging and treatment planning for PSMA-targeted radiotherapeutics, and guidance of focal therapy for oligometastatic disease.
CONCLUSIONS: However, all of these indications and applications for PCa PSMA PET imaging are still lacking and require large, prospective, systematic clinical trials for validation. Such validation trials are needed and hopefully will be forthcoming as the fields of molecular imaging, urology, radiation oncology and medical oncology continue to define and refine the utility of PSMA-targeted PET imaging to improve the management of PCa patients.

Prostate Cancer and Prostatic Diseases advance online publication, 3 May 2016; doi:10.1038/pcan.2016.13

INTRODUCTION

Prostate cancer (PCa) is the most commonly diagnosed non-cutaneous cancer in men in the United States.[1] Traditional imaging methods in PCa—including magnetic resonance imaging (MRI) for primary disease and contrast-enhanced computed tomography (CECT) and technetium-99 m (^{99m}Tc)-methylene diphosphonate bone scan (BS) for metastatic disease—have a number of significant limitations. These limitations have stimulated the development of new molecular imaging approaches that promise improved sensitivity and specificity for diagnostic imaging of PCa.

A particularly promising target for PCa molecular imaging is prostate-specific membrane antigen (PSMA), a homodimeric type II membrane metalloenzyme that functions as a glutamate carboxypeptidase/folate hydrolase and is overexpressed in PCa.[2] PSMA is expressed in the vast majority of PCa tissue specimens and its degree of expression correlates with a number of important metrics of PCa tumor aggressiveness including Gleason score, propensity to metastasize and the development of castration resistance.[3–9]

The recognition of these features of PSMA lead to the development of the first molecular imaging agent for this target, the radiolabeled monoclonal antibody indium-111 (^{111}In)-capromab pendetide (ProstaScint), which can be imaged using single-photon emission computed tomography to anatomically localize foci of PCa. ProstaScint provided important proof-of-concept information demonstrating the ability of PSMA-directed imaging to detect metastatic recurrent PCa,[10,11] but ultimately suffered from intrinsic limitations regarding its targeting of an intracellular epitope of PSMA, less ideal imaging characteristics of the ^{111}In radionuclide labeling, and longer blood pool biodistribution inherent in an intact antibody imaging agent.

More recently, new PSMA-targeted imaging agents, including both new antibodies with improved imaging characteristics[12] and small-molecule inhibitors of PSMA,[13–15] have been developed and extensively studied. Many of these agents are labeled with radionuclide that allows for positron emission tomography (PET) imaging (for example, fluorine-18 (^{18}F), gallium-68 (^{68}Ga) and zirconium-89 (^{89}Zr)), a functional imaging technique that provides improved spatial resolution and easier quantitation compared with single-photon emission computed tomography. Important clinical questions in both primary and metastatic PCa have begun to be addressed with these agents, and in the following review we will highlight some of the most important accomplishments to date as well as remaining challenges. The subheadings within this review were arrived at by consensus of the authors as representing important clinical questions that remain to be answered in PCa imaging. The majority of references for this narrative review

[1]The Russell H. Morgan Department of Radiology and Radiological Science, Johns Hopkins University School of Medicine, Baltimore, MD, USA; [2]The James Buchanan Brady Urological Institute and Department of Urology, Johns Hopkins University School of Medicine, Baltimore, MD, USA; [3]Department of Medical Oncology, Johns Hopkins University School of Medicine, Baltimore, MD, USA; [4]Department of Radiation Oncology, Johns Hopkins University School of Medicine, Baltimore, MD, USA and [5]Department of Radiology, University of Wisconsin School of Medicine and Public Health and University of Wisconsin Carbone Cancer Center, Madison, WI, USA. Correspondence: Dr SY Cho, Department of Radiology, University of Wisconsin School of Medicine and Public Health, 1111 Highland Avenue, WIMR1 Rm 7139, Madison, WI 53705, USA.
E-mail: scho@uwhealth.org
Received 6 January 2016; revised 10 February 2016; accepted 8 March 2016

MIM Software Inc. v. Progenics Pharmaceuticals, Inc.
IPR2025-00630
Progenics EX2020

were found by searching Pubmed for 'PSMA' and 'PET' or 'positron emission tomography.' Additional references were also incorporated on the basis of individual author's experience in PSMA-targeted PCa imaging or related fields.

CONTEMPORARY AGENTS FOR PSMA-BASED PET IMAGING OF PCA

Although there are newer PSMA-targeted imaging agents labeled with single-photon emitting radionuclides such as technetium-99 m (^{99m}Tc)[16] and iodine-123 (^{123}I, (ref. 17)), herein we will focus on PET radiotracers.

The prototype for an external epitope-binding PSMA-targeted antibody is J591. This intact human monoclonal antibody has been extensively studied and is currently finding application in PET imaging when labeled with ^{89}Zr,[18] a PET radionuclide with a particularly long half-life of 78.4 h. Antibody-based agents typically have long circulatory times before achieving optimal tumor-to-background levels, necessitating the use of such long-lived isotopes for PET imaging. The primary disadvantage of intact antibodies for PET is the need for imaging several days after injection, although smaller engineered antibody fragments are being investigated in an effort to reduce the time required from injection to imaging.[19]

Small-molecule inhibitors of PSMA have significant pharmacokinetic advantages over antibody-based agents, generally allowing imaging within 1 h of radiotracer injection. The vast majority of available data on PSMA PET imaging with small molecules has been obtained with agents labeled with ^{68}Ga (for example, refs 20–22). The most common of these compounds contains the heterobifunctional linker *N,N'*-bis[2-hydroxy-5-(carboxyethyl)benzyl] ethylenediamine-*N,N'*-diacetic acid moiety that chelates the ^{68}Ga radiometal and is conjugated through a linker with a urea that binds in the active site of PSMA (Figure 1); this agent is often referred to in the literature as '^{68}Ga-PSMA' or '^{68}Ga-PSMA *N,N'*-bis[2-hydroxy-5-(carboxyethyl)benzyl] ethylenediamine-*N,N'*-diacetic acid' or more recently '^{68}Ga-PSMA-11,' although a number of other ^{68}Ga-labeled radiotracers have been reported that differ in the chelation moiety and/or the linker. ^{68}Ga is an attractive radionuclide for PET imaging applications because it is produced by a tabletop ^{68}Ge/^{68}Ga generator, whereas most nuclei that decay by positron emission require a cyclotron. For smaller hospitals or academic centers that cannot support the infrastructure necessary to operate a cyclotron, ^{68}Ga is particularly attractive.

Although not as extensively studied as the ^{68}Ga agents,[18] F-labeled inhibitors of PSMA have been reported and offer distinct advantages (Figure 1; refs 23,24). ^{18}F-labeled agents offer large-scale radiosynthesis that would allow for a high volume of patient studies and these compounds also have a long enough physical half-life (109 min) that they can be centrally produced and distributed to many sites using the infrastructure that already exists for distributing ^{18}F-fluorodeoxyglucose for clinical applications (for example, PETNET in the United States). ^{18}F has higher intrinsic PET spatial resolution than ^{68}Ga, especially in smaller lesions, due to its intrinsically shorter positron range and higher positron yield, which may potentially be an advantage for detection of small subcentimeter lymph node metastases, although this needs to be further assessed in upcoming clinical trials.[25]

IMPLICATIONS OF PSMA IMAGING IN LOCAL PCA

According to current guidelines, patients with localized PCa may be managed with a number of different treatment options including active surveillance, radical prostatectomy, external beam radiation therapy and brachytherapy.[26–28] The choice of treatment is in large part predicated on patient age, coexisting medical comorbidities and risk of cancer progression. For those patients at the lowest risk for cancer progression (that is, cT1c, Gleason 3+3 and PSA $\leqslant 10\,\mathrm{ng\,ml^{-1}}$) active surveillance is often advocated as to avoid the potential complications of treatment. In contrast, for patients with intermediate- or high-risk cancer, active treatment with surgery or radiation therapy with or without hormonal therapy is more commonly selected. Finally, in the setting of metastatic disease, patients are typically managed with systemic therapy only (albeit the paradigm in recent years is shifting toward multimodal therapy including both treatment to the primary tumor and metastatic sites). Given these very different therapeutic trajectories for patients newly diagnosed with localized PCa, we believe that new molecular imaging agents would be most useful for (1) the characterization of PCa as clinically insignificant (that is, no Gleason pattern 4 or 5) and appropriate for active surveillance, (2) accurate pre-operative/pre-radiotherapy initial staging to ensure that disease is confined to the prostate and (3) assessment of response to pre-radiation androgen deprivation therapy (ADT) in patient with high-risk and locally advanced PCa.

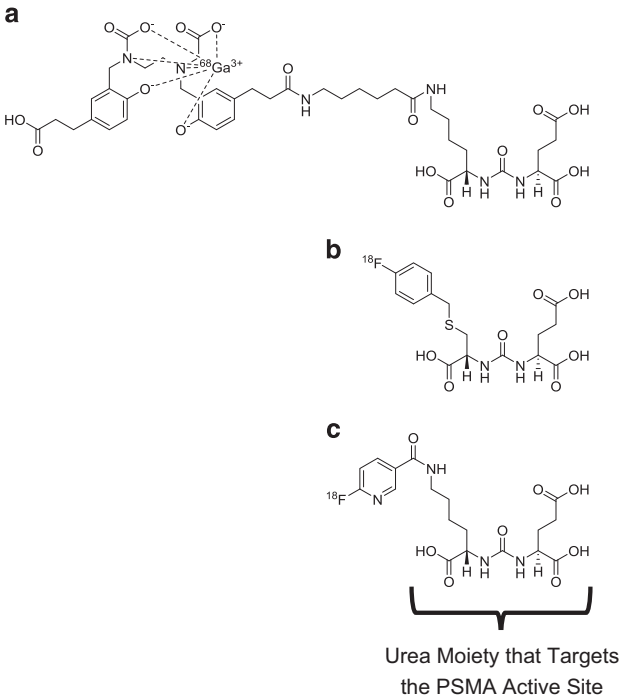

Figure 1. Chemical structures of (**a**) ^{68}Ga-PSMA-HBED-CC, the most common ^{68}Ga-labeled PSMA radiotracer and two ^{18}F-labeled agents, (**b**) ^{18}F-DCFBC and (**c**) ^{18}F-DCFPyL. Note the urea moiety common to all three radiotracers that allows for high-affinity binding to the active site of PSMA. PSMA, prostate-specific membrane antigen. HBED-CC, *N,N'*-bis[2-hydroxy-5-(carboxyethyl)benzyl] ethylenediamine-*N,N'*-diacetic acid.

Primary PCa characterization

As noted above, PSMA expression correlates with PCa tumor aggressiveness. As such, it might be expected that with a quantitative imaging modality such as PET, the degree of radiotracer uptake might predict tumor Gleason score. Indeed, studies with PSMA PET ligands in patients with primary PCa suggest that such a correlation does exist. A prospective study by Osborne *et al.*[29] reported on imaging with a ^{89}Zr-labeled derivative of the J591 antibody in 11 patients undergoing radical prostatectomy. The long half-life of ^{89}Zr allowed *ex vivo* microPET imaging of the prostatectomy specimens and correlation of *ex vivo*

© 2016 Macmillan Publishers Limited
MIM Software Inc. v. Progenics Pharmaceuticals, Inc.
IPR2025-00630
Progenics EX2020

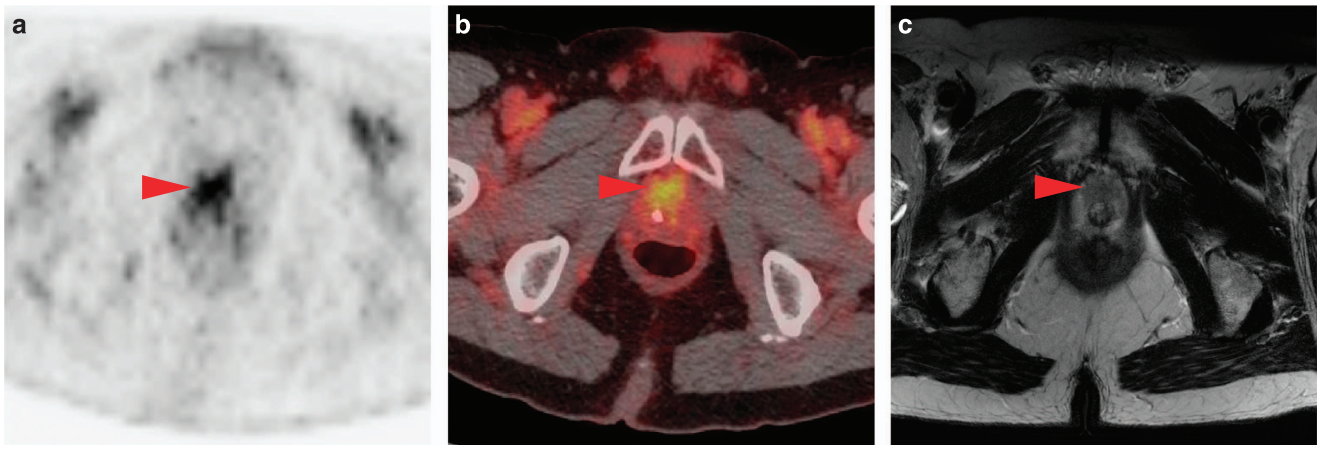

Figure 2. (**a**) Axial ^{18}F-DCFBC PET and (**b**) PET/CT images through the pelvis at the level of the prostate in a patient with Gleason 4+5 = 9 PCa in the anterior apex (red arrowheads, maximum SUV 4.1 (lean body mass corrected)). In a small series of patients, the degree of uptake of this radiotracer was shown to positively correlate to Gleason score.[29] (**c**) Axial T2-weighted images demonstrate a correlating low-signal abnormality in the same location (red arrowheads). The apparent diffusion coefficient MRI sequence acquisition had a great deal of intrinsic noise in this case and was of limited diagnostic utility (not shown). CT, computed tomography; MRI, magnetic resonance imaging; PCa, prostate cancer; PET, positron emission tomography; SUV, standardized uptake value.

results with *in vivo* PET imaging and findings on pathology. The authors found that ^{89}Zr-J591 reliably identified the sites of primary PCa with sum Gleason scores >7 and that the amount of *ex vivo* radiotracer uptake in the sites of disease positively correlated with Gleason score.

A similar prospective pilot study by Rowe *et al.*[30] examined the ^{18}F-labeled small-molecule radiotracer ^{18}F-DCFBC in 13 patients with primary PCa planned for radical prostatectomy. High-volume Gleason 7 and higher disease was successfully imaged (Figure 2), although small-volume and Gleason 6 disease was not always appreciated. Furthermore, the uptake of the radiotracer on PET imaging demonstrated a moderately strong positive correlation with Gleason score (ρ-coefficient = 0.65). An additional observation in this trial showed that PSMA PET may be potentially able to discriminate clinically significant high-grade PCa from BPH. These two studies offer encouragement that clinically significant disease that would merit aggressive therapy with prostatectomy or radiotherapy might be non-invasively identified by PSMA-based PET imaging with high specificity. Larger prospective trials, however, are needed to confirm these initial studies.

Pre-operative/pre-radiotherapy staging

As with any malignancy, accurate pretreatment initial staging is essential to guide appropriate therapy. Particularly, in those PCa patients with suspected clinically localized disease that has high-risk features (defined by the National Comprehensive Cancer Network as T3a disease and/or sum Gleason score 8–10 and/or serum PSA >20 ng ml^{-1}), there is a significant probability of lymph node metastases that are occult on CECT.[31] Patients with intermediate-risk disease (which the National Comprehensive Cancer Network defines as T2b–T2c and/or sum Gleason score 7 and/or PSA 10–20 ng ml^{-1}) may also have extraprostatic involvement and are often imaged in an effort to pre-operatively identify metastatic sites. Indeed, CECT and MRI are both limited primarily to determining lymph node involvement on the basis of the size, although ancillary characteristics such as hyperenhancement, rounded lymph node shape and hypercellularity as determined by restricted diffusion can also aid in determining the presence of lymph node metastases.[32] Molecular imaging agents that might identify lymph node involvement more accurately than CECT have the potential to improve the selection of patients that are appropriate for local therapy.

A recent retrospective study by Budaüs *et al.* evaluating the ability of ^{68}Ga-PSMA agents to identify lymph node metastases in a cohort of patients with high-risk primary PCa demonstrated a surprisingly low sensitivity of only 33% at the patient level.[33] The specificity characteristics of the radiotracer in this context were outstanding, with 100% of the lymph nodes pre-operatively identified on PET being found to contain disease. In addition, a larger (130 patients) retrospective study of intermediate- to high-risk patients undergoing ^{68}Ga-PSMA imaging before prostatectomy continued to find limitations in patient-level sensitivity (65.9%), although the specificity was also remarkably high (98.9%).[34] For comparison, a meta-analysis of CECT and MRI detection of metastatic lymph nodes in primary PCa patients found similar sensitivities as ^{68}Ga-PSMA (42% for CECT and 39% for pelvic MRI), although these modalities were not as specific.[35] Given the otherwise promising results that have been reported for PSMA-based radiotracers in other PCa applications, the relatively low reported sensitivities has sparked a discussion in the literature[36,37] in which the importance of well-designed prospective studies in homogeneous patient populations was emphasized as important before conclusions regarding a new imaging method could be drawn. We agree with this assertion, however, in our own group's experience with the radiotracer[18] F-DCFPyL in a prospective study of patients with National Comprehensive Cancer Network high- and very-high-risk (T3b–T4 and/or Gleason pattern 5 and/or >4 cores with sum Gleason score 8–10) PCa, we also have observed somewhat limited sensitivity for PSMA-based detection of lymph node metastases in the pre-operative setting (Figure 3, currently unpublished results).

Although data with diagnostic pre-operative imaging suggest limitations, a small well-done study of five patients injected with an ^{111}In-labeled PSMA ligand for radioguided lymphadenectomy 24 h before radical prostatectomy was more encouraging. In this study, the authors found that radioguided surgery with the use of a gamma probe more reliably identified small lymph node metastases than did ^{68}Ga-PSMA PET imaging in the same patient cohort.[38] Although this finding will need to be confirmed in a larger group of patients, it might suggest that intraoperative guidance with PSMA ligands could be the most important application of these agents in primary disease staging.

© 2016 Macmillan Publishers Limited

MIM Software Inc. v. Progenics Pharmaceuticals, Inc.
IPR2025-00630
Progenics EX2020

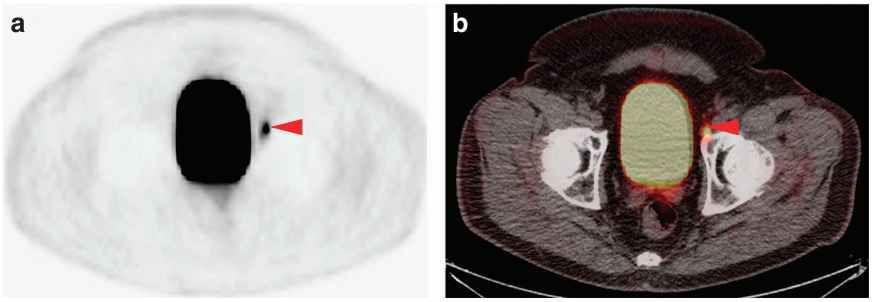

Figure 3. (**a**) Axial pre-operative ^{18}F-DCFPyL PET and (**b**) PET/CT images through the pelvis in a patient with NCCN high-risk primary PCa (cT2c, PSA = 125.5 ng ml^{-1}, Gleason 3+5 = 8) and no definitive evidence of pelvic lymph node metastases on CECT. Red arrowheads indicate intense radiotracer uptake in a 6-mm short axis diameter left external iliac lymph node that was subsequently proven to be disease involved following radical prostatectomy and pelvic lymph node dissection. The patient's primary disease was also radiotracer-avid but is below the level of this image. At midline, a large amount of radioactivity is present within the urinary bladder lumen. CECT, contrast-enhanced computed tomography; CT, computed tomography; NCCN, National Comprehensive Cancer Network; PCa, prostate cancer; PET, positron emission tomography.

Assessment of response to pre-radiation ADT

Patients with high-risk localized or locally advanced PCa treated with standard-of-care radiation and ADT have highly variable, responses. Better markers to stratify and also adapt treatment to these patients earlier during their treatment course are needed. It is now well recognized that androgen receptor (AR) signaling is critical for PCa tumor maintenance in both hormone therapy naive as well as the castration-resistant state. Recent pre-clinical data suggest that PSMA is regulated directly by the AR and may serve as a surrogate marker for AR signaling dynamics.[39] A quantitative, non-invasive method for PSMA detection and more importantly monitoring AR signaling dynamics in humans is not currently available. Development of PSMA PET imaging may allow for the selection of appropriate risk adaptive therapies and allow non-invasive functional assessment of AR signaling dynamics in living subjects. Multiple randomized trials have established the benefit of combined modality therapy with androgen deprivation and radiation for men with high-risk localized or locally advanced PCa.[40–43] Animal studies have shown that radiation is most effective for tumor reduction in combination with ADT.[44–46] This would agree with the increasing clinical evidence showing that biochemical response to ADT, as measured by PSA immediately before radiation, rather than duration of ADT is the critical factor for determining the benefit of combined treatment of radiation and ADT.[47–51] Recent studies have demonstrated that for men with clinically localized, nonmetastatic PCa receiving ADT and dose-escalated radiation, attaining a pre-RT PSA of <0.5 or $\leqslant 0.3$ ng ml^{-1} after ADT, portends improved clinical outcomes, suggesting that the degree of suppression of AR signaling determines outcome in men treated with radiation.[52,53] The ability to identify men at increased risk of death from PCa based on pre-radiation AR signaling would help the design of new clinical trials testing novel, more potent anti-androgen therapies, such as enzalutamide,[54] in combination with radiation to improve the outcome for men who are poor responders to current standard-of-care ADT regimens. The differential sensitivity of intra-prostatic lesions to ADT might be explained by different levels of AR inhibition. Furthermore, because declines in serum PSA levels reflect an average across all lesions, it is not currently possible to determine whether AR inhibition varies at different sites. A solution to those limitations of serum PSA may be PMSA-targered PET that accurately measures intra-tumoral AR signaling. In collaboration with the National Cancer Institute and Johns Hopkins University, a clinical trial to assess this hypothesis using ^{18}F-DCFPyL PET/computed tomography (CT) in high-risk and locally advanced PCa patients (NCT02420977) is currently underway.

APPLICATIONS OF PSMA IMAGING IN RECURRENT AND SYSTEMIC PCA

Biochemically recurrent PCa

The most extensively studied application of PSMA-based imaging in PCa is in the context of biochemical recurrence following failed local therapy (defined as a rise in serum PSA level of $\geqslant 0.2$ ng ml^{-1} post radical prostatectomy,[55] and as a 2 ng ml^{-1} rise above the PSA nadir post radiation[56,57]). By definition, these patients do not have evidence of metastatic disease visible on conventional imaging, so the choice of salvage treatment (for example, systemic therapy versus radiation therapy of the prostate bed) is often based on imperfect clinical parameters such as PSA doubling time. Although there is certainly evidence that empiric therapy has benefits and improves outcomes in selected patients with biochemical recurrence,[58] reliable imaging assessment and localization of the site of recurrent disease would potentially provide more appropriate guidance of treatment (Figure 4). These considerations point to a significant need for improved imaging techniques in the biochemically recurrent patient population.

A number of studies in biochemically recurrent PCa patients have been carried out with PSMA-targeted imaging, primarily using ^{68}Ga-PSMA ligands and with some studies including comparison with choline-based PET radiotracers. These studies are summarized in Table 1. The two largest reported studies by Afshar-Oromieh A *et al.*[12] and Eiber M. *et al.*[22] included 319 and 248 patients, respectively, and both reported promising results. In the 319-patient study,[21] Afshar-Oromieh *et al.* retrospectively analyzed imaging from patients with recurrent PCa and found at least one lesion suggestive of PCa in 82.8% of cases. Lesion detection was positively correlated with serum PSA level (with presumed sensitivity for PSA values $\leqslant 0.5$ ng ml^{-1} of 48.1%, and presumed sensitivity for PSA values >20.0 ng ml^{-1} of 100.0%) and the administration of androgen deprivation therapy, but was not correlated with Gleason score at original diagnosis or serum PSA doubling time. In a subset of lesions for which histology was available, the true sensitivity was 76.6% with a specificity of 100.0%.

In the second large retrospective study,[22] Eiber *et al.* evaluated the results of ^{68}Ga-PSMA imaging in 248 patients with biochemical recurrence after radical prostatectomy. The detection rates were similar to the study by Afshar-Oromieh *et al.*,[21] with 89.5% of patients demonstrating suspicious abnormal radiotracer uptake. The authors also found positive correlation with serum PSA levels, with detection rates ranging from 57.9% in patients with serum PSA 0.2 to <0.5 ng ml^{-1} to 96.8% in patients with PSA >2 ng ml^{-1}. Higher PSA velocities did increase the detection rate; however, there was no significant correlation with PSA

© 2016 Macmillan Publishers Limited
MIM Software Inc. v. Progenics Pharmaceuticals, Inc.
IPR2025-00630
Progenics EX2020

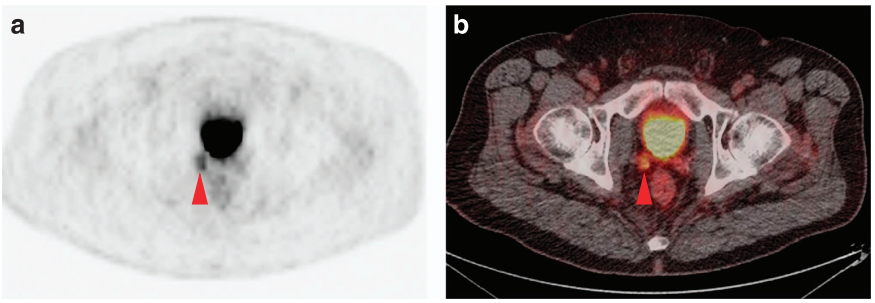

Figure 4. (**a**) ^{18}F-DCFPyL PET and (**b**) ^{18}F-DCFPyL PET/CT images from a patient with biochemical recurrence following radical prostatectomy (PSA 0.3 ng dl^{-1} at the time of imaging). Subtle increased radiotracer uptake is seen in the right prostate bed (red arrowheads) compatible with local recurrence of disease (uptake in the urinary bladder is present anteromedial to the local recurrence). The patient subsequently underwent salvage radiotherapy with a boost to the region of ^{18}F-DCFPyL uptake and PSA level became undetectable. The lack of radiotracer uptake outside of the typical salvage pelvic radiation field increased the confidence level of the treating clinicians that salvage radiotherapy was the appropriate course of action in this patient. CT, computed tomography; PET, positron emission tomography.

Table 1. Trials of ^{68}Ga-PSMA PET imaging in biochemical recurrence

Authors and year	*PSMA PET patient-level sensitivity (%)*	*Sample size*	*Factors positively associated with PSMA-avid lesion detection*	*Comparison radiotracer*	*Comparison radiotracer patient-level sensitivity (%)*
Afshar-Oromieh *et al.*[21]	82.8	319	PSA, androgen deprivation therapy	—	—
Eiber *et al.*[22]	89.5	248	PSA, PSA velocity, Gleason score	—	—
Afshar-Oromieh *et al.*[58]	86	37	None reported as statistically significant	^{18}F-fluoromethylcholine	70
Morigi *et al.*[59]	66	38	PSA	^{18}F-fluoromethylcholine	29

Abbreviations: PET, positron emission tomography; PSMA, prostate-specific membrane antigen.

doubling time. Interestingly, the Eiber *et al.* study differed in that higher Gleason score at the time of prostatectomy contributed to increased detection efficiency. Further, the authors reported no significant correlation between putative sensitivity and androgen deprivation therapy. These differences between these two large retrospective studies emphasize the need for well-designed prospective studies with large numbers of patients to deconvolute the nuances of PSMA PET utility and application in PCa biochemical recurrence.

An early study comparing a ^{68}Ga-labeled PSMA ligand to ^{18}F-fluoromethylcholine in the detection of biochemically recurrent PCa found a higher sensitivity for lesions typical of PCa with the PSMA-targeted radiotracer (86% of patients versus 70%, respectively[59]). In another very well-done comparison with ^{18}F-fluoromethylcholine, the ^{68}Ga-labeled PSMA radiotracer prospectively detected lesions in 66% of 38 patients who had undergone prior attempt at curative therapy and then developed a post-therapy rise in PSA, whereas ^{18}F-fluoromethylcholine was putatively true positive in only 29% of patients.[60] The superiority of the ^{68}Ga-labeled agent for lesion detection was demonstrated across all PSA levels (<0.5, 0.5–2.0 and >2.0 ng ml^{-1}).

A particular interesting study was recently published in which ^{68}Ga-PSMA was compared with the ^{18}F-labeled PSMA ligand ^{18}F-DCFPyL[61] in patients with biochemical recurrence. Both radiotracers identified suspicious foci of abnormal radiotracer uptake suggesting sites of disease in 11 of 14 patients (79%). However, in three of the patients (21%), additional lesions were observed with ^{18}F-DCFPyL. Although the patient-level sensitivity of the radiotracers was identical, the additional lesions seen with ^{18}F-DCFPyL hints that the ^{18}F-labeled radiotracer may detect subtle sites of disease that would be missed by ^{68}Ga-PSMA, as described above based on the improved imaging characteristics of ^{18}F versus ^{68}Ga radionuclides for PET detection of smaller-sized lesions, potentially improving staging in the biochemically recurrent patient population.

As a confirmation of the superiority of PSMA-based PET to conventional cross-sectional imaging, a recent study directly comparing a ^{68}Ga-labeled PSMA radiotracer with three-dimensional volumetric CT in the evaluation of pelvic lymph nodes in patients with biochemically recurrent PCa demonstrated a superiority of PSMA-targeted PET to advanced CECT metrics, with two-thirds of patients with lymph nodes identified by PET having been negative with CECT.[62]

Evaluation and treatment planning in patients with widespread metastatic disease

Although limited in the detection of biochemically recurrent PCa, CECT and BS can reliably detect widespread metastatic PCa. Nonetheless, PSMA-based PET has superior sensitivity in comparison with CECT and/or BS, either alone or in combination, for the detection of the sites of metastasis in both hormone-naive and castration-resistant metastatic PCa patients.[63] Even relative to the highly sensitive modality of Na^{18}F PET/CT for the detection of osteoblastic bone metastases, PSMA-targeted PET/CT may identify more bone lesions in patients with widespread metastases.[64] Perhaps more important than this added sensitivity, the recent emergence of PSMA-targeted radiotherapeutics suggests that complete staging with diagnostic PSMA-based PET, of both soft tissue as well as bone metastases, may have an important role in the future treatment planning of patients with widely metastatic PCa, given that the total PSMA-ligand-avid tumor burden can inform the administered dose of radiotherapeutics.

Early studies on PSMA-based radiotherapy were carried out with a lutetium-177 (^{177}Lu)-labeled version of the J591 antibody (^{177}Lu is a beta-particle emitting radionuclide that also decays by single-photon emission and can be imaged with a gamma camera). In a phase I trial involving 35 patients with progressive

© 2016 Macmillan Publishers Limited

MIM Software Inc. v. Progenics Pharmaceuticals, Inc.
IPR2025-00630
Progenics EX2020

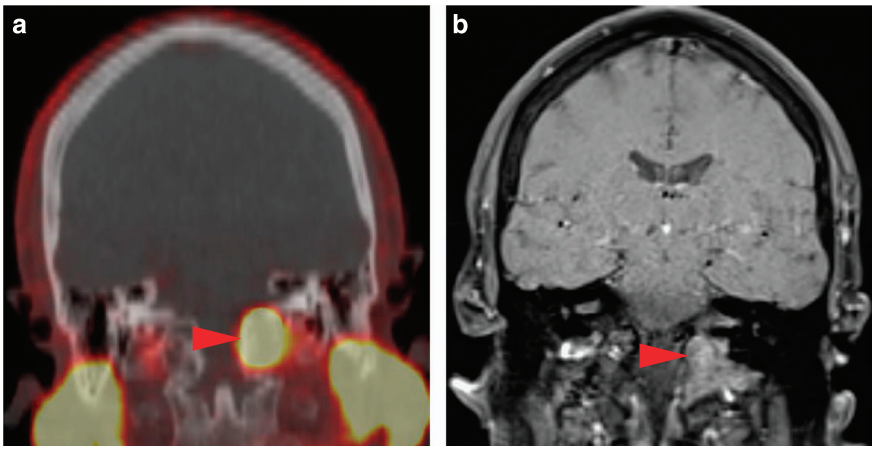

Figure 5. An unusual case of oligometastatic prostate cancer with treatment guided by PSMA PET. (**a**) Coronal fused image from ^{18}F-DCFPyL PET/CT demonstrating intense radiotracer uptake at the left skull base, highly suspicious for a site of metastatic PCa (red arrowhead, maximum SUV 18.4 (lean body mass corrected)). No other abnormal uptake was appreciated on the PET/CT. High uptake within the salivary glands is partly imaged, a known aspect of the normal biodistribution of PSMA-targeted radiotracers. (**b**) Coronal T1-weighted fat saturation post-contrast MRI demonstrating intense abnormal enhancement at the left skull base (red arrowhead), compatible with metastatic PCa. The patient was treated with stereotactic ablative radiotherapy with subsequent decrease in serum PSA. CT, computed tomography; MRI, magnetic resonance imaging; PET, positron emission tomography; SUV, standardized uptake value.

castration-resistant metastatic PCa, Bander *et al.*[65] demonstrated that multiple doses of ^{177}Lu-J591 were well tolerated with reasonable toxicity and with radiotracer uptake at known sites of metastatic PCa. The follow-up phase II study with ^{177}Lu-J591 was carried out in 47 metastatic castration-resistant patients, with 59.6% of patients showing a decrease in serum PSA, although reversible myelosuppression was observed with a significant number of patients having grade 4 thrombocytopenia and/or neutropenia.[66]

More recently, radiotherapeutic versions of small-molecule inhibitors of PSMA have also been reported. ^{177}Lu has also been the radiometal of choice for these agents, given that the same chelator moieties that can be conjugated to ^{68}Ga also generally have affinity for ^{177}Lu, allowing for combined diagnostic and therapeutic capabilities into a single agent or a theranostic PCa agent. Weineisen *et al.*[67] recently reported on an optimized ligand ('PSMA inhibitor for imaging and therapy', 'PSMA I&T') that could be labeled with both ^{68}Ga and ^{177}Lu; ^{68}Ga-PSMA I&T imaging demonstrated high tumor-to-background and ^{177}Lu-PSMA I&T was well tolerated in two patients with no detectable side effects. An additional small study of 10 patients who underwent imaging with ^{68}Ga-PSMA and were then treated with the radioligand ^{177}Lu-DKFZ-617 ('Lu-PSMA') was notable for a serum PSA decline in 70% of the patients, with five patients experiencing a decline of $>50\%$.[68] Four patients had some degree of myelosuppression; however, the overall hematologic effects appear to be less than those observed with ^{177}Lu-J591.

These early promising results obtained by imaging and then treating patients with radiotherapeutics targeting PSMA (that is, a 'theranostic' approach) certainly merit further study in larger patient cohorts. Caution must be exercised, however, as there is very high PSMA-targeted radiotracer uptake in the salivary glands and kidneys, and long-term toxicity to these organs may ultimately limit application of these new therapeutic agents.

GUIDING TARGETED THERAPY FOR OLIGOMETASTATIC DISEASE

In recent years, there has been increasing biological and clinical evidence for, and recognition of, an intermediate state of cancer that exists on a continuum between localized and widespread metastatic cancer.[69,70] Often termed oligometastatic disease and generally defined as less than or equal to five metastatic sites, this state is believed to arise biologically as a result of cancer cells acquiring some, but not all, of the characteristics necessary for wide metastatic spread. In selected patients with certain malignancies, focally treating all the sites of oligometastatic disease may offer cure or long-term local control (Figure 5; ref. 70). Multiple clinical trials are currently underway to assess the best approach for the treatment of oligometastatic disease in PCa.[71]

It follows that the more reliably an imaging modality is able to identify the sites of metastatic PCa, the more appropriately patients can be selected for the treatment of oligometastatic disease. Given the earlier discussions in this manuscript on the lack of sensitivity of CECT and BS for detecting the sites of metastatic PCa in pre-operative high-risk and biochemically recurrent patients, these conventional imaging modalities would be expected to significantly understage patients. As such, conventional imaging would suggest some patients have oligometastases when they actually harbor widespread metastatic disease or under represent the number of oligometastases. More sensitive molecular imaging methods such as PSMA PET offer the opportunity to at least partially address the current limitations in staging oligometastatic patients.

Suggestions of the role PSMA-directed therapy for oligometastatic PCa may play in the future have already begun to appear in the literature. For example, in the large retrospective trial of ^{68}Ga-PSMA in biochemical recurrence reported by Afshar-Oromieh *et al.*,[21] it was noted that 50 out of 116 patients for whom follow-up was available had received local therapy at the sites of biochemical recurrence that were identified by the PSMA PET scan, instead of proceeding to immediate systemic therapy such as androgen deprivation. These focal therapies included external beam radiation, surgery and high-intensity focused ultrasound. Although some of these lesions were undoubtedly local recurrence and not metastases, *per se*, the ability of PSMA-targeted PET to guide such interventions is an important finding.

A more direct example of focal oligometastatic treatment guided by PSMA imaging was recently published. Schiavina *et al.* described a case of a patient with biochemical recurrence who underwent ^{68}Ga-PSMA PET/CT scanning and was found to have radiotracer-avid retroperitoneal adenopathy.[72] No other sites of disease were appreciated. Following salvage retroperitoneal lymph node dissection, the patient's PSA became undetectable. A larger-scale retrospective study by Hijazi and colleagues

© 2016 Macmillan Publishers Limited
MIM Software Inc. v. Progenics Pharmaceuticals, Inc.
IPR2025-00630
Progenics EX2020

demonstrated that ^{68}Ga-PSMA PET could reliably identify oligometastatic lymph node involvement in patients who were treated with an extended pelvic lymph node dissection after biochemical recurrence or in high-risk PCa before prostatectomy.[73]

CONCLUSIONS

A large, and growing, literature has emerged in recent years demonstrating the potential utility of PSMA-based imaging of PCa for a variety of indications. To date, the most clear clinically indication is for patients with biochemical recurrence, with PSMA-based PET so far proving to have higher sensitivity than any other modality for localization of the site of recurrence, including other PET molecular imaging agents. Other applications that show promise include the characterization and risk stratification of primary PCa, complete staging of metastatic PCa to allow for PSMA-targeted radiotherapy and improved identification of patients with oligometastatic disease. Early results would indicate that pre-operative imaging for determination of pelvic lymph node involvement in high-risk primary PCa may be limited, although PSMA-based intraoperative guidance may ultimately prove valuable. In coming years, the onus is on our field, composed of a multi-disciplinary collaborative effort of imagers and treating physicians and surgeons, to carry out large and well-thought-out prospective trials to definitively uncover the true utility of PSMA-based PET to improve the management and outcomes of patients with PCa.

CONFLICT OF INTEREST

MGP is a co-inventor on a US Patent covering ^{18}F-DCFPyL and as such are entitled to a portion of any licensing fees and royalties generated by this technology. This arrangement has been reviewed and approved by the Johns Hopkins University in accordance with its conflict of interest policies. The remaining authors declare no conflict of interest.

ACKNOWLEDGEMENTS

We acknowledge funding from CA134675, CA184228 and CA183031, PCF Young Investigator Award, PCF Creativity Award, and a Movember-PCF Challenge Award as well as philanthropic funds to The James Buchanan Brady Urological Institute that have supported our group's work in PSMA imaging.

REFERENCES

1 Siegel RL, Miller KD, Jemal A. Cancer statistics, 2015. *CA Cancer J Clin* 2015; **65**: 5–29.
2 Kiess AP, Banerjee SR, Mease RC, Rowe SP, Rao A, Foss CA *et al.* Prostate-specific membrane antigen as a target for cancer imaging and therapy. *Q J Nucl Med Mol Imaging* 2015; **59**: 241–268.
3 Wright GL Jr, Grob BM, Haley C, Grossman K, Newhall K, Petrylak D *et al.* Upregulation of prostate-specific membrane antigen after androgen-deprivation therapy. *Urology* 1996; **48**: 326–334.
4 Sweat SD, Pacelli A, Murphy GP, Bostwick DG. Prostate-specific membrane antigen expression is greatest in prostate adenocarcinoma and lymph node metastases. *Urology* 1998; **52**: 637–640.
5 Chang SS, Reuter VE, Heston WD, Gaudin PB. Comparison of anti-prostate-specific membrane antigen antibodies and other immunomarkers in metastatic prostate carcinoma. *Urology* 2001; **57**: 1179–1183.
6 Noss KR, Wolfe SA, Grimes SR. Upregulation of prostate specific membrane antigen/folate hydrolase transcription by an enhancer. *Gene* 2002; **285**: 247–256.
7 Ross JS, Sheehan CE, Fisher HA, Kaufman RP Jr, Kaur P, Gray K *et al.* Correlation of primary tumor prostate-specific membrane antigen expression with disease recurrence in prostate cancer. *Clin Cancer Res* 2003; **9**: 6357–6362.
8 Perner S, Hofer MD, Kim R, Shah RB, Li H, Möller P *et al.* Prostate-specific membrane antigen expression as a predictor of prostate cancer progression. *Hum Pathol* 2007; **38**: 696–701.
9 Evans MJ, Smith-Jones PM, Wongvipat J, Navarro V, Kim S, Bander NH *et al.* Noninvasive measurement of androgen receptor signaling with a positron-emitting radiopharmaceutical that targets prostate-specific membrane antigen. *Proc Natl Acad Sci USA* 2011; **108**: 9578–9582.
10 Sodee DB, Nelson AD, Faulhaber PF, Maclennan GT, Resnick MI, Bakale G. Update on fused capromab pendetide imaging of prostate cancer. *Clin Prostate Cancer* 2005; **3**: 230–238.
11 Mohammed AA, Shergill IS, Vandal MT, Gujral SS. ProstaScint and its role in the diagnosis of prostate cancer. *Expert Rev Mol Diagn* 2007; **7**: 345–349.
12 Holland JP, Divilov V, Bander NH, Smith-Jones PM, Larson SM, Lewis JS. ^{89}Zr-DFO-J591 for immunoPET of prostate-specific membrane antigen expression in vivo. *J Nucl Med* 2010; **51**: 1293–1300.
13 Mease RC, Dusich CL, Foss CA, Ravert HT, Dannals RF, Seidel J *et al.* N-[N-[(S)-1, 3-Dicarboxypropyl]carbamoyl]-4-[^{18}F]fluorobenzyl-L-cysteine, [^{18}F]DCFBC: a new imaging probe for prostate cancer. *Clin Cancer Res* 2008; **14**: 3036–3043.
14 Banerjee SR, Pullambhatla M, Byun Y, Nimmagadda S, Green G, Fox JJ *et al.* ^{68}Ga-labeled inhibitors of prostate-specific membrane antigen (PSMA) for imaging prostate cancer. *J Med Chem* 2010; **53**: 5333–5341.
15 Chen Y, Pullambhatla M, Foss CA, Byun Y, Nimmagadda S, Senthamizhchelvan S *et al.* 2-(3-{1-Carboxy-5-[(6-[^{18}F]fluoro-pyridine-3-carbonyl)-amino]-pentyl}-ureido)-pentanedioic acid, [^{18}F]DCFPyL, a PSMA-based PET imaging agent for prostate cancer. *Clin Cancer Res* 2011; **17**: 7645–7653.
16 Vallabhajosula S, Nikolopoulou A, Babich JW, Osborne JR, Tagawa ST, Lipai I *et al.* ^{99m}Tc-labeled small-molecule inhibitors of prostate-specific membrane antigen: pharmacokinetics and biodistribution studies in healthy subjects and patients with metastatic prostate cancer. *J Nucl Med* 2014; **55**: 1791–1798.
17 Hillier SM, Kern AM, Maresca KP, Marquis JC, Eckelman WC, Joyal JL *et al.* ^{123}I-MIP-1072, a small-molecule inhibitor of prostate-specific membrane antigen, is effective at monitoring tumor response to taxane therapy. *J Nucl Med* 2011; **52**: 1087–1093.
18 Pandit-Taskar N, O'Donoghue JA, Jurack JC, Lyashchenko SK, Cheal SM, Beylergil V *et al.* A phase I/II study for analytic validation of ^{89}Zr-J591 immunoPET as a molecular imaging agent for metastatic prostate cancer. *Clin Cancer Res* 2015; **21**: 5277–5285.
19 Viola-Villegas NT, Sevak KK, Carlin SD, Doran MG, Evans HW, Bartlett DW *et al.* Noninvasive imaging of PSMA in prostate tumors with ^{89}Zr-labeled huJ591 engineered antibody fragments: the faster alternatives. *Mol Pharm* 2014; **11**: 3965–3973.
20 Afshar-Oromieh A, Malcher A, Eder M, Eisenhut M, Linhart HG, Hadaschik BA *et al.* PET imaging with a [^{68}Ga]gallium-labelled PSMA ligand for the diagnosis of prostate cancer: biodistribution in humans and first evaluation of tumour lesions. *Eur J Nucl Med Mol Imaging* 2013; **40**: 797–798.
21 Afshar-Oromieh A, Avtzi E, Giesel FL, Holland-Letz T, Linhart HG, Eder M *et al.* The diagnostic value of PET/CT imaging with the ^{68}Ga-labelled PSMA ligand HBED-CC in the diagnosis of recurrent prostate cancer. *Eur J Nucl Med Mol Imaging* 2015; **42**: 197–209.
22 Eiber M, Maurer T, Souvatzoglou M, Beer AJ, Ruffani A, Haller B *et al.* Evaluation of hybrid ^{68}Ga-PSMA ligand PET/CT in 248 patients with biochemical recurrence after radical prostatectomy. *J Nucl Med* 2015; **56**: 668–674.
23 Cho SY, Gage KL, Mease RC, Senthamizhchelvan S, Holt DP, Jeffrey-Kwanisai A *et al.* Biodistribution, tumor detection, and radiation dosimetry of ^{18}F-DCFBC, a low-molecular-weight inhibitor of prostate-specific membrane antigen, in patients with metastatic prostate cancer. *J Nucl Med* 2012; **53**: 1883–1891.
24 Szabo Z, Mena E, Rowe SP, Plyku D, Nidal R, Eisenberger MA *et al.* Initial evaluation of [^{18}F]DCFPyL for prostate-specific membrane antigen (PSMA)-targeted PET imaging of prostate cancer. *Mol Imaging Biol* 2015; **17**: 565–574.
25 Sanchez-Crespo A. Comparison of Gallium-68 and Fluorine-18 imaging characteristics in positron emission tomography. *Appl Radiat Isot* 2013; **76**: 55–62.
26 National Comprehensive Cancer Network. Prostate Cancer (Version 1.2016). Available at http://www.nccn.org/professionals/physician_gls/pdf/prostate.pdf. Accessed 1 November 2015.
27 American Urological Association. Guideline for the Management of Clinically Localized Prostate Cancer (2007). Available at https://www.auanet.org/common/pdf/education/clinical-guidance/Prostate-Cancer.pdf. Accessed 1 November 2015.
28 European Association of Urology. Guidelines on Prostate Cancer (2015). Avaiable at https://www.auanet.org/common/pdf/education/clinical-guidance/Prostate-Cancer.pdf. Accessed 1 November 2015.
29 Osborne JR, Green DA, Spratt DE, Lyashchenko S, Fareedy SB, Robinson BD *et al.* A prospective pilot study of ^{89}Zr-J591/prostate specific membrane antigen positron emission tomography in men with localized prostate cancer undergoing radical prostatectomy. *J Urol* 2014; **191**: 1439–1445.
30 Rowe SP, Gage KL, Faraj SF, Macura KJ, Cornish TC, Gonzalez-Roibon N *et al.* ^{18}F-DCFBC PET/CT for PSMA-based detection and characterization of primary prostate cancer. *J Nucl Med* 2015; **56**: 1003–1010.
31 Briganti A, Abdollah F, Nini A, Suardi N, Gallina A, Capitanio U *et al.* Performance characteristics of computed tomography in detecting lymph node metastases in contemporary patients with prostate cancer treated with extended lymph node dissection. *Eur Urol* 2012; **61**: 1132–1138.
32 Eiber M, Beer AJ, Holzapfel K, Tauber R, Ganter C, Weirich G *et al.* Preliminary results for characterization of pelvic lymph nodes in patients with prostate cancer by diffusion-weighted MR-imaging. *Invest Radiol* 2010; **45**: 15–23.

© 2016 Macmillan Publishers Limited

MIM Software Inc. v. Progenics Pharmaceuticals, Inc.
IPR2025-00630
Progenics EX2020

33 Budäus L, Leyh-Bannurah SR, Salomon G, Michl U, Heinzer H, Huland H *et al.* Initial experience of ^{68}Ga-PSMA PET/CT imaging in high-risk prostate cancer patients prior to radical prostatectomy. *Eur Urol* 2016; **69**: 393–396.
34 Maurer T, Gschwend JE, Rauscher I, Souvatzoglou M, Haller B, Weirich G *et al.* Diagnostic efficacy of ^{68}Gallium-PSMA-PET compared to conventional imaging in lymph node staging of 130 consecutive patients with intermediate to high-risk prostate cancer. *J Urol* 2015; **195**: 1436–1443.
35 Hövels AM, Heesakkers RA, Adang EM, Jager GJ, Strum S, Hoogeveen YL *et al.* The diagnostic accuracy of CT and MRI in the staging of pelvic lymph nodes in patients with prostate cancer: a meta-analysis. *Clin Radiol* 2008; **63**: 387–395.
36 Derlin T, Eiber M, Schwaiger M, Bengel FM. Re: Lars Budäus, Sami-Ramzi Leyh-Bannurah, Georg Salomon *et al*. Initial experience of 68Ga-PSMA PET/CT in high-risk prostate cancer patients prior to radical prostatectomy. *Eur Urol* 2015 (e-pub ahead of print 8 August 2015; http://dx.doi.org/10.1016/j.eururo.2015.06.010).
37 Budäus L, Leyh-Bannurah SR, Steuber T. Reply to Thorsten Derlin, Matthias Eiber, Markus Schwaiger, and Frank M. Bengel's letter to the editor re: Lars Budäus, Sami-Ramzi Leyh-Bannurah, Georg Salomon *et al.* Initial experience of ^{68}Ga-PSMA PET/CT in high-risk prostate cancer patients prior to radical prostatectomy. *Eur Urol* 2015 (e-pub ahead of print 12 August 2015; http://dx.doi.org/10.1016/j.eururo.2015.06.010).
38 Maurer T, Weirich G, Schottelius M, Weineisen M, Frisch B, Okur A *et al.* Prostate-specific membrane antigen-radioguided surgery for metastatic lymph nodes in prostate cancer. *Eur Urol* 2015; **68**: 530–534.
39 Evans MJ, Smith-Jones PM, Wongvipat J, Navarro V, Kim S, Bander NH *et al.* Noninvasive measurement of androgen receptor signaling with a positron-emitting radiopharmaceutical that targets prostate-specific membrane antigen. *Proc Natl Acad Sci USA* 2011; **108**: 9578–9582.
40 Horwitz EM, Bae K, Hanks GE, Porter A, Grignon DJ, Brereton HD *et al.* Ten-year follow-up of radiation therapy oncology group 92-02: a phase III trial of the duration of elective androgen deprivation in locally advanced prostate cancer. *J Clin Oncol* 2008; **26**: 2497–2504.
41 Widmark A, Klepp O, Solberg A, Damber JE, Angelsen A, Fransson P *et al.* Endocrine treatment, with or without radiotherapy, in locally advanced prostate cancer (SPCG-7/SFUO-3): an open randomised phase III trial. *Lancet* 2009; **373**: 301–308.
42 Bolla M, Van Tienhoven G, Warde P, Dubois JB, Mirimanoff RO, Storme G *et al.* External irradiation with or without long-term androgen suppression for prostate cancer with high metastatic risk: 10-year results of an EORTC randomised study. *Lancet Oncol* 2010; **11**: 1066–1073.
43 Mason MD, Parulekar WR, Sydes MR, Brundage M, Kirkbride P, Gospodarowicz M *et al.* Final report of the intergroup randomized study of combined androgen-deprivation therapy plus radiotherapy versus androgen-deprivation alone in locally advanced prostate cancer. *J Clin Oncol* 2015; **33**: 2143–2150.
44 Polkingham WR, Parker JS, Lee MX, Kass EM, Spratt DE, Iaquinta PJ *et al.* Androgen receptor signaling regulates DNA repair in prostate cancers. *Cancer Discov* 2013; **3**: 1245–1253.
45 Goodwin JF, Schiewer MJ, Dean JL, Schrecengost RS, de Leeuw R, Han S *et al.* A hormone-DNA repair circuit governs the response to genotoxic insult. *Cancer Discov* 2013; **3**: 1254–1271.
46 Spratt DE, Evans MJ, Davis BJ, Doran MG, Lee MX, Shah N *et al.* Androgen receptor upregulation mediates radioresistance after ionizing radiation. *Cancer Res* 2015; **75**: 4688–4696.
47 Zelefsky MJ, Lyass O, Fuks Z, Wolfe T, Burman C, Ling CC *et al.* Predictors of improved outcome for patients with localized prostate cancer treated with neoadjuvant androgen ablation therapy and three-dimensional conformal radiotherapy. *J Clin Oncol* 1998; **16**: 3380–3385.
48 Ludgate CM, Bishop DC, Pai H, Eldridge B, Lim J, Berthelet E *et al.* Neoadjuvant hormone therapy and external-beam radiation for localized high-risk prostate cancer: the importance of PSA nadir before radiation. *Int J Radiat Oncol Biol Phys* 2005; **62**: 1309–1315.
49 Heymann JJ, Benson MC, O'Toole KM, Malyszko B, Brody R, Vecchio D *et al.* Phase II study of neoadjuvant androgen deprivation followed by external-beam radiotherapy with 9 months of androgen deprivation for intermediate- to high-risk localized prostate cancer. *J Clin Oncol* 2007; **25**: 77–84.
50 Mitchell DM, McAleese J, Park RM, Stewart DP, Stranex S, Eakin RL *et al.* Failure to achieve a PSA level $<$ or $=$ 1 ng/mL after neoadjuvant LHRHa therapy predicts lower biochemical control rate and overall survival in localized prostate cancer treated with radiotherapy. *Int J Radiat Oncol Biol Phys* 2007; **69**: 1467–1471.
51 Alexander A, Crook J, Jones S, Malone S, Bowen J, Truong P *et al.* Is biochemical response more important than duration of neoadjuvant hormone therapy before radiotherapy for clinically localized prostate cancer? An analysis of the 3- versus 8-month randomized trial. *Int J Radiat Oncol Biol Phys* 2010; **76**: 23–30.
52 McGuire SE, Lee AK, Cerne JZ, Munsell MF, Levy LB, Kudchadker RJ *et al.* PSA response to neoadjuvant androgen deprivation therapy is a strong independent predictor of survival in high-risk prostate cancer in the dose-escalated radiation therapy era. *Int J Radiat Oncol Biol Phys* 2013; **85**: e39–e46.
53 Zelefsky MJ, Gomez DR, Polkinghorn WR, Pei X, Kollmeier M. Biochemical response to androgen deprivation therapy before external beam radiation therapy predicts long-term prostate cancer survival outcomes. *Int J Radiat Oncol Biol Phys* 2013; **86**: 529–533.
54 Scher HI, Fizazi K, Saad F, Taplin ME, Sternberg CN, Miller K *et al.* Increased survival with enzalutamide in prostate cancer after chemotherapy. *N Engl J Med* 2012; **367**: 1187–1197.
55 Cookson MS, Aus G, Burnett AL, Canby-Hagino ED, D-Aminco AV, Dmochowski RR *et al.* Variation in the definition of biochemical recurrence in patients treated for localized prostate cancer: the American Urological Association Prostate Guidelines for Localized Prostate Cancer Update Panel report and recommendations for a standard in the reporting of surgical outcomes. *J Urol* 2007; **177**: 540–545.
56 Roach M 3rd, Hanks G, Thames H Jr, Scheilhammer P, Shipley WU, Sokol GH *et al.* Defining biochemical failure following radiotherapy with or without hormonal therapy in men with clinically localized prostate cancer: recommendations of the RTOG-ASTRO Phoenix Consensus Conference. *Int J Radiat Oncol Biol Phys* 2006; **15**: 965–974.
57 Abramowitz MC, Li T, Buyyounouski MK, Ross E, Uzzo RG, Pollack A *et al.* The Phoenix definition of biochemical failure predicts for overall survival in patients with prostate cancer. *Cancer* 2008; **112**: 55–60.
58 Trock BJ, Han M, Freedland SJ, Humphreys EB, DeWeese TL, Partin AW *et al.* Prostate cancer-specific survival following salvage radiotherapy vs observation in men with biochemical recurrence after radical prostatectomy. *JAMA* 2008; **299**: 2760–2769.
59 Afshar-Oromieh A, Zechmann CM, Malcher A, Eder M, Eisenhut M, Linhart HG *et al.* Comparison of PET imaging with ^{68}Ga-labelled PSMA ligand and ^{18}F-choline-based PET/CT for the diagnosis of recurrent prostate cancer. *Eur J Nucl Med Mol Imaging* 2014; **41**: 11–20.
60 Morigi JJ, Stricker PD, van Leeuwen PJ, Tang R, Ho B, Nguyen Q *et al.* Prospective comparison of ^{18}F-fluoromethylcholine versus ^{68}Ga-PSMA PET/CT in prostate cancer patients who have rising PSA after curative treatment and are being considered for targeted therapy. *J Nucl Med* 2015; **56**: 1185–1190.
61 Deitlein M, Kobe C, Kuhnert G, Stockter S, Fischer T, Schomäcker K *et al.* Comparison of [^{18}F]DCFPyL and [^{68}Ga]Ga-PSMA-HBED-CC for PSMA-PET in patients with relapsed prostate cancer. *Mol Imaging Biol* 2015; **17**: 575–584.
62 Giesel FL, Fiedler H, Stefanova M, Sterzing F, Rius M, Kopka K *et al.* PSMA PET/CT with Glu-urea-Lys-(Ahx)-[^{68}Ga(HBED-CC)] versus 3D CT volumetric lymph node assessment in recurrent prostate cancer. *Eur J Nucl Med Mol Imaging* 2015; **42**: 1794–1800.
63 Rowe SP, Macura KJ, Ciarallo A, Mena E, Blackford A, Nadal R *et al.* Comparison of Prostate-Specific Membrane Antigen-based ^{18}F-DCFBC PET/CT to conventional imaging modalities for detection of hormone-naïve and castration-resistant metastatic prostate cancer. *J Nucl Med* 2016; **57**: 46–53.
64 Rowe SP, Mana-ay M, Javadi MS, Szabo Z, Leal JP, Pomper MG *et al.* PSMA-based detection of prostate cancer bone lesions with 18F-DCFPyL PET/CT: a sensitive alternative to 99mTc-MDP bone scan and Na18F PET/CT? *Clin Genitourin Cancer* 2016; **14**: e115–e118.
65 Bander NH, Milowsky MI, Nanus DM, Kostakoglu L, Vallabhajosula S, Goldsmith SJ. Phase I trial of ^{177}lutetium-labeled J591, a monoclonal antibody to prostate-specific membrane antigen, in patients with androgen-independent prostate cancer. *J Clin Oncol* 2005; **23**: 4591–4601.
66 Tagawa ST, Milowsky MI, Morris M, Vallabhajosula S, Christos P, Akhtar NH *et al.* Phase II study of lutetium-177-labeled anti-prostate-specific membrane antigen monoclonal J591 for metastatic castration-resistant prostate cancer. *Clin Cancer Res* 2013; **19**: 5182–5191.
67 Weineisen M, Schottelius M, Simecek J, Baum RP, Yildiz A, Beykan S *et al.* ^{68}Ga- and ^{177}Lu-labeled PSMA I&T: optimization of a PSMA-targeted theranostic concept and first proof-of-concept human studies. *J Nucl Med* 2015; **56**: 1169–1176.
68 Ahmadzadehfar H, Rahbar K, Kürpig S, Bögemann M, Claesener M, Eppard E *et al.* Early side effects and first results of radioligand therapy with ^{177}Lu-DKFZ-617 PSMA of castrate-resistant metastatic prostate cancer: a two-centre study. *EJNMMI Res* 2015; **5**: 114.
69 Hellman S, Weichselbaum RR. Oligometastases. *J Clin Oncol* 1995; **13**: 8–10.
70 Reyes DK, Pienta KJ. The biology and treatment of oligometastatic cancer. *Oncotarget* 2015; **6**: 8491–8524.
71 Miyahira AK, Lang JM, Den RB, Garraway IP, Lotan TL, Ross AE *et al.* Multidisciplinary intervention of early, lethal metastatic prostate cancer : report from the 2015 Coffey-Holden Prostate Cancer Academy Meeting. *Prostate* 2015; **76**: 125–139.
72 Schiavina R, Ceci F, Romagnoli D, Uprimny C, Brunocilla E, Borghesi M *et al.* ^{68}Ga-PSMA-PET/CT-guided salvage retroperitoneal lymph node dissection for disease relapse after radical prostatectomy for prostate cancer. *Clin Gentiourin Cancer* 2015; **13**: e415–e417.
73 Hijazi S, Meller B, Leitsmann C, Strauss A, Meller J, Ritter CO *et al.* Pelvic lymph node dissection for nodal oligometastatic prostate cancer detected by ^{68}Ga-PSMA-positron emission tomography/computed tomography. *Prostate* 2015; **75**: 1934–1940.

© 2016 Macmillan Publishers Limited
MIM Software Inc. v. Progenics Pharmaceuticals, Inc.
IPR2025-00630
Progenics EX2020