The Essential Physics of Medical Imaging

THIRD EDITION

JERROLD T. BUSHBERG, PhD
Clinical Professor of Radiology and Radiation Oncology
University of California, Davis
Sacramento, California

J. ANTHONY SEIBERT, PhD
Professor of Radiology
University of California, Davis
Sacramento, California

EDWIN M. LEIDHOLDT JR, PhD
Clinical Associate Professor of Radiology
University of California, Davis
Sacramento, California

JOHN M. BOONE, PhD
Professor of Radiology and Biomedical Engineering
University of California, Davis
Sacramento, California

Wolters Kluwer Health | Lippincott Williams & Wilkins
Philadelphia • Baltimore • New York • London
Buenos Aires • Hong Kong • Sydney • Tokyo

MIM Software Inc. v. Progenics Pharmaceuticals, Inc.
IPR2025-00725
Progenics EX2027

Executive Editor: Charles W. Mitchell
Product Manager: Ryan Shaw
Vendor Manager: Alicia Jackson
Senior Manufacturing Manager: Benjamin Rivera
Senior Marketing Manager: Angela Panetta
Design Coordinator: Stephen Druding
Production Service: SPi Global

Copyright © 2012 by LIPPINCOTT WILLIAMS & WILKINS, a WOLTERS KLUWER business
Two Commerce Square
2001 Market Street
Philadelphia, PA 19103 USA
LWW.com

2nd edition © 2002 by LIPPINCOTT WILLIAMS & WILKINS
1st edition © 1994 by LIPPINCOTT WILLIAMS & WILKINS

All rights reserved. This book is protected by copyright. No part of this book may be reproduced in any form by any means, including photocopying, or utilized by any information storage and retrieval system without written permission from the copyright owner, except for brief quotations embodied in critical articles and reviews. Materials appearing in this book prepared by individuals as part of their official duties as U.S. government employees are not covered by the above-mentioned copyright.

Printed in China

Library of Congress Cataloging-in-Publication Data
Bushberg, Jerrold T.
The essential physics of medical imaging / Jerrold T. Bushberg. — 3rd ed.
p. ; cm.
Includes bibliographical references and index.
ISBN 978-0-7817-8057-5
1. Diagnostic imaging. 2. Medical physics. I. Title.
[DNLM: 1. Diagnostic Imaging—methods. WN 200]
RC78.7.D53E87 2011
616.07'54—dc22

2011004310

Care has been taken to confirm the accuracy of the information presented and to describe generally accepted practices. However, the authors, editors, and publisher are not responsible for errors or omissions or for any consequences from application of the information in this book and make no warranty, expressed or implied, with respect to the currency, completeness, or accuracy of the contents of the publication. Application of the information in a particular situation remains the professional responsibility of the practitioner.

The authors, editors, and publisher have exerted every effort to ensure that drug selection and dosage set forth in this text are in accordance with current recommendations and practice at the time of publication. However, in view of ongoing research, changes in government regulations, and the constant flow of information relating to drug therapy and drug reactions, the reader is urged to check the package insert for each drug for any change in indications and dosage and for added warnings and precautions. This is particularly important when the recommended agent is a new or infrequently employed drug.

Some drugs and medical devices presented in the publication have Food and Drug Administration (FDA) clearance for limited use in restricted research settings. It is the responsibility of the health care provider to ascertain the FDA status of each drug or device planned for use in their clinical practice.

To purchase additional copies of this book, call our customer service department at (800) 638-3030 or fax orders to (301) 223-2320. International customers should call (301) 223-2300.

Visit Lippincott Williams & Wilkins on the Internet: at LWW.com. Lippincott Williams & Wilkins customer service representatives are available from 8:30 am to 6 pm, EST.

10 9 8 7 6 5 4 3 2 1

MIM Software Inc. v. Progenics Pharmaceuticals, Inc.
IPR2025-00725
Progenics EX2027

CHAPTER 1

Introduction to Medical Imaging

Medical imaging of the human body requires some form of energy. In the medical imaging techniques used in radiology, the energy used to produce the image must be capable of penetrating tissues. Visible light, which has limited ability to penetrate tissues at depth, is used mostly outside of the radiology department for medical imaging. Visible light images are used in dermatology (skin photography), gastroenterology and obstetrics (endoscopy), and pathology (light microscopy). Of course, all disciplines in medicine use direct visual observation, which also utilizes visible light. In diagnostic radiology, the electromagnetic spectrum outside the visible light region is used for medical imaging, including x-rays in mammography and computed tomography (CT); radiofrequency (RF) in magnetic resonance imaging (MRI), and gamma rays in nuclear medicine. Mechanical energy, in the form of high-frequency sound waves, is used in ultrasound imaging.

With the exception of nuclear medicine, all medical imaging requires that the energy used to penetrate the body's tissues also interacts with those tissues. If energy were to pass through the body and not experience some type of interaction (e.g., absorption or scattering), then the detected energy would not contain any useful information regarding the internal anatomy, and thus it would not be possible to construct an image of the anatomy using that information. In nuclear medicine imaging, radioactive substances are injected or ingested, and it is the physiological *interactions* of the agent that give rise to the information in the images.

While medical images can have an aesthetic appearance, the diagnostic utility of a medical image relates both to the technical quality of the image and the conditions of its acquisition. Consequently, the assessment of image quality in medical imaging involves very little artistic appraisal and a great deal of technical evaluation. In most cases, the image quality that is obtained from medical imaging devices involves compromise—better x-ray images can be made when the radiation dose to the patient is high, better magnetic resonance images can be made when the image acquisition time is long, and better ultrasound images result when the ultrasound power levels are large. Of course, patient safety and comfort must be considered when acquiring medical images; thus, excessive patient dose in the pursuit of a perfect image is not acceptable. Rather, the power and energy used to make medical images require a balance between patient safety and image quality.

1.1 The Modalities

Different types of medical images can be made by varying the types of energies and the acquisition technology used. The different modes of making images are referred to as *modalities*. Each modality has its own applications in medicine.

MIM Software Inc. v. Progenics Pharmaceuticals, Inc.
IPR2025-00725
Progenics EX2027

Radiography

Radiography was the first medical imaging technology, made possible when the physicist Wilhelm Roentgen discovered x-rays on November 8, 1895. Roentgen also made the first radiographic images of human anatomy (Fig. 1-1). Radiography (also called roentgenography) defined the field of radiology and gave rise to radiologists, physicians who specialize in the interpretation of medical images. Radiography is performed with an x-ray source on one side of the patient and a (typically flat) x-ray detector on the other side. A short-duration (typically less than ½ second) pulse of x-rays is emitted by the x-ray tube, a large fraction of the x-rays interact in the patient, and some of the x-rays pass through the patient and reach the detector, where a radiographic image is formed. The homogeneous distribution of x-rays that enters the patient is modified by the degree to which the x-rays are removed from the beam (i.e., attenuated) by scattering and absorption within the tissues. The attenuation properties of tissues such as bone, soft tissue, and air inside the patient are very different, resulting in a heterogeneous distribution of x-rays that emerges from the patient. The radiographic image is a picture of this x-ray distribution. The detector used in radiography can be photographic film (e.g., screen-film radiography) or an electronic detector system (i.e., digital radiography).

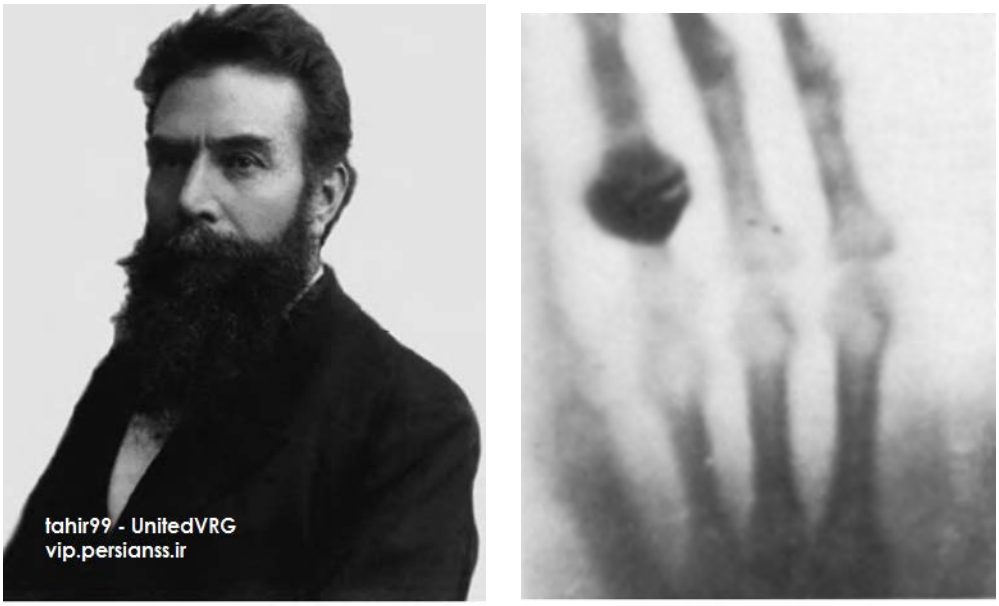

A B

■ **FIGURE 1-1** Wilhelm Conrad Roentgen (1845–1923) in 1896 (**A**). Roentgen received the first Nobel Prize in Physics in 1901 for his discovery of x-rays on November 8, 1895. The beginning of diagnostic radiology is represented by this famous radiographic image, made by Roentgen on December 22, 1895 of his wife's hand (**B**). The bones of her hand as well as two rings on her finger are clearly visible. Within a few months, Roentgen had determined the basic physical properties of x-rays. Roentgen published his findings in a preliminary report entitled "On a New Kind of Rays" on December 28, 1895 in the Proceedings of the Physico-Medical Society of Wurzburg. An English translation was published in the journal Nature on January 23, 1896. Almost simultaneously, as word of the discovery spread around the world, medical applications of this "new kind of ray" rapidly made radiological imaging an essential component of medical care. In keeping with mathematical conventions, Roentgen assigned the letter "x" to represent the unknown nature of the ray and thus the term "x-rays" was born.

MIM Software Inc. v. Progenics Pharmaceuticals, Inc.
IPR2025-00725
Progenics EX2027

Transmission imaging refers to imaging in which the energy source is outside the body on one side, and the energy passes through the body and is detected on the other side of the body. Radiography is a transmission imaging modality. *Projection imaging* refers to the case when each point on the image corresponds to information along a straight-line trajectory through the patient. Radiography is also a projection imaging modality. Radiographic images are useful for a very wide range of medical indications, including the diagnosis of broken bones, lung cancer, cardiovascular disorders, etc. (Fig. 1-2).

Fluoroscopy

Fluoroscopy refers to the continuous acquisition of a sequence of x-ray images over time, essentially a real-time x-ray movie of the patient. It is a transmission projection imaging modality, and is, in essence, just real-time radiography. Fluoroscopic systems use x-ray detector systems capable of producing images in rapid temporal sequence. Fluoroscopy is used for positioning catheters in arteries, visualizing contrast agents in the GI tract, and for other medical applications such as invasive therapeutic procedures where real-time image feedback is necessary. It is also used to make x-ray movies of anatomic motion, such as of the heart or the esophagus.

Mammography

Mammography is radiography of the breast, and is thus a transmission projection type of imaging. To accentuate contrast in the breast, mammography makes use of

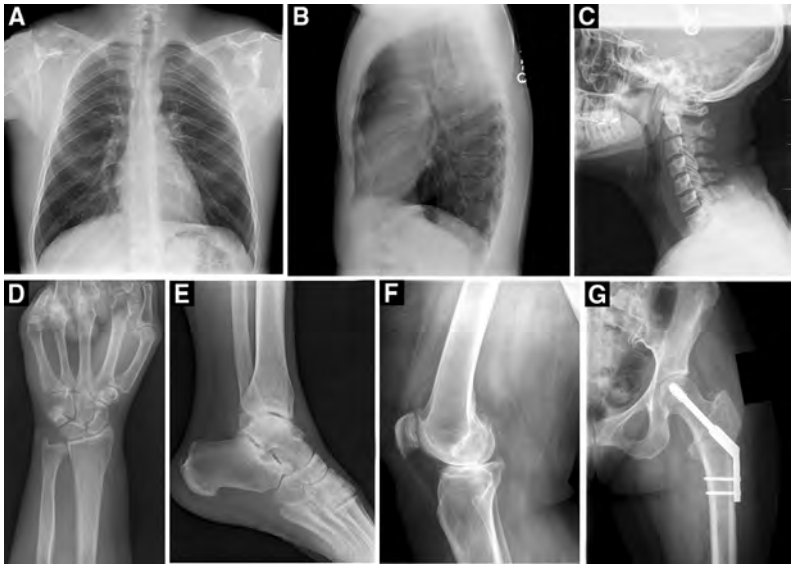

■ **FIGURE 1-2** Chest radiography is the most common imaging procedure in diagnostic radiology, often acquired as orthogonal posterior-anterior (**A**) and lateral (**B**) projections to provide information regarding depth and position of the anatomy. High-energy x-rays are used to reduce the conspicuity of the ribs and other bones to permit better visualization of air spaces and soft tissue structures in the thorax. The image is a map of the attenuation of the x-rays: dark areas (high film optical density) correspond to low attenuation, and bright areas (low film optical density) correspond to high attenuation. **C.** Lateral cervical spine radiographs are commonly performed to assess suspected neck injury after trauma, and extremity images of the (**D**) wrist, (**E**) ankle, and (**F**) knee provide low-dose, cost-effective diagnostic information. **G.** Metal objects, such as this orthopedic implant designed for fixation of certain types of femoral fractures, are well seen on radiographs.

MIM Software Inc. v. Progenics Pharmaceuticals, Inc.
IPR2025-00725
Progenics EX2027

much lower x-ray energies than general purpose radiography, and consequently the x-ray and detector systems are designed specifically for breast imaging. Mammography is used to screen asymptomatic women for breast cancer (screening mammography) and is also used to aid in the diagnosis of women with breast symptoms such as the presence of a lump (diagnostic mammography) (Fig. 1-3A). Digital mammography has eclipsed the use of screen-film mammography in the United States, and the use of computer-aided detection is widespread in digital mammography. Some digital mammography systems are now capable of tomosynthesis, whereby the x-ray tube (and in some cases the detector) moves in an arc from approximately 7 to 40 degrees around the breast. This limited angle tomographic method leads to the reconstruction of tomosynthesis images (Fig. 1-3B), which are parallel to the plane of the detector, and can reduce the superimposition of anatomy above and below the in-focus plane.

Computed Tomography

Computed tomography (CT) became clinically available in the early 1970s, and is the first medical imaging modality made possible by the computer. CT images are produced by passing x-rays through the body at a large number of angles, by rotating the x-ray tube around the body. A detector array, opposite the x-ray source, collects the transmission projection data. The numerous data points collected in this manner

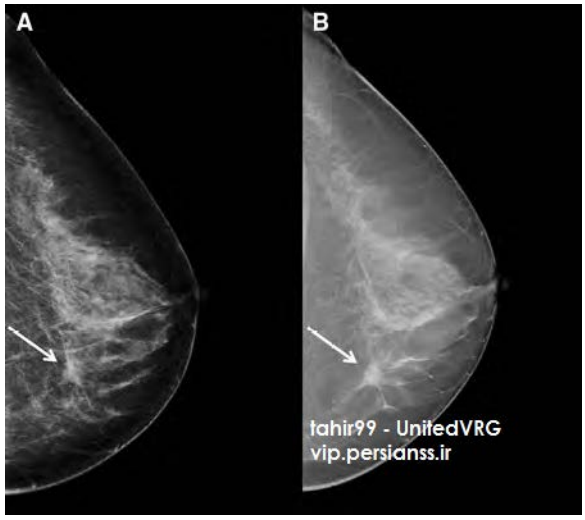

■ **FIGURE 1-3** Mammography is a specialized x-ray projection imaging technique useful for detecting breast anomalies such as masses and calcifications. Dedicated mammography equipment uses low x-ray energies, K-edge filters, compression, screen/film or digital detectors, antiscatter grids and automatic exposure control to produce breast images of high quality and low x-ray dose. The digital mammogram in (**A**) shows glandular and fatty tissues, the skin line of the breast, and a possibly cancerous mass (*arrow*). In projection mammography, superposition of tissues at different depths can mask the features of malignancy or cause artifacts that mimic tumors. The digital tomosynthesis image in (**B**) shows a mid-depth synthesized tomogram. By reducing overlying and underlying anatomy with the tomosynthesis, the suspected mass in the breast is clearly depicted with a spiculated appearance, indicative of cancer. X-ray mammography currently is the procedure of choice for screening and early detection of breast cancer because of high sensitivity, excellent benefit-to-risk ratio, and low cost.

MIM Software Inc. v. Progenics Pharmaceuticals, Inc.
IPR2025-00725
Progenics EX2027

are synthesized by a computer into *tomographic* images of the patient. The term tomography refers to a picture (*graph*) of a slice (*tomo*). CT is a transmission technique that results in images of individual slabs of tissue in the patient. The advantage of CT over radiography is its ability to display three-dimensional (3D) slices of the anatomy of interest, eliminating the superposition of anatomical structures and thereby presenting an unobstructed view of detailed anatomy to the physician.

CT changed the practice of medicine by substantially reducing the need for exploratory surgery. Modern CT scanners can acquire 0.50- to 0.62-mm-thick tomographic images along a 50-cm length of the patient (i.e., 800 images) in 5 seconds, and reveal the presence of cancer, ruptured disks, subdural hematomas, aneurysms, and many other pathologies (Fig. 1-4). The CT volume data set is essentially isotropic, which has led to the increased use of coronal and sagittal CT images, in addition to traditional axial images in CT. There are a number of different acquisition modes available on modern CT scanners, including dual-energy imaging, organ perfusion imaging, and prospectively gated cardiac CT. While CT is usually used for anatomic imaging, the use of iodinated contrast injected intravenously allows the functional assessment of various organs as well.

Because of the speed of acquisition, the high-quality diagnostic images, and the widespread availability of CT in the United States, CT has replaced a number of imaging procedures that were previously performed radiographically. This trend continues. However, the wide-scale incorporation of CT into diagnostic medicine has led to more than 60 million CT scans being performed annually in the United States. This large number has led to an increase in the radiation burden in the United States, such that now about half of medical radiation is due to CT. Radiation levels from medical imaging are now equivalent to background radiation levels in the United States, (NCRP 2009).

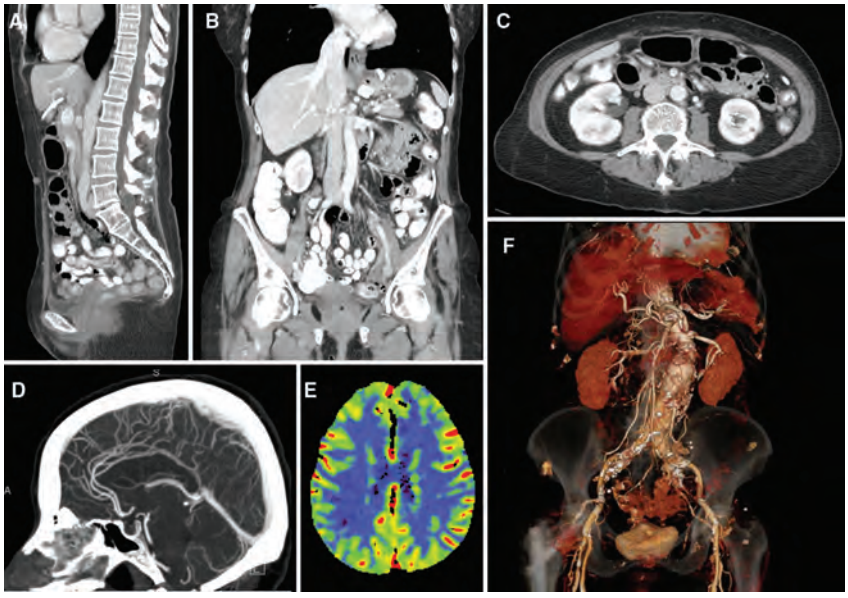

■ **FIGURE 1-4** CT reveals superb anatomical detail, as seen in (**A**) sagittal, (**B**) coronal, and (**C**) axial images from an abdomen-pelvis CT scan. With the injection of iodinated contrast material, CT angiography (CTA) can be performed, here (**D**) showing CTA of the head. Analysis of a sequence of temporal images allows assessment of perfusion; (**E**) demonstrates a color coded map corresponding to blood volume in this patient undergoing evaluation for a suspected cerebrovascular accident ("stroke"). **F.** Image processing can produce pseudocolored 3D representations of the anatomy from the CT data.

MIM Software Inc. v. Progenics Pharmaceuticals, Inc.
IPR2025-00725
Progenics EX2027

Magnetic Resonance Imaging

Magnetic resonance imaging (MRI) scanners use magnetic fields that are about 10,000 to 60,000 times stronger than the earth's magnetic field. Most MRI utilizes the nuclear magnetic resonance properties of the proton—that is, the nucleus of the hydrogen atom, which is very abundant in biological tissues (each cubic millimeter of tissue contains about 10^{18} protons). The proton has a magnetic moment and, when placed in a 1.5 T magnetic field, the proton precesses (wobbles) about its axis and preferentially absorbs radio wave energy at the resonance frequency of about 64 million cycles per second (megahertz—MHz).

In MRI, the patient is placed in the magnetic field, and a pulse of radio waves is generated by antennas ("coils") positioned around the patient. The protons in the patient absorb the radio waves, and subsequently reemit this radio wave energy after a period of time that depends upon the spatially dependent magnetic properties of the tissue. The radio waves emitted by the protons in the patient are detected by the antennas that surround the patient. By slightly changing the strength of the magnetic field as a function of position in the patient using magnetic field *gradients*, the proton resonance frequency varies as a function of position, since frequency is proportional to magnetic field strength. The MRI system uses the frequency and phase of the returning radio waves to determine the position of each signal from the patient. One frequently used mode of operation of MRI systems is referred to as *spin echo* imaging.

MRI produces a set of tomographic images depicting slices through the patient, in which each point in an image depends on the micromagnetic properties of the tissue corresponding to that point. Because different types of tissue such as fat, white and gray matter in the brain, cerebral spinal fluid, and cancer all have different local magnetic properties, images made using MRI demonstrate high sensitivity to anatomical variations and therefore are high in contrast. MRI has demonstrated exceptional utility in neurological imaging (head and spine) and for musculoskeletal applications such as imaging the knee after athletic injury (Fig. 1-5A–D).

MRI is a tomographic imaging modality, and competes with x-ray CT in many clinical applications. The acquisition of the highest quality images using MRI requires tens of minutes, whereas a CT scan of the entire head requires seconds. Thus, for patients where motion cannot be controlled (pediatric patients) or in anatomical areas where involuntary patient motion occurs (the beating heart and churning intestines), CT is often used instead of MRI. Also, because of the large magnetic field used in MRI, only specialized electronic monitoring equipment can be used while the patient is being scanned. Thus, for most trauma, CT is preferred. MRI should not be performed on patients who have cardiac pacemakers or internal ferromagnetic objects such as surgical aneurysm clips, metal plate or rod implants, or metal shards near critical anatomy such as the eye.

Despite some indications for which MRI should not be used, fast image acquisition techniques using special coils have made it possible to produce images in much shorter periods of time, and this has opened up the potential of using MRI for imaging of the motion-prone thorax and abdomen (Fig. 1-5E). MRI scanners can also detect the presence of motion, which is useful for monitoring blood flow through arteries (MR *angiography*—Figure 1-5F), as well as blood flow in the brain (*functional* MR), which leads to the ability to measure brain function correlated to a task (e.g., finger tapping, response to various stimuli, etc.).

An area of MR data collection that allows for analysis of metabolic products in the tissue is MR *spectroscopy*, whereby a single voxel or multiple voxels may be analyzed

MIM Software Inc. v. Progenics Pharmaceuticals, Inc.
IPR2025-00725
Progenics EX2027

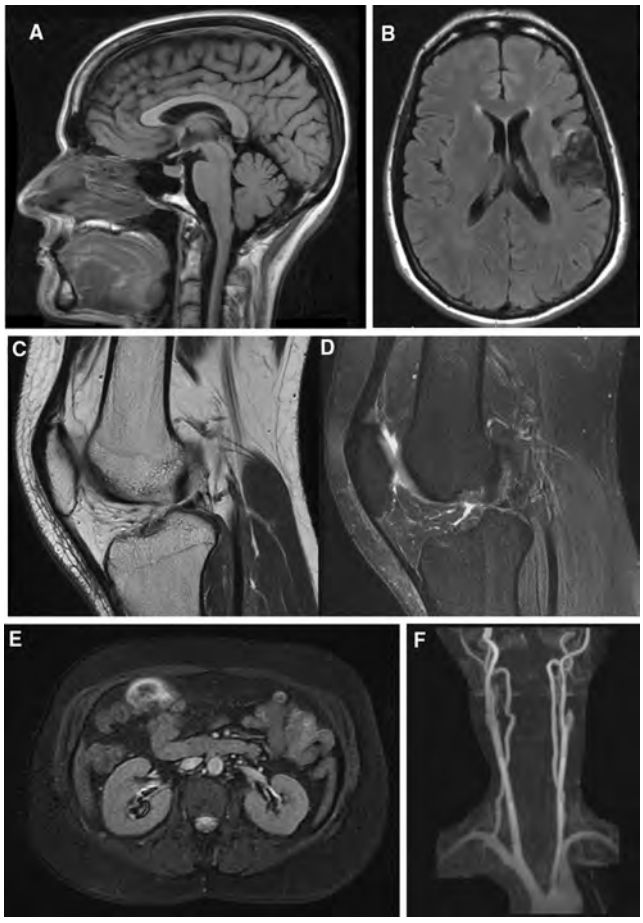

■ **FIGURE 1-5** MRI provides excellent and selectable tissue contrast, determined by acquisition pulse sequences and data acquisition methods. Tomographic images can be acquired and displayed in any plane including conventional axial, sagittal and coronal planes. (**A**) Sagittal T1-weighted contrast image of the brain; (**B**) axial fluid-attenuated inversion recovery (FLAIR) image showing an area of brain infarct; sagittal image of the knee, with (**C**) T1-weighted contrast and (**D**) T1-weighted contrast with "fat saturation" (fat signal is selectively reduced) to visualize structures and signals otherwise overwhelmed by the large fat signal; (**E**) maximum intensity projection generated from the axial tomographic images of a time-of-flight MR angiogram; (**F**) gadolinium contrast-enhanced abdominal image, acquired with a fast imaging employing steady-state acquisition sequence, which allows very short acquisition times to provide high signal-to-noise ratio of fluid-filled structures and reduce the effects of patient motion.

using specialized MRI sequences to evaluate the biochemical composition of tissues in a precisely defined volume. The spectroscopic signal can act as a signature for tumors and other maladies.

Ultrasound Imaging

When a book is dropped on a table, the impact causes pressure waves (called sound) to propagate through the air such that they can be heard at a distance. Mechanical energy in the form of high-frequency ("ultra") sound can be used to generate images of the anatomy of a patient. A short-duration pulse of sound is generated by an

MIM Software Inc. v. Progenics Pharmaceuticals, Inc.
IPR2025-00725
Progenics EX2027

ultrasound *transducer* that is in direct physical contact with the tissues being imaged. The sound waves travel into the tissue, and are reflected by internal structures in the body, creating echoes. The reflected sound waves then reach the transducer, which records the returning sound. This mode of operation of an ultrasound device is called *pulse echo* imaging. The sound beam is swept over a slice of the patient line by line using a linear array multielement transducer to produce a rectangular scanned area, or through incremental angles with a phased array multielement transducer to produce a sector scanned area. The echo amplitudes from each line of ultrasound are recorded and used to compute a brightness mode image with grayscale-encoded acoustic signals representing a tomographic slice of the tissues of interest.

Ultrasound is reflected strongly by interfaces, such as the surfaces and internal structures of abdominal organs. Because ultrasound is thought to be less harmful than ionizing radiation to a growing fetus, ultrasound imaging is preferred in obstetrical patients (Fig. 1-6A,B). An interface between tissue and air is highly echoic, and thus, very little sound can penetrate from tissue into an air-filled cavity. Therefore, ultrasound imaging has less utility in the thorax where the air in the lungs presents a

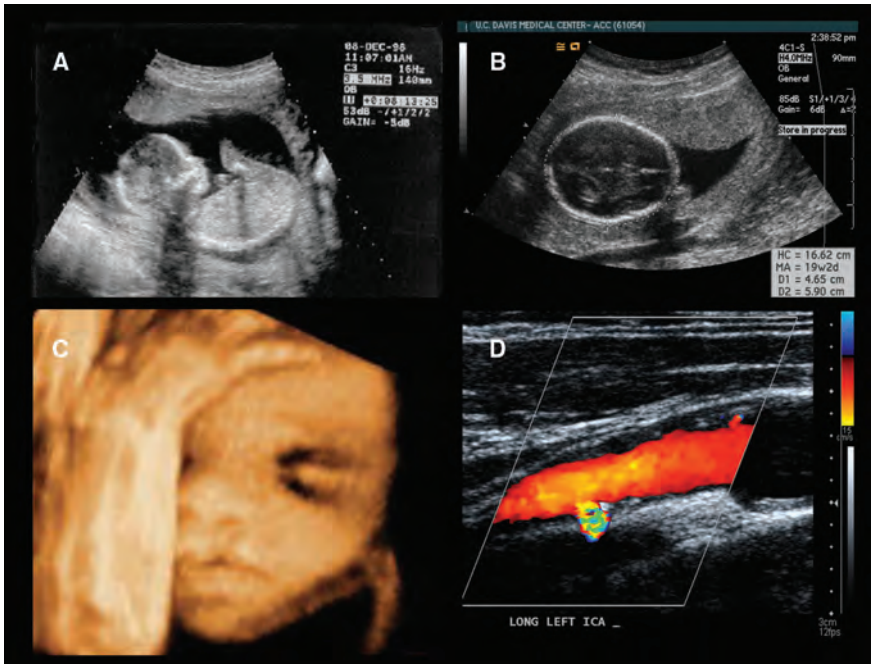

■ **FIGURE 1-6** The ultrasound image is a map of the echoes from tissue boundaries of high-frequency sound wave pulses. **A.** A phased-array transducer operating at 3.5 MHz produced the normal obstetrical ultrasound image (sagittal profile) of Jennifer Lauren Bushberg at 5½ months before her "first birthday." Variations in the image brightness are due to acoustic characteristics of the tissues; for example, the fluid in the placenta is echo free, whereas most fetal tissues are echogenic and produce larger returned signals. Acoustic shadowing is caused by highly attenuating or scattering tissues, such as bone or air, producing the corresponding low intensity streaks distal to the transducer. **B.** Distance measurements (e.g., fetal head diameter assessment for age estimation) are part of the diagnostic evaluation of a cross-sectional brain ultrasound image of a fetus. **C.** From a stack of tomographic images acquired with known geometry and image locations, 3D image rendering of the acoustic image data can show anatomic findings, such as a cleft palate of the fetus. **D.** Vascular assessment using Doppler color-flow imaging can be performed by many ultrasound systems. A color-flow image of the internal carotid artery superimposed on the grayscale image demonstrates an aneurysm in the left internal carotid artery of this patient.

MIM Software Inc. v. Progenics Pharmaceuticals, Inc.
IPR2025-00725
Progenics EX2027

barrier that the sound beam cannot penetrate. Similarly, an interface between tissue and bone is also highly echoic, thus making brain imaging, for example, impractical in most cases. Because each ultrasound image represents a tomographic slice, multiple images spaced a known distance apart represent a volume of tissue, and with specialized algorithms, anatomy can be reconstructed with volume rendering methods as shown in Figure 1-6C.

Doppler Ultrasound

Doppler ultrasound makes use of a phenomenon familiar to train enthusiasts. For the observer standing beside railroad tracks as a rapidly moving train goes by blowing its whistle, the pitch of the whistle is higher as the train approaches and becomes lower as the train passes by the observer and speeds off into the distance. The change in the pitch of the whistle, which is an apparent change in the frequency of the sound, is a result of the Doppler effect. The same phenomenon occurs at ultrasound frequencies, and the change in frequency (the Doppler shift) is used to measure the motion of blood. Both the speed and direction of blood flow can be measured, and within a subarea of the grayscale image, a color flow display typically shows blood flow in one direction as red, and in the other direction as blue. In Figure 1-6D, a color-flow map reveals arterial flow of the left internal carotid artery superimposed upon the grayscale image; the small, multicolored nub on the vessel demonstrates complex flow patterns of an ulcerated aneurysm.

Nuclear Medicine Imaging

Nuclear medicine is the branch of radiology in which a chemical or other substance containing a radioactive isotope is given to the patient orally, by injection or by inhalation. Once the material has distributed itself according to the physiological status of the patient, a radiation detector is used to make projection images from the x- and/or gamma rays emitted during radioactive decay of the agent. Nuclear medicine produces emission images (as opposed to transmission images), because the radioisotopes emit their energy from inside the patient.

Nuclear medicine imaging is a form of functional imaging. Rather than yielding information about just the anatomy of the patient, nuclear medicine images provide information regarding the physiological conditions in the patient. For example, thallium tends to concentrate in normal heart muscle, but in areas that are infarcted or are ischemic, thallium does not concentrate as well. These areas appear as "cold spots" on a nuclear medicine image, and are indicative of the functional status of the heart. Thyroid tissue has a great affinity for iodine, and by administering radioactive iodine (or its analogues), the thyroid can be imaged. If thyroid cancer has metastasized in the patient, then "hot spots" indicating their location may be present on the nuclear medicine images. Thus functional imaging is the forte of nuclear medicine.

Nuclear Medicine Planar Imaging

Nuclear medicine planar images are projection images, since each point on the image is representative of the radioisotope activity along a line projected through the patient. Planar nuclear images are essentially 2D maps of the 3D radioisotope distribution, and are helpful in the evaluation of a large number of disorders (Fig. 1-7).

MIM Software Inc. v. Progenics Pharmaceuticals, Inc.
IPR2025-00725
Progenics EX2027

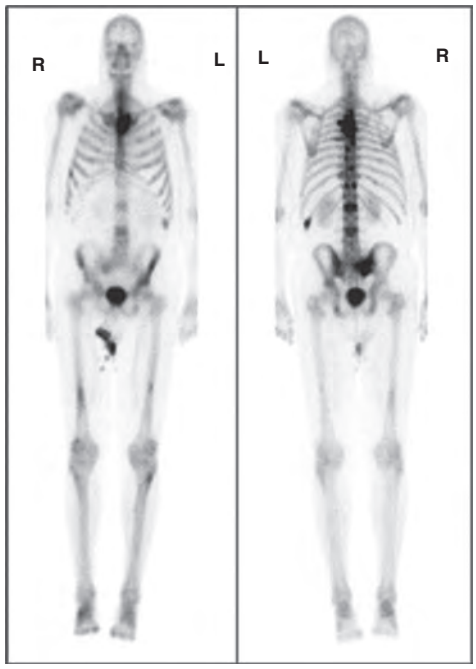

■ **FIGURE 1-7** Anterior and posterior whole-body bone scan images of a 64-year-old male with prostate cancer. This patient was injected with 925 MBq (25 mCi) of ^{99m}Tc methylenediphosphonate (MDP) and was imaged 3 hours later with a dual-head scintillation camera. The images demonstrate multiple metastatic lesions. Lesions are readily seen in ribs, sternum, spine, pelvis, femurs and left tibia. Planar imaging is still the standard for many nuclear medicine examinations (e.g., whole-body bone scans and hepatobiliary thyroid, renal and pulmonary studies). (Image courtesy of DK Shelton.)

Single Photon Emission Computed Tomography

Single photon emission computed tomography (SPECT) is the tomographic counterpart of nuclear medicine planar imaging, just like CT is the tomographic counterpart of radiography. In SPECT, a nuclear camera records x- or gamma-ray emissions from the patient from a series of different angles around the patient. These projection data are used to reconstruct a series of tomographic emission images. SPECT images provide diagnostic functional information similar to nuclear planar examinations; however, their tomographic nature allows physicians to better understand the precise distribution of the radioactive agent, and to make a better assessment of the function of specific organs or tissues within the body (Fig. 1-8). The same radioactive isotopes are used in both planar nuclear imaging and SPECT.

Positron Emission Tomography

Positrons are positively charged electrons, and are emitted by some radioactive isotopes such as fluorine-18 and oxygen-15. These radioisotopes are incorporated into metabolically relevant compounds, such as ^{18}F-fluorodeoxyglucose (^{18}FDG), which localize in the body after administration. The decay of the isotope produces a positron, which rapidly undergoes a very unique interaction: the positron (e^+) combines with an electron (e^-) from the surrounding tissue, and the mass of both the e^+ and the e^- is converted by annihilation into pure energy, following Einstein's famous equation $E = mc^2$. The energy that is emitted is called *annihilation radiation*. Annihilation radiation production is similar to gamma ray emission, except that two photons are produced, and they are emitted simultaneously in almost exactly opposite directions, that is, 180 degrees from each other. A positron emission tomography (PET) scanner utilizes rings of detectors that surround the patient, and has special circuitry that is capable of identifying the photon pairs produced during

MIM Software Inc. v. Progenics Pharmaceuticals, Inc.
IPR2025-00725
Progenics EX2027

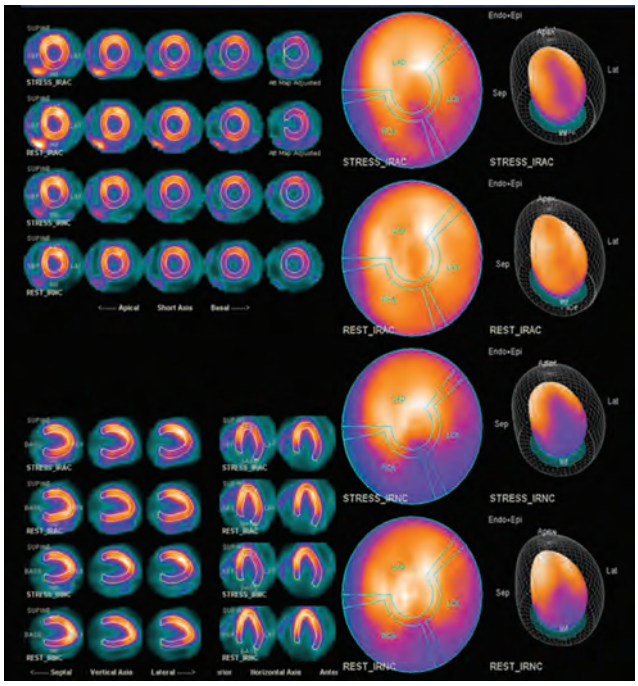

■ **FIGURE 1-8** Two-day stress-rest myocardial perfusion imaging with SPECT/CT was performed on an 89-year-old, obese male with a history of prior CABG, bradycardia, and syncope. This patient had pharmacological stress with regadenoson and was injected with 1.11 GBq (30 mCi) of ^{99m}Tc-tetrofosmin at peak stress. Stress imaging followed 30 minutes later, on a variable-angle two-headed SPECT camera. Image data were acquired over 180 degrees at 20 seconds per stop. The rest imaging was done 24 hours later with a 1.11 GBq (30 mCi) injection of ^{99m}Tc-tetrofosmin. Stress and rest perfusion tomographic images are shown on the left side in the short axis, horizontal long axis, and vertical long axis views. "Bullseye" and 3D tomographic images are shown in the right panel. Stress and rest images on the bottom (IRNC) demonstrate count reduction in the inferior wall due to diaphragmatic attenuation. The same images corrected for attenuation by CT (IRAC) on the top better demonstrate the inferior wall perfusion reduction on stress, which is normal on rest. This is referred to as a "reversible perfusion defect" which is due to coronary disease or ischemia in the distribution of the posterior descending artery. SPECT/CT is becoming the standard for a number of nuclear medicine examinations, including myocardial perfusion imaging. (Image courtesy of DK Shelton.)

annihilation. When a photon pair is detected by two detectors on the scanner, it is assumed that the annihilation event took place somewhere along a straight line between those two detectors. This information is used to mathematically compute the 3D distribution of the PET agent, resulting in a set of tomographic emission images.

Although more expensive than SPECT, PET has clinical advantages in certain diagnostic areas. The PET detector system is more sensitive to the presence of radioisotopes than SPECT cameras, and thus can detect very subtle pathologies. Furthermore, many of the elements that emit positrons (carbon, oxygen, fluorine) are quite physiologically relevant (fluorine is a good substitute for a hydroxyl group), and can be incorporated into a large number of biochemicals. The most important of these is ^{18}FDG, which is concentrated in tissues of high glucose metabolism such as primary tumors and their metastases. PET scans of cancer patients have the ability in many cases to assess the extent of disease, which may be underestimated by CT alone, and to serve as a baseline against which the effectiveness of chemotherapy can be evaluated. PET studies are often combined with CT images acquired immediately before or after the PET scan.

MIM Software Inc. v. Progenics Pharmaceuticals, Inc.
IPR2025-00725
Progenics EX2027

PET/CT combined imaging has applications in oncology, cardiology, neurology, and infection and has become a routine diagnostic tool for cancer staging. Its role in the early assessment of the effectiveness of cancer treatment reduces the time, expense, and morbidity from failed therapy (Fig. 1-9).

Combined Imaging Modalities

Each of the imaging modalities has strengths (e.g., very high spatial resolution in radiography) and limitations (e.g., anatomical superposition in radiography). In particular, nuclear medicine imaging, whether with a scintillation camera or PET, often shows abnormalities with high contrast, but with insufficient anatomic detail to permit identification of the organ or tissue with the lesion. Furthermore, in nuclear medicine, attenuation by the patient of emitted radiation degrades the information in the images. Combining a nuclear medicine imaging system (SPECT or PET) with another imaging system providing good definition of anatomy (CT or MRI) permits the creation of fused images, enabling anatomic localization of abnormalities, and correction of the emission images for attenuation (Fig. 1-10).

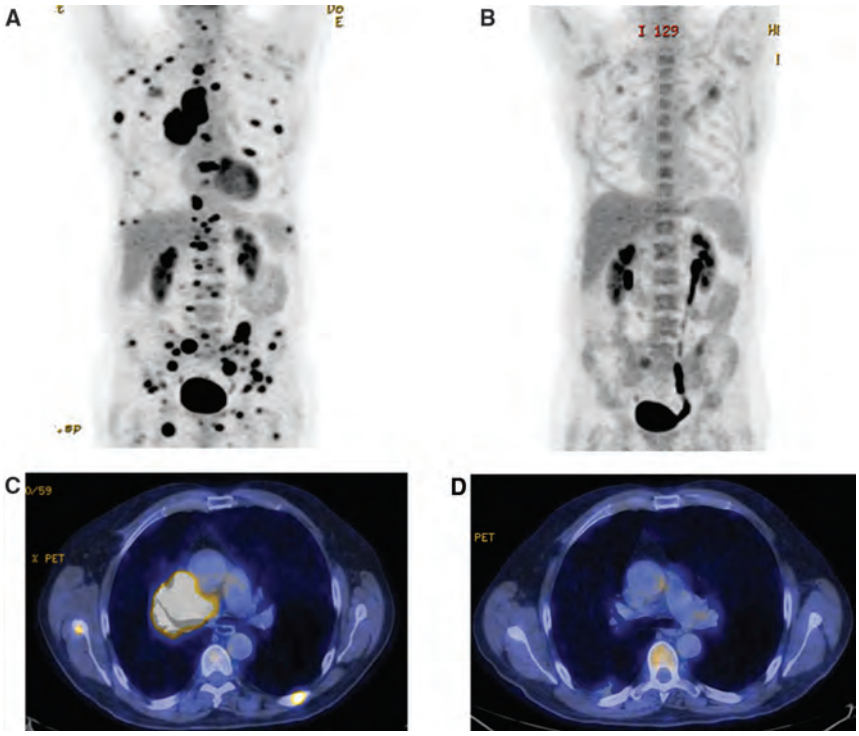

■ **FIGURE 1-9** Two whole-body PET/CT studies of a 68-year-old male undergoing treatment for small cell lung cancer. Maximal intensity projection images are shown before (**A**) and after (**B**) chemotherapy. For each study, the patient was injected intravenously with 740 MBq (20 mCi) of ^{18}FDG. The CT acquisition was immediately followed by the PET study, which was acquired for 30 minutes, beginning 60 minutes after injection of the FDG. The bottom panel shows the colorized PET/CT fusion axial images before (**C**) and after (**D**) chemotherapy. The primary tumor in the right hilum (**C**) is very FDG avid (i.e., hypermetabolic). The corresponding axial slice (**D**) was acquired 3 months later, showing dramatic metabolic response to the chemotherapy. The metastatic foci in the right scapula and left posterior rib have also resolved. The unique abilities of the PET/CT scan in this case were to assess the extent of disease, which was underestimated by CT alone, and to assess the effectiveness of chemotherapy. (Images courtesy of DK Shelton.)

MIM Software Inc. v. Progenics Pharmaceuticals, Inc.
IPR2025-00725
Progenics EX2027

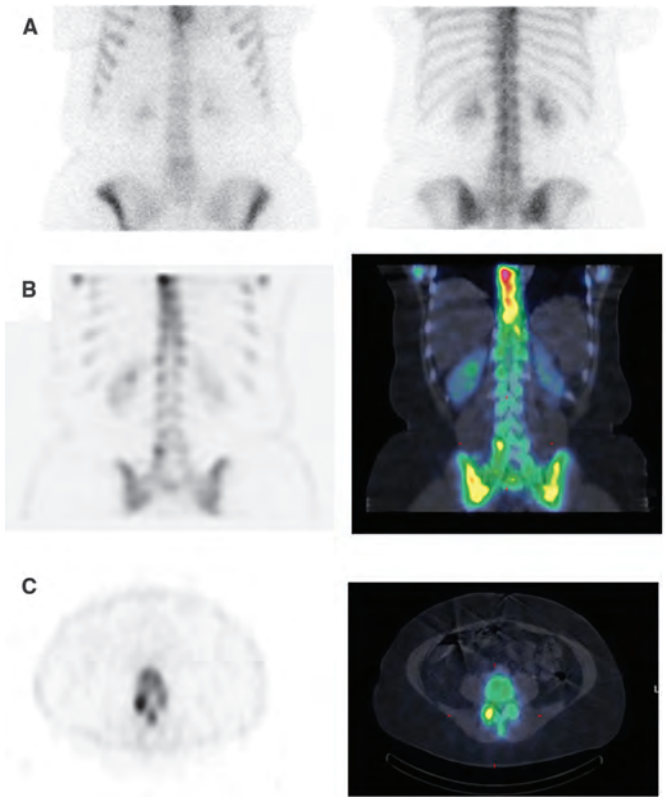

■ **FIGURE 1-10** A planar and SPECT/CT bone scan done 3 hours after injection of 925 MBq (25 mCi) Tc-MDP. **A.** Anterior (**left**) and posterior (**right**) spot views of the spine in this 54-year-old female with back pain. The posterior view shows a faintly seen focus over a lower, right facet of the lumbar spine. **B.** Coronal views of the subsequent SPECT bone scan (**left**) better demonstrate the focus on the right lumbar spine at L4. The colorized image of the SPECT bone scan with CT fusion is shown on right. **C.** The axial views of the SPECT bone scan (**left**) and the colorized SPECT/CT fusion image (**right**) best localizes the abnormality in the right L4 facet, consistent with active facet arthropathy. (Images courtesy of DK Shelton.)

1.2 Image Properties

Contrast

Contrast in an image manifests as differences in the grayscale values in the image. A uniformly gray image has no contrast, whereas an image with sharp transitions between dark gray and light gray demonstrates high contrast. The various imaging modalities introduced above generate contrast using a number of different forms of energy, which interact within the patient's tissues based upon different physical properties.

The contrast in x-ray transmission imaging (radiography, fluoroscopy, mammography, and CT) is produced by differences in tissue composition, which determine the local x-ray absorption coefficient, which in turn is dependent upon the density (g/cm^3) and the effective atomic number. The energies of the x-ray photons in the beam (adjusted by the operator) also affect contrast in x-ray images. Because bone has a markedly different effective atomic number ($Z_{eff} \approx 13$) than soft tissue ($Z_{eff} \approx 7$), due to its high concentration of calcium ($Z = 20$) and phosphorus ($Z = 15$), bones

MIM Software Inc. v. Progenics Pharmaceuticals, Inc.
IPR2025-00725
Progenics EX2027