The Orthodontic Treatment of Impacted Teeth

Adrian Becker

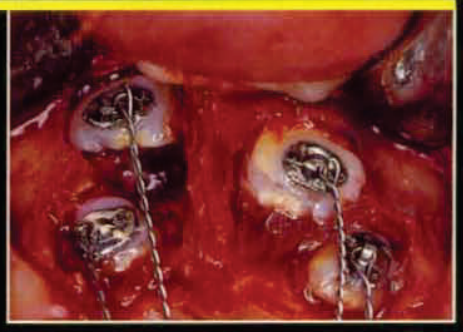

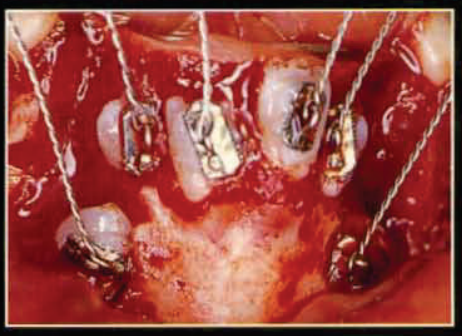

ODONTOLOGIE
D 059 026646 8

TZ

18495 * WU 400 DEC

The Orthodontic Treatment of Impacted Teeth

ADRIAN BECKER BDS, LDS RCS, DDO RCPS

Clinical Associate Professor, Department of Orthodontics, Hebrew University-Hadassah School of Dental Medicine, founded by the Alpha Omega Fraternity, Jerusalem, Israel

MARTIN DUNITZ

BIBLIOTHÈQUE DE L'UNIVERSITÉ
DE PARIS V
U.F.R. DE ODONTOLOGIE
1, rue Maurice-Arnoux
92120 MONTROUGE

© Martin Dunitz Ltd 1998
First published in the United Kingdom in 1998 by

Martin Dunitz Ltd
The Livery House
7–9 Pratt Street
London NW1 0AE

All rights reserved. No part of this publication may be reproduced, stored in a retrieval system, or transmitted, in any form or by any means, electronic, mechanical, photocopying, recording or otherwise without the prior permission of the publisher or in accordance with the provisions of the Copyright Act 1988, or under the terms of any licence permitting limited copying issued by the Copyright Licensing Agency, 33–34 Alfred Place, London WC1E 7DP.

A CIP catalogue record for this book is available from the British Library

ISBN 1 85317 328 2

Composition by Wearset, Boldon, Tyne and Wear
Printed and bound in Singapore

CONTENTS

Preface vii

1. General principles related to the diagnosis and treatment of impacted teeth 1

2. Radiographic methods related to the diagnosis of impacted teeth 13

3. Surgical exposure of impacted teeth 25

4. Treatment strategy 43

5. Maxillary central incisors 53

6. Palatally impacted canines 85

7. Other single teeth 151

8. Impacted teeth in the adult 179

9. Cleidocranial dysplasia 199

Index 231

reopening of the space for the missing tooth is undertaken.

At this point, the palatal arch is constructed on a plaster model, into which the molar bands have been accurately seated and the artificial tooth sited, as described above. The patient's denture is now discarded or the over-retained deciduous tooth is extracted, and the palatal arch carrying the artificial incisor tooth is inserted by recementing the molar bands to their former place.

When moving teeth mesio-distally along an archwire with a multibracketed fixed appliance, the establishment of interproximal contacts between the teeth enables a high degree of control of individual tooth position. Once this has been achieved, uprighting and torqueing movements may be carried out, with care being taken to see that the spaces do not reopen. The desired treatment result includes closed contacts.

In the situation where a tooth is unerupted and space must be made for it, the orthodontist should err on the side of reopening excess space and then maintaining it until the tooth reaches its place. However, to do so, the space needs to be maintained during the many further months of treatment, when the adjacent teeth will be altering their relationships to one another. While attention is diverted to the details of the treatment in these other areas, changes may inadvertently alter the space. The original coil spring, which may have opened the space, must be de-activated, since it will otherwise continue to increase the dimensions of the space. However, the placement of active root-uprighting springs will tend to close the space by compressing the spring.

The size of the artificial incisor tooth and its mesio-distal siting may be very useful in holding the achieved space and in ideally placing the adjacent teeth, regardless of their locations and without the need for the coil spring or the ligation of groups of teeth. The natural teeth are swiftly brought into interproximal contacts with the artificial tooth and with each other, and this status is then simple to maintain.

TEMPORARY PROSTHETIC REPLACEMENT AND TOOTH TRANSPOSITION

Rarely, one or more of the impacted teeth is also transposed. For the most part, it is preferable to align the teeth in their transposed positions, rather than to try to retranspose them to their ideal positions, for reasons already discussed in Chapter 6. Nevertheless, there are situations in which this may be the preferred line of treatment.

Given the high frequency of missing lateral incisors in cases of transposition of maxillary canine/first premolar transposition (Peck et al, 1993), treatment of the transposition may have to consider the artificial replacement of the missing teeth during the appliance therapy. The use of a palatal arch to augment the anchorage value of the molar teeth and to provide the vehicle for the artificial replacement teeth is an effective way to deal with this problem (Fig. 8.6).

By tying in a labial archwire from molar to molar, passing through a bracket on each of the artificial lateral incisors, these strategic points on the perimeter of the arch are defined in relation to one another, since the incisor pontics are also rigidly fixed to the molar bands on the lingual side. The small section of labial archwire that intervenes between molar tube and incisor bracket is therefore well supported in terms of anchorage, and may be used to slide the more buccal of the transposed teeth (usually the canine) in the mesio-distal plane. At the same time, the more lingual of the transposed teeth must be moved further lingually to allow its partner to pass by. Finally, it must be moved in the opposite mesio-distal direction and back in the line of the arch.

To achieve this, the more lingual tooth may be ligated to several different and strategically planned loops and cross-pieces, which will have been prepared on the palatal arch ahead of time, using elastic thread. Once again, positive use is made of the palatal arch as an integral part of the orthodontic appliance system, and it is not merely a means of supporting an artificial tooth.

(a)

(b)

(c)

(d)

(e)

(f)

Figure 8.6

(a–c) A 27-year-old female with congenitally absent maxillary lateral incisors and maxillary canine/first premolar bilateral transposition. The deciduous canines and right lateral incisor are still present. (d) Occlusal view of maxillary arch. (e–g) Intra-oral views after extraction of deciduous teeth. (h–j) Treatment progress, seen from the right side. (k,l) Use of palatal arch as support for lateral incisor pontics and also to move premolars through varying use of elastic thread. (m) Occlusal view of complete maxillary dentition, with wire splint from first premolar to first premolar, including lateral incisor pontics. (n–p) Intra-oral views of the completed orthodontic result. The patient was referred for permanent prosthodontic treatment of the lateral incisor problem.

(Figure 8.6 *continued*)

(g)

(h)

(i)

(j)

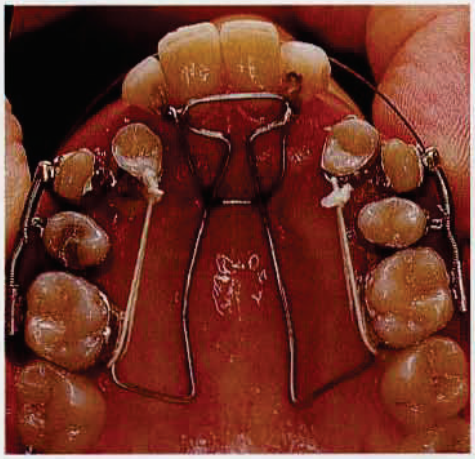

(k)

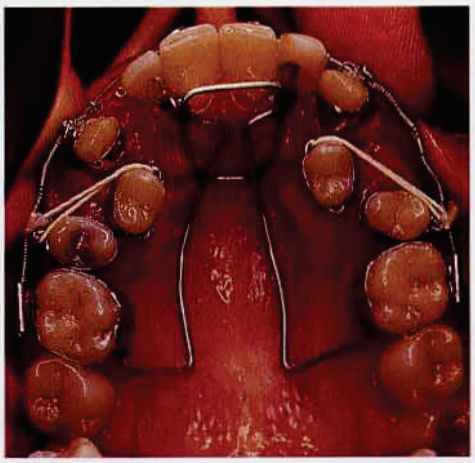

(l)

(Figure 8.6 *continued*)

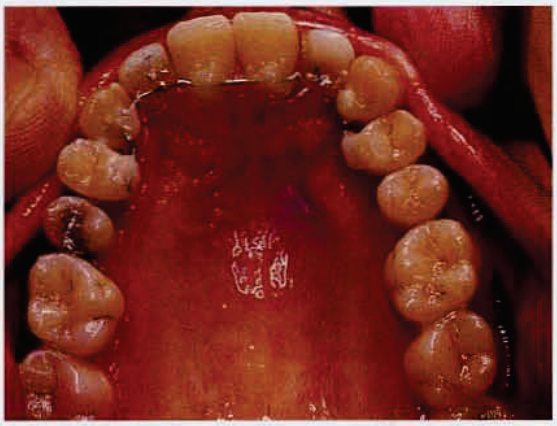

(m)

(n)

(o)

(p)

THE UNERUPTED THIRD MOLAR AS A POTENTIAL BRIDGE ABUTMENT OR AS AN ANTAGONIST FOR AN UNOPPOSED TOOTH

In the previous chapter, we discussed the uprighting of molar teeth that were prevented from erupting, partially or fully, by their relationship with an immediate mesial neighbour. It is pertinent in the context of the present chapter to discuss a different scenario that commonly presents.

Following the extraction of posterior teeth in the adult patient, the establishment of a 'free-end edentulous saddle' makes oral rehabilitation problematic. This may sometimes find a potentially convenient solution in the discovery of an unerupted third molar. However, the absence of standing posterior teeth creates mechanotherapeutic difficulties in providing the vertical traction that is aimed at enhancing the eruptive potential of an unerupted third molar.

Elastic traction of the tooth to the opposing jaw is a useful method, and has been referred to above (Orton et al, 1995), but the use of removable appliances in the adult patient is unreliable. Adults have far greater difficulty becoming accustomed to the bulk of the removable plate and its interference with masticatory and articular function. The use of a fixed mandibular appliance offers a much more satisfactory and dimensionally modest alternative, which interferes neither with eating nor with speech. Furthermore, if the mandibular appliance is to be used only as a source of anchorage, brackets and archwires may be dispensed with, making it very inconspicuous indeed.

An unopposed second molar in the opposite arch is the tooth that faces the potential

manner similar to that occuring with normal, unassisted eruption in the normal patient (Becker et al, 1983; Kohavi et al, 1984). This will enhance the vertical height of the alveolar processes of the two jaws, incidentally deepening the labial and lingual sulci and improving the overall facial proportions.

In the other two methods, the need to maintain patency of the exposure and visual contact with the unerupted teeth dictates that the bone level must be pared down to that of the deepest tooth. This clearly includes the reduction of both the lingual and buccal cortical plates to this level – and this in a patient whose alveolar processes are already of reduced height, because of the syndrome.

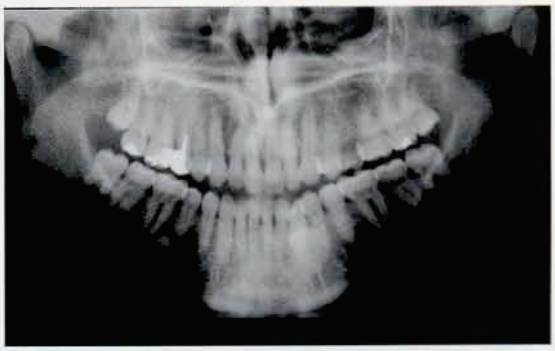

Figure 9.20

Panoramic radiograph of a patient 12 years after all appliances were removed. A newly developing supernumerary premolar tooth is noted.

PATIENT VARIATION

Similarities are seen among all of the patients suffering from cleidocranial dysplasia, but there is a varying degree of expression of the various characteristic features of the disease, together with many other sporadic phenomena that have been reported to occur with the condition. Erupted permanent incisors are sometimes seen, and these may eliminate the need for the 'incisor-erupting' initial heavy archwire, in one or both arches. Instead, the treatment may begin with the levelling phase with the modified Johnson twin-wire arch.

Some patients make their appearance for the first time at an advanced dental age, when root apex closure has occurred in most of the erupted and unerupted teeth. Obviously, there is no developmental determinant to dividing the treatment into the above-mentioned stages, although it may still be advisable from a strictly mechanical point of view. It is difficult to design an appliance that may efficiently extrude teeth in several areas at the same time. Nevertheless, the inclusion of the canines with the anterior teeth may have some merit in these cases.

At the completion of all the treatment and the placement of retainers, new radiographs should be taken to check for the development of recurrent supernumerary teeth, which sometimes occurs in the 14–16-year-old patient (Fig. 9.20). At this point, any decision regarding the extraction of such teeth is strictly a surgical one (Becker et al, 1982; Becker and Shteyer, 1987). When such teeth are identified at this late stage, their extraction is no longer an orthodontic decision, since full alignment of the teeth has been achieved and suitable retention will prevent any adverse effects. Such factors as location and accessibility, incipient resorption of neighbouring erupted teeth, and cysts will all influence the surgeon regarding the necessity and timing of their extraction.

REFERENCES

Becker A (1987) Periodontal splinting with multistrand wire following orthodontic realignment of migrated teeth: report of 38 cases. *Int J Adult Orthod Orthogn Surg* **2**: 99–109.

Becker A, Goultschin J (1984) The multistrand retainer and splint. *Am J Orthod* **81**: 470–4.

Becker A, Shochat S (1982) Submergence of a deciduous tooth, its ramifications on the dentition and treatment of the resulting malocclusion. *Am J Orthod* **81**: 240–4.

Becker A, Shteyer A (1987) A surgical and orthodontic approach to the dentition in cleidocranial dysostosis. *Trans Eur Orthod Soc* **63**: 121 (abst).

Becker A, Zilberman Y (1978) The palatally impacted canine: a new approach to its treatment. *Am J Orthod* **74**: 422–9.

Becker A, Bimstein E, Shteyer A (1982) Interdisciplinary treatment of multiple unerupted supernumerary teeth. *Am J Orthod* **81**: 417–22.

Becker A, Kohavi D, Zilberman Y (1983) Periodontal status following the alignment of palatally impacted canine teeth. *Am J Orthod* **84**: 332–6.

Becker A, Lustmann J, Shteyer A (1997a) Cleidocranial dysplasia: part 1 – general principles of the orthodontic and surgical treatment modality. *Am J Orthod Dentofac Orthop* **111**: 28–33.

Becker A, Shteyer A, Bimstein E, Lustmann J (1997b) Cleidocranial dysplasia: part 2 – a treatment protocol for the orthodontic and surgical modality. *Am J Orthod Dentofac Orthop* **111**: 173–83.

Behlfelt K (1987) Cleido-cranial dysplasia: diagnosis and treatment concept. *Trans Eur Orthod Soc* **63**: 25 (abst).

Ben Bassat Y, Brin I, Fuks A, Zilberman Y (1985) Effect of trauma to the primary incisors on permanent successors in different developmental stages. *Ped Dent* **7**: 37–4.

Bixler D (1976) Hereditable disorders affecting cementum and the periodontal structures. In: *Oral Facial Genetics* (ed RE Stewart, GH Prescott), pp 282–4. Mosby, St Louis.

Brin I, Ben Bassat Y, Fuks A, Zilberman Y (1984) Trauma to the primary incisors and its effect on the permanent incisors. *Ped Dent* **6**: 78–82.

Cohen MM Jr (1976) Dysmorphic syndromes with craniofacial manifestations. In: *Oral Facial Genetics* (ed RE Stewart, GH Prescott), pp 566–7. Mosby, St Louis.

Davies TM, Lewis DH, Gillbe GV (1987) The surgical and orthodontic management of unerupted teeth in cleidocranial dysostosis. *Br J Ortho* **14**: 43–7.

Elomaa E, Elomaa M (1967) Orthodontic treatment of a case of cleidocranial dysostosis. *Suom Hammaslaak Toim* **67**: 139–51.

Frame K, Evans RIW (1989) Progressive development of supernumerary teeth in cleidocranial dysplasia. *Br J Orthod* **16**: 103–6.

Frommer HH, Lapeyrolerie FM (1964) Two case reports of cleidocranial dysostosis. *New York J Dent* **34**: 103–7.

Gorlin RJ, Cohen MM Jr, Levin LS (1990) *Syndromes of the head and neck*, 3rd edn, pp 249–53. Oxford University Press, New York.

Gron A (1962) Prediction of tooth emergence. *J Dent Res* **41**: 573–85.

Hall RK, Hyland AL (1978) Combined surgical and orthodontic management of the oral abnormalities in children with cleidocranial dysplasia. *Int J Oral Surg* **7**: 267–73.

Hitchin AD, Fairley JM (1974) Dental management in cleido-cranial dysostosis. *Br J Oral Surg* **12**: 46–55.

Howe GL (1971) *Minor Oral Surgery*, 2nd edn, pp 135–7. Wright, Bristol.

Johnson JE (1934) A new orthodontic mechanism: the twin wire alignment appliance. *Int J Orthod* **20**: 946–63.

Kalliala E, Taskinen PJ (1962) Cleidocranial dystosis: report of 6 typical cases and 1 atypical case. *J Oral Surg* **15**: 808–22.

Kelly E, Nakamoto RY (1974) Cleidocranial dysostosis – a prosthodontic problem. *J Pros Dent* **31**: 518–26.

Kohavi D, Becker A, Zilberman Y (1984) Surgical exposure, orthodontic movement and final tooth position as factors in periodontal breakdown of treated palatally impacted canines. *Am J Orthod* **85**: 72–7.

Lappin MM (1951) Practical management of

the impacted maxillary canine. *Am J Orthod* **37**: 769–78.

Laskin D (1985) *Oral and Maxillofacial Surgery*, Vol 2, pp 44–7. Mosby, St Louis.

Lewis PD (1971) Preorthodontic surgery in the treatment of impacted canines. *Am J Orthod* **60**: 382–97.

Miller R, Sakamoto E, Zell A et al (1978) Cleidocranial dysostosis. A multidisciplinary approach to treatment. *J Am Dent Assoc* **96**: 296–300.

Muller EE (1967) Transplantation of teeth in cleidocranial dysostosis. In: *Oral Surgery: Transactions of the 2nd Congress of the International Association of Oral Surgeons* (ed E Husted, E Hjorting-Hansen), pp 375–9. Munksgaard, Copenhagen.

Oksala E, Fagerstrom G (1971) A two-stage sutotransplantation of 14 teeth in a patient with cleidocranial dysostosis. *Suom Hammaslaak Toim* **67**: 333–8.

Probster L, Bachmann R, Weber H (1991) Custom-made resin-bonded attachments supporting a removable partial denture using the spark erosion technique: a case report. *Quintessence Int* **22**: 349–54.

Richardson A, Swinson T (1987) Combined orthodontic and surgical approach to cleidocranial dysostosis. *Trans Eur Orthod Soc* **63**: 23 (abst).

Ricketts RM (1981) Perspectives in the clinical application of cephalometrics. The first fifty years. *Angle Orthod* **51**: 115–50.

Shafer WG, Hine MK, Levy BM (1983) *A Texbook of Oral Pathology*, 4th edn, pp 678–80. Saunders, Philadelphia.

Shepard ES (1961) *Technique and Treatment with the Twin-Wire Appliance*. Mosby, St Louis.

Smylski PT, Woodside DG, Harnett BE (1974) Surgical and orthodontic treatment of cleidocranial dysostosis. *Int J Oral Surg* **3**: 380–5.

Seow WK, Hertzberg J (1995) Dental development and molar root length in children with cleidocranial dysplasia. *Pediatr Dent* **17**: 101–5.

Stewart RE, Prescott GH (eds) (1976) *Oral Facial Genetics*. Mosby, St Louis.

Tachdjian MO (1990) *Pediatric Orthopedics*. 2nd edn, pp 840–4. Saunders, Philadelphia.

Trimble LD, West RA, McNeill RW (1982) Cleidocranial dysplasia: comprehensive treatment of the dentofacial abnormalities. *J Am Dent Assoc* **105**: 661–6.

Vermette ME, Kokich VG, Kennedy DB (1995) Uncovering labially impacted teeth: apically repositioned flap and closed-eruption techniques. *Angle Orthod* **65**: 23–32.

von der Heydt K (1975) The surgical uncovering and orthodontic positioning of unerupted maxillary canines. *Am J Orthod* **68**: 256–76.

Weintraub GS, Yasilove IL (1978) Prosthodontic therapy for cleidocranial dysostosis. Report of a case. *J Am Dent Assoc* **96**: 301–5.

Winther JE, Khan MW (1972) Cleidocranial dysostosis: report of 4 cases. *Dent Pract* **22**: 215–19.

Yamamoto H, Sakae T, Davies JE (1989) Cleidocranial dysplasia: a light microscope, electron microscope and crystallographic study. *Oral Surg Oral Med Oral Path* **68**: 195–200.

Zachrisson BU (1977) Clinical experience with direct-bonded orthodontic retainers. *Am J Orthod* **71**: 440–8.

Zegarelli EV, Kutscher AH, Hyman GA (1978) *Diagnosis of Diseases of the Mouth and Jaws*, p 137. Lea & Febiger, Philadelphia.

Zilberman Y, Fuks A, Ben Bassat Y et al (1986) Effect of trauma to primary incisors on root development of their permanent successors. *Ped Dent* **8**: 289–93.

Index

Page numbers in *italic* refer to the illustrations

active palatal arches 121–2, *123*
active removable plates 181–2, *188*
Adam's clasp 166, 181
adult patients
  diagnosis 178–80
  management 180–1
  temporary prostheses 181–7
alignment
  group 1 canines 117, *117*
  group 2 canines 120–3, *120*
  group 3 canines 131–4
  group 4 canines 134
  group 5 canines 135–9
  spontaneous 62
anchor teeth 187
anchorage
  implants 196
  units 44, 109, 120, 167
Angle's Class II malocclusion 10
ankylosis 29, 35, 45, 81
  crown resorption 171–2
apical root dilaceration 73
appearance 10–11, 62–3, 202, 211
appliances 109
  see *also* mechanotherapy
  active removable plate 181–2
  Adam's clasp 166, 181
  adult patients 193, *194*
  auxiliary labial wire 122–3, *124*
  auxiliary springs 37, *38*, 48–9
  ballista 37, 121, *122*
  Begg brackets 65, 222
  box elastics 72, 215–16
  brackets 46–7, *46*
  buttons 77, 81, *170*
  early mixed dentition 63–4
  ectopic first molars 166
  Edgewise brackets 46, 65, *159*
  eruption 113
  extra-oral headgear 157, 169
  'finger' spring *164*
  fixed versus removable 166
  flipper (spoon) dentures 72, 179, 181, 187
  Johnson's (modified) twin-wire arch
    maxillary central incisors 64–8, *67–70*
    root dilaceration 74, *78*
  magnets 50, *50*
  mandibular second molars 167, *168*
  multi-bracketed 44, 190
  orthodontic bands 46
  removable 123
  separators 166
  Siamese brackets 46, 167
  threaded pins 45–6, *45*
arch lengths 111
archform 110–11, 217
archwires
  anchorage bases 44
  buccal 68
  elastic displacement 49
  incisor-aligning 64, 213, 216–17, *217*
  incisor-erupting 213, *213*, 214, *215*
  mandibular canines 154
  palatally displaced canines 111–12
  tooth transposition 190
attachments 44–8
  bonding 30, 31, 36–40, *38*
  buttons 77, 81
  extra-oral anchorage 196
  eyelets 37, 39, 47–8, *47*
    group 1 canines 118–19
    group 2 canines 120
    group 3 canines 130–1
  Goshgarian bar 186–7, *188–9*
auxiliary labial wires 122–3, *124*
auxiliary springs 37, *38*, 48–9, 120–3, *124*

ballista 37, 121, *122*
bands, orthodontic 46
Begg brackets 65, 222
Begg technique 111–12
Belfast-Hamburg approach 205–7
bonding 46
  acid-etch 159
  agents 39
  attachments 30, 31, 36–40, *38*
  unfilled resin 196
bone
  channelling 26
  cleidocranial dysplasia 207
  height 71
  support 113–14, *114*
box elastics 72, 215–16
brackets, orthodontic 46–7, *46*
bridge abutment 193, 196
buccal arches 187
buccal impaction
  maxillary canines 151–3, *152–3*
  surgical exposure 30–2, *31*, *32*
buccal traction 128, *132–3*
buttonholing 32, *32*
buttons 77, 81, *170*

canines
  CT scanning 22
  deciduous
    cystic changes 97–98, *97*
    extraction 102, *103*, *104*
    morbidity 96
    root non-resorption 90, *91*
  development 86–8, *87*
  eruption 6, 88
  mandibular 4, 154–6, *154*, *155*, *156*, *188–9*
  maxillary *89*
    eruption *26*
    impaction, buccal 151–3, *152–3*
    inspection 100
    missing 186–7
    palatal *15*
    radiography 21
    root development 4
  palatal
    classification 112–47
    displacement theories 88–96
    impaction *86*
      complications 96–100
      diagnosis 100–1
      extraction 111, 113

cont'd
group 1 115–19, *116–17*
group 2 119–27, *119*, *126–7*
group 3 128–34, *129*
group 4 134–5, *136–7*
group 5 135–9, *138*, *139*
group 6 139–46
heredity 95–6
mechanotherapy 110–12, *110*, *111*, *112*
prevalence 85–6
treatment, timing 101–9
radiography *19*, 101
treatment, preventive 102–5
central incisors
congenital absence 53
diagnosis 59–61
dilaceration *21*, 55–8, 72–6
eruption 53
prognosis 71–6
root development *55*, 56, 58, 72–6
space loss 8, *16*
treatment 61–82
central mandibular incisors 4–5
children
central incisors 53, *54*, 62
dental age 1–6, 2, 4
diagnosis 8
orthodontic separators 166
surgical intervention 9
traumatic injury 55–9, *68–70*
cleidocranial dysplasia 199–200, *200*, *201*, 202
Belfast-Hamburg approach 205–7
diagnosis 211
Jerusalem approach 207–9, 211–22, 226
long-term retention 210
patient variation 227
patient well-being 209, 210
Toronto-Melbourne approach 204–5
treatment 202–4, 222, *225*, 226–7
computed tomography (CT) scanning 22, *23*, 24
palatally impacted canines 99
cross-bite 182
crowding 7, *8*, 32
cleidocranial dysplasia 209–10
extraction 111–12
mandibular canines 156
mandibular second premolars 157
maxillary first molars 165
palatally impacted canines 89–90, *89*, 102
crowns
amputation 76
calcification 4
dilaceration 56, 73–4, *75*
resorption 33
see also replacement resorption
ankylosis 171–2
impaction 169–70
palatally impacted canines 98, *98*
CT *see* computed tomography
cysts
dentigerous 8, 98, 174, 176
palatally impacted canines 97, *97*, *99*
marsupialization 174

deciduous teeth
cystic changes 97–98, *97*
extraction 102, *103*, *104*
retained 3, *3*, 5, 8, *10*
cleidocranial dysplasia 202, 207
mandibular second premolars 157–8
supernumerary teeth *16*
surgical intervention 27–8
dental age 1–6, 102, 211
dental follicles
cystic change 97, *98*, 99
surgical exposure of impacted teeth 9, 33–5, *34*
dental history 59
dentigerous cysts 8, 174, 176
palatally impacted canines 97, *97*, *99*
development
canines 86–8, *87*
dental age 1–6, 33
dental follicles 33
dilaceration 55–7
dilaceration
apical root 73
central incisors *21*, 55–8, 60–1, *66*, 72–6

Edgewise brackets 46, 65, *159*
elastic ligatures 47–9, *48*, *49*, 72
elastic traction 193–96
enucleation 174
eruption
canines 6, *26*, 88
delayed 3, 6–7, 53, 62
forced 113–14
full flap closure 31–2
maxillary central incisors 6, 53
premature 6, 9
primary failure of 171
spontaneous 62
surgical intervention 26–8, *27*
traction 109
etching 38, 130, 196
exposure 27–8, *27*, *28*, *38*, 109
extra-oral anchorage 196
extra-oral headgear 157, 169
extra-oral radiography 17
extraction
crowding 111–12
deciduous canines 102, *103*, *104*
dental age 2
first premolars 102, *105*
infraocclusion 161
lateral incisors 103–5, *106*
mandibular second premolars 157
palatally impacted canines 111, 113
preventive treatment 102–5, *103*, *104*, *105*
eyelets 47–8, *47*
attachment 37, 39
group 1 canines 118–19
group 2 canines 120
group 3 canines 130–1

facial appearance 10–11, 62–3, 202, 211
'finger' spring *164*
flipper (spoon) dentures 72, 179, 181, 187
follicular sacs 97, *98*, 99
free-end edentulous saddles 193

gold chain ligatures 47
Goshgarian bar 186–7, *188–9*
guidance theory 90–3

hard tissue obstructions 28–9
headgear 157, 169
healing, by secondary intention 9
heredity
cleidocranial dysplasia 199
guidance theory 95–6, *95*
infraocclusion 171, *173*
Hertwig's root sheath 57, 58, *58*

impaction
buccal 151–3, *152–3*
surgical exposure 30–2, *31*, *32*
complications 58
crown resorption 169–70
diagnosis 6–11, *9*
disguise 178–80
guidance theory 90–3
hard tissue obstruction 28–9
neglect and disguise 178–80
obstructed 71–2
odontomes *86*
palatal
complications 96–100
diagnosis 100–1
group 1 canines 115–19, *116–17*
group 2 canines 119–27, *119*, *126–7*
group 3 canines 128–34, *129*
group 4 canines 134–5, *136–7*
group 5 canines 135–9, *138*, *139*
group 6 canines 139–46
heredity 95–6
mechanotherapy 110–12, *110*, *111*, *112*
prevalence 85–6
treatment timing 101–9
radiography 13–24
surgical exposure 8–10, 25–41
traumatic causes 72–82
implants 180, 196

incisor-aligning archwires 64, 213, 216–17, *217*
incisor-erupting archwires 213, *213*, 214, *215*
incisors
central
dilacerated *21*
maxillary
arrested root development 58
congenital absence 53
diagnosis 59–61
eruption 53
obstructive causes 53–5, 71–2
prognosis 71–6
space loss 8, 16
traumatic causes 55–9, 72–5
treatment 61–82
missing 182–5
root development 4–5
eruption 6, 53
lateral
extraction 103–5, *106*
maxillary 4–5, *10*
palatally impacted canines 91–3, 92, *94*, 99, 110, *110*
root development 4–5, *10*
root resorption 141, *142–3*, *144–5*, *146*, *147–8*
late 98–100, *99*
maxillary *87*, *147–8*, *191–3*
infraocclusion
deciduous teeth 159–61, *162*, *163*, *164–5*
extraction 161
non-ankylotic 172, 174
permanent teeth 170–4, *171*, *172*
surgical exposure 29
intrusive luxation 58–9, 76–82, *77–80*

Jerusalem approach
diagnosis 211
orthodontics *212–13*, 213–18, *214*, 220–2, *223–4*
surgery 214, 219
Johnson's (modified) twin-wire arch
cleidocranial dysplasia 213
maxillary central incisors 64–5, *64*, *66*, 67–8, *67*, *68–70*
root dilaceration 74, *78*

lasso wires 45, *45*
lateral incisors
extraction 103–5, *106*
palatally impacted canines 91–3, 92, *94*, 99, 110, *110*
root development 4–5, *10*
root resorption 98–100, *99*, 141, *142–8*
lateral mandibular incisors, root development 4, 5
lateral open bite 161, *163*
lesions, soft tissue 28
ligatures
elastic 48–9, *48*, *49*, 72
gold chain 47
pigtail 47–8, 214–15
slingshot elastic *49*, *116*, 118
stainless steel 47–8

magnets 50, *50*
malocclusion 10, 44
mandibles
arch, radiography 14, *14*
canines 4, 154–6, *154–6*, *188–9*
removable appliance 123
second molars 167, 169
second premolars 157, 157–9, *158*, *160*
marsupialization 174
maxilla
anterior occlusal 14, *15*
arch radiography 14, *15*
canines *89*
eruption 26
impaction, buccal 151–3, *152–3*
inspection 100
missing 186–7
palatal *15*
radiography 21
root development 4
central incisors
arrested root development 58
congenital absence 53
diagnosis 59–61
prognosis 71–6
space loss 8, *16*
treatment 61–82
first molars 165–7, *175–6*
first premolars, root development 4
incisors *87*, *147–8*
lateral incisors, root development 4–5, *10*
second premolars 161, *162*, *163*, *164–5*
mechanotherapy
see *also* appliances
cleidocranial dysplasia 208–9
eruptions 62
group 5 canines 138–9, *138*
palatally impacted canines 109–12
timing 105, 108–9
medical history 59
mesial crown displacement 118–19
molar bands 187, *188*, 190
molars
elastic traction 193–6
eruption 6
mandibular second 167, 169
root development 4–5
second deciduous 159–61
third 193, 196
mosquito forceps 39

Nasmyth's membrane 36

odontomes 7, 54, 60
Ong's projection *15*
oral hygiene 72, 108, 112, 125, 176, 211
orthophosphoric acid 36
overjets 182

palatal approach 131, *131*
palatal arch 37, 65, 187, 190
palatal displacement 88–96
palatal impaction
canines *86*
classification 112–47
complications 96–100
diagnosis 100–1
heredity 95–6
prevalence 85–6
treatment 110–12, *110*, *111*, *112*
treatment timing 101–9
palatal mucosa 32–3
palatal root displacement 119, 125
palpation 59–60, 100–1
patients
adults
diagnosis 178–80
management 180–1
temporary prostheses 181–7
appearance 10–11, 62–3, 202, 211
children
diagnosis 8
orthodontic separators 166
surgical intervention 9
traumatic injury 55–9, *68–70*
dental age 1–6, 2, *4*
history 59
motivation 10–11
psychological well-being 209, 210
permanent teeth, late-developing 6
pigtail ligatures 47–8, 214–15
premolars
development *5*, *6*, *7*
extraction 102, *105*
impacted *20*
mandibular
abnormal orientation 157–9, *158*, *159*
crowding 157
extraction 157
late-developing *160*
maxillary 161, *162*, *163*, *164–5*
root development 4
movement 135
preventive treatment 102–5
prosthetics
cleidocranial dysplasia 203
temporary 181–7, 190
psychological well-being 209, 210
pulp necrosis 81, 97

radicular cysts see dentigerous cysts
radiography
canines *19*, 101
central incisors 60–1

cont'd
cephalometric 20, *20*, *21*, *22*
cleidocranial dysplasia *200*, *201*
crown resorption 169
deciduous teeth 8, *9*
extra-oral 17
mandibular arches 14, *14*
mandibular canines 154
maxillary canines 21
maxillary first molars 165
maxillary second premolars 161
occlusal 14–16, *14*, *15*
odontomes 60
parallax method 17–22, *18*
periapical 8, 13–14, *16*
root resorption 140
views at right-angles 18–22, *19*, *20*, *21*, 22
replacement resorption 81, 98, 169
see *also* ankylosis
resorption
see *also* ankylosis
crown 33, 98, *98*, 169–72
incisors 98–100, *99*, 141, *142–8*
replacement 81, 98, 169
root
axial orientation 220, 222
development 4–5, *10*
arrested 58
canines 4
dental age 2, 3–5, *3*
impacted central incisors *55*, 56, 58, 72–6
dilaceration 73
displacement 119, 125
Hertwig's sheath 57, 58, *58*
non-resorption 90, *91*, 114–15
orientation, correction 75
resorption
central incisors 98–100, *99*, 141, *142–3*, *144–5*, *146*
lateral incisors 141, *147–8*
palatally impacted canines 140
rotation 118, 120, 125

secondary intention, healing 9
separators, orthodontic 166
Siamese brackets *46*, 167
slingshot elastic *49*, *116*, 118
soft tissue 28, 55, 72
soldered palatal arches 182, *183*, *184–6*
space closure 153
space opening 105, *107*, 110, *110*
spongiosum 207
stainless steel ligatures 47–8
supernumerary teeth 7, 53–5, 202, 207
supplemental teeth 199
surgery
attachment bonding 36–40
cleidocranial dysplasia 203–9
dentigerous cysts 174, 176
eruptions 26–8, *27*
exposure 27–8, *27*, *28*, *38*
group 1 canines 117
group 2 canines 119–20
group 3 canines 128–34
group 4 canines 134
group 5 canines 135
impacted teeth 8–10, 25, 30–5, 41
mandibular canines 154
mandibular second premolars 157
soft tissue lesions 28
timing 9–10, 207–8
surgical flaps
apical repositioning 30, *31*, 109, 128
closure 31–3, 35, 47

third molars 193, 196
threaded pins 45–6, *45*
Tip-Edge technique 111–12
tooth buds 54–6
tooth development
canines 86–8, *87*
dental age 1–6, 33
dental follicle 33
dilaceration 55–7
tooth germ displacement *95*, 96, *96*, *97*
tooth position, parallax method 17–22, *17*, *18*
Toronto-Melbourne approach 204–5
traction
attachment bonding 40
buccal, group 3 canines 128, *132–3*
dental follicle 33–5
direct versus two-stage *131*
elastic 193–6
mechanotherapy 109
orthodontic 33–5, 40
trans-palatal bars 186–7, *188–9*
transplantation 203
transposition 138–9, *138*, 156, 190
trauma
canines 72–72
central incisors 55–9
children 55–9, *68–70*
intrusive luxation 58–9, 76–82, *77–80*
soft tissue 55
treatment
see *also* appliances
Angle's Class II malocclusion 44
attachments 44
attitudes to 61–3, 108, 141, 181
bands, orthodontic 46
brackets, orthodontic 46–7, *46*
buttonholing 32, *32*
duration 43–4
elastic ligature 48–9, *48*
enucleation 174
eyelets 47–8, *47*
impacted incisors 63–71
lasso wires 45, *45*
ligatures
elastic 48–9, *48*, *49*, 72
gold chain 47
pigtail 47–8, 214–15
slingshot elastic *49*, *116*, 118
stainless steel 47–8
magnets 50, *50*
preventive 102–5
threaded pins 45–6, *45*
timing 61, 101–9
true (vertex) occlusal 15, *15*
tunnel approach 128, *130*

well-being, psychological 209, 210
Whitehead's varnish 9, 25, 159

BIBLIOTHÈQUE DE L'UNIVERSITÉ
DE PARIS V
U.E.R. D'ODONTOLOGIE
1, rue Maurice-Arnoux
92120 MONTROUGE

The Orthodontic Treatment of Impacted Teeth

Impacted teeth have provided an ongoing challenge to the dental profession, and many of its specialties have offered treatment modalities in widely differing styles. In the long-term, it has come to be recognized that superior results are obtainable by the orthodontic/surgical modality. There is, however, a considerable difference of opinion between these two specialties as to which procedures should be carried out first and to what lengths each should be pursued.

This text proposes ways in which difficulties posed by impactions may be overcome with an integrated orthodontic/surgical strategy. It emphasizes the importance of determining an appropriate directional traction force and presents ways of effecting this with the use of different types of orthodontic auxiliaries. The relationship between these factors and a favourable prognosis of the completed treatment result is stressed.

A range of issues affecting impacted teeth, including an extensive review of their diagnostic and management procedures, and aetiology is presented.

Contents • General principles • Radiographic methods • Surgical exposure • Treatment strategy • Maxillary central incisors • Palatally impacted canines • Other single teeth • Impacted teeth in the adult • Cleidocranial dysplasia

With over 400 colour and black-and-white photographs

Adrian Becker BDS, LDS RCS, DDO RCPS is Clinical Associate Professor in the Department of Orthodontics, Hebrew University-Hadassah School of Dental Medicine, founded by the Alpha Omega Fraternity, Jerusalem, Israel and the Director of its Centre for the Treatment of Craniofacial Disorders in Handicapped Children.

Formerly Visiting Professor of Orthodontics at the University of Southern California he has published over 60 articles in international dental journals mostly on various aspects concerned with impacted teeth.

ISBN 1-85317-328-2

9 781853 173288

MARTIN DUNITZ