COORDINATING THE PREDETERMINED PATTERN AND TOOTH POSITIONER WITH CONVENTIONAL TREATMENT

H. D. Kesling, D.D.S., M.D.S., La Porte, Ind.

IT SHOULD be the ambition and determination of every orthodontist to treat each of his patients in such a manner as to produce the best possible results in tooth arrangement with the least inconvenience to himself and his patient. Any discussion among orthodontists is sure to reveal numerous theories concerning the proper age for treatment and the mechanics for producing any given result. Orthodontic literature presents a variety of techniques for the management of the different types of cases. Colleges offer specialized courses covering the mechanics of various appliances. Nevertheless, much of each orthodontist's time is consumed making appliance adjustments which will contribute little or nothing definite to the final result. There is no way of measuring the inefficiency of orthodontic operations, but a fair estimate would reveal that not more than 15 per cent of the time is spent on operations that are necessary and which will contribute directly to the final result. In the past, it was the common practice to make adjustments weekly, or even daily. This did not allow sufficient time for the tissues to repond fully to the pressures which were being exerted by the appliance before additional changes were administered. With the materials and appliances available today it is possible to make adjustments that will be active over a period of weeks. Barring accidents, so long as these adjustments are carrying the teeth toward the desired results, there is no need for more frequent adjustments.

Calvin Case developed stationary anchorage by preparing rigid attachments for groups of teeth and pinning this anchorage against individual teeth for movement. Using these mechanics, he attempted to move only individual teeth but did not attempt to coordinate group tooth movements. Angle, Ketcham, Mershon, and others visualized the possibilities of group tooth movements. Through appliances which these men developed, we are able to treat cases in much less time through reciprocal tooth movements. Among Tweed's many contributions was his technique for successfully developing and using dynamic or complete arch stationary anchorage. This anchorage paved the way for successful mass movements of teeth. A further step forward, in line with these previous developments in orthodontics, is possible when we develop a predetermined pattern of the proposed tooth positions prior to treatment and coordinate this pattern with treatment. This pattern can be used as a guide for basic treatment with conventional appliances and later utilized for the construction of the Positioner.

Read before a meeting of the Southern Society of Orthodontists, Jan. 28 and 29, 1946.

ClearCorrect Exhibit 1015, Page 1 of 9

Temptation to start treatment before the permanent canines and premolars have erupted is prompted by the idea that more space is needed for these erupting teeth. If this space could be created, it would allow these teeth to assume better positions as they erupt. However, in the writer's experience, this course of treatment has invariably led to disappointment. In crowded arches, unless the first molars are tipped forward, space is gained only by "ballooning out" the teeth and supporting alveolar process, either labially or buccally, without any development or modification of the apical base. This seems to hold true regardless of the age at which treatment is undertaken. Clinical experience proves that it is more practicable to close wide spaces caused by removing teeth than to attempt to create even slight spaces.

Since treatment during the transitional period cannot be considered final, it would seem advisable to undertake major tooth movements after the permanent canines and premolars have erupted into the mouth. Only emergency cases should have earlier treatment. In these cases the early treatment should be considered only as an attempt to aid Nature through the developmental stage. To complete treatment successfully, not infrequently these cases will need major tooth movements after the premolars and permanent canines have erupted.

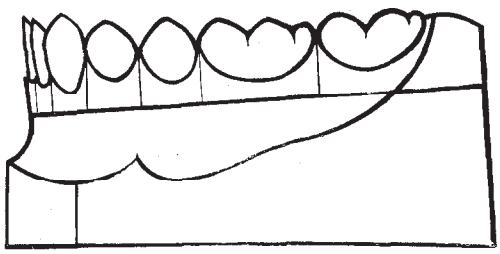

Fig. 1.

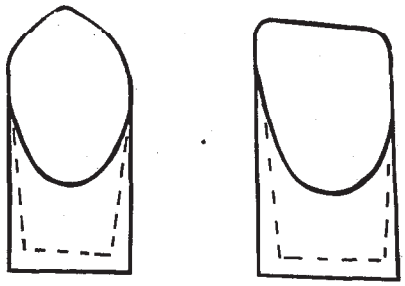

Fig. 2.

Fig. 1.—Diagram of case showing vertical and horizontal saw cuts.

Fig. 2.—Diagram of individual teeth, dotted line showing desirable trimming on mesial, distal, and root end.

The predetermined pattern, or setup, for the case should be developed as a part of the preliminary study and used as a guide in diagnosis. Nothing an operator can do can be as enlightening for this purpose as the preparation of such a setup. In treatment we strive to coordinate tooth anatomy with the existing basal bone. There is no better way to visualize this coordination than through the predetermined pattern prepared before treatment is undertaken. If the technique of the setup is carefully executed and care is taken to preserve the tooth anatomy on the plaster models, the result will be sufficiently clear-cut as to leave no doubts as to the most desirable course of treatment.

The predetermined pattern is made by dissecting the teeth from a plaster model, and, after trimming them, rearranging the teeth in wax into the desired arch form, axial positioning, and interdigitation (Figs. 1 and 2). The operator is free to move the teeth, within reason, to any position which he thinks

they should assume in the patient's mouth. He should, of course, bear in mind the movements that are possible considering the anchorage available. Also he must know and respect the biologic limitations of tooth movements. With experience he will soon realize the possibilities and limitations of the mechanics used in orthodontics. He will position the teeth on the predetermined pattern into positions which are practical to create in the mouth.

Each case presents a fixed amount of tooth anatomy and also a fixed amount of apical base for its support. If the arch of teeth is crowded or the anterior teeth tipped forward, it is only wishful thinking to hope to create space for their proper positions without carrying some teeth off the apical base. The only alternative is moving the buccal teeth distally, and this is possible only to the extent that the first molars are tipped mesially. If these teeth are upright, any distal movement is a difficult procedure and invariably causes impingement on the space required for the eruption of the third molars. If the apical, or bony, base is narrow in the premolar area, it is reasonable to expect that the arch of teeth will also be narrow and, regardless of the treatment instigated, Nature will again bring these teeth back to about the original relationship. When we recognize our limitations so far as bony development is concerned, we will never attempt tooth movements which will leave teeth off the apical base or in axial positions that are not stable. This makes the problem of elimination of some dental units quite simple and, whether we like it or not, we must admit that it is necessary to remove some units in a high percentage of all cases of malocclusion, and especially in Class I cases.

When repositioning the teeth in wax they should be kept upright over the apical base. It is possible when constructing the predetermined pattern to eliminate some teeth and position the others. Before truly efficient treatment can be instigated, such fundamental decisions must be made. What could be a more dependable guide for reaching such decisions than an exact reproduction of the teeth coordinated with the existing apical base? When decisions are based on such concrete evidence, percentages of successful treatment will mount as compared with cases treated by those wishful thinkers who are still hoping to create basal bone where it is not.

If two premolars are removed from the mandibular arch, it is very poor technique to draw back the six anterior teeth, positioning them off the apical base in order to place the canines in contact with the second premolars (Figs. 3 and 4). Such tooth positioning is almost impossible to reproduce in the mouth, because reciprocal action will carry the buccal teeth forward to some extent while moving the anterior teeth to the posterior. In most cases it would even be advantageous to have these buccal teeth move mesially in such treatment. In accordance with the movements desired and the movements possible with present mechanics, we would, on the predetermined pattern, position the buccal teeth forward as well as the anterior segment toward the posterior (Figs. 5 and 6). Therefore, by making a predetermined pattern, an operator has a better concept of the treatment desired for a particular case and can more efficiently plan and execute active treatment.

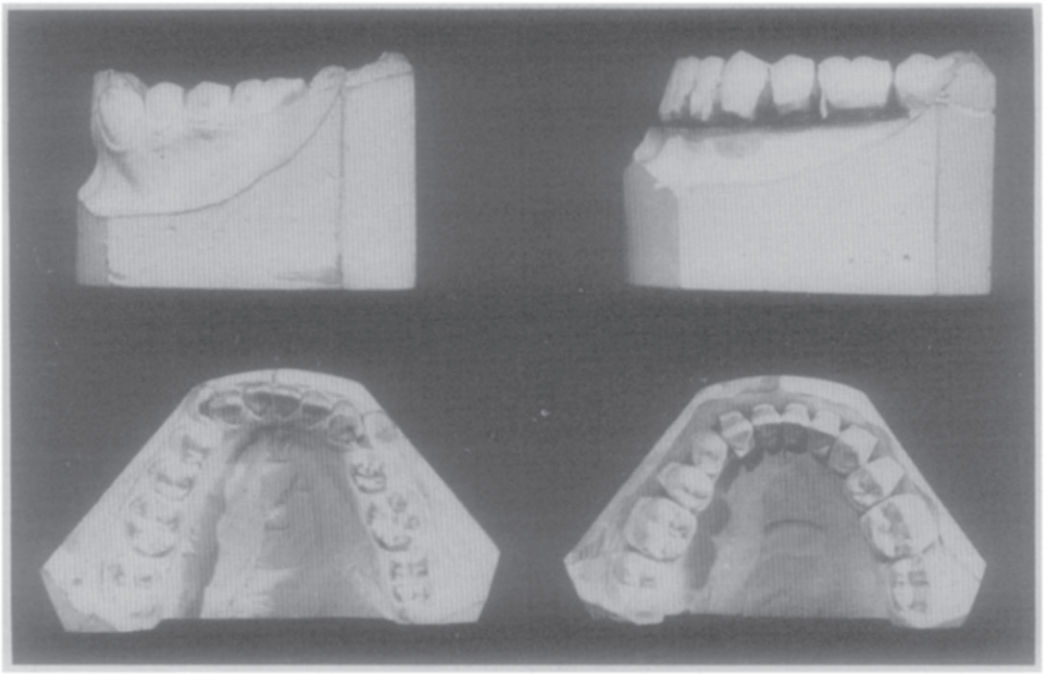

Fig. 3.—Left side of original and setup models showing cuspid moved into the space of the first premolar, throwing the anterior teeth too much to the lingual.

Fig. 4.—Occlusal view of models shown in Fig. 3.

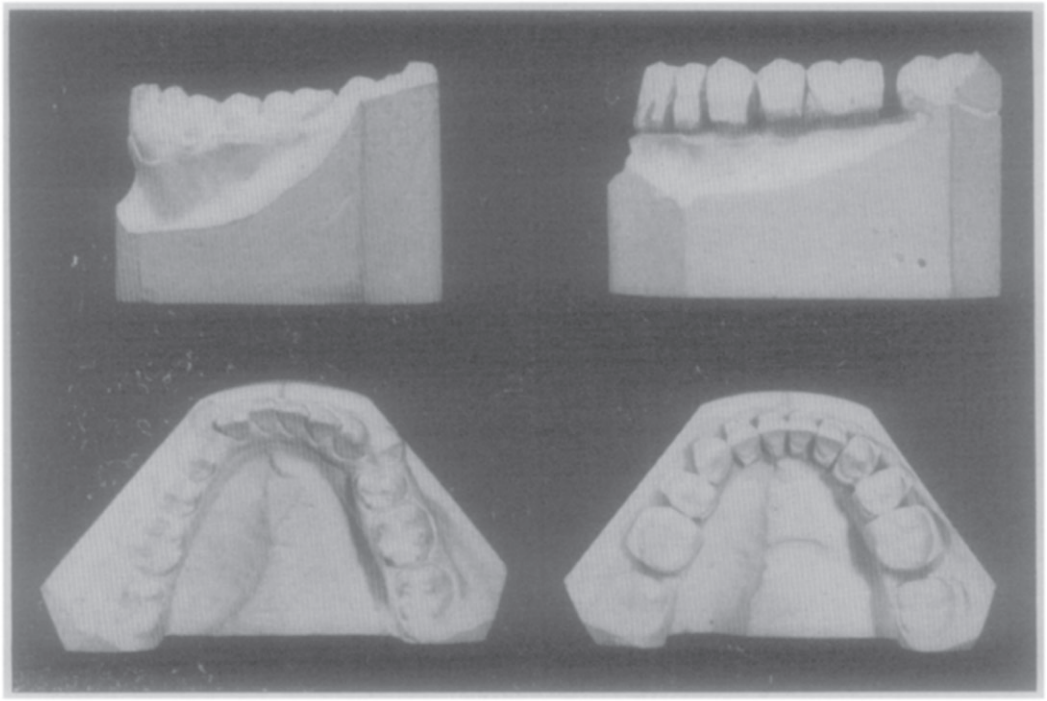

Fig. 5.—Left side of original and setup models showing correct positioning of the teeth over basal bone.

Fig. 6.—Occlusal view of models shown in Fig. 5.

By knowing the exact movements necessary for completion of treatment, anchorage problems become simplified. In order to control the teeth, it is necessary to have some rigid attachment to each individual tooth. At the present time there is no practical means of attaching to the teeth other than by banding. Perfect bands do not necessarily mean good orthodontics nor the most desirable finished result. At the best, bands and attachments can only be considered temporary and as a means, during treatment, of attaching to the individual teeth. Many operators overestimate the necessity of making and placing perfect bands and devote more time to this part of the technique than to the more important part—the manipulation of the appliance. Usually the leveling off and lining up of the teeth can be accomplished with one adjustment, by applying a very small high-tempered arch wire. This is only possible if enough time is allowed for the tissues to repond to this light force.

Fig. 7.—X-ray showing second premolar and cuspid roots after treatment.

Treatment of both arches can be carried on together, bearing in mind that the mandibular teeth should advance toward the predetermined pattern and stationary anchorage somewhat ahead of the maxillary teeth. Adjustments should be made which will definitely cause the teeth to progress toward the predetermined pattern and which will not cause unnecessary tooth movements in any other directions. With the mechanisms we have at hand for creating such movements, it is quite possible to make adjustments that will be active over a period of three or four weeks. Such an adjustment need not be unusually severe but of such a nature that the action will be continuous. Too frequent adjustments are a waste of time and a source of discomfort to the patient. Most orthodontists have had experiences where it has been impossible to see a patient for a period of eight to ten weeks because of illness. When the patient returned, the changes that had taken place in the absence of regular appliance adjustments were surprisingly good.

We must learn the possibilities of our treating mechanism. We must make

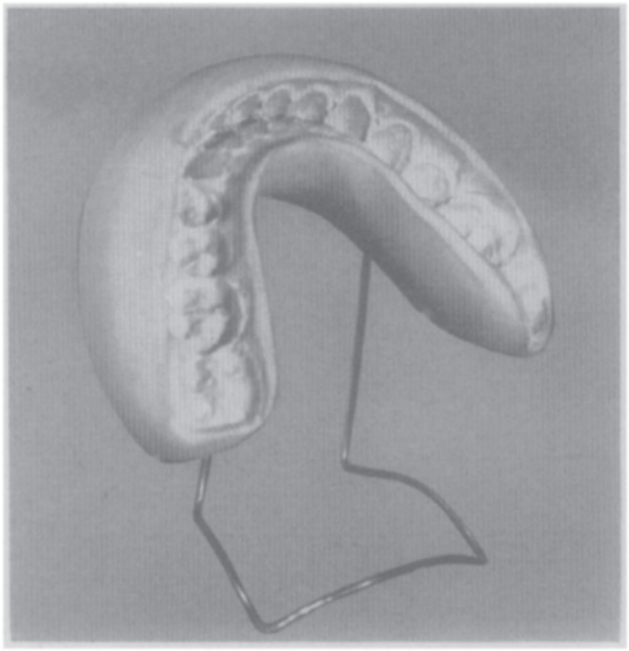

Fig. 8.—Tooth positioning appliance.

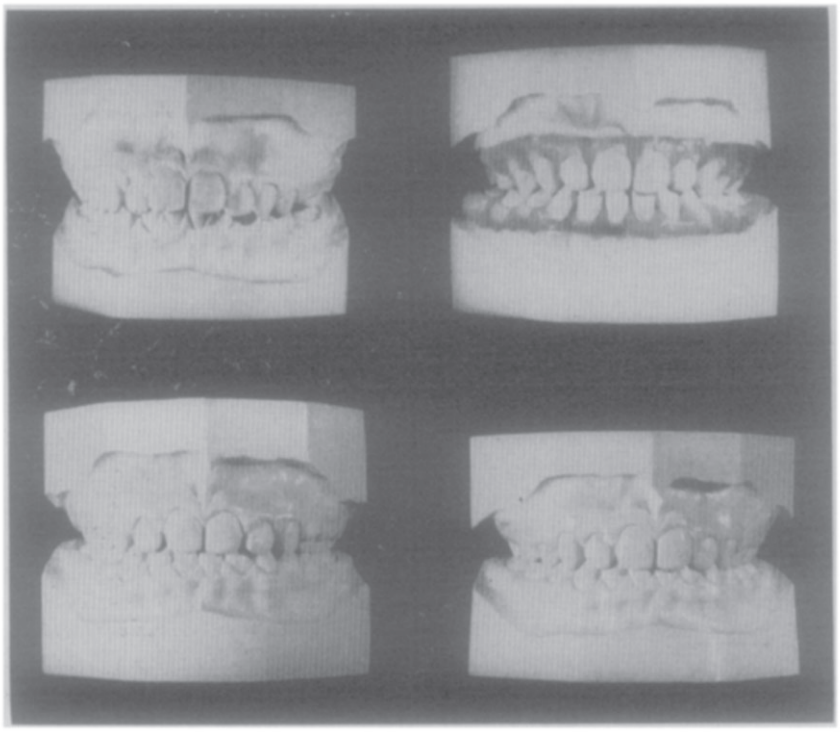

Fig. 9.—Front view. Upper left, original. Upper right, setup model. Lower left, basic treatment. Lower right, finished case.

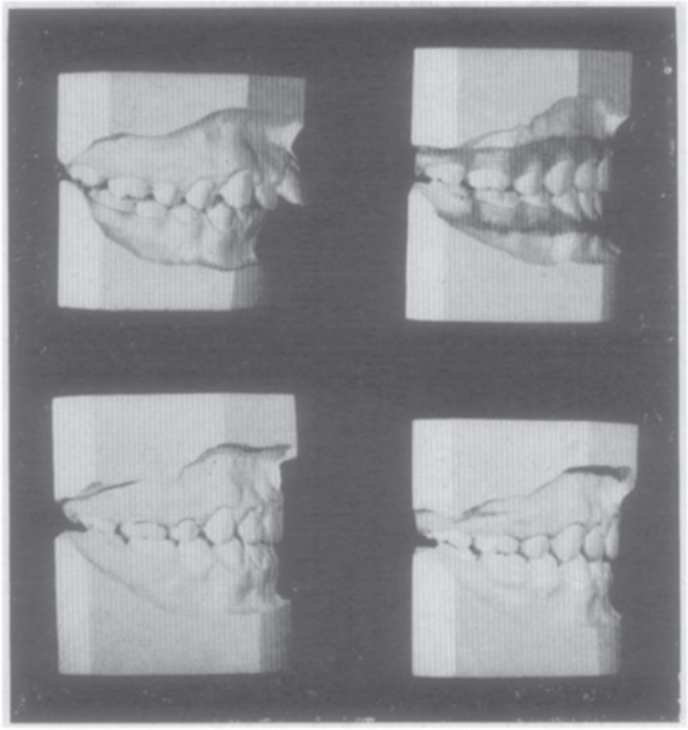

Fig. 10.—Right side. Upper left, original. Upper right, setup model. Lower left, basic treatment. Lower right, finished case.

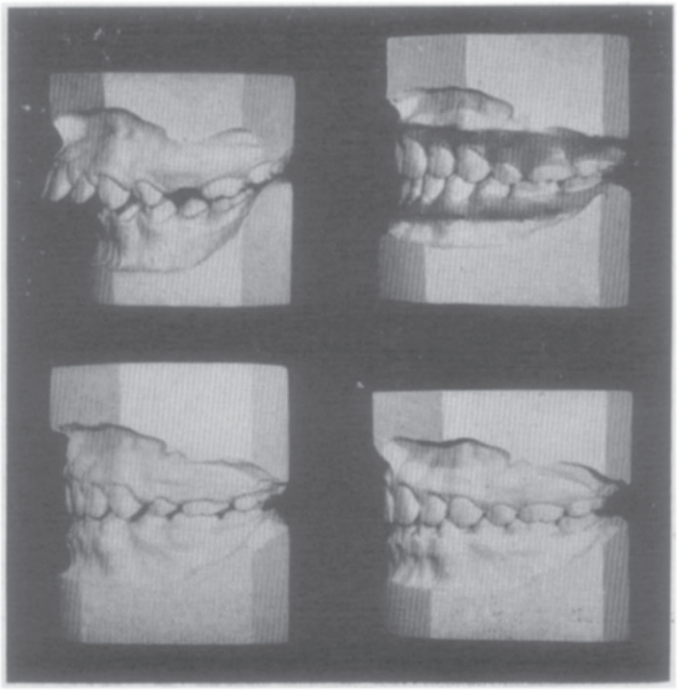

Fig. 11.—Left side. Upper left, original. Upper right, setup model. Lower left, basic treatment. Lower right, finished case.

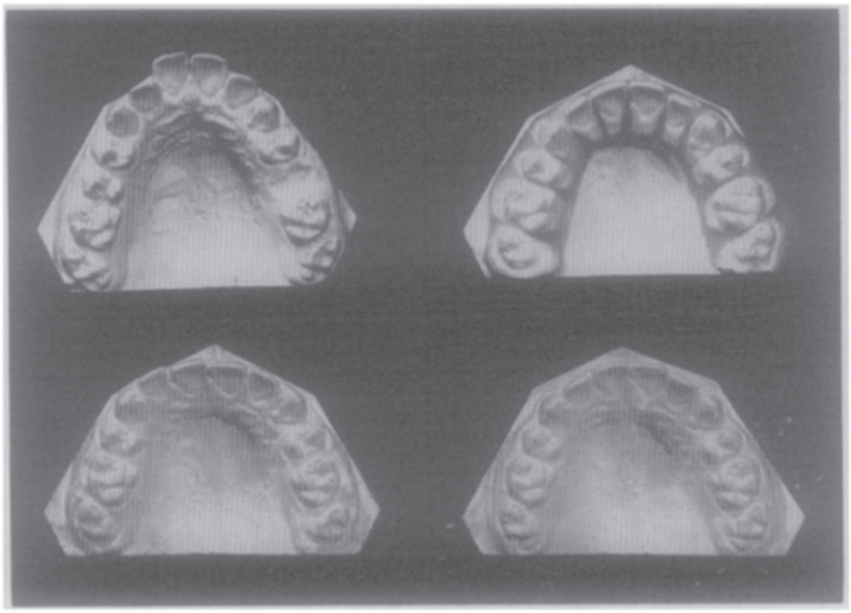

Fig. 12.—Upper occlusal. Upper left, original. Upper right, setup model. Lower left, basic treatment. Lower right, finished case.

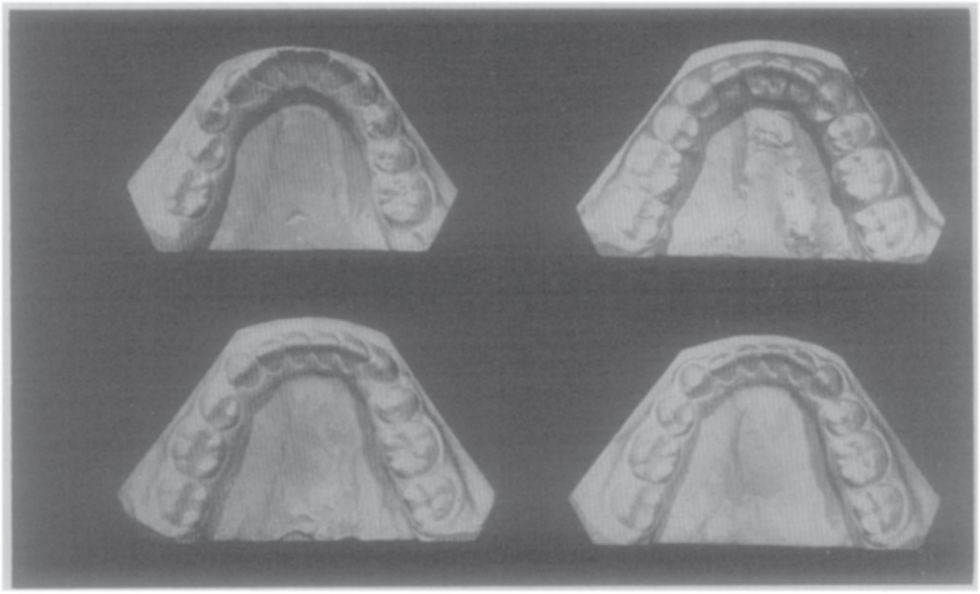

Fig. 13.—Lower occlusal. Upper left, original. Upper right, setup model. Lower left, basic treatment. Lower right, finished case.

adjustments accordingly and allow enough time for this stored-up energy to create tissue changes and desired tooth movements. There is less damage to tissue when we know by a predetermined pattern the desired position of each tooth and through the mechanism carry the tooth only toward that predetermined position.

Major tooth movements are completed when the teeth are properly rotated and approaching their normal axial inclination and interdigitation. It seems entirely unnecessary to prolong conventional treatment after these positions have been accomplished. It is necessary, however, in the case of extractions, to parallel the roots of the teeth that are being moved into the space of an extracted tooth (Fig. 7).

During basic treatment the predetermined pattern should be duplicated in artificial stone and these models used to fabricate a tooth-positioning appliance for the final artistic positioning (Fig. 8). As the end of conventional treatment approaches, the function of the tooth-positioning appliance should be explained, both to the parents and to the child. The patient should be informed of his responsibility with regard to the wearing of this finishing appliance. The operator, the patient, and the parents should collaborate on a definite schedule for the patient's wearing of the Positioner. The patient should practice four hours of exercise wearing daily as well as wearing the Positioner while sleeping at night. To be most effective, the appliance should be placed immediately after the removal of the conventional appliance. At this time the teeth are unstable from active treatment and are susceptible to the gentle forces of the tooth-positioning appliance.

If the Positioner is worn as directed, slight rotations will be corrected, spaces will be reduced, and the arch form and axial positioning of the teeth will approach that of the predetermined pattern in three or four weeks' time. At this time it will be necessary to decide whether the patient is to wear the Positioner as a retainer for a few weeks or whether it is a case that is going to require prolonged retention. If it is the latter, a conventional type of retainer should be constructed and cordinated with the Positioner.

Orthodontic treatment should be instigated at the most opportune time. With the exception of emergency cases this would be when the premolars and permanent canines are erupted. At this time it is possible to develop a predetermined pattern of the case. This will serve as a valuable diagnostic aid, as a guide through basic treatment, and as a form over which the tooth-positioning appliance can be constructed. With the predetermined pattern the operator can more efficiently plan and execute the major tooth movements with fewer appointments and less inconvenience to himself and the patient. Many of the one hundred results to be shown in the clinic session of this meeting have been accomplished with from fifteen to eighteen basic treatment appointments. It seems well within the realm of possibility that in the future most orthodontic cases can be successfully treated with twelve to fifteen basic treatment appointments. This can be accomplished, however, only if the operator first determines his goal and then coordinates all of his efforts toward that end.

910 Indiana Avenue