Fig 26-2 Clinical appearance at the beginning of (*a, b*) and after (*c, d*) Invisalign therapy. The space for aligning the crowded anterior teeth was achieved primarily by posterior IPR prior to taking impressions.

Preliminary Requirements

As stated initially, IPR is often indicated to correct crowding of dental arches. In these and similar situations (eg, protrusions) the question is: should enamel reduction take place before or during treatment?

During ClinCheck, the responsible laboratory technician will recognize the amount of space that needs to be created by IPR—if no other means are indicated. Still, every method has some inherent errors. This means that every treatment can be better staged if most of the enamel reduction is done before the polyvinyl siloxane (PVS) impressions are made (Figs 26-2a to 26-2d). To make sure that not too much enamel is removed, some IPR is left to be performed as prescribed in ClinCheck.

The question then arises: how much enamel must be removed? Orthodontic literature is replete with methods to evaluate crowding.[38–45] Unfortunately, none of these methods is sufficiently reliable. Thus, it is preferable to define the amount of space needed through a modified diagnostic setup (Fig 26-3). During this setup, one tooth is eliminated on both sides (or only a single tooth if all IPR is supposed to take place in the mandibular anterior segment only), and the remaining teeth are optimally aligned within the dental arch. This leaves a space whose size can be compared to the mesiodistal width of the tooth that originally occupied this area. In our view, the difference yields the most accurate amount of IPR that is needed.

Allocation of Interproximal Enamel Reduction

After the required amount of IPR is determined, the clinician must decide on which surfaces it should be carried out. The choice is generally between the anterior and the posterior teeth. Before the decision about the location of IPR is made, the following factors must be considered:

- IPR should take place close to the area where space is required. The advantage of this is that teeth require less movement, and thus the crowding is relieved more quickly. This fact favors IPR mainly in the anterior region.

ClearCorrect Exhibit 1016, Page 272 of 335

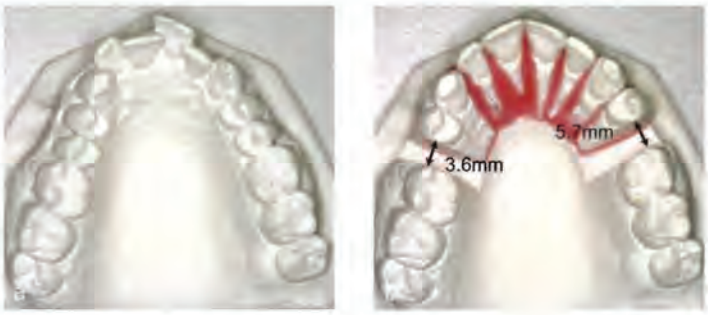

Fig 26-3 (*a*) For this patient, crowding should be corrected primarily by IPR and only by a limited protrusion of the incisors on the right coupled with retrusion on the left. (*b*) Diagnostic setup defines the amount of IPR needed. After arbitrary removal of the two second premolars with a mesiodistal width of 6.8 mm, the remaining space amounts to 3.6 mm on the right and 5.7 mm on the left. Thus, IPR must extend to 3.2 mm on the right side and only to 1.1 mm on the contralateral side.

- IPR between anterior teeth has the added advantage of preventing open gingival embrasures or even eliminating them. It works best, however, if the distance between the contact point and the alveolar crest is less than 6 mm.[28,29,46]
- The main disadvantage to IPR in the anterior area is that it is limited because the enamel layer is relatively thin (Fig 26-4).
- IPR between anterior teeth of just one dental arch changes the Bolton ratio.[6,7] This would be favorable if a discrepancy existed before, but if this is not the case, overjet and overbite will be affected. Of course, the various compensation factors for the Bolton ratio have to be taken into account.[6,7] Given that, the overall Bolton ratio normally varies between 87.5% and 94.8%, considerable tooth-size discrepancies can be compensated by manipulations of angulation and inclination, and by finishing with a modicum of overbite. This means, for example, that for an average total maxillary tooth mass (first molar to first molar) of 96.4 mm,[47] every mandibular width first molar to first molar between 84.4 and 91.4 mm is acceptable. In other words, within this range IPR may be carried out but is not an absolute necessity.

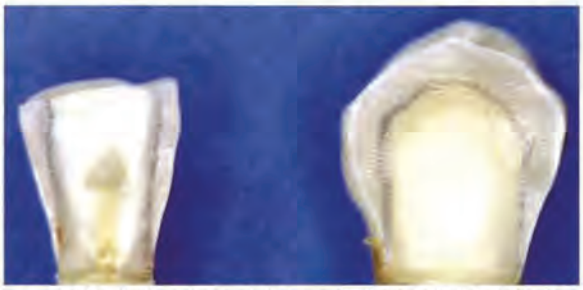

Fig 26-4 Vertical sections at the greatest mesiodistal width of a mandibular incisor (*left*) and a first premolar (*right*) demonstrate the thickness of the enamel layer. The border between enamel and dentin is marked with a pencil line.

- Table 26-1 reflects the amount of enamel that can be safely removed by IPR in the anterior area according to Fillion.[48]
- IPR in the posterior region is favorable because the enamel layer of the premolars and molars is much thicker than that of the anterior teeth (see Fig 26-4, Table 26-2). Thus, much more enamel can be removed without running the risk of mutilating the respective teeth.

Table 26-1 Minimum amount of enamel (mm) that can be removed with IPR in the anterior area*

	Central incisor		Lateral incisor		Canine	
	Mesial	Distal	Mesial	Distal	Mesial	Distal
Maxillary	0.3	0.3	0.3	0.3	0.3	0.6
Mandibular	0.2	0.2	0.2	0.2	0.2	0.3

* *Without additional diagnostic measures (eg, periapical radiographs).*

Table 26-2 Minimum amount of enamel (mm) that can be removed with IPR in the posterior area*

	First premolar		Second premolar		First molar	
	Mesial	Distal	Mesial	Distal	Mesial	Distal
Maxillary	0.6	0.6	0.6	0.6	0.6	0.6
Mandibular	0.6	0.6	0.6	0.6	0.6	0.6

* *Without additional diagnostic measures (eg, periapical radiographs).*

ClearCorrect Exhibit 1016, Page 273 of 335

Fig 26-5 Interproximal caries, which was observed during inspection of the individual bitewings and was accessible after IPR for a minimally invasive restoration.

Fig 26-6 Multiple dumbbell separators were placed by the patient. Since the patient has a Class II, division 2 malocclusion with a 100% overbite, the separation effect is intensified when she bites down.

- IPR in posterior teeth has the disadvantage that more teeth have to be moved over a certain distance before the problem—usually crowding of anterior teeth—is solved. This leads to a prolonged treatment time—a fact any patient should be well informed about. Moreover, the intercuspation changes if IPR is executed only in one dental arch.
- IPR should never be routinely distributed evenly between teeth of any given dental arch region without previous consideration of individual tooth shape and size, with the final goal of a symmetric dentition in mind. Factors like midline deviations should be accounted for.

These arguments make the decision of where to perform the indicated IPR rather demanding. It is generally agreed that half of the normal enamel layer thickness can be removed without any harm. Thus, the question arises as to how thick the layer of enamel of all teeth is. There are respective tables by Hudson,[9] Shillingburg and Grace,[10] and Stroud et al.[49] However, these numbers are of limited use in an individual patient, since one looks at minimum values to be on the safe side (see Tables 26-1 and 26-2).

It might be asked whether periapical radiographs should be taken initially to define the individual enamel layer thickness, especially if more IPR in the anterior area is desirable. Although such an approach can be reasonable in individual situations, it is not generally advisable since all intraoral radiographs give an enlarged image and are of limited sharpness. If teeth are rotated or overlap each other because of existing crowding, radiographs are of no value. Nevertheless, the radiographic records should be carefully examined before IPR is performed to detect any existing abnormalities. Figure 26-5 shows a second premolar with interproximal caries that was accessible after IPR and treated with only minimally invasive procedures. However, the patient was upset that he had not been informed earlier about the manifest caries.

To summarize, Tables 26-1 and 26-2 can help to allocate necessary IPR. If needed, the given amounts can be increased following evaluation of high-quality orthoradial periapical radiographs. Sheridan's rule of thumb that 0.5 mm of enamel can be reduced from practically all anterior interproximal spaces and 1.0 mm from all posterior proximal areas is a helpful guide. Overall, space that can be gained by IPR between the mesial aspects of the first molars amounts to at least 10 mm in the maxillary and almost 9 mm in the mandibular arch.

Preparatory Measures

In situations with severe crowding, it is sometimes difficult, if not impossible, to conduct a judicious IPR because the respective proximal surfaces overlap. This holds especially true for the anterior teeth. Therefore, one must either begin IPR with the usually uncrowded posterior teeth or overcome this problem by separation, as was described by Tuverson as early as 1980.[50] Such a separation could be performed immediately in the orthodontic office, or the patient can start this process at home. The latter is often preferable for both parties because it is less traumatic, since movements of the teeth occur over a longer period (at best, overnight). In such situations the authors use Maxian (dumbbell) separators, which are available in different sizes (Fig 26-6). They are cut into pieces and delivered to the patient, who is taught how to apply them (lending a pair of hemostats is advisable).

ClearCorrect Exhibit 1016, Page 274 of 335

If the separators stay in the mouth overnight, there is sufficient space after their removal the following morning to start a qualified IPR. In patients with severe crowding, it might be necessary to repeat this procedure several times. Under these circumstances, separation starts at the most accessible (ie, the least crowded) area. After the first IPR, the crowding decreases spontaneously, which implies uncontrolled tooth movements. Still, this is a desirable landscape because such "unraveling" facilitates IPR at all proximal surfaces that are considered. Although it would be disadvantageous if the posterior teeth were to come forward and occupy the created space, it is not clinically practical or necessary to place a thermoformed retainer while IPR is still in progress. Therefore, IPR is carried out until sufficient space is created; at this point, the retainer is inserted. In the rare case, however, that separation of posterior teeth becomes necessary, standard O-rings or metal spring separators should be inserted.

If particular teeth are severely angulated, it might be difficult to perform a perfect IPR—especially if the clinician lacks experience. In this situation, it may be advisable to inspect the teeth in question beforehand and mark the area that is to be removed by IPR (Fig 26-7).

Fig 26-7 Patient with a mesially angulated right lateral incisor for which perfect IPR requires sound clinical experience. In such a situation it can be helpful, after separation, to mark the long axis of the tooth and, parallel to it, the enamel area that is to be removed.

Enamel Removal

A plethora of instruments is advocated for IPR; single- or double-sided versions include manually driven abrasive strips of various materials,[30,51] motor-driven abrasive strips,[52–55] abrasive (diamond-coated) disks or oscillating disk segments,[55,56] tungsten carbide burs,[3,48,57] and diamond-coated burs.[3,58,59] Some of the above listed devices are either operated freehand or clamped into a type of holder to improve their effectiveness; others are operated using a contra-angle handpiece.

IPR roughens the enamel surface. The degree of roughness, however, depends primarily on the aggressiveness of the device used.[3] On the other hand, the abrasiveness determines the effectiveness of the procedure. A device that is less abrasive can only do the job when it operates for a much longer time or at a much higher speed. If this method takes an inordinate amount of time, then what is the point? And at times, IPR is so minuscule that the enamel removal cannot be well controlled if it occurs at high speed.

IPR can leave behind a plaque-retentive surface and an increased risk of caries.[59,60] It is crucial, therefore, to produce an enamel surface not rougher than natural, untreated enamel—preferably, even smoother. To achieve this, polishing of the surface is necessary after IPR.[4] Other criteria for selecting the best IPR protocol are safety and reliability, as perfect results must be achieved in every patient.

Our own studies and experiences have led to the protocols described below.[54,58]

IPR in posterior teeth (when more than 0.5 mm enamel is to be removed): A modified ARS technique seems to be most adequate. This is achieved through placement of a tungsten carbide bur (no. 699L) horizontally underneath the interproximal contact point of two adjacent teeth. The bur is then run at high speed (> 100.000 min^{-1}) and pulled with gentle force straight toward the occlusal surfaces. To achieve even surfaces, cutting should not be interrupted. This is done twice, once from the buccal side and once from the lingual side. Considerable heat is generated in this process; therefore, water cooling is highly recommended.

This vertical approach is preferable to a horizontal movement of the bur from the buccal or lingual side, as the bur has a conical shape such that horizontal movement would produce a triangular shape of the proximal area with the contact point far too gingival.

On the other hand, it might be traumatic to place the bur into the interproximal space if it is completely filled by a papilla. To protect the soft tissue, Sheridan has advocated placement of an "indicator wire"—a thick brass wire (0.5 to 0.7 mm) below the bur (on top of the papilla).[12] Unfortunately, the placement and presence of the indicator wire can be painful, and thus its use is not advisable.

IPR is a procedure well tolerated by the patient. In our experience, no patient has complained following the removal of 0.5 mm (or slightly more) enamel.

ClearCorrect Exhibit 1016, Page 275 of 335

Fig 26-8 Perforated oscillating disk segment during IPR. It is obvious that the visibility through the segment is excellent, and no safeguard is needed.

Fig 26-9 The authors' preferred device for measuring the amount of enamel reduction: a gauge for spark plugs. This gauge includes 20 blades and can measure spaces 0.05 to 1.00 mm wide.

IPR in anterior teeth: This can be accomplished most effectively with very thin (0.1 mm), flexible, diamond-coated perforated disks spinning at 10,000 min^{-1} or by oscillating disk segments at 5,500 min^{-1}. Rotating disks must be operated with a safeguard. If the disk is perforated, the visibility of the working field is excellent. To prevent aspiration of airborne cooling water mixed with intraoral bacteria, staff members must wear facemasks and protective goggles. The patient should also be covered. In the event that separation was not sufficient or not performed, it may be prudent to start with lightening strips. After access is created, the remaining cutting can take place with the disk as described above.

Oscillating segmental disks are favored (Fig 26-8). These differ from conventional disks in that they oscillate 30 degrees at 5,500 min^{-1}. The oscillating disk segments have two major advantages: they are unlikely to cut the lip and tongue and, therefore, do not require safeguards, and they are much smaller than full disks and thus are unlikely to cut any antagonist teeth.

Independent of the region where IPR is to take place, three aspects need to be considered:

1. Whenever a natural and an artificial tooth surface neighbor each other, the restorative surface should be preferred for reduction—either entirely or at least to a greater extent.
2. If IPR is only indicated at one of two adjacent tooth surfaces, it is difficult to leave one completely untouched. In such a situation, it is advisable to place a steel matrix over the surface to be protected or use single-sided disks or disk segments.
3. Most important, however, is the question, should IPR be performed before the PVS impressions are made and before any treatment is started, or should it be performed during treatment as prescribed by ClinCheck? The answer depends on the amount of enamel that is to be removed. If the amount is relatively small (less than 1.5 mm), IPR could be performed during therapy. More extensive IPR should take place up front. In other words, the more accurately the tooth morphology is reflected in the impression, and thus in the virtual model, the more precise the treatment outcome prediction can be. If IPR is executed before PVS impressions are made, the following points should be considered:

- Stay about 0.3 mm short of the necessary IPR. This approach prevents overextended enamel removal as well as residual spacing between teeth at the end of treatment. In a case with minimally sufficient IPR, it is left to ClinCheck technicians to disclose any possible collisions between teeth. Naturally, at every visit, contacts between the moving teeth should be checked with dental floss and, if tight, minimal IPR may be performed.
- Once the preimpression IPR is done, a thermoformed retainer must be placed.
- Information should be given in the Special Instructions section of the treatment planning form so that the

ClearCorrect Exhibit 1016, Page 276 of 335

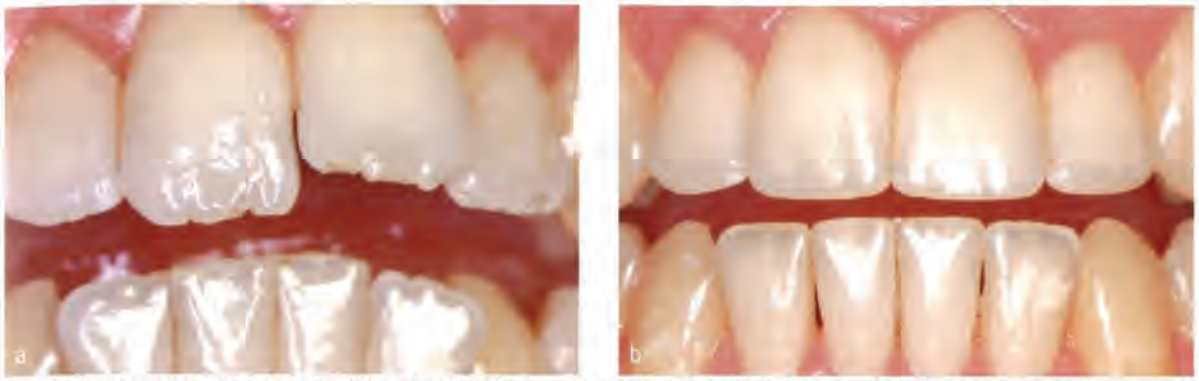

FIG 26-10 Incisors before (*a*) and after (*b*) treatment, including recontouring of the incisal edges, which were characterized by mammelons as a result of the existing open bite.

technician will not interpret the observed space for imperfections in the impression. Concurrently, it is crucial to submit intraoral photographs taken immediately after the IPR.

Measuring the Amount of Enamel Removal

To prevent excessive enamel removal, IPR should be initiated with a cutting device that is thinner than the amount of enamel to be removed. Thus, the amount of IPR and created space needs to be measured repeatedly. There is a multitude of measuring devices, from very simple sliding calipers to elaborate and costly ones, as presented by Sheridan and Hastings.[61] Each has its advantages. For a device to be practical for IPR, it should fulfill four conditions: simplicity of use (ie, applicable in all areas of the dental arch); measurement gradations from 0.1 mm to at least 1.2 mm, with all steps in between; sterilizability; and reasonable cost.

These requirements are fulfilled mainly by two devices. The first is a simple series of wires with various diameters. To distinguish them from one another, one end can be bent into the respective digit, or each is identified by a small numbered tag as suggested by Philippe,[62] or one end can be covered with a plastic tube that is inscribed with the diameter of the wire.

The second, even more practical, device is a measuring gauge used for spark plugs, which can be bought from any automotive supply store (Fig 26-9). Common gauges allow measurement of any gap between 0.1 and 2.0 mm, with increments of 0.1 mm. If the individual gauge also contains a blade of 0.05 mm thickness, all measurements can be further refined. The main disadvantage of these gauges is that they are generally not made out of stainless steel but rather from an inferior alloy. Thus, if they are sterilized, they will corrode. This can be overcome by a thorough disinfection followed by wrapping the individual blades with fine plastic or metal foil.

Once the IPR procedure has started, the orthodontist should repeatedly insert the gauge into the created gap until it slides easily in and out. To avoid removing too much enamel, it is advisable to use a blade (combination) that is 0.1 mm smaller than the intended IPR value. The last 0.1 mm is removed by the recontouring and polishing process.[58]

Contouring of Teeth After Interproximal Enamel Reduction

After removal of interproximal enamel, the individual teeth are recontoured to give them a natural look. This is especially necessary for posterior teeth and maxillary incisors,[20] whereas for mandibular incisors this procedure can often be omitted. The contouring is best performed with fine (red ring) diamond-coated burs of various shapes, preferably ones that have a blank (not coated) tip. This guiding—polished, nonabrasive—tip, when moved buccolingually, helps level any surface irregularities, since it does not cut additional enamel. Sufficient water cooling is mandatory. The length of time needed for a perfect recontouring should not be underestimated.

ClearCorrect Exhibit 1016, Page 277 of 335

Fig 26-11 Enamel polishing with a Sof-Lex XT disk. Because of its flexibility, it can be directed into various areas to create a smooth transition from treated to untreated surfaces.

Polishing of Teeth After Interproximal Enamel Reduction

Polishing of all manipulated tooth surfaces is the next step. Irrespective of the devices used, the shaved surface will display furrows up to 40 µm wide and deep. Such rough surfaces accumulate plaque more readily and increase the risk for caries or periodontal disease.[60,63,64] To achieve perfectly polished enamel, it is crucial to avoid coarse instruments from the beginning.[3,51]

As with enamel cutting, a variety of polishing instruments and methods are described in the literature. Several studies[3,55,56,58,65] prove that with careful polishing the previously rough surface can be made very smooth (Fig 26-10). In an investigation by Zhong et al,[58] a minimum of 94% of all polished surfaces at the various heights of the interproximal space were smoother than untreated enamel in vivo. This was also true for the remaining 6%, where a few isolated furrows of up to 3 µm in depth could be observed. In commenting on this study, Zachrisson wrote, "The satisfactory result should relieve the orthodontist of any apprehension about inducing a carious environment in areas treated by enamel reduction."[4]

This was accomplished by using two extra-thin polishing disks with different surface coating (Sof-Lex XT fine and ultrafine, 3M), each attached to a handpiece, for 40 seconds with water cooling at 4,000 min^{-1}. Instead of water cooling, fluoride gel can be used. Many other techniques and variations were tested, but none produced results of a comparable quality within the same amount of time.

Even if polishing with the Sof-Lex disks produces a superior smoothness of the enamel surface, it has to be pointed out that because of the small size of the Sof-Lex disks (radius: approximately 6.5 mm), it can be difficult in large teeth to polish all treated surfaces. The disk must therefore be introduced from different angles. Such a maneuver does not present a problem because the extra-thin Sof-Lex disks are extremely flexible (Fig 26-11). This flexibility also helps to accomplish a smooth transition from the surfaces that have been worked on to the natural enamel. It should be mentioned that intensive use of a polishing disk leads to its rapid degradation. Thus, every disk has to be discarded after use on one patient.

Is it essential to use the micro motor of the dental unit for polishing, or can the same result be accomplished manually? The answer is that enamel smoothness is the result of the distance a polishing medium has traveled over a tooth surface. A simple test shows that an abrasive strip is moved an average of 10 mm. With full concentration, a clinician can jiggle such a strip 140 times/minute. Thus, after 40 seconds the polishing distance amounts to 1.87 m. On the other hand, considering the working range of a polishing disk is about 4.5 mm from its center (not at the outer edge, which would make the calculation even more stunning), it travels with one rotation ($2\pi r$) 28 mm. At a speed of 4,000 min^{-1}, the polishing surface has traveled 75.4 m after 40 seconds. Obviously, machine polishing is more than 40 times more effective than any manual method. Put differently, to produce a comparable surface texture, the manual polishing time must be extended to almost 27 minutes—not considering whether the polishing strip would last that long and whether it would need to be changed, or whether the manual speed could be maintained over this time. The answer, then, to whether manual polishing can achieve the same result as polishing with the micro motor is simply, no!

Another question relates to the fact that all teeth have a physiologic mobility: could the roughness after IPR reduce itself through a naturally induced polishing? Radlanski et al investigated this question and found that after 1 year only a very limited area of the previously reduced enamel achieved even a slight smoothness.[66] The answer to this second question, then, is also no: self-polishing after IPR cannot be expected.

ClearCorrect Exhibit 1016, Page 278 of 335

Fluoridation

Even if polishing has been performed with all required care, some furrows might remain and enhance plaque accumulation. This remains a theoretical possibility[37,67] and should not be ignored—especially since the most fluoridated enamel layer is removed with IPR.[68–70] Removal by itself is not significant, as the fluoride concentration of the new outermost enamel layer is increased by saliva and can be further increased by fluoride-containing substances.[71–75] Incorporation of fluorine increases the microhardness of the enamel surface[76] and may actually result in an enamel structure that is more caries-resistant than the original surface layer.[77] Zachrisson recommends twice-daily mouth rinsing with a weak fluoride solution; he considers special topical fluoridation superfluous.[4] His opinion was substantiated by a long-term study[4] over more than 10 years that did not reveal any adverse effects of IPR in a group of 59 consecutive orthodontic patients. El-Mangoury et al even concluded that enamel after IPR remineralized spontaneously without an increased pathological caries risk.[78]

Although it is generally agreed that low-concentration fluoride preparations over longer time periods are ideal,[72,73,79] higher concentrations also achieve this goal, as more calcium fluoride is precipitated if higher fluoride concentrations are applied.[75,80,81] Furthermore, it is known that about 10% of patients do not comply with the instructions.[82] It is best to apply a higher-concentration fluoride topically[30] and advise the patient to use fluoride-impregnated floss, fluoridated toothpaste applied with a toothpick, fluoride-containing sugar-free chewing gum, or one of the following: daily fluoride tablets, fluoridated cooking salt, weak fluoride mouth rinses, or fluoride gel once a week.[83] Where available, amine fluoride has a better effect than other formulations.[74,84,85] For topical fluoridation, there are further alternatives: highly concentrated fluoride varnishes, less concentrated fluoride solutions and gels (eg, Elmex fluid and gel, GABA International), and fluoride- and thymol-containing varnish. In the future slow-release formulations[76] that enhance fluoride uptake in deeper enamel layers may also be considered.[86] Finally, it should be noted that aligners can be used as appropriate fluoride-preparation carriers.

Advantages and Disadvantages of Interproximal Enamel Reduction

The clinician may still wish to extract premolars in severe crowding cases, but IPR has its place. IPR transforms a crowded dentition into one with spacing that is thus easier to treat. Careful IPR never produces more space than is necessary, in stark contrast to premolar extraction therapy. Further, if crowding is resolved without IPR, open gingival embrasures can hardly be avoided in adult patients with long clinical crowns, particularly if they suffer from gingival recession.[46,87]

Finally, IPR is patient friendly, as demonstrated in the study by Zhong et al, in which 32 consecutive patients with 296 treated surfaces completed an anonymous questionnaire.[58] On a discomfort scale ranging from 1 (no discomfort) to 10 (pain), 81% selected grades 1 to 3. The remaining patients mainly reported minor trauma of the interproximal papilla, which is often a side effect of IPR. None of the patients said they would choose local anesthesia for further IPR.

The main disadvantage of IPR is that, if performed with adequate precision, it consumes a good amount of the clinician's time. A time study showed that high-quality IPR takes approximately 2.2 minutes per tooth surface with the change of various instruments. This time may be reduced by clinical experience, but likely not by much. Other disadvantages include removal of the most-fluoridated enamel layer and the inevitable slight gingival traumas. Finally, it is sometimes a challenge to overcome a patient's concern regarding IPR. The rationale we use is mainly that IPR is the reproduction of a physiologic process that no longer occurs because of changed nutritional habits.

References

1. Meier B, Wiemer KB, Miethke RR. Invisalign—Patient profiling. Analysis of a prospective survey. J Orofac Orthop 2003;64:352–358.
2. Pinheiro MLRM. Interproximal enamel reduction. World J Orthod 2002;3:223–232.
3. Piacentini C, Sfondrini G. A scanning electron microscopy comparison of enamel polishing methods after air-rotor stripping. Am J Orthod Dentofacial Orthop 1996;109:57–63.
4. Zachrisson BU. Actual damage to teeth and periodontal tissues with mesiodistal enamel reduction ("stripping"). World J Orthod 2004;5:178–183.
5. Ballard ML. Asymmetry in tooth size: A factor in the etiology, diagnosis, and treatment of malocclusion. Angle Orthod 1944;14:67–71.

ClearCorrect Exhibit 1016, Page 279 of 335

6. Bolton WA. Disharmony of tooth size and its relation to the analysis and treatment of malocclusion. Angle Orthod 1958;28:113–130.
7. Bolton WA. The clinical application of a tooth-size analysis. J Dent Res 1962;48:504–529.
8. Begg PR. Stone Age man's dentition. J Dent Res 1954;40:298–312, 373–383, 462–475, 517–531.
9. Hudson AL. A study of the effects of mesiodistal reduction of mandibular anterior teeth. J Dent Res 1956;42:615–624.
10. Shillingburg HT Jr, Grace CS. Thickness of enamel and dentin. J South Calif Dent Assoc 1973;41(1):33–36.
11. Rogers GA, Wagner MJ. Protection of stripped enamel surfaces with topical fluoride applications. J Dent Res 1969;56:551–559.
12. Sheridan JJ. Air-rotor stripping. J Clin Orthod 1985;19:43–59.
13. Sheridan JJ. Air-rotor stripping update. J Clin Orthod 1987;21:781–788.
14. Joseph VP, Rossouw PE, Basson NJ. Orthodontic microabrasive reproximation. Am J Orthod Dentofacial Orthop 1992;102:351–359.
15. Rossouw PE, Tortorella A. A pilot investigation of enamel reduction procedures. J Can Dent Assoc 2003;69:384–388.
16. Kelsten LB. A technique for realignment and stripping of crowded lower incisors. J Pract Orthod 1969;3(2):82–84.
17. Paskow H. Self-alignment following interproximal stripping. J Dent Res 1970;58:240–249.
18. Peck H, Peck S. An index for assessing tooth shape deviations as applied to the mandibular incisors. J Dent Res 1972;61: 384–401.
19. Peck H, Peck S. Crown dimensions and mandibular alignment. Angle Orthod 1972;42:148–153.
20. Tuverson DL. Anterior interocclusal relations. Part II. J Dent Res 1980;78:371–393.
21. Lusterman EA. Treatment of a Class II Division 2 malocclusion involving mesiodistal reduction of mandibular anterior teeth. J Dent Res 1954;40:44–50.
22. Ley M, Muller-Hartwick R, Jost-Brinkmann PG. Approximale Schmelzreduktion. Wann und wie? Inf Orthod Kieferorthop 2005;37:2–4.
23. Begg PR, Kesling PC. Begg Orthodontic Theory and Practice, ed 3. Philadelphia: Saunders, 1977.
24. Boese LR. Fiberotomy and reproximation without lower retention 9 years in retrospect: Part II. Angle Orthod 1980;50:169–178.
25. Alexander RG, Sinclair PM, Goates LJ. Differential diagnosis and treatment planning for the adult nonsurgical orthodontic patient. J Dent Res 1986;89:95–112.
26. DiPaolo RJ, Boruchov MJ. Thoughts on stripping of anterior teeth. J Clin Orthod 1971;5:510–511.
27. Sheridan JJ, Ledoux PM. Air-rotor stripping and proximal sealants. An SEM evaluation. J Clin Orthod 1989;23:790–794.
28. Kurth JR, Kokich VG. Open gingival embrasures after orthodontic treatment in adults: Prevalence and etiology. Am J Orthod Dentofacial Orthop 2001;120:116–123.
29. Atherton JD. The gingival response to orthodontic tooth movement. J Dent Res 1970;58:179–186.
30. de Harfin JF. Interproximal stripping for the treatment of adult crowding. J Clin Orthod 2000;34:424–433.
31. Lashar MC. A consideration of the principles of mechanical arches as applied to the dental arch. Angle Orthod 1943;4:248–268.
32. Williams R. Eliminating lower retention. J Clin Orthod 1985;19:342–349.
33. Betteridge MA. The effects of interdental stripping on the labial segments evaluated one year out of retention. Br J Orthod 1981;8:193–197.
34. Kramer GM. A consideration of root proximity. Int J Periodontics Restorative Dent 1987;7(6):8–33.
35. Philippe J. De l'harmonie entre la taille des dents et celle des arcades. Rev Orthop Dento Faciale 2004;38:37–51.
36. Årtun J, Kokich VG, Osterberg SK. Long-term effect of root proximity on periodontal health after orthodontic treatment. Am J Orthod Dentofacial Orthop 1987;91:125–130.
37. Crain G, Sheridan JJ. Susceptibility to caries and periodontal disease after posterior air-rotor stripping. J Clin Orthod 1990;24:84–85.
38. Musich DR, Ackerman JL. The catenometer: A reliable device for estimating dental arch perimeter. J Dent Res 1973;63:366–375.
39. Beazley WW. Assessment of mandibular arch length discrepancy utilizing an individualized arch form. Angle Orthod 1971;41(1): 45–54.
40. Kinast H. Herstellungstechnische Grundlagen des Arcumeters und sein Gebrauch. J Orofac Orthop 2000;61:297–304.
41. Nance HN. The limitations of orthodontic treatment. I. Mixed dentition diagnosis and treatment. Am J Orthod Oral Surg 1947;33:177–223.
42. Nance HN. The limitations of orthodontic treatment. II. Diagnosis and treatment in the permanent dentition. Am J Orthod Oral Surg 1947;33: 253–301.
43. Carey CW. Treatment planning and the technical program in the four fundamental treatment forms. J Dent Res 1958;44:887–898.
44. Moorrees CFA. The dentition of the growing child. A longitudinal study of the dental development between 3 and 18 years of age. Cambridge: Harvard University Press, 1959.
45. Lundström A. The significance of early loss of deciduous teeth in the etiology of malocclusion. J Dent Res 1955;41:819–826.
46. Wu YJ, Tu YK, Huang SM, Chan CP. The influence of the distance from the contact point to the crest of bone on the presence of the interproximal dental papilla. Chang Gung Med J 2003;26: 822–828.
47. Miethke RR. Zahnbreiten und Zahnbreitenkorrelationen [thesis]. Berlin, 1972.
48. Fillion D. Vor- und Nachteile der approximalen Schmelzreduktion. Teil II. Inf Orthod Kieferorthop 1995;27:64–90.
49. Stroud JL, English J, Buschang PH. Enamel thickness of the posterior dentition: Its implications for nonextraction treatment. Angle Orthod 1998;68:141–146.
50. Tuverson DL. Anterior interocclusal relations. Part I. J Dent Res 1980;78:361–370.
51. Lundgren T, Milleding P, Mohlin B, Nannmark U. Restitution of enamel after interdental stripping. Swed Dent J 1993;17:217–224.
52. Hugo B, Lussi A, Gygax M. Anwendungen des EVA-Systems (II). Schweiz Monatsschr Zahnmed 1991;101:1587–1592.
53. Gygax M, Lussi A, Hugo B. Anwendungen des EVA-Systems (I). Schweiz Monatsschr Zahnmed 1991;101:1429–1434.
54. Hugo B, Lussi A, Hotz P. The preparation of enamel margin beveling in proximal cavities [in German]. Schweiz Monatsschr Zahnmed 1992;102:1181–1188.
55. Hein C, Jost-Brinkmann PG, Schillai G. The enamel surface quality after interproximal stripping—A scanning electron microscopic assessment of different polishing procedures [in German]. Fortschr Kieferorthop 1990;51:327–335.
56. Zhong M, Jost-Brinkmann PG, Radlanski RJ, Miethke RR. SEM evaluation of a new technique for interdental stripping. J Clin Orthod 1999;33:286–392.
57. Lucchese A, Porcu F, Dolci F. Effects of various stripping techniques on surface enamel. J Clin Orthod 2001;35:691–695.
58. Zhong M, Jost-Brinkmann PG, Zellmann M, Zellmann S, Radlanski RJ. Clinical evaluation of a new technique for interdental enamel reduction. J Orofac Orthop 2000;61:432–439.

ClearCorrect Exhibit 1016, Page 280 of 335

59. Leclerc JF. Etat de la surface de l'email apres remodelage amelaire proximal? Etude au microscope electronique. J l'Edgewise 1992;25: 25–33.
60. Radlanski RJ, Jäger A, Schwestka R, Bertzbach F. Plaque accumulations caused by interdental stripping. Am J Orthod Dentofacial Orthop 1988;94:416–420.
61. Sheridan JJ, Hastings J. Air-rotor stripping and lower incisor extraction treatment. J Clin Orthod 1992;26:18–22.
62. Philippe J. A method of enamel reduction for correction of adult arch-length discrepancy. J Clin Orthod 1991;25:484–489.
63. Swartz ML, Phillips RW. Comparison of bacterial accumulation on rough and smooth enamel surfaces. J Periodontol 1967;28:304–307.
64. Arends J, Christofferson J. The nature of early carious lesions in enamel. J Dent Res 1986;65:2–11.
65. Jost-Brinkmann PG, Otani H, Nakata M. Surface condition of primary teeth after approximal grinding and polishing. J Clin Pediatr Dent 1991;16:41–45.
66. Radlanski RJ, Jäger A, Zimmer B. Morphology of interdentally stripped enamel one year after treatment. J Clin Orthod 1989;23:748–750.
67. Kapur K, Fischer EE, Manly RS. Effect of surface alteration of permeability of enamel to a lactate buffer. J Dent Res 1961;40: 1174–1182.
68. Joseph VP, Rossouw PE, Harris AM, Adams L. Stereometric evaluation of the enamel-stripping effect of hydrochloric acid. J Clin Orthod 1992;26:761–764.
69. Keene HJ, Mellberg JR, Pederson ED. Relationship between dental caries experience and surface enamel fluoride concentration in young men from three optimally fluoridated cities. J Dent Res 1980;59:1941–1945.
70. Konttinen ML, Hanhijarjvi H. Fluoride concentrations of the surface enamel of children living in an optimally fluoridated community. Scand J Dent Res 1986;94:427–435.
71. Amaechi BT, Higham SM. In vitro remineralisation of eroded enamel lesions by saliva. J Dent 2001;29:371–376.
72. Inaba D, Kawasaki K, Iijima Y, et al. Enamel fluoride uptake from mouthrinse solutions with different NaF concentrations. Community Dent Oral Epidemiol 2002;30:248–253.
73. Kashani H, Birkhed D, Petersson LG. Fluoride concentration in the approximal area after using toothpicks and other fluoride-containing products. Eur J Oral Sci 1998;106:564–570.
74. Mok Y, Hill FJ, Newman HN. Enamel fluoride uptake affected by site of application: Comparing sodium and amine fluorides. Caries Res 1990;24:11–17.
75. Lagerweij MD, ten Cate JM. Remineralisation of enamel lesions with daily applications of a high-concentration fluoride gel and a fluoridated toothpaste: An in situ study. Caries Res 2002;36: 270–274.
76. Bottenberg P, Cleymaet R, Rohrkasten K, Lampert F. Microhardness changes in surface enamel after application of bioadhesive fluoride tablets in situ. Clin Oral Investig 2000;4:153–156.
77. Iijima Y, Koulourides T. Fluoride incorporation into and retention in remineralized enamel. J Dent Res 1989;68:1289–1292.
78. el-Mangoury NH, Moussa MM, Mostafa YA, Girgis AS. In-vivo remineralization after air-rotor stripping. J Clin Orthod 1991;25:75–78.
79. Featherstone JD, Glena R, Shariati M, Shields CP. Dependence of in vitro demineralization of apatite and remineralization of dental enamel on fluoride concentration. J Dent Res 1990;69(special issue):620–625.
80. Hellwig E, Lussi A. What is the optimum fluoride concentration needed for the remineralization process? Caries Res 2001;35(suppl 1):57–59.
81. Øgaard B. CaF2 formation: Cariostatic properties and factors enhancing the effect. Caries Res 2001;35:40–44.
82. Geiger AM, Gorelick L, Gwinnett AJ, Benson BJ. Reducing white spot lesions in orthodontic populations with fluoride rinsing. Am J Orthod Dentofacial Orthop 1992;101:403–407.
83. Heintze SD, Jost-Brinkmann P-G, Finke C, Miethke R-R. Oral Health for the Orthodontic Patient. Chicago: Quintessence, 1998.
84. Chan JC, Hill FJ, Newman HN. Uptake of fluoride by sound and artificially carious enamel in vitro following application of topical sodium and amine fluorides. J Dent 1991;19:110–115.
85. Petzold M. The influence of different fluoride compounds and treatment conditions on dental enamel: A descriptive in vitro study of the CaF2 precipitation and microstructure. Caries Res 2001; 35(suppl 1):45–51.
86. Capilouto ML, DePaola PF, Gron P. In vivo study of slow-release fluoride resin and enamel uptake. Caries Res 1990;24:441–445.
87. Burke S, Burch JG, Tetz JA. Incidence and size of pretreatment overlap and posttreatment gingival embrasure space between maxillary central incisors. Am J Orthod Dentofacial Orthop 1994;105: 506–511.

ClearCorrect Exhibit 1016, Page 281 of 335

chapter 27

Facial Esthethic Examination and Analysis

by
Marc B. Ackerman, DMD

ClearCorrect Exhibit 1016, Page 283 of 335

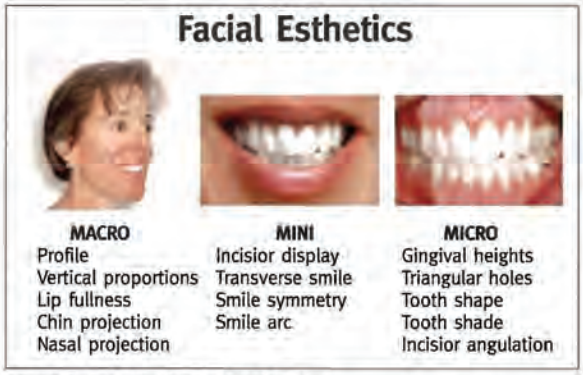

FIG 27-1 Facial esthetic classification.

The first 100 years of treatment planning in orthodontics were based on measurements taken from a system of static records, with the primary goal of treatment aimed at the attainment of a tooth-centered, occlusal model. A significant shortcoming of this focus on measurements from hard tissue anatomic elements from the lateral cephalogram and plaster study casts was that clinicians did not take into account the esthetics of resting and dynamic soft tissue relationships, which is regarded by patients as the most critical aspect in treatment planning. Orthodontics in the 21st century utilizes enhancement technologies with a range of techniques aimed not only at correcting the patient's functional deficiencies or treating his or her "disease," but also at improving the esthetic appearance of the face and in particular the smile.[1,2] Systematized patient examination and esthetic treatment planning with the Invisalign System are the focus of this chapter.

Contemporary Facial Esthetic Treatment Planning

Problem-oriented treatment planning, with its focus on the identification of problems and their possible solutions, has served orthodontists very well in the last several decades. Problem-oriented treatment planning should now include the identification of favorable attributes as well as the identification of problems. The sole emphasis on patient problems and their solutions may result in a treatment plan that has a potentially negative effect on the esthetic elements of that patient. A classic example is the extraction of maxillary premolars in the correction of a skeletal Class II malocclusion, which, while satisfying functional and occlusal issues, may produce an unfortunate effect on nasal and lip esthetics in profile. The goal of orthodontic treatment is minimization of a patient's negative attributes and preservation of attributes that are esthetically favorable.

Facial esthetics can be divided into three subcategories: macroesthetics, miniesthetics, and microesthetics (Fig 27-1). The specific concerns of the patient can be elucidated through open-ended clinician-patient communication and then integrated into the diagnostic decision tree. The physical burden of treatment is borne by the patient and must be weighed in determining the extent of intervention. A systematic approach to clinical examination of the patient is essential for the development of an optimization-oriented database.

Data Collection

Primary data collection begins at the clinical examination and is supplemented with static and dynamic recordings of the patient in three spatial dimensions. Record taking should replicate the functional and esthetic presentation of the patient. Findings from the clinical examination should either be confirmed or challenged by data obtained from the records. Analysis of the clinical database generates a diagnostic summary and optimized problem list. An emerging soft tissue paradigm[3] in orthodontic treatment planning has refocused analysis on facial proportionality and balance versus reliance on normative data derived from cephalometrics. The art of esthetic treatment planning in orthodontics lies in the clinician's ability to envisage the patient's desired three-dimensional (3-D) soft tissue outcome and then to engineer the dental and skeletal hard tissues to produce such a change.

In today's clinical environment there are three methods of data collection. The first and most commonly used method includes still photography, study casts, and cephalometric radiographs. The second is the use of databasing programs to document direct clinical measurement of the patient's resting and dynamic relationships. The third involves the use of digital video to record the dynamics of facial movement.

Conventional records

Standard orthodontic records have not changed significantly in many years. In clinical practice, standard records include film or digital photographs, radiographs, and study casts (whether plaster, mounted or unmounted, or

ClearCorrect Exhibit 1016, Page 284 of 335

Fig 27-2 Conventional views: (*a*) frontal portrait photograph at rest, closed lips; (*b*) frontal portrait photograph on smile; (*c*) profile portrait photograph, closed lips.

Fig 27-3 Supplemental view: oblique (45-degree) portrait photograph on smile.

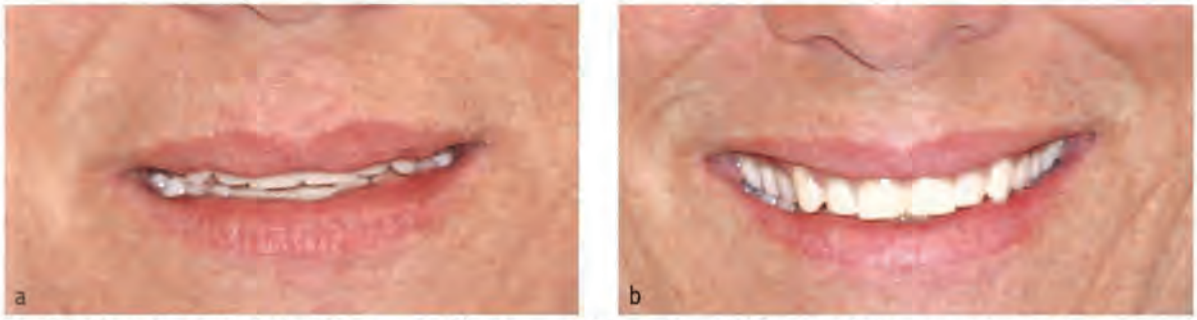

Fig 27-4 Views for direct facial measurements: (*a*) philtrum and commissure height, interlabial gap, and incisor display at rest; (*b*) philtrum and commissure height, interlabial gap, and incisor/gingival display on social smile.

electronic models). The facial images, which are universally considered standard records, include frontal at rest, frontal smile, and profile-at-rest images (Figs 27-2a to 27-2c). While these orientations do provide an adequate amount of diagnostic information, they do not contain all of the information needed for 3-D visualization and quantification. Ideally, supplemental images should be taken in the oblique or three-quarter view (Fig 27-3).

Direct facial measurement

The goal of the clinical examination is to quantitatively assess soft and hard tissue attributes of the dentofacial complex and record what elements are satisfactory and which are in need of optimization. Measurement should be thorough, systematic, and consistent—and should minimize the chance that something of importance will be overlooked.

Contemporary clinical examination uses a computer-databasing program to facilitate data entry. These data are then merged into reports and treatment planning screens or forms.[4] By using a computer database, the orthodontist saves valuable time both in the clinical examination and in the diagnostic and treatment planning workup. The information is stored for recall and analysis and can even have predefined parameters that identify problematic measurements automatically.

The following frontal measurements should be performed systematically in evaluation of anterior dental display, both at rest and on smile (Figs 27-4a and 27-4b): philtrum height, commissure height, interlabial gap, amount of incisor display at rest, amount of incisor display on smile, crown height, gingival display, and smile arc.

The philtrum height is measured in millimeters from the subnasale (the base of the nose at the midline) to the most inferior portion of the upper lip on the vermilion tip beneath the philtral columns. In the adolescent, it is common to find the philtrum height to be shorter than the commissure height, and the difference can be explained in the differential in lip growth with maturation.

The commissure height is measured from a line constructed from the alar base through the subspinale, then from the commissures perpendicular to this line.

The interlabial gap is the distance in millimeters between the upper and lower lips.

ClearCorrect Exhibit 1016, Page 285 of 335

Fig 27-5 The smile arc is best visualized in the oblique view.

Fig 27-6 Digital videography affords the clinician multiple frames for evaluation of lip-tooth relationships during speech and smiling.

The amount of maxillary incisor display at rest is a critical esthetic parameter because one of the inevitable characteristics of an aging tooth-lip relationship is diminished maxillary incisor display at rest and on smile. For example, an adult patient with 3 mm of gingival display on smile and 3 mm of maxillary incisor display at rest should only carefully consider maxillary incisor intrusion to reduce gingival display, since reduction in gingival display also results in diminished incisor show at rest and during conversation (a characteristic of the aging face). When smiling, patients will either show the entire maxillary incisor or only a percentage of the incisor. Measurement of the percentage of incisor display, when combined with the crown height, helps the clinician decide how much tooth movement is required to attain the appropriate smile for that patient.

The vertical (crown) height of the maxillary central incisors in the adult is normally between 9 and 12 mm, with an average of 10.6 mm in men and 9.6 mm in women. The age of the patient is a factor in crown height because of the rate of gingival apical migration in the adolescent.

The amount of gingival display on smile varies in terms of what is acceptable esthetically, but it is important to always remember the relationship between gingival display and the amount of incisor shown at rest. In broad terms, it is better for a patient to be treated less aggressively in reducing gingival display during a smile when considering that the aging process results in a natural diminishment of this characteristic. A gummy smile is more often esthetically pleasing than a smile with diminished tooth display.

The smile arc should be defined as the relationship of the curvature of the incisal edges of the maxillary incisors and canines to the curvature of the lower lip in the posed social smile.[5] The ideal smile arc has the maxillary incisal edge curvature parallel to the curvature of the lower lip upon smile: the term *consonant* is used to describe this parallel relationship. A *nonconsonant*, or flat, smile arc is characterized by a maxillary incisal curvature that is flatter than the curvature of the lower lip on smile. The smile arc relationship is not as quantifiable as the other attributes, so the qualitative observation of consonant, flat, or reverse smile arcs is generally cited (Fig 27-5).

Digital videography

Dynamic recording of a patient's facial motion is accomplished with the use of digital videography.[6] This technology may be used to document and evaluate such characteristics as range of mandibular motion on opening and laterotrusive movements and deviations upon opening, smile, and speech. Digital video and computer technology has primarily been used to record anterior tooth display during speech and smiling. Digital videos can be recorded in a standardized fashion with the camera at a fixed distance from the subject. These images should be taken in a standard format with emphasis on natural head position, so that future analysis and research possibilities may be maximized. Video should be taken in the frontal, oblique, and lateral dimensions. Clinically, this technology is most relevant in the patient with an asymmetric smile. The question that arises is, does the patient have a dental asymmetry, skeletal asymmetry, or asymmetric movement of the lip curtain during animation? The single-smile photograph cannot corroborate the clinical impression gained during the data collection process. The video clip may be reviewed and evaluated during all planning phases of treatment as well as for comparison of the treatment effects (Fig 27-6).

ClearCorrect Exhibit 1016, Page 286 of 335

FIG 27-7 Common facial types: (*a*) mesocephalic, (*b*) brachycephalic, and (*c*) dolichocephalic.

Systematic Clinical Examination of Facial and Smile Esthetics

Macroesthetics

Frontal perspective

The starting point for the macroesthetic examination is the frontal view. Transverse and vertical relationships comprise the major components of the frontal examination and analysis. The proportional relationship of height and width is far more important than absolute values in establishing overall facial type. Faces can be broadly categorized as mesocephalic, brachycephalic, or dolichocephalic[7] (Figs 27-7a to 27-7c). The differentiation between these facial types has to do with the general proportionality of facial breadth to facial height, with brachycephalic faces being broader and shorter. Generally, the most attractive faces tend to have common proportions and relationships that differ from normative values.[8]

Vertical facial proportions

The ideal face is vertically divided into equal thirds by horizontal lines adjacent to the hairline, eyebrows, the nasal base, and menton (Fig 27-8). Orthodontic treatment is to a large extent limited to the lower facial third. Measurement of the upper face is often hindered by the variability in identification of such broad landmarks as location of the hairline and radix.

Clinical examination begins with the evaluation of lower facial height. In the ideal lower third of the face, the upper lip makes up the upper third, and the lower lip and chin compose the lower two thirds (Fig 27-9). Disproportion of the vertical facial thirds may be a result of many dental and skeletal factors, and these proportional relationships may help define the contributing factors related to vertical discrepancies.

Transverse facial proportions

The assessment of the transverse components of facial width is best described by the rule of fifths.[4] This method describes the ideal transverse relationships of the face. The face is divided sagittally into five equal parts from helix to helix of the outer ears (Fig 27-10). Each of the segments should approximate the width of one eye. Transverse fifths should be individually examined and then assessed as a complete group.

The middle fifth of the face is delineated by the inner canthi of the eyes. A vertical line from the inner canthus should be coincident with the alar base of the nose. Variation in this facial third could be due to transverse deficiencies or excesses in either the inner canthi or alar base. A vertical line from the outer canthi of the eyes frames the medial three fifths of the face, which should be coincident with the gonial angles of the mandible. Although disproportion may be very subtle, it is worth noting since treatments can positively change the shape or relative proportion of the gonial angles. The outer two fifths of the face are measured from the lateral canthus of the eye to the lateral helix of the ear, which represents the width of the ears. Another significant frontal relationship is the midpupillary distance, which should be transversely aligned with the commissures of the mouth.

Nasal anatomy in the transverse plane should also be assessed through proportionality. The width of the alar base should be approximately the same as the intercanthal distance, which should be the same as the width of an eye. If the intercanthal distance is smaller than an eye width, it is better to keep the nose slightly wider than the intercanthal distance. The width of the alar base is heavily influenced by inherited ethnic characteristics.

Asymmetry of the face is a somewhat natural occurrence. Systematic examination of the patient's facial symmetry should be directly measured in the frontal plane.

ClearCorrect Exhibit 1016, Page 287 of 335

Fig 27-8 Vertical proportions in the frontal view: delineation of the vertical facial thirds.

Fig 27-9 In the ideal lower third of the face, the upper lip makes up the upper third and the lower lip and chin compose the lower two thirds.

Fig 27-10 Transverse proportions in the frontal view: delineation of the transverse facial fifths.

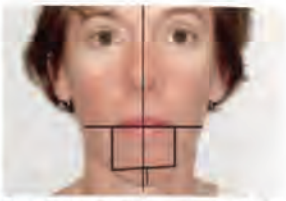

Fig 27-11 Measurement of the midsymphysis to the midsagittal plane is a logical indicator of chin asymmetry, but the parasymphyseal heights should also be measured when chin asymmetry is suspected.

The following measurements make up this portion of the clinical exam: nasal tip to midsagittal plane, maxillary dental midline to midsagittal plane, mandibular dental midline to midsymphysis, mandibular asymmetry with or without functional shift, chin asymmetry, maxillomandibular asymmetry, oblique perspective, and profile perspective.

To measure nasal tip to midsagittal plane, the clinician has the patient elevate his or her head slightly and then visualizes the nasal tip in relation to the midsagittal plane to best view the position of the nasal tip. Any deviation of the nasal tip should be noted in relation to the maxillary midline. The clinician should not make the mistake of treating the maxillary midline according to a distorted nose. An attempt to obtain the etiology of nasal tip asymmetry is recommended. The patient should be questioned as to any previous history of nasal trauma or nasal surgery for deviated septum. The patient may then be advised appropriately as to whether this deviation is severe enough to consider correction.

The maxillary dental midline should be recorded relative to the midsagittal plane. A discrepancy could be due to either dental factors or skeletal maxillary rotation. Maxillary rotation is a rare clinical finding and is usually accompanied by posterior dental crossbite (Sarver DM, personal communication, 2001).

The mandibular dental midline to midsymphysis relationship is best visualized by standing behind the patient and viewing the mandibular arch from above. The patient should open his or her mouth for the clinician to view the mandibular arch and its relationship to the body of the mandible and symphysis. Mandibular dental midline discrepancies are usually due to tooth-related issues such as dental crowding with shifted incisors, premature exfoliation of primary teeth and subsequent space closure in preadolescents, congenitally missing teeth, or an extracted unilateral tooth. If the mandibular dental midline is not coincident with the midsymphysis, it usually indicates a dental shift. However, chin asymmetry should also be considered.

Mandibular asymmetry is suspected when the midsymphysis is not coincident with the midsagittal plane. An important diagnostic factor is whether a lateral functional shift is present secondary to a functional shift of the mandible as a result of crossbite. When the patient's jaw is manipulated into centric relation, a bilateral, end-to-end crossbite is usually present, and as the patient moves his or her teeth into full occlusion, he or she must choose a side to move the mandible into maximum intercuspation. This lateral shift is not indicative of true mandibular symmetry but of transverse maxillary deficiency and a resultant functional shift of the mandible. True mandibular asymmetry is suspected when, in closure into centric relation, no lateral functional shift occurs. The truly asymmetric mandible may be due to an inherited asymmetric facial growth pattern or as a result of localized or systemic factors. A thorough history of traumatic injuries and a review of the patient's medical history will help ascertain potential etiologies of true mandibular asymmetry.

Facial asymmetry may in some cases be limited to the chin only. If the systematic evaluation of facial symmetry determines dental and skeletal midlines and vertical relations of the maxilla to be normal and lower facial asymmetry is noted, then the asymmetry may be isolated to the chin. Measurement of the midsymphysis to the midsagittal plane is a logical indicator of chin asymmetry, but the

ClearCorrect Exhibit 1016, Page 288 of 335

parasymphyseal heights should also be measured when chin asymmetry is suspected (Fig 27-11). The frontal view is recommended, but a view from the superior facial aspect (much like for the evaluation of the mandibular dental midline) with the mouth closed also affords the clinician excellent visualization of the chin in relation to the body of the mandible and the midsymphysis.

Mandibular asymmetry is often accompanied by maxillary compensation, which is reflected clinically by a transverse cant of the maxilla. This means that evaluation of mandibular deformity should include the possibility of maxillomandibular deformity. Transverse tilting of the maxilla may be detectable cephalometrically but is most evident during the macroesthetic examination. The transverse cant of the maxilla is often determined by the relative difference in gingival display at the level of the canine moving posterior on smile.

Oblique perspective

The oblique view in the macroesthetic examination affords the orthodontist another perspective for evaluating the facial thirds. With regard to the upper face, the clinician may view the relative projection of the orbital rim and malar eminence. Orbital and malar retrusion are often seen in craniofacial syndromes. Cheek projection is evaluated in the area of the zygomatic and malar scaffold. Skin laxity and atrophy of the malar fat pad in this area may actually be a characteristic of aging and therefore seen in the older patient population.[9] This area can be described as deficient, balanced, or prominent. Nasal anatomy, which was described in the frontal examination, may also be characterized in this dimension (Fig 27-12). Lip anatomy is also viewed in the oblique and lateral view. The philtral area and vermilion of the maxillary lip should be clearly demarcated. The height of the philtrum should be noted as short, balanced, or excessive. Vermilion display should be termed as excessive, balanced, or thin. The relative projection of the maxilla and mandible can be assessed in the oblique view. Midface deficiency can result in increased nasolabial folding, relaxed upper lip support, and altered columellar and nasal tip support.

One of the other values of the oblique view is visualization of the body and gonial angle of the mandible as well as the cervicomental area. Mandibular deficiency with associated dental compensation may produce lower lip eversion, excessive vermilion display, and a pronounced labiomental sulcus. A characterization of mandibular form is also very important. The oblique view also demonstrates the effects of animation on the appearance of lip and chin projection.

Profile perspective

The last view in the macroesthetic examination is the profile or sagittal perspective. Natural head position is essential for accurate evaluation of profile characteristics. The patient should be instructed to look straight ahead and if possible into his or her own image in an appropriately placed mirror. The visual axis is what determines "natural head position." This axis very often, but not always, approximates the Frankfort horizontal plane. The classic vertical facial thirds should also be applied in profile view (Fig 27-13). An assessment of lower facial deficiency or excess should be noted.

The nasolabial angle describes the inclination of the columella in relation to the upper lip and should be in the range of 90 to 120 degrees.[10] The nasolabial angle is determined by several factors: (1) anteroposterior position of the maxilla, (2) anteroposterior position of the maxillary incisors, (3) vertical position or rotation of the nasal tip, and (4) soft tissue thickness of the maxillary lip, which contributes to the nasolabial angle, where a thin upper lip favors a flatter angle and a thicker lip favors an acute angle.

The characterization of the lower face in profile is measured by the relative degree of lip projection, the labiomental sulcus, the chin-neck length, and the chin-neck angle. Maxillary and mandibular sagittal position can be described by means of facial divergence. The lower third of the face is evaluated in reference to the anterior soft tissue point at glabella. Based on the position of the maxilla and mandible relative to this point, a patient's profile will be described as straight, convex, or concave and either anteriorly or posteriorly divergent.

Lip projection is a function of maxillomandibular protrusion or retrusion, dental protrusion or retrusion, or lip thickness. The description of lip projection should include pertinent information from any of the above sources. For example, a patient with lower lip protrusion may be maxillary (midface) deficient with dentoalveolar compensation including flared incisors and a thin maxillary vermilion display, or may simply have a thick lower lip that appears protrusive.

The labiomental sulcus is defined as the fold of soft tissue between the lower lip and the chin and may vary greatly in form and depth (Fig 27-14). The clinical variables that can affect the labiomental sulcus are mandibular incisor position (upright mandibular incisors tend to result in a shallow labiomental sulcus because of a lack of lower lip projection, whereas excessive mandibular incisor proclination deepens the labiomental sulcus) and vertical height of the lower facial third, which has a direct bearing on chin

ClearCorrect Exhibit 1016, Page 289 of 335

Fig 27-12 The oblique view provides visualization of the nasal anatomy and form (A) and the mandibular form and gonial angle (B).

Fig 27-13 Delineation of the vertical facial thirds in the profile view. This patient has a longer lower facial third with excess height from the lower lip to menton.

Fig 27-14 The labiomental sulcus is defined as the fold of soft tissue between the lower lip and the chin and may vary greatly in form and depth.

position and the labiomental sulcus. Diminished lower facial height usually results in a deeper labiomental sulcus (as in the patient with a complete denture who has an overclosed bite, whereas a patient with a long lower facial third has a tendency toward a flat labiomental sulcus.

Chin projection is determined by the amount of anteroposterior bony projection of the anterior, inferior border of the mandible and the amount of soft tissue that overlays that bony projection. The amount of profile chin projection is measured by the distance from pogonion (the most anterior point on the bony chin) to soft tissue pogonion (the most anterior point on the soft tissue profile of the chin) and is not generally alterable by surgical means. In the adolescent, the amount of chin is directly correlated to the amount of mandibular growth that occurs, because the chin point itself is borne on the mandible as it grows anteriorly.

Miniesthetics

Frontal perspective

Vertical characteristics/lip-tooth-gingival relationships

Key features of vertical facial miniesthetic characteristics is the relationship of the incisal edges of the maxillary incisors relative to the lower lip as well as the relationship of the gingival margins of the maxillary incisors relative to the upper lip. The gingival margins of the canines should be coincident with the upper lip and the lateral incisors positioned slightly inferior to the adjacent teeth (Fig 27-15). It is generally accepted that the gingival margins should be coincident with the upper lip in the social smile. However, this is very much a function of the age of the patient, since children show more teeth at rest and gingival display on smile than do adults.[11]

The vertical characteristics of facial miniesthetics impact the relative amount of gingival display at rest and animation. Gingival display is the amount of "gumminess" of the smile. Measuring the amount of gingival display on smile easily quantitates a gummy smile. The decision whether the amount of gingival display is an esthetic problem, in which treatment is desirable, is a personal choice. Orthodontists tend to see the gummy smile as an unesthetic characteristic, whereas laypersons attach importance only in the more extreme cases. The use of computerized graphic simulation of the frontal view of the smile is useful in counseling a patient and showing potential treatment changes. The individual is then able to guide the clinician and express opinions about what should and should not be corrected. Computer imaging not only provides the patient with a visual template for treatment, but also provides the clinician with a testing ground for treatment options.

Transverse characteristics

The three transverse characteristics of facial miniesthetics in the frontal dimension are arch form, buccal corridor, and transverse cant of the maxillary occlusal plane (Fig 27-16). Arch form plays a pivotal role in the transverse dimension. In cases in which the arch forms are narrow or collapsed, the smile may also appear narrow and therefore present inadequate transverse smile characteristics. An important consideration in widening a narrow arch form, particularly in adults, is the axial inclination of the buccal segments. Cases in which the posterior teeth are already flared laterally are not good candidates for dental expansion. Patients in whom the premolars and molars are upright have more capacity for transverse expansion—certainly in the adolescent, but it is particularly important in the adult, where

ClearCorrect Exhibit 1016, Page 290 of 335

Fig 27-15 It is generally accepted that the gingival margins should be coincident with the upper lip in the social smile. However, this is very much a function of the age of the patient, since children show more teeth at rest and gingival display on smile than do adults. In this adult patient, there is asymmetrical lip curtain with greater elevation on the patient's right side. Thus, the asymmetric gingival heights are further highlighted because of the asymmetry of the dynamic lip.

Fig 27-16 The three transverse characteristics of facial miniesthetics in the frontal dimension are arch form, buccal corridor, and transverse cant of the maxillary occlusal plane. This patient's maxillary arch has been overexpanded with conventional orthodontic treatment. The arch form is exceedingly broad, the buccal corridor has been completely obliterated, and there is a flat smile arc.

sutural expansion is less likely. Orthodontic expansion and widening of collapsed arch form can dramatically improve the appearance of facial esthetics and smile by decreasing the size of the buccal corridors and improving the transverse smile dimension. The transverse smile dimension (and the buccal corridor) is related to the lateral projection of the premolars and molars into the buccal corridors. The wider the arch form is in the premolar area, the greater the portion of the buccal corridor that is filled.

Arch expansion can have undesirable effects. Expansion of the arch form may fill out the transverse dimension of the smile, but two undesirable side effects may result. First, the buccal corridor can be obliterated and create a "denturelike" smile. Second, when the anterior sweep of the maxillary arch is broadened, the smile arc may be flattened. While it may not be possible to avoid these undesirable aspects of expansion, the clinician must make a judgment in concert with the patient as to what compromises are acceptable in the pursuit of the ideal facial esthetic outcome. Careful observation should be made to avoid these side effects if possible.

The last transverse characteristic of facial miniesthetics is the transverse cant of the maxillary occlusal plane. Transverse cant of the maxilla can be due to differential eruption and placement of the anterior teeth and to skeletal asymmetry of the skull base or mandible that results in a compensatory cant to the maxilla. Intraoral images or even mounted dental casts do not adequately reflect the relationship of the maxilla to the smile. Only frontal smile visualization permits the orthodontist to visualize any tooth-related asymmetry transversely. Smile asymmetry may also be due to soft tissue considerations such as an asymmetric smile curtain. In the asymmetric smile curtain, there is a differential elevation of the upper lip during smile, which gives the illusion of transverse cant to the maxilla. This smile characteristic emphasizes the importance of direct clinical examination in treatment planning the smile, since this soft tissue animation is not visible in a frontal radiograph or reflected in study casts. It is not well documented in static photographic images, and is documented best in digital video clips.

Oblique perspective

The oblique view of the smile reveals characteristics not obtainable on the frontal view and certainly not obtainable through any cephalometric analysis. The palatal plane may be canted anteroposteriorly in a number of orientations. In the most desirable orientation, the occlusal plane is consonant with the curvature of the lower lip on smile. Deviations from this orientation include a downward cant of the posterior maxilla, upward cant of the anterior maxilla, or variations of both.[12] In the initial examination and diagnostic phase of treatment, it is important to visualize the occlusal plane in its relationship to the lower lip.

Early definitions of the smile arc were limited to the curvature of the canines and the incisors to the lower lip on smile because smile evaluation was made on direct frontal view. The visualization of the complete smile arc afforded by the oblique view expands the definition of the smile arc to include the molars and the premolars (Fig 27-17).

ClearCorrect Exhibit 1016, Page 291 of 335

Fig 27-17 The visualization of the complete smile arc afforded by the oblique view expands the definition of the smile arc to include the molars and the premolars.

Fig 27-18 Microesthetic evaluation.

Fig 27-19 Obliterated gingival papillae or "dark triangles" in the anterior dentition should be noted. Note the small black triangles in between the maxillary and mandibular central incisors. This is due to mild horizontal bone loss over time as well as to a tooth shape issue. Reproximation of the contact points should be undertaken to broaden the area of contact and reposition the interdental papilla.

Fig 27-20 Patient case example: (*a*) frontal portrait photograph on smile; (*b*) oblique (45-degree) portrait photograph on smile.

Profile perspective

The two miniesthetic characteristics visualized in the profile view are overjet and incisor angulation. Excessively positive overjet is one of the most recognizable dental traits to the layperson. Excessive positive overjet is not as readily perceived in the frontal dimension as it is in the sagittal dimension. Many Class II patterns have very esthetic smiles frontally, but not when the patient's smile is observed from the side. In Class III patterns, the same phenomenon may be true: on frontal smile the smile looks esthetic, but on the oblique or sagittal view, the overall appearance reflects the underlying skeletal pattern and dental compensation. The patient and/or parents have to decide with the clinician whether this is an acceptable outcome.

The amount of maxillary anterior projection also has great influence on the transverse smile dimension in the frontal view. When the maxilla is retrusive, the wider portion of the dental arch is positioned more posteriorly relative to the anterior oral commissure. This creates the illusion of greater buccal corridor in the frontal dimension. Overall, the sagittal cant of the maxillary occlusal plane in natural head position can influence smile arc in the frontal dimension, affecting vertical characteristics. A negative cant of this plane will diminish the apposition of the incisal edges of the maxillary anterior teeth to the superior vermilion border of the lower lip at smile.

Microesthetics

The microesthetic portion of the clinical examination focuses on the morphology of tooth-to-tooth contacts and the surrounding intraoral tissues (Fig 27-18). As a structural unit, the dentogingival complex is defined by the relationship of the teeth to the alveolar bone and surrounding gingival and masticatory mucosa. The factors that influence the appearance of the dentogingival complex are the patient's periodontal status and past history of disease, the proximal and occlusal contacts of the teeth, the shape of the individual teeth, and the type of gingival architecture.

An assessment of the patient's current periodontal status is exceedingly important from an orthodontic point of view. The clinician should take an accurate dental history to ascertain whether the patient has had any periodontal disease and related treatment. Clinically, the teeth should be examined for plaque accumulation and supragingival calculus. Patients who cannot maintain a satisfactory

ClearCorrect Exhibit 1016, Page 292 of 335

Fig 27-21 (a to c) ClinCheck images from the patient in Fig 27-20. Note the orientation of the maxillary arch.

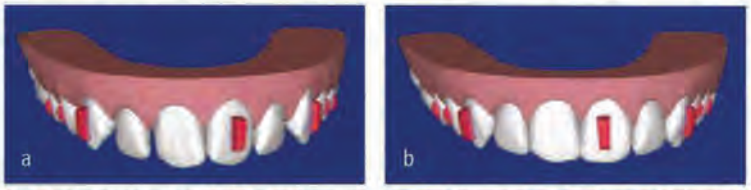

Fig 27-22 Reoriented ClinCheck images. A slight inferior cant of the anterior maxillary arch simulates the natural head position relationship. (*a*) Pretreatment; (*b*) simulated final result.

level of oral hygiene are at risk for gingival inflammation and caries during treatment. Periapical radiographs along with a panoramic radiograph will reveal alveolar architecture and any evidence of horizontal or vertical bone loss. Suspected periodontal defects should be probed and the depths recorded. The extent of attachment loss and degree of tooth mobility will influence tooth movement. "Black triangles" or obliterated interdental papillae should be noted (Fig 27-19).

Integration of Clinical Database with ClinCheck Images

The data obtained from the comprehensive clinical examination of the patient in the frontal, oblique, and profile perspectives should be correlated with the virtual case setup in the ClinCheck program. Esthetic treatment planning involves the integration of the patient's 3-D lip-tooth relationships with the virtual images of the teeth and gingival scaffold seen in ClinCheck. The clinician should, in his or her mind, reorient the virtual arches into their corrected positions within the framework of the patient's soft tissues at rest and during speech and smiling (Figs 27-20 and 27-21). Because the arches automatically appear in ClinCheck with the occlusal plane perpendicular to the computer screen, it should be noted that in reality there is a cant of the occlusal plane in natural head position (Figs 27-22a and 27-22b). This information becomes crucial when planning vertical maxillary incisor positioning relative to the preservation or creation of a consonant smile arc.

References

1. Ackerman MB. Orthodontics and its discontents. Orthod Craniofac Res 2004;7:187–188.
2. Ackerman JL, Keane ML, Ackerman MB. Orthodontics in the age of enhancement. Aust Orthod J 2004;20:3A–5A.
3. Sarver DM, Ackerman JL. About face: The re-emerging soft tissue paradigm. Am J Orthod Dentofacial Orthop 2000;117:575–576.
4. Sarver DM. Esthetic Orthodontics and Orthognathic Surgery. St Louis: Mosby, 1997.
5. Ackerman JL, Ackerman MB, Brensinger CM, Landis JR. A morphometric analysis of the posed smile. Clin Orthod Res 1998;1:2–11.
6. Ackerman MB. Digital video as a clinical tool in orthodontics: Dynamic smile design in diagnosis and treatment planning. In: McNamara JA, Ferrara AM (eds). Information Technology and Orthodontic Treatment, vol 40, Cranofacial Growth Series. Ann Arbor, MI: University of Michigan Press, 2003.
7. Farkas LG, Munro JR. Anthropometric Facial Proportions in Medicine. Springfield, IL: Charles C. Thomas, 1987.
8. Peck H, Peck S. A concept of facial esthetics. Angle Orthod 1970;40:284–318.
9. Pessa JE. The potential role of stereolithography in the study of facial aging. Am J Orthod Dentofacial Orthop 2001;119:117–120.
10. Krugman ME. Photoanalysis of the rhinoplasty patient. Ear Nose Throat J 1981;60:328–330.
11. Zachrisson BU. Esthetic factors involved in anterior tooth display and the smile: Vertical dimension. J Clin Orthod 1998;32:432–445.
12. Burstone CJ, Marcotte MR. Problem Solving in Orthodontics: Goal-Oriented Treatment Strategies. Chicago: Quintessence, 2000: 31–50.

ClearCorrect Exhibit 1016, Page 293 of 335

chapter 28

Surgical Treatment and Invisalign

by
Ross Miller, DDS and Trang Duong, DDS

ClearCorrect Exhibit 1016, Page 295 of 335

The utilization of Invisalign in orthognathic surgery is an exciting prospect. Clear plastic appliances continue to be the esthetic standard in orthodontics and are thus a valuable part of the orthodontist's armamentarium. The goal of this chapter is to explain the value of Invisalign in orthognathic surgery cases, both as an appliance and as a diagnostic tool (ClinCheck) to help plan the patient's surgery and orthodontic treatment.

Most orthodontic records—photographs, casts, radiographs, and written records—are static in nature: there is no movement. ClinCheck offers movement, and movement offers a window into the future, revealing the patient's progress over a given series of aligners or time.

Treatment Planning

Sound goals are the foundation of orthodontic treatment, and this is especially true of surgery. The use of Invisalign as part of a treatment plan should not change or modify the goals set for the patient, unless one discovers that unrealistic goals have been set. The Invisalign System influences visualization of treatment and timing of Invisalign and fixed appliances. ClinCheck should be seen as a supplemental part of diagnosis and treatment planning, as it is extremely helpful in visualizing the treatment and can further help to clarify the relationships between vertical, transverse, and anteroposterior movements.

ClinCheck offers the orthodontist a new way of viewing treatment goals, even if fixed appliances are used for part of the treatment, and permits the orthodontist to visualize movement of not only the teeth but also the jaws, in three dimensions. Even though ClinCheck is model based—that is, created from an impression of the teeth without the reference of the skeletal base—it can provide simulations that will help with the diagnostic process. At the time of publication, skeletal changes that can be performed easily in ClinCheck are anteroposterior corrections of the maxillary and mandibular jaws.

ClinCheck can simulate the following movements: vertical movements (of teeth and jaws), dental or skeletal expansion, anteroposterior movements (of jaws), and asymmetric movements. Surgical movements that are difficult to describe or that require multiple-piece maxillary or mandibular surgery can also be performed. The actual visualization of bony segments on ClinCheck is not currently possible. That is to say, an orthodontist cannot ask Align Technology to move segments of bone on ClinCheck. Align technicians can, however, move the maxillary or mandibular arches in any direction.

Timing

Timing refers to when and what appliances are to be applied. Some clinicians prefer to use fixed appliances before Invisalign, and others opt for Invisalign first. Our preference is to use Invisalign until 2 to 4 months before surgery and then fixed appliances until 6 months after surgery.

Realistically, the patient should understand that treatment will take more than 2 years. A well-planned treatment plan can be executed in 2 years, but we recommend a 6-month buffer for possible midcourse correction or patient noncompliance with the removable appliances. Timing is dependent on factors such as skill of the orthodontist and surgeon, patient compliance, case severity, treatment goals, and surgical plan. One timeline will not apply to all cases. The orthodontist planning the treatment should allow enough leeway to deal with unexpected developments and delays and build time into the treatment plan so the patient understands the timeline.

Communication

The first communication the orthodontist should have is with the patient and the oral surgeon. Everyone involved should understand that Invisalign, in combination with fixed appliances, is to be used in the treatment. There should be agreement about the treatment plan, especially on the part of the patient. It is critical to discuss with the patient the sequence of appliances (especially the fixed) before treatment. An orthodontist does not want to present fixed appliances to a patient who was not aware of and in agreement with the treatment plan.

Communication in ClinCheck is very important for accurate tooth and jaw setups. This is especially true for surgical treatment plans. The "Comments" section of the Virtual Invisalign Practice (VIP) treatment planning form (see chapter 15) is the correct place to log specific requests. In some instances, these comments are communicated directly to the technicians that set up the cases. Communication needs to be clear and concise and might include several ClinCheck iterations or possibly even a phone call to the clinical department. Following are some examples of instructions that might be included for surgical cases:

ClearCorrect Exhibit 1016, Page 296 of 335

- *Mandibular advancement*: "This is a surgical treatment. Please move the mandible forward 4 mm and do the orthodontic setup in that position. Please use Class I canine as the guide to distance. As the mandible comes forward, please do dental expansion on the maxillary arch. Please move the mandible forward at stage 1 and do all orthodontic movement from that position."
- *Mandibular setback*: "This is a surgical treatment. Please move the mandible back 2 mm and do the orthodontic setup in that position. Please use Class I canine as the guide to distance. As the mandible moves back, please do dental expansion on the mandibular arch. Please move the mandible back at stage 1 and do all orthodontic movement from that position."
- *Maxillary advancement*: "This is a surgical treatment. Please move the maxilla forward 4 mm and do the orthodontic setup in that position. Please use Class I canine as the guide to distance. As the maxilla comes forward, please do dental expansion on the maxillary arch. Please move the maxillary jaw forward at stage 1 and do all orthodontic movement from that position."
- *Maxillary setback*: "This is a surgical treatment. Please move the maxilla back 2 mm and do the orthodontic setup in that position. Please use Class I canine as the guide to distance. As the maxilla moves back, please do dental expansion on the maxillary arch. Please move the maxillary jaw back at stage 1 and do all orthodontic movement from that position."
- *Vertical movements*: Vertical movements that are symmetric (in vertical movement) for both arches up or down do not generally require special instructions; however, those that include autorotation of the mandible will require special comments: "This is a surgical treatment. The surgical plan includes a 2-mm vertical movement of the maxillary arch in the upward direction. Please simulate a mandibular movement with 3 degrees of rotation of the mandible. Please perform the surgical movements at stage 1 and adjust the teeth at that point. Expand maxillary arch as needed."
- *Multiple-piece maxillary surgery*: At first glance, it may appear that this would be extremely difficult, and in fact, ClinCheck cannot provide for multiple cuts. This limitation of ClinCheck, however, does not mean that such a procedure cannot be planned; the instructions given would be identical to those given above for vertical movements.

These comments are not appropriate for every patient and are not intended as instructions for any given surgical treatment; they are meant as general comments for various types of surgical treatment. Note that the comments are written in clear, concise language.

ClinCheck visualization is not intended to be a final display of the diagnosis and treatment plan, but it can be part of the "database" that is used to develop the optimal treatment plan. As the clinician runs ClinCheck a number of times, he or she can get a feel for the validity of the treatment plan and make minor modifications as necessary. The clinician will most likely have to communicate directly with the clinical team to obtain exactly what is needed in the treatment plan. Basic advances and setbacks, of course, are much easier to simulate than vertical movements or multiple-piece surgeries.

ClinCheck and Surgical Cases

ClinChecks are made from four general parts: initial position, bite, final position, and movements from initial to final position. These components must flow smoothly and be well integrated into the treatment plan. The clinician must not ignore the last point and should be mindful of such questions as "What is the root doing?" and "Can a plastic appliance move the root like that?"

The clinician is advised to not just accept the ClinCheck but to review it thoroughly: laboratory technicians set up the ClinCheck files for the clinician to evaluate. In particular, the clinician should note all vertical movements. The treatment plan should not aim to obtain "socked in" first or second molars; this should be done with the fixed appliances. An assessment of the ClinCheck gives the clinician the opportunity to ask whether extrusion is needed or whether relative intrusion of neighboring teeth will achieve better results. It also provides the clinician the opportunity to get rid of unwanted root torques and tips. In assessing the ClinCheck, the clinician should keep in mind that extrusive movements do not work well with clear plastic appliances.

An evaluation of the initial bite and position should also be undertaken. When performing this evaluation, the clinician should have the patient's treatment form, casts, photographs, and charts available. The clinician should also be certain that stage 1 on ClinCheck matches the patient's bite and should check this from multiple views. If the initial bite is not correct, the clinician can determine what modifications are needed to make the setup work.

ClearCorrect Exhibit 1016, Page 297 of 335

Fig 28-1 (a to h) Pretreatment photographs.

The ClinCheck can be useful in assessing the occlusal symmetry of the maxillary and mandibular arches. Use of the grid and superimposition tool can be helpful. Clearly, asymmetric movements can lead to asymmetric outcomes. Yet, there will be times when movements cannot be symmetric—for instance, when there are unilateral distalizations or single-tooth crossbites. Nevertheless, the default should be symmetric movements.

It is important for clinicians to remember that outcomes must not be based on the seductive videos of ClinCheck but rather on what is possible clinically. Surgical cases for which the use of a fixed appliance are planned provide the clinician a great opportunity to learn and use ClinCheck.

Case Report

Diagnosis

A 36-year-old man presented with a chief concern to fix an overjet. He had a history of orthodontic treatment in 1974 and 1975. He presented with a Class II retrognathic profile (Figs 28-1a to 28-1c). Intraoral photographs showed that molars and canines were Class II with an increased 12-mm overjet (Figs 28-1d to 28-1f). The first premolars had been extracted. The maxillary arch was constricted and V-shaped, the maxillary incisors were proclined, and 3 mm of anterior spacing was present (Figs 28-1g and 28-1h). The mandibular arch was U-shaped, and there was 3 mm of anterior crowding. Soft tissues were healthy; adequate attached gingiva was present. The panoramic radiograph was within normal limits (Fig 28-2). The initial cephalometric analysis (Figs 28-3a and 28-3b) revealed a Class II skeletal pattern with a retrognathic mandible and slightly retrognathic maxilla, proclined maxillary incisors, and an overerupted mandibular incisor.

ClearCorrect Exhibit 1016, Page 298 of 335

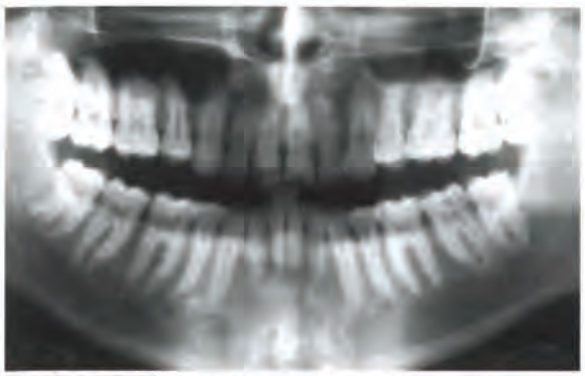

Fig 28-2 Pretreatment panoramic radiograph.

Fig 28-3a Pretreatment cephalogram.

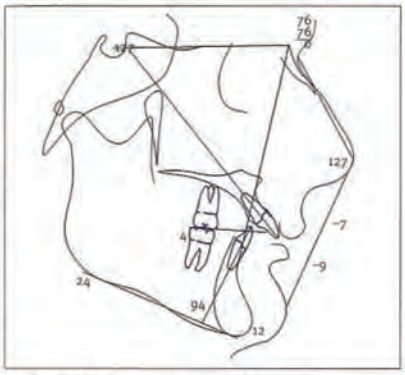

Fig 28-3b Pretreatment tracing.

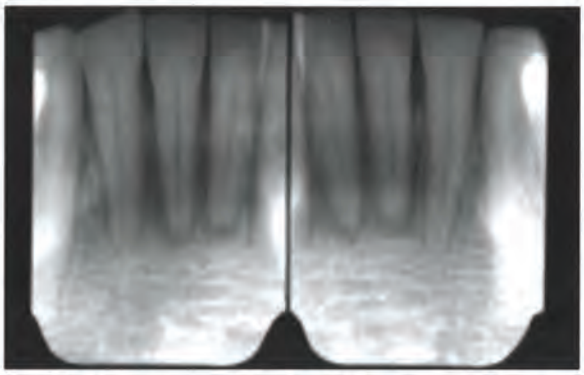

Fig 28-4 Minor root resorption due to intrusion mechanics during the pre-fixed appliance phase.

Treatment objectives

The skeletal objectives were to improve the profile via maxillary and mandibular advancement surgery. The dental objectives were to achieve Class I molar and canine relationships and achieve ideal overjet and overbite via surgery. The arches were to be coordinated, and the presurgical alignment was to be done with Invisalign. Presurgical alignment consisted of retroclining the maxillary incisors to close spaces and to level the curve of Spee by intruding the mandibular incisors. The movements in ClinCheck were programmed to move the maxillary incisors only by tip-back to improve the incisor position as well as to close the spaces. To preserve maximum anchorage, only the four incisors were moved; all other teeth remained stationary in ClinCheck. In the mandibular arch, the movements programmed into ClinCheck consisted of intruding the four incisors and keeping the remainder of the dentition stationary. Attachments were placed on the canines and premolars to aid in retention of the aligner during the intrusion.

Treatment progress and results

The initial examination was performed and impressions taken on January 28, 1999. A pretreatment orthognathic consultation was completed on May 21, 1999. Pre–polyvinyl siloxane (PVS) impression interproximal enamel reduction was done on June 23, 1999, and impressions were taken and sent to Align for ClinCheck fabrication. Treatment commenced on October 5, 1999 with bonding of attachments and delivery of the first aligner. The original treatment consisted of 28 maxillary aligners and 35 mandibular aligners. The aligners were initially made of pelethane, which was not retentive enough; the aligners were remade out of a different material (at the time polycarbonate was used). The new aligners were delivered on November 18, 1999, new attachments were placed, and treatment commenced. On May 5, 2000, progress records were taken. Some minor root resorption was present at the mandibular central incisors, which seems consistent with intrusion mechanics (Fig 28-4). On August 23, 2000, maxillary aligner 20 was given as a

ClearCorrect Exhibit 1016, Page 299 of 335

Fig 28-5 (a to h) Patient's appearance at the end of Invisalign treatment.

retainer, and the patient was instructed to wear it nights only. On November 29, 2000, Invisalign treatment was finished and photographs were taken.

After Invisalign alignment (Figs 28-5a to 28-5h), the maxillary spaces were closed. It can be seen from the maxillary superimposition that the maxillary incisor was tipped back 5 mm and retroclined about 30 degrees. The molar position was maintained. It is important to remember that ClinCheck moved only the four incisors. In the mandibular arch, the incisors were moved inferiorly 3 mm and advanced 2 mm. The mandibular molars remained in the same relative position.

Invisalign was used to achieve presurgical alignment. After about 1 year of Invisalign treatment, the patient was switched to a fixed appliance in preparation for surgery.

The patient was fully banded on December 13, 2000, and 0.014 NiTi wires were inserted. These wires were then changed sequentially to 16 × 22 NiTi on January 24, 2001, then to 19 × 25 NiTi on February 2, and finally to 19 × 22 stainless steel on March 21. Kobayshi hooks were placed on May 10, and the date for surgery was set for June 21. The surgical procedure was maxillary and mandibular advancement. On July 11, the patient was seen postoperatively and was doing well (Figs 28-6a to 28-6h).

One week later, elastics were started from maxillary to mandibular canines and first premolars. On August 22, the maxillary teeth from second premolar to second premolar were repositioned and 0.016 NiTi delivered; then on September 4, a 19 × 25 NiTi maxillary archwire was placed. Photographs and study casts were taken on September 19; a panoramic radiograph taken on September 26 showed shorter anterior roots. On October 1, a 19 × 25 stainless steel wire was placed on the maxillary arch and finishing bends were placed for the next 3 months.

Impressions for retainers were taken on February 2, 2002, and the patient was debonded on March 27, 2002, with delivery of a maxillary Hawley retainer and a mandibular spring aligner. Class I molar and canine relationship was achieved with ideal overjet and overbite (Figs 28-7a to 28-7h). In addition to the advancement,

ClearCorrect Exhibit 1016, Page 300 of 335

FIG 28-6 (a to h) Postsurgical images. Postoperative swelling is evident.

advancement genioplasty was performed (Figs 28-8a to 28-8c). The posttreatment cephalogram revealed that the maxillary incisors were retroclined and the curve of Spee leveled.

A maxillary black triangle between the central incisors was present at the end of treatment, and it was decided to correct this with additional aligners. New PVS impressions were made, five maxillary aligners were delivered, and interproximal reduction was performed between the central incisors. New maxillary and mandibular Hawley retainers were delivered to allow the posterior occlusion to settle. Retention photographs taken 1.5 years after the final photographs show that the correction of the black triangle is stable and also that the settling in the posterior occlusion resulted in good Class I relationship and occlusal interdigitation (Figs 28-9a to 28-9h). Minor relapse was noted in the mandibular anteriors.

Treatment summary

The patient's initial (January 1998) and final (March 2002) records were taken 3 years, 3 month apart, but first aligners were delivered November 1999. Treatment comprised three stages: (1) presurgical alignment achieved with aligners from November 18, 1999, to November 29, 2000; (2) presurgical treatment with fixed appliances from December 13, 2000, to June 21, 2001; and (3) postsurgical fixed appliances from July 11, 2001, to March 27, 2002, for detailing. Total treatment time was 1 year in Invisalign and 15 months in fixed appliances, for a total of 27 months of treatment.

This case illustrates the first completed surgical case treated with Invisalign and conventional fixed appliances. It documents that the combined treatment of Invisalign and fixed appliances can be used to achieve favorable esthetic and occlusal results, even though total treatment time may be slightly increased.

ClearCorrect Exhibit 1016, Page 301 of 335

Fig 28-7 (a to h) Postsurgical images after debonding.

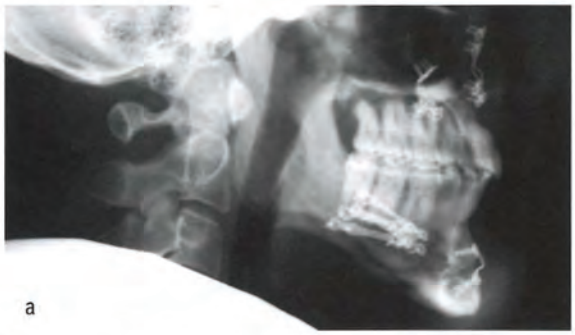

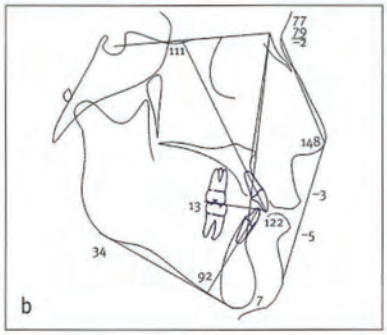

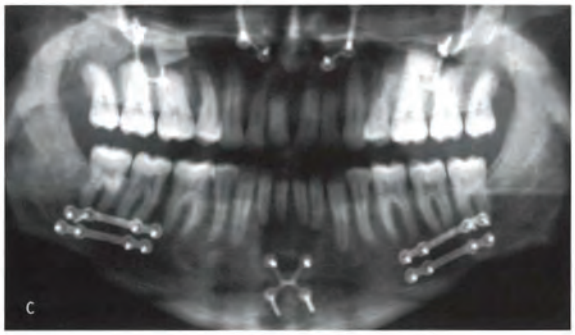

Fig 28-8 Post-debonding cephalogram (*a*), tracing (*b*), and panoramic radiograph (*c*).

ClearCorrect Exhibit 1016, Page 302 of 335

Fig 28-9 (a to h) Final records.

Conclusions

Advances in technology have increased the efficiency of orthodontics and improved the patient experience during treatment. Patients today have more options with the types of appliances they can choose, and orthodontists have various appliances, wires, and imaging tools available to them. It will be exciting and interesting to see the new advances and changes orthodontics undergoes in the future. As with any new technology, however, careful use and good judgement should always be used.

ClearCorrect Exhibit 1016, Page 303 of 335

chapter 29

Feasibility Study of the Invisalign System in Treatment of Adolescents

by
Andrew Trosien, DDS and Robert Fry, DDS

Several articles have appeared in the literature to describe the effectiveness of Align Technology's Invisalign System since it was first introduced in 1997. Invisalign was originally offered to adult patients seeking orthodontic treatment with an esthetic appliance.

The first clinical study on the feasibility of Invisalign was performed on adult patients. Adults were chosen as the initial test sample for three reasons; (1) Adults have a static dentition, whereas adolescents and children have actively erupting teeth and growing jaws; (2) adults are generally regarded as the most compliant patient group. Children are thought to be somewhat compliant and adolescents are typically believed to be noncompliant. Studying the efficacy of aligners required that the patients wear them as directed; (3) from a business perspective, Invisalign treatment was targeted at adults who wanted orthodontic treatment but were reluctant to wear fixed appliances. The results gathered from the study of adults showed that aligners were effective at treating generalized crowding and spacing cases.

Shortly after the initial studies of Invisalign treatment began, 20 or so orthodontists around the country each began treatment on three patients as a beta test. Many of these patients were adolescents. The empirical data gathered from these clinicians showed that adolescents may be successfully treated with the Invisalign System. It was decided to initiate a formal study to determine if adolescents with permanent dentition (ie, second molar to second molar) could be treated with the appliance.

Study Design

In 2000, Align Technology and the orthodontists affiliated with the company's research and development department began working on a design for the study. At the time, very little was known about the capability of the Invisalign System. To focus specifically on the treatment of adolescents, many of the other variables had to be controlled. Because of this, a narrow scope of diagnosis was created for the inclusion criteria so as to remove variability of the treatment plans.

The primary objective of the study was to determine the efficacy of the Invisalign aligner in treating adolescent patients. The variables measured were tooth alignment, oral hygiene, patient cooperation, and quality of life.

Materials and Methods

Patient selection

Patients were recruited from the authors' private practices in Kansas City, Kansas (RF), and Tracy, California (AT). Twenty-one and 13 patients were recruited from each practice, respectively, with a total enrollment of 34 patients. There were 13 male patients (mean age: 15 years, 3 months) and 21 female patients (mean age: 15 years, 2 months) distributed between the two practices. Patients were included in the study if they were 12 to 18 years old and had maxillary and mandibular permanent dentition, mild to moderate spacing (1 to 6 mm), mild to moderate crowding (1 to 6 mm), and Class I posterior occlusion. Patients were excluded if they or their parents were unwilling to sign consent forms or if they had severe malocclusion. The selected patients and their parent(s) were informed of the study, asked to participate, and given a consent form. Patients were given a choice of Invisalign treatment or standard treatment with either fixed or removable appliances.

Records

Standard records were taken for each patient for the purpose of orthodontic treatment planning. In addition, for the purpose of the Invisalign treatment, polyvinyl siloxane (PVS) impressions of each arch and a centric occlusion wax bite were made. The PVS impressions, a prescription form, panoramic radiograph, lateral cephalogram, and photographs for each patient were submitted to Align Technology. Once received at Align, the cases went through the normal commercial process of pouring casts, three-dimensional scanning, and virtual treatment. All cases were treated under the normal commercial manufacturing guidelines for staging, speed, and attachments. The virtual treatments were based on the treating orthodontists' treatment plan in the prescription form. The final virtual treatment plan was presented in ClinCheck via the Internet to the treating orthodontist. The treating orthodontist reviewed the virtual treatment plan and either accepted or requested a modification in the treatment based on the desired treatment plan and goal. Once the treatment plan was accepted, aligners were fabricated and delivered. Intraoral photographs and progress casts were obtained every 6 months, and a panoramic radiograph was taken at the end of 12 months. At the completion of treatment, photographs, impressions, a panoramic radiograph, and a lateral head film were taken.

ClearCorrect Exhibit 1016, Page 306 of 335

TABLE 29-1 Oral hygiene parameter coding used for scoring patients at each appointment

Score	Parameter*			
	Brushing	Flossing	Plaque	Gingivitis
1	Never	Never	None	Normal
2	Daily	Monthly	Some	Somewhat inflamed
3	2 × daily	Weekly	A lot	Very inflamed
4	3 × daily	Multiple times weekly	NA	NA
5	> 3 × daily	Daily	NA	NA
6	NA	2 × daily	NA	NA

** = Not applicable.*

TABLE 29-2 Change in oral hygiene habits parameter coding used for scoring patients at each appointment

Score	Change in hygiene habits*
n + 0	None
n + 1	Better (than last visit)
n − 1	Worse (than last visit)

** = Not applicable.*
n = Current culmulative score in this category.

Data collection

Each patient was seen every 6 weeks after delivery of the first aligner. Data collection occurred at each visit. Collection was undertaken by either the treating orthodontist or a registered dental assistant. Neither the data collectors nor the patients were blinded as to the aspects of the study or the data collection. No calibration among data collectors was performed prior to the study. Training was limited to the instructions provided with each form.

At each visit, data were collected and recorded on an oral hygiene case report form and an aligner case report form. Five aspects of oral hygiene data were recorded: amount of plaque, degree of gingivitis, frequency of brushing, frequency of flossing, and change in oral hygiene habits. Scoring for these parameters is shown in Tables 29-1 and 29-2.

Retention, accuracy of fit, hours of wear per day, days of wear per aligner, and break/loss data were recorded on the aligner case report form. The criteria for scoring retention and break/loss data are listed in Table 29-3.

TABLE 29-3 Aligner wear parameter coding used for scoring patients at each appointment

Score	Parameter*			
	Aligner retention	Lost	Broken	Attachments
0	NA	No	No	None
1	Excellent	Yes	Yes	Yes
2	Good	NA	NA	Broken off
3	Fair	NA	NA	Removed
4	Poor	NA	NA	Rebonded

** = Not applicable.*

Every 6 months, data were collected on a new quality-of-life questionnaire. This questionnaire was adapted from the Dental Impact on Daily Performance scale by Leao and Sheiham.[1] It was used to measure the degree of satisfaction using the parameters of appearance, comfort, pain, performance, and eating restriction. The patient completed the questionnaire with no instructions other than those included on the form.

Progression of treatment

If, at any stage during treatment, the patient's teeth did not follow the prescribed path, the case was stopped and new PVS impressions were taken for additional aligners. During the time the new aligners were being fabricated, the patient was instructed to wear a clear vacuum-formed appliance to retain the current position of the teeth. Patients whose failure was due to poor compliance were, however, not retreated, but were instead cut from the study. After the last aligner was delivered, each treating orthodontist determined the need for additional aligners for minor adjustments.

Efficacy of treatment

Irregularity index measurements were made to quantify the alignment of the teeth before and after treatment. Measurements were made with a digital caliper on photocopied pictures of the pretreatment and final casts. The technique was adapted from Little.[2]

ClearCorrect Exhibit 1016, Page 307 of 335

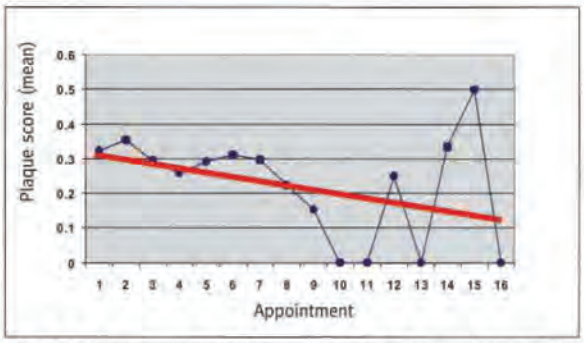

FIG 29-1 Mean amount of plaque found at each appointment. The trend line shows a slight decrease in the mean value of each patient's plaque score per appointment.

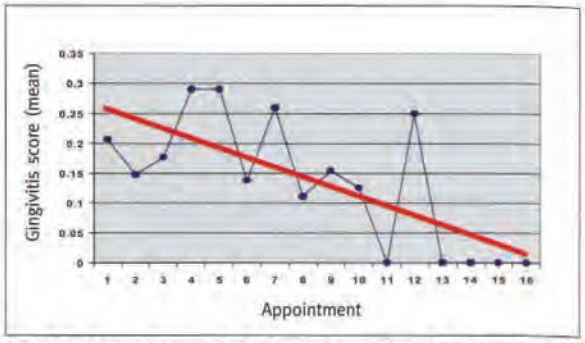

FIG 29-2 Mean degree of gingival inflammation found at each appointment. The trend line shows a slight decrease in the mean value of each patient's degree of gingival inflammation per appointment.

Results

Patient sample outcome

Five patients withdrew from the study and four were dropped, leaving 25 who successfully completed the study. Patients withdrew from the study if they moved away; patients were dropped as a result of poor compliance. Eighteen of the total 34 patients required additional aligners to complete their treatment.

Certainly, the attrition rate is notable. All of the patients who withdrew or were dropped from the study had been selected from a screening of an underserved population and were therefore given a 90% courtesy off of the treatment fee. This created a lack of financial commitment to treatment and may have been the cause of the failed appointments and cooperation.

Treatment length

The average number of aligners used was 19 maxillary and 21 mandibular. At the time the study was conducted, the staging methods used and the amount of movement per aligner were different than those implemented today. Contemporary staging of these cases would likely result in slightly fewer total aligners per case. Considering a 2-week-per-aligner wear schedule, the treatment would ostensibly result in a 40-week (10-month) treatment time. Eighteen patients required aligners additional to their original prescription.

The total number of aligners necessary for a given patient's treatment is significant in that it appeared to be inversely related to the cooperation of the patient. In other words, the shorter the treatment, the more likely the patient was to finish it successfully. The longer the treatment, the more likely the patient was to become noncompliant with the wear schedule. Such a relationship is purely observational; data were not collected to measure this statistically.

Although all of the patients in the study finished their treatment in a reasonable amount of time, it was noted that the transition between active treatment and retention was ill defined. In traditional orthodontic treatment, there is a clear demarcation between active treatment and retention, as it is marked by the removal of the brackets. However, a single aligner by itself is essentially a retainer. In some cases, detailing of the final aligner was done over several weeks. This resulted in a prolonged transition into retention. From a practice-management standpoint, this caused a number of problems. The changing of the status of the patient, taking of final records, and celebration of the end of treatment were all difficult to pinpoint, since there was never a defined treatment endpoint. This discovery would suggest that a firm decision as to the end of active treatment and the beginning of retention be made in all cases, even if the retainer is an aligner.

Oral hygiene

Maintenance of good hygiene is an important factor during orthodontic treatment because it has been shown to affect treatment time and outcome. Research has shown that, in general, adults have significantly less plaque accumulation and healthier gingival tissues than adolescents during treatment.[3] Approximately 20% to 30% of the adolescents had inadequate plaque removal during treatment and lost significant periodontal bone support during treatment.[3] A longitudinal study showed that adolescents who had ineffective plaque removal during treatment also developed significant decalcification.[4] Studies have shown that the amount of plaque, gingivitis, and decalcification is higher in patients with fixed appliances than those without.[5–7]

ClearCorrect Exhibit 1016, Page 308 of 335

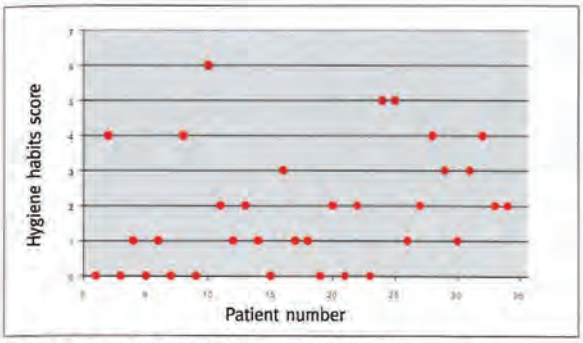

Fig 29-3 Oral hygiene habits at the end of treatment.

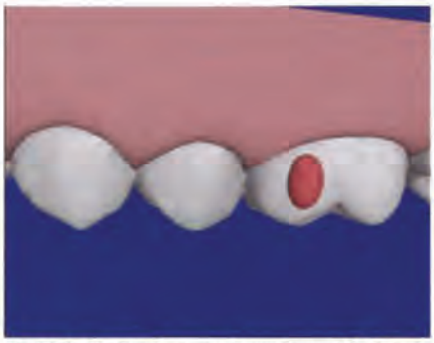

Fig 29-4 Shallowly erupted teeth provide little in the way of retention for aligners.

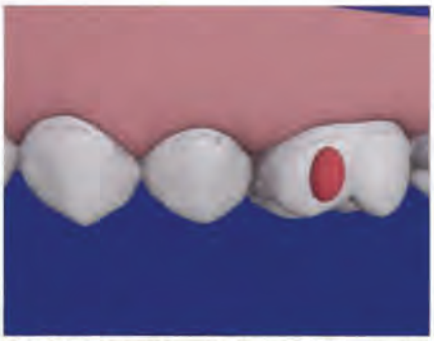

Fig 29-5 Retraction of the gingiva on the ClinCheck model provided sufficient undercuts for aligner retention.

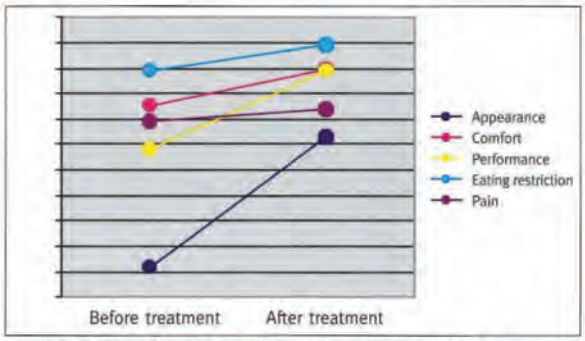

Fig 29-6 Comparison of quality-of-life parameters for before and after treatment (means for all patients).

In this study, the amount of plaque found on the teeth at each appointment decreased over the course of treatment (Fig 29-1), as did the degree of gingival inflammation at each appointment (Fig 29-2). Oral hygiene habits improved over the course of treatment (Fig 29-3).

Given the aforementioned deterioration in oral hygiene that is often seen in fixed-appliance cases, it is remarkable how well the hygiene was maintained in these cases. Certainly such good oral hygiene, and the improvement in oral hygiene habits, could have been caused by the oral hygiene instruction given at the beginning of treatment by the treating orthodontists. Although this instruction is also given to fixed-appliance patients in these practices, a lack of a control group does not allow a relative comparison. Even in the absence of such relative comparison, however, the salient point is that hygiene did not deteriorate over the course of treatment. Another potential bias is the fact that both the data recorders and the patients were aware of the study and were in no way blinded as to the appointment, data, or purpose. Such a bias could have increased the recorded level of hygiene during treatment.

Aligner wear cooperation

Cooperation has been a high-visibility topic in orthodontics for many years. It is generally believed that cooperation with treatment is a key factor in achieving a successful result. This is certainly true with treatment that involves aligners. The fact that aligners can be removed easily could predispose poor cooperators to wear them fewer hours per day than prescribed. Also, the ability to remove aligners could lead to their being lost or misplaced. In this group, the aligners were worn, on average, 20 hours per day. With respect to individual aligner failure, 2.2% were lost and 1.6% were broken.

A component of cooperation is the comfort of the appliance being used. In traditional orthodontics, appliances such as removable thumb cribs and headgears are often worn a less-than-optimal amount of time simply because they are uncomfortable. In this study, we discovered that

ClearCorrect Exhibit 1016, Page 309 of 335

a similar discomfort could occur if the teeth were insufficiently erupted. In other words, if the teeth are not erupted far enough into the mouth to reveal the height of contour and the underlying gingival embrasure and undercuts, the aligners have nothing to "snap" over. In one study patient, the aligners would not stay tightly over the teeth (Fig 29-4). The addition of attachments did not assist in the retention of the appliance. However, reducing the gingival height of the ClinCheck model, thereby revealing the undercuts, solved the problem and resulted in excellent retention (Fig 29-5). This evidence suggests that younger patients with shallowly erupted teeth should be observed for treatment until they are older.

Quality of life

Means of all patients' quality-of-life data for the initial and final periods were calculated (Fig 29-6). Nonstatistical observation of the data suggests an improvement in appearance and performance. This makes sense, given that the patients' teeth were straightened during treatment. The malocclusions treated in this study were relatively mild, leading one to assume that there would not be a substantial change in a patient's quality of life over the course of treatment. One could postulate that a severe malocclusion would lead to significant changes in the quality-of-life data once the treatment was complete.

TABLE 29-4 Irregularity index measurements for 22 patients (pre- and posttreatment measurements of the anterior irregularity of study casts)

Patient	Maxilla			Mandible		
	Pretreatment (mm)	Posttreatment (mm)	% reduction	Pretreatment (mm)	Posttreatment (mm)	% reduction
1	3.70	2.83	23.51	4.65	1.36	70.75
2	6.91	0.45	93.49	7.90	0.93	88.23
3	3.94	1.56	60.41	4.89	3.29	32.72
4	3.99	1.58	60.40	2.54	0.54	78.74
5	7.35	1.59	78.37	6.82	1.48	78.30
6	6.41	1.96	69.42	2.17	0.64	70.51
7	3.37	2.46	27.00	4.28	1.39	67.52
8	5.35	0.70	86.92	4.53	0.64	85.87
9	6.70	2.94	56.12	6.71	0.65	90.31
10	8.28	0.80	90.34	12.17	0.88	92.77
11	4.92	2.59	47.36	4.32	1.48	65.74
12	4.54	3.96	12.78	2.37	0.54	77.22
13	3.03	2.51	17.16	3.18	3.54	–11.32
14	4.58	4.48	2.18	7.36	0.09	98.82
15	5.26	4.79	8.94	2.60	1.14	56.15
16	8.04	2.43	69.78	12.27	2.63	78.57
17	3.77	2.89	23.34	6.10	0.90	85.25
18	5.37	1.44	73.18	1.62	0.26	83.95
19	9.84	3.79	61.48	5.85	0.80	86.32
20	8.40	2.96	64.76	3.85	1.21	68.57
21	5.08	1.51	70.28	1.92	0.40	79.17
22	6.66	1.41	78.83	1.35	0.34	74.81
Mean	5.70	2.35	53.46	4.98	1.14	72.68

ClearCorrect Exhibit 1016, Page 310 of 335

As mentioned, there was no blinding in the design of this study. This may have affected the data. The fact that 6 months passed between questionnaire assessments might have helped reduce this bias, as the patients may have forgotten their previous answers. In addition, the patients completed these questionnaires without assistance of the office staff, thereby eliminating additional bias resulting from the data collectors.

Treatment outcome

Irregularity index measurements showed an improvement in anterior alignment in each patient studied, with a mean reduction in irregularity of 73% in the mandible and 53% in the maxilla. The measurements for 22 patients are shown in Table 29-4. Initial review of the irregularity numbers indicates that the final results were not devoid of irregularity of the anterior teeth. In fact, the sensitivity of this metric is such that even a well-treated case will result in an irregularity index of greater than zero. That these numbers reflect a successful result is reflected in the posttreatment photographs and casts. Nevertheless, the simplicity of the cases in this sample limits the findings to simple cases. Furthermore, the lack of a fixed-appliance control group mitigates any direct comparison with fixed appliances.

References

1. Leao A, Sheiham A. Relation between clinical dental status and subjective impacts on daily living. J Dent Res 1995;74:1408–1413.
2. Little RM. The irregularity index: A quantitative score of mandibular anterior alignment. J Dent Res 1975;68:554–563.
3. Boyd RL, Leggott PJ, Quinn RS, Eakle WS, Chambers D. Periodontal implications of orthodontic treatment in adults with reduced or normal periodontal tissues versus those of adolescents. Am J Orthod Dentofacial Orthop 1989;96:191–198.
4. Boyd RL. Two-year longitudinal study of a peroxide-fluoride rinse on decalcification in adolescent orthodontic patients. J Clin Dent 1992;3(3):83–87.
5. Mizrahi E. Enamel demineralization following orthodontic treatment. J Dent Res 1982;82(1):62–67.
6. Huser MC, Baehni PC, Lang R. Effects of orthodontic bands on microbiologic and clinical parameters. Am J Orthod Dentofacial Orthop 1990;97:213–218.
7. Gorelick L, Geiger AM, Gwinnett AJ. Incidence of white spot formation after bonding and banding. J Dent Res 1982;81(2):93–98.

chapter 30

Data Mining: Principles and Considerations

by
Eric Kuo, DDS

ClearCorrect Exhibit 1016, Page 313 of 335

Data mining is the process by which vast amounts of data are transformed into insight by finding trends and correlations that cannot be detected from individual case studies alone. In dentistry, data mining can be used to understand epidemiologic patterns, utilization of procedures, and demographics. Data mining uses software tools to query a large catalog of data. This approach can identify correlations and patterns that may go unnoticed when only a few individual data sets or data points are observed. For data mining to be successful, a defined information model and related infrastructure are required, since not all collected information will be relevant (Fig 30-1). Because the prediction is only as good as the model, one risk of this methodology is using an incorrect model and drawing erroneous conclusions from what could be noise inherent in any data system.

The Invisalign Metrics Analysis Program (MAP) is a data-mining pilot program developed to establish specific measurable quantities (metrics) to better understand key performance indicators, trends in treatment approach and outcome, key clinician and patient demographics, and treatment success and satisfaction with Invisalign treatment (Fig 30-2). It is an initiative that, once established, can grow into a robust orthodontic data management tool for scientific research and dental education. For the time being, it is used to design and develop better Invisalign product offerings and educational training materials.

In the Invisalign MAP model, specific case parameters are stored in a digital information warehouse. These case parameters can include demographic information such as patient age, clinical information (eg, treatment approach), and manufacturing information (eg, number of aligners manufactured for the case). This information can be useful to better understand how Invisalign is used by orthodontists, for what types of patients, and with what levels of success.

Case Study 1: Use of Reproximation with Invisalign

Reproximation (or interproximal enamel reduction [IPR]) is an alternative to extraction whereby a portion of the interproximal enamel is removed from one or more teeth to create arch length for alignment of crowded teeth. It is often used when the teeth should not be advanced or expanded buccally because of either poor periodontal health or inclination of the dentition. Moderately crowded cases can also be treated with reproximation instead of extraction to avoid retraction of the anterior teeth and flattening of the profile, especially when the total extraction space significantly exceeds the total amount of crowding present. Reproximation, however, is technique sensitive, and understanding the impact of reproximation techniques on case complication is important to characterize (see chapter 26).

Reproximation can be built into the case in one of two ways. The clinician can create interproximal spaces prior to taking the Invisalign impressions, perhaps creating the space with interdental elastic separators for access. Alternatively, reproximation can be performed as the aligners are being delivered, using the reproximation form as the guide and interproximal space measurement gauges to determine accuracy (Figs 30-3 and 30-4).

The first approach may be more accurate, but unless a diagnostic setup is performed, it can lead to a certain amount of guesswork as to which surfaces require enamel removal. The latter approach reduces the guesswork, since the setup is reviewed alongside the reproximation plan; however, reproducing the exact amount of reproximation as indicated in the form is technique sensitive. Failure to deliver the exact amount of reproximation as indicated on the form can lead to either crowding at the end of treatment from inadequate space creation or interproximal spaces from overreduction. Usually, either of these scenarios can be corrected with additional aligners as long as the dental contours that follow the reproximation remain properly shaped. The need for additional aligners, however, can be a hassle for both the clinician and the patient.

Some of the questions that would be interesting to answer are:

1. To what extent is reproximation requested by clinicians?
2. Are reproximation cases more complicated than nonreproximation cases?
3. What is the effect of reproximation utilization on treatment convenience?
4. What is the overall trend in use of reproximation?

To answer these questions, a sample of Invisalign-treated cases was evaluated and categorized based on use of reproximation. Cases in which reproximation was performed prior to impressions were put in category 1. Generalized space-closure cases were also placed in this category since the physical appearance of both types was

ClearCorrect Exhibit 1016, Page 314 of 335

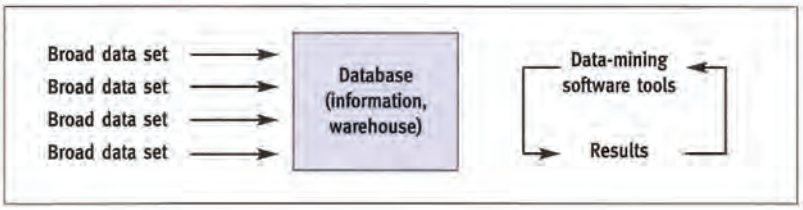

FIG 30-1 Data-mining tools can identify trends and correlations within the information stored in the database, but the conclusions are relevant only if the information model is correct.

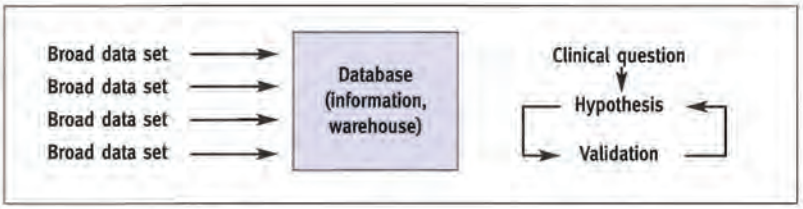

FIG 30-2 Align's data-mining infrastructure can store clinical parameters in an information database to test the validity of a clinical hypothesis.

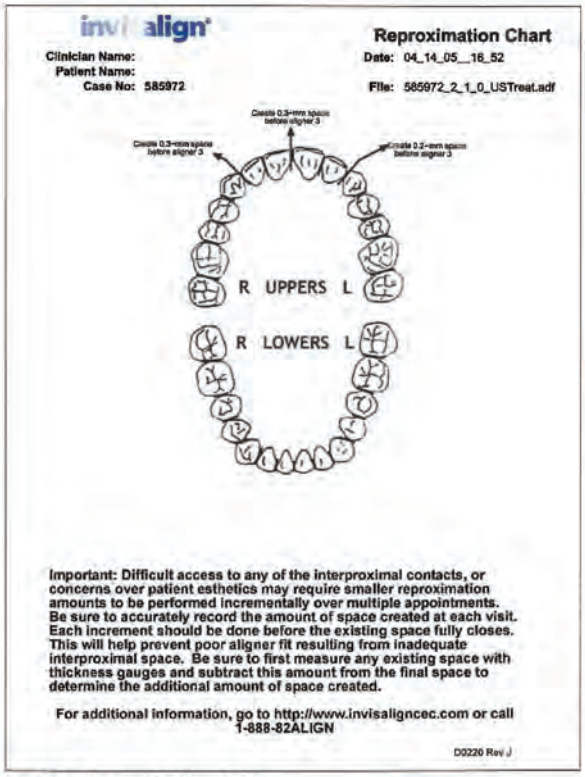

invisalign

Reproximation Chart

Clinician Name:
Patient Name:
Case No: 585972

Date: 04_14_05__16_52
File: 585972_2_1_0_USTreat.adf

R UPPERS L

R LOWERS L

Important: Difficult access to any of the interproximal contacts, or concerns over patient esthetics may require smaller reproximation amounts to be performed incrementally over multiple appointments. Be sure to accurately record the amount of space created at each visit. Each increment should be done before the existing space fully closes. This will help prevent poor aligner fit resulting from inadequate interproximal space. Be sure to first measure any existing space with thickness gauges and subtract this amount from the final space to determine the additional amount of space created.

For additional information, go to http://www.invisaligncec.com or call 1-888-82ALIGN

D0220 Rev J

FIG 30-3 Reproximation form.

FIG 30-4 Interproximal measurement gauges.

essentially identical. Cases in which no reproximation was performed were placed into category 2. These were crowding cases in which the teeth were aligned without reproximation either before or after the impression. Cases that needed anterior reproximation during aligner delivery (postimpression) were put in category 3. Cases that needed reproximation distal to the first premolar during aligner delivery were put in category 4.

For this investigation, cases in which spaces were left for restorative work were omitted because such space closure could inherently lead to additional detailing work unrelated to the outcome specific to whether reproximation was used or not. Extraction and distalization cases were also not included, since it was believed that such cases could introduce complications that were unrelated to the use (or not) of reproximation.

The hypothesis was that cases requiring reproximation after impressions, especially of posterior teeth, were more likely to require additional aligners for treatment, since postimpression reproximation is technique sensitive, especially when trying to access posterior interproximal contacts. Performing reproximation before impressions, however, would probably be more accurate as long as the guesswork about which surfaces to recontour could be reduced.

For this study, 555 cases (1,005 treated arches) were randomly selected from all cases ordered between April

ClearCorrect Exhibit 1016, Page 315 of 335

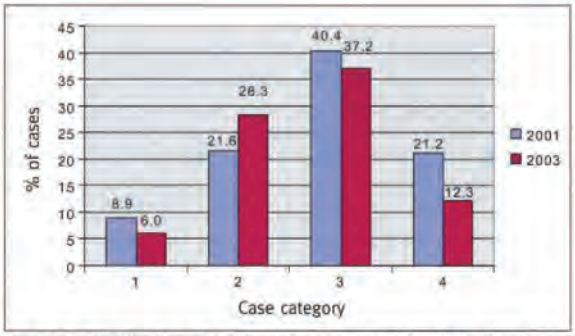

FIG 30-5 Distribution of treatment approaches for Invisalign cases with reproximation. Categories: (1) Preimpression reproximation/space closure; (2) no reproximation; (3) anterior reproximation only, postimpression; (4) any posterior reproximation, postimpression.

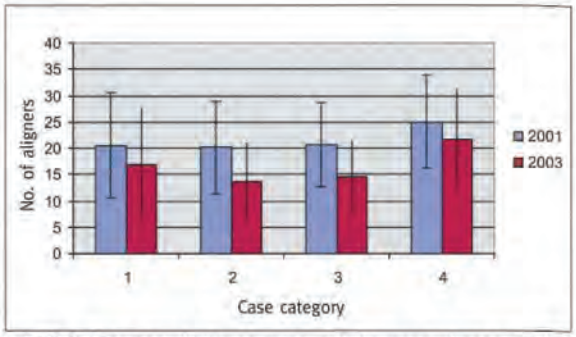

FIG 30-6 Case complexity as measured by mean aligner number per arch, the hypothesis being that more complicated cases require more tooth movement (and aligners) to resolve. Categories: (1) Preimpression reproximation/space closure; (2) no reproximation; (3) anterior reproximation only, postimpression; (4) any posterior reproximation, postimpression.

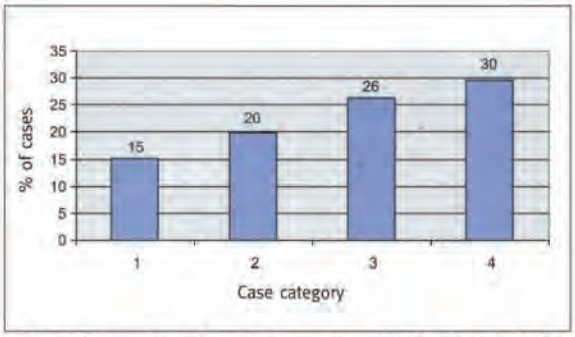

FIG 30-7 Percentage of cases in each category for which additional aligners were ordered to complete treatment. The data are consistent with the hypothesis that space management is critical to treatment outcome success. (Taken from 2001 sample; confidence level = 0.95.) Categories: (1) Preimpression reproximation/space closure; (2) no reproximation; (3) anterior reproximation only, postimpression; (4) any posterior reproximation, postimpression.

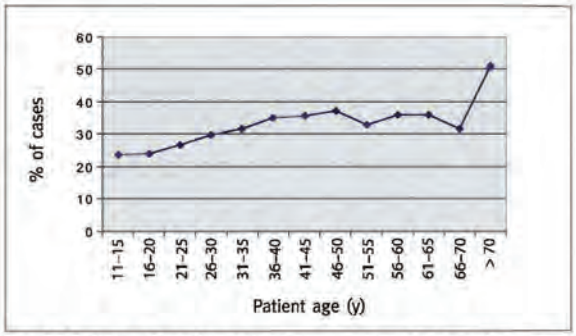

FIG 30-8 Rate of additional aligners ordered, by patient age. (Taken from 2003 data; n = 23,054 treated arches.)

and June 2001. Another 744 cases (1,261 treated arches) were randomly selected from April to June 2003 as a second time point to investigate trends in utilization of reproximation. The utilization of reproximation within these sample groups is shown in Fig 30-5.

Between 2001 and 2003, the use of reproximation decreased from 62% to 50% of cases. The increase in group 2 (no reproximation) and the decrease in group 4 (posterior reproximation) was statistically different between 2001 and 2003 (chi-square test, $P < .005$). One theory explaining this change is that as clinicians better appreciate the challenges associated with reproximation, they rely on it less to achieve their treatment goals, especially in the posterior dentition, where reproximation can be difficult to deliver with accuracy.

To determine the inherent complexity of each case, the number of aligners manufactured for each arch was used as an indicator (Fig 30-6). The critical assumption here is that this was a rough estimate of treatment complexity, since more complicated cases should require greater tooth movement and, hence, a greater number of aligners. The study results did not reveal a statistically different number of aligners among the different treatment approaches; however, cases planned with posterior reproximation, on average, had a higher number of aligners associated with the cases.

An analysis of the rate of additional aligner use for each category revealed that the more extensive the amount of postimpression reproximation, the higher the rate of additional aligners being ordered (Fig 30-7).

ClearCorrect Exhibit 1016, Page 316 of 335

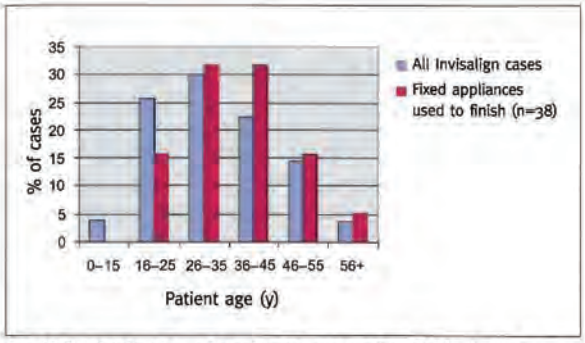

FIG 30-9 Distribution of treatment approaches for Invisalign cases with reproximation. Categories: (1) Preimpression reproximation/space closure; (2) no reproximation; (3) anterior reproximation only, postimpression; (4) any posterior reproximation, postimpression.

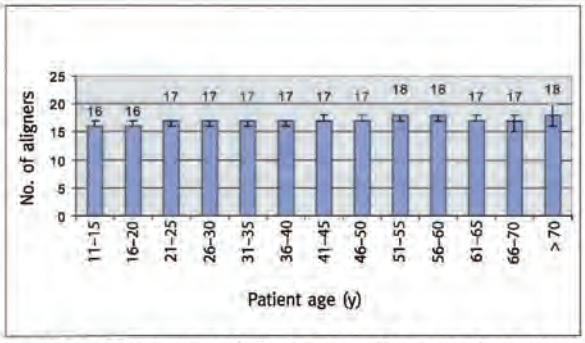

FIG 30-10 Mean number of aligners per arch, by patient age (2003 data).

The conclusion from this exercise was that the data were consistent with the observation and general belief that cases that require reproximation during the course of treatment, especially in the posterior dentition, were more likely to require additional aligners at the end of treatment, and that space-closure cases and cases in which space was created prior to impressions were less likely to require additional aligners. The fact that additional aligners were needed in 15% of space closure/preimpression cases (group 1), however, suggests that certain types of cases within this category may still require detailing at the end of treatment. Nonetheless, this information could be of interest to a clinician trying to assess treatment times as it relates to treatment approach. Pressed for a limited amount of treatment time, a clinician may elect to treat a case with either preimpression reproximation or no reproximation in an effort to reduce the need for additional aligners at the end of the aligner series. At the same time, not knowing how much to reproximate up front could also lead to additional complexity; hence, additional effort such as a diagnostic setup may be necessary to properly assess the treatment plan. The fact that there was not a significant increase in utilization of preimpression reproximation between 2001 and 2003, but an overall decrease in reproximation use concurrent with an increase in nonreproximation cases (see Fig 30-5), suggests that clinicians were becoming cognizant of the challenge of trying to deliver preimpression reproximation without a three-dimensional visualization of the treatment goal.

Case Study 2: Patient Age and Need for Additional Aligners

Invisalign is indicated for patients whose second molars are fully erupted. This guideline was established because erupting dentition and skeletal growth are not currently simulated by the ClinCheck software. Because of concerns about potential compliance problems with younger patients, it is important to characterize the effect of patient age on treatment.

To study this effect, all cases that included patient age were analyzed based on the use of additional aligners. If younger patients were not compliant in wearing the aligners, one would expect a higher rate of additional aligners being ordered for younger patients. As Fig 30-8 shows, however, the rate of additional aligners ordered was actually higher for older patients, not for younger patients. One possible explanation for the results is a greater acceptance of fixed appliances in younger patients in the event that they are needed for finishing. Adults may be less likely to accept fixed appliances and may prefer trying to finish their treatment using aligners. Survey data, however, did not show a higher utilization of fixed appliances for finishing in younger patients (Fig 30-9).

Another possible explanation for the higher rate of additional aligners in older patients is that older patients may have more complicated malocclusions, or their teeth may be less responsive to orthodontic movement; as a result, older patients may be more likely to require refinement. To test this hypothesis, the mean number of aligners per arch was calculated by patient age, with the assumption that

ClearCorrect Exhibit 1016, Page 317 of 335

the number of aligners is correlated to the complexity of the treatment.

Figure 30-10 shows that the mean number of aligners did increase with patient age, which means that the severity of malocclusion could be a function of patient age. This could explain why older patients exhibited a higher utilization rate of additional aligners for treatment. In other words, while compliance in younger patients may be an issue (this was not proven or disproven by the data), its effect appears to be overshadowed by the more significant effect of older patients needing more aligners to correct their more complicated malocclusions.

The assertion that younger patients are less likely than adults to be compliant with Invisalign, and are more likely to require multiple refinements to finish treatment, cannot therefore be supported by the data. Initially, this may be counterintuitive; however, given that Invisalign is still in its early stages of adoption and that many clinicians are still somewhat cautious in offering it to their patients, perhaps younger patients currently being treated with Invisalign are a well-selected population, who are determined to avoid wearing brackets and therefore more apt to be compliant. If this is the case, then the data make perfect sense. And based on these data, since the rate of additional aligner utilization in younger patients is no worse than in older patients, clinicians should be encouraged to treat younger patients with Invisalign, as long as the malocclusions being treated are compatible with the appliance's indications.

Concluding Comments

A successful data-mining program requires that the characteristics being studied are objectively parameterized. As demonstrated in the case studies above, much of what is being reviewed today in Align's research laboratories are still very basic parameters such as the number of aligners manufactured, treatment approach, and patient demographics. As such, the outcomes are only useful for assessing consistency with a given hypothesis, rather than for proving or disproving a theory.

A more rigorous but challenging approach could be to characterize cases based on traditional orthodontic parameters such as Angle classification, overjet, and amount of crowding. The reasons why the characterization approach is challenging is that the standards and definitions for these measurements can vary widely, and measurement processes need to be automated to be applicable to a large sample in an accurate and reproducible fashion. Poorly defined data in large quantities without any scientific hypothesis to test are not very useful, and do not lead to meaningful results. Large amounts of well-defined, quality data used to test specific hypotheses, however, are extremely powerful and can lead to interesting observations, which can in turn spark even more interesting questions and results. Align Technology's data-mining initiative holds great promise for better understanding how and why Invisalign treatment works and for identifying clinical parameters correlated with treatment outcome success.

ClearCorrect Exhibit 1016, Page 318 of 335

SECTION V

OFFICE DESIGN AND TECHNOLOGY

chapter 31

Invisalign Office Design and Technology

by
Orhan C. Tuncay, DMD; Marc S. Lemchen, DMD; and Agnes A. Kan

What is the function of the Invisalign orthodontic office, and how can it be designed to best deliver what is required of it? Other pertinent questions are, who uses the office, and what are these users' expectations? Patient needs and expectations are the two principal parameters, which suggests that the orthodontic office should seamlessly blend form with function. Unless the mission and objectives of the space are clearly defined, the architect will design a space that serves as a monument to himself or herself, or the builder will simply build a generic box. In the context of this chapter, "mission" is defined as tasks performed in the orthodontic office, and "objective" is defined as how these tasks are performed.

The mission of the orthodontic office may be listed as all of the following: patient waiting, reception duties and appointments, payment collection, patient data storage and retrieval, office work for correspondence and financial business, consultation of the patient with the clinician or clinical personnel, patient education, staff training, collection of diagnostic information, treatment, sterilization, and fabrication of orthodontic appliances.

It is necessary to break down these tasks to design a space that will permit the performance of these functions in a specific way. Orthodontic practices are high-volume establishments. In the absence of efficiency, they cannot reach their full potential of productivity. Efficiency is linked not only to high quality of treatment but also to income. The architectural design and incorporated technology must have a symbiotic existence. Retrofitting one element to suit another generally does not bring efficiency; it only adds one more element to an already crowded operation. This is an important consideration, as one can never know what kind of novel treatment techniques or additional equipment might be needed in the future. The design should prepare the space for easy conversion.

Functional Needs Fundamental to the Mission of the Orthodontic Practice

Patient waiting area

The waiting areas should never be used for waiting, but it is often hard to adhere to this principle. If waiting is to take place, what should be the design considerations for the waiting area? This question may best be answered by assigning a function for the space. This space can be many things, but one element is certain: it should be relaxing. The space could be useful in helping to relax patients before their appointment. This relaxation benefit also applies to adults who are accompanying a child patient.

How does a waiting area invite people to relax? A person's experience of entry into the office is significant, as it is essential that he or she develop a positive first impression of the space. Some spaces are inviting, comfortable, and relaxing, whereas others convey a feeling of coldness or tension. The personality of a space and how it affects humans is called *feng shui* in the Chinese culture. The personality of a space is dictated not only by its layout but also by the harmonious interaction of its furnishings, color scheme, light, and materials. In terms of layout, factors that affect the waiting area must be considered first. The waiting area is located next to the reception area. Obviously, incoming patients stop at the reception desk first. The patient's approach to the reception desk, combined with his or her experience there, influences the "entrance" factor of the waiting area (Figs 31-1 and 31-2). Patients carry the mood of their day into the waiting area or to the treatment areas. Thus, whether it is the initial visit or a regularly scheduled visit, it is best to ensure that the patients are happy and in a good mood at all times when they are in the orthodontic office.

Receptionist's area

From the perspective of the patient or the parent, it is important to be "received." People who walk into an establishment—be it an orthodontic office or a restaurant—enjoy being recognized and accommodated. For the patient, the receptionist's area has a high impact value. It is essential, therefore, that the receptionist is in a position (spatially) to comfortably interact with the client, at eye level or lower. The client should have a comfortable stance and should not have to carry bags while trying to negotiate the appointment. (The staff should assist the patient in hanging coats or securing bags or briefcases in a coat closet). Nonetheless, the receptionist's area should distinctly separate the receptionist from the client. A traditional physical barrier (ie, a counter) is necessary (see Figs 31-1 and 31-2). Such a counter should have certain convenience features—most notably, a ledge on which the clients can place their handbags or briefcases. Above all, however, it has to "feel good" to be there. The materials used in the design of the receptionist's counter are as instrumental as the counter's design in promoting this feeling.

ClearCorrect Exhibit 1016, Page 322 of 335

Many of the busiest orthodontic offices grow big without being noticed. In the early years of a practice, it is more important just to grow. More and more patients are brought into the practice, but the infrastructure is not modified. Many busy practices identify the receptionist's desk as a bottleneck area that interferes with rather than facilitates efficient patient flow.[1] Based on our data, 37 square feet per worker must be allocated for the reception area. The location of the reception desk needs to be sufficiently removed from other areas to provide a sense of privacy for the patient. Oftentimes, payments are made, financial matters are discussed, or appointment times need to be negotiated while the client is standing at the counter. Enough privacy to accommodate these conversations serves the office well. Thus, the reception counter is best isolated from the waiting area.

Areas for consultations, initial examinations, records, and patient education

It is recommended that areas used for patient-specific discussions be sufficiently isolated so as to not interfere with the flow of patient and staff traffic. It is beneficial, however, to locate the treatment coordinator in close proximity to where the initial examination will take place. Patients are better serviced when the treatment coordinator has ready access to everything he or she needs. This level of detail may not matter too much in a small boutique practice with only a few chairs; but even in a small practice, these functions must be isolated from the treatment area.

For larger offices, these areas are best located closer to the waiting area—but not along the way from the waiting area to the treatment area. Of course, these areas should all be easily accessible from the treatment area. The design of these areas cannot encourage excuses for not keeping them impeccably neat. These are areas of business where potential patients are educated about why they should choose this particular practice. Once the space is designed for this vitally fundamental function, the layout of the examination chair, radiographic equipment, and other imaging locations is nothing more than a "best fit" exercise. If the space is a serious problem, the clever use of panels made from transparent or semitransparent materials along with equally clever lighting layout creates exciting, clean, hi-tech spaces. Similar approaches can also be used in offices where space is not a limiting factor. Lighting makes or breaks a good design.



Fig 31-1 A foyer and receptionist's desk welcome the patient efficiently and purposefully. The clear Lucite chairs are more decorative than functional. Patients may use the chairs to rest their bags.



Fig 31-2 The waiting area in another practice is traditional in design, yet uncluttered. It is important to provide adequate space for the adults, as the location's patient population characteristics dictate. Computers are everywhere throughout the office, but they are unobtrusive in the living room–like waiting room.

ClearCorrect Exhibit 1016, Page 323 of 335

Fig 31-3 The back wall of a main clinic. It is equipped and laid out to take records in a compact space. Note the dramatic use of light fixtures. The first shelf of the cabinet above the sink is made up of slots to store the day's aligner trays to be delivered. Large boxes are stored elsewhere in the office.

Fig 31-4 Main clinic. Mobile cabinets augment the cuspidor and flat-panel monitors.

Spaces for the staff

Construction of a staff lounge is a show of respect for the people who ensure the success of a thriving practice. Our data reveal that successful practices do not overlook the importance of a staff lounge. If space is limited, however, a staff lounge could be constructed with versatility in mind. A staff lounge could also be used, for example, as a space to conduct in-service training. The design of the staff lounge is best decided by input from the people who will use it. This gives the staff a feeling of belonging. Staff members who look at their duties as "just a job" cannot be good marketers of the practice.

Staff members use their lounge to change and hang clothes, eat lunch, take a coffee break, make private phone calls, and conduct other activities. If the staff members use the lounge to heat food or perform another activity that might generate odors not suitable for an office environment, the room needs to be well ventilated. The staff lounge is ideally located as remotely as possible from public areas. In a suburban setting, it may even have a separate entrance wherever possible.

Treatment areas

Treatment areas need to be constructed to perform two functions: patient treatment and support services. The treatment area is where the patients sit, and the support services area is where sterilization and consultation take place. Oftentimes, the support areas look and function as if they were an afterthought. In some cases, the treatment areas are filled with distractions such as games, busy objects or paintings, and the like. Patients do not, and should not, sit in the treatment area long. Moreover, it is important to remember that, when they do, they mostly look at the ceiling. A television monitor is enjoyed by all patients, even though they only watch it briefly.

Whose comfort is most important in the treatment area? Clearly, it is the workers' comfort. Patients spend minimal time in the treatment area. Their time can be counted in minutes. As much as adult patients might recognize and comment on a luxurious treatment chair, a standard-issue chair does not elicit disapproving comments: patients are most forgiving. For example, if they have to get out of the chair and walk a few steps to the tooth-brushing area, they do not mind.

The unit treatment area should be viewed as a workstation, where everything is within easy reach for the clinical personnel (Figs 31-3 and 31-4). This includes not only how the clinical personnel can reach the items needed for a given procedure but also the ease of discarding used items. If the orthodontist has an existing practice and a new one is planned, it is useful to videotape the activities of the staff over various times of the day and for various procedures. In the videotape, weaknesses of the existing system will become apparent.

After a new office is built and the practice has had some time to function within it, almost everyone can identify elements in the office that they would do a little differently. To avoid such remorse, a videotape analysis can be useful. A camera mounted on a high tripod and placed

ClearCorrect Exhibit 1016, Page 324 of 335

Fig 31-5 Glass paneling is used in such a way to suggest the Invisalign tray. In practical terms, it also provides privacy for conversations. Note that the monitor is visible to the patient to discuss treatment progress and to allow the patient to read the progress notes. This style of communication promotes better cooperation.

unobtrusively in a corner is all that is needed and can be of immeasurable utility before moving out of or renovating an existing office. Efficiency brings comfort no matter the setting; in this case, the comfort of the clinical personnel is the focus.

To achieve greater efficiency and convenience, it is necessary to design storage facilities that will enable the Invisalign boxes to be kept within easy reach. The delivery of aligners in a plastic bag should be smooth.

Finally, because Invisalign is an interactive experience for the patient, it is important to keep patients informed about their progress. Accordingly, a large monitor should be installed at each chair (Fig 31-5). Patients should see not only their ClinCheck images and progress photos, but also what is being written about them in the progress notes. This approach eliminates "you've never told me that"–type comments. Normally, with children, concerns are addressed to the accompanying parent. With adults, however, direct, one-on-one conversation must be standard operating procedure.

Sterilization area

An area that is often overlooked is the sterilization room. Obviously, its location should be near the clinic areas, but the way dirty instruments are brought in and clean ones taken out should be carefully planned. In a busy practice, even the smallest of traffic details matter. Our research data indicate that larger practices find the sterilization room setup inadequate. An opening into the sterilization room through which instrument trays can be passed is

Fig 31-6 Data entry and patient education station is located in the entry of the main clinic. The side view of the three-panel arrangement can be seen in Fig 31-4.

preferred over walking the trays through the door. It also helps to furnish this area with high-speed sterilizers. Quick-turnover sterilization times reduce the need for a large inventory of intraoral instruments. High-speed sterilizers also do not generate a great deal of heat or steam. In close quarters, where a high-powered ventilation fan cannot be fitted, this strategy is preferred. Obviously, this is a problem encountered more often in older high-rise building locations. An architect who understands the flow of an Invisalign practice and its sterilization requirements can design the elements needed in this space sensibly.

Consultation room

The consultation rooms need to be substantial, as it is a key marketing area. In an Invisalign-exclusive practice, its function is slightly different. Education of the patient in Invisalign therapy takes place in this space. Patient education does not require separate quarters. Invisalign patients often have already been educated through their various dental experiences or prior orthodontic treatment. All that is needed for the potential patients is an explana-

ClearCorrect Exhibit 1016, Page 325 of 335

tion of the mechanism of the Invisalign System. As mentioned in chapter 19, for example, the clinician thinks in terms of distances over which forces are applied, rather than simply force magnitude.

The consultation room is also where payments are discussed. Privacy, therefore, needs to be provided in the design. Fundamentally, however, visual elements and equipment are critical (Fig 31-6). They must engulf the patient. The importance of the use of audiovisual equipment in this setting cannot be overstated. In this space, the potential patient is made to understand and see what the treatment entails. Unlike the conventional methods of explaining treatment with fixed appliances, patients see the intended treatment outcome and the stages by which it is achieved. This is done in an effort to eliminate misunderstandings. It is dangerous if patients fantasize about what their teeth will look like. Instead, they should see the intended result and how many aligners it will take to get there.

Finally, the consultation room is also used to educate the staff. It is useful to include seminars in the morning huddle. These seminars are structured such that the staff is educated about orthodontics, in a fashion not dissimilar to what a student of orthodontics is exposed to. The more the staff knows and understands, the better their performance and skills will be. Elements of ClinCheck, polyvinyl siloxane impressions, emerging technology, limitations of tooth movement, and similar topics should be covered.

Technology

The Invisalign System is a shift in the orthodontic paradigm. Clearly, it is technology dependent. The Invisalign office must be equipped appropriately to deliver Invisalign treatment. Imaging systems are the key. A network of computers in all areas of the office will be necessary to deliver the intended care. Invisalign is an interactive system. The clinical personnel interact with the patient at all phases of treatment. Because the patient is intimately involved in the process—because the appliances are removable—images need to be readily available in the treatment area. Thus, it is imperative that all chairs are equipped to facilitate this level of interaction. The equipment that is needed can vary in its configuration, either in the form of individual, networked central processing units (CPUs) or thin client terminals at each chair. These choices depend on many factors, but whatever system the office chooses, it cannot adversely affect the interaction with the patient. The most important equipment consideration is the monitor the patient will see. A 19-inch monitor works best. It is cost-effective and big enough to engage the patient in his or her own treatment. With a 19-inch monitor at the chair, the patient will clearly see his or her ClinCheck and other images.

The Ideal Invisalign Office

Figure 31-7 presents a design for an optimized Invisalign office. As patients enter, they are not in contact with the rest of the office, and the seating areas for adults and children are separated. A concierge caters to people in the waiting areas for such matters as providing refreshments, arranging parking or reservations for lunch, and checking on train or airline schedules.

The most innovative element of this office is the conference center. This centrally located space may be used for staff meetings, continuing education, and meetings with patients. The clinician has a personal monitor, whereas the people seated across the conference table view flat-panel monitors mounted on the walls behind the clinician or the treatment coordinator. The outer walls of the conference center serve as countertops to support the clinic or waiting area.

In the treatment areas, chairs are divided by semitransparent panels to engulf the patient in the Invisalign experience. They also provide privacy. Images collected by the radiographic, scanning, or photographic equipment may be processed at the countertops.

This layout may be modified for computer support as outlined in this chapter.

Technology Requirements

The technology in the Invisalign office is the backbone of support and the central nervous system for efficiency. Indeed, adequate infrastructure for the implementation, maintenance, and upgrade of technology must be designed into a new office. These features include sufficient physical space; environmental controls for sound, temperature, and humidity; uninterruptible electrical power for present and future needs; and access to cabling within control areas to workstation locations. This will allow for the constant evolution of the office's technology backbone. The objective is to establish a technology platform that enables lightning-fast computer access, which is

ClearCorrect Exhibit 1016, Page 326 of 335

FIG 31-7 An idealized Invisalign office layout.

ClearCorrect Exhibit 1016, Page 327 of 335

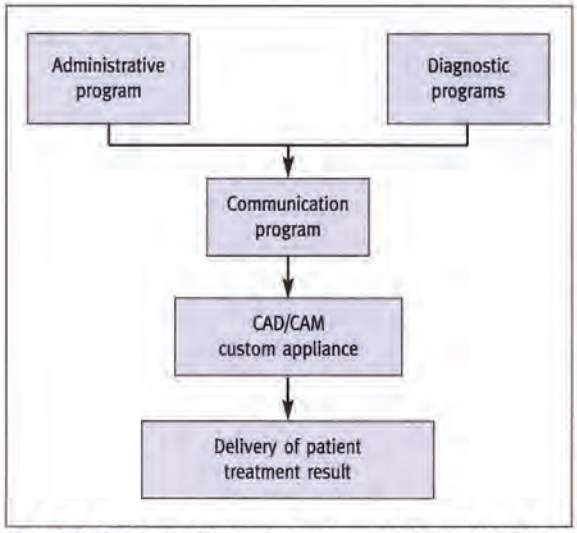

FIG 31-8 Flowchart of computer systems to deliver the desired Invisalign result.

essential for managing administrative, diagnostic (records, diagnosis, and on-line appliance design), treatment information (treatment cards), and inter- and intraoffice communication between clinicians, referrals, patients, and vendors. Not only does this technology enable the orthodontist to provide better treatment, but it allows greater patient participation in treatment choices. In return, this differentiates the practice to a whole new level and provides the "wow factor" to motivate both patients and parents to pursue their (and their children's) orthodontic needs.

Over the last 20 years, the role of computerization in the orthodontic practice has grown far beyond the seemingly elementary tasks of scheduling and billing. More than ever, orthodontists are empowered by this technology to do much more—and, conversely, paralyzed and able to do almost nothing when technology fails. There is a confluence of technology from the first entry of the new patient into the practice to the use of custom computer-designed and computer-manufactured appliances (of which Invisalign is only one of the first) (Fig 31-8).

It is helpful to first consider each of the areas most affected by the expression of this relatively new technology and then describe the physical requirements to implement and manage these programs effectively. Without question, the more orthodontists ask the computer to do in the office, the more powerful the system needs to be, the greater its requirements, and the more complex its maintenance.

Administrative programs

Administrative practice-management programs encompass the patient's first contact with the practice. This can be with the first phone call or visit to a website, the filling out of initial data, the check-in for the first visit, the scheduling of appointments, billing, and both hard and soft communications. All the information that is necessary for excellent patient care and practice growth is based on these management programs.

The whole concept of an Invisalign office has to do with state-of-the-art technology. This must start from the patient's first encounter with the office and follow through to the placement of the retainer and maintenance appointments. Keeping the use of technology as a point of focus will both facilitate treatment and differentiate the Invisalign experience from traditional orthodontic therapy.

Initial forms are completed and sent electronically to the office. In the ideal paperless office, these forms are never printed out, but just filed electronically. The perfect administrative program audits the patient's data, displaying warnings if pertinent data such as health histories, informed consents, or critical diagnostic records are missing.

Appointments are made either over the Internet or by phone. These appointments, and all subsequent appointments, are confirmed via e-mail. Ideally, notification of appointment confirmations and arrival of aligners should be done electronically prior to the patient's appointment.

Of course, no office can function without billing. There is nothing new about an accounts receivable program, but certainly its interaction with the clinical part of the management program is critical. Automated billing via credit card or direct bank withdrawal can dramatically simplify collections.

An additional feature of a practice-management program is the compiling and production of birthday cards, holiday greetings, thank-you letters for referrals, and other practice-building communications. These are coordinated by the administrative area of the practice-management program, either with traditional printed material or through e-mail, thus saving paper and postage costs.

Diagnostic programs

Paramount in an Invisalign office are the diagnostic programs. These programs organize and store diagnostic records, plan treatment, and monitor or modify treatment.

ClearCorrect Exhibit 1016, Page 328 of 335

Image capture is managed by a program to capture, modify, and store digital images. These images include intra- and extraoral images and digital panoramic and cephalometric radiographs. The program also provides a method to digitize cephalometric images for diagnostic measurements using any number of standard analyses. The program must also provide a method of transmitting these images to other professionals and vendors. To complete the case submission for Invisalign, these data must be easily manipulated to enable the images to be uploaded to Align Technology.

Communication programs

Communication both within and outside of the office is a critical issue in any high-technology office, all the more so in one that must deal with a computer-designed and computer-manufactured appliance.

Within the office, paperless messaging and intraoffice communication may be done with a custom-designed program called V.Com. (Virtual Software Solutions). The system functions on several levels. It provides a banner across the top of the screen on each computer, which tells the clinician or staff where they are needed and for what procedure. The same system is also used for coded or text messages to tell the staff of phone calls, action instructions, and more.

V.Com has an additional message pad function. Messages can be entered on screen on a message pad form. If these messages relate to a patient, they are automatically noted in the patient's treatment card, as are any replies to the patient-specific message. For example, the clinician can call up the message pad from any computer, see all of the messages, and respond, with the responses going back to the sender or any other designee and being noted in the patient's chart. These messages can then be deleted from the message pad, archived, or printed.

E-mail messages can be sent to referring clinicians, consulting specialists, or even the patients themselves from within the patient's treatment card. Records, which consist of panoramic and cephalometric radiographs and digital photographs, can be uploaded to a host website (such as www.AnywhereDolphin.com, if the imaging program used is Dolphin Imaging). This also includes any messages or notes between the clinician and the person(s) to whom the records have been uploaded. An entry or comment made in the patient's treatment card can be sent by clicking the e-mail icon, which brings up a prompt that asks to whom the entry or comment should be sent. If, for example, the patient's dentist is selected, that dentist will receive an e-mail stating that "on this date the following entry was made on (patient's name) treatment card." The fact that a copy of this entry was e-mailed to the selected party is automatically entered in the treatment card as well. The time saved by this feature is significant.

If an orthodontist wants to send a message that includes patient records, he or she can upload the records to AnywhereDolphin by simply clicking on the upload icon. The orthodontist is then asked to whom the records are to be made available and for any message that is to be attached. The intended recipient receives an e-mail with the attached message, a note stating that the records are available to them, and a link that brings them directly to the AnywhereDolphin site.

Computerized appliance fabrication

Invisalign, as well as a number of other new orthodontic appliance systems, now involves the transmission of patient data both to and from the orthodontic office before a computer-designed and computer-fabricated appliance can be placed for the patient. Other computer-designed and computer-fabricated appliances available or soon to be available include Orametrix's SureSmile wires and Ormco's Insignia bracket system, or the systems of OrthoCAD for bonding. Ultimately, the data will be entirely digital, provided by light, laser, or x-ray scans that produce the patient's three-dimensional data in what is known as *machine code* to be used to design and fabricate the appliance. At present however, a combination of digital and physical records sent to the appliance fabricator is used.

For Invisalign, digital images (extra- and intraoral photographs and digital cephalometric and panoramic radiograph images) as well as a physical set of impressions are sent. The impressions are digitized by a computerized axial tomography (CAT) scan process (see chapter 6). From this now-totally-digital data, a digital representation of the dentition is prepared. This is sent back to the orthodontic office over the Internet in the form of the ClinCheck. The ClinCheck allows the orthodontist to confirm that the treatment guidelines prescribed have been adhered to and that the result will meet or exceed expectations given adequate tissue response and patient compliance. The actual ClinCheck process is another topic (see chapter 11). What is important to note is the need for high-speed communication, which makes possible the transmission and reception of this data, as well as for powerful video hardware

ClearCorrect Exhibit 1016, Page 329 of 335

to be able to display and use this data to design the patient's appliance. Broadband Internet access is a must.

Computer room

To support the kind of hardware required to run these programs, carry data into and out of the office, back up data, and allow for maintenance and updating of this infrastructure, the construction of the hardware skeleton, or backbone, is required. An Invisalign office needs a "nerve center," or computer room, that communicates with a large number of workstations located throughout the office and in remote locations, as well. It is here that the traditional office has been sorely deficient. A new way of designing an office is required.

The use of computers in dental offices dates to the late 1970s and early 1980s. These first steps into the computer age usually involved word processing and billing. In the late 1980s, some use of scheduling programs and the very beginning of computerized treatment records and notes was seen. In the late 1980s, the computer began to store video images of patients. Some very early uses of computerized diagnostic tools also occurred. In the 1990s, digital imaging—both photographic and radiographic—became commonplace in the office. Currently, the era of instant transmission and sharing of patient records is at hand, which allows data to be viewed over the Internet by practitioners in different offices and different specialties.

The trend is clear. Over the past 20 years, what was thought to be cutting edge has become standard. The use of, and dependence on, computers in the professional office has grown at an ever-accelerating pace. Larger, more reliable, computer platforms are required in orthodontic offices to do everything from making appointments to generating appliances and prosthetics. Phone systems, if they do not do so already, will soon use the Internet to carry voices as well as data, while increasing the speed at which data can be transmitted. Even plaster casts, probably soon to become a tool of the past, are digitized and stored for retrieval electronically.

As professionals have embraced more and more technology, the use of the darkroom, and soon the file cabinet, has become a thing of the past. At first blush, this may appear to be a great way to save space in the office, as well as the labor of developing and duplicating radiographs and filing charts. This change is not without its requirements, however. No longer do orthodontists have a few computers in their offices, sitting isolated on desks, or even rudimentary networks sharing data on a peer-to-peer level. Currently, it is not unusual to find offices with 20 to 40 computers connected to powerful servers, uninterruptible power supplies (UPSs), sophisticated tape backups, and multiple smaller servers for everything from intraoral scanning to connecting multiple offices.

Decisions regarding the purchase of new technology are often made more difficult by the "FOO" factor. This "fear of obsolescence" is the most common reason for not integrating new technology. Paralysis can occur from always waiting for the next generation, the next fastest chip, or for the price to come down. It is necessary to accept the fact that the latest technology will be cutting-edge for little more than a day and that tomorrow inevitably brings something new or better. It is furthermore necessary to accept the fact that technology needs to be purchased only when it makes sense, either because of the need for increased efficiency or a more clearly defined return on investment. It is not reasonable to think that one system and one program can be installed and used without modification or upgrade for the next 5 years. The fact is that it will be necessary to upgrade hardware and software, perhaps frequently, to maintain a technological edge in both the diagnostic and management arenas. This edge often differentiates one practice from another.

Given the fact that hardware and software will need to be upgraded continuously, it is interesting that, up to this point, orthodontists have generally failed to build offices that facilitate the installation, maintenance, and upgrade of computer systems. An infrastructure that can allow computer systems to evolve, without inconvenient and costly reconstruction and modification of physical plants, is essential.

The issues that should be considered include the amount of physical space required, power requirements, ventilation, noise control, and access for wiring and rewiring. Ease of recabling, as well as space for phone equipment, should also be considered. All of these factors must be taken into account not only in relation to the systems currently in place but with consideration for the evolution that will undoubtedly continue to take place. These issues include additional software applications, larger storage devices for images with greater resolution, new diagnostic procedures such as intraoral scanning, and computer-driven appliance fabrication and treatment monitoring.

Constructing a data center in the orthodontic office is a science and should be treated as such. It is important to accept the fact that doing this correctly requires space.

ClearCorrect Exhibit 1016, Page 330 of 335

The darkroom and filing area may be gone, but there is now a need for a dedicated computer room/closet that provides adequate ventilation, power, noise control, and—most important—access that allows neat organization of hundreds of cables that will run in and out of this space. While space is always at a premium in an office, this is now truly a required area, not a luxury.

Rack-mounted equipment

To go about making use of such an arrangement in an efficient manner, it is necessary to first make a commitment to using rack-mounted equipment. Rack-mounted equipment allows more devices to be packed into a smaller area in a more organized and maintainable fashion by using standardized sizing, both vertically and horizontally. Standard rack-mounted equipment is 19 inches wide, but varies in height. The height is listed as "U"s, meaning units of height. Each U is 1.75 inches. A server, for example, could be as small as 1 U in height (1.75 inches); a 2-U server would be 3.5 inches high by 19 inches deep. On a typical 7-foot Electronics Industries Association–compliant rack, there are 42 rack units. Generally, rack-mounted equipment sits on slides, similar to a drawer, that allow the unit to slide out for service. The cables are on extending arms to allow the machine to slide out without pulling out all the cables from the back.

The use of rack-mounted equipment allows for better cable management and easier maintenance, power handling, and ventilation. This is a significant leap beyond servers in floor-standing towers that are lined up along a wall or under a counter with a nest of poorly managed cables. In designing an office, it is important to note that not all racks are equal; there are some compatibility issues.

Size of the data center room

Room to move around the equipment racks on all sides and for adequate air movement is essential. It is also necessary to leave enough space to manage a lot of cables. There must also be room to grow as computer usage increases. Adequate space for phone equipment, which may tie into the computer, is also needed. Even if it is not rack-mounted, phone equipment should be included in the office's data center. Most everything will go on a rack, including servers, UPSs, switches to allow one keyboard and monitor to control multiple servers on the rack, a keyboard drawer, and monitor. A phone is needed on the rack as well, since it may be necessary to obtain technical assistance over the phone while doing upgrades and making modifications.

The data center need not be in the office. It could be in the basement or down the hall, since it should essentially be able to run as what is called a "lights-off" installation. In general, for a 4,000-square-foot office, a 6 × 10–foot room (60 square feet) should be adequate for present and future requirements. Ceiling height should also be considered. Smaller offices require less space, but it is important to keep in mind the rack's dimensions and the need to work comfortably around it.

Power requirements

It is best to provide the data center with two dedicated 30-amp lines, having available both 110 and 220 volts. These lines should be on a 24-hour circuit. Ideally, a backup generator will be available to handle the data center, including its heating, ventilation, and air conditioning equipment. Generators are not generally expensive or complicated to install. The UPS can be programmed to do an orderly shutdown of the server in the event of a power failure—another good precaution. These considerations are best regarded as insurance—a premium to be paid with the hope that the benefits will never be needed—that provides the comfort of protection.

Heating, ventilation, and air conditioning (HVAC)

Computers create a tremendous amount of heat and noise. The hotter the computer gets, the more likely it and its subsystems are to fail. Since reliability is a critically important factor, ventilation cannot be ignored. In addition, computer equipment, especially tape drives and hard drives, are particularly sensitive to dirt and dust. Since they all have a large number of powerful internal fans cooling them, the computers are pulling a good volume of room air over critical components. This, of course, pulls in any dust or dirt that is suspended in the air.

To protect computer equipment from heat and dirt, a controlled environment is critical. Ideally, the data center in the office will have adequate individually controlled air conditioning and good air filtration to remove particulate matter. Humidity should be controlled as well, to eliminate as much buildup as possible of static electricity, which can instantly "zap" hardware.

The following design criteria are often used by convention: temperature, 68°F to 77°F; and humidity, 50% ± 5. It is necessary to consult an HVAC contractor to find the best way of addressing these concerns.

ClearCorrect Exhibit 1016, Page 331 of 335

Cabling

Choosing the type of cable to run is an important decision. Cables are categorized according to the amount and type of data they can carry and, importantly, at what speed. The category also indicates the type of shielding from interference that is in the cable. Cables are also rated as to their fire resistance; many local building codes now require that cables that run in the ceiling, floor, or walls be plenum rated. Cable requirements change continuously. Currently, at a minimum, category 6 cable should be used. Category 5 cables transfer data at a maximum of 100 MB/s, whereas category 5e and 6 cables transfer data at 1 GB/s. Whatever cable is run, however, will eventually be replaced to move more data more quickly. For this reason, how the cables are run is critical.

An early decision to make is where to run the cables. Cables can be run in the ceiling, beneath a raised floor with removable panels, or in the ceiling of the space beneath the office. In the ceiling, cables can be run in trays to keep them in one place, bundled together with nylon wire ties or wrapped with Velcro straps. It is important not to run the cables parallel with electrical cables and preferably not within 6 inches of an electrical cable. It is also best not to line the cables up too neatly, since this facilitates cross-talk between the cables, in spite of their shielding.

In big data centers, it is common to run cabling beneath a raised floor. These are often special floors made up of removable panels that look similar to a suspended ceiling. The sections can be removed for access. This would be great in a dental office, since all of the plumbing and electrical would be accessible as well. It is costly, however, since the floor has to be load bearing. It is also not necessarily attractive, unless covered with some other type of flooring, obviating some of its benefit.

As already noted, it is important to check local building codes. Whether in the ceiling, wall, or floor, according to code, cables are often supposed to be plenum rated for fire resistance. Additional codes requiring that all abandoned wiring be removed exist in some areas. This would be an issue when recabling. Removing abandoned cables certainly facilitates knowing which cables run where, but removing them from a tangled web in the ceiling is not an easy job.

Some computers are mounted on individual treatment units, and no longer just on a counter or stand in front of or behind the patient. This means there has to be a way of getting the cable to the chair, as well as up or down a wall into a wall jack if the computer is on a desk or counter. This is difficult even in a standard wall with plasterboard and studs; it is almost impossible in cement walls and floors or plaster walls. If there are areas in the office without suspended ceiling tiles, getting the cables through the ceiling is costly. More important, the need to recable relatively easily without having to redecorate with new floor covering, flooring, or wall covering must be considered. For this reason, once the cable leaves an accessible ceiling or floor and travels through any inaccessible area, it should be in a conduit to allow the old cable to be easily removed and a new one to be pulled.

Servers in the office

In today's professional office, there is likely to be more than one server in the computer center. For example, one author's (ML's) office runs:

1. A main server with dual 2.8 GHz Xeon processors, 4-GB RAM, 2 × raid controllers, 4 × 72–GB hard drives, and 2 × 36–GB hard drives
2. A second server running the terminal server, which allows access to the main server from remote locations (to allow clinicians to work from home) or access to all computer data from a second office location
3. An exchange server, which manages office e-mail
4. An old UNIX server, which is left over from an antiquated practice-management program but that is maintained for old, unconverted data
5. A dedicated server for Orametrix, a diagnostic and treatment tool that scans intraorally and fabricates custom wires

In contrast, another office (OT's) runs on a single server with mirrored hard drives and dual processors. A 1- or 2-year age difference is reflected in the equipment specifications.

Backup

Both of these authors' offices use a tape backup. This device has a library of eight tapes, which it rotates through in backing up critical data every night. Key staff members receive an e-mail from the server reporting that the backup was successful, or, occasionally, that it was not. Some imaging data is also backed up to a remote site managed by our imaging provider. Backing up data is a thankless task, unless disaster strikes. Conventional wisdom states that it is best to back up daily and take at

ClearCorrect Exhibit 1016, Page 332 of 335

least one backup copy offsite each week. It is also important to periodically attempt to restore data from the backup tape. It is not uncommon to find that the backup program indicates a successful backup, but that the tape cannot restore the data to your system.

Internet-protocol phone equipment

Phone equipment can also be tied into the computer system. This allows the addition of many interesting features, such as the ability to bring up a patient's chart immediately if his or her phone number is recognized by caller ID. Having the phone connected over the Internet also enables staff members who work from home, on insurance processing and word processing, to plug a special phone into their home broadband router and answer the office phones from home.

Broadband connection

Having the ability to transmit data requires a high-speed connection to the Internet. Some offices transmit almost all of their treatment notes, radiographs, and images to referring clinicians over secure Internet connections. One problem for offices that are so equipped is that some referring clinicians do not have broadband connections in their offices. Often, however, these professional offices are quick to upgrade when they see the many advantages of a broadband connection.

There are a number of broadband connections available. In our office, we use what is known as a T1 line. While it is relatively costly, we use it for our phone service as well, saving on the total cost. There is a tradeoff: when the phone lines take up part of the broadband bandwidth (referred to as a fractional T1 line), the rate at which data can be transmitted drops. With a new office location requiring data interchange with our main server, we have since reverted to separate lines for our phones, thus reclaiming our total T1 bandwidth. Other systems include DSL (digital subscriber line) over a phone line, which offers different speeds for uploading and downloading depending on price, or cable modems, which are fast and reliable but whose speed degrades as more people in an area use it. All of these technologies provide different speeds for uploading and downloading data. Because of the need in offices to upload images, which involve large amounts of data, upload speed is more important than it is for home broadband, for which downloading is the primary use.

Compromise

Because clinicians are not always able to fulfill their wish list because of space limitations, there are some smaller steps that can be taken to achieve a more manageable approach to computer installation. These steps include the following:

- Use a "short" rack system that can sit under a counter (although it will require more depth than a standard 24-inch cabinet); this will limit the number of devices that can be rack mounted. Two short racks could be used side by side. These racks are on wheels and can roll out to allow access to the cabling from the back. It is necessary to specify the correct vertical rails to accommodate computer equipment; there are several different kinds. Access is still best if you can move around the rack.
- Provide adequate 24-hour power.
- For ventilation, run an air-conditioning duct right down to the rack, and use an auxiliary blower in the duct to increase airflow. A good exhaust duct is a good idea as well.
- These machines and their cooling devices are noisy. Choose a spot where noise is not an issue or where you can provide sound insulation without interfering with the ventilation.
- Provide access for Internet connection (ie, cable, DSL, or T1).

Information technology support

As information technology (IT) needs become more complex, the need for 24-hour support becomes more evident. While it might be possible to run an orthodontic office if the imaging program, or even the scheduling or billing system, is down, the prospect of a total loss of all records during a computer malfunction now exists. We found it best to employ a full-time IT support person on staff. Between backups, program upgrades, hardware maintenance, and custom programming, he is kept busy. There is a significant cost factor here, which offsets some of the cost benefits of the digital practice. Before venturing into the high-technology world, the practitioner must be prepared to either spend an increasing amount of personal time working with the system, assign specific staff members to the task, have dependable outside local support, or have an in-house IT person. The importance of "local support" cannot be overemphasized. Even the best of the

ClearCorrect Exhibit 1016, Page 333 of 335

software vendors, with the best support, can only do so much offsite. A local, hands-on technician is a real requirement.

Summary

There is clearly no turning back. We have seen many new technologies evolve in medicine and dentistry. All of them seem to require more space, more equipment, and more technical support. It makes little sense to design and build a facility that does not take into account that more computer equipment is needed and that it is changing at an ever-increasing pace. It can only save time and expense to design into our offices the ability to keep pace with the rapidly expanding opportunities to provide our patients with the best possible diagnostic, treatment, and communication technology.

Reference

1. Lorino R. Design characteristics of the efficient orthodontic office [master's thesis]. Philadelphia: Temple University, 2004.

Recommended Reading

ABR'S E-Newsletter, May 11, 2001, no. 1, vol. 1. ABR Consulting Group website. Available at http://www.abrconsulting.com/Newsletter/05-11-01.htm. Accessed August 1, 2003.

ABR'S E-Newsletter, June 8, 2001, no. 1, vol. 2. ABR Consulting Group website. Available at http://www.abrconsulting.com/Newsletter/06-08-01.htm. Accessed August 1, 2003.

ABR'S E-Newsletter, August 24, 2001, no. 1, vol. 3. ABR Consulting Group website. Available at http://www.abrconsulting.com/Newsletter/08-24-01.htm. Accessed August 1, 2003.

ABR'S E-Newsletter, September 21, 2001, no. 1, vol. 4. ABR Consulting Group website. Available at http://www.abrconsulting.com/Newsletter/09-01-01.htm. Accessed July 31, 2003.

Types of cables. NetworkStuff.net–XDR2.com website. Available at http://www.networkstuff.net/WhatIsCable.htm. Accessed August 1, 2003.

What's the difference between CAT 5 and CAT 5e cable? CAT 5 Cable Company website. Available at http://www.cat-5-cable-company.com/faq-cat5-v-cat5e.htm. Accessed August 1, 2003.

Turner V, Pitt W, Brill KG. Industry standard tier classifications define site infrastructure performance [The Uptime Institute website]. Available at http://www.upsite.com/TUIpages/whitepapers/tuitiers.html. Accessed August 1, 2003.

ClearCorrect Exhibit 1016, Page 334 of 335