Check for updates

Beating Heart Catheter-Based Edge-to-Edge Mitral Valve Procedure in a Porcine Model

Efficacy and Healing Response

James I. Fann, MD; Frederick G. St. Goar, MD; Jan Komtebedde, DVM; Mehmet C. Oz, MD; Peter C. Block, MD; Elyse Foster, MD; Jagdish Butany, MBBS, MS; Ted Feldman, MD; Thomas A. Burdon, MD

Background—Surgical edge-to-edge repair has been used in the treatment of mitral regurgitation. We evaluated the ability of a catheter-delivered clip (Evalve, Inc) to achieve edge-to-edge mitral valve approximation without cardiopulmonary bypass and the healing response of this technique.

Methods and Results—Twenty-one pigs underwent general anesthesia and left thoracotomy. A 10F flexible delivery catheter with a clip was placed into the left atrium. With echocardiographic and fluoroscopic guidance, the clip grasped and approximated the mid portion of the anterior and posterior leaflets. After a double orifice had been confirmed, the clip was detached and the catheter withdrawn. All animals survived and had successful clip placement. Three animals were euthanized at 4 weeks, 9 at 12 weeks, 1 at 17 weeks, 7 at 24 weeks, and 1 at 52 weeks. The clip was well positioned, with leaflet approximation in all animals except 1, in which the clip separated from the posterior leaflet at 4 weeks without affecting valve function. The clip was modified and implanted in 4 pigs; all were intact at 12 to 24 weeks. Scanning electron microscopy showed clip encapsulation with complete endothelialization. Mitral stenosis and thromboembolism did not develop. Two animals developed endocarditis (1 at 12 weeks and 1 at 17 weeks). Progressive healing occurred in all other animals.

Conclusions—Edge-to-edge mitral valve approximation can be successfully and reliably achieved with a catheter-delivered clip without cardiopulmonary bypass, resulting in durable healing. The success of this device supports the development of a percutaneous catheter-based system for mitral valve repair. **(*Circulation*. 2004;110:988-993.)**

Key Words: mitral valve ■ catheters ■ surgery ■ echocardiography

Downloaded from http://ahajournals.org by on May 18, 2026

The edge-to-edge mitral valve repair technique has been used in treating degenerative and functional regurgitation by surgically approximating the edges of anterior and posterior leaflets at the site of regurgitation.[1–9] If the repair suture is placed near the middle of both leaflets, this procedure generates a "double-orifice" valve. This simple approach can effectively reestablish mitral valve competence and provides an alternative to more complex repair procedures.[1,2,4–6] The edge-to-edge technique ensures a fixed region of coaptation that allows systolic leaflet closure without compromising the subvalvular apparatus, thereby preserving left ventricular function.

A less invasive approach for mitral valve repair is likely to be of benefit for patients with mitral regurgitation, particularly those who cannot tolerate an extensive open-heart surgical repair or replacement.[10–12] Morales et al[10] described the use of a screwlike device to approximate the leaflet edges to achieve a double orifice valve. Downing et al[11] and Alfieri et al[12] reported their experience with a suture-based approach via a thoracotomy to achieve edge-to-edge leaflet approximation without cardiopulmonary bypass. The question remained whether a reliable repair system can be developed that can be used in the surgical setting and, more importantly, via a percutaneous endovascular approach in the catheterization laboratory. The purpose of the present study was to determine whether a catheter-delivered clip could be used to accomplish edge-to-edge mitral valve repair in a closed-heart setting and to evaluate its performance in terms of leaflet fixation and healing. An additional goal was to provide the technological basis for a percutaneous system to achieve the edge-to-edge mitral repair.

Methods

Clip Design and Function

The clip device is a 2-armed, polyester-covered, soft tissue–fixation device. Its design allows controlled movement among 3 configura-

Received November 18, 2003; de novo received January 19, 2004; revision received March 23, 2004; accepted March 25, 2004.

From Stanford University (J.I.F., T.A.B.), Stanford, Calif; Cardiovascular Institute (F.G.S.G.), Mountain View, Calif; Evalve, Inc (J.K.), Redwood City, Calif; Columbia University (M.C.O.), New York, NY; Emory University (P.C.B.), Atlanta, Ga; University of California (E.F.), San Francisco, Calif; University of Toronto (J.B.), Ontario, Canada; and Evanston Northwestern Healthcare (T.F.), Evanston, Ill.

Correspondence to James I. Fann, MD, Department of Cardiothoracic Surgery, Stanford University Medical Center, 300 Pasteur Dr, Stanford, CA 94305. E-mail jfann@stanford.edu

© 2004 American Heart Association, Inc.

Circulation **is available at http://www.circulationaha.org** **DOI: 10.1161/01.CIR.0000139855.12616.15**

Imperative Care v. Inari Medical
IPR2025-01025
Imperative Care Ex. 1078

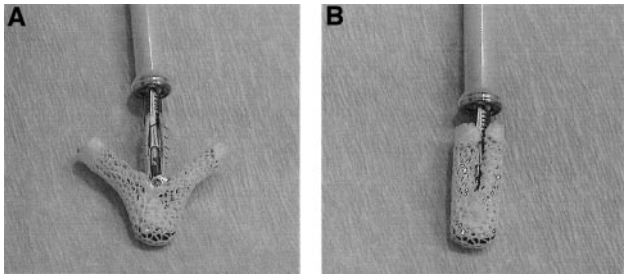

Figure 1. Delivery catheter and mechanical clip are shown with clip in open (A) and closed (B) positions. Clip is detached from catheter after edge-to-edge leaflet approximation has been achieved.

tions: closed, grasping, and inverted. The outside dimension when closed is 4 mm; in the grasping position, the 2 "arms" span ≈20 mm (Figure 1). It is designed to coapt up to 8 mm of mitral leaflet on each side. In the open position, it is used to grasp and immobilize the central mitral leaflet scallops by retraction of the delivery catheter. Each arm has an opposing "gripper" that aids in securing the leaflets in the clip by means of small multipronged friction elements. After the leaflet is captured between an arm on the ventricular side and a gripper on the atrial side, the clip is closed in a locked position. Once a functioning double-orifice mitral valve is confirmed with echocardiography, the clip is detached. The handle at the user end of the delivery catheter actuates the arms and grippers, the locking mechanism, and detachment of the clip device. In the present study, the clip and delivery catheter system were packaged and sterilized with 1 cycle of ethylene oxide at a local hospital.

Animal Experiment

Twenty-one Yorkshire pigs (weight 70 to 90 kg) received intravenous ketamine and atropine and underwent endotracheal intubation and general anesthesia with inhalational isoflurane (1% to 5%, Drager anesthesia/ventilator). A catheter was placed in the left aural artery for hemodynamic monitoring, and an intravenous catheter was placed for vascular access. Continuous ECG monitoring was used. A 9F introducer was placed in the femoral artery for subsequent passage of a 7F pressure line for left ventricular pressure measurement. Ampicillin (35 mg/kg IM) and gentamicin (4 mg/kg IM) were given immediately before the operation and at 12 hours after completion of the operation. Aspirin (325 mg) and clopidogrel (Plavix 600 mg, Bristol-Myers Squibb/Sanofi Pharmaceuticals) were given orally 24 hours before the procedure. The animal was positioned in the right lateral decubitus position. Under sterile conditions, a left lateral thoracotomy was performed, the fifth rib was removed, and a pericardial cradle was created. A baseline epicardial echocardiographic study was performed (Acuson, V4c and V7 probes, 5- to 7-MHz probe, Siemens Medical) with collection of 2D and Doppler data in the standard views, including short and long axes and reverse apical 2- and 4-chamber images through the dome of the left atrium. Intravenous heparin was administered to maintain an activated clotting time of >600 seconds. A pursestring suture was placed at the lateral aspect of the left atrium, followed by placement of an 18-gauge catheter for atrial pressure measurement before and after device placement. Another left atrial pursestring suture was placed just anterior to the left superior pulmonary vein, and a 19F introducer catheter with a curved tip and hemostasis valve was inserted. A 4-mm-wide by 12-mm-long implantable clip (Evalve, Inc) attached to a 10F delivery catheter was inserted through the introducer in a closed position into the left atrium (Figure 2). Heparinized saline was infused continuously through the delivery catheter.

Once in the left atrium and positioned with echocardiographic guidance, the clip was opened and oriented so that it was perpendicular to the line of leaflet coaptation and the tip of the clip was directly above the point of coaptation of the middle portion of the anterior and posterior leaflets. With the delivery catheter aligned

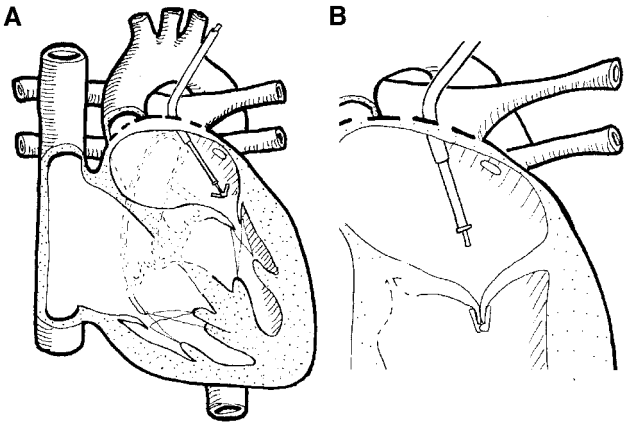

Figure 2. Diagram of placement of delivery catheter and detachable clip via introducer into left atrium (A) and detachment of clip from catheter (B).

with the long axis of the left ventricle, the clip was advanced through the mitral orifice to the level of the papillary muscles. With echocardiographic guidance, retraction of the delivery catheter and clip against the leaflets was visually timed to occur during systole, when the leaflets were naturally apposed. Echocardiographic evaluation was performed to confirm successful grasping of both leaflets; the location of the clip and valvular competence were evaluated. If the result was deemed suboptimal, the clip was advanced into the left ventricle, and further grasping was attempted. If substantial catheter repositioning was indicated (eg, if the delivery catheter was not properly aligned with the left ventricular long axis or if the clip was not sufficiently perpendicular to the line of coaptation), the clip was inverted, and the clip and delivery catheter were pulled back up into the left atrium, where manipulations and adjustments could be performed distant from valve leaflets and the chordae tendineae. Once a successful grasp was confirmed echocardiographically, the clip was closed under fluoroscopic guidance. Until detachment from the delivery catheter, the clip could be easily repositioned multiple times or removed. When adequate clip closure was achieved, echocardiographic imaging was again performed to evaluate clip placement and leaflet approximation, relative orifice sizes, and mitral valve competence. The clip was then detached from the delivery catheter. After the delivery catheter and the introducer were withdrawn from the left atrium, the thoracotomy was closed, and the animals recovered. The postoperative antibiotic regimen included cephalexin (20 mg/kg twice per day orally for 3 weeks). The animals were maintained on aspirin (325 mg/d orally) and clopidogrel (150 mg/d orally). Low-molecular-weight heparin (Lovenox 80 mg twice per day subcutaneously, Aventis Pharmaceuticals) was started 8 to 12 hours after the procedure and continued for 4 weeks postoperatively. Notably, because of premature partial release of the clip from the posterior mitral valve leaflet on follow-up (see below), 4 of the 21 pigs underwent placement of a clip with a modified frictional component.

Follow-Up Studies

Each animal was assigned a specific survival period before implantation: 4, 12, 24, or 52 weeks. The initial postoperative evaluations were conducted in all animals at 1 week after the implantation. Transthoracic and/or transesophageal echocardiography and fluoroscopy were performed to assess clip motion, double-orifice valve configuration, and absence of mitral regurgitation. Subsequent interim evaluations were performed. At the time the animals were euthanized, each was given intravenous ketamine and atropine, intubated, and placed under general anesthesia with inhalational isoflurane as described previously with the initial operation. The animals were placed in a right decubitus position, and a repeat left lateral thoracotomy incision was made. Epicardial echocardiography and fluoroscopy were performed. Additionally, the left atrial and left

Downloaded from http://ahajournals.org by on May 18, 2026

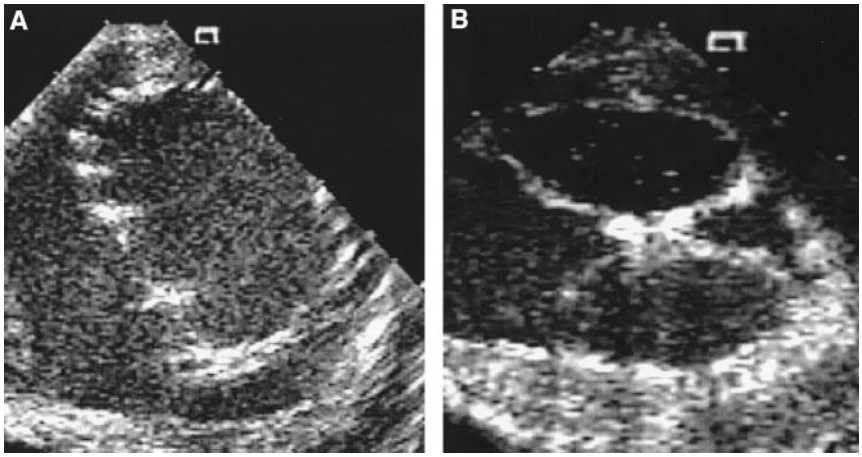

Figure 3. Epicardial echocardiographic short-axis images of mitral valve before (A) and after (B) clip placement. Double-orifice mitral valve was achieved after clip placement and detachment (B).

ventricular pressures were measured simultaneously with an 18-gauge catheter directly placed in the left atrium and a 7F catheter placed via an introducer in the femoral artery, respectively. After adequate echocardiographic and fluoroscopic images and hemodynamic measurements were obtained, the heart was arrested in diastole and explanted. Postmortem evaluation of the heart was performed, including gross inspection of the left atrium, left ventricle, mitral valve, mitral annulus, and subvalvular apparatus. The heart, along with the mitral valve and subvalvular structure, was fixed in 10% formalin (for histopathology) or 2.5% glutaraldehyde (for scanning electron microscopy). Histopathology of the mitral valve with clip, chordae, and papillary muscles was performed. The heart, liver, spleen, kidneys, and brain were removed and evaluated for evidence of thromboembolism and thrombosis.

The animal care committee at the facility approved the use of laboratory animals in this protocol. All animals received humane care in compliance with the "Guide for the Care and Use of Laboratory Animals" prepared by the Institute of Laboratory Animal Resources, National Research Council, and published by the National Academy Press (revised 1996).

Statistical Analysis

All data are reported as mean±SD. Preimplantation and postimplantation hemodynamic data were evaluated with Student's *t* test for paired comparisons. A probability value less than 0.05 was considered statistically significant.

Results

Baseline echocardiography of the study animals demonstrated no mitral valve pathology or regurgitation in 20 animals and mild to moderate mitral regurgitation in 1 animal. All animals underwent successful clip placement with echocardiographic confirmation of a double-orifice mitral valve and survived the procedure (Figure 3). The number of grasping attempts ranged from 1 to 4, with half of the cases achieving a double-orifice mitral valve on the first grasp attempt; there was no change with increased experience. The time for device introduction and deployment with removal of the delivery catheter was 18.3±9.0 minutes, which also did not change with increasing experience. After the procedure, the degree of mitral regurgitation remained none to trace in all 21 animals, including the one with mild to moderate mitral regurgitation at baseline.

Interim and Explantation Evaluations

At the interim evaluation 1 week after the procedure, adequate transthoracic echocardiographic views were obtained in 16 animals. In these animals, the degree of mitral regurgitation remained none to trace. In the remaining 5 animals,

TABLE 1. Echocardiographic Evaluations of Mitral Valve Function Immediately After Implantation, Initial Interim Evaluations, and Final Evaluations at Time of Explantation

Animal Group* (No. of Animals)	Time of Intended Interval Study					
	Postclip†	1 Week	4 Weeks	12 Weeks	24 Weeks	52 Weeks
4-Week (3)	3 N/T	1 ND; 2 N/T	3 N/T‡	...	...	...
12-Week (9)	9 N/T	2 ND; 7 N/T	1 ND; 8 N/T	8 N/T; 1 moderate§	...	...
17-Week (1)	1 N/T	1 N/T	1 ND	1 N/T	1 moderate‖	...
24-Week (7)	7 N/T	2 ND; 5 N/T	1 ND; 6 N/T	2 ND; 5 N/T	6 N/T; 1 mild	...
52-Week (1)	1 N/T	1 N/T	1 N/T	1 N/T	1 N/T	1 mild

N/T indicates none or trace mitral regurgitation; ND, not able to determine echocardiographically.

*Animals were grouped according to time of device explantation.

†Echocardiographic evaluation immediately after clip deployment.

‡One animal in this group, found to have a double-orifice mitral valve at 1-week follow-up, had loss of clip attachment to the posterior leaflet edge at 4 weeks; there was only trace regurgitation.

§This animal developed clinically silent endocarditis, with moderate regurgitation seen at time of explantation at 12 weeks.

‖This animal, intended to be explanted at 24 weeks, was diagnosed with symptomatic endocarditis at 17 weeks; although the double-orifice valve was present, there was moderate regurgitation.

Downloaded from http://ahajournals.org by on May 18, 2026

TABLE 2. Hemodynamic Data Before Clip Deployment, Immediately After Clip Deployment, and at Time of Explantation

	Before Implantation	After Implantation	Explantation
Mean left atrial pressure, mm Hg	12.5±7.1	12.6±7.4	7.76±4.4
Left ventricular systolic pressure, mm Hg	106.4±13.4	108.3±17.0	92.2±14.0
Left ventricular diastolic pressure, mm Hg	8.33±11.5	8.90±20.1	6.56±9.9

Values are mean±SD. Comparisons of preimplantation and postimplantation data are not statistically significant.

visualization of the mitral valve was less optimal, and the presence of a double orifice could not be confirmed (Table 1). Additional echocardiographic studies were performed at 4 weeks; the status of the valve could not be determined in 3 animals. The clip was well positioned with good leaflet approximation in the remaining animals except one. In this animal, a double-orifice mitral valve was documented at 1-week follow-up, but the clip was separated from the posterior leaflet but was securely attached to the anterior leaflet by 4 weeks. The mitral valve remained competent by echocardiography (trace regurgitation). The device and its components were intact. It was suspected that there might have been inadequate capture of the posterior leaflet at the time of implantation, with subsequent release of tissue. The frictional component was modified to ensure optimal capture, and this modified clip was implanted in 4 pigs (noted above). All were intact at 12 to 24 weeks, with good leaflet approximation.

A total of 3 animals were euthanized at 4 weeks, 9 at 12 weeks, 1 at 17 weeks, 7 at 24 weeks, and 1 at 52 weeks. A double-orifice mitral valve was found in 20 (96%) of the implants at time of explantation (Figure 4). No clinical evidence of thromboembolism was detected. Two animals developed infective endocarditis. One animal originally intended to be euthanized at 24 weeks was found to have fevers and failure to thrive at 17 weeks and thus was euthanized. In this animal, evaluation of the mitral valve demonstrated infective endocarditis. Blood cultures obtained before euthanasia were positive for pseudomonas and *Escherichia coli*. Another animal was found to have infective endocarditis at time of intended euthanasia at 12 weeks. However, endocarditis was not suspected before explantation, and blood cultures were not obtained. Both of these animals underwent clip placement on the same date.

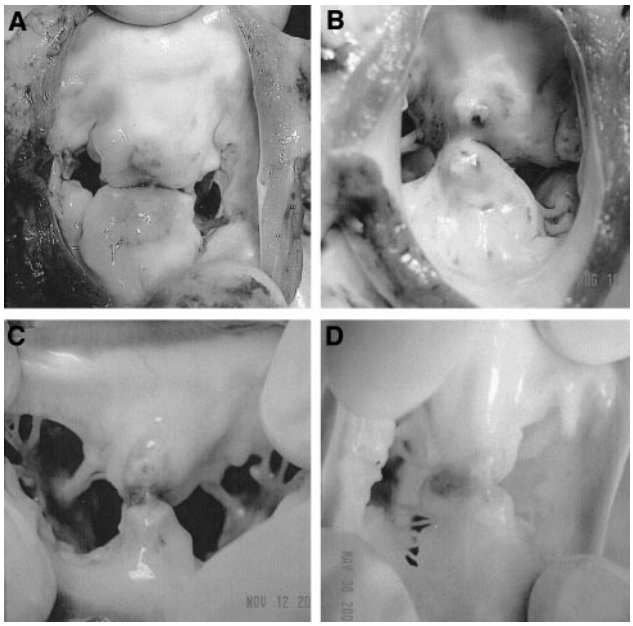

Figure 4. Representative atrial views of clip approximating mid portion of anterior and posterior leaflets at various time intervals (A, 4 weeks; B, 12 weeks; C, 24 weeks; and D, 52 weeks).

Baseline (preimplantation) and postimplantation hemodynamic data are shown in Table 2. Left atrial pressures measured after implantation and at time of euthanasia were not elevated, which suggests the absence of mitral stenosis.

Histopathology

Histopathologic evaluations of the mitral valve with clip, chordae, and papillary muscles were performed. Progressive healing with endothelialization occurred, except for the animals that sustained endocarditis (noted above). There were modest changes in the vicinity of the clip, with mild tissue thickening with an intact surface of endothelial cells in the native valve tissue. At 4 weeks, the layer of cells on the ventricular surface consisted of fibrous tissue and collagen. On the atrial aspect, there was evidence of tissue deposition between the arms of the clip. At 12 weeks, on the ventricular surface, there was a thicker layer of tissue that covered the polyester fabric. On the atrial surface, there was greater cellular coverage, with the gap between the arms of the clip less pronounced than with the 4-week specimens. At 24 and 52 weeks, there was a mature, continuous tissue bridge between the anterior and posterior leaflets between the arms of the clip. The heart, liver, spleen, kidneys, and brain were unremarkable for thrombosis, thromboembolism, or infarcts at all time periods. Scanning electron microscopy of 3 mitral valves (1 each at 4, 12, and 24 weeks) showed complete tissue encapsulation of the clip with endothelial cells on the surface (Figure 5).

Discussion

This study demonstrated that durable edge-to-edge mitral valve approximation can be successfully and reliably achieved with a clip device delivered via a catheter without cardiopulmonary bypass. Similar to suture approximation of the anterior and posterior leaflet edges in the surgical approach with an arrested heart, the clip became well incorporated into the surrounding valvular tissue. These findings

Downloaded from http://ahajournals.org by on May 18, 2026

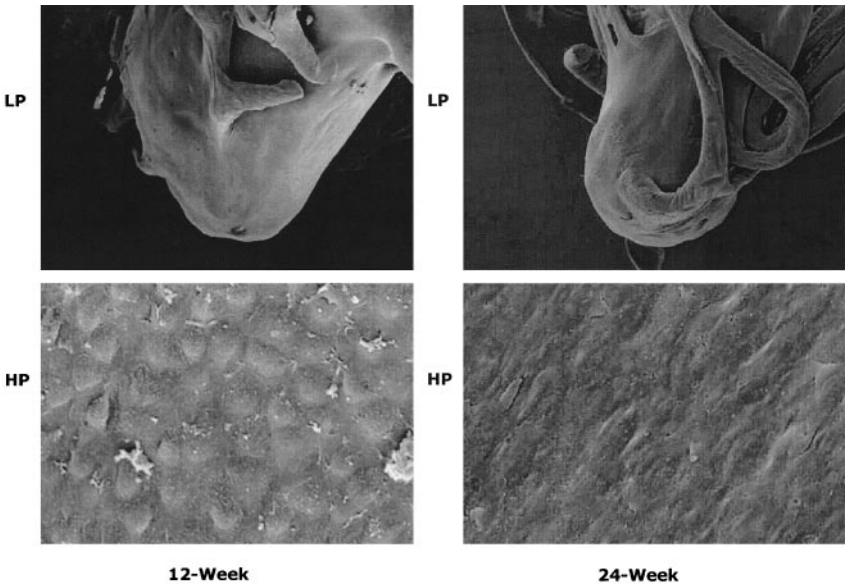

Figure 5. Low-power (LP) and high-power (HP) scanning electron microscopy of clip incorporated by surrounding tissue and endothelialization at 12 and 24 weeks.

Downloaded from http://ahajournals.org by on May 18, 2026

support the development and clinical evaluation of an endovascular catheter-based system for mitral valve repair.

The surgical edge-to-edge technique has been used to repair complex mitral valve pathology involving both leaflets, anterior leaflet prolapse or restriction, and mitral annular calcification; such a repair may be performed expediently with relatively short cardiopulmonary bypass and aortic cross-clamp times.[1–6] The overall operative mortality rate with this approach has ranged from 0.7% to 4.2%, with a freedom from reoperation rate of 90% to 95% at 5 to 6 years.[1–6] Maisano and colleagues[5] recently found that of the patients who underwent edge-to-edge procedures (including those with mitral annular calcification and those requiring a "rescue" procedure after an unsuccessful repair attempt), freedom from reoperation was 89% at 4 years. Excluding those with mitral annular calcification, however, edge-to-edge repair was associated with a significantly higher freedom from reoperation of 95% at 4 years.[5] These findings are not unexpected, because patients with mitral annular calcification are a challenging subset not only for this approach but also for valve-replacement procedures that require potentially problematic annular decalcification.[13] These clinical results and the findings in the present study support the development of an endovascular catheter-based approach to edge-to-edge mitral valve repair. We demonstrated reliable clip approximation of the valve leaflets with no evidence of trauma to the leaflets, subvalvular apparatus, or the ventricular wall. Histologically, there was a mature tissue bridge between the anterior and posterior leaflet between the arms of the clip, similar to what was demonstrated by Privitera et al[9] in the clinical setting.

Iatrogenic valve stenosis is a potential limitation of this technique; however, Timek et al[14] have found that edge-to-edge mitral valve repair is not associated with substantial transvalvular obstruction during high-flow conditions and does not perturb normal mitral annular dynamics in normal ovine hearts. Clinically, others have shown that even with concomitant ring annuloplasty, the edge-to-edge technique does not cause mitral valve obstruction, either at baseline or during physical exercise, and does not affect valve hemodynamic and valve reserve.[15] On the basis of the hemodynamic data, the present study demonstrated no change in left atrial pressures before and after creation of the double-orifice mitral valve, which supports the absence of mitral stenosis.

Detachment of the clip from 1 leaflet was observed in 1 case (4%). Because the clip is intended to attach independently to both leaflets at time of implantation, the device did not embolize. There was no appreciable valve damage, and in retrospect, it is likely that leaflet tissue insertion or capture was not optimal. The frictional element on the clip was modified, and subsequent experiments were performed without this problem. Given the results with the modified clip, the fact that both leaflets are captured at time of implantation, and the degree of tissue encapsulation observed as early as 4 weeks, the possibility of device embolization appears unlikely. Also observed were 2 cases of infective endocarditis. Previous studies using the porcine model have resulted in higher rates of infection, including endocarditis, than clinically found in human studies.[16,17] Factors that might contribute to the increased occurrence include the techniques and environment during device preparation and the postoperative housing conditions. At the time of device preparation, the clip was examined, handled directly with latex gloves, and exposed to the animal operating room environment, which was less optimal than that used clinically. Because both procedures were performed on the same day, it is likely that there was a breach in sterility. These events were of concern, and a protective cover was added to eliminate direct contact with the implant during device preparation. Use of appropriate periprocedural antibiotics and routine endocarditis prophylaxis are also mandatory.

Study Limitations

This experiment assessed the ability to approximate the mitral leaflet edges with a catheter-based system and the histological follow-up. One limitation was that the animals did not

have mitral regurgitation (eg, leaflet prolapse or annular dilation), and thus the ability of the clip to relieve mitral regurgitation was not evaluated. The ability to image the valve leaflets and the subvalvular apparatus is critically important in the application of this technology. In this study, epicardial echocardiography provided visualization of the valve anatomy and of the relationship of the device to the target region. With conventional transthoracic or transesophageal echocardiography in the clinical setting, anatomic assessment and device imaging is possible, particularly as the experience increases. Finally, long-term follow-up in the experimental and clinical settings will be necessary to fully evaluate this device.

In summary, a catheter-based clip device can effectively and reliably approximate the mitral valve leaflets without cardiopulmonary bypass, thereby creating a functional double-orifice mitral valve. The clip and catheter-delivery system enable extension of this technology to a percutaneous, endovascular approach via transseptal access for edge-to-edge repair of the mitral valve.

Disclosure

Dr Foster has received a grant from Evalve, Inc. Drs Fann, St. Goar, Oz, Block, and Burdon have equity in and/or consulting relationships with Evalve, Inc, and Dr Komtebedde is an employee of Evalve, Inc.

Acknowledgment

This study was supported by a grant from Evalve, Inc, Redwood City, Calif.

References

1. Alfieri O, Maisano F, DeBonis M, et al. The edge-to-edge technique in mitral valve repair: a simple solution for complex problems. *J Thorac Cardiovasc Surg*. 2001;122:674–681.
2. Lorusso R, Borghetti V, Totaro P, et al. The double-orifice technique for mitral valve reconstruction: predictors of outcome. *Eur J Cardiothorac Surg*. 2001;20:583–589.
3. Maisano F, Schreuder JJ, Oppizzi M, et al. The double orifice technique as a standardized approach to treat mitral regurgitation due to severe myxomatous disease: surgical technique. *Eur J Cardiothorac Surg*. 2000; 17:201–215.
4. Umana JP, Salehizadeh B, DeRose JJ, et al. "Bow-tie" mitral valve repair: an adjuvant technique for ischemic mitral regurgitation. *Ann Thorac Surg*. 1998;66:1640–1646.
5. Maisano F, Caldarola A, Blasio A, et al. Mid term results of the edge-to-edge mitral valve repair without annuloplasty. *J Thorac Cardiovasc Surg*. 2003;126:1987–1997.
6. Kherani AR, Cheema FH, Casher J, et al. Edge-to-edge mitral valve repair: the Columbia Presbyterian experience. *Ann Thorac Surg*. 2004; 78:73–76.
7. Maisano F, Redaelli A, Pennati G, et al. The hemodynamic effects of double-orifice valve repair for mitral regurgitation: a 3-D computational model. *Eur J Cardiothorac Surg*. 1999;15:419–425.
8. Gatti G, Cardu G, Trane R, et al. The edge-to-edge technique as a trick to rescue an imperfect mitral valve repair. *Eur J Cardiothorac Surg*. 2002; 22:817–820.
9. Privitera S, Butany J, Cusimano RJ, et al. Alfieri mitral valve repair: clinical outcome and pathology. *Circulation*. 2002;106:e173–e174.
10. Morales DLS, Madigan JD, Choudhri AF, et al. Development of an off bypass mitral valve repair. *Heart Surg Forum*. 1999;2:115–120.
11. Downing SW, Herzog WA, McLaughlin JS, et al. Beating-heart mitral valve surgery: preliminary model and methodology. *J Thorac Cardiovasc Surg*. 2002;123:1141–1146.
12. Alfieri O, Elefteriades JA, Chapolini RJ, et al. Novel suture device for beating-heart mitral leaflet approximation. *Ann Thorac Surg*. 2002;74: 1488–1493.
13. Feindel CM, Tufail Z, David TE, et al. Mitral valve surgery in patients with extensive calcification of the mitral annulus. *J Thorac Cardiovasc Surg*. 2003;126:777–782.
14. Timek TA, Nielsen SL, Liang D, et al. Edge-to-edge mitral repair: gradients and three-dimensional annular dynamics in vivo during inotropic stimulation. *Eur J Cardiothorac Surg*. 2001;19:431–437.
15. Redaelli A, Guadagni G, Fumero R, et al. A computational study of the hemodynamics after "edge-to edge" mitral valve repair. *J Biomed Eng*. 2001;123:565–570.
16. Cowart RP, Payne JT, Turk JR, et al. Factors optimizing the use of subcutaneous vascular access ports in weaned pigs. *Contemp Top Lab Anim Sci*. 1999;38:67–70.
17. Lock JE, Bass JL, Lund G, et al. Transcatheter closure of patent ductus arteriosus in piglets. *Am J Cardiol*. 1985;55:826–829.

Downloaded from http://ahajournals.org by on May 18, 2026