PET-CT image co-registration in the thorax: influence of respiration

Gerhard W. Goerres, Ehab Kamel, Thai-Nia H. Heidelberg, Michael R. Schwitter, Cyrill Burger, Gustav K. von Schulthess

Division of Nuclear Medicine, Department of Radiology, University Hospital Zurich, Raemistrasse 100, 8091 Zurich, Switzerland

Received 1 September and in revised form 26 October 2001 / Published online: 9 January 2002
© Springer-Verlag 2002

Abstract. Because anatomical information on fluorine-18 fluorodeoxyglucose (FDG) whole-body positron emission tomography (PET) images is limited, combination with structural imaging is often important. In principle, software co-registration of PET and computed tomography (CT) data or dual-modality imaging using a combined PET-CT camera has an important role to play, since "hardware-co-registered" images are thereby made available. A major unanswered question is under which breathing protocol the respiration level in the CT images of a patient will best match the PET images, which represent summed images over many breathing cycles. To address this issue, 28 tumour patients undergoing routine FDG PET examinations were included in this study. In ten patients, PET and CT were performed using a new combined high-performance in-line PET-CT camera without the need for repositioning of the patient, while in 18 patients imaging was performed on separate scanners located close to each other. CT was performed at four respiration levels: free breathing (FB), maximal inspiration (MaxInsp), maximal expiration (MaxExp) and normal expiration (NormExp). The following distances were measured: (a) between a reference point taken to be the anterior superior edge of intervertebral disc space T10–11 and the apex of the lung, (b) from the apex of the lung to the top of the diaphragm, (c) from the apex of the lung to the costo-diaphragmatic recess and (d) from the reference point to the lateral thoracic wall. Differences between CT and corresponding PET images in respect of these distances were compared. In addition, for each of 15 lung tumours in 12 patients, changes in tumour position between PET and CT using the same protocol were measured. CT during NormExp showed the best fit with PET, followed by CT during FB. The mean differences in movement of the diaphragmatic dome on CT during NormExp, FB, MaxInsp and MaxExp, as compared with its level on PET scan, were, respectively, 0.4 mm (SD 11.7), –11.6 mm (13.3), –44.4 mm (25.5) and –9.5 mm (25.6). CT acquired in MaxExp and MaxInsp is not suitable for image co-registration owing to the poor match of images in MaxInsp and because of difficulties with patient performance in MaxExp. With reference to lung lesions, NormExp showed the best results, with a higher probability of a good match and a smaller range of measured values in comparison with FB. Image misregistration in combined PET-CT imaging can be minimized to dimensions comparable to the spatial resolution of modern PET scanners. For PET-CT image co-registration, the use of a normal expiration breath-hold protocol for CT acquisition is recommended, independent of whether combined PET-CT systems or stand-alone systems are used.

Keywords: PET-CT – Image fusion – Physiology – Respiration – Artefact

Eur J Nucl Med (2002) 29:351–360
DOI 10.1007/s00259-001-0710-4

Gerhard W. Goerres (✉)
Division of Nuclear Medicine, Department of Radiology, University Hospital Zurich, Raemistrasse 100, 8091 Zurich, Switzerland
e-mail: gerhard.goerres@dmr.usz.ch
Tel.: +41-+1-2552850, Fax: +41-1-2554414

Introduction

In modern oncology, diagnosis and staging of disease processes are based mainly on morphological cross-sectional imaging with computed tomography (CT) or magnetic resonance imaging (MRI). However, these modalities are neither as sensitive nor as specific as fluorine-18 fluorodeoxyglucose positron emission tomography (FDG PET) in identifying manifestations of many tumours or in defining their biological behaviour and response to therapy. Therefore, FDG PET has become an important imaging method. FDG accumulates in many different malignant tumours [1] and allows them to be identified with exquisite sensitivity. However, it shows few ana-

Volkswagen Exhibit 1021, Page 1 of 10

Table 1. Respiration frequencies in healthy human subjects (adapted from Mead 1959)

Author	Year	No. of individuals	Age of individuals	Mean breaths/min (range)
Quetelet	1884	300	Birth	44 (23–70)
			15–20	20 (10–24)
			20–25	18.7 (14–24)
			25–30	16.0 (15–21)
			30–50	18.1 (11–23)
Hutchinson	1850	1,714	Adults	20.2 (6–31)
Handbook of Respiration	1958	5	Adults	11.7
Mead	1959	27	Adults	27

Frequency of respiration depends on many factors, such as age, body weight, and work load. There is a wide physiological range and each individual has its own normal respiration frequency during rest. During the PET emission scan of 4 min and the PET transmission scan of 2 min, between 66 and 186 breathing cycles can be considered normal in healthy adult persons

tomical structures, thereby making it difficult to achieve precise lesion localization and, consequently, lesion specification and accurate staging. Hence, there has been increasing interest in combined imaging.

Recent developments in software for image co-registration and, particularly, advances in dual-modality imaging that provide "hardware" co-registration have led to the development of in-line PET-CT systems [2] that acquire morphological and functional information in the same examination. Software image co-registration is an established way of enhancing the interpretation of pathological findings in the brain. Fusion of anatomical and functional images of the thorax and abdomen is more difficult because body positioning is variable and motion artefacts due to respiration are poorly controlled. While hardware fusion can overcome the former problem, the latter affects both hardware and software fusion approaches. It is well known that there is a wide range of respiration frequencies in healthy individuals (Table 1) and that respiratory-induced thoracic movements strongly influence the quality of CT images [3,4]. The physiological range of movements of the thoracic cage and inner thoracic organs has been described previously, showing a difference between the left and right diaphragm as well as changes in chest circumference and vertical movements of the thoracic cage [5]. A large inter-individual range of these movements can be expected. Tumours and organs move widely during the breathing cycle, and the relative relationship between the tumour and surrounding normal structures may change [3,6,7,8,9]. In addition, the ability to breathe freely may be limited in patients with oncological disease. This not only may influence a patient's capability to successfully undergo a PET or CT examination in the supine position but also may affect the co-registration of images.

To optimize fusion of PET and CT images, the respiratory levels of both types of examination should be adapted to a best fit. Since the acquisition of a PET scan takes several minutes per field of view (FOV), it is impossible for a patient to keep a defined breathing position during the scan. Respiratory gating of PET scanning is possible in principle, but the time required in this already lengthy examination makes this approach clinically impractical. In contrast, patients can be asked to hold their breath during CT scanning, although defining the position of breath holding is less than perfect for most respiratory arrest positions.

The purpose of this study was to evaluate the optimum breath-holding position of patients during CT imaging, in terms of providing the best match with PET imaging of the thorax, by acquiring CT scans during different respiratory phases. This information should help to define standardized imaging protocols that optimize image co-registration in PET-CT imaging, particularly in integrated systems.

Materials and methods

Patients. The study group consisted of 28 patients (15 male, 13 female; mean age 56.4 years, range 34–81 years). All patients underwent a PET examination for oncological staging or restaging in a routine clinical setup. Eleven patients had bronchogenic cancer, four cancer of the head and neck, three melanoma, two cancer of the cervix, two breast cancer, three lymphoma and three colorectal carcinoma. The study was conducted according the guidelines of the institutional review board of the hospital, and written informed consent was obtained from each patient.

Patients were instructed to breathe normally during the PET scan and to perform four breathing manoeuvres during four sequential CT scans. During the first CT scan, patients breathed normally and freely (free breathing = FB). For the second, third and fourth CT scans, patients held their breath at levels of maximum inspiration (MaxInsp), maximum expiration (MaxExp) and normal expiration (NormExp), respectively. NormExp was defined as the respiratory level that was reached when the patient first inhaled and then exhaled without forcing expiration, and then held the breath in this position. Before PET and CT examinations started, these four levels of respiration were explained to and rehearsed with the patient.

Data acquisition. A first series of 18 patients were scanned on stand-alone PET and CT cameras (GEMS Advance Nxi and GEMS High Speed CT/i scanner, Milwaukee, Wis., USA) located approximately 10 m from each other in adjacent rooms, and a sec-

Volkswagen Exhibit 1021, Page 2 of 10

ond series of ten patients were evaluated on a new combined in-line PET-CT camera (GEMS Discovery LS, Milwaukee, USA). The PET camera has a 14.6-cm axial FOV and a transaxial resolution of 4.8 mm full-width at half-maximum at the centre. PET scans were obtained using an acquisition time of 4 min for the emission and 2 min for the transmission scan per cradle position, with a one-slice overlap at the borders of the FOV to avoid artefacts. Thus, an examination with six to seven cradle positions from the top of the head to the pelvic floor resulted in an acquisition time of roughly 45 min. All PET scans were acquired before the CT scans. This is not a system requirement. Patients fasted for at least 4 h prior to scanning, which started approximately 45 min after the injection of 330–430 MBq of FDG (mean 386 MBq).

Data acquisition with spiral CT was performed covering the same axial FOV of the body as with the FDG PET scan, with a 512×512 matrix size and a FOV of 50 cm. On the CT/i scanner, data acquisition was as follows: First, a scout view was obtained in the antero-posterior view using 120 kV, 10 mA and a maximal scan time of 13 s. During FB a whole-body CT scan was acquired from the top of the head to the pelvic floor, using 140 kV, 40 mA, a pitch of 1.7 and a 5-mm reconstruction interval to match the slice thickness of the PET scan. Furthermore, in each patient of the first series, CT scans of the thorax were acquired in the three different breathing positions described above using a pitch of 2.5, without changing the other low-dose radiation parameters, and covering a FOV from the shoulders to the upper abdomen. Scanning time was 17 s for each examination, MaxInsp, MaxExp and NormExp.

For the examination, the patients of the first series were positioned on a mattress containing plastic beads, which upon evacuation formed a body mould around the posterior and lateral aspects of the patients, but allowed normal respiration. The position of the patient was marked within the camera using a laser system, tape and pen lines. Immediately after the end of the PET scan, patients were moved within the mattress to the CT scanner, which was located in a room approximately 10 m away. Repositioning was performed using the tape landmarks and the laser system installed in the CT camera. Transfer of the patient and repositioning took between 5 and 10 min.

In the second series, the combined in-line PET-CT system permitted acquisition of perfectly matched data by simply moving the table position by 60 cm from the CT to the PET gantry. During system installation, the two gantries had been mechanically aligned using phantoms to ensure a "hardware" co-registration of images to within 2 mm in the three spatial directions. Further optimization down to a "hardware" co-registration match in phantoms of <1 mm was achieved by electronically adjusting the three spatial offset parameters. No further patient-specific software image co-registration was required to obtain the final matched data. PET scans in the combined system were acquired from the head to the pelvic floor using the same protocol as above, but CT scans were obtained with the PET table now also operating as a CT table. In contrast to the first series, the more powerful MDCT scanner used in the combined system made it possible to acquire a FOV of 867 mm in 22.5 s – a view from the head to the pelvic floor. Using 40 mA again, data were acquired with 140 kV and a pitch of approximately 6. After the CT scans, patients were asked how they could perform the breathing tasks, and were asked to rank them with respect to comfort.

Image reconstruction and co-registration. PET images were reconstructed using segmentation and a standard iterative algorithm (OSEM, two iterative steps). Images were reformatted into axial, coronal and sagittal views. Before co-registration of all images, CT data were resampled to the resolution of the PET scan, i.e. a matrix of 128×128 in the transaxial plane, although the original CT images were available for viewing at all times. In the first series, co-registration of PET and CT images was done using in-house software (PMOD) [10] which allows the registration of two sets of images with a simple rigid transformation based on anatomical landmarks. Transformation between the two studies was interactively determined by the users, who practiced image processing in eight preliminary patients not taking part in the study.

In the second series, the combined PET-CT system directly provided co-registration as a result of the hardware configuration as described above. The acquired images were viewed with software providing multiplanar reformatted images of PET, CT and fused data with linked cursors (eNtegra GE Medical Systems, Haifa, Israel). Distance measurements in PET and CT images were performed using the PMOD software, as in the first series.

Measurement of respiratory and tumour movements. In all of the acquired PET and CT scans, displacement of the diaphragm and of the thoracic cage was measured (Fig. 1). In addition, movement of the 15 pulmonary lesions identified in the 28 patients was measured (these lesions were identified in 11 patients with bronchogenic carcinoma and one patient with advanced cancer of the head and neck).

As point of reference, the midline point at the upper anterior border of the intervertebral disc space between thoracic vertebrae 10 and 11 (T10–11) was chosen, which was easily identifiable on the CT scans of all patients. This choice was based on the assumption that the position of this point of reference in the vertebral column would be stable during the different parts of the scanning protocol in a supine patient. The reference point was always defined by the same experienced nuclear physician/radiologist and listed in a protocol to allow for an exact reference in aligned images. Because the intervertebral disc space T10–11 is not visible on PET scans, the reference point was matched from the FB CT onto the PET emission scan after alignment. The point was tagged with a cross visible in all three dimensions, and served as the reference for all comparisons between PET and CT in an individual patient. As measurements were performed on the non-attenuation-corrected PET images, in which the lung appears substantially darker than the surrounding tissues, the measuring points could be readily identified at the edge between the lung and the thoracic wall or diaphragm. Furthermore, the contrast level of images was defined and standardized to guarantee that both collaborators who measured the distances had equal image qualities and to reduce difficulties in identification of the border between the lung and adjacent structures on PET. The following distances were measured:

1. Point of reference to the upper border of the lung on the coronal section on which the reference point was visible (Fig. 1a and c).
2. Lung apex to the top of the diaphragm (Fig. 1b and d).
3. Lung apex to the posterior costo-diaphragmatic recess, on the sagittal view, showing the largest cranio-caudal extension of the lung (Fig. 1b and d).
4. Transverse distance from the point of reference to the lateral thoracic wall (Fig. 1a and c).

All measurements were performed independently by two collaborators, who practiced these measurements in eight preliminary patients before the study started. Displacements in relation to landmarks defined by normal mediastinal and hilar structures such as the carina and the xyphoid process were not measured because such structures could not be reliably identified on the FDG PET scans. Absolute distances were measured in PET and CT scans, and the differences in the distances between the CT measurement and the corresponding PET measurement were calculated.

Volkswagen Exhibit 1021, Page 3 of 10

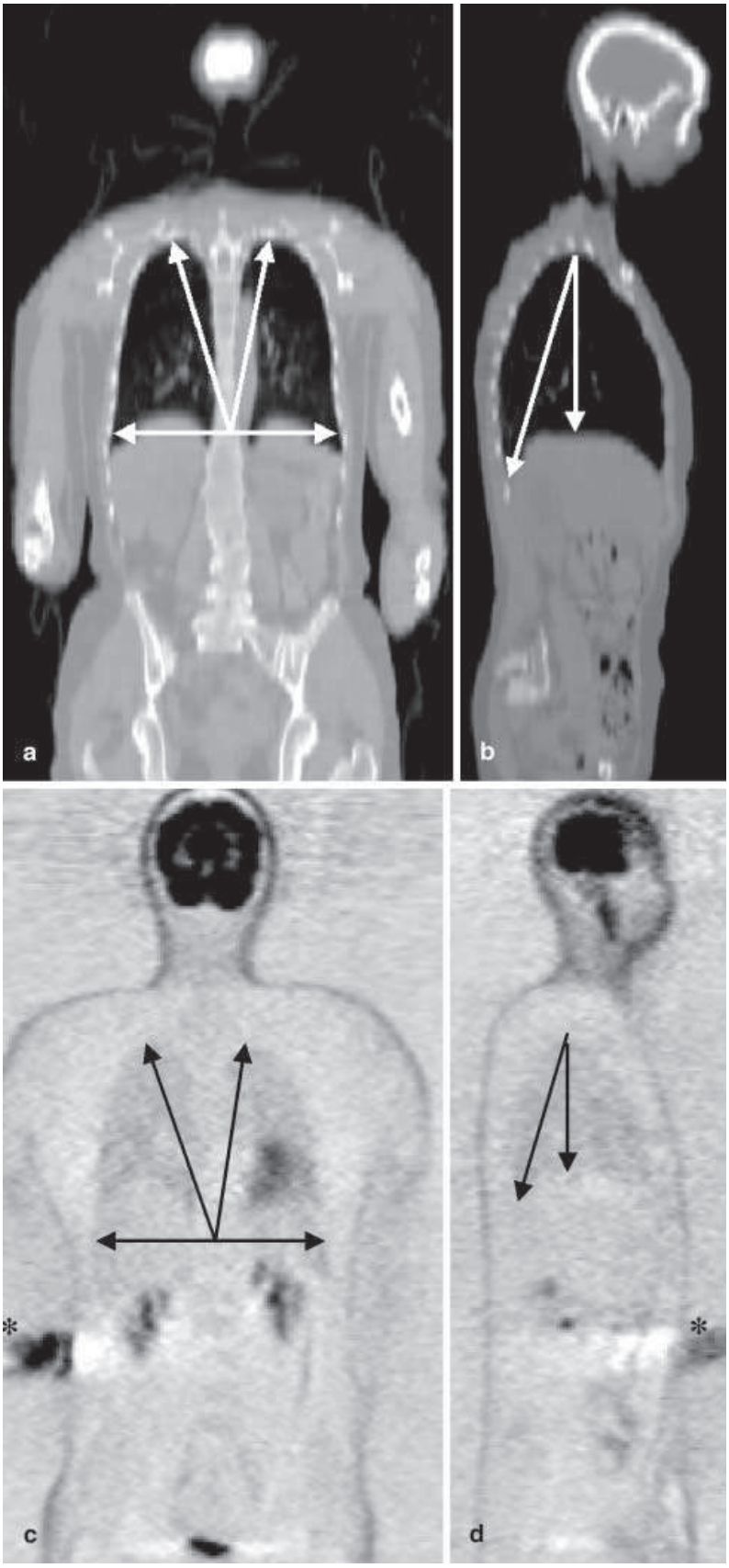

Fig. 1a–d. Measurements. **a** In the first 18 patients distances were measured from the point of reference, i.e. the upper anterior border of the intervertebral disc space between thoracic vertebrae 10 and 11 in the midline, to the upper border of the lung visible in the same coronal view. From the reference point, additional measurements were performed to the lateral thoracic wall. **b** In the sagittal plane the image with the largest distance between the apex and the diaphragm was identified, and distances between the apex and the diaphragmatic dome and between the apex and the posterior costo-diaphragmatic recess were measured on the same slice. **c** The same measurements as in **a** are shown in a PET scan of another patient. The non-attenuation-corrected and filtered back-projected images were chosen for the measurements since the lung appears darker than in the attenuation-corrected images, thus improving edge detection between lung and thoracic wall. *Artefact due to paravascular injection of FDG. **d** The same measurements as in **b**. Due to difficulties in edge detection of organs in PET images, inter-observer agreement with respect to measured distances is worse than with CT. Identification of the posterior recess is more difficult than identification of the diaphragmatic dome. *Artefact due to paravascular injection of FDG

Volkswagen Exhibit 1021, Page 4 of 10

Based on the experience gained in the first 18 patients, only the difference in diaphragmatic positions (i.e. difference in distance between the apex and the diaphragmatic dome) was measured in the ten patients scanned on the new integrated PET-CT scanner, since during respiration the diaphragm has the largest range of movements.

Finally, as already mentioned, we analysed respiratory movements of lung lesions in 12 patients taking part in this study. Fifteen lung lesions were analysed in 11 patients with bronchogenic carcinoma and one patient with lung metastases of cancer of the head and neck. Of these tumours, four were located in the upper lobes, four in the lower lobes and seven near the hila, with two of them in the middle lobe. For each lesion, the distance to the reference point T10–11 was measured in the four CT scans and in the PET scan. The distance measured represents the length of the distance vector and thus the geometric mean of the three-dimensional movement of a lesion. Like the reference point, the point of measurement – in larger lesions an identifiable point within or at the border of the lesion – was defined by the nuclear physician/radiologist in charge of the study, and all measurements were done independently by the two trained collaborators.

Data analysis and statistical evaluation. For each of the measurements listed above, the difference between measured distances in PET and CT was used for statistical analysis using a paired, two-tailed *t* test to check for differences between the respiration levels. Furthermore, the percentage of good or bad matches between CT and PET was counted for each respiration level. Inter-observer agreement between the two collaborators was estimated by means of Bland-Altman plots [11]. By using this graphical approach the difference of two measurements against the mean of the same measurements is shown. This approach allowed visualisation of the extent to which the measurements differed from each other. Inter-observer agreement was evaluated for all PET and CT measurements of anatomical distances done on the separate PET and CT cameras and for the measurements of diaphragmatic movements on the new combined PET-CT system. Intra-observer agreement for PET and CT measurements was not assessed by the Bland-Altman method, but repeated measurements performed by a single person were evaluated.

Results

Patient interview

All patients found that MaxExp was the least comfortable breathing position, and most of the patients were not able to maintain this position during the CT scan. Therefore, values as measured during MaxExp were not reliable.

Fig. 2a–d. Inter-observer agreement. **a** Bland-Altman plot showing the differences between all the measurements performed by two different collaborators in the CT images acquired on a stand-alone scanner. Mean –0.002 cm; SD 0.13 cm; mean+2SD = +0.26 cm; mean–2SD = –0.26 cm. 95% of all measurements are within a 3-mm range above/below the mean. **b** Bland Altman plot showing the differences between all the measurements performed by two different collaborators in the PET images acquired on a stand-alone scanner. Mean +0.01 cm; SD 0.26 cm; mean+2SD = +0.53 cm; mean–2SD = –0.51 cm. 95% of all measurements are within a 5-mm range above/below the mean. This corresponds to the resolution of the PET scanner. **c** Bland-Altman plot showing the differences between two different collaborators with respect to the measured distance between the apex and the diaphragmatic dome (four different respiration levels) in the CT images acquired on a combined PET-CT scanner. Mean –0.01 cm; SD 0.07 cm; mean+2SD = +0.13 cm; mean–2SD =–0.15 cm. 95% of all measurements are within a 2-mm range above/below the mean. **d** Bland-Altman plot showing the differences between 2 different collaborators with respect to the measured distance between the apex and the diaphragmatic dome in the PET images acquired on a combined PET-CT scanner. Mean –0.09 cm; SD 0.23 cm; mean+2SD = +0.37 cm; mean–2SD = –0.55 cm. 95% of all measurements are within a 5-mm range above/below the mean.

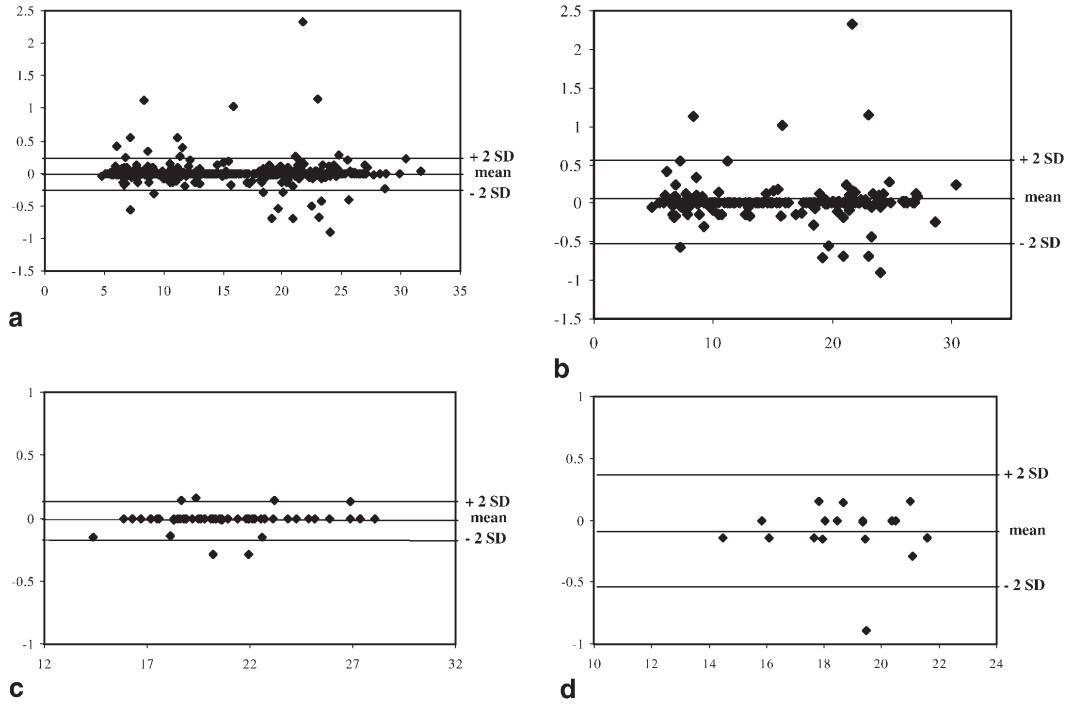

Volkswagen Exhibit 1021, Page 5 of 10

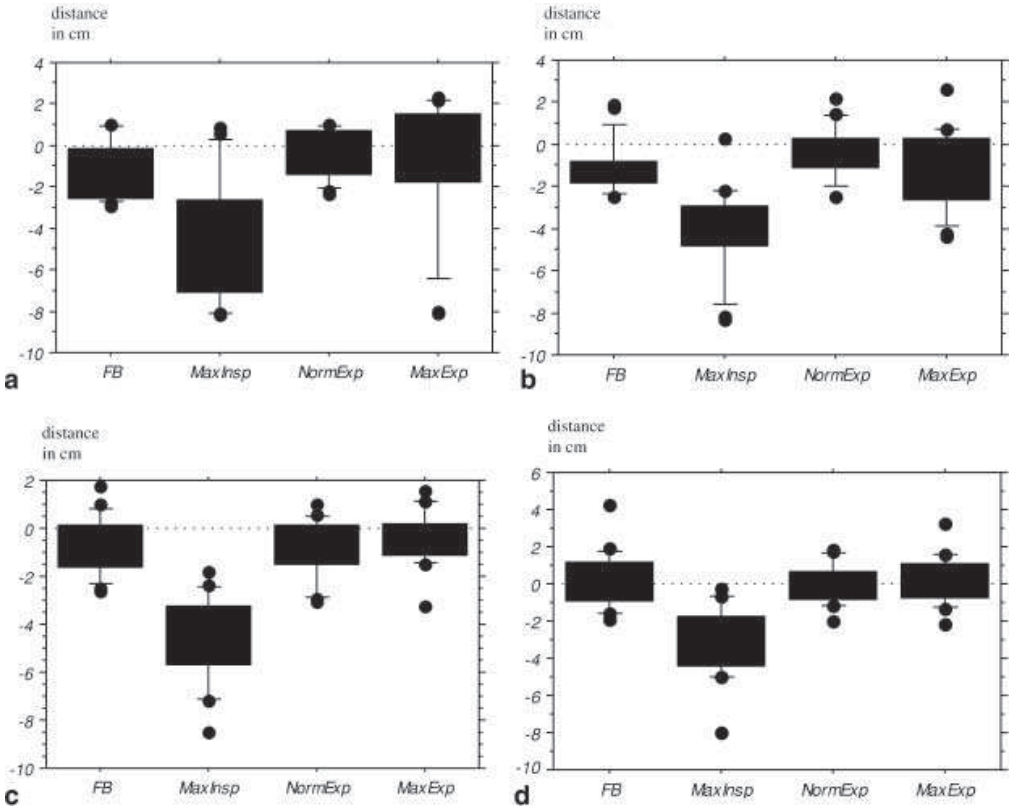

Fig. 3a–d. Movement of the diaphragm. **a, b** Distances between the apex of the lung and the right diaphragm (**a**) and the apex of the lung and the left diaphragm (**b**) measured on the combined PET-CT scanner (mean difference between CT and PET in cm). NormExp matches best for image co-registration. **c, d** Distances between the apex of the lung and the right diaphragm (**c**) and the apex of the lung and the left diaphragm (**d**) measured on the stand-alone PET and CT scanners (mean difference between CT and PET in cm). In these patients, NormExp seems to be slightly better than FB or MaxExp only on the left side, with a smaller range of values

MaxInsp was also felt to be difficult to perform. Most patients found that the NormExp level could be held without problems, but for some patients FB was more agreeable. One patient started to speak and one patient yawned during the FB CT scan. During NormExp, patients were more attentive and showed better compliance.

Reliability of measurements

Inter-observer agreement of the two collaborators in measuring distances in the four CT scans was better than the inter-observer variability of the measurements in the PET scan. In the first patient group scanned on the two separate PET and CT scanners, the measurements in PET by the two collaborators matched perfectly in 51.2% of cases. In CT, the agreement between the measurements was better: FB CT 74.6%, MaxInsp CT 74.9%, NormExp CT 70.5% and MaxExp CT 79.8%. In Fig. 2a and b, Bland-Altman plots of all PET and all CT measurements are shown. On the combined in-line PET-CT scanner, 20 measurements were done in ten patients. Two mismatches were found between the collaborators for each of FB CT, MaxInsp CT and MaxExp CT, while three mismatches were found for NormExp CT. Taking all the measurements together (80 distances), the mean difference between the collaborators was 1 mm (Fig. 2c). In contrast, an identical distance was measured in the PET images (20 distances) in only seven patients. The mean difference was 9 mm, with 95% of all measurements lying within a 5-mm range above or below the mean (Fig. 2d).

Repeated measurements performed by a single person showed identical values in only 20% of measurements on PET, but in 80% of measurements on CT. If measurements within a 3-mm range in PET images were to be considered identical, then PET would have equalled the performance of CT.

Measurement of respiratory movements

In the first series of 18 patients, measurements between the reference point and the upper border of the lung visible in the same coronal section revealed small differences between the four respiration levels and between the left and right sides. Measured differences between PET and CT ranged between 6 and 20 mm. Differences between PET and CT were larger when measuring the distance between the diaphragmatic dome and the apex of the lung, reaching up to 57 mm on the left side and up to 41 mm on the right side for the four breathing tasks. The best or second best matches between PET and CT were found in 80.5% during NormExp and in 47.2% during FB for the left and right sides together. The worst matches were found during MaxInsp in 88.9% for the left and right sides together. Still larger differences between PET and CT were obtained when measuring the distance between the apex of the lung and the costo-diaphragmatic recess. Therefore, measurements of the dia-

Volkswagen Exhibit 1021, Page 6 of 10

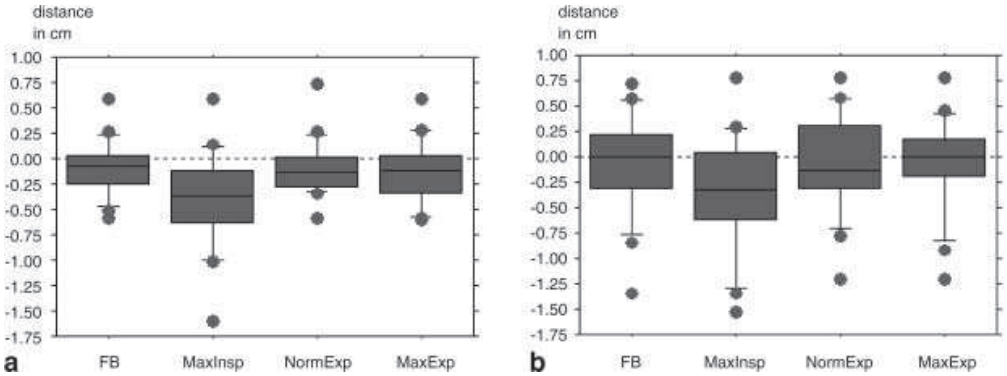

Fig. 4a, b. Movement of the thoracic wall. Box plots illustrating the differences in measured distances between the reference point and the left (**a**) and right (**b**) thoracic wall (mean difference between CT and PET in cm). In the transverse plane the range of measured differences is in the order of several millimetres

Table 2. Match of CT and PET for measurements between the apex and the diaphragmatic dome on the combined PET-CT camera[a,b]

Respiration level	Best match (%)	2nd best match (%)	2nd worst match (%)	Worst match (%)
FB	27	13.5	59.5	0
NormExp	52.7	30.6	16.7	0
MaxInsp	5.3	7.9	5.3	81.5
MaxExp	16.2	35.1	24.3	24.4

[a] If two measured distances were identical for two different respiration levels, they were both considered to be the second best or worst etc. If they were nearer to the worst match they were called the second worst; if they were nearer to the best match they were called the second best. For this reason, columns do not necessarily total 100%, though all columns together total 400%

[b] Best match (given in % of measurements for the right and left thoracic sides together) was found with NormExp, i.e. the defined expiration level. Free shallow breathing (FB) had a higher range of measured values and showed worse fits with the PET scan than normal expiration. Maximal expiration was not performed correctly by most patients and, like maximal inspiration, is unsuitable for PET-CT image fusion

Table 3. Mean differences (and SD, range) in movement of the diaphragmatic dome on CT under the four different respiration levels, as compared with the level of the diaphragmatic dome on the PET scan

Respiration level	Mean	SD	Range
NormExp	0.4 mm	11.7 mm	–24.7 mm to 18.9 mm
FB	–11.6 mm	13.3 mm	–29.1 mm to 18.9 mm
MaxInsp	–44.4 mm	25.5 mm	–82.9 mm to 8.7 mm
MaxExp	–9.5 mm	25.6 mm	–81.4 mm to 26.2 mm

As values are in relation to the level of the diaphragmatic dome in the PET scan, they can be negative or positive

Table 4. Significance of the differences (paired two-tailed *t* test) in the movement of the diaphragmatic dome on CT under the four respiration levels

FB vs MaxInsp	S	*P*=0.0001 left and right
MaxInsp vs MaxExp	S	*P*=0.004 left, *P*=0.001 right
MaxInsp vs NormExp	S	*P*=0.001 left and right
FB vs MaxExp	NS	*P*=0.8 left, *P*=0.7 right
NormExp vs MaxExp	NS	*P*=0.1 left, *P*=0.6 right
FB vs NormExp	S/NS	*P*=0.009 left, *P*=0.1 right

No significant differences were revealed between NormExp or FB and MaxExp. This was mainly due to the bad performance of MaxExp caused by most patients inhaling during the CT scan. Box plots illustrating the mean values and the ranges measured for patients examined on the combined PET-CT scanner are shown in Fig. 3

phragmatic dome provided more reliable information about diaphragmatic movements in this study. In patients scanned on the combined PET-CT scanner only this distance was evaluated.

In the second series of ten patients, best or second best matches between PET and CT were found with NormExp in 83.3% of all patients for the left and right sides together (Table 2), and with FB in 40.5% (Table 2). As in the first series, the worst match between PET and CT was found during MaxInsp (81.5% of all measurements) (Table 2, Fig. 3 and b). Mean differences in movement of the diaphragmatic dome on CT under the four registration levels, as compared with PET, are shown in Table 3, and statistical comparisons in Table 4. NormExp, MaxExp and FB CT images did sometimes fit the PET image, but the probability of a good fit increased when using NormExp for image co-registration and the range of measured values was smallest when using NormExp (Fig. 3a and b, Table 3). This was less evident in the first series performed on two separate PET and CT scanners (Fig. 3c and d).

Measurements between the reference point and the left and right thoracic wall showed only small differences between the four respiration levels and a slight difference between the left and right side (Fig. 4, Tables 5 and 6). The range of measured values was within 1 cm for most respiration levels.

In 12 patients, 15 lesions within the lung were evaluated. The movements of lesions depended on their loca-

Volkswagen Exhibit 1021, Page 7 of 10

Table 5. Mean differences (and SD, range) between the distances from the reference point to the left and right thoracic wall measured on CT under the four different respiration levels, in relation to the distance measured in the PET scan

Respiration level	Mean	SD	Range
NormExp	–0.5 mm	3.1 mm	–5.9 mm to 7.4 mm
FB	–0.4 mm	2.9 mm	–5.9 mm to 5.9 mm
MaxInsp	–3.3 mm	4.5 mm	–16.1 mm to 5.9 mm
MaxExp	–0.7 mm	3.0 mm	–6.0 mm to 5.9 mm

Table 6. Significance of differences(two-tailed *t* test) in the measured distances from the reference point to the left and right thoracic wall on CT under the four respiration levels

FB vs MaxInsp	S	P=0.0004 left, P=0.0001 right
MaxInsp vs MaxExp	S	P=0.0004 left, P=0.0004 right
MaxInsp vs NormExp	S	P=0.0007 left, P=0.0004 right
FB vs MaxExp	NS	P=0.8 left, P=0.2 right
NormExp vs MaxExp	NS	P=0.6 left, P=0.4 right
FB vs NormExp	NS	P=0.7 left, P=0.6 right

Only MaxInsp showed significant differences compared with the other respiration levels. Box plots illustrating the mean values and the range measured for patients examined on the combined PET-CT scanner are shown in Fig. 4

Table 7. Match of PET-CT co-registered images in 15 lung lesions, for the four different respiration levels

Respiration level	Best and second best match (%)	Worst and second worst match (%)
NormExp	67	33
FB	47	53
MaxInsp	27	73
MaxExp	59	41

The best and second best match and the worst and second worst match are taken together and listed for the four different respiration levels. Measured distances in the MaxExp CT were not reliable since some patients could not perform this breathing task. Because the best and second best match and, respectively, the worst and second worst match are taken together, the added sum is 200% in each column

tion within the lung. Compared with lesions in the lower parts of the lung, lesions in the upper parts and near the hila tended to show a smaller range of movements. As in diaphragmatic movements, the worst matches between PET and CT measurements were found during MaxInsp (range between 5 mm and 33 mm; Table 7; Fig. 6). In contrast, best and second best matches were obtained during NormExp (range between 0 mm and 14 mm; Table 7). FB was not as good as NormExp, with a larger range of values, from 0 mm to 31 mm (Table 7).

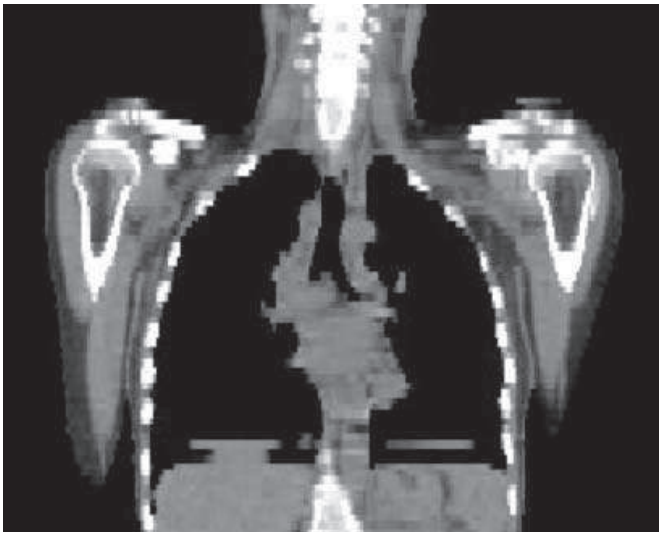

Fig. 5. A typical mushroom-shaped respiration-induced CT artefact. Such artefacts occur when CT of the thorax and abdomen catches the diaphragm at two different levels. Spiral CT scan should therefore be taken in one run over the whole examined body area

Discussion

With the introduction of combined PET-CT systems, co-registration of functional and morphological imaging studies is intrinsically available due to the hardware arrangement of the PET and CT systems. The only remaining potential co-registration errors in such systems are due to physiological motion, which in the chest is predominantly caused by breathing, except in the vicinity of the heart or with insufficient patient cooperation. Because a PET scan takes several minutes per FOV and a PET scan is an average image over many breathing cycles, the co-registration of PET images with CT images would require respiratory gating of the PET. This is not a promising approach owing to the substantial resulting increase in imaging time. In contrast, CT is fast and allows for more flexible imaging protocols; thus, optimization of co-registration has to focus on optimizing the CT data acquisition protocol.

The first important step in CT scanning is to acquire it in one continuous sweep over the whole area examined. This avoids imaging of the diaphragm at different positions, which can lead to blurred images and mushroom-shaped artefacts (Fig. 5) [12]. Continuous efforts have been made to compensate for motion artefacts on CT scans, e.g. by the use of ultra-short scanning times in electron beam CT, modified filtered back-projection algorithms and respiratory gating [13, 14]. Respiratory movements may cause artefacts in CT that can mimic disease and even lead to misdiagnoses [15]. With the advent of MDCT systems, the entire lung can be readily scanned while a patient holds his breath. In fact, the use of an MDCT in a combined PET-CT scanner permits scanning of the lungs with a slice thickness of 5 mm,

Volkswagen Exhibit 1021, Page 8 of 10

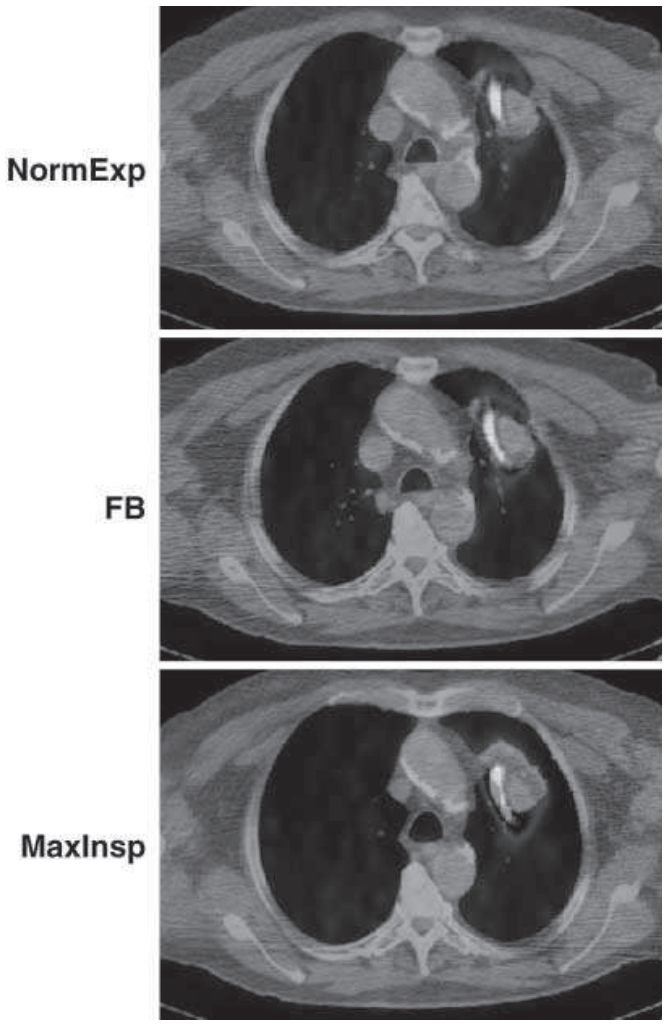

Fig. 6. PET-CT co-registration in a lung lesion. PET-CT co-registered images of a patient with bronchogenic cancer. The co-registration of the increased FDG uptake in PET to the anatomical lesion in CT differs only slightly in normal expiration (NormExp) and free breathing (FB) In maximal inspiration (MaxInsp), the tumour changes its position with a rotational component, and FDG activity appears to shift posteriorly

which matches current PET scanner slice thickness, in less than 10 s. The only co-registration problem not addressed by a combined in-line PET-MDCT system is which respiratory level or manoeuvre during CT data acquisition will offer the best match between CT data and the "free breathing" PET data. Compensation for CT motion artefacts per se is not enough for successful co-registration of the data deriving from the two imaging systems. Movements of the thoracic wall and diaphragm, as well as within the thoracic cage, are quite different in magnitude in all three directions, thus leading to distortions and asymmetrical position changes. This is illustrated in Fig. 6, showing a PET-CT examination of a patient with non-small cell lung cancer. The co-registration of the increased FDG uptake in PET to the anatomical lesion in CT differs only slightly in NormExp and FB. In MaxInsp, however, the PET lesion appears more posterior than the CT lesion, because the anterior parts of the lung move forward and upward during the CT image acquisition of MaxInsp. Also the shape of the tumour changes in the corresponding slice, because of the through-plane motion. Fifteen lesions were measured in 12 patients and a tendency towards larger relative movements in the lower parts of the lung was found. This is a preliminary finding and further studies in larger patient populations with pulmonary nodules will be needed to evaluate how the size of a lesion, its location within the lung and the complex three-dimensional movements during respiration influence the quality of co-registered PET and CT images and how the respiration protocol of the CT acquisition can be optimized.

With the spatial resolution of the best PET scanners in the range of 5 mm, the match between PET and CT imaging data has to be of that order to be qualitatively acceptable. Our data on the match of PET and CT imaging show that in all imaging protocols the differences are small enough to satisfy this condition. However, our data also show that it is rather difficult to adequately measure distances in PET scans, since it is not easy to identify edges of organs, even when using non-attenuation-corrected PET images and standardized contrast levelling. The relative difficulties in correctly measuring distances in PET images are reflected in the evaluation of inter-observer agreement, as shown in the Bland-Altman plots (Fig. 2). In the CT scans 95% of all measured differences between the two collaborators, corresponding to 2 standard deviations, were within 0.26 cm above and below the mean. In contrast, 95% of the PET measurements were within a range of 0.52 cm. Although the values measured in PET are much worse than the measurable differences on CT scans, they correspond to the spatial resolution of a PET image and, therefore, are considered to be qualitatively acceptable.

The movements near the diaphragm are clearly the largest, possibly reaching several centimetres, and are relatively unidirectional. Hence, the cranio-caudal mismatch of the diaphragmatic positions in PET and CT has to be minimized. CT acquisition using a NormExp protocol allows co-registration of such lesions with a mean fit of about 4 mm (SD 12 mm). Therefore, the use of normal expiration provides co-registration to dimensions comparable to the spatial resolution afforded by PET. The relatively large standard deviation suggests that there is substantial variability in patient behaviour. Frequently, a suboptimal image match of small lesions in the lung will not affect the diagnostic value of PET-CT, because the image interpreter will readily identify the lack of superposition as a misregistration artefact due to respiration. Small lesions in general, and particularly those located close to the pleura or the diaphragm, pose a potential problem. Small misregistrations may lead to placement of the lesion noted on PET onto a wrong anatomical structure on CT. In clinical practice, this poses a problem only if the lesion is located at the border of anatomical structures like the pleura. If a

Volkswagen Exhibit 1021, Page 9 of 10

lesion is located in the lung parenchyma on CT, even a misplacement of the PET lesion to the thoracic wall will not suggest pleural invasion. On the other hand, if a pleural lesion noted on CT abuts the chest wall, even a lesion on PET appearing separated from the pleural wall will not permit one to rule out chest wall invasion.

The data of this study further suggest that maximal inspiration and maximal expiration are unsuitable for the acquisition of high-quality fused PET-CT images in the chest. This is because, first, there is a large difference in the diaphragmatic positions on CT and PET images during maximal inspiration and, second, maximum inspiration and particularly maximal expiration are poorly tolerated by patients. Furthermore, a large mismatch of PET and CT images will not only cause anatomical misregistration but also prevent the use of the CT scan as an adequate attenuation map. It has been shown that the CT scan can be used to correct for the attenuation of photons within the patient [16]. Taking a mismatching CT scan for attenuation correction may lead to incorrect calculation of FDG activity in the PET image and eventually to misinterpretation of lesions adjacent to the diaphragm. This will have to be addressed in further studies.

While free breathing can be performed by all patients, we found that the defined expiration protocol in normal expiration provides a higher proportion of best-match imaging studies. This may be due to the higher variability of FB CT studies, leading to a respiration snapshot during the respiratory cycle. The reason why most patients were able to hold their breath at normal expiration without difficulties is the MDCT, which allows scanning of the entire patient from head to pelvic floor in slightly more than 20 s.

Whatever respiration protocol is used for CT acquisition, the patient should be informed about the beginning of the CT acquisition. However, during free breathing, we had two uncooperative patients (sighing/yawning and speaking) despite the fact that they had been told when the CT scan was starting. Because factors like deglutition, sniffing, sneezing, coughing, phonation or speech will decrease the quality of CT scans, it is important to keep the patient attentive during scanning. Using the normal expiration protocol, the patient inhales and then normally exhales before the CT scan is started, which may enhance attentiveness and cooperation.

Conclusion

Optimal co-registration is obtained with a normal expiration protocol independent of whether a stand-alone PET and CT system with patient motion restriction or an in-line PET-CT system is used. The free breathing protocol is a second-best alternative. A perfect match between PET and CT is not possible, but the attainable quality of image co-registration is in the range of the resolution of the PET camera. Therefore, we recommend the Norm-Exp respiration level for clinical imaging.

Acknowledgements. The authors gratefully acknowledge the assistance of Dr. Thomas Hany, who helped with patient recruitment and guidance in image analysis, and Merrill Griff for his help in preparing this manuscript.

References

1. Smith TAD. FDG uptake, tumor characteristics and response to therapy: a review. *Nucl Med Commun* 1998; 19:97–105.
2. Beyer T, Townsend DW, Brun T, Kinahan PE, Charron M, Roddy R, Jerin J, Young J, Byars L, Nutt R. A combined PET/CT scanner for clinical oncology. *J Nucl Med* 2000; 41:1369–1379.
3. Ross CS, Hussey DH, Pennington EC, Stanford W, Doornbos JF. Analysis of movement of intrathoracic neoplasms using ultrafast computerized tomography. *Int J Radiat Oncol Biol Phys* 1990; 18:671–677.
4. Shimizu S, Shirato H, Kagei K, Nishioka T, Bo X, Dosaka-Akita H, Hashimoto S, Aoyama H, Tsuchiya K, Miyasaka K. Impact of respiratory movement on the computed tomographic images of small lung tumors in three dimensional (3D) radiotherapy. *Int J Radiat Oncol Biol Phys* 2000; 46:1127–1133.
5. Wade OL. Movements of the thoracic cage and diaphragm in respiration. *J Physiol* 1954; 124:193–212.
6. Ekberg L, Holmberg O, Wittgren L, Bjelkengren G, Landberg T. What margins should be added to the clinical target volume in radiotherapy treatment planning for lung cancer? *Radiother Oncol* 1998; 48:71–77.
7. Balter JM, Lam KL, McGinn CJ, Lawrence TS, Ten Haken RK. Improvement of CT-based treatment planning models of abdominal targets using static exhale imaging. *Int J Radiat Oncol Biol Phys* 1998; 41:939–943.
8. Davies SC, Hill AL, Holmes RB, Halliwell M, Jackson PC. Ultrasound quantitation of respiratory organ motion in the upper abdomen.*Br J Radiol* 1994; 67:1096–1102.
9. Kubo HD, Hill BC. Respiration gated radiotherapy treatment: a technical study. *Phys Med Biol* 1996; 41:83–91.
10. Mikolajczyk K, Szabatin M, Rudnicki P, Grodzki M, Burger C. A JAVA environment for medical image data analysis: initial application for brain PET quantitation. *Med Inform (Lond)* 1998; 23:207–214.
11. Martin JM, Altman DG. Statistical methods for assessing agreement between two methods of clinical measurement. *Lancet* 1986; 8:307–310.
12. Balter JM, Ten Haken RK, Lawrence TS, Lam KL, Robertson JM. Uncertainties in CT based radiation therapy treatment planning associated with patient breathing. *Int J Radiat Oncol Biol Phys* 1996; 36:167–174.
13. Ritchie CJ, Kim Y, Crawford CR, Godwin JD. CT motion artifact correction using pixel specific back-projection. *Proc IEEE Eng Med Biol Soc* 1992; 14:1782–1783.
14. Ritchie CJ, Hsieh J, Gard MF, Godwin JD. Predictive respiratory gating: a new method to reduce motion artifacts on CT scan.*Radiology* 1994; 190:847–852.
15. Traver RD, Conces DJ, Godwin JD. Motion artifacts on CT simulate bronchiectasis. *Am J Roentgenol* 1988; 151:1117–1119.
16. Kinahan PE, Townsend DW, Beyer T, Sashin D. Attenuation correction for a combined 3D PET/CT scanner. *Med Phys* 1998; 25:2046–2053.

Volkswagen Exhibit 1021, Page 10 of 10