Fundamentals of Electrocardiography Interpretation

Daniel E. Becker, DDS

Professor of Allied Health Sciences, Sinclair Community College, and Associate Director of Education, General Dental Practice Residency, Miami Valley Hospital, Dayton, Ohio 45409

The use of dynamic electrocardiogram (ECG) monitoring is regarded as a standard of care during general anesthesia and is strongly encouraged when providing deep sedation. Although significant cardiovascular changes rarely if ever can be attributed to mild or moderate sedation techniques, the American Dental Association recommends ECG monitoring for patients with significant cardiovascular disease. The purpose of this continuing education article is to review basic principals of ECG monitoring and interpretation.

Key Words: Electrocardiography; Patient monitoring; Continuing education.

Dynamic electrocardiographic (ECG) monitoring is a standard of practice when providing general anesthesia, but opinions are mixed regarding its use during moderate (conscious) and deep sedation. The American Dental Society of Anesthesiology included pulse oximetry for patient monitoring in its guidelines published in 1991.[1] The guidelines at that time also encouraged ECG monitoring during deep sedation, but not during moderate (conscious) sedation. The American Dental Association recently revised its monitoring guidelines to include ECG monitoring for all deeply-sedated patients and for consciously-sedated patients with compromised cardiovascular function.[2] Most publications in the medical anesthesia literature regard ECG monitoring as a standard for both sedation and anesthesia,[3] but many experts question its actual value in preventing sedation-related morbidity and mortality among patients without preexisting cardiac risk. Despite this controversy, a growing number of state dental boards are requiring ECG monitoring for general anesthesia and all levels of intravenous sedation.

Disregarding these legal controversies, there is an intangible reassurance provided by an ECG monitor that adds to that provided by periodic measurement of blood pressure and continuous pulse oximetry. This of course presumes that the operator is comfortable witnessing occasional benign arrhythmias and the subtle mechanical nuances all monitors present during routine use. The purpose of this Continuing Education article is to provide fundamental concepts of ECG recognition that will enable the dentist to feel more comfortable with the routine use of dynamic ECG monitoring.

GENERAL PRINCIPLES OF CARDIAC FUNCTION

The output of the heart per minute (cardiac output) is the paramount cardiovascular event required to sustain blood flow throughout the body. In addition to blood volume and contractile strength, the heart must sustain a regular cycle of relaxation and contraction if it is to fulfill its objective. This regularity is predicated on a series of complex electrophysiological events within the cardiac tissues that can be monitored using a device called the electrocardiogram. This device is variably referred to as an ECG or as an EKG, the latter based on the Greek term ''kardia'' for heart. Many prefer EKG to ECG because it is less likely to be confused verbally with EEG, the abbreviation for electroencephalogram. However, we will arbitrarily adopt ECG for this presentation.

The quintessential events required for a normal cardiac cycle are the rhythmic contraction and relaxation of the atria and ventricles. The heart is composed of 2 principal cell types: working cells and specialized neural-

Received June 27, 2005; accepted for publication September 20, 2005.

Address correspondence to Dr Daniel Becker, Miami Valley Hospital, Dayton, Ohio 45409; dan.becker@sinclair.edu.

Anesth Prog 53:53–64 2006
© 2006 by the American Dental Society of Anesthesiology
ISSN 0003-3006/06/$9.50
SSDI 0003-3006(06)

iRhythm, Inc. / Welch Allyn, Inc.
Exhibit 1014
Page 1

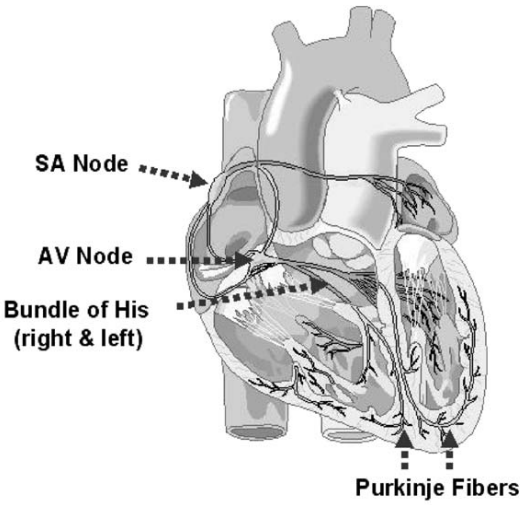

Pacemaker	Intrinsic Rate
Sinoatrial (SA) node	60-80/min
Atrioventricular (AV) node	40-50/min
Bundle of His	30-40/min
Purkinje fibers	15-30/min

Figure 1. Specialized neural-like conductive tissues and their approximate firing rates.

like conductive cells. The working cells are the muscle or myocardium of the atria and ventricles. Specialized cells include the sinuatrial (SA) node, the atrioventricular (AV) node, the bundle of His, and the Purkinje fibers (Figure 1). These cells initiate and conduct electrical impulses throughout the myocardium, and this regulates the rhythm of a cardiac cycle. In order to initiate impulses, specialized cells have a property called *automaticity,* which reflects an ability to initiate electrical impulses spontaneously. This is independent of any nerves or hormones, but their actual rate of firing can be influenced by autonomic nerves, with sympathetics increasing and parasympathetics decreasing their rate. Each cardiac cycle commences with an impulse, spontaneously generated by the SA node, that subsequently spreads throughout the remainder of the neural-like conductive tissues and onto the muscle (myocardial) cells. Abnormalities within this conduction system will compromise cardiac output and are called arrhythmias or dysrhythmias synonymously.

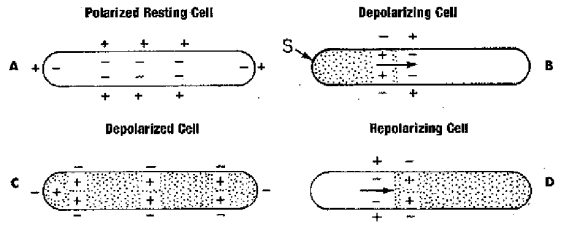

Figure 2. Depolarization and repolarization of cell membranes. A) The resting cell membrane is charged positively on the outside and negatively on the inside. B) Following a stimulus (S), positive ions enter the cell reversing this polarity. C) This process continues until the entire cell is depolarized. D) Ions are returned to their normal location and the cell repolarizes to its normal resting potential.

ELECTROPHYSIOLOGICAL CONSIDERATIONS

To fully appreciate electrical impulses and the information provided by an ECG, we must first review fundamental concepts regarding electrical membrane potentials. All cardiac cell membranes are positively charged on their outer surfaces because of the relative distribution of cations. This *resting membrane potential* is maintained by an active transport mechanism called the *sodium-potassium pump.* When the cell is stimulated, ion channels open, allowing a sudden influx of sodium and/or calcium ions and thereby reversing the resting potential. This period of *depolarization* is very brief because sodium channels close abruptly, denying further influx of sodium. Simultaneously, potassium channels open and allow intracellular potassium to diffuse outward while sodium ions are actively pumped out. This reestablishes a positive charge to the outside of the membrane, a process called *repolarization* that returns the membrane to its resting membrane potential. The processes of depolarization and repolarization are referred to collectively as an *action potential.* This event self-propagates as an impulse along the entire surface of a cell and from one cell to another, provided that their membranes are connected (Figure 2).

It is essential that one address the actual purpose of an action potential. All human cells exhibit this phenomenon, and its purpose varies according to the cell's function. The purpose of action potentials in neurons is to

iRhythm, Inc. / Welch Allyn, Inc.
Exhibit 1014
Page 2

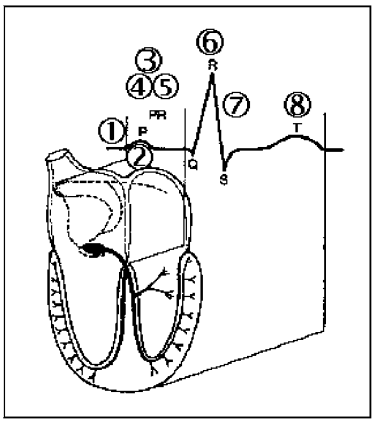

	Physiologic Event	ECG Evidence
1.	SA node initiates impulse	Not visible
2.	Depolarization of atrial muscle	P wave
3.	Atrial contraction	Not visible
4.	Depolarization of AV node & Common Bundle	Not visible
5.	Repolarization of atrial muscle	Not visible
6.	Depolarization of ventricular muscle	QRS complex
7.	Contraction of ventricular muscle	Not visible
8.	Repolarization of ventricular muscle	T wave

Figure 3. Summary of events of a cardiac cycle. Of the 8 physiologic events listed for a cardiac cycle, only 3 are actually observed on an ECG tracing.

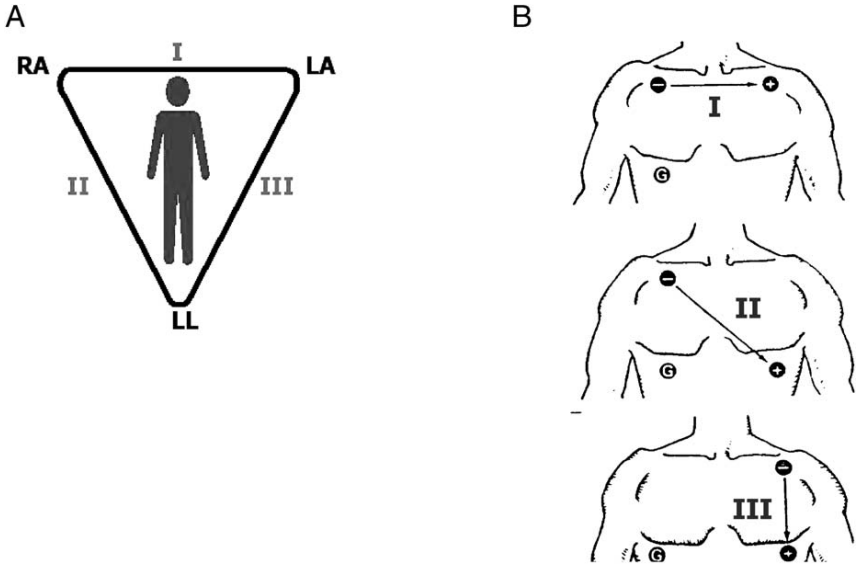

Figure 4. A) Einthoven's triangle and B) standard limb leads I, II, and III.

initiate release of neurotransmitters that either excite or stabilize cell membranes of the tissue innervated. In skeletal and cardiac muscle cells, action potentials release stored calcium ions that initiate the actual contractile process.

Cells comprising the heart's conduction system are unique in 2 aspects. First of all, they possess automaticity. The physiological explanation for this property resides in the resting membrane's partial permeability to calcium and/or sodium ions. The gradual inward ''leak'' of cations decreases the voltage of the resting potential until a threshold is reached. At this point, all channels open and rapid cation influx depolarizes the membrane. The second unique characteristic of this specialized tissue is the fact that, unlike classic neural tissue, these cells do not release neurotransmitters. Instead, they are in direct contact with cardiac muscle, and their action potential initiates depolarization of the cardiac muscle cells directly.

Cardiac muscle cells are fused to one another by special attachments called *intercalated discs.* This allows them to function as a continuous sheet of cells called a *syncytium.*[4] The atrial syncytium is separated from that of the ventricles by a layer of connective tissue that acts as an insulator. The SA node initiates depolarization of the atrial muscle, but the insulation precludes propagation into the ventricles except at 1 place, the AV node. The AV node delays and finally relays the impulse along

iRhythm, Inc. / Welch Allyn, Inc.
Exhibit 1014
Page 3

the common bundle of His, which penetrates the connective tissue to enter the ventricles. The impulse continues along the common bundle of His and its branches until it finally reaches the Purkinje fibers, which ignite the ventricular muscle syncytium.

The action potential of an individual cell can be measured using microprobes inserted through its cell membrane. It is far too small an electrical event to be measured by surface electrodes. However, action potentials that spread throughout the muscle syncytia of the heart are great enough for surface electrodes to record and produce a tracing known as an ECG. It is important to appreciate that the ECG cannot record electrical events generated by the specialized cells of the conduction system; their voltages are far too small. What you observe in an ECG tracing is the action potentials of the atrial and ventricular muscle cells. However, other events can be deduced from the tracing.

THE ECG TRACING

The electrical sequence of a cardiac cycle is initiated by the sinoatrial node, the so-called pacemaker of the heart. This is because the SA node has a faster rate of spontaneous firing than the remaining specialized tissues (see Figure 1). However, if this rate should decrease, other portions of this specialized system can gain control, a phenomenon termed *escape.*

The baseline of an ECG tracing is called the isoelectric line and denotes resting membrane potentials. Deflections from this point are lettered in alphabetical order, and following each, the tracing normally returns to the isoelectric point. The first deflection is the P wave and represents depolarization of atrial muscle cells. It does not represent contraction of this muscle, nor does it represent firing of the SA node. These events are deduced based on the shape and consistency of the P waves. One assumes that the SA node fires at the start of the P wave, and one assumes that atrial contraction begins at the peak of the P wave. Although atrial repolarization follows depolarization, the ECG provides no evidence of this event. A popular misconception is that evidence of repolarization is obscured by the subsequent QRS complex. Were this true, however, repolarization would be observed in cases where the QRS complex is delayed or absent, eg, AV blocks. The correct explanation is that atrial repolarization is too minor in amplitude to be recorded by surface electrodes.[5,6]

The QRS complex represents depolarization of ventricular muscle cells. The Q portion is the initial downward deflection, the R portion is the initial upward deflection, and the S portion is the return to the baseline, or the so-called isoelectric point. Often, the Q portion is not evident and the depolarization presents as only an ''RS'' complex. In any case, the complex does not represent ventricular contraction. One assumes that contraction will commence at the peak of the R portion of the complex. Unlike contraction of the atria, ventricular contraction can be confirmed clinically by palpating a pulse or by monitoring a pulse oximeter wave form. A patient in cardiac arrest may have normal QRS complexes on his or her ECG; ventricular muscle cells are depolarizing, but there is no contraction. This phenomenon is called *pulseless electrical activity.* Following depolarization, ventricular muscle repolarizes, and this event is great enough in amplitude to generate the T wave on the ECG tracing.

The PR interval is measured from the beginning of the P wave to the beginning of the R portion of the QRS complex. (This is conventional because the Q portion of the complex is so frequently indiscernible.) Because the PR interval commences with atrial muscle depolarization and ends with the start of ventricular depolarization, one can assume that the electrical impulse passes through the AV node into the ventricle during this interval. If the PR interval is prolonged, one may deduce that AV block is present. The electrical events of an ECG are illustrated and summarized in Figure 3.

TECHNICAL CONSIDERATIONS

In 1901 a Dutch physiologist, Willem Einthoven, developed a galvanometer that could record the electrical activity of the heart. He found that a tracing can be produced as action potentials spread between negatively and positively charged electrodes. (A third electrode serves to ground the current.) He found that tracings varied according to the location of the positive and negative electrodes, and subsequently described 3 angles or *leads* in the form of a triangle with the heart in the middle. This is known today as Einthoven's triangle, and the 3 electrode arrangements are known as the primary limb leads I, II, and III (Figure 4). As research continued throughout the 20th century, additional arrangements were discovered that enable physicians to analyze electrical events as they spread in many directions through the heart, much like an apple slicer sections an apple into various parts. Today, the cardiologist analyzes a 12-lead ECG to aid in diagnosing infarctions, hypertrophy, and complex arrhythmias. Our purpose in this article, however, is to identify only the basic arrhythmias that justify dynamic ECG monitoring during sedation and general anesthesia. For this purpose, a single-lead ECG is all that is required. Most often, lead II is selected because it generally records the largest waves.

iRhythm, Inc. / Welch Allyn, Inc.
Exhibit 1014
Page 4

ECG PAPER

An ECG monitor displays a tracing that lacks any grid as background. However, most of these monitors are equipped with optional printers that can generate a gridded printout if desired. As the stylus of the recording device is deflected by electrical currents, the recording paper is moving at a speed of 25 mm/s. This creates an ECG tracing whose components can be measured. The vertical axis of an ECG denotes voltage and the direction of waveforms from the baseline. These considerations are generally irrelevant during routine monitoring, but have significance for diagnosing ischemia and infarction. The horizontal axis denotes time and sequence of events, both of which are essential for arrhythmia recognition. Standard ECG recording paper is divided into small and large squares. The former represent 0.04-second intervals. Five small squares constitute a large square, which represents 0.20 seconds. Notice, in Figure 5, that the lines between every 5 boxes are heavier, so that each 5-mm unit horizontally corresponds to 0.2 seconds ($5 \times 0.04 = 0.2$). The ECG can therefore be regarded as a moving graph with 0.04- and 0.2-second divisions.

ECG ANALYSIS

Dynamic ECG monitors display heart rate, but it can also be ascertained from a printed tracing using either of 2 methods:

1. When the heart rate is regular, count the number of large (0.2-second) boxes between 2 successive QRS complexes and divide 300 by this number. The number of large time boxes is divided into 300 because $300 \times 0.20 = 60$ and heart rate is calculated in beats per minute or 60 seconds. For example, if there are 3 large boxes between QRS complexes, the heart rate is 100 beats/min, because $300 \div 3 = 100$. Similarly, if 4 large time boxes are counted between QRS complexes, the heart rate is 75 beats/min (Figure 6).
2. If the heart rate is irregular, the first method will not be accurate because the intervals between QRS complexes vary from beat to beat. In most cases, ECG graph paper is scored with marks at 3-second intervals. In such cases simply count the number of QRS complexes every 3 or 6 seconds and multiply this number by 20 or 10 respectively.

How one chooses to analyze an ECG rhythm strip is arbitrary. Each clinician must adopt a sequence of analysis that accommodates personal methods of reasoning. Always keep in mind that events during the PR interval pertain to supraventricular activity. When abnormalities are detected, try to establish the event as ventricular or supraventricular in origin. The following sequence represents one suggestion for analysis of an ECG tracing. I describe it as a 5-step analysis. Refer to Figure 6 during the following explanation.

Step 1: Is the Rhythm Regular or Irregular?

If the intervals between QRS complexes (R-R intervals) are consistent, ventricular rhythm is regular. If intervals between P waves (P-P intervals) are consistent, the atrial rhythm is regular. In Figure 6 the rhythm is regular.

Step 2: Are All QRS Complexes Similar, and Are They Narrow?

The duration of the QRS complex should not exceed 0.10 seconds (2½ small squares). A widened complex indicates ventricular enlargement (hypertrophy) or that ventricular depolarization is being initiated by pacemaker tissue below the AV node, eg, ventricular-paced rhythm. In this case, 1 ventricle depolarizes first and the current must spread into the second ventricle. This takes more time than when the current spreads down the bundle into both ventricles simultaneously. If QRS complexes are narrow, the rhythm is being initiated by a pacemaker at the AV node or higher and is described as a supraventricular rhythm. If the complexes are wide, the pacemaker is in the ventricles and is described as a ventricular rhythm. Should complexes vary in appearance, more than one pacemaker is generating impulses. This phenomenon is referred to as *ectopic pacemakers,* and the rhythm described as *ectopy.*

Step 3: Are All P Waves Similar and Are PR Intervals Normal?

If P waves are all similar, and normal in shape, one can assume that the SA node is the primary pacemaker. In this case the rhythm is *sinus* in character. If P waves vary in shape or are absent, other tissue(s) are functioning as pacers.

The PR interval is normally 0.12–0.20 seconds (3–5 small squares). Longer intervals indicate that the impulse is being delayed from entering the ventricles and the condition is designated AV block.

Step 4: Is the Rate Normal?

If the rhythm is regular, count the number of large squares between QRS complexes and divide this num-

iRhythm, Inc. / Welch Allyn, Inc.
Exhibit 1014
Page 5

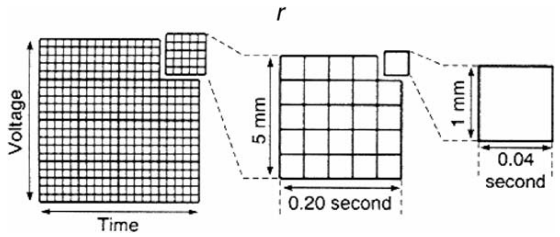

Figure 5. Standard ECG paper.

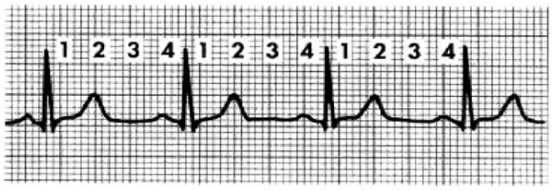

Figure 6. The normal ECG tracing.

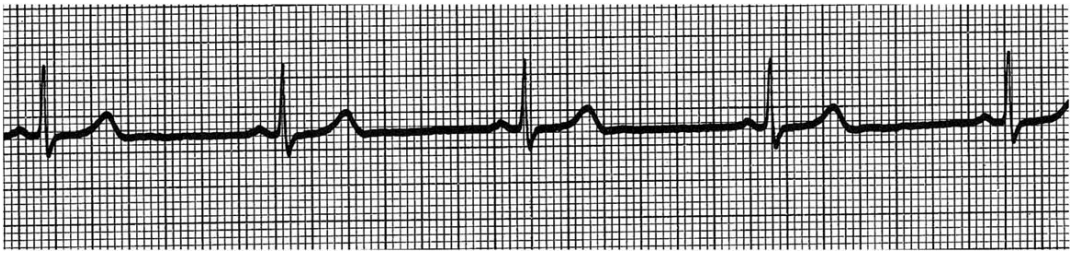

Figure 7. Sinus bradycardia. Each cycle commences with a P wave and the PR interval is normal. Therefore, rhythms are sinus-paced and differ only in rate: normal sinus rhythm, sinus bradycardia, or sinus tachycardia. In this case, it is sinus bradycardia, because the rate is <60.

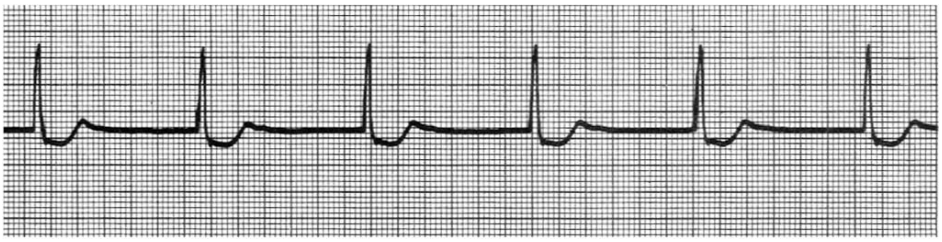

Figure 8. Junctional rhythm. There are no P waves and a PR interval cannot be ascertained. Therefore, the sinoatrial node is not pacing this rhythm. But the QRS complexes are narrow, so the pacemaker is above the ventricles. The logical conclusion is that the atrioventricular node or neighboring tissue is pacing the heart. This is called junctional rhythm. Because this node has a slower firing rate than the sinoatrial node (See Figure 1), rates of 50 and 90 are the cutoffs for bradycardic and tachycardic rates, ie, junctional bradycardia or tachycardia.

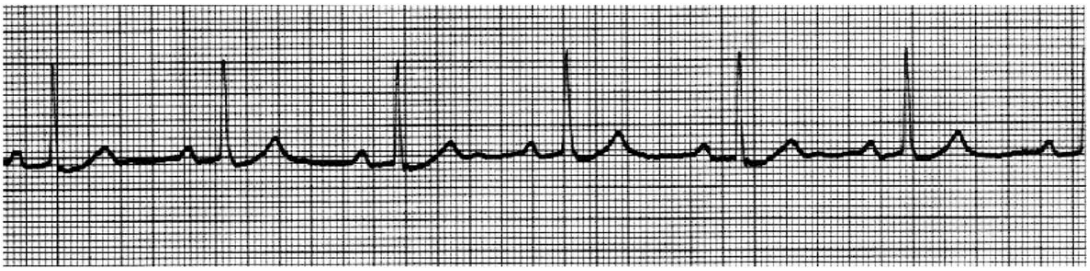

Figure 9. Normal sinus rhythm with first-degree atrioventricular block. Each cycle commences with a P wave, but the PR interval is prolonged. Therefore, rhythm is sinus-paced but the impulse is being delayed at the atrioventricular node. Rates can be normal, bradycardic, or tachycardic.

iRhythm, Inc. / Welch Allyn, Inc.
Exhibit 1014
Page 6

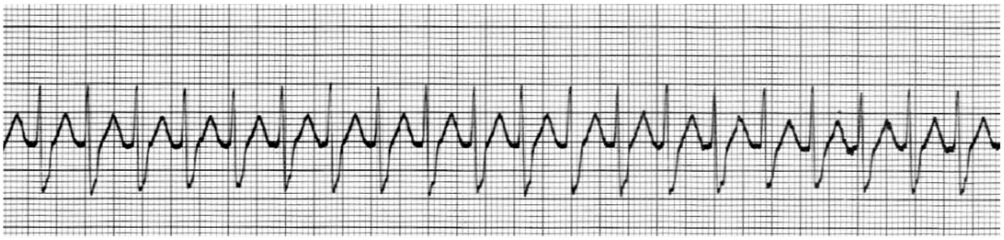

Figure 10. Supraventricular tachycardia. There are no P waves and a PR interval cannot be ascertained. Only 1 wave is discernible between QRS complexes and one cannot determine whether a P wave is absent or occurring simultaneously with the T wave. The rhythm is rapid, but one cannot conclude whether it is sinus-paced or paced by some other tissue. It could be sinus tachycardia or junctional tachycardia, but we can't be sure. This dilemma surfaces when rates become greater than 150. Therefore, because the QRS complexes are narrow, we know only that the rhythm is being paced from above the ventricle. Is it sinus or junctional paced? We ''cop out'' and call it ''supraventricular.''

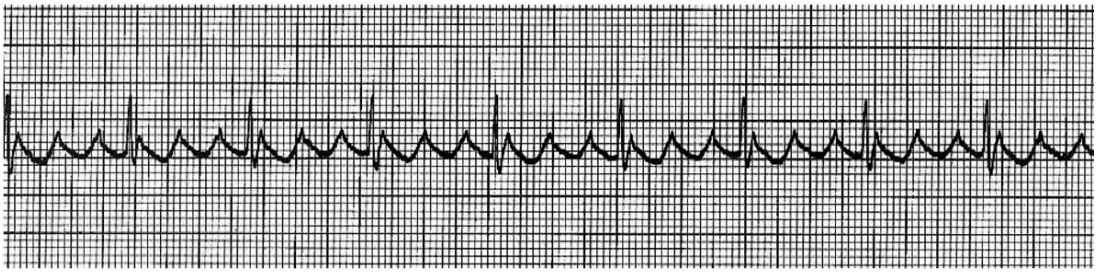

Figure 11. Atrial flutter. Multiple waves appear between each QRS complex and we cannot ascertain whether they are P or T waves. This pattern emerges when an ectopic pacemaker emerges in the atrial muscle and fires more rapidly than the sinuatrial node. This generates multiple depolarizations in the atrial muscle, reflected as so-called flutter waves. Each has a slant to its anterior portion; we can describe this as a saw-toothed pattern. Normally, the atrioventricular node allows only one of them to pass into the ventricle each cycle, which results in a regular ventricular response.

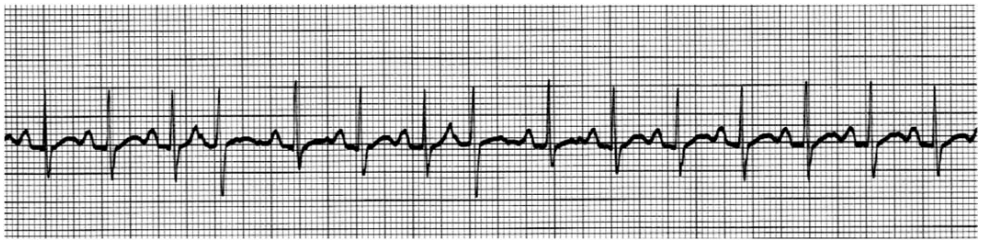

Figure 12. Premature atrial and junctional complexes. Most cycles commence with a P wave, and most PR intervals are normal. Therefore, the rhythm is sinus-paced, but occasionally an extra impulse is fired from an ectopic pacemaker that travels down into the ventricle and creates an extra QRS complex. Notice that normally there is a pause, or a period of time following a T wave until the next P wave commences. In the case of premature complexes, this pause is interrupted. At this point in your training, it is not important to interpret the source of this premature complex; is it atrial or junctional? We know it is coming from above the ventricle, and it is always acceptable to call it a premature atrial complex. The difference between the two has little clinical relevance.

iRhythm, Inc. / Welch Allyn, Inc.
Exhibit 1014
Page 7

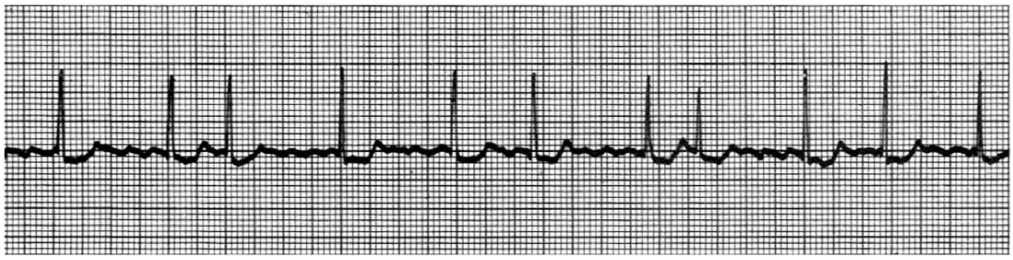

Figure 13. Atrial fibrillation. The waves between each QRS complex are random and indistinct; in essence, they're a mess! Furthermore, the R-R intervals are consistently irregular. This pattern emerges when several ectopic pacemakers emerge in the atrial muscle and all fire more rapidly than the sinuatrial node. This generates multiple depolarizations in the atrial muscle, far more numerous than those with atrial flutter. The atrioventricular node is so overwhelmed with impulses that it cannot allow any to pass through on a regular basis. Therefore, we see this striking irregular ventricular response.

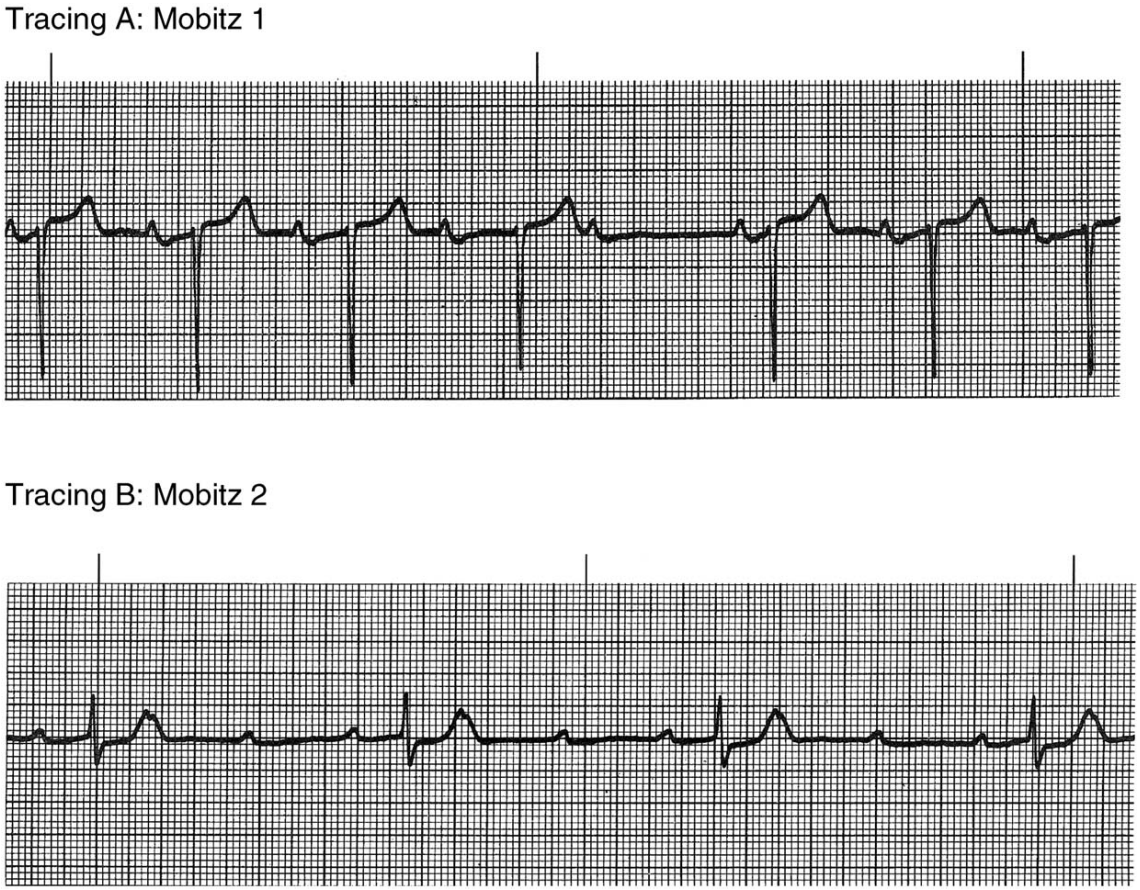

Figure 14. Normal sinus rhythm with second-degree (Mobitz) atrioventricular block. Each cycle commences with a P wave, but occasionally the P wave is not followed by a QRS and another P wave appears. This is called a ''dropped beat'' and is the fundamental defect in a second-degree or Mobitz block. First look at tracing A. (Don't be disturbed by the fact that the QRS complexes go down instead of up. Waves are waves! Their direction depends on the particular lead used to record the tracing.) Notice that each successive PR interval lengthens until finally 1 P wave stands alone and a beat is dropped. Also notice that after the beat is dropped, the PR intervals commence again to progressively lengthen until another beat is dropped. This strange pattern of PR intervals was first described by a cardiologist named Wenckebach. Therefore, this type of second-degree block is called a Mobitz 1 or Wenckebach block. In tracing B, notice that all PR intervals are identical. They may be normal in length or delayed, but they are all the same; even after a beat is dropped, they resume their duration. This is called a Mobitz 2 block. In this particular example, the ratio of P waves to QRS complexes is 2 : 1. Therefore, the R-R intervals are regular. With any other ratio, eg, 3 : 1 or 4 : 1, the R-R interval would appear irregular.

iRhythm, Inc. / Welch Allyn, Inc.
Exhibit 1014
Page 8

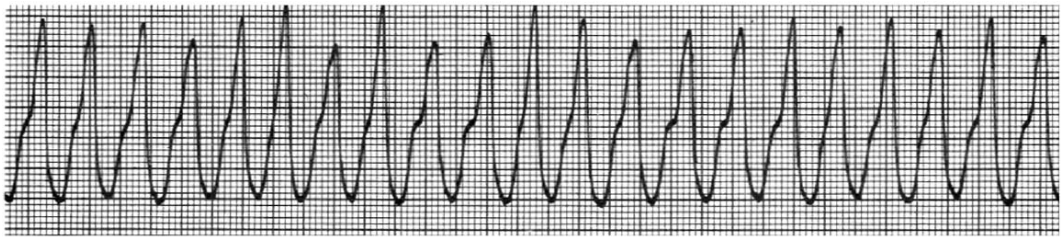

Figure 15. Ventricular tachycardia. There are no P waves and a PR interval cannot be ascertained. No waves are discernible between QRS complexes, but the R-R intervals are regular and the QRS complexes are wide. The rhythm is rapid and is being paced by tissue in the ventricle. This rhythm differs from supraventricular tachycardia (Figure 10) only in the fact that the QRS complexes are wide rather than narrow.

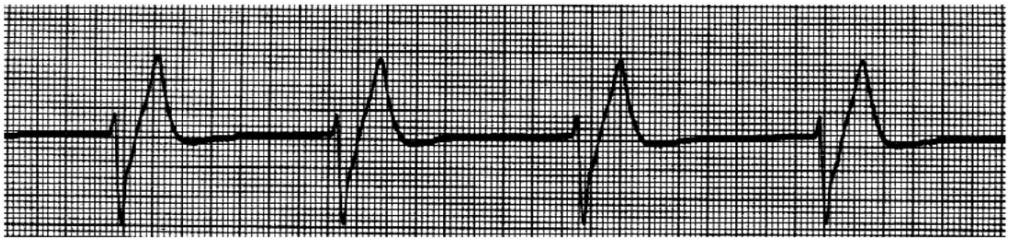

Figure 16. Idioventricular rhythm. There are no P waves and a PR interval cannot be ascertained. No waves are discernible between QRS complexes, but the R-R intervals are regular and the QRS complexes are wide. The rhythm is slow and is being paced by tissue in the ventricle. This rhythm differs from ventricular tachycardia (Figure 15) only in the fact that the rate is slow; it could just as well be called ventricular bradycardia.

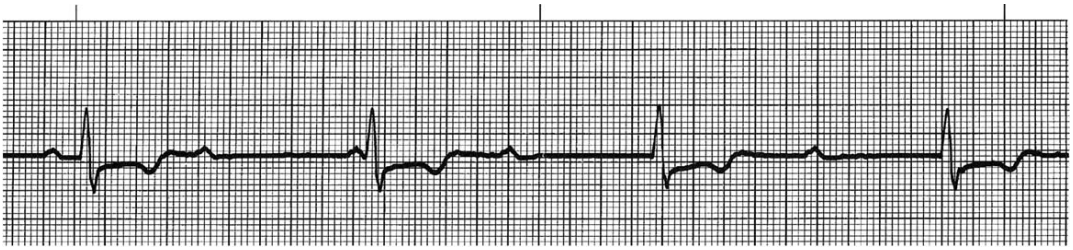

Figure 17. Third-degree (complete) block. There are P waves but the PR intervals appear inconsistent; no pattern is repeated. If impulses were being conducted into the ventricles, the R-R intervals would be irregular and the QRS complexes would be narrow. Neither is the case, however; the R-R intervals are regular and the complexes are slightly widened. (They get wider and wider according to the location of the ventricular pacemaker. In this case, the pacer is probably in the bundle of His, because the complex is relatively narrow.) On closer analysis, one can detect that intervals between P waves (P-P intervals) are consistent and that R-R intervals are consistent. The only explanation is that the SA node is pacing the atria but impulses are not reaching the ventricles. Therefore, the ventricles have developed their own pacemaker and we have a complete (third-degree) heart block.

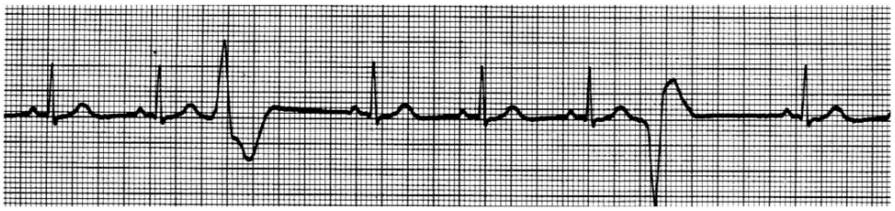

Figure 18. Premature ventricular complexes. Most cycles contain narrow QRS complexes and could represent any of the supraventricular rhythms described in groups A or B. But occasionally one sees a wide QRS complex interposed between the cardiac cycles. Therefore, the primary rhythm may be sinus- or supraventricular-paced, but occasionally an extra impulse is fired from an ectopic pacemaker within the ventricle and creates a wide QRS complex. These complexes are called premature ventricular complexes and may accompany any of the supraventricular rhythms described thus far. If the complexes on a tracing all resemble one another in shape, a single irritable focus is the culprit and is described as unifocal. If the premature ventricular complexes have variable shapes, multiple foci are implicated and the rhythm is described as multifocal.

iRhythm, Inc. / Welch Allyn, Inc.
Exhibit 1014
Page 9

Table Suggested System for Logical Analysis of ECG Tracings*

Narrow QRS = Supraventricular Rhythm (Sinus, Atrial, or Junctional)		*Wide QRS = Ventricular Rhythm*	
Group A: Regular R-R	*Group B: Irregular R-R*	*Group C: Regular R-R*	*Group D: Variable R-R*
NSR, sinus bradycardia, sinus tachycardia	PAC or PJC	Ventricular tachycardia	PVC
Junctional rhythm	Atrial fibrillation	Idioventricular rhythm	Ventricular fibrillation
AV block: first-degree	AV block: Mobitz (second-degree) 1 or 2†	AV block: third-degree	Asystole
Supraventricular tachycardia			
Atrial flutter†			

* Possible rhythms are separated according to width of QRS complex and R to R regularity. There will always be exceptions, but do not consider these in your initial attempts at analysis. ECG indicates electrocardiogram; NSR, normal sinus rhythm; PAC, premature atrial complex; PJC, premature junctional complex; PVC, premature ventricular complex; and AV, atrioventricular.

† The most noted exceptions: atrial flutter can present as an irregular R-R, and a second-degree Mobitz II AV block will have a regular R-R if the conduction ratio is 2:1.

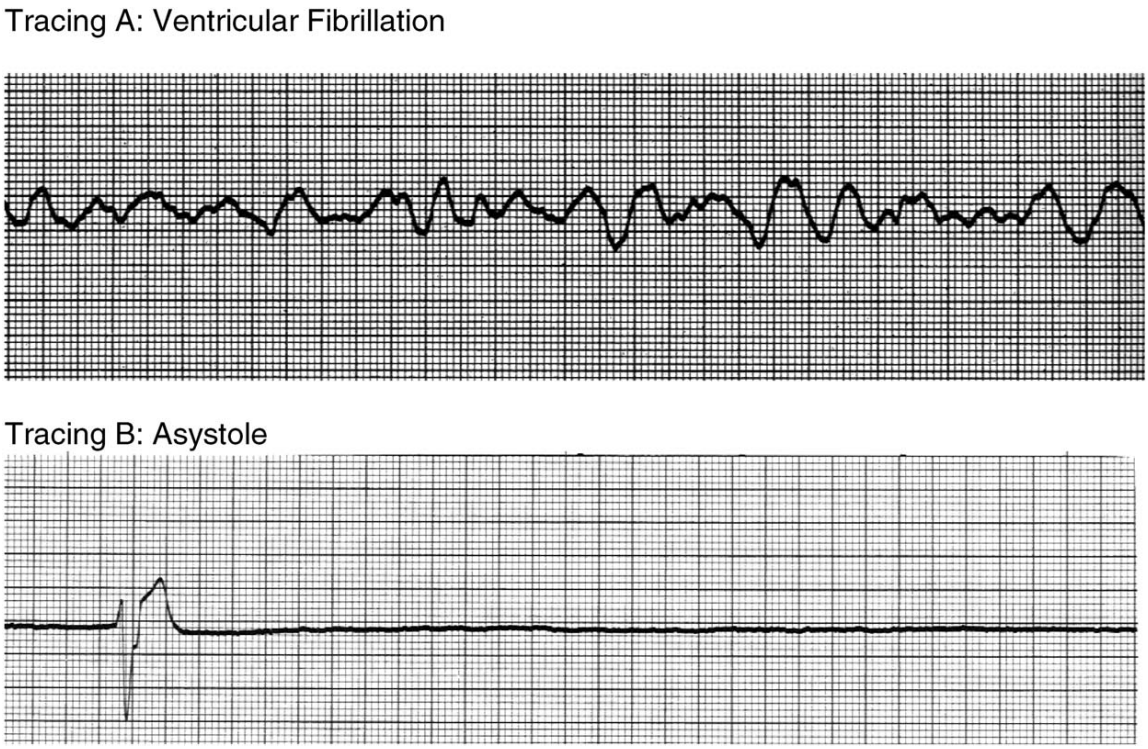

Figure 19. Ventricular fibrillation and asystole. Here we have the worst tracings of all. Tracing A is pure chaos with no consistent waves whatsoever—ventricular fibrillation. In tracing B, following a single beat, we have no further evidence of electrical activity. This is called asystole. In either case, the patient is in cardiac arrest with no pulse.

ber into 300. However, if the rhythm is irregular, count the number of QRS complexes in a 6-second segment and multiply by 10. Rates below 60 indicate bradycardia; those above 100 indicate tachycardia. In Figure 6 there are approximately 4 large boxes between QRS complexes, so the rate is approximately 75.

Step 5: Do Waves and Complexes Proceed in Normal Sequence?

Each P wave should be followed by a QRS complex, which is followed by a T wave. This assures a normal sequence for each cardiac cycle.

iRhythm, Inc. / Welch Allyn, Inc.
Exhibit 1014
Page 10

ARRHYTHMIA IDENTIFICATION

Most basic courses in ECG interpretation emphasize the precise recognition of at least 15–20 arrhythmias. The primary objectives are rote memorization of a name for each rhythm and its deviant characteristics. However, this approach nurtures an inability to assess the clinical significance of a particular arrhythmia. ECG analysis must be correlated with the patient's appearance and vital signs. Collectively, these will establish the clinical significance of the electrical disturbance and determine any indication for intervention. One method for organizing your thoughts is presented in the Table. By performing the first 2 steps described above, you can organize all basic arrhythmias into 4 groups (Table).

Rhythms in Group A

During the first 2 steps of your 5-step analysis, you find that the R-R intervals are regular and all QRS complexes are narrow. From this, we know that the heart is being paced from tissue above the ventricle. The possible rhythms in group A are illustrated in Figures 7–11. For each, apply steps 3–5 of your 5-step analysis.

Rhythms in Group B

During the first 2 steps of your 5-step analysis, you find that the R-R intervals are irregular but all QRS complexes are narrow. From this, we know that the heart is being paced from tissue above the ventricles. The possible rhythms in group B are illustrated in Figures 12–14. For each, apply steps 3–5 of your 5-step analysis.

Rhythms in Group C

During the first 2 steps of your 5-step analysis, you find that the R-R intervals are regular but all QRS complexes are wide. From this, we know that the heart is being paced from tissue below the AV node, within the ventricles. The possible rhythms in group C are illustrated in Figures 15–17. For each, apply steps 3–5 of your 5-step analysis.

Rhythms in Group D

During the first 2 steps of your 5-step analysis, you find that the R-R intervals are irregular and that the QRS complexes vary in shape. The possible rhythms in group D are illustrated in Figures 18–19. For each, apply steps 3–5 of your 5-step analysis.

REFERENCES

1. Rosenberg MB, Campbell RL. Guidelines for intraoperative monitoring of dental patients undergoing conscious sedation, deep sedation, and general anesthesia. *Oral Surg Oral Med Oral Pathol.* 1991;71:2–8.
2. American Dental Association. *Guidelines for the Use of Conscious Sedation, Deep Sedation and General Anesthesia for Dentists.* Adopted by the House of Delegates, American Dental Association, October 2005.
3. Eichhorn JH, Cooper JB, Cullen DJ, et al. Standards for patient monitoring during anesthesia at Harvard Medical School. *JAMA.* 1986;256:1017–1020.
4. Guyton AC, Hall JE. *Textbook of Medical Physiology.* 10th ed. Philadelphia, Pa: WB Saunders Co; 2000.
5. Brunwald E, Zipes DP, Libby P. *Heart Disease: A Textbook of Cardiovascular Medicine.* 6th ed. Philadelphia, Pa: WB Saunders Co; 2001.
6. Goldberger AL. *Clinical Electrocardiography: A Simplified Approach.* 6th ed. St Louis, Mo: Mosby Inc; 1999.

iRhythm, Inc. / Welch Allyn, Inc.
Exhibit 1014
Page 11

CONTINUING EDUCATION QUESTIONS

1. Which of the following events is recorded in an ECG tracing?
   A. Depolarization of the SA node.
   B. Contraction of ventricular muscle.
   C. Repolarization of atrial muscle.
   D. Depolarization of ventricular muscle.
2. An ECG tracing reveals upright P waves preceding each QRS complex, but they have varied shapes and sizes. The QRS complexes are narrow but the R-R intervals are irregular. Which of the following can be concluded regarding this rhythm?
   A. It is a sinus rhythm.
   B. The heart is being paced by multiple pacemaker sites within the atria.
   C. A heart block is present.
   D. The AV node or common bundle of His is pacing the heart.
3. An ECG tracing reveals several P waves that are not followed by QRS complexes, but all remaining cycles have PR intervals that measure 0.16 mm. Which of the following can be concluded regarding this rhythm?
   A. A first-degree block is present.
   B. A second-degree Mobitz I block is present.
   C. A second-degree Mobitz II block is present.
   D. A third-degree block is present.
4. An ECG tracing reveals mostly normal cycles, but occasionally a single isolated QRS complex appears following a T wave. These extra complexes have a wide, bizarre shape but they are all similar. Which of the following would be an accurate explanation for these bizarre complexes?
   A. They are premature complexes generated by the same ectopic pacemaker in the ventricles.
   B. They are premature complexes generated by multiple ectopic pacemakers in the ventricles.
   C. They are premature atrial complexes triggered by the SA node.
   D. They are premature atrial complexes triggered by an irritable focus in the nodal area.

iRhythm, Inc. / Welch Allyn, Inc.
Exhibit 1014
Page 12