Check for updates

Spatial Vector Electrocardiography

A Method for Calculating the Spatial Electrical Vectors of the Heart from Conventional Leads

By Robert P. Grant, M.D.

A new method for the interpretation of conventional electrocardiographic leads is presented. It is based upon evidence that all body surface leads tend to record from the same resultant electrical forces. The various leads write different QRS and T contours in a given case, then, simply because the axis for each of the leads has a different direction in the electrical field and therefore registers different components of these electrical forces. The method has many advantages over "pattern" methods of interpretation. To illustrate its use, a study of QRS vectors is presented with special reference to the $S_1S_2S_3$ pattern.

FOR MANY YEARS it has been recognized that the QRS and T deflections on each of the standard limb leads can be considered to be written by the same central QRS and T electrical forces. Recently it has been shown that the deflections in precordial leads are, in many regards, written by exactly the same forces that are responsible for the limb lead deflections.[1] This has led to the development of a method for interpreting the ventricular electrocardiogram (ECG) by resolving the QRS and T deflections on the various limb and precordial leads into two electrical forces, a mean QRS force and a mean T force.

The clinical interpretation can, to a large extent, be based upon the magnitudes and directions of these two mean forces, and, as will be seen, this is a more accurate and objective method for interpretation than one based on "patterns." In addition, such a method greatly simplifies many aspects of the clinical electrocardiogram and provides a rational method for the study of the electrical factors responsible for the various QRS and T abnormalities which are encountered clinically. In the present paper, the method as adapted for routine interpreting of conventional leads will be described, and its validity discussed. In a second part of the paper, the application and usefulness of the method will be illustrated by considering the properties of QRS electrical forces in the human subject, with special reference to the forces responsible for the so-called $S_1S_2S_3$ syndrome—tracings with conspicuous S waves in all three standard limb leads. In later papers, the spatial forces responsible for T-wave abnormalities and the altered QRS forces in myocardial infarction will be described.

From the Departments of Medicine and Physiology, Emory University Medical School and the Grady Memorial Hospital, Atlanta, Georgia.

Aided by a grant from the Life Insurance Medical Research Fund.

I. The Method and its Validity

The principles on which spatial vector electrocardiography are based are largely the contribution of Wilson and his colleagues,[2] and the method to be presented in this paper is a relatively simple extension of vector methods first used by Einthoven and later developed by Wilson,[3] Bayley,[4] and others.[5] Theoretic aspects of spatial forces as applied to human electrocardiography have been discussed elsewhere,[1] and the present paper will present the method in as brief and nontechnical terms as possible. This necessarily requires omissions, simplifications, and generalizations. The reader is referred to the bibliography for more comprehensive and accurate treatment of the subject.

Spatial Vectors

The galvanometer is a measuring instrument, and the amplitude of an electrocardiographic deflection is an extremely precise meas-

Downloaded from http://ahajournals.org by on October 23, 2024

iRhythm, Inc. / Welch Allyn, Inc.
Exhibit 1020
Page 1

urement of electrical forces of the heart at that instant. To understand how to use a deflection as a measurement of an electrical force it is well to remember that any force, whether mechanical, chemical or electrical, has three measurable properties: magnitude, direction and sense. A mathematical symbol, the vector, may be used to indicate these three properties. A vector resembles an arrow; its length indicates the magnitude of the force, its inclination indicates the direction of the force, and the location of the arrowhead indicates the sense or orientation of electrical positivity for that force. Accordingly, an accurate way of looking at the electrical field of the heart is to consider the heart as generating QRS and T vectors at each region of the ventricular myocardium (fig. 1*A*). The deviation of the galvanometric string from the baseline is a measurement of the projection of the vector, or the extent to which it impinges on the axis of the given lead. The axis of a bipolar lead is the hypothetic line connecting the two points on the surface of the body where the electrodes are placed for the lead; the axis of a unipolar V lead is the hypothetic line from the point on the body surface where the exploring electrode is placed to the relative zero point of the electrical field, a point near the center of the heart.

Although each part of the heart can be considered to be generating its own QRS and T vectors, the galvanometer responds to the sum effect of all vectors generated at a given instant. Accordingly, as far as the electrocardiogram is concerned, a single resultant vector can be considered to exist for each instant of the QRS and T cycles (fig. 1*B*). The changing contour of the QRS deflection on a given lead simply reflects the fact that the resultant QRS vector has a different direction and magnitude from one instant to another during the QRS cycle. When a positive deflection or R wave is written in a given lead, this means that the resultant QRS vector for that interval of the QRS cycle is pointing relatively toward the positive electrode of that lead, and the amplitude of the R wave measures the extent to which the force impinges on the axis of the lead, that is, it measures the projection of the vector on that lead. If the R wave is followed by an S wave, this means that during the remainder of the QRS cycle the instantaneous vectors point relatively toward the negative pole of that lead, and the amplitude of the S wave measures the projections of these vectors on the axis of the lead.

The explanation for this variation in the QRS vectors from instant to instant during a single QRS cycle is that, while the vectors are generally directed from endocardium to epicardium, all parts of the ventricular myocardium do not generate QRS vectors simultaneously. The QRS process spreads from one region of the ventricles to another in accordance with the distribution of the Purkinje network, and therefore vectors from different regions of the heart dominate the electrical field at different intervals in the QRS cycle. Of course, the galvanometer does not record these anatomic differences, and it treats the vectors as if they all arose from the same point in the body (fig. 1*C*). Accordingly, for electrocardiographic purposes, all the vectors can be considered to originate from a single point at the center or zero point of the electrical field.

Because the instantaneous QRS vector is different in direction and magnitude from instant to instant during a QRS cycle, its end describes an irregular ellipse around the zero point during such a cycle. This ellipse is called the QRS vectorcardiogram or QRS loop (fig. 1*D*). The resultant of all these instantaneous QRS vectors, that is, the single vector which expresses an effective single magnitude and direction for all of these instantaneous QRS vectors, is called the mean QRS vector, and is in general the same measurement as Einthoven's Mean Electrical Axis. The electrical forces generated during repolarization can be treated as instantaneous T vectors, as an S-T-T loop, or as a mean T vector in the same way.

The heart is a three-dimensional structure and the instantaneous and mean QRS and T vectors may have any direction in space. Accordingly, the electrical forces of the heart are more accurately represented by spatial vectors, that is, vectors visualized three-dimensionally. The limb leads, whether unipolar or bipolar, form axes which lie in the frontal plane of the body, and their deflections are measurements

Downloaded from http://ahajournals.org by on October 23, 2024

iRhythm, Inc. / Welch Allyn, Inc.
Exhibit 1020
Page 2

of only the frontal plane projection of the spatial vectors. Actually, unipolar and bipolar limb leads record from exactly the same frontal plane vectors, for the body surface connections are the same for each. The QRS and T deflections are different in the various unipolar and bipolar limb leads only because the axis for each of the leads has a different direction in the frontal plane, as shown in figure 1*E*. The precordial leads, on the other hand, measure the spatial vectors in various anterior-posterior directions. When these leads are re-

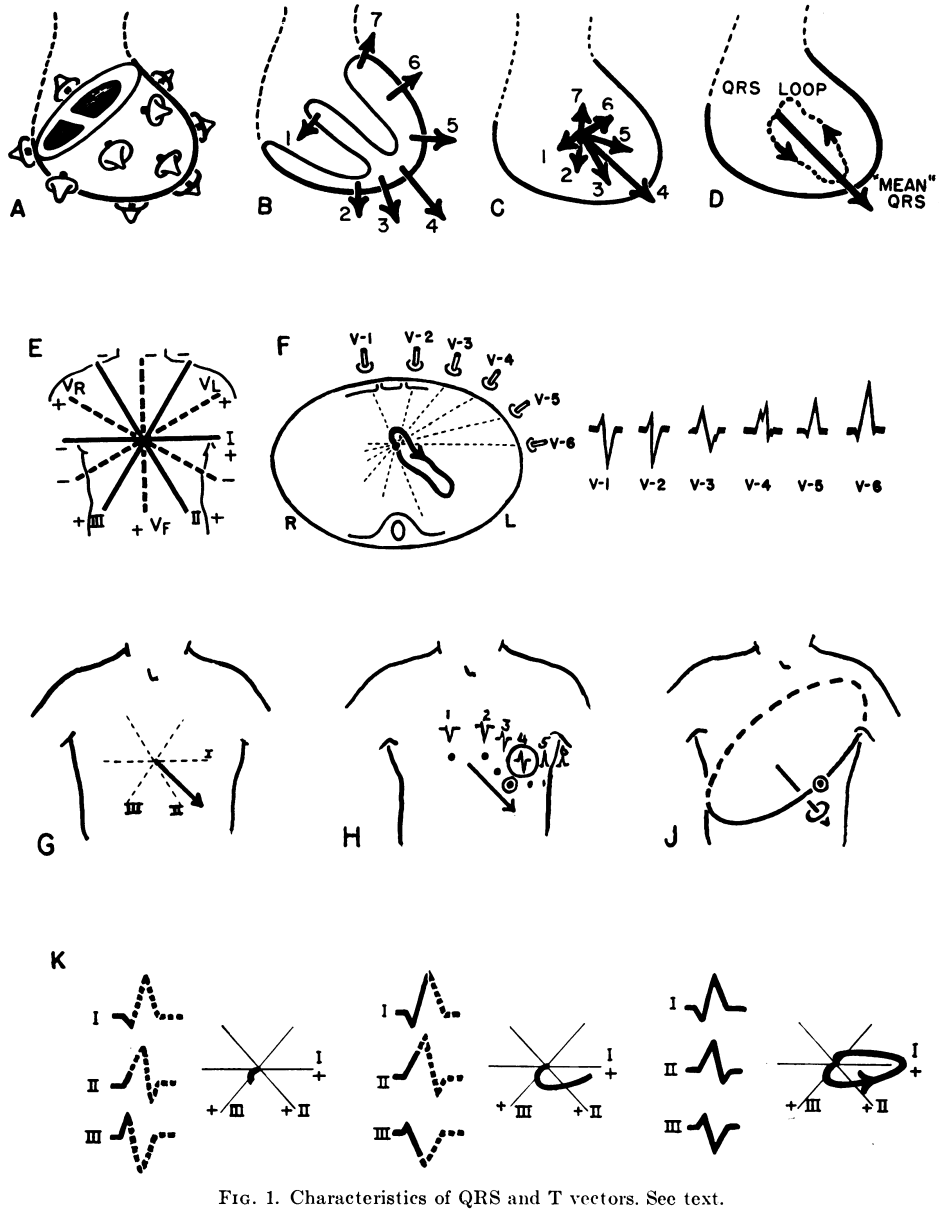

FIG. 1. Characteristics of QRS and T vectors. See text.

Downloaded from http://ahajournals.org by on October 23, 2024

iRhythm, Inc. / Welch Allyn, Inc.
Exhibit 1020
Page 3

corded by V-lead methods, the axes approximate lines from the position on the chest surface where the recording electrode is placed to the center of the heart. In general, then the QRS and T deflections written by the conventional precordial V leads are measurements of projections of the spatial vectors on six axes which lie roughly in the coronal plane of the body (fig. 2*E*).

Although both precordial and limb leads are recording from the same spatial vectors, the precordial leads are nearer the center of the electrical field, and therefore a given unit of electrical force will produce a bigger deflection in a precordial lead than in a limb lead. For this reason, the magnitudes of precordial and limb lead deflections cannot be used together to determine the absolute magnitude of the spatial vectors. However, the positivity or negativity of a precordial or limb lead deflection reflects the general direction of the vector; that is, it indicates whether the vector is pointing toward or away from the recording electrode. For example, when a given precordial QRS deflection as a whole is positive, that is, when it encloses more area under its upright portions that under its inverted portions, the mean spatial QRS vector must be directed relatively *toward* that precordial electrode position. When the deflection is resultantly negative, the mean spatial QRS vector must be pointing *away* from the electrode. When the deflection is transitional, the responsible mean vector must be directed exactly perpendicularly to the axis of the lead.

Accordingly, precordial and limb leads can be used together to determine the directions in space of the various instantaneous and mean vectors. Once the direction of a vector is known, it is quite easy to estimate its relative magnitude from the conventional leads, as will be shown. However, it is not often necessary to measure the magnitude of a vector because this is not nearly so useful clinically as its direction. The reason for this is that a heart disease which is accompanied by significant electrocardiographic abnormalities is nearly always asymmetric in its involvement, that is, it affects one region or portion of the heart more than another. Therefore, the QRS or T process or both are affected asymmetrically in these cases, and the resultant directions of the vector or vectors are changed, with or without a change in magnitude.

To determine the direction of a mean spatial vector, then, first its direction in the frontal plane of the body is determined. This is done on a drawing of the frontal plane triaxial system simply by deciding which limb lead has recorded the conspicuously largest or smallest resultant QRS deflection. The vector is parallel with the axis of the lead with the largest deflection, or perpendicular to the axis of the lead with the smallest or, for a mean vector, the transitional deflection. Precise calculation of the deflections is not necessary, for it is usually immediately evident which lead has the largest or smallest deflection, keeping in mind the fact that the resultant enclosed area of the deflection, that is, the area under negative portions of the deflection subtracted from the area under positive portions, must be the basis for this comparison. When the triaxial reference figure, its polarity, and its position in the body are clearly in mind, one can determine the directions of the mean QRS and T vectors in the frontal plane of the body within 5 degree error from simple inspection of the leads by this method.

Then, to determine how far anteriorly or posteriorly from its frontal plane projection the spatial vector is directed, one turns to the precordial leads. As was shown, the mean spatial QRS vector will be perpendicular to the precordial lead which records the transitional QRS complex. Accordingly, having drawn the direction of the mean QRS vector as seen in the frontal plane, the spatial QRS vector must have a direction anteriorly or posteriorly from this projection so that it is perpendicular to the axis of the precordial electrode which recorded the transitional complex.

This is easier to visualize if the chest is drawn three-dimensionally from the frontal view. The triaxial system is lightly drawn on the figure and the mean QRS vector as calculated for the frontal plane is added (fig. 1*G*). Then, the locations of the six precordial electrode positions are drawn on the figure, and the one which recorded the transitional QRS

Downloaded from http://ahajournals.org by on October 23, 2024

iRhythm, Inc. / Welch Allyn, Inc.
Exhibit 1020
Page 4

complex is identified (fig. 1*H*). Obviously, this electrode position must lie on a line or pathway of electrode positions around the chest, all of whose axes are perpendicular to the spatial vector. This line is called the "transitional pathway" for that vector, and can be described as the line on the surface of the chest where a plane perpendicular to the spatial vector at its origin would intersect the surface of the chest. When the frontal plane projection of the vector is drawn on the figure and the location of the V lead with the transitional complex is identified, it is a simple matter to draw the entire transitional pathway for the vector around the chest, for it must pass through this precordial electrode position. This makes the direction of the mean spatial QRS vector more graphic, looking as if it were mounted on a disc (fig. 1*J*). All electrode positions on one side of the transitional pathway will write resultant positive deflections for that vector, and all electrode positions on the other side will write resultant negative deflections for that vector. By using these same principles, the directions of the mean spatial T and S-T vectors can also be determined from simple inspection of the leads.

To calculate the spatial QRS loop from conventional leads, exactly the same principles are used as in calculating the mean spatial vectors. First, the frontal plane characteristics of the loop are determined from the limb leads, and then the sagittal plane characteristics are determined from the precordial V leads. In drawing the frontal plane projection of the loop it has often been thought that simultaneously recorded limb leads were necessary. However, this is not so, provided several complexes on each lead are studied to equate variations due to shift of the heart in respiratory cycles, and provided one keeps in mind the physical law of network circuits called "Einthoven's Law" which states that the amplitude of a portion of a deflection on Lead I plus the amplitude of the same portion on Lead III is equal to its amplitude on Lead II. For example, if, in a given patient, there are initial downward deflections in the QRS complexes on Lead I, II and III, the Q wave on Lead II must be bigger than the Q wave on either of the other two leads. Since a given vector is parallel with the axis of the lead with the largest deflection, in this patient the instantaneous vectors for the first part of the QRS loop must be roughly parallel with the Lead II axis, pointing to the negative pole of that lead. Then, if the Q wave is conspicuously briefer in duration on one of these leads than the other two, the loop must next extend toward a point on the triaxial system which is perpendicular to the axis of that lead. Then, if the next part of the QRS complexes on these three leads is an R wave, the loop will now extend to a point on the axis of the lead with the largest R wave, as far out along this axis toward the positive pole as the amplitude of the R wave indicates, and so forth. The construction of a QRS loop from the bipolar leads is illustrated in fig. 1*K*. In this way the QRS loop in the frontal plane can be drawn with reasonable accuracy as far as its general contour is concerned. Short-cuts and modifications of this method for drawing the loop will occur to the reader as he experiments with it.

The standard limb leads provide deflections for three axes in the frontal plane and the frontal projection of the spatial loop can be calculated on these axes. When unipolar limb leads are taken in addition to the standard bipolar leads, the calculation of the frontal plane loop becomes more accurate, for now there are deflections for six axes in the frontal plane. When all six limb leads are available, it is usually simplest to draw the loop from one type of limb lead, and then modify it in accordance with the deflections from the other type of lead. With a little practice the general contour of the frontal plane loop becomes quite easy to draw in this way.

To calculate the spatial loop, that is, to determine the extent to which the instantaneous vectors at each part of the loop point anteriorly or posteriorly from their frontal plane projections, the QRS complexes of the precordial V leads are used. The QRS deflections at V_1 and V_2 may be used for certain of the sagittal plane characteristics of the loop. For example, if in a given case these deflections have an initial R wave followed by an S wave, the instantaneous vectors forming the first part of

Downloaded from http://ahajournals.org by on October 23, 2024

iRhythm, Inc. / Welch Allyn, Inc.
Exhibit 1020
Page 5

the frontal plane loop must also be directed anteriorly to the frontal plane of the body, and the vectors making up the remainder of the frontal plane loop must be posteriorly directed. To make more accurate sagittal plane spatial measurements of the loop, the precordial electrode position where a given part of the deflection is recorded as a zero or isoelectric component of the deflection is identified. The instantaneous vector for this part of the QRS loop must be perpendicular to the axis of that precordial lead. Accordingly, by finding the locations of transitional points on the chest for three or four parts of the QRS cycle, the directions of three or four instantaneous spatial vectors can be determined, and from these the general contour of the loop in space can be established.

Still another way to determine the anteroposterior characteristics of the loop is to draw a coronal cross section of the chest. In a general way, the axes for all six precordial V leads lie in this plane (fig. 1*F*). Then, from the characteristics of the QRS complexes on each of the precordial leads, keeping the polarity of the leads in mind, the coronal projection of the loop can be drawn by following the same procedure that was described for plotting the frontal plane loop from the three limb leads. By plotting the loop on the frontal, sagittal and coronal planes, and confirming the findings by the transitional pathway method, the spatial loop or any portion of it can be calculated as accurately as body surface electrocardiographic methods are ever likely to allow.

The Validity and Usefulness of the Spatial Vector Method

There are, to be sure, limitations in the spatial vector method. Variations in chest size and contour from patient to patient make it impossible to be sure of the directions of precordial lead axes in a given case. Also, errors in precordial electrode placement will result in errors in calculations of the spatial vectors. However, these are sources of error in any method for interpretation which uses these particular precordial leads; they only become evident in the vector method because of the greater precision which such a method involves. The complexities of the generating processes of the heart, and the physical properties of the body as a conductor are still largely unknown; accordingly, any method for clinical electrocardiography which is based upon body surface derivations can give at best only a vague and general notion of the characteristics of the cardiac electrical forces, no matter how accurate the recording equipment or how rational or precise the calculating method.

How valid is this method for interpreting the electrocardiogram? How well does it satisfy current theory of the nature of the electrical processes of the heart and the conductive characteristics of the surrounding tissue? There has been general agreement among most workers for many years that limb lead deflections can be treated by vector methods. Indeed, "axis deviation" is a vector principle, for it is simply the direction of the mean QRS vector in the frontal plane. Precordial leads, on the other hand, have not previously been treated by vector methods because it was thought likely that, since precordial lead electrodes are nearer the heart than limb lead electrodes, they might be dominated by the potentials of the immediately subjacent surface of the myocardium and would not be recording as equally from the heart as a whole as do the limb leads. In short, they were thought to more closely resemble "direct" leads (leads taken by placing the electrode directly on the generating tissue and recording relatively exclusively the potentials generated immediately beneath the electrode) than "spatial" leads (leads remote enough to be recording relatively equally from all parts of the generating tissue).

Wilson and co-workers[2] who were the first to consider the spatial characteristics of these electrical forces and have done the most important work in this field, recognized that to treat precordial leads as "direct" or as "spatial" leads is largely a difference in interpretation, and, depending upon the purposes of the study, either interpretation might be valid. For example, in the criteria they introduced for determining the position of the electrical field of the heart in the chest, a resemblance is sought between the QRS deflection in certain precordial leads and the QRS deflections in one or

Downloaded from http://ahajournals.org by on October 23, 2024

iRhythm, Inc. / Welch Allyn, Inc.
Exhibit 1020
Page 6

another unipolar limb lead; in this procedure both precordial and limb leads are treated as "spatial" leads. On the other hand, in explaining the QRS deformity of myocardial infarction, the precordial leads are said to lose their initial positive deflection because they "overlie" the infarcted region of the myocardium, which is now to treat these same leads as "direct" leads.

Strictly speaking there is no such thing as a perfect "direct" lead as far as the intact heart is concerned. Even when the electrode is placed directly on the surface of the heart it records potentials from remote regions of the heart as well as from the region with which it is in contact. When Lewis and Rothberger[6] introduced the direct lead method to study the time of arrival of the excitation process at the various regions of the heart, they concluded that only an extremely brief portion of the QRS deflection in a direct lead represents activation of the underlying myocardial tissue. This is the portion of the deflection where there is a sudden shift from relative positivity to negativity, recording the instant that excitation takes place in the tissue immediately beneath the electrode. This sudden change in the deflection is called the "intrinsic deflection." The portions of the deflection preceding and following the intrinsic deflection represent potentials from remoter parts of the heart and are called "extrinsic components."

In experimental animals and in human subjects in whom the heart has been surgically exposed, unipolar leads from the precordium have been shown to resemble leads taken directly from the surface of the heart. To be sure, they are not identical, and therefore the intrinsic deflection in the precordial lead has been called an intrinsicoid deflection. However, it is important to realize that this resemblance does not at all prove that precordial leads are more nearly "direct" leads than "spatial" leads. Indeed, no matter how remote on a radius from the heart a recording electrode is placed, it is probable that the deflection will always resemble in contour a "direct" lead deflection taken on the same radius from the heart. The reason for this is that, generally speaking, the vector at a given region of the heart is directed perpendicularly to the surface of the heart; therefore, the vector generated from a region of the heart which "faces" a given unipolar lead is parallel with the axis of that lead. It was shown earlier that when a vector is parallel with the axis of a lead it writes its largest deflection on that lead. Accordingly, the vector from the "facing" region of the heart will write the largest positive part of the QRS deflection no matter how near or how far from the heart the recording electrode lies. Similarly, the vectors responsible for the "extrinsic" components of the direct lead have the same directions relative to the axis of the given lead whether the electrode is directly on the heart or remote from it on the same radius. In short, the principle difference between a "direct" lead deflection and a "spatial" lead deflection when the two are recorded on the same radius from the heart lies in the amplitude of the intrinsic deflection. The over-all contour of the deflection will tend to be the same for the two electrode positions.

The controversy about whether precordial leads should be treated as "direct" leads or as "spatial" leads is therefore largely a controversy in terminology. The precordial lead is both; and whether one chooses to treat it as one or the other depends upon which point of view will more usefully serve the purposes of the study. In a spatial vector method of interpretation, leads from various regions of the body surface are treated simply as different perspectives in the measurement of the QRS and T electrical forces generated in the heart. Accordingly, leads taken from any region of the body surface—and leads taken from directly on the heart could be incorporated into the method if such leads were readily available in a given patient—can within certain limits be rationally treated as "spatial" leads for the purposes of this method of interpretation.

Experiments have been reported in which the QRS and T deflections in precordial leads were critically compared with the actual characteristics of the QRS and T electrical forces of the heart in order to see if the intrinsic deflections dominated the mean characteristics of these deflections.[1] It was found in eight carefully conducted experiments that the precordial

Downloaded from http://ahajournals.org by on October 23, 2024

iRhythm, Inc. / Welch Allyn, Inc.
Exhibit 1020
Page 7

leads were recording the mean characteristics of the QRS and T spatial forces with considerable accuracy. The method was then simplified so that this relationship of precordial leads to the electrical field of the heart could be studied in large numbers of subjects, and in over 1000 consecutive clinical electrocardiograms no significant discrepancies were encountered.

There is one other factor which is relevant in evaluating the validity of vector methods when applied to the human subject. If one accepts the theory that the electrocardiogram is, in effect, a record of fluctuating potentials generated from a dipole near the center of a volume conductor, it is a physical and mathematical fact that the simplest and most elementary of all methods for studying these potentials would be a spatial vector method. In such a method no concessions would be made for the possibility of variations in conductivity in various regions of the body, the eccentric anatomic position of the heart would be disregarded, and no allowances would be made for the disparity in the electrical remoteness of the various lead electrodes. It was found in the experiments cited and in a subsequent experience with over 4000 consecutive clinical electrocardiograms in which the spatial vector method of interpretation has been used, that infrequently were there discrepancies or inconsistencies which could not be attributed to technical errors in electrode placement or to unusual problems in chest contour or heart position. It seems likely therefore, that, although there most certainly are measurable differences in tissue conductivity in various regions of the body and incongruities in the geometric figure which the electrical field of the heart represents, these variables are not great enough to interfere with the validity of a simple spatial vector method.

If the assumptions on which the spatial vector method is based are correct, its use in clinical electrocardiography has several advantages over empiric "pattern" methods, whether the vector method is used to supplement conventional methods or is used alone.

(1) All possible variations and abnormalities of QRS and T deflection contours on all possible body surface leads are due simply to one or another variation in the direction of mean or instantaneous spatial vectors. Thus, the vast number of different "patterns" which may be encountered in the various leads for different types and degrees of electrocardiographic abnormality can be reduced to just two variables: the direction of the mean spatial QRS vector and the direction of the mean spatial T vector.

Plotting the spatial QRS loop is often helpful in the analysis of the tracing, and this reduces the different QRS contours which may be encountered on the various leads to a single determination also. Thus, "pattern" memorizing, and the consulting of tables of the "normal ranges" for deflection size on the various leads becomes largely unnecessary.

(2) When the directions of the mean spatial QRS and T vectors and the contour of the spatial QRS loop are known for a given patient, the QRS and T contours for leads from any region of the body surface can be predicted. The reason for this is that any additional body surface lead merely represents another axis through a known electrical field. If the direction of the axis is known, it is easy to predict the deflection which a given QRS loop or mean T vector would write on that lead. This has been tested experimentally and has been found to be true. Accordingly, spatial vector methods for interpretation tend to eliminate the need for additional leads and leads from unusual regions of the body.

II. Spatial QRS Vectors

1. *Material and Methods of Study*

To illustrate the usefulness of the spatial vector method for routine clinical electrocardiography and to demonstrate the type of information it gives, the QRS vectors in the normal subject will be discussed and an analysis of the vectors in the $S_1S_2S_3$ syndrome presented. The material on which this study is based was obtained from 3000 consecutive clinical electrocardiograms in the files of the Grady Memorial Hospital. Eighty tracings in this group had conspicuous S waves on each of the standard limb leads and represent the $S_1S_2S_3$ cases. The remaining tracings represent a control expe-

Downloaded from http://ahajournals.org by on October 23, 2024

iRhythm, Inc. / Welch Allyn, Inc.
Exhibit 1020
Page 8

rience with many different types of normal and abnormal electrocardiograms.

In each case, in addition to the three standard limb leads, conventional precordial leads (V_1 to V_6) were recorded. In about half of the subjects unipolar extermity leads of the Wilson type were available, and, in several subjects, the "spatial" lead described elsewhere had been taken.[1] A few subjects were also studied by frontal and sagittal plane oscilloscopic vectorcardiographic methods.

For each subject the mean spatial QRS and T vectors and the spatial ventricular gradient were determined. In the illustrations, the frontal plane characteristics of the vectors are drawn on the standard limb lead triaxial system. The spatial directions of the mean vectors are shown by adding an appropriate three-dimensional perspective to the frontal plane drawing. The spatial directions of the QRS loop are shown by drawing the frontal, sagittal and coronal projections of the loop. As will be shown, there are advantages in considering certain parts of the QRS loop independently. For this purpose a mean spatial vector for each .04 second of the loop is identified, the .04 and .08 vector in the illustrations. In cases with a QRS interval over .10 second, .12 and .16 vectors are added to the illustrations.

In each case, the directions of the various QRS forces were identified and the forces responsible for the terminal portions of the deflections compared with the directions of earlier forces. In addition, to evaluate the extent to which excitation processes were normal, the directions of the mean spatial T vector and the spatial ventricular gradient were established in each case. These data were then interpreted in the light of the size, function and anatomic position of the heart, and the body build of the subject as described in the clinical record.

The method for calculating the instantaneous and mean QRS vectors has already been described. Calculating the direction of the spatial ventricular gradient is a simple extension of this method, for the gradient is the vector sum of the mean spatial QRS and T vectors. However, in order to add two vectors their magnitudes must be known as well as their directions. To determine these, the resultant enclosed areas of the QRS and T deflections are compared on each of the various leads. Then, when the frontal plane directions of the mean vectors have been plotted on the triaxial system, they are given magnitudes relative to one another which correspond with the relative magnitudes of the deflections. For example, if after determining the directions of the mean QRS and T vectors in the frontal plane in a given subject, the T waves on the limb leads are noted to tend to enclose about twice as much resultant area as the QRS complexes, the T vector is made twice as long as the QRS vector on the triaxial system. Then to determine the magnitudes of the vectors in space, the same type of comparison of QRS and T deflections is done from the precordial leads, indicating the magnitudes of the two vectors relative to one another in the anterior-posterior plane.

To add two vectors, they are treated as adjacent sides of a parallelogram, the parallelogram is completed, and the diagonal of the parallelogram is the sum of the two vectors. Accordingly, having visualized the spatial magnitudes and directions of mean QRS and T vectors, one needs merely to visualize the parallelogram they form, and the diagonal of this figure indicates the general direction of the ventricular gradient in the given case.

2. *Characteristics of Spatial QRS Vectors*

From a spatial vector point of view, three types of QRS abnormality are recognized clinically. (a) When a region of ventricular myocardium is electrically inert or dead, the instantaneous vectors for the first .03 to .04 second of the spatial QRS loop are caused to have abnormal directions, while the remainder of the loop may remain normal. This is characteristically seen in myocardial infarction. The abnormally directed vectors point away from the infarcted region of the heart. Since this is usually the left ventricle, the initial QRS vectors generally point toward the negative poles on the triaxial system, accounting for the "Q waves" recorded in one lead or another in this disorder.

(b) Abnormalities in the magnitude and direction of the mean spatial QRS vector are seen when one or the other ventricle is hyper-

Downloaded from http://ahajournals.org by on October 23, 2024

iRhythm, Inc. / Welch Allyn, Inc.
Exhibit 1020
Page 9

trophied or enlarged. The reason for this is that enlargement causes the QRS vectors from that ventricle to be larger than normal and to dominate the QRS electrical field. Accordingly, when the direction of the mean spatial QRS vector is determined in such a case, it will point toward the affected ventricle, wherever in the chest it may lie.

(c) Abnormalities in timing of QRS vectors without abnormalities in the forces themselves occur when one or the other bundle branch is blocked. The QRS interval is prolonged with terminal vectors of the QRS loop generated from the blocked ventricle in such a case. Accordingly, to determine which bundle branch is blocked one need merely evaluate the direction of the terminal vectors of the spatial loop, and they will point in the general direction of the blocked ventricle, wherever in the chest it may lie.

In the average normal subject, the QRS loop is relatively narrow and elongate. Its direction in the body varies with the age and body build of the subject.

In adolescence and in young adulthood the QRS loop has a relatively more vertical position, and in the average healthy subject of 20 years of age it is directed 70 to 95 degrees vertically from the Lead I axis, that is, nearly perpendicular to Lead I. Beyond this age it begins to drift leftward. By 35 years, it is often about 45 degrees from Lead I, and in the elderly subject it is frequently parallel with this lead. In the sagittal view in all age groups the loop tends to be directed somewhat posteriorly to the frontal plane. In young people, this posterior direction may be only 10 to 15 degrees; in older subjects it is frequently as much as 45 to 50 degrees.

These variations in direction of the spatial loop and the mean spatial QRS vector are perhaps partly due to an actual anatomic rotation of the heart as the years pass. However, probably of greater importance are the variations in the relative thickness and surface area of the two ventricles in these age groups, the right ventricle relatively dominating the QRS electrical field in infancy, to a less extent in adolescence, and the left ventricle dominating the electrical field in older age groups. In the obese subject regardless of his age the loop tends to be relatively horizontal in direction, while in the thin subject it is usually quite vertical.

Regarding the exact contour of the loop in normal subjects, vectorcardiographic recordings show that it is actually a relatively tortuous structure with many irregularities and twists in its pathway around the triaxial figure. These irregularities represent minor variations in the directions of successive instantaneous QRS vectors and are often too small to be detected in conventional linear electrocardiographic deflections. Whether they are of clinical significance or not must await further experience with oscilloscopic recordings of the loop.

There are both theoretic and practical reasons for dividing the spatial QRS loop into two portions of .04 second each and assigning a mean vector to each, a spatial .04 and a spatial .08 vector. For example, it is well established that the vectors during the first .04 second of the QRS cycle are principally the result of depolarization of the endocardial surface of the two ventricles, for this is believed to be the length of time it takes an impulse to spread throughout the Purkinje network to the inner layers of myocardium. Accordingly, the directions of the instantaneous vectors during the first .04 second of the loop tend to reflect the sequence in which the various regions of the endocardium receive Purkinje stimulation. On the other hand, the vectors during the last .04 second of the QRS cycle are due to depolarization of more epicardial layers. Since conduction is much slower across the myocardial wall than it is along the Purkinje network, the sequence in which the various regions of epicardium generate their QRS vectors is likely to be different from the endocardial sequence, and will vary to a certain extent with the thickness of the myocardial wall at each region of the heart. In other words, in general, the vectors during the first .04 second of the loop come from a different part of the heart, follow a different sequence, and are subject to different variables from the vectors during the last .04 second of the loop.

There is indirect evidence that the very first vector of the QRS cycle in the normal subject is generated from the left side of the inter-

Downloaded from http://ahajournals.org by on October 23, 2024

iRhythm, Inc. / Welch Allyn, Inc.
Exhibit 1020
Page 10

ventricular septum. The concept of a "septal Q wave" is based upon this evidence, most workers assuming that the force is somewhat perpendicular to the septum in direction. Actually, however, the vector characteristics of this force in the human subject are entirely unknown. The duration of the period of principally septal excitation is not known, and therefore it is difficult to decide how much of the initial part of the QRS loop to attribute to it. In a few subjects free of heart disease, measurements of the spatial .04 vector were made by the tetrahedral method shortly before death and its direction compared with the lay of the septum at postmortem examination. It was found in these cases that the .04 vector was more nearly parallel with the long axis of the septum than perpendicular to it.

It should also be pointed out that even if the direction of the septal vector were known, the empiric recognition of a "Q wave" on one or another lead does not necessarily indicate the location of the septum in that subject. The reason for this is that, in a volume conductor like the human body, a given vector projects an area of relative negativity on one half of the body surface, and an area of resultant positivity on the other half. Therefore a Q wave might be recorded from the septal vector when the electrode is placed at any point on nearly half of the entire chest surface. For this reason, a Q wave or any other deflection on a single lead sheds little light on the direction of the responsible vector. Furthermore, the duration of the Q wave must be taken into consideration before attributing it to a given vector from a specific anatomic region of the heart. Thus a Q wave of .02 second on a given lead is due to a resultant vector differently directed from that writing a Q wave of .04 second in another lead. These considerations of the interpretation of "septal Q waves" apply also to the anatomic interpretation of "Q waves" in myocardial infarction.

From a clinical point of view, the spatial .04 vector is likely to be altered in direction when there is a localized disturbance of endocardial depolarization such as might occur with a disorder of the Purkinje network or with death of a region of endocardial myocardium. This latter appears to be the cause of the abnormally directed .04 vector in myocardial infarction. If the infarct should be transmural, one might expect the .08 vector also to be altered in direction. This is not often seen, however, perhaps in part because a given sized transmural infarct will involve a relatively smaller portion of epicardial than endocardial area.

An understanding of the factors governing the direction of the .04 vector is extremely important in clinical electrocardiography for the only difference between the normal subject and the subject with a myocardial infarction, as far as the QRS forces are concerned, is the direction of the vector for the first .04 second of the loop. In the normal subject it tends to be parallel with the mean spatial QRS vector. In the subject with an infarct it tends to point away from the location of the infarct and since infarcts occur nearly always in the left ventricle, it will tend to point away from one or another region of the left ventricle. It can be readily imagined that with unusual positions of the heart in the chest, with variations in the magnitude of the putative septal force, or with unusual locations of the infarct, the normal subject and the subject with an infarct might have "Q waves" recorded at very nearly identical locations on the body surface. It is only by learning more about the factors contributing to the direction of this .04 vector in the normal and abnormal subject that the electrocardiographic diagnosis of myocardial infarction from the QRS complex will come to have a rational and secure foundation. These aspects of the .04 vector will be discussed in greater detail in a later paper concerned with the spatial QRS forces in myocardial infarction.

As far as the spatial .08 vector is concerned, it is the resultant of vectors from the more epicardial regions of the heart. In the majority of normal subjects, it points posteriorly and leftward, as if a region on the posterior surface of the left ventricle were either the last epicardial region to be depolarized or generated the largest potential for this interval. On the other hand, in certain children and young adults who are otherwise altogether normal, a terminal contribution from a superior part of the

Downloaded from http://ahajournals.org by on October 23, 2024

iRhythm, Inc. / Welch Allyn, Inc.
Exhibit 1020
Page 11

right ventricle appears to be present and may occasionally be quite large in magnitude. This will be further discussed in connection with the $S_1S_2S_3$ cases.

Abnormalities in the direction of the spatial .08 vector will be seen when either a region of ventricular wall is increased in thickness, or there is a defect in the conduction system. In the former case, the terminal vector will tend to point toward the thickened or hypertrophied region, and in the latter case it will point toward the blocked region. Of course, when the hypertrophy is marked or when the bundle block is complete, there will be prolongation of the QRS interval, and it will be the .12 or .16 vector which points toward the abnormality.

In the majority of normal subjects the spatial .04 and .08 vectors are relatively parallel to one another, reflecting the elongate contour of the QRS loop. They have relatively the same direction as the mean spatial QRS vector, and the ventricular gradient is usually not more than 30 degrees from this direction. In addition, the spatial .04 and .08 vectors have characteristic directions relative to one another in various age groups and various heart positions. When the heart is vertical in position as in young adult subjects, the mean QRS vector is relatively perpendicular to the Lead I axis, and the .04 vector usually lies to the left of and anteriorly to the .08 vector. In older subjects with a more horizontal position of the heart, the mean spatial QRS vector is relatively parallel with the Lead I axis, and the .04 vector usually lies to the right of and anterior to the .08 vector. These variations in the directions of the .04 and .08 vectors relative to one another are no doubt due to the dynamic and anatomic changes which take place in the relationship of the right to left ventricle in the various age groups. There are, however, many individual variations in this pattern and precise studies of this relationship have not yet been performed.

It is well to remember that both the .04 and .08 vectors are resultant vectors. That is, their directions are the average for all the instantaneous vectors generated during these relatively gross periods of the QRS cycle. Accordingly, in only the most general way do they reflect excitation at discrete anatomic sites in the heart.

3. *The Spatial QRS Forces in the $S_1S_2S_3$ Syndrome*

At the outset it must be pointed out that to catalog tracings according to the presence or absence of certain contours in the QRS complex on each of the standard limb leads is extremely arbitrary. A difference of only a few degrees in the direction of an instantaneous QRS vector will change it from writing an R wave on a given lead to writing an S wave on that lead. For example, if, in a given patient, the .08 vector should be directed cephalad and perpendicular to the axis of Lead I, the QRS complex on Lead I will have an isoelectric portion for the last .04 second of the deflection, while Leads II and III will have terminal S waves. Should, now, this vector be directed only a few degrees leftward of this position, Lead I will have an R wave terminally; on the other hand, if it should shift only a few degrees rightward of its original direction, it will write a terminal S wave on this lead. In the former instance the tracing would be cataloged as an $R_1S_2S_3$ tracing and in the latter instance, as an $S_1S_2S_3$ tracing.

In order for an S wave to appear on all three limb leads, the .08 vector must point somewhere in an arc of 60 degrees toward the right shoulder. Obviously the factors which produce an $S_1S_2S_3$ tracing in one patient may produce an $S_1S_2R_3$ or $R_1S_2S_3$ tracing in other subjects because of minor factors such as differences in body build or in the position of the heart in the chest.

The arbitrariness of cataloging tracings according to the contours of the QRS deflections on certain leads becomes even more obvious when the electrical field is considered spatially. Thus, if a given QRS loop should be directed markedly posteriorly, it will write limb lead deflections which are quite different in contour from those written when the same loop is flush with the frontal plane. This is the limitation of attempting to tabulate the characteristics of QRS and T deflections in individual leads such as the precordial V leads, for, in these tabulations of "normal ranges," the charac-

Downloaded from http://ahajournals.org by on October 23, 2024

iRhythm, Inc. / Welch Allyn, Inc.
Exhibit 1020
Page 12

teristics of the electrical field in other planes of the body are disregarded.

For convenience of discussion, the $S_1S_2S_3$ cases are divided into three groups. Group I are those cases with QRS intervals of .12 second or less; group II are those cases with a QRS interval of .12 to .14 second, and group III are those with a QRS interval over .14 second.

Of the 80 cases, 59 belonged to group I. In nearly all of the cases in this group, the S waves were due to forces which in the frontal plane were directed toward the right side of the neck or right shoulder. In the sagittal plane, there was considerably greater variation in direction of the .08 vector. In 4 cases it was directed slightly anteriorly to the frontal plane, in 24 cases it was directed nearly completely posteriorly, and in the remaining cases it was directed somewhere between these two extremes. In the cases with an anteriorly directed .08 vector, the .04 vector tended also to be more anteriorly directed than usual, and in those with a posteriorly directed .08 vector, the .04 vector tended to be more posteriorly directed. In other words, those cases with an anteriorly directed .08 vector tended to have a fat, reniform QRS loop (fig. 2, tracing 1) and those with a more posteriorly directed .08 vector tended to have a more elongate loop, approaching that of the normal subject (fig. 2, tracing 5). From a clinical point of view, the impression was gained that this group of $S_1S_2S_3$ tracings was more commonly encountered among young subjects. However, the series was inadequately controlled to permit definite conclusions in this regard.

From these electrical findings it was evident that in group I there tended to be an orderly transition in $S_1S_2S_3$ cases from those with a rightward and anteriorly directed .08 vector, through those in whom the .08 vector was nearly completely posteriorly directed, to the normal subject in whom the .08 vector was leftward in the frontal plane and just slightly posterior to the .04 vector. This transition is illustrated in figure 2. Tracing 1 is an example of an anteriorly directed .08 vector; tracings 2 through 5 illustrate greater and greater degrees of posterior direction of the .08 vector, and tracing 6 illustrates a nearly normal relationship between the .04 and .08 vector.

The tracings used in this figure were selected for their QRS properties alone. In some, the ventricular gradient is abnormal, and these were from subjects with organic heart disease. Others were from subjects with no electrocardiographic or clinical evidence of heart disease. In the group as a whole there was no consistent relationship with any particular type of heart disease. Indeed, the majority of subjects of this group had no heart disease, and it can therefore be concluded that an $S_1S_2S_3$ tracing with a QRS interval of .12 second or less is not necessarily indicative of the presence of organic heart disease.

What is the cause of the abnormally directed .08 vector in these cases? The likeliest explanation is that, in a given subject, either a region in the right ventricle or a region on the posterior surface of the left ventricle may be the last site of epicardial depolarization. In the vast majority of normal subjects, the left ventricular site is the last region of the heart to be depolarized and in these cases, the .08 vector is leftward, posterior and inferior in direction, resembling tracing 6 in figure 2. In an extremely small number of subjects, the right ventricular site is the last region to be depolarized, and these are the instances with a rightward, superior and anterior .08 vector, as in tracing 1. In a considerably larger number of subjects than this latter group, but representing perhaps only 5 per cent of normal subjects, both sites are generating terminal forces and the .08 vector has a direction intermediary between the two extremes.

It has long been appreciated that a region on the posterior surface of the left ventricle is usually the last epicardial region of the heart to be depolarized. It should not be unexpected, however, that occasionally some other region may be the last site of depolarization in otherwise normal subjects. Depending upon the thickness of ventricular wall at one or another region, and depending upon congenital variations in distribution of conduction tissue among different subjects, some other site might be later than this in undergoing depolarization or

Downloaded from http://ahajournals.org by on October 23, 2024

iRhythm, Inc. / Welch Allyn, Inc.
Exhibit 1020
Page 13

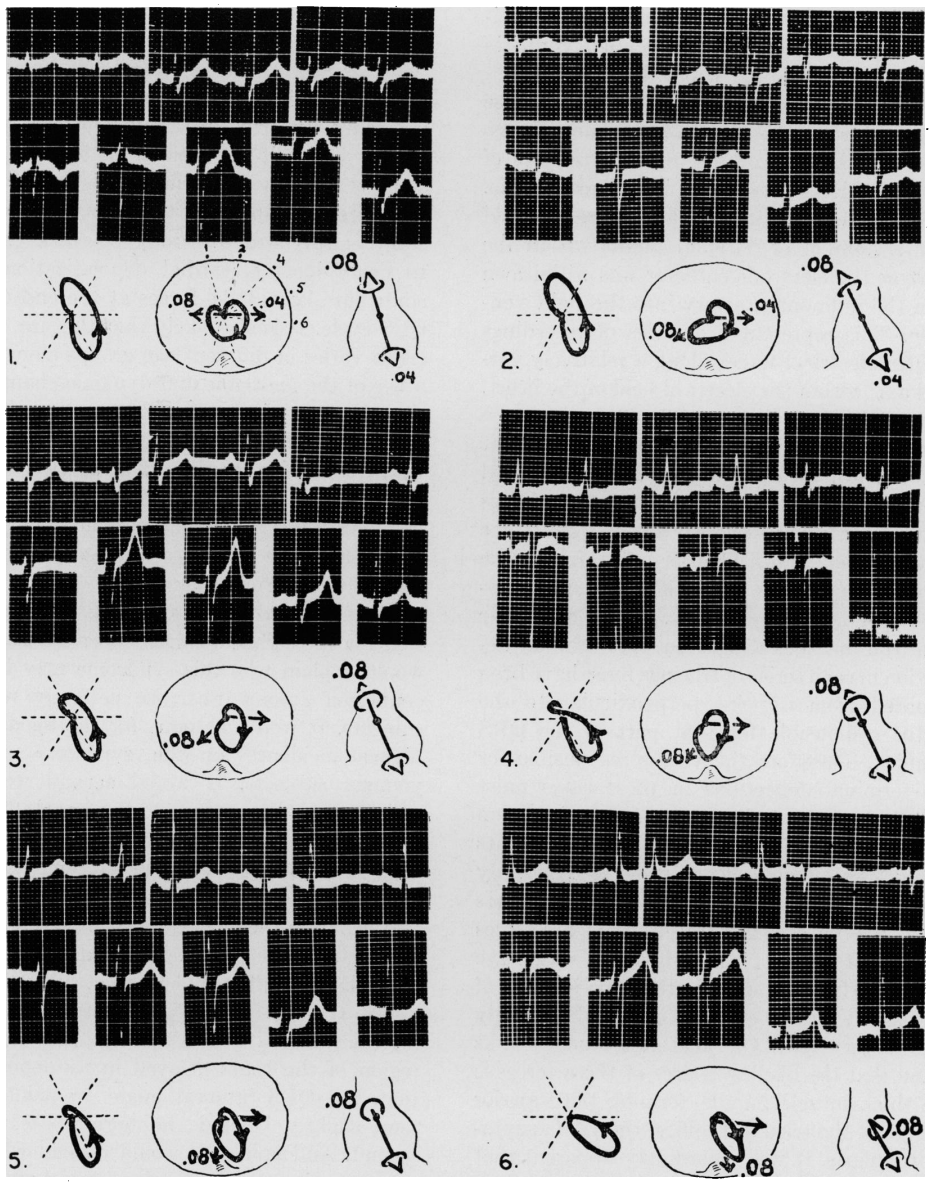

FIG. 2. Five cases of S_1 S_2 S_3 pattern illustrating varying degrees of posterior direction of the .08 vector, and one case, tracing 6, which approaches the normal in the direction of its .08 vector. The standard limb leads, V_1, V_2, V_3, V_4, and V_6 precordial leads, frontal and coronal planes projections of the QRS loop, and the spatial directions of the .04 and .08 vectors are shown.

contribute a vector of larger magnitude. However, when an anatomic site in the right ventricle is sought where an .08 vector with this particular direction might be generated, considerable difficulty is encountered. The vector points rightward, superiorly and slightly an-

Downloaded from http://ahajournals.org by on October 23, 2024

iRhythm, Inc. / Welch Allyn, Inc.
Exhibit 1020
Page 14

teriorly, and it is difficult to envision an epicardial surface of either right or left ventricle which faces in this particular direction.

The explanation for the .08 vector in these $S_1S_2S_3$ cases was therefore obscure until Kossmann and his co-workers[7] reported studies of terminal QRS forces, using intracardiac leads. In these studies, QRS complexes were recorded from a number of different points within the heart as the electrode-catheter was withdrawn from the pulmonary artery into the right ventricle. This represented a series of recordings of QRS electrical forces along a relatively vertical axis within the electrical field of the heart. Then, QRS complexes were recorded as the electrode was withdrawn through the right ventricle into the right atrium. This represented another series of recordings of the same forces along a vertical axis slightly to the right of the previous one. Transitional or null forms of the terminal part of the QRS complex were identified in each of the two series. It should be clear from the previous discussion that the null deflection in each series of tracings must have been recorded from a point perpendicular to the vector responsible for that part of the QRS complex. Therefore the vector responsible for the terminal deflections in these cases must have been generated from an anatomic region in the plane which includes the two points where the null deflections were recorded. By this method, Kossmann and his co-workers found that in certain subjects there are forces in the last third of the QRS cycle which are generated from a region in the superior part of the right ventricle and are directed superiorly and to the right. On anatomic study it was found that the likeliest source of these forces is the thick muscle bundle forming the superior margin of the tricuspid orifice, the crista supraventricularis. It was accordingly apparent that in some subjects this region of the heart plays an effective role in the generating vectors during the last third of the QRS cycle This study did not relate this finding to the $S_1S_2S_3$ syndrome. Nevertheless, the direction of the force in the study by Kossmann and associates and the direction of the .08 vector in $S_1S_2S_3$ subjects is strikingly similar.

That the crista supraventricularis might occasionally be a late site of depolarization seems likely insofar as it may show considerable variation in size from subject to subject. For example, in congenital heart disease it is occasionally markedly hypertrophied, and in the tetralogy of Fallot it contributes to the pulmonic stenosis of this syndrome. It is conceivable therefore, that among certain otherwise normal subjects this structure may be thick enough to delay local epicardial depolarization and contribute large QRS forces at the end of the QRS cycle. It is also likely that the size of the crista varies in different age groups along with other of the anatomic and dynamic changes in the two ventricles as age advances. It would be relatively larger in younger subjects, consistent with domination by the right ventricle in this age group. Unfortunately, no critical measurements of the crista among normal subjects are available in the literature so these possibilities remain unconfirmed.

There are several reasons why this explanation for the $S_1S_2S_3$ syndrome is reasonable. It would explain why this syndrome may be encountered among otherwise perfectly normal subjects. It would account for the apparently higher incidence of the syndrome among younger subjects. It would account for the rarity of anteriorly directed abnormal .08 vectors and the frequency of posteriorly directed abnormal .08 vectors, for, with lesser degrees of enlargement of this structure, intermediary deviations from the normal in the direction of the .08 vector would occur. It would explain why many but not all of this group of subjects with $S_1S_2S_3$ tracings have slightly prolonged QRS intervals, from .10 to .12 second, for, with this region of the heart delayed in its depolarization, the QRS interval might frequently extend slightly beyond the normal .08 to .09 second. And finally, it would explain why the .04 vector is more anteriorly directed when the .08 vector is rightward and anterior in direction, for early left ventricular forces might tend to be free of opposing right ventricular forces in such cases.

How can one be sure that these tracings do not represent a form of right bundle branch block, perhaps due to a congenital variation in the distribution of conduction tissue in this

Downloaded from http://ahajournals.org by on October 23, 2024

iRhythm, Inc. / Welch Allyn, Inc.
Exhibit 1020
Page 15

region of the right ventricle? Unfortunately there is no way to differentiate delay in QRS forces due to an increase in ventricular wall thickness from that due to a local conduction defect so this question cannot be categorically answered. The fact that the $S_1S_2S_3$ syndrome appears to be more frequent in younger age groups favors variation in right ventricular muscle thickness as its cause because it indicates that the defect may be reversible.

In group II, the eleven cases with a QRS interval of .12 to .14 second, left ventricular hypertrophy was present clinically in nearly all cases. This is in striking contrast to the group I cases, where no organic heart disease appeared to be related to the QRS deformity. The QRS loop in group II might have one or the other of two different positions to account for the S waves as a result of the left ventricular hypertrophy. (1) In a small number of cases, the QRS loop had rotated posteriorly, so that only a foreshortened projection of the loop was recorded in the frontal plane, and the terminal vectors pointed posteriorly and slightly rightward producing S waves in the limb leads (fig. 3*B*). Presumably the hypertrophied left ventricle lay principally posteriorly in these cases.

The foreshortening of the loop in these cases is of particular interest in clinical electrocardiography because it illustrates an important property of spatial electrical forces. When the loop is rotated markedly posteriorly, most of the instantaneous QRS vectors are relatively perpendicular to the frontal plane. Under these circumstances slight differences in the directions of successive instantaneous vectors produce marked difference in the contours of the deflections in the limb leads. Accordingly, in these cases, the limb lead QRS complexes are not only relatively small, but often also show marked slurring, notching, and W- and M-shaped complexes. Such deflection deformities have in the past been considered abnormal. Actually, however, it can be seen that they may in some cases be due simply to posterior rotation of the loop.

(2) The second way in which left ventricular hypertrophy produces $S_1S_2S_3$ tracings is by causing the QRS loop to be markedly leftward in position. Indeed, it may be deviated so far to the left that certain of its terminal forces are actually directed rightward and superiorly, which accounts for the S-waves in these cases (fig. 3*A*). In the sagittal plane, these loops are generally relatively flush with the frontal plane, showing little of the posterior direction which is usually seen in left ventricular hypertrophy. This type of loop rotation is interesting because the directions of the terminal QRS vectors do not fit with the generalization that a given vector is directed perpendicularly to the surface where it is generated. The left ventricle would have to be rotated to an impossible degree to produce these rightward terminal forces. Wilson and his co-workers have offered an explanation for this.[9] They point out that endocardial conduction via the Purkinje network is faster—perhaps 10 times faster—than transmyocardial conduction. Accordingly, when the ventricular wall is thickened, the wave of excitation at the endocardium will be considerably further along than the wave of excitation at the epicardium. With greater and greater increases in wall thickness, the wave front from endocardium to epicardium will become more and more oblique to the surface of the ventricle. This would cause the resultant vectors generated from a markedly hypertrophied left ventricle to be directed significantly more superiorly than the generating epicardial surface is facing.

Two cases were encountered in group II who had markedly leftward loops as in figure 3*A*, but who showed no clinical evidence of left ventricular hypertrophy or other heart disease. In both instances the QRS-T angle was nearly 150 degrees and the ventricular gradient normal in direction, indicating that a conduction disturbance was responsible for the QRS abnormality and that no intrinsic myocardial disease was present electrically. Presumably in these two normal subjects there was a congenital defect in conduction in one of the sub-branches of the left bundle branch, for this is the only way in which terminal forces with this direction can be explained. Such sub-branch block has been suggested before,[10,11] but has never been proved in the human subject.

In group III, the $S_1S_2S_3$ cases with QRS in-

Downloaded from http://ahajournals.org by on October 23, 2024

iRhythm, Inc. / Welch Allyn, Inc.
Exhibit 1020
Page 16

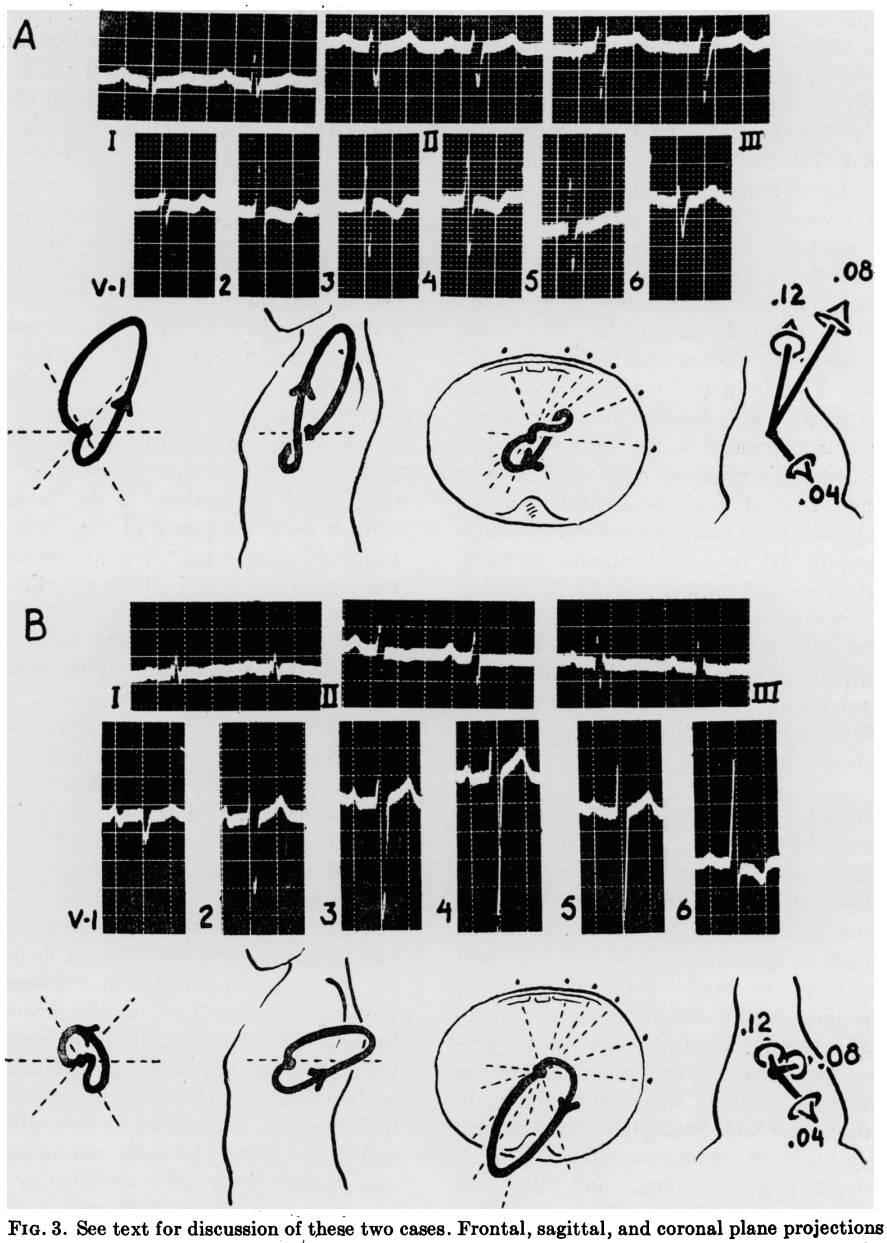

FIG. 3. See text for discussion of these two cases. Frontal, sagittal, and coronal plane projections of the QRS loop and the spatial characteristics of the .04, .08, and .12 QRS vectors are shown. The QRS complexes in tracing *B* have been retouched to make them clearer.

tervals over .14 second, the terminal vector was relatively flush with the frontal plane, and markedly superior and slightly rightward in direction in all 9 cases. In other words, many of these cases showed the R_1S_3 "pattern" of left bundle branch block in the limb leads, and

Downloaded from http://ahajournals.org by on October 23, 2024

iRhythm, Inc. / Welch Allyn, Inc.
Exhibit 1020
Page 17

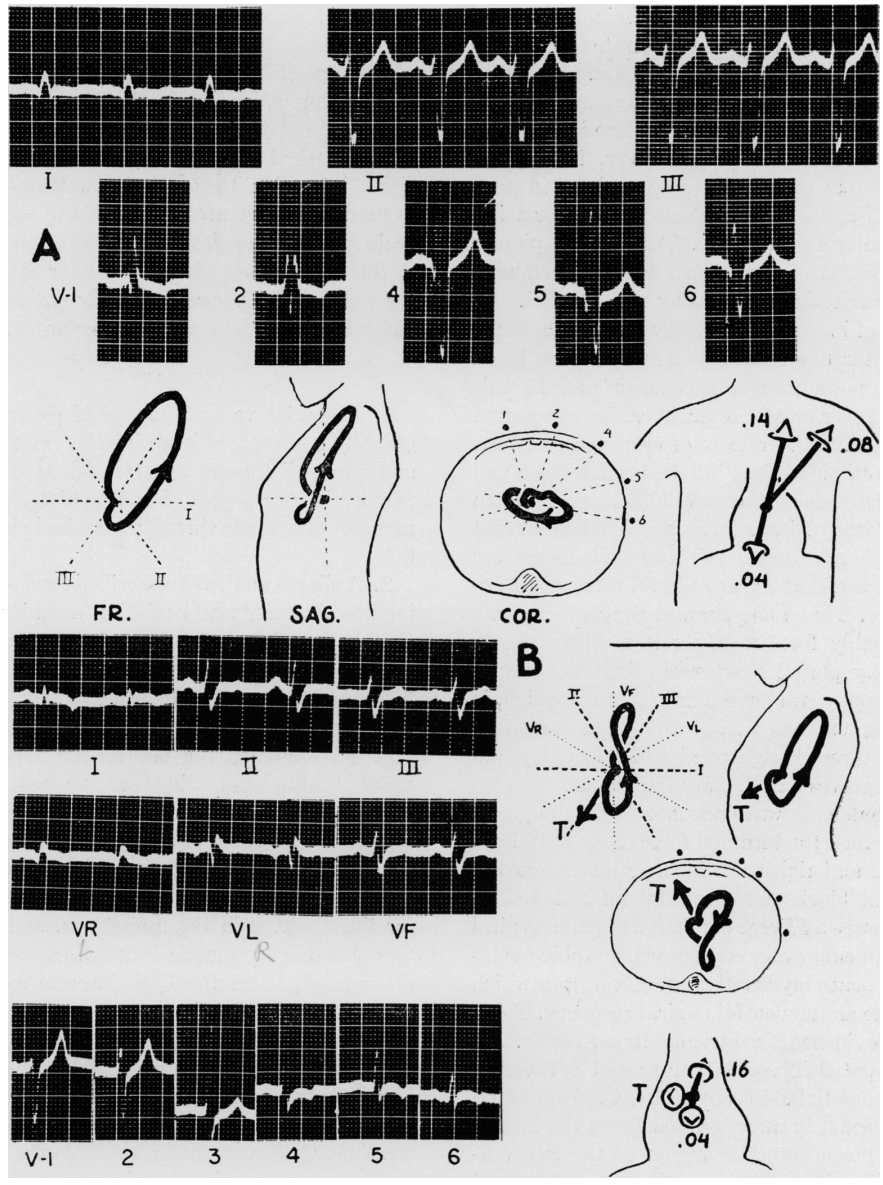

FIG. 4. See text for discussion of these two cases. Frontal, sagittal, and coronal plane projections of the QRS loop and the spatial characteristics of the .04, .08, and .16 QRS vectors are shown. Note: In figure 4*B*, the tracing V_R should have been labelled V_L, and V_L should have been labelled V_R.

a bifid R in V_1, the "pattern" of right bundle branch block in the precordial leads (fig. 4*A*). Accordingly, "pattern" methods of interpretation cannot satisfactorily explain these tracings. However, vector methods offer a rational way to decide which bundle branch is blocked

Downloaded from http://ahajournals.org by on October 23, 2024

iRhythm, Inc. / Welch Allyn, Inc.
Exhibit 1020
Page 18

in such cases, because the terminal vector of the QRS loop must be generated from the blocked ventricle in the given case. Using Wilson's hypothesis that the vectors are directed obliquely to the generating surface in the presence of ventricular hypertrophy, it becomes evident that these cases are probably instances of left bundle branch block with marked left ventricular hypertrophy. The clinical picture supported this conclusion for in all instances, left ventricular hypertrophy was present.

It is of interest that no clear-cut instances of $S_1S_2S_3$ due to either right bundle branch block or cor pulmonale were encountered in this series; however such cases have been reported by others.[11, 12] A review of electrocardiograms characteristic of right bundle branch block and cor pulmonale in the past 3000 tracings taken in the Grady Memorial Hospital indicated that in these syndromes the terminal forces are usually directed rightward and relatively horizontally. That none showed $S_1S_2S_3$ complexes is probably fortuitous, for it is likely that a vertically placed heart with right ventricular hypertrophy will have terminal forces which, in pointing obliquely from the right ventricle, will be directed rightward and superiorly and write S waves on the three limb leads.

A single case was encountered in the group IV in which the terminal forces may have been delayed and rightward in direction because of perifocal block of myocardial infarction. The subject was a 57 year old man who had a typical clinical history and electrocardiographic evolution of acute myocardial infarction from which he made an uneventful clinical recovery. There was no evidence of ventricular hypertrophy. The mean spatial T vector, the spatial S-T vector and the spatial .04 vector of the QRS loop were all abnormal in direction, localizing the infarct in the posterosuperior region of the left ventricle (fig. 4*B*). Then, the direction of the .14 vector was plotted to determine where the delayed QRS forces responsible for the QRS prolongation were generated. It was found that it pointed in the direction of the infarct; that is, the terminal forces were being generated from very nearly the region of the heart where the infarct lay. Accordingly, it is likely that the abnormal direction of the terminal forces in this case was due to perifocal delay in excitation of the epicardium overlying the infarct. The mechanism which Bayley[13] has suggested for this focal delay in epicardial excitation is that with electrical death of the endocardium at the site of infarction, the excitation wave must pass around this inert area to reach the epicardial regions. Thus, depolarization of the epicardium at this region takes place much later than when the excitation can spread directly radially from the subendocardial conduction network.

Summary

1. A spatial vector concept of electrocardiography is presented in which the various limb and precordial leads are treated as different perspectives or points of vantage in the measurement of a single three-dimensional electrical field.

2. A simple method is described for determining the directions and relative magnitudes of the various electrical forces of the heart from inspection of the conventional leads. The validity and advantages of the method are discussed.

3. To illustrate the use of the method, a series of 80 $S_1S_2S_3$ tracings are analyzed by the spatial vector method. It was found that when the QRS interval was .12 second or less, late depolarization in the right ventricle, perhaps at the crista supraventricularis, was responsible for the S waves in the limb leads, and rarely was this due to organic heart disease. On the other hand, when the QRS interval exceeded .12 second, marked left ventricular hypertrophy, with or without left bundle branch block, was present in nearly all cases. The hypertrophy of the left ventricle appeared to be responsible for the unusual direction of the terminal QRS vectors in these cases. In the present series no clear-cut instances of $S_1S_2S_3$ tracings due to cor pulmonale or right bundle branch block were encountered, although it is recognized that such cases might occur when the heart is electrically in a vertical position.

4. A case of possible perifocal block is presented in which the $S_1S_2S_3$ syndrome may have been directly due to the disease process.

Downloaded from http://ahajournals.org by on October 23, 2024

iRhythm, Inc. / Welch Allyn, Inc.
Exhibit 1020
Page 19

REFERENCES

[1] GRANT, R. P.: The relationship of precordial leads to the electrical field of the heart. Circulation **1:** 878, 1950.

[2] WILSON, F. N., ROSENBAUM, F. F., AND JOHNSTON, F. D.: The interpretation of the ventricular complex of the electrocardiogram. In Advances in Internal Medicine, New York, Interscience Publishers, 1947, vol. 2, p. 1.

[3] WILSON, F. N., JOHNSTON, F. D., AND KOSSMANN, C. E.: The substitution of a tetrahedron for the Einthoven triangle. Am. Heart J. **33:** 594, 1947.

[4] BAYLEY, R. H.: On certain applications of modern electrocardiographic theory to the interpretation of electrocardiograms which indicate myocardial disease. Am. Heart J. **26:** 769, 1943.

[5] GRANT, R. P.: An approach to the spatial electrocardiogram. Am. Heart J. **39:** 17, 1950.

[6] LEWIS, T., AND ROTHSCHILD, M. A.: The excitatory process in the dog heart. Part II. The ventricles. Phil. Tr. R. Soc. Med., s. B. **206:** 181, 1915.

[7] KOSSMANN, C. E., BERGER, A. R., RADER, B., BRUMLÍK, J., BRILLER, S. A., AND DONNELLY, J.: Intracardiac and intravascular potentials resulting from electrical activity of the normal human heart. Circulation **2:** 10, 1950.

[8] WILSON, F. N., MACLEOD, A. G., AND BARKER, P. S.: The interpretation of the initial deflections of the ventricular complex of the electrocardiogram. Am. Heart J. **6:** 637, 1931.

[9] MEYER, P., AND SCHMIDT, C. L.: Etude electrocardiographique de blocs localisés dans certaines regions du ventricule gauche (blocs focaux) en particulier de syndromes representant l'homologue du blocs du Wilson pour le ventricule gauche. Arch. d. mal. du coeur **41:** 707, 1948.

[10] SEGERS, M., VASTESAEGER, M., AND DENOLIN, H.: Les différents aspects des troubles de la conduction intraventriculaire. Acta cardiol. **2:** 166, 1947.

[11] CAROUSO, G., TILMANT, J., AND LENÈGRE, J.: Signification des ondes S_1 S_2 et S_3 predominances. Arch. d. mal du coeur **42:** 418, 1949.

[12] JOHNSON, J. B., FERRER, M. I., WEST, J. R., AND COURNAND, A.: The electrocardiographic evidence of right ventricular hypertrophy and pulmonary artery pressure in patients with chronic pulmonary disease. Circulation **1:** 536, 1950.

[13] FIRST, S. R., BAYLEY, R. H., and BEDFORD, D. R.: Peri-infarction block; electrocardiographic abnormality occasionally resembling bundle branch block and local ventricular block of other types. Circulation **2:** 31, 1950.

Downloaded from http://ahajournals.org by on October 23, 2024

iRhythm, Inc. / Welch Allyn, Inc.
Exhibit 1020
Page 20