ELSEVIER
SAUNDERS

Facial Plast Surg Clin N Am 12 (2004) 387–395

FACIAL PLASTIC
SURGERY CLINICS
OF NORTH AMERICA

Nasal anatomy and physiology

Andrew P. Lane, MD

Department of Otolaryngology–Head and Neck Surgery, Johns Hopkins University School of Medicine, Outpatient Center, 6th Floor, 601 North Caroline Street, Baltimore, MD 21287, USA

For the rhinoplasty surgeon, the anatomy of the nose is familiar, particularly as it pertains to external cosmetic appearance. However, it is also necessary to understand the anatomy and physiology of the internal nose from a functional perspective to achieve optimal results in rhinoplastic surgery. The primary purpose of the nose is to filter and condition inspired air, while acting as the major source of airway resistance. Cosmetic and reconstructive surgery at the junction of the internal and external nose can have a significant impact on nasal airflow dynamics. Because of the highly intertwined nature of nasal form and function, it is the responsibility of the rhinoplasty surgeon to take into account the "invisible" internal portion of the nasal cavity while focusing on the outwardly visible external structure.

Anatomy

External nose

The piriform aperture is the bony entrance to the internal nasal cavity. It is bordered superiorly by the paired nasal bones, which merge in the midline to form a pyramid projecting outward as the bony nasal dorsum. The remaining borders of the piriform aperture are provided by the maxillary bone, including its frontal processes laterally and the maxillary crest inferiorly in the midline. The cartilaginous framework of the nose consists of paired upper lateral, lower lateral, and sesamoid cartilages. At the most caudal aspect of the nose, the nostril is divided into the alar base and the vestibule. The size and shape of the alar base and external naris varies widely among individuals and ethnic types, depending on the configuration and distribution of fibro-fatty connective tissue [1]. Just inside the external nares, the cavity of the nasal vestibule fills the lower third of the nose and is bounded medially by the mobile septum and laterally by the alar side wall. Nasal hairs called vibrissae grow at the entrance to the vestibule from a fold of skin wrapping under the lateral crus. The junction of the vestibule with the floor of the nasal cavity occurs at the inferior edge of the piriform ridge and is demarcated by the limin nasi. By slowing down the airstream, directing currents into the nasal cavity, and filtering large particles, the vestibule and vibrissae play a very early role in the respiratory activity of the nose [2].

Septum

The upper third of the bony septum is formed by the perpendicular plate of the ethmoid, which articulates anteriorly with an inward spine of the nasal bones and is continuous superiorly with the frontal bone and cribriform plate. Inferiorly, the perpendicular plate articulates with the vomer and the quadrilateral septal cartilage. The vomer is a keel-shaped bone that extends from the nasal crest of the palatine bones and maxilla posteriorly to the sphenoid rostrum. The premaxillary wings of the maxilla fuse in the midline with the vomer to form a groove in which the inferior edge of the quadrilateral cartilage rests. The articulation of the cartilage with the premaxilla and vomer is densely interwoven with decussating periosteal and perichondrial fibers. The septal cartilage provides support for the nasal dorsum below the rhinion caudally to the supratip region. The upper lateral cartilages and dorsal cartilaginous septum arise

E-mail address: alane3@jhmi.edu

1064-7406/04/$ – see front matter © 2004 Elsevier Inc. All rights reserved.
doi:10.1016/j.fsc.2004.04.001

Aerin Exhibit 1018, Page 1 of 9
Aerin Medical Inc. v. Neurent Medical Ltd.
IPR2025-01125

as a single embryological unit with a common perichondrial lining [3]. Caudally, the upper lateral cartilages diverge from the septum to form a fibrous aponeurosis. The septum contributes in this area to the superior angle of the internal nasal valve, a critical anatomic feature for normal nasal respiration. The slit-like nasal valve is formed by the upper lateral cartilages, the septum, and the inferior turbinate. It is the flow-limiting segment of the nasal airway and contributes approximately 50% of total airflow resistance for the combined upper and lower airways [4]. The function of the nasal valve is discussed in a later section.

Lateral wall

The lateral nasal wall presents an irregularly shaped surface characterized by the inferior, middle, and superior turbinates (Fig. 1). Scroll-like in shape and pitted, the conchal bones support the soft tissue erectile component of the turbinates. The projection of each concha into the nasal cavity creates a space beneath the turbinate called a meatus. The inferior meatus lies between the inferior turbinate and the floor of the nose. Contained within this space is the orifice of the nasolacrimal duct. Between the inferior and middle turbinate lies the middle meatus, a region critical to the function of the anterior paranasal sinuses. The frontal, maxillary, and ethmoid sinuses all have their outflow through this area either directly or by means of the ethmoidal infundibulum. The be appreciated. infundibulum drains into the middle meatus via the hiatus semilunaris, a crescent-shaped opening between the free margin of the uncinate process and the anterior lamella of the ethmoid bulla. Mucosal inflammation and polyps frequently occur in this location and can lead to sinus outflow obstruction, mucus stasis, and ultimately bacterial sinusitis [5]. The superior meatus, which is located between the middle and superior turbinates, is the site of drainage for the posterior ethmoid sinuses. Occasionally there is also a supreme meatus that may be the point of outflow for additional posterior ethmoid cells. The sphenoid sinus ostium is not located in a meatus, but rather opens directly into the nasal cavity between the superior turbinate and the nasal septum. The anatomy of the paranasal sinuses themselves is beyond the scope of this discussion, but their contribution to the dimensions and function of the nasal cavity should be appreciated.

Blood supply

Arterial

The rich vascular supply to the nasal cavities derives from both the internal and external carotid systems [6]. The anterior and posterior ethmoid arteries arise from the ophthalmic branch of the internal carotid artery, crossing the orbit to enter the ethmoid labyrinth through foramina near the fronto-ethmoid suture (Figs. 2 and 3). The vessels usually course medially within bony canals to the cribriform

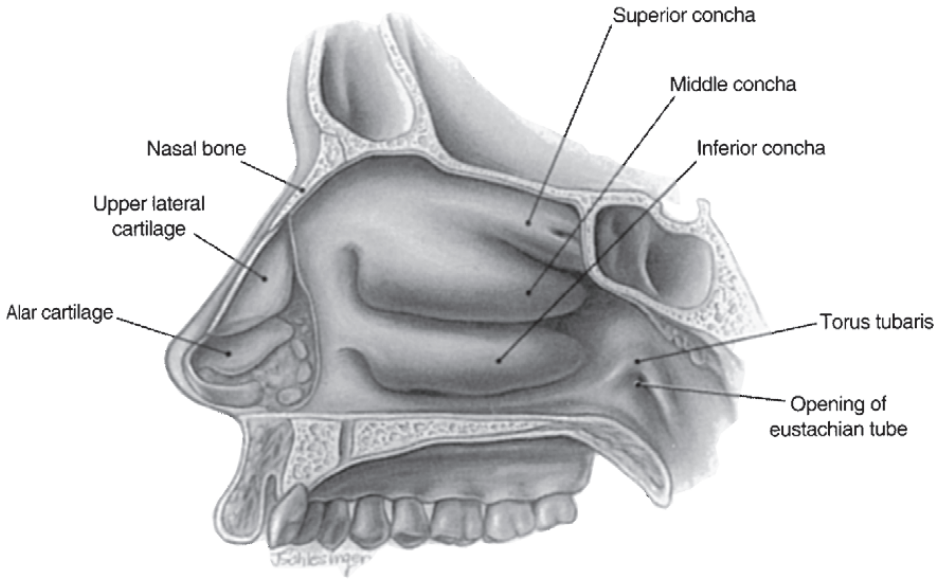

Fig. 1. Lateral nasal wall anatomy. Left side of the nose with nasal septum removed. (*From* O'Neal RM, Beil Jr RJ, Schlesinger J. Surgical anatomy of the nose. Otolaryngol Clin N Am 1999;32(1):175 [Fig. 29]; with permission.)

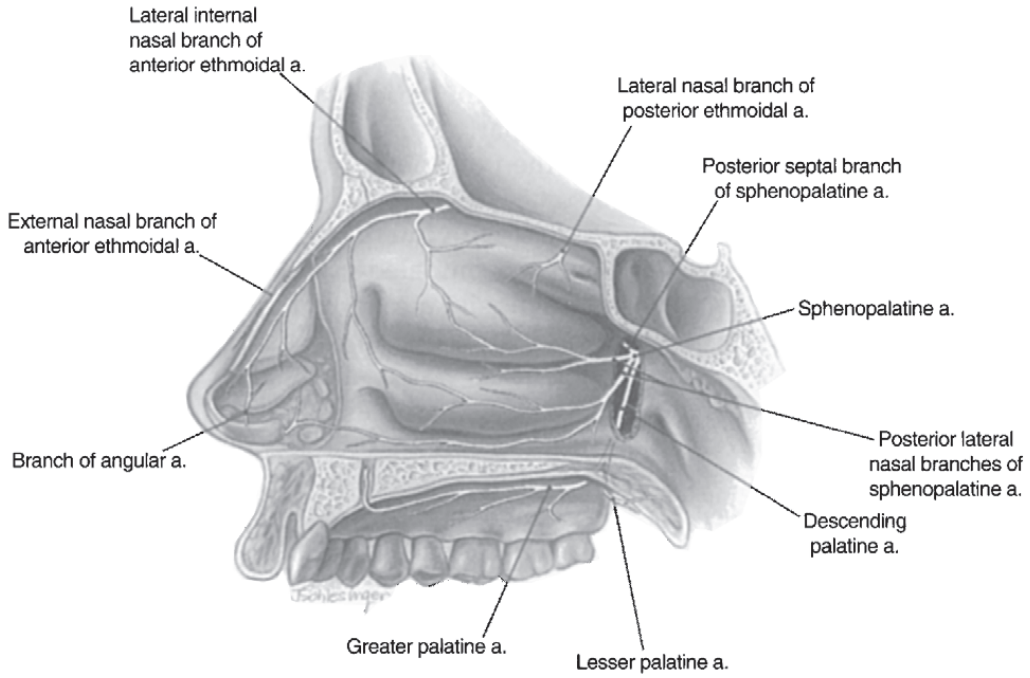

Fig. 2. Right lateral wall of the nose showing arterial blood supply. (*From* Otolaryngol Clin N Am 1999;177 [Fig. 32]; with permission.)

plate; however, they may be dehiscent and suspended in mesenteries up to 4 mm below the ethmoid roof [7]. After traversing the ethmoid and passing intracranially, the ethmoid arteries give off branches to supply the dura, as well as nasal branches that return through the cribriform plate to supply the nasal cavities. The posterior ethmoid artery feeds the superior turbinate and posterior septum, while the anterior ethmoid artery supplies the anterior middle turbinate and septum. The contribution of the external

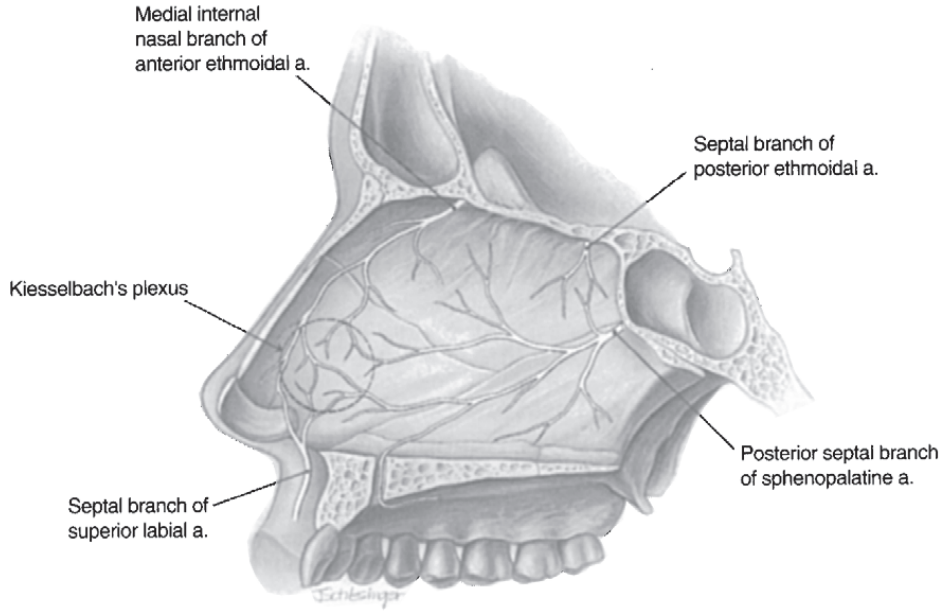

Fig. 3. Left side of the nasal septum showing arterial blood supply. Circle demonstrates Kesselbach's plexus. (*From* Otolaryngol Clin N Am 1999;177 [Fig. 33]; with permission.)

carotid artery to the nasal vasculature comes from the internal maxillary artery and facial arteries. There are two terminal branches of the facial artery, the superior labial and the angular, which supply the anterior nasal septum and nasal cavity. The major arterial source for the remainder of the nasal cavity is the internal maxillary artery, which branches terminally within the pterygopalatine fossa. The sphenopalatine branch exits into the nose via the sphenopalatine foramen, located near the posteroinferior attachment of the middle turbinate. This artery divides into posterior lateral and posterior septal branches that supply the turbinates, lateral nasal wall, sinuses, and septum. The posterior septal artery gives off the nasopalatine artery, which continues anteriorly in a groove along the vomer to reach the incisive foramen. Another branch of the internal maxillary artery, the descending palatine artery, exits into the oral cavity through the greater palatine foramen. An important area of arterial anastomosis occurs at the anterior nasal septum, linking branches of the greater palatine, superior labial, sphenopalatine, and anterior ethmoid arteries. This region, known as Kesselbach's plexus or Little's area, is the most common source of epistaxis [6].

Venous

The veins of the nose follow similar courses to the arterial systems. Most of the venous drainage of the septum and lateral nasal cavity follows the sphenopalatine artery to the pterygoid plexus, located in the infratemporal fossa [8]. Ethmoid veins drain into the ophthalmic plexus and into the superior and inferior ophthalmic veins. There are numerous anastomoses between these venous systems and the veins of the face, palate, and pharynx. Ultimately, the venous outflow communicates with the cavernous sinus and anterior cranial fossa [9]. It is important to recognize that the veins in this region are valveless and represent potential routes of spread of infection from the nasal cavity to the orbits and intracranial space.

Cavernous plexi

A critical feature of the nasal mucosa is its ability to expand and constrict as necessary to alter the dimensions of the nasal cavity. This is accomplished in large part by the cavernous plexus system, prominent in the septum and inferior and middle turbinates. Cavernous plexi consist of bundles of anastomosing valveless vessels of arterial and venous origin that connect to the fenestrated capillary networks of the epithelial microcirculation [8]. The superficial plexus drains only the subepithelial and glandular capillaries, while the thick-walled deep plexus, running along the periosteum or perichondium, also receives arterial blood from arteriovenous anastomoses. The blood flow into the arteries of the anastomoses is regulated by a smooth muscle layer, allowing cavernous plexi to act as capacitance vessels. The muscle tone is responsive to circulating sympathetic and parasympathetic agents, as well as to mechanical, thermal, and psychological stimuli. Throughout the day, there is a constant cycling of congestion and decongestion that alternates between the two nasal cavities reciprocally [10]. However, the fluctuating resistance to airflow associated with this nasal cycle is rarely perceptible in the normal state.

Lymphatics

The nasal vestibule lymphatics drain anteriorly with the external nose, ultimately into the facial vein and submandibular lymph nodes. The remainder of the nasal cavity drains posteriorly toward the lateral retropharyngeal lymph nodes. There are anterosuperior and posterosuperior trunks draining the lateral nasal wall: the former derives from the inferior turbinate and anterior portion of the middle turbinate, while the latter originates in the posterior middle turbinate, superior turbinate, sphenoethmoidal recess, and olfactory cleft. The septal lymphatics cross the nasal floor to join these trunks, which converge posterior to the Eustachian tube before entering the lateral retropharyngeal nodes. Nasal lymphatic drainage also contributes to the jugulodigastric and deep cervical lymph chains.

Innervation

General sensation

The major sensory nerve supply to the nose derives from the maxillary and ophthalmic divisions of cranial nerve Vz (Figs. 4 and 5). The maxillary division enters the roof of the pterygopalatine fossa via the foramen rotundum, then sends off several sensory branches to the midface structures. The branches destined to innervate the nasal cavity enter the nose through the sphenopalatine foramen, together with the sphenopalatine vessels and autonomic fibers from the sphenopalatine ganglion. Posteroinferior nasal branches give sensation to the mucosa of the turbinates and lateral nasal wall. Posterosuperior branches pass across the face of the sphenoid bone to reach the nasal septum as the nasopalatine (Scarpa's)

Aerin Exhibit 1018, Page 4 of 9
Aerin Medical Inc. v. Neurent Medical Ltd.
IPR2025-01125

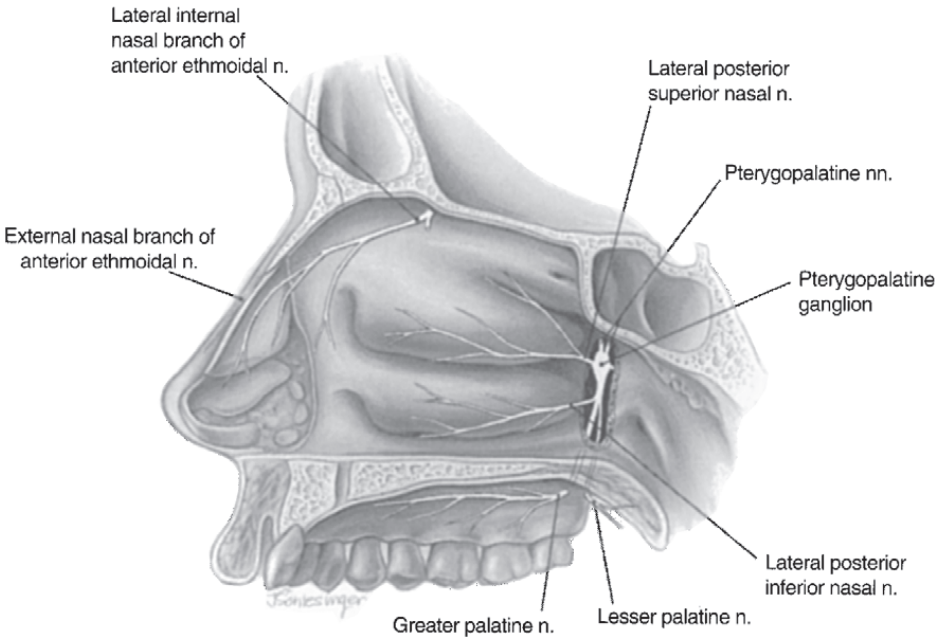

Fig. 4. Right lateral wall of the nose showing nerve supply. (*From* Otolaryngol Clin N Am 1999;176 [Fig. 30]; with permission.)

nerve. The nasopalatine nerve then passes through the incisive foramen to innervate the anterior and superior gingiva. Sensory contributions by the ophthalmic division of the trigeminal nerve come from the nasociliary nerve, which branches off V2 after it enters the orbit through the superior orbital fissure. The nasociliary nerve in turn divides into anterior and posterior ethmoid nerves that enter the nose together with their respective arteries. The anterior ethmoid nerve supplies the anterior lateral nasal wall, while the posterior ethmoid nerve innervates the posterior and superior septum and lateral nasal wall.

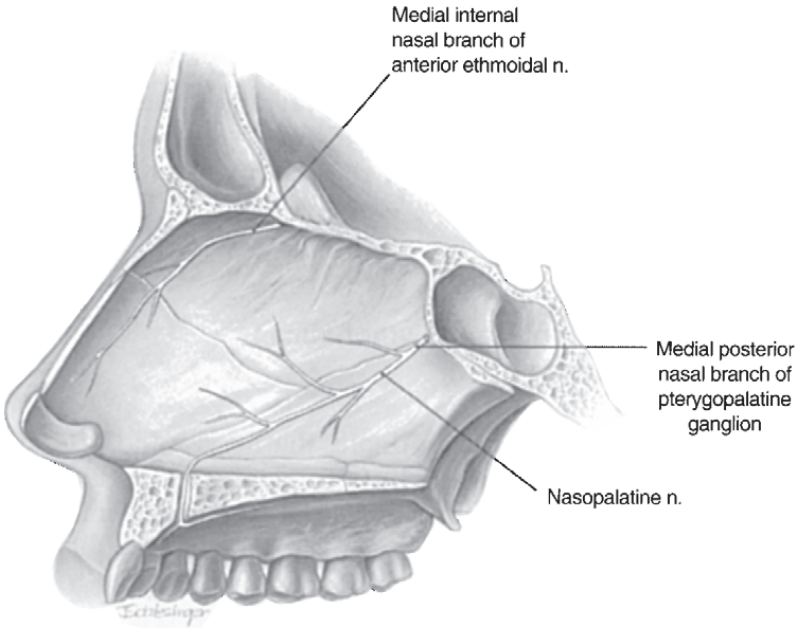

Fig. 5. Left nasal septum with lateral wall removed showing sensory nerve supply. (*From* Otolaryngol Clin N Am 1999;176 [Fig. 31]; with permission.)

Autonomic supply

Sympathetic and parasympathetic innervation of nasal glands and vascular beds is central to normal physiologic activity [11]. The sympathetic pathway begins in the thoracolumbar spinal cord, where preganglionic fibers exit and travel with the vagosympathetic trunk to terminate in the cervical sympathetic ganglion. Postganglionic fibers run along the internal carotid artery and eventually form the deep petrosal nerve, which merges with the greater superficial petrosal nerve to create the vidian nerve. The vidian nerve enters the pterygopalatine fossa where it contributes to the sphenopalatine ganglion; however, rather than synapse there, the sympathetic fibers join branches of V2 spreading throughout the mucosa. Other sympathetic fibers travel from the carotid plexus along ethmoid nerve branches of V1. Parasympathetic innervation of the nasal cavity begins in the superior salivary nucleus of the midbrain. Fibers travel with the facial nerve (nervus intermedius portion) to the geniculate ganglion, then exit as the greater superficial petrosal nerve without synapsing. This nerve merges with the sympathetic deep petrosal nerve to form the vidian nerve, as previously described. In contrast to the sympathetic fibers, the parasympathetic fibers do synapse in the sphenopalatine ganglion, with the postganglionic fibers distributed to the sinonasal mucosa along with sensory branches of V2 [6].

Microscopic anatomy

The internal lining of the nose at the level of the vestibule is a keratinized stratified squamous epithelium, with sebaceous glands, sweat glands, and numerous coarse hairs (vibrissae). At the limen vestibuli, the epithelium begins to change over to a pseudostratified respiratory epithelium characterized by five cell types: basal cells, goblet cells, ciliated columnar cells, nonciliated columnar cells, and small granule cells [12]. In high-airflow regions of the nasal cavity, such as the heads of the turbinates, there may be islands of squamous epithelium amid the respiratory epithelium. Respiratory mucosal cells rest on a basement membrane that overlies a loose lamina propria. The submucosa contains blood vessels, venous plexi, glandular elements, sensory nerves, and immune cells. Submucosal capillaries and venules have fenestrated endothelial linings and relatively porous basement membranes, facilitating the transit of fluid and white blood cells to the mucosal surface. Ciliated columnar cells, the predominant cell type at the surface, rest on the basement membrane and project both cilia and microvilli from their apical ends into the nasal lumen.

Numbering up to 1000 per cell, the motile cilia play a critical role in mucociliary clearance. Ultrastructurally, cilia are anchored to basal bodies below the cell surface and are encased by extensions of the plasma membrane. Within the cilium are axonemes, which are comprised microtubules arranged in a characteristic "9 + 2" pattern. Nine outer pairs of microtubules make a cartwheel pattern at the periphery of the axoneme, surrounding two single microtubules in the center. The two subfibers of each outer microtubule pair are linked by regularly arranged dynein arms, while each microtubule pair is linked to adjacent ones by an elastic substance called nexin. The mechanism by which ciliary movement occurs is described in a later section.

Goblet cells are aptly named because of their characteristic goblet shape, which tapers to a narrow attachment at the basal membrane. At the luminal surface, goblet cells are covered by microvilli and have a small opening through which mucin is secreted. Small granule cells are endocrine-type cells that produce polypeptide hormones and catecholamines thought to play a role in modulating nasal airway reflexes. The function of the basal cells and nonciliated columnar cells is less clear, but evidence suggests they play a role as progenitor populations. Since columnar cells lack hemidesmosomes needed to attach themselves to the basement membrane, it is believed that another important function of basal cells is to anchor columnar cells with adhesion molecules such as laminin.

In the olfactory clefts, there is another transition to a specialized neuroepithelium that contains bipolar olfactory receptor neurons and their progenitors, supporting sustentacular cells, and mucous glands. The exact dimensions of the olfactory epithelium vary significantly among individuals, and the olfactory region is normally interspersed with patches of respiratory mucosa. The olfactory epithelium also contains specialized glands known as Bowman's glands, the secretions of which are thought to have a critical role in olfactory function.

In the epithelium and submucosa, there are three different types of glands: serous, seromucous, and intraepithelial. The sinonasal cavities produce between 1 L and 2 L of mucus per day, which is necessary to humidify inspired air, prevent desiccation of the mucosa, and provide defense against airborne particulates. Serous glands are located anteriorly in the nasal vestibule and make a small contribution to overall mucus production. The bulk of the

mucus in the nose is generated by the submucosal seromucous glands, which number approximately 80,000 to 100,000. The acini of these glands may be serous or mucous, with a ratio of about 8:1. During development, the seromucous glands grow into distinct superficial and deep layers, separated by connective tissue containing nerves and blood vessels. Intraepithelial glands are irregularly distributed and few in number. They contribute little to the total daily production of nasal mucus.

Nasal physiology

A major function of the nasal cavity is to lubricate and humidify inspired air while removing airborne particles before they reach the lower airway. The nasal mucus, which plays an essential role in this process, contains 2% to 3% glycoproteins and 1% to 2% salts; the rest is water [13]. It is slightly acidic, with a pH between 5.5 and 6.5. The major protein content is made up of immunoglobulins, which take part in immune protective function. After secretion, the mucus forms a low-viscosity, periciliary sol layer, on top of which rests a 12-micron to 15-micron thick tenacious gel layer. Most of the mucus blanket is swept from anterior to posterior by the coordinated action of the epithelial cell cilia. The cilia beat in a biphasic pattern, with a rapid effective phase wherein the cilia straighten to contact the gel phase of the mucus and force it along, followed by relaxation and a slower recovery stroke to their previous positions in the sol layer. This pattern repeats approximately 1000 times or more each minute [4]. At the most anterior portion of the inferior turbinates, the cilia propel the mucus anteriorly toward the nasal vestibule and out of the nose. In a healthy nose, the average rate of movement of particles in the mucus blanket is about 6 mm per minute, but a wide range of speeds greater than this also exist under normal conditions [14]. Dryness of the mucosa slows down ciliary flow, as does decreased relative humidity.

The nasal cavity warms inspiratory air through turbulent flow that maximizes contact with the available mucosal surface area. Radiated heat from the nasal microcirculation is sufficient to warm room temperature air by 10°C by the time it reaches the pharynx. The vessels of the mucosa are arranged to flow opposite to the direction of nasal airflow, making the exchange more efficient. As the warm expired air passes the comparatively cool nasal mucosa, some heat is returned to the system, which causes condensation of water vapor and thus a regeneration of humidity. When the nasal mucosa is significantly cooled, as on a winter day outdoors, the humidifying capacity of the nose is reduced, and the increased condensation leads to runniness [15].

Airflow

Although the oral cavity provides a roughly twofold lower-resistance pathway for breathing, 85% of the adult population preferentially breathes through the nose, except in times of exercise or when speaking. The resistance within the nose comes from two main sources: the nasal valve and mucosal swelling. At the internal nasal valve, the cross-section of the nasal airway is approximately 20 mm^2 to 40 mm^2 on each side [16]. As noted earlier, this comprises about 50% of the total airway resistance from the nose to the alveoli. The semirigid passageway posterior to the nasal valve is irregular in shape, bordered by the septum medially and the turbinates laterally. The cross-sectional area of the main portion of the nasal airway is approximately 130 mm^2. The caliber of the airway is largely controlled by the state of vascular engorgement of the capillaries and capacitance vessels in the surrounding nasal mucosa. As described previously, the alternating pattern of reciprocal congestion and decongestion, known as the nasal cycle, acts to increase resistance on one side relative to the other throughout the day, while keeping the combined total nasal resistance constant [10]. Other factors, especially inflammatory triggers, can also create large resistance increases by stimulating mucosal swelling. When the nasal passages become too congested for breathing, there is a reflexive switch to the low-resistance alternative of mouth breathing, which sacrifices the air conditioning and barrier defenses of the nose [17,18].

The dynamics of airflow in the human nose have been studied extensively by Swift and Proctor [19], using both cast models and human subjects to measure flow direction and velocity at multiple locations. In these detailed experiments, it was shown that inspired air initially enters each nostril in an upward direction at about 2 to 3 m/s, then turns 80° to 90° to a horizontal direction just before the nasal valve. The airflow becomes laminar as the direction shifts. Within the nasal valve, because of the narrow cross-sectional area, the speed increases to as much as 12 to 18 m/s, which is a force of air movement equivalent to gale force winds. More posteriorly, as the airway widens again, the velocity decreases back toward 2 to 3 m/s, and the flow becomes more turbulent. Passage through the narrow valve endows the air with kinetic energy needed to generate this turbulence in the wider distal airway. Turbulence is

important to the function of the nose because it promotes interaction of the air with the mucosa. If the airflow were strictly laminar, there would be an insulating boundary of air against the mucosa that would prevent mixing. During quiet breathing, turbulent flow begins at about the level of the midportion of the middle turbinate. As respiratory flow increases with exercise, however, the point at which turbulent flow begins moves increasingly anterior in the nasal cavity. Regardless of the rate of flow, most of the airstream travels between the inferior and middle turbinates or along the nasal floor on its way to the nasopharynx.

The nasal valve plays a critical role in determining the airflow characteristics of the nasal airway [20]. Multiple anatomic factors contribute to the nasal valve, including the septum, upper lateral cartilages, bony piriform aperture, inferior turbinates, and erectile tissue of the nasal wall. The cartilaginous structure of the nasal vestibule, together with the activity of the alar dilator muscles, contributes to airflow dynamics independently of the state of mucosal swelling inside the nose. Similarly, the acutely angled triangle formed by the upper lateral cartilage and the septum is of fixed dimensions. However, the flexibility of these fixed structures allows the external valve to act as a Starling resistor, which can limit flow by collapsing when airflow is rapid. Partial collapse of the upper lateral cartilages occurs at a flow rate of about 30 L/min [21]. In contrast to the static structures of the vestibule, in the immediate vicinity of the piriform aperture, the head of the inferior turbinate and the septal body provide lateral and medial erectile tissues that dynamically modulate the size of the nasal valve. By Poiseuille's Law, the flow through the nasal valve is proportional to the radius of the opening raised to the fourth power, and thus small changes in airway caliber can have profound effects on flow and resistance. In this way, the erectile tissue of the internal nasal valve plays a very important function by providing variable resistance in parallel with the stable resistance of the fixed structures [22]. Changes in mucosal microvascular tone induced by physiologic and pathologic influences exponentially alter nasal airflow resistance.

Summary

The anatomy and physiology of the internal nose are too often left out of consideration by those undertaking rhinoplastic surgery. Knowledge of the basic physiologic mechanisms of normal nasal function should be a prerequisite for operating on the external structures, because of the close relationship between form and function. Despite the fact that our culture places emphasis only on the visible portion of the nose, individual patients trust the rhinoplastic surgeon to respect and preserve the functions of that critical portion that remains unseen.

References

[1] Griesman B. Base of nose anatomy and plastic repair. Arch Otolaryngol Head Neck Surg 1950;51:541–56.
[2] Cottle MH. The structure and function of the nasal vestibule. AMA Arch Otolaryngol 1955;62(2):173–81.
[3] Straatsma BR, Straatsma CR. The anatomical relationship of the lateral nasal cartilage to the nasal bone and the cartilaginous nasal septum. Plast Reconstr Surg 1951;8(6):433–55.
[4] Cole P. Respiratory role of the upper airways. St. Louis (MO): Mosby Year Book; 1993.
[5] Lanza DC, Kennedy DW, Koltai PJ. Applied nasal anatomy and embryology. Ear Nose Throat J 1991;70(7):416–22.
[6] Cauna N. Blood and nerve supply of the nasal lining. In: Proctor D, editor. The nose. Amsterdam: Elsevier Biomedical Press; 1982. p. 45–70.
[7] Stammberger H. Functional endoscopic sinus surgery. Philadelphia: BC Decker; 1991.
[8] Dawes JD, Prichard MM. Studies of the vascular arrangements of the nose. J Anat 1953;87(3):311–22.
[9] Lang J. Clinical anatomy of the nose, nasal cavity, and paranasal sinuses. New York: Thieme Medical Publishers; 1989.
[10] Hasegawa M, Kern EB. The human nasal cycle. Mayo Clin Proc 1977;52(1):28–34.
[11] Cauna N, Cauna D, Hinderer KH. Innervation of human nasal glands. J Neurocytol 1972;1(1):49–60.
[12] Mygind N, Pedersen M, Neilson M. Morphology of the upper airway epithelium. In: Proctor D, editor. The nose. Amsterdam: Elsevier Biomedical Press; 1982. p. 71–98.
[13] Widdicombe W, Wells UM. Airway secretions. In: Andersen DPI, editor. The nose: upper airway physiology and the atmospheric environment. New York: Elsevier Biomedical Press; 1982. p. 215–44.
[14] Quinlan MF, Salman SD, Swift DL, Wagner Jr HN, Proctor DF. Measurement of mucociliary function in man. Am Rev Respir Dis 1969;99(1):13–23.
[15] Baroody F. Anatomy and physiology. In: Naclerio RM, Durham SR, Mygind N, editors. Rhinitis: mechanisms and management. New York: Marcel Dekker; 1999. p. 1–22.
[16] Bridger GP, Proctor DF. Maximum nasal inspiratory flow and nasal resistance. Ann Otol Rhinol Laryngol 1970;79(3):481–8.
[17] Lane AP, Drake AF, Warren DW. Perceptual and

physiologic effects of histamine challenge on nasal breathing. Am J Rhinol 2000;14(1):1–5.

[18] Niinimaa V, Cole P, Mintz S, Shephard RJ. The switching point from nasal to oronasal breathing. Respir Physiol 1980;42(1):61–71.

[19] Swift D, Proctor DF. Access of air to the respiratory tract. In: Brain J, Proctor DF, Reid LM, editors. Respiratory defense mechanisms. Chapter 3. New York: Marcel Dekker; 1977.

[20] Kasperbauer JL, Kern EB. Nasal valve physiology. Implications in nasal surgery. Otolaryngol Clin N Am 1987;20(4):699–719.

[21] Cole P, Haight JS, Love L, Oprysk D. Dynamic components of nasal resistance. Am Rev Respir Dis 1985; 132(6):1229–32.

[22] Cole P. The four components of the nasal valve. Am J Rhinol 2003;17(2):107–10.