Anti-VEGF Agents in the Treatment of Neovascular Age-related Macular Degeneration: Applying Clinical Trial Results to the Treatment of Everyday Patients

DAVID M. BROWN AND CARL D. REGILLO

• PURPOSE: The vision gains reported with monthly intravitreal ranibizumab in the MARINA and ANCHOR trials led to an immediate paradigm shift in the treatment of neovascular AMD with retina physicians universally switching to the pan-VEGF blocking agents ranibizumab and bevacizumab, and patients expecting visual improvement. As these agents are primarily used on a pro re nata (PRN) dosing schedule (because neither patients nor physicians want monthly injections), the factors involved in making the treatment and retreatment decisions are very important in any attempt to maximize vision gain.

• DESIGN: Analysis of literature, ongoing clinical trials, and the clinical assessments that can aid clinicians in treatment and retreatment decisions.

• METHODS: Literature review and perspective.

• RESULTS: If a monthly injection protocol is not used, clinicians should use both functional and anatomic criteria to attempt to guide treatment and retreatment decisions. Qualitative optical coherence tomography (OCT) appears to be the most sensitive and practical assessment tool to determine anatomic response to treatment but should be used in conjunction with clinical examination.

• CONCLUSIONS: If monthly intravitreal injections are not performed, a combination of clinical examination (looking for new hemorrhage) and qualitative OCT (to assess response to treatment and early signs of recurrent leakage) can be used to guide anti-vascular endothelial growth factor (anti-VEGF), treatments with the goal of maintaining a "normal" retinal anatomy in an attempt to maximize the benefit (visual acuity gains) to risk (number of injections required) ratio. (Am J Ophthalmol 2007;144:627–637. © 2007 by Elsevier Inc. All rights reserved.)

TREATMENTS FOR NEOVASCULAR AGE-RELATED MACULAR degeneration (AMD) have improved dramatically since 1999 when the only treatment clinically available was Macular Photocoagulation Study (MPS)-style laser photocoagulation.[1] For subfoveal choroidal neovascularization (CNV), MPS guided laser photocoagulation leads to an immediate, permanent loss of central vision with its aim to limit the spread of the uncontrollable disease analogous to surgical amputation in general surgery. Photodynamic therapy with verteporfin (vPDT) became available in 2000. Unlike laser photocoagulation, vPDT involves relatively selective photochemical damage to CNV, with less damage to the associated choroid and retina. vPDT decreased the rate of moderate and severe vision loss, demonstrated improved vision (a gain of ≥15 letters on the Early Treatment of Diabetic Retinopathy Study (ETDRS) chart in up to 6% of patients with subfoveal CNV secondary to AMD) (Table).[2,3] However, 30% to 40% of vPDT-treated patients still lost at least 15 letters from the pretreatment baseline visual acuity (VA). Furthermore, although PDT clinical trials showed consistent benefit when treating patients with subfoveal predominantly classic CNV, other CNV subtypes appeared to benefit only if the lesion was relatively small in size.[2,3,7] Combining vPDT treatment with intravitreal (ITV) injection of a corticosteroid was popularized by Spaide and associates.[8] This combination approach appeared to decrease the number of required vPDT treatments to achieve a nonleaking CNV, but has yet to demonstrate definitive, clinically significant, added visual benefit compared with vPDT alone.

THE SEARCH FOR A MORE TARGETED TREATMENT

NEOVASCULAR AMD IS ASSOCIATED WITH INCREASED VASCULAR permeability as well as CNV infiltration. This increase in vascular permeability leads to abnormal fluid collection within or below the retina that causes visual dysfunction when it involves the center of the macula. For the past 50 years, researchers have attempted to determine the underlying mechanism of neovascularization and vascular leakage in the eye. In 1983, Senger and associates identified a "tumor vascular permeability factor" (VPF) that could induce vascular leakage.[9] In 1989, Ferrara and Henzel reported the isolation and sequencing of an endothelial cell mitogen dubbed vascular endothelial growth factor (VEGF),[10] which was later determined to be the same molecule as VPF. VEGF-A (also referred to as simply VEGF) is a vascular endothelial cell-specific growth factor

Accepted for publication Jun 20, 2007.

From the Vitreoretinal Consultants, Houston, Texas (D.M.B.); and the Wills Eye Institute, Philadelphia, Pennsylvania (C.D.R.).

Inquiries to David M. Brown, Vitreoretinal Consultants, Texas Medical Center Office, Scurlock Tower, 6560 Fannin, Suite 750, Houston, TX 77030; e-mail: dmbmd@houstonretina.com.

0002-9394/07/$32.00
doi:10.1016/j.ajo.2007.06.039

© 2007 BY ELSEVIER INC. ALL RIGHTS RESERVED.

Petitioner Fresenius Ex. 1025, 0001

TABLE. Summary of Published Results for Several Neovascular Age-Related Macular Degeneration Studies Using 2-m Early Treatment of Diabetic Retinopathy Study Refracted Visual Acuities

Study	Study Design	Study Arms	Efficacy Endpoints: Mean Change in letters of VA from Baseline*	Efficacy Endpoints: ≥15 Letters Lost (% Patients)*	Efficacy Endpoints: ≥15 Letters Gained (% Patients)*
TAP (12-month time point)[2]	PDT every 3 months for	PDT	−2.2	39*	6
	24 months (n = 609)	Placebo	−3.5	54	2
VISION (12-month time point)[4]	ITV pegaptanib every 6	0.3 mg	N/A	30*	6
	weeks for 24 months	Sham		45	2
	(n = 1,186)				
MARINA (24-month time point)[5]	ITV ranibizumab monthly	0.3 mg	5.4*	8*	26*
	for 24 months	0.5 mg	6.6*	10*	33*
	(n = 716)	Sham	−14.9	47	4
ANCHOR (12-month time point)[6]	ITV ranibizumab monthly	0.3 mg	8.5*	6*	36*
	for 24 months	0.5 mg	11.3*	4*	40*
	(n = 423)	PDT	−9.5	36	6
PIER (12-month time point)	ITV ranibizumab monthly	0.3 mg	−1.6*	17*	12
(Regillo et al, unpublished	for 3 months, then	0.5 mg	−0.2*	10*	13
data)	every 3 months for a	Sham	−16.3	51	10
	total of 24 months				
	(n = 184)				

ITV = intravitreal; N/A = not applicable (not directly reported in the article); PDT = photodynamic therapy; VA = visual acuity.
*$P \leq .001$ compared with the control arm.

and, within the VEGF family, is the most potent promoter of angiogenesis and inducer of vascular permeability.[11] In addition, VEGF-A is 50,000 times more potent as an enhancer of vascular permeability than is histamine.[12] VEGF-A has been shown to be involved in the development of ocular diseases such as neovascular AMD.[13]

The first ocular anti-VEGF agent was an aptomer-based therapeutic designed to target $VEGF_{165}$, the most abundant isoform of VEGF-A in ocular disease. The VISION trials using this aptomer (Pegaptanib sodium, Macugen; OSI/Eyetech Pharmaceuticals, New York, New York, USA) demonstrated efficacy in all CNV subtypes secondary to AMD, and the number of pegaptanib-treated patients with all CNV subtypes who had 15-letter improvements was comparable to PDT-treated patients with predominantly classic CNV secondary to AMD in other studies (4% to 6%; Table).[4] The proportion of patients losing ≥15 letters from the pretreatment baseline VA, however, was still about 40% despite ITV pegaptanib injections every six weeks during the two-year trial. Nonetheless, because of the broad treatment effect with some visual benefit in all CNV subtypes secondary to AMD, along with the good safety profile, pegaptanib sodium was approved by the Food and Drug Administration in 2004 for the treatment of neovascular AMD.

Ranibizumab (Lucentis; Genentech, Inc, South San Francisco, California, USA) is an anti-VEGF agent that is Food and Drug Administration approved for the treatment of all subfoveal CNV subtypes secondary to AMD. Ranibizumab is a humanized antigen-binding fragment that targets all VEGF-A isoforms and their biologically active degradation products, and it has been shown to bind and inhibit $VEGF_{165}$, $VEGF_{121}$, and $VEGF_{110}$. Ranibizumab has been investigated in clinical trials in patients with neovascular AMD since 2000 (Table; Figure 1). MARINA was a randomized Phase III clinical trial of minimally classic or occult CNV secondary to AMD treated with monthly ITV ranibizumab (0.3 mg or 0.5 mg) or sham injections for 24 months. Anatomically, ranibizumab treatment was associated with arrested growth of and cessation of leakage from the CNV (including intense, progressive staining of the retinal pigment epithelium [RPE]). The mean change from baseline in each of the ranibizumab-treated groups differed significantly from the sham-injected group at 12 and 24 months ($P < .001$). Mean retinal thickness on ocular coherence tomography (OCT) was reduced dramatically in the first week after initial treatment, and this reduction was associated with mean improvement in VA. With monthly injections, both the reduction in retinal thickness and the VA gains were maintained. At the end of the 24-month study, significantly more ranibizumab-treated patients had maintained or improved vision (lost <15 letters of VA) than sham-injected patients, with 92% and 90% of ranibizumab-treated patients (0.3 mg and 0.5 mg, respectively) losing fewer than 15 letters of VA, compared with 53% of sham-injected patients ($P < .001$).[5] In addition, the mean change in VA from baseline was a gain of 5.4 and 6.6

Petitioner Fresenius Ex. 1025, 0002

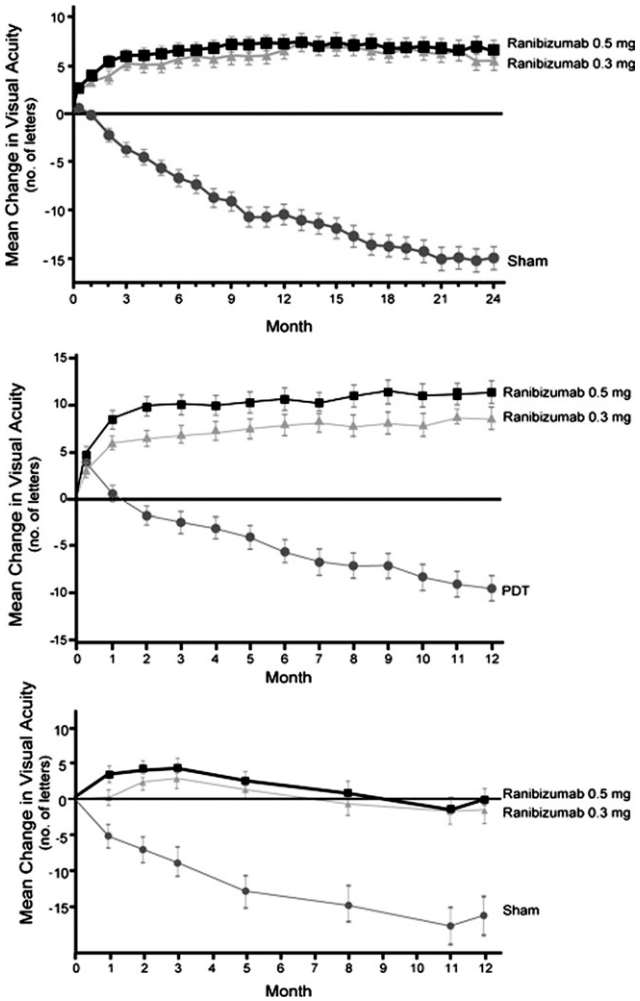

FIGURE 1. Visual acuity over time for the (Upper panel) MARINA, (Middle panel) ANCHOR, and (Lower panel) PIER Phase III trials. All three panels show the mean change from baseline in visual acuity [VA] (number of letters) over time (months). The black boxes represent the mean change in VA for the 0.5 mg ranibizumab group, the gray triangles represent the mean change in VA for the 0.3 mg group, and the gray circles represent the mean change in VA for the control group in each of the studies. Pairwise analysis of variance (ANOVA) adjusting for the VA score on day zero was used to analyze the mean change in VA from baseline at each monthly assessment. At each monthly assessment, there was a significant difference between the ranibizumab and control groups. (MARINA and ANCHOR panels are reproduced with permission from Rosenfeld and associates, N Engl J Med 2006;355:1419–1431 and Brown and associates, N Engl J Med 2006;355:1432–1444).

letters for ranibizumab-treated patients (0.3 mg and 0.5 mg, respectively), compared with a loss of 14.9 letters in sham-treated patients ($P < .001$). After 24 months, 26% and 33% of ranibizumab-treated patients gained 15 or more letters of VA (0.3 and 0.5 mg, respectively), compared with 4% of sham-injected patients ($P < .001$).[5]

ANCHOR was a randomized Phase III clinical trial of patients with predominantly classic CNV secondary to AMD treated with monthly ITV ranibizumab (0.3 mg or 0.5 mg) and sham PDT or sham injection and PDT for 24 months. Anatomically, fluorescein angiography (FA) at 12 months revealed a dramatic reduction of leakage from the CNV (and area of intense, progressive staining of the RPE) compared with baseline among ranibizumab-treated patients compared with an overall increase in leakage among PDT-treated patients ($P < .01$). Analogous to the anatomic changes seen on OCT in the MARINA trial, retinal thickness was markedly reduced within a week of initial treatment, and this reduction was associated with commensurate gains in VA. Repeated injections maintained this anatomical improvement and allowed for unprecedented gains in VA at the primary endpoint at 12 months. At the 12-month time point, 94% and 96% of ranibizumab-treated patients (0.3 mg and 0.5 mg, respectively) had lost fewer than 15 letters of VA, compared with 64% of PDT-treated patients ($P < .0001$).[6] In addition, the mean change in VA from baseline was a gain of 8.5 and 11.3 letters for ranibizumab-treated patients (0.3 mg and 0.5 mg, respectively), compared with a loss of 9.5 letters in PDT-treated patients ($P < .001$).[6] After 12 months, 36% and 40% of ranibizumab-treated patients gained 15 or more letters of VA (0.3 and 0.5 mg, respectively), compared with 6% of PDT-treated patients ($P < .001$).[6]

While ranibizumab is an anti-VEGF antibody fragment, bevacizumab is a related humanized, full-length anti-VEGF antibody that was also developed by Genentech. At the July 2005 American Society of Retina Specialists (ASRS) meeting in Montreal, Canada, Phillip Rosenfeld, MD, presented a small series of patients with neovascular AMD treated with off-label ITV bevacizumab (Food and Drug Administration approved for intravenous treatment of metastatic colon cancer in combination with chemotherapy). The preliminary results from this series demonstrated good short-term safety and efficacy similar to that seen in patients treated with ranibizumab.[14] Other investigators have since demonstrated comparable clinical results with larger but still short-term and uncontrolled series of patients with neovascular AMD treated with off-label ITV bevacizumab.[15–17] These reports resulted in a relatively quick and widespread adoption of off-label ITV bevacizumab by retina specialists before the clinical availability of ranibizumab. Bevacizumab use has continued around the world, and increasing pharmacokinetic, histopathology, and toxicity studies have subsequently been performed in RPE cell lines and bovine, rabbit, pig, and monkey models that demonstrate no evidence of ocular toxicity at the dose commonly administered.[18–20] Durability of effect of bevacizumab appears comparable to ranibizumab with apparent intravitreal concentrations up to one month after injection.[21] There are no data available to assess the relative efficacy and safety of off-label ITV bevacizumab but with support from the National Eye Institute, The

Petitioner Fresenius Ex. 1025, 0003

Comparison of Age-Related Macular Degeneration Treatments Trial (CATT) is being organized to determine the safety and efficacy of intravitreal bevacizumab compared with ranibizumab.[22] The trial will be a head-to-head, prospective, randomized, masked clinical trial of ranibizumab and off-label ITV bevacizumab in 1,200 patients. Monthly ranibizumab and bevacizumab injection regimens will be included as well as pro re nata (PRN) treatment regimens with both agents and is expected to begin this year. Direct comparisons of the efficacy and potential adverse events of off-label ITV bevacizumab and ranibizumab can only be made at the conclusion of such a head-to-head study.

OCULAR RISKS AND POSSIBLE SYSTEMIC RISKS OF ANTI-VEGF THERAPY

THE OCULAR RISKS OF ANTI-VEGF INJECTIONS APPEAR TO be primarily related to the injection process itself. In the MARINA, ANCHOR, and PIER trials, ranibizumab treatment was associated with a 1.7% or lower rate of key serious ocular adverse events such as endophthalmitis, retinal detachment, and uveitis.[5,6] The theoretical risk exists that intraocular pan-VEGF suppression may cause choriocapillaris damage. However, these findings have not been collaborated by wide-field angiography looking for choriocapillaris damage in our patients who had more than 24 injections of ranibizumab (unpublished data). Because intravenous anti-VEGF blockade is known to be associated with increased rates of thromboembolic events, systemic absorption of these agents from intraocular injections may increase these rates in treated patients. In animal studies, ITV ranibizumab was cleared from the vitreous with a half-life of approximately three days.[23] After reaching a maximum at approximately one day, serum concentrations decline in parallel to vitreous concentrations with a systemic level <1000 times the vitreous concentrations. In human trials, serum ranibizumab levels ranged from 0.3 ng/ml to 2.36 ng/ml following monthly injections.[24] These levels were below the concentration of ranibizumab (11 ng/ml to 27 ng/ml) thought to be necessary to inhibit 50% of the biologic activity of VEGF-A. Systemic absorption of ITV bevacizumab has also been demonstrated in approximately 11.8% of patients (Csaky K, personal communication). This may be significant given bevacizumab's terminal half-life in the systemic circulation is approximately 20 days compared with 12 hours for ranibizumab. In the initial Phase III trials with ranibizumab, the actual key serious nonocular adverse events were not found to be significantly different than the corresponding control groups.[5,6] However, in January 2007, Genentech released data that showed in preliminary analysis of the SAILOR cohort (a Phase IIIb study with much larger sample size than the Phase III trials), that the 0.5 mg dose had a significantly higher risk of stroke compared with the 0.3 mg dose (1.2% vs 0.3%; $P = .02$).[25] Ongoing safety analysis is being performed in patients in the SAILOR trial as well as longer term follow-up in the HORIZON trial (the extension study of MARINA and ANCHOR). The CATT trial is also designed to provide systemic safety data for both ranibizumab and bevacizumab.

ALTERNATIVE DOSING STRATEGIES FOR ANTI-VEGF AGENTS

BECAUSE OF BOTH OCULAR AND SYSTEMIC SAFETY CONcerns, as well as cost and physician and patient convenience issues, ideally an alternative dosing strategy can be used to decrease the number of required injections for anti-VEGF agents. A recently completed Phase IIIb study, PIER, was a randomized, double-masked, sham-controlled clinical trial of patients with subfoveal CNV secondary to AMD treated with ITV ranibizumab monthly for the first three months, followed by mandated quarterly dosing for 24 months (Regillo et al, 2006, unpublished data). For the first three months, both the anatomic improvements on OCT and the VA gains mirrored the ANCHOR and MARINA trials. After this period, the average VA decreased to baseline levels, because quarterly injections were unable to maintain the anatomic improvements seen with monthly injections. This is thought to be directly related to the mandated quarterly dosing in PIER, with some patients requiring more frequent injections to maintain the anatomic and visual improvements achieved in the first three months of the study. At the 12-month time point, the mean change in VA from baseline was a loss of 1.6 and 0.2 letters for ranibizumab-treated patients (0.3 mg and 0.5 mg, respectively), compared with a loss of 16.3 letters for sham-treated patients ($P < .0001$). In addition, 83% and 90% of ranibizumab-treated patients (0.3 and 0.5 mg, respectively) lost fewer than 15 letters of VA, compared with 49% of sham-injected patients. After 12 months, 12% and 13% of ranibizumab-treated patients gained 15 or more letters of VA (0.3 and 0.5 mg, respectively), compared with 10% of sham-injected patients. Although the PIER trial results are far superior to those seen with any previous agent in AMD trials, the high expectations of overall improvement in mean visual acuity demonstrated in the ANCHOR and MARINA trials were not achieved. These initial PIER study data show that treating patients with CNV secondary to AMD every three months is less effective than monthly dosing with ranibizumab.

Another small, uncontrolled, but very well-designed study exploring an alternate dosing strategy for ranibizumab is PrONTO, a prospective OCT imaging study of patients with all subtypes of CNV secondary to AMD treated with ITV ranibizumab monthly for the first two months (three injections), followed by PRN dosing there-

Petitioner Fresenius Ex. 1025, 0004

after.[26] OCT was used to evaluate quantitative retinal thickness, and retreatment decisions were based on these quantitative OCT measurements as well as on other criteria, such as visual loss associated with any edema observed on qualitative OCT, the presence of new classic CNV on FA, and the presence of new hemorrhage or persistent fluid on qualitative OCT. Of note, fluid was observed with qualitative OCT 100% of the time at the time of ITV injection, whereas retinal thickness increases greater than 100 μm were observed with quantitative OCT and were the reason for injection only 16% of the time.[26] ITV injections were also administered for decreased vision with evidence of fluid on qualitative OCT 41% of the time, for persistent fluid 29% of the time, for new subretinal hemorrhage with concomitant fluid on qualitative OCT 7% of the time, and for new classic CNV observed on FA as well as fluid on qualitative OCT 6% of the time. Preliminary results from the 40 patients enrolled in the study show that mean VA from baseline improved by 9.3 letters in ranibizumab-treated patients ($P < .001$) and mean central retinal thickness decreased by 178 μm ($P < .001$). At one month (one injection), 85% of ranibizumab-treated patients had resolution of intraretinal, subretinal edema and 77.5% had resolution of subretinal fluid. At two months (two injections), 92.5% of ranibizumab-treated patients had resolution of subretinal fluid and intraretinal cysts, and at three months (three injections), 97.5% had resolution of subretinal fluid, whereas 92.5% had resolution of intraretinal cysts.[26] At 12 months, the mean number of injections was 5.6, and 17.5% (7/40) of patients did not require retreatment after the initial three ITV injections of ranibizumab. This OCT-guided dosing strategy achieved results comparable to the MARINA and ANCHOR trials with less than half of the required monthly injections used in the Phase III trials.

WHY DO PAN-VEGF BLOCKING AGENTS IMPROVE VA IN NEOVASCULAR AMD?

THERE ARE NUMEROUS EXAMPLES OF RETINAL DISEASES IN which the anatomy of the fovea must be restored before visual improvements can occur. Two examples are macula-off retinal detachments and Irvine-Gass cystoid macular edema, where VA improves only when the anatomic pathology is corrected. Conversely, irreversible visual loss from progressive intraretinal fibrosis or atrophy occurs when the retina is subjected to prolonged subretinal and intraretinal edema as in diffuse diabetic macular edema and chronic central serous retinopathy. The MARINA and ANCHOR trials demonstrated a marked reduction in leakage from CNV in ranibizumab-treated patients compared with increased leakage in the controls, with qualitative OCT images of the retina of ranibizumab-treated patients appearing completely dry in almost all patients after 24 ITV injections. These anatomic changes were associated with overall visual improvement in ranibizumab-treated patients.

No previous treatment has been as efficacious as ranibizumab at eliminating the edema in the subretinal space and neurosensory retina in neovascular AMD. Pegaptanib sodium, which theoretically only blocks one isoform of VEGF-A in the eye, rarely eliminates all macular edema even with continued use. In contrast, most ranibizumab-treated patients (>70%) have resolution of all macular edema as seen by OCT within one month of their first injection, and more than 90% have resolution of all edema after three consecutive monthly injections.[26] The visual gains seen in the initial three months of therapy in the ANCHOR, MARINA, and PIER trials are very similar and demonstrate visual gains very quickly after initiation of therapy and resolution of retinal edema. The on-average return to baseline (loss of the improvement in VA achieved in the first three months) in the PIER trial is likely related to the inability of mandated quarterly ITV ranibizumab injections to eliminate CNV leakage for all patients; some patients likely required more frequent ITV injections, whereas others could have used less frequent ITV injections, as supported by OCT findings in the trial (Regillo et al, 2006, unpublished data). This suggests that greater control through a criteria-based retreatment strategy may be warranted.

• **OCT AND THE MANAGEMENT OF OCULAR DISEASES:** OCT is a noninvasive diagnostic imaging tool that can perform high-resolution, micron-scale, cross-sectional, or tomographic imaging in tissue by measuring the echo time delay and intensity of backscattered light.[27] OCT allows real-time in situ imaging of tissue with resolution of up to 15 μm and enables examination of the epiretinal, intraretinal, and subretinal morphology.[27] OCT uses several measures to generate its images, including the central subfield, center point thickness, automated retinal boundary lines, inner retinal surface, and the RPE band. In OCT images, bright colors such as red and white represent regions of high reflectivity such as the nerve fiber layer, the plexiform layers, or the RPE, whereas dark colors such as blue or black represent regions of low reflectivity, such as the nuclear layers and photoreceptor inner and outer segments. Only the hyporeflective photoreceptor layer is visible at the foveola, where the indentation of the foveal pit is at its maximum.

OCT has been used in the management of many retinal diseases, including macular holes,[28] macular edema,[29,30] and neovascular AMD.[31] In AMD, OCT is useful in evaluating and documenting retinal angiomatous proliferation (RAP) lesions before and after laser photocoagulation in patients with RAP lesions secondary to AMD.[31] The early stages of RAP are difficult to detect with both contact lens biomicroscopy and angiographic examinations, but typical intraretinal features can be observed with

Petitioner Fresenius Ex. 1025, 0005

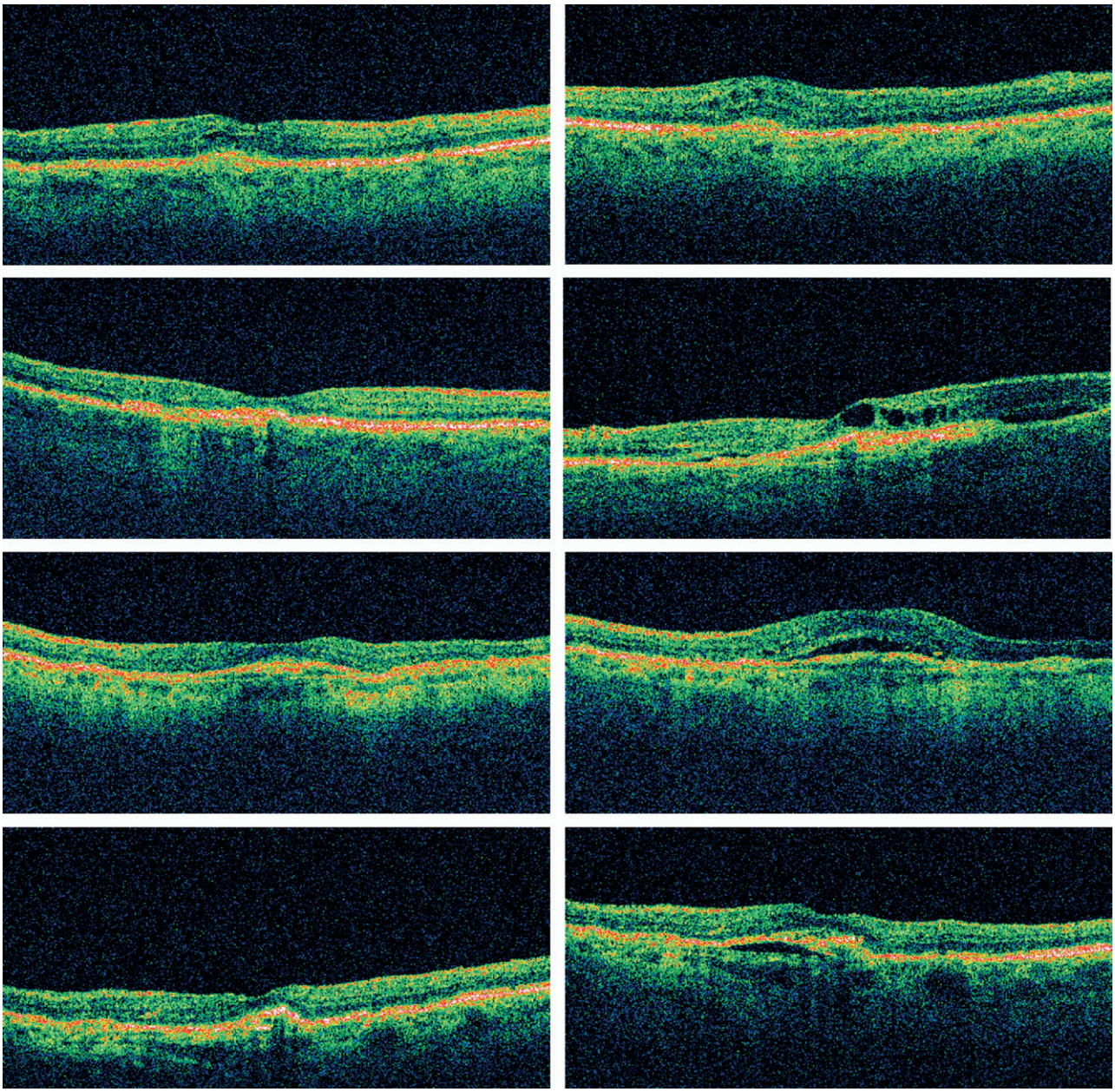

FIGURE 2. Examples of optical coherence therapy (OCT) images from different patients being treated with ranibizumab for neovascular age-related macular degeneration (AMD) demonstrating various patterns of recurrent choroidal neovascularization (CNV) leakage such as (Top row) diffuse edema; (Second row) intraretinal cysts; (Third row) subretinal fluid; or (Bottom row) subretinal pigment epithelium (RPE) fluid. Top row (Left): Three months after completing the MARINA protocol, the patient's visual acuity (VA) in the involved eye was 20/25 with no injections for four months. Automated center point foveal thickness was 263 μ. (Right) Diffuse edema: The first sign of disease progression was evident on OCT six weeks later with diffuse edema and loss of the foveal depression. The VA declined to 20/50. Automated center point thickness increased to 341 μ. Second row (Left): The patient finished the MARINA study with a VA of 20/63 in the treated eye and a normal foveal depression but quantitative OCT revealed atrophy with a foveal central thickness of 98 μ. (Right) Intraretinal cysts: Five months after the patient's last required intravitreal injection in the study, intraretinal cysts developed with no change in her best-corrected VA (20/63). Center point foveal thickness increased but was still in "normal" range at 178 μ. Third row (Left): The patient finished the MARINA study with a VA of 20/25 in the treated eye and an OCT scan showing a near normal appearing foveal contour with underlying CNV. The central foveal thickness was 138 μ. (Right) Subretinal fluid: Just six weeks into the extension study (10 weeks after her last scheduled injection in the MARINA trial), subretinal fluid became evident on the OCT with a commensurate decrease in VA to 20/40. Quantitative center point foveal thickness increased to 204 μ. Bottom row (Left): The patient completed the MARINA study with a VA of 20/50 and no evidence of CNV leakage determined by OCT. Automated center point foveal thickness was 160 μ. (Right) Sub-RPE fluid: Three months after her last ITV ranibizumab injection, OCT revealed fluid in the sub-RPE space. Automated center point foveal thickness increased slightly to 190 μ, but VA improved to 20/25.

Petitioner Fresenius Ex. 1025, 0006

qualitative OCT.[31] In the management of diabetic retinopathy, OCT has been demonstrated to be more sensitive than contact lens biomicroscopy for the detection of mild foveal thickening in patients with diabetic macular edema.[29] An OCT study of patients with diabetic macular edema found that best-corrected VA was significantly correlated with central foveal thickness ($r = -0.528$; $P < .01$).[30] There was 77% agreement between OCT and clinical examination. In addition, cystoid macular edema was detected in 15.4% of eyes with OCT, but cystoid macular edema was not detected with contact lens biomicroscopy and FA in 40% and 60% of these eyes, respectively. In this study, OCT detected serous foveal detachments detected that could not be seen with either contact lens biomicroscopy or FA.[30] This finding illustrates that OCT can document subtle disease activity in macular disease often undetectable by standard clinical examinations.

• **QUANTITATIVE vs QUALITATIVE OCT:** Quantitative OCT uses fast macular thickness-based acquisition protocols, in which six radial scans are centered on a patient's fixation and then compressed into one scan, which can be acquired quickly (1.92 seconds) and contains 128 A-scans per line.[31] However, fast macular thickness-based acquisition protocols provide low-resolution images that have some inherent errors particularly in eyes with neovascular AMD.[32] Errors of retinal boundary detection and thickness measurement were observed in 92% of AMD eyes when fast macular thickness-based acquisition protocols were used.[32] Poor VA in patients with neovascular AMD makes fixation difficult to maintain, and the center point thickness measurement is dependent on the fovea being in the center of each vector line. Thus any shift of the patient's fixation causes significant error. Even when fixation is excellent, the anatomic heterogeneity of CNV lesions (eccentric with variable intraretinal cysts and subretinal fluid pockets) often misleads the automated detection of retinal boundaries necessary for accurate quantitative measurements. An additional and significant problem of quantitative OCT is that sub-RPE fluid (pigment epithelial detachment) is not quantified even if fixation and retinal boundary detection is accurate.

In contrast, qualitative OCT using normal acquisition protocols (Macular Thickness Map acquisition on the Stratus OCT 3, software version 4.1; Carl Zeiss Meditec, Dublin, California, USA) provides a transverse resolution of 512 A-scans per B-scan that yields more detailed intraretinal information.[31] Fortunately, fixation difficulties inherent with AMD patients do not affect qualitative OCT analysis because it relies much less on each vector cut being centered on fixation. Qualitative OCT simply looks for any anatomic evidence of CNV leakage in the imaged tissues. This more detailed scan is useful for visualizing neovascular-associated leakage and provides higher-resolution images without relying on the machine to interpret the images. The actual thickness and morphology of the CNV complex are quite difficult to assess on OCT images because the posterior CNV boundary is difficult to ascertain. Higher resolution OCT machines (in development by both Topcon and Carl Zeiss Meditec) may allow this component to be more readily assessed. Until higher resolution OCT images are available to facilitate this assessment, however, one must look for evidence of CNV leakage (or VEGF-A-mediated leakage from other sources) in the intraretinal, subretinal, and sub-RPE space using the available OCT protocols.

Just as there are recognizable OCT patterns in diabetic macular edema,[33] specific patterns of structural changes resulting from CNV leakage can be seen on qualitative OCT in patients with neovascular AMD. To define the patterns of leakage after successful anatomic correction of CNV leakage with ranibizumab, we monitored qualitative OCT at our clinical trial center (which recruited and followed the largest number of patients in both the ANCHOR and MARINA Phase III clinical trials) with monthly ETDRS refractions, clinical examinations, and high-resolution qualitative OCT. We looked for the first anatomic changes indicating recurrent disease activity on the six radial qualitative OCT scans (using Macular Thickness Map acquisition protocol). There were four distinct patterns: diffuse retinal edema, intraretinal cysts, subretinal fluid, and sub-RPE fluid or serous pigment epithelial detachment (Figure 2). Diffuse retinal edema is a sponge-like thickening that appears as increased retinal thickness with areas of reduced intraretinal reflectivity compared with retina without thickening (Figure 2, Top row). Intraretinal cysts (Figure 2, Second row) and subretinal fluid (Figure 2, Third row) are easy to identify as areas of low reflectivity that are "empty" on the OCT and represent frank fluid in the retina and subretinal space, respectively. Sub-RPE fluid is also optically empty on OCT (Figure 2, Bottom row) and can present as one of the first signs of recurrence of leakage following cessation of anti-VEGF therapy.

In our series of 28 patients from the MARINA and ANCHOR studies, only one had any evidence of disease activity on qualitative OCT at final follow-up (unpublished data). These patients were then followed monthly to determine the initial patterns associated with disease recurrence. Sixty percent of eyes presented with only one pattern. Among these patients, the most common pattern was intraretinal cysts (seen in 30% of patients), whereas 20% presented with subretinal fluid, and 5% each presented with diffuse edema or sub-RPE fluid. Diffuse edema is the most difficult to ascertain; but fortunately, only 10% of cases presented with this pattern (either alone or in combination with other patterns). Overall, 95% of patients presented with at least one of the easier-to-detect patterns (intraretinal cysts, subretinal fluid, or sub-RPE fluid). All six cuts of the retinal thickness map should be assessed because most CNV secondary to AMD is asym-

Petitioner Fresenius Ex. 1025, 0007

metric; one cut or an average often misses early or subtle disease activity. Eccentric lesions are the most likely to present with abnormal patterns on only one or a few of the scans. Just as radiologists review every scan to interpret magnetic resonance imaging (MRI) and computed tomography (CT) studies, it is imperative for retinal specialists to analyze each of the scans in order to detect the first signs of disease recurrence.

ANATOMICALLY BASED CLINICAL MANAGEMENT OF PATIENTS WITH NEOVASCULAR AMD

THE MARINA AND ANCHOR TRIALS PROVIDE CLEAR EVIdence that monthly ranibizumab is safe and effective for the treatment of neovascular AMD.[5,6] However, many clinicians and patients are reluctant to commit to a strategy of 24 ITV injections in the first two years of treatment. VA gains in neovascular AMD (with any anti-VEGF agent) are typically seen only with concomitant anatomic "correction" of the fovea by the elimination of edema. Thus it is logical that a strategy that minimizes the duration of intraretinal edema might provide an alternative treatment approach with the potential for fewer injections but maximal visual gains. Because the PrONTO study (which relied on OCT-based morphology for retreatment) showed VA gains similar to MARINA and ANCHOR and required far fewer injections, we used a simplified PrONTO algorithm to guide our retreatment decisions in the extension studies after MARINA and ANCHOR. These continuation studies allowed retreatment up to once per month at the treating physician's discretion. Essentially, patients were followed with clinical examinations and qualitative OCT every four to six weeks to detect the first sign of disease recurrence. Patients were retreated if new hemorrhage was present on clinical exam or if any of the patterns indicating recurrence of CNV leakage (diffuse edema, intraretinal cysts, subretinal fluid, or sub-RPE fluid) could be seen on qualitative OCT examination.

In our series of 28 treated patients, 33% needed no retreatments in the extension study, because their OCT findings never changed. For those requiring retreatment, the mean time to retreatment was 108 days. This protocol allowed the VA gains achieved with the MARINA and ANCHOR protocols to be maintained (on average) in their third year of treatment (mean loss of two ETDRS letters). Mean VA improvement in this cohort was 6.9 letters (from their initial screening visit baseline three years earlier) with an average number of 4.2 injections in the third year of treatment. This approach, if used with nonstudy patients (although still requiring frequent clinical exams and OCTs), would have resulted in approximately $18,000 savings per year over mandatory monthly ranibizumab injections (at the Medicare allowable rate), even factoring in the cost of the extra OCT exams. Moreover, these patients had less exposure to the incremental potential risks of monthly intravitreal injections.

In our experience, clinical interpretation of the six high-resolution cuts obtained with serial qualitative OCT macular thickness map acquisition protocol exams allows us to monitor the biologic effects and duration of a treatment regimen, and we use this technique to help guide treatment and retreatment decisions in patients treated with both ranibizumab and bevacizumab. Although "anatomic" restoration of the normal retinal architecture is not always associated with improvement in VA, gains in VA generally cannot be achieved without this "anatomic" restoration (analogous to repairing macula-off retinal detachments). As with the improvements in VA observed after retinal detachment repair, gains in VA are most commonly seen in newly diagnosed disease and in retinas with less structural compromise. Some retreatment algorithms rely on VA losses before allowing retreatment with an anti-VEGF agent. This is difficult in a clinical setting because VA can be variable in eyes with neovascular AMD and very few retina patients have manifest refractions at every exam. Even if best-corrected VA is available, VA changes often lag behind anatomic changes. Rosenfeld demonstrated in the PrONTO for the first time ever a positive correlation with OCT changes and lagging visual acuity.[26] Because qualitative OCT examination and interpretation can demonstrate subtle disease activity before biomicroscopy and VA changes in AMD and other macular diseases, it is logical to use qualitative OCT along with other clinical parameters to guide retreatment decisions before they can effect visual acuity. The one-year data of the PrONTO trial appear to validate this assumption, showing VA improvements analogous to those seen in the MARINA and ANCHOR trials with only 5.6 average injections per year. Although the PrONTO protocol had two criteria which did not rely on OCT imaging (new subretinal hemorrhage or new classic choroidal neovascular membrane [CNVM]), in every case in which these retreatment criteria were used to guide treatment, qualitative OCT changes were noted by the investigators that would have prompted the injections. The CATT trial will also be evaluating both ranibizumab and bevacizumab using a qualitative OCT-based retreatment strategy such as that used in PrONTO. With both agents, restoration of the "normal" anatomy precedes VA improvements and maintaining this "normalized" anatomy with the least number of injections would be the goal of any ITV anti-VEGF regimen.

• **RECOMMENDATIONS FOR USING OCT IN PATIENTS WITH NEOVASCULAR AMD:** If patients with neovascular AMD cannot or will not be treated with monthly intravitreal anti-VEGF agents (as in the ANCHOR and MARINA protocols), it is reasonable to tailor the schedule of anti-VEGF ITV injections to the individual patient's response as

Petitioner Fresenius Ex. 1025, 0008

determined by clinical exam and qualitative OCT examinations. First, disease remission, as demonstrated by a lack of CNV-related intra- or subretinal fluid, must be achieved with sequential ITV injections of an anti-VEGF agent. Deturgescence of the retina should be accomplished before VA improvements can be expected. It is likely that two or three monthly ITV injections will be required to achieve resolution of all CNV-related fluid in the macula, as suggested by the PrONTO study results.[26] If VA gains do not correlate with anatomic improvement, fluorescein fundus angiography should be considered to rule out retinal pigment epithelial rip or persistent leakage that occasionally occurs in the absence of OCT changes. Ongoing follow-up with serial clinical examinations and qualitative OCT can determine the duration of the anti-VEGF anatomic response and the need for possible retreatments.

Retreatment should be based on each patient's clinical response and the frequency of monitoring should be tailored to each patient. In the MARINA, ANCHOR, and PIER studies, most gains in VA were achieved within the first few months. Ideally, the goal of retreatment should be to maintain these gains in VA. The 12-month results from the PIER study show that, for the average patient, quarterly injections alone are not sufficient to keep the retina "fluid-free" and to maintain the gains in VA observed with the first three monthly ITV injections of ranibizumab. To maintain improved VA in patients with neovascular AMD, we suggest that eyes be retreated at the first sign of CNV leakage on clinical or qualitative OCT with or without visual acuity changes. Specifically, retreatment should be considered if there is any evidence of disease progression either by clinical exam (new hemorrhage) or retinal edema (diffuse edema or intraretinal cysts), subretinal edema, or sub-RPE fluid on these qualitative OCT images (Figure 2). Alternatively "treat and extend" protocols can be used in an attempt to preempt any anatomic changes for as long as possible (again monitoring for qualitative OCT changes).[34] Although this technique will probably increase the average number of injections per patient, it should minimize anatomic damage from recurrent fluid. In certain circumstances, if a particular patient demonstrates a recognizable pattern of relapse, retreatment may be considered on a routine schedule even before the development of fluid accumulation. It is the author's experience that pigment epithelial detachments associated with definite CNVM often require longer injection regimens (six to nine injections). However, if a patient's VA remains poor even after all retinal, subretinal, and sub-RPE edema is resolved (such as counting fingers or worse), it is unlikely that continued injections will improve VA particularly if there is significant macular fibrosis. Additional clinical parameters that should be considered in retreatment decisions are the presence of new subretinal hemorrhage and the clinical or FA evidence of CNV leakage, which might occur outside the 1500-μm radius of the OCT map cuts. This anatomically based treatment strategy could be useful with any current or future agent that eliminates retinal, subretinal, or sub-RPE edema. If a particular agent does not achieve full leakage remission, more frequent dosing or a different agent should be used. Alternatively, combination therapy such as with PDT or ITV corticosteroids can be considered.

CONCLUSIONS AND FUTURE DIRECTIONS

THE VISUAL RESULTS ASSOCIATED WITH A MONTHLY anti-VEGF blockade in clinical trials are unprecedented in terms of maintaining or improving VA. In clinical practice, it is crucial to employ appropriate retreatment strategies to best replicate the visual results achieved in the MARINA and ANCHOR trials. To this end, if a monthly injection schedule is not feasible, clinicians must use anatomic and functional criteria to guide treatment decisions. Functional tests such as best-corrected VA even in conjunction with funduscopic examination are insufficient in helping the clinician to decide exactly when and how often to treat. Qualitative OCT is the most sensitive and practical assessment tool to determine anatomic response to treatment, but typically does not demonstrate new intraretinal or subretinal hemorrhage. A combination of clinical examination (looking for new hemorrhage) and qualitative OCT (to assess response to treatment and early signs of recurrent leakage) can be used to guide anti-VEGF treatments with the goal of maintaining a "normal" retinal anatomy in an attempt to maximize the benefit (VA gains) to risk (number of injections required) ratio. This type of strategy can be implemented with any current or future anti-VEGF agent to help determine retreatment decisions.

Pro re nata dosing strategies will need to be tested in a standardized fashion with adequate sample size to see how they compare with the MARINA and ANCHOR results. The CAAT trial includes two arms using PRN dosing (one bevacizumab and one ranibizumab), and Genentech is committed to a separate postmarketing ranibizumab study attempting to validate anatomic based retreatment strategies (Shams N, personal communication). Only at the conclusion of these studies can one determine whether the advantages of a PRN strategy (decreased risk and financial benefits) comes at the expense of letters of vision not gained.

Finding the ideal treatment for CNV secondary to AMD will likely require attacking multiple pathophysiologic pathways to address the complex disease mechanisms that lead to visual loss.[35] Effective monotherapy anti-VEGF agents such as ranibizumab are thought to block the neovascular stimulus, inhibit the growth of abnormal blood vessels, and eliminate edema. It appears to be primarily the anti-permeability effects of ranibizumab that eliminate retinal and subretinal edema that led to

Petitioner Fresenius Ex. 1025, 0009

the unprecedented improvements in VA seen in the ANCHOR and MARINA trials. Combining other types of therapy with an anti-VEGF agent may decrease the number of treatments required by addressing the non-VEGF components of the disease process. Pharmacotherapeutics that inhibit VEGF-A with a longer duration of action than ranibizumab or that can be incorporated in sustained-release delivery systems may be available in the near future. In addition, we encourage the use of qualitative OCT in future clinical trials to evaluate anatomic changes and potentially serve as a surrogate marker for changes in VA.

THIS STUDY RECEIVED RESEARCH SUPPORT FROM ACUITY PHARMACEUTICALS, PHILADELPHIA, PENNSYLVANIA, ALCON Pharmaceuticals, Fort Worth, Texas, Allergan, Irvine, California, Alimera, Alpharetta, Georgia, Eli Lilly, Indianapolis, Indiana, Eyetech Pharmaceuticals, Melville, New York, Genentech, South San Francisco, California, Carl Zeiss Meditec, Dublin, California, Regeneron Pharmaceuticals, Tarrytown, New York, Novartis Ophthalmics, East Hanover, New Jersey, Pfizer, New York, New York, and Q.L.T., Inc, Fort Collins, Colorado (Dr Brown). Dr Regillo received research support from Alcon, Acuity, Eyetech, Genentech, and Novartis. Genentech provided financial support for third-party editorial assistance in the initial drafts of this manuscript. Drs Brown and Regillo have both served on Scientific Advisory Boards for Eyetech, Genentech, and Novartis. Both authors were involved in design and conduct of study; collection, management, analysis, and interpretation of the data; and preparation, review, or approval of the manuscript.

REFERENCES

1. Macular Photocoagulation Study (MPS) Group. Argon laser photocoagulation for senile macular degeneration. Results of a randomized clinical trial. Arch Ophthalmol 1982;100:912–918.
2. Treatment of Age-related Macular Degeneration with Photodynamic Therapy (TAP) Study Group. Photodynamic therapy of subfoveal choroidal neovascularization in age-related macular degeneration with verteporfin: one-year results of 2 randomized clinical trials—TAP report. Arch Ophthalmol 1999;117:1329–1345.
3. Bressler NM. Photodynamic therapy of subfoveal choroidal neovascularization in age-related macular degeneration with verteporfin: two-year results of 2 randomized clinical trials—TAP Report no. 2. Arch Ophthalmol 2001;119:198–207.
4. Gragoudas ES, Adamis AP, Cunningham ET Jr, et al. Pegaptanib for neovascular age-related macular degeneration. N Engl J Med 2004;351:2805–2816.
5. Rosenfeld PJ, Brown DM, Heier JS, et al. Ranibizumab for neovascular age-related macular degeneration. N Engl J Med 2006;355:1419–1431.
6. Brown DM, Kaiser PK, Michels M, et al, for the Anchor Study Group. Comparison of ranibizumab and verteporfin photodynamic therapy for neovascular age-related macular degeneration. N Engl J Med 2006;355:1432–1444.
7. Verteporfin in Photodynamic Therapy Study Group. Verteporfin therapy of subfoveal choroidal neovascularization in age-related macular degeneration: two-year results of a randomized clinical trial including lesions with occult with no classic choroidal neovascularization—Verteporfin In Photodynamic Therapy Report no. 2. Am J Ophthalmol 2001;131:541–560.
8. Spaide RF, Sorenson J, Maranan L. Photodynamic therapy with verteporfin combined with intravitreal injection of triamcinolone acetonide for choroidal neovascularization. Ophthalmology 2005;112:301–304.
9. Senger DR, Galli SJ, Dvorak AM, et al. Tumor cells secrete a vascular permeability factor that promotes accumulation of ascites fluid. Science 1983;219:983–985.
10. Ferrara N, Henzel WJ. Pituitary follicular cells secrete a novel heparin-binding growth factor specific for vascular endothelial cells. Biochem Biophys Res Commun 1989;161:851–858.
11. Ferrara N, Gerber HP, LeCouter J. The biology of VEGF and its receptors. Nat Med 2003;9:669–676.
12. Senger DR, Connolly DT, Van de Water L, et al. Purification and NH2-terminal amino acid sequence of guinea pig tumor-secreted vascular permeability factor. Cancer Res 1990;50:1774–1778.
13. Kliffen M, Sharma HS, Mooy CM, et al. Increased expression of angiogenic growth factors in age-related maculopathy. Br J Ophthalmol 1997;81:154–162.
14. Rich RM, Rosenfeld PJ, Puliafito C, et al. Short-term safety and efficacy of intravitreal bevacizumab (Avastin) for neovascular age-related macular degeneration. Retina 2006;26:495–511.
15. Spaide RF, Laud K, Fine HF, et al. Intravitreal bevacizumab treatment of choroidal neovascularization secondary to age-related macular degeneration. Retina 2006;26:383–390.
16. Avery RL, Pieramici DJ, Rabena MD, et al. Intravitreal bevacizumab (Avastin) for neovascular age-related macular degeneration. Ophthalmology 2006;113:363–372.
17. Emerson MV, Lauer AK, Flaxel CJ, et al. Intravitreal bevacizumab (Avastin) treatment of neovascular age-related macular degeneration. Retina 2007;27:439–444.
18. Shahar J, Avery RL, Heilweil G, et al. Electrophysiologic and retinal penetration studies following intravitreal injection of bevacizumab (Avastin). Retina 2006;26:262–269.
19. Luthra S, Narayanan R, Marques LEA, et al. Evaluation of in vitro effects of bevacizumab (Avastin) on retinal pigment epithelial, neurosensory retinal, and microvascular endothelial cells. Retina 2006;26:512–518.
20. Peters S, Heiduschka P, Julien S, et al. Ultra-structural findings in the primate eye after intravitreal injection of bevacizumab. Am J Ophthalmol 2007;143:995–1002.
21. Beer PM, Wong SJ, Hammad AM, et al. Vitreous levels of unbound bevacizumab and unbound vascular endothelial growth factor in two patients. Retina 2006;26:871–876.
22. Mitka M. Study aims to clarify efficacy, safety of eye drug treatments. JAMA 2007;297:1538–1539.
23. Gaudreault J, Fei D, Rusit J, et al. Preclinical pharmacokinetics of ranibizumab (rhuFabV2) after a single intravitreal injection. Invest Ophthalmol Vis Sci 2005;46:726–733.
24. FDA U.S. Biologic License Application (BL125156) Ranibizumab label. Available at: http://www.fda.gov/cder/foi/label/2006/125156lbl.pdf. Accessed Date: May 28, 2007.

Petitioner Fresenius Ex. 1025, 0010

25. Genentech press release concerning PIER study. Available at: http://www.fda.gov/medwatch/safety/2007/Lucentis_DHCP_01–24–2007.pdf. Accessed Date: May 28, 2007.
26. Fung AE, Lalwani GA, Rosenfeld PJ, et al. An optical coherence tomography-guided, variable dosing regimen with intravitreal ranibizumab (Lucentis) for neovascular age-related macular degeneration. Am J Ophthalmol 2007;143: 566–583.
27. Schuman JS, Puliafito CA, Fujimoto JG. Optical coherence tomography of ocular diseases. Thorofare, New Jersey: SLACK Inc., 2004.
28. Altaweel M, Ip M. Macular hole: improved understanding of pathogenesis, staging, and management based on optical coherence tomography. Semin Ophthalmol 2003;18:58–66.
29. Brown JC, Solomon SD, Bressler SB, et al. Detection of diabetic foveal edema: contact lens biomicroscopy compared with optical coherence tomography. Arch Ophthalmol 2004; 122:330–335.
30. Ozdek SC, Erdinc MA, Gurelik G, et al. Optical coherence tomographic assessment of diabetic macular edema: comparison with fluorescein angiographic and clinical findings. Ophthalmologica 2005;219:86–92.
31. Antonio P, Napolitano MC, Francesco B, Raffaella GC. The role of optical coherence tomography (OCT) in the diagnosis and management of retinal angiomatous proliferation (RAP) in patients with age-related macular degeneration. Ann Acad Med Singapore 2006;35: 420–425.
32. Sadda SR, Wu Z, Walsh AC, et al. Errors in retinal thickness measurements obtained by optical coherence tomography. Ophthalmology 2006;113:285–293.
33. Kim BY, Smith SD, Kaiser PK. Optical coherence tomographic patterns of diabetic macular edema. Am J Ophthalmol 2006;142:405–412.
34. Spaide R. Ranibizumab according to need: a treatment for age-related macular degeneration. Am J Ophthalmol 2007; 143:679–680.
35. Konerding MA. Ocular angiogenesis: translating preclinical indications to successful clinical development. Expert Opin Ther Targets 2004;8:255–258.

Petitioner Fresenius Ex. 1025, 0011

Biosketch

David M. Brown, MD, FACS, graduated with highest honors from Baylor College of Medicine, Houston, Texas and completed an ophthalmology residency and a medical and surgical retina fellowship at the University of Iowa, Iowa City, Iowa as a Heed Fellow, a Knapp Fellow, and the Ronald G. Michels fellow. Dr Brown is a Clinical Assistant Professor, Department of Ophthalmology, The Methodist Hospital, Weil College of Medicine, Cornell University, Ithaca, New York and he directs the Greater Houston Retina Research Center in Houston, Texas.

Petitioner Fresenius Ex. 1025, 0012

Biosketch

Carl Regillo received his medical degree from Harvard University, Boston, Massachusetts and performed both his ophthalmology residency and vitreoretinal fellowship at Wills Eye Hospital, Philadelphia, Pennsylvania. He is a prior Heed fellow and recipient of the American Academy of Ophthalmology Achievement and Senior Achievement Awards. Dr Regillo is currently the Director of the Wills Clinical Retina Research Unit, Professor of Ophthalmology at Thomas Jefferson University, Philadelphia, Pennsylvania and Chariman of the Academy Retina section of the Basic and Clinical Science Course.

Petitioner Fresenius Ex. 1025, 0013