An Optical Coherence Tomography-Guided, Variable Dosing Regimen with Intravitreal Ranibizumab (Lucentis) for Neovascular Age-related Macular Degeneration

ANNE E. FUNG, GEETA A. LALWANI, PHILIP J. ROSENFELD, SANDER R. DUBOVY, STEPHAN MICHELS, WILLIAM J. FEUER, CARMEN A. PULIAFITO, JANET L. DAVIS, HARRY W. FLYNN, JR, AND MARIA ESQUIABRO

• PURPOSE: To evaluate an optical coherence tomography (OCT)-guided, variable-dosing regimen with intravitreal ranibizumab for the treatment of patients with neovascular age-related macular degeneration (AMD).

• DESIGN: Open-label, prospective, single-center, nonrandomized, investigator-sponsored clinical study.

• METHODS: In this two-year study, neovascular AMD patients with subfoveal choroidal neovascularization (CNV) (n = 40) and a central retinal thickness of at least 300 μm as measured by OCT were enrolled to receive three consecutive monthly intravitreal injections of ranibizumab (0.5 mg). Thereafter, retreatment with ranibizumab was performed if one of the following changes was observed between visits: a loss of five letters in conjunction with fluid in the macula as detected by OCT, an increase in OCT central retinal thickness of at least 100 μm, new-onset classic CNV, new macular hemorrhage, or persistent macular fluid detected by OCT at least one month after the previous injection of ranibizumab.

• RESULTS: At month 12, the mean visual acuity improved by 9.3 letters ($P < .001$) and the mean OCT central retinal thickness decreased by 178 μm ($P < .001$). Visual acuity improved 15 or more letters in 35% of patients. These visual acuity and OCT outcomes were achieved with an average of 5.6 injections over 12 months. After a fluid-free macula was achieved, the mean injection-free interval was 4.5 months before another reinjection was necessary.

• CONCLUSION: This OCT-guided, variable-dosing regimen with ranibizumab resulted in visual acuity outcomes similar to the Phase III clinical studies, but required fewer intravitreal injections. OCT appears useful for determining when retreatment with ranibizumab is necessary. (Am J Ophthalmol 2007;143:566–583. © 2007 by Elsevier Inc. All rights reserved.)

See accompanying Editorial on page 679.

Accepted for publication Jan 13, 2007.

From the Bascom Palmer Eye Institute, University of Miami Miller School of Medicine, Miami, Florida (G.A.L., P.J.R., S.R.D., W.J.F., C.A.P., J.L.D., H.W.F., M.E.); Pacific Eye Associates, California Pacific Medical Center, San Francisco, California (A.E.F.); University Eye Hospital Vienna, Austria (S.M.).

Inquiries to Philip J. Rosenfeld, Bascom Palmer Eye Institute, University of Miami Miller School of Medicine, 900 N.W. 17th Street, Miami, FL 33136; e-mail: prosenfeld@med.miami.edu

INHIBITION OF VASCULAR ENDOTHELIAL GROWTH FACTOR-A (VEGF) is an effective strategy for the treatment of neovascular age-related macular degeneration (AMD).[1–4] The most effective treatment uses ranibizumab (Lucentis, Genentech Inc, South San Francisco, California, USA), a recombinant, humanized, monoclonal antibody antigen-binding fragment (Fab) that neutralizes all biologically active forms of VEGF.[5] In the two Phase III clinical studies using intravitreal injections of ranibizumab, mean visual acuity improved over 24 and 12 months, respectively.[2,3] This was the first therapy for neovascular AMD to show any improvement in mean visual acuity. In these studies, statistically significant benefits were observed for all the primary and secondary efficacy endpoints when compared with control groups. To obtain these impressive results, investigators followed a fixed-dosing regimen requiring an injection of ranibizumab, 0.5 mg or 0.3 mg, every month for two years.

The first suggestion that frequent intravitreal injections of ranibizumab could result in improved visual acuity came from the earlier Phase I/II studies.[6,7] In these studies, ranibizumab was injected every two or four weeks into eyes of patients with neovascular AMD and these patients were followed for 140 days or 210 days. The number of ranibizumab injections ranged from five to nine depending on the study and the cohort within each study. Despite differences in the overall number of injections, the outcomes from these studies were very similar. Mean visual acuity improved and these improvements were associated with an absence of angiographic leakage from choroidal neovascularization (CNV) and an absence of fluid in the macula as assessed by optical coherence tomography (OCT) (Rosenfeld PJ, unpublished data, 2003).

After completion of these Phase I/II studies, most of the study participants enrolled in an open-label extension study to evaluate the safety and tolerability of long-term (up to four years) continued treatment with intravitreal

© 2007 BY ELSEVIER INC. ALL RIGHTS RESERVED.
0002-9394/07/$32.00
doi:10.1016/j.ajo.2007.01.028

Petitioner Fresenius Ex. 1045, 0001

injections of ranibizumab (Heier JS and associates. ARVO 2005, E-Abstract 1393). Although the extension study initially required monthly injections of ranibizumab after the patient was enrolled, the study was subsequently amended to permit reinjection only if needed as determined by the treating physician. As a result of retreatment being offered at the discretion of the investigator, some patients received monthly injections with ranibizumab to maintain their visual acuity, whereas others were reinjected less frequently or not at all. During this extension study at the Bascom Palmer Eye Institute, OCT imaging was used to follow many of these patients in conjunction with fluorescein angiography, and OCT appeared to detect the earliest signs of fluid reaccumulating in the macula even before leakage could be detected by fluorescein angiography (Rosenfeld PJ, unpublished data, 2003).

Based on these observations from the Phase I/II and extension studies, an investigator sponsored trial known as the Prospective Optical coherence tomography imaging of patients with Neovascular AMD Treated with intra-Ocular ranibizumab (Lucentis) [PrONTO] study was designed to investigate the role of OCT imaging in a variable dosing regimen with ranibizumab at the Bascom Palmer Eye Institute. This report describes the 12 month results of the PrONTO Study.

METHODS

PRONTO IS A TWO-YEAR, OPEN-LABEL, PROSPECTIVE, SINGLE-CENTER clinical study designed to investigate the efficacy, durability, and safety of a variable dosing regimen with intravitreal ranibizumab in patients with neovascular AMD. The PrONTO Study is an investigator sponsored trial supported by Genentech, Inc, and performed with the approval of the Food and Drug Administration. Before the initiation of the study, additional approval for the PrONTO study was obtained from the Institutional Review Board at the University of Miami Miller School of Medicine. Informed consent was obtained from all patients before determination of full eligibility, and the study was performed in accordance with the Health Insurance Portability and Accountability Act (HIPAA). The PrONTO Study is registered at www.clinicaltrials.gov, and the clinical trial accession number is NCT00344227.

The major efficacy end points were the change in visual acuity and OCT measurements from baseline and the number of ranibizumab injections required over two years. Other efficacy end points included the number of consecutive monthly injections required from baseline to achieve a fluid-free macula as determined by OCT. After a fluid-free macula was achieved, the durability of the treatment effect was determined by calculating the time until the next injection was needed because of fluid reaccumulating in the macula, otherwise known as the injection-free interval. Finally, after the injections resumed, we calculated the follow-up number of reinjections required to once again achieve a fluid-free macula.

TABLE 1. Major Eligibility Criteria for Enrollment into the PrONTO Study

Inclusion criteria
Age 50 years or older.
Active primary or recurrent macular neovascularization secondary to AMD involving the central fovea in the study eye with evidence of disease progression.
OCT central retinal thickness ≥300 microns.
Best-corrected visual acuity, using ETDRS charts, of 20/40 to 20/400 (Snellen equivalent) in the study eye.
Exclusion criteria
More than three prior treatments with verteporfin photodynamic therapy.
Previous participation in a clinical trial (for either eye) involving antiangiogenic drugs (pegaptanib, ranibizumab, anecortave acetate, protein kinase C inhibitors).
Previous subfoveal focal laser photocoagulation in the study eye.
Laser photocoagulation (juxtafoveal or extrafoveal) in the study eye within one month preceding day 0.
Subfoveal fibrosis or atrophy in the study eye.
History of vitrectomy surgery in the study eye.
Aphakia or absence of the posterior capsule in the study eye.
History of idiopathic or autoimmune-associated uveitis in either eye.

AMD = age-related macular degeneration; PrONTO = Prospective Optical coherence tomography imaging of patients with Neovascular AMD Treated with intra-Ocular ranibizumab study; OCT = optical coherence tomography; ETDRS = Early Treatment of Diabetic Retinopathy Study.

At the start of the study, only one eye of a patient was determined to be eligible and assigned as the study eye. The major eligibility criteria are shown in Table 1. The major inclusion criteria included a diagnosis of neovascular AMD with a baseline protocol visual acuity letter score from 20 to 70 letters using the Early Treatment Diabetic Retinopathy Study chart at two meters (Snellen equivalent of 20/40 to 20/400) obtained using a standard refraction protocol[8] and an OCT 1 mm central retinal thickness of at least 300 μm. There were no exclusion criteria for preexisting cardiovascular, cerebrovascular, or peripheral vascular conditions. Of note, all fluorescein angiographic lesion types and lesion sizes were eligible for the study. The angiographic lesion types at baseline were independently assessed by three of the investigators (P.J.R., S.R.D., and G.A.L.) and agreement was reached on all interpretations. The diagnosis of retinal angiomatous proliferation (RAP) was independently assessed for each lesion using the characteristic features which included intraretinal hemorrhage, intraretinal vascular anastomoses, and the OCT appearance of a retinal pigment epithelial detachment

Petitioner Fresenius Ex. 1045, 0002

TABLE 2. The Number of Times Each Criterion was Used Alone or in Combination With Other Criteria to Retreat Neovascular AMD Patients With Ranibizumab After Month 2 Through Month 12

Retreatment criteria	Only one criterion observed for retreatment	Vision loss (≥5 letters) associated with fluid detected by OCT	Increase in central retinal thickness ≥100 microns	New-onset hemorrhage	New classic CNV
Vision loss (≥5 letters) associated with fluid detected by OCT	31	—	4*	5*	0
Increase in central retinal thickness ≥100 microns	12	4*	—	4*	0
New-onset hemorrhage	12	5*	4*	—	1
New classic CNV	7	0	0	1	—
Persistent fluid following last injection	30	—	—	—	—

AMD = age-related macular degeneration; OCT = optical coherence tomography; CNV = choroidal neovascularization.

Most patients fulfilled only one criterion for reinjection as listed in the second column, but some patients fulfilled two or more criteria and are listed in columns 3 to 6.

*Two of these individuals had three criteria for reinjection: vision loss (≥5 letters) associated with fluid detected by OCT, increase in central retinal thickness ≥100 microns, and new onset hemorrhage.

with overlying cystic changes in the retina. In calculating lesion areas, we assumed a standard disk diameter of 1.8 mm and a standard disk area (DA) of 2.54 mm^2. All digital fundus photography was performed using Topcon TRC-50IX retinal cameras (Topcon America Corp (TAC), Paramus, New Jersey, USA) with a 35 degree viewing angle and the images were stored using the Topcon Imagenet software (version 2.14, Windows 2000 v.5.0; Paramus, New Jersey, USA). Images were then transferred to an OIS workstation (OIS Winstation XP 10 3000 Auto Import Capture version 10.2.59; Sacramento, California, USA) where the lesion areas were measured.

OCT (Stratus OCT, Carl Zeiss Meditec, Dublin, California, USA) quantitative assessments were obtained using six diagonal fast, low density scans (low resolution, 128 A-scans per diagonal). The central 1 mm central retinal thickness measurements were obtained from the macular thickness maps calculated from the six low-resolution fast scans after it was confirmed that the two boundaries delineated as the internal limiting membrane (inner boundary) and the retinal pigment epithelium (RPE) and the Bruch membrane (outer boundary) were appropriately identified by the validated internal algorithm. If boundaries were incorrectly identified, then the scans were repeated until the boundaries were accurately identified by the algorithm. The central retinal thickness was defined as the distance between these inner and outer boundaries and did not include any fluid under the RPE. Eligible patients were required to have a 1 mm central retinal thickness of at least 300 μm. OCT qualitative assessments were performed using all six diagonal slow, high density scans (high resolution, 512 A-scans per diagonal). These high resolution diagonal scans were used to evaluate whether fluid was present in the macula and whether retreatment was needed. For the purposes of this study, fluid in the macula was identified as intraretinal fluid (cysts) and subretinal fluid, and a fluid-free macula was defined by the absence of retinal cysts and subretinal fluid as determined by OCT. Fluid under the RPE, otherwise known as a pigment epithelial detachment (PED), was recorded as an OCT finding in the macula but not included in any of the retreatment criteria. The decision not to include a PED in the retreatment criteria was based on prior anecdotal observations from the Phase I/II extension study with ranibizumab. In the extension study, there appeared to be little correlation between the presence of a PED and visual acuity. In addition, PEDs could remain stable for months and resolution of fluid within the PED was thought to be a lagging indicator of VEGF activity. In contrast, macular cysts and subretinal fluid appeared to respond more rapidly to the presence or absence of VEGF.

During the screening process, patients underwent a complete physical exam with laboratory testing. Laboratory testing consisted of an electrocardiogram, complete blood count, and chemistry panel performed at baseline and at month 12. Blood pressure measurements were performed at every visit. Eligible patients underwent visual acuity testing and ophthalmoscopic examinations at baseline, day 14, day 30, day 45, day 60, and monthly thereafter. Fundus photography and OCT imaging were performed at baseline and on days one, two, four, seven, 14, and 30 after the first two monthly injections, and monthly thereafter. Fluorescein angiography was performed at baseline, month 1, month 2, month 3, and every three months thereafter. All ophthalmic photographers and OCT technicians involved in the study were previously certified to participate in Food and Drug Adminstration–approved clinical trials at the Bascom Palmer Eye Institute.

After determination of eligibility, patients received an intravitreal injection of ranibizumab (LUCENTIS, Genentech, Inc) using a standard protocol at the Bascom Palmer Eye Institute. The eye was topically anesthetized with sterile 4% lidocaine and a povidone-iodine (10%) scrub was performed on the lids and lashes. A sterile speculum was placed between the lids, and povidone-

Petitioner Fresenius Ex. 1045, 0003

TABLE 3. Visual Acuity of Eyes With Neovascular AMD Treated With a Variable-Dosing Regimen of Ranibizumab Through 12 Months

Patients' study eyes (n = 40)	Baseline visual acuity letters (Snellen equivalent)	Day 14 visual acuity letters (Snellen equivalent)	Month 1 visual acuity letters (Snellen equivalent)	Month 3 visual acuity letters (Snellen equivalent)	Month 12 visual acuity letters (Snellen equivalent)	Change in visual acuity letter scores from baseline to month 12 visual acuity letters (Snellen equivalent)
Mean (*P* value)*	56.2	63.1	63.9	67.0	65.5	+9.3
	$20/80^{+1}$	$20/50^{-2}$ ($P < .001$)	$20/50^{-1}$ ($P < .001$)	$20/50^{+2}$ ($P < .001$)	20/50 ($P < .001$)	
Median (*P* value)†	57	65.0	66.0	71.0	68	+11.0
	$20/80^{+2}$	(20/50) ($P < .001$)	$20/50^{+1}$ ($P < .001$)	$20/40^{+1}$ ($P < .001$)	$20/40^{-2}$ ($P < .001$)	

AMD = age-related macular degeneration.
*Paired the Student *t* test.
†Paired the Wilcoxon signed-rank test.

TABLE 4. OCT Central Retinal Thickness of Eyes With Neovascular AMD Treated With a Variable-Dosing Regimen of Ranibizumab Through 12 Months

Patients' study eyes (n = 40)	Baseline central retinal thickness (μm)	Day 1 central retinal thickness (μm)	Month 1 central retinal thickness (μm)	Month 3 central retinal thickness (μm)	Month 12 central retinal thickness (μm)	Change in central retinal thickness (μM) from baseline to month 12
Mean (*P* value)*	393.9	347.1 ($P < .001$)	237.2 ($P < .001$)	204.3 ($P < .001$)	216.1 ($P < .001$)	−177.8
Median (*P* value)†	384.5	336.0 ($P < .001$)	203.5 ($P < .001$)	186.0 ($P < .001$)	199.0 ($P < .001$)	−185.5

OCT = optical coherence tomography; AMD = age-related macular degeneration.
*Paired the Student *t* test.
†Paired the Wilcoxon signed-rank test.

TABLE 5. Distribution of OCT Lesion Characteristics From Baseline Through Month 3 in Neovascular AMD Patients Treated With Ranibizumab at Day 0, Month 1, and Month 2

OCT lesion characteristics (n = 40)	Day 0 n (%)	Day 7 n (%)	Day 14 n (%)	Month 1 n (%)	Month 2 n (%)	Month 3 n (%)
Retinal cysts	36 (90%)	7 (17.5%)	6 (15%)	6 (15%)	3 (7.5%)	3* (7.5%)
Subretinal fluid	30 (75%)	19 (47.5%)	15 (37.5%)	9 (22.5%)	3 (7.5%)	1* (2.5%)
RPE detachment	29 (72.5%)	27 (67.5%)	24 (60%)	23 (57.5%)	18 (45%)	15 (37.5%)
Epiretinal membrane	9 (22.5%)	9 (22.5%)	9 (22.5%)	9 (22.5%)	9 (22.5%)	9 (22.5%)
RPE tear	0	1 (2.5%)	1 (2.5%)	1 (2.5%)	1 (2.5%)	1 (2.5%)

OCT = optical coherence tomography; RPE = retinal pigment epithelium; AMD = age-related macular degeneration.
*One eye had both residual retinal cysts and subretinal fluid.

iodine (5%) drops were applied over the ocular surface three times over several minutes. Additional topical anesthesia was achieved by applying a sterile cotton swab soaked in sterile 4% lidocaine to the area designated for injection in the inferotemporal quadrant. Ranibizumab (0.05 ml, 0.5 mg) in a tuberculin syringe with a 30-gauge needle was injected through the pars plana into the vitreous cavity through the sclera 3 to 4 mm posterior to the limbus. Post-injection light perception was assessed and the intraocular pressure was monitored until it was lower than 30 mm Hg. The patient was instructed to apply moxifloxacin antibiotic drops (vigamox 0.5% solution) to the study eye four times per day for three days. All patients received a call within 24 hours to assess their status and remind them to use their antibiotic drops.

Intravitreal injections of ranibizumab were administered to all patients at baseline, month 1, and month 2. Additional reinjections were given if any of the following changes were observed by the evaluating physician as shown in Table 2: (1) visual acuity loss of at least five letters with OCT evidence of fluid in the macula, (2) an increase in OCT central retinal thickness of at least 100

Petitioner Fresenius Ex. 1045, 0004

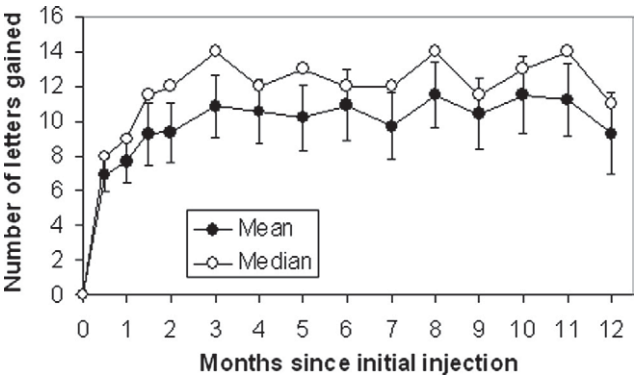

FIGURE 1. Mean and median change in visual acuity through 12 months of eyes with neovascular age-related macular degeneration (AMD) treated with a variable dosing intravitreal ranibizumab regimen. Vertical lines are 1 standard error of the means.

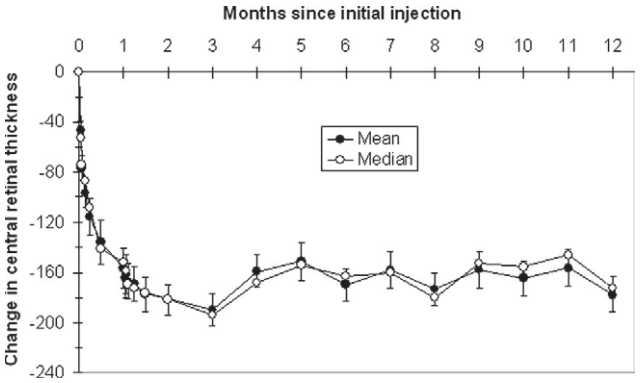

FIGURE 2. Mean and median change in the optical coherence tomography (OCT) central retinal thickness through 12 months of eyes with neovascular age-related macular degeneration (AMD) treated with a variable dosing intravitreal ranibizumab regimen. Vertical lines are 1 standard error of the means.

TABLE 6. Distribution of Visual Acuity Changes in Eyes With Neovascular AMD After 3 Doses of Ranibizumab at Month 3 and After a Variable-Dosing Regimen From Months 3 Through 12

Change in visual acuity from baseline through 12 months	Month 3 40 eyes n (%)	Month 12 40 eyes n (%)
≥6 line increase	2 (5%)	3 (7.5%)
≥3 line to <6 line increase	11 (27.5%)	11 (27.5%)
≥1 line to <3 line increase	20 (50%)	16 (40%)
No change	5 (12.5%)	5 (12.5%)
≥1 line to <3 line decrease	1 (2.5%)	3 (7.5%)
≥3 line decrease	1 (2.5%)	2 (5%)

AMD = age-related macular degeneration.

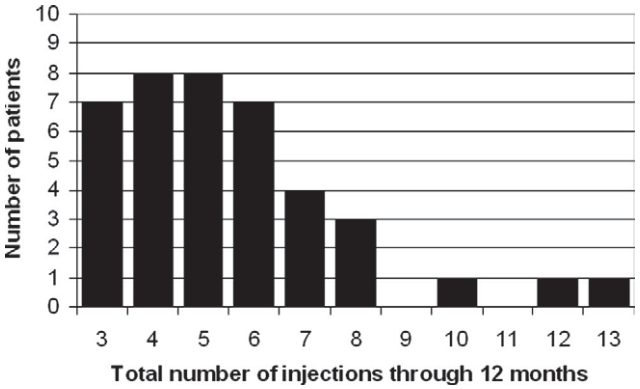

FIGURE 3. Distribution of the total number of injections of ranibizumab administered per neovascular age-related macular degeneration (AMD) patient through 12 months according to the Prospective Optical coherence tomography imaging of patients with Neovascular AMD Treated with intra-Ocular ranibizumab (PrONTO) study criteria.

μm, (3) new macular hemorrhage, (4) new area of classic CNV, or (5) evidence of persistent fluid on OCT at least one month after the previous injection. All criteria were based on comparisons with the previously scheduled visit. If a reinjection was performed as part of an unscheduled visit, then the patient returned at the next scheduled visit for follow-up, but all subsequent reinjection decisions were postponed until the next scheduled visit at least one month after the injection. If any single criterion for reinjection was fulfilled, then the intravitreal injection was performed as previously described.

The major outcome measurements in the PrONTO study included Early Treatment Diabetic Retinopathy Study visual acuity letter scores, OCT central retinal thickness measurements, the change in visual acuity letter scores and OCT measurements from baseline, the consecutive number of injections required to achieve a fluid-free macula from baseline, the injection-free interval after a fluid-free macula was achieved, the number of consecutive reinjections required to achieve a fluid-free macula after the fluid started to reaccumulate and injections were

FIGURE 4. Case 1: A 100-year-old woman with neovascular age-related macular degeneration (AMD) diagnosed with predominantly classic choroidal neovascularization (CNV) in her left eye, given three ranibizumab injections, and then followed through month 12. Color fundus images with early and late phase fluorescein angiographic images are shown at baseline, at month 3 (one month after the third injection), and then at month 6, month 9, and month 12 without any additional injections of ranibizumab. At months 6 and 12, fundus photography was performed using a 50 degree viewing angle rather than the protocol 35 degree angle.

Petitioner Fresenius Ex. 1045, 0005

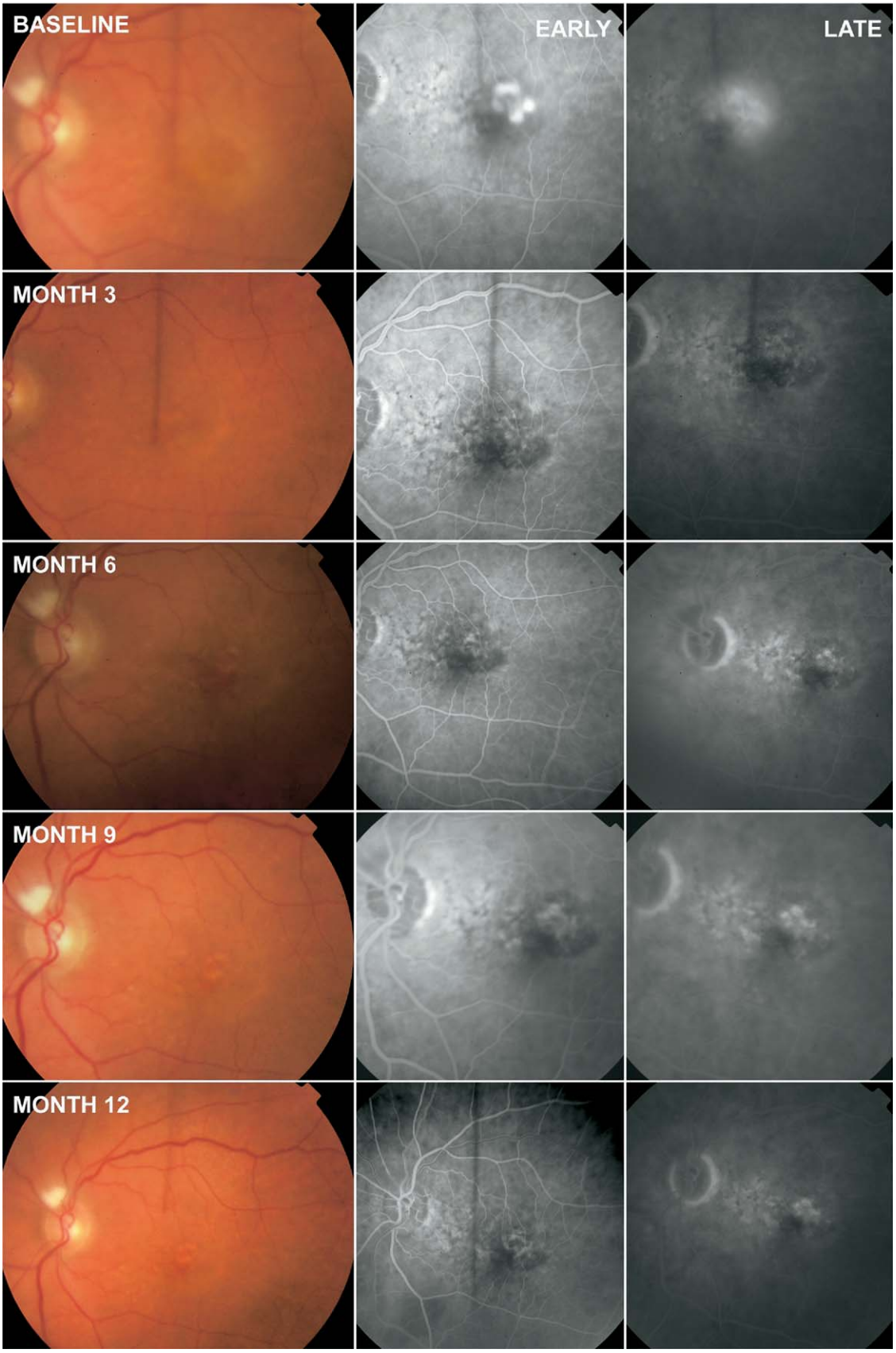

Petitioner Fresenius Ex. 1045, 0006

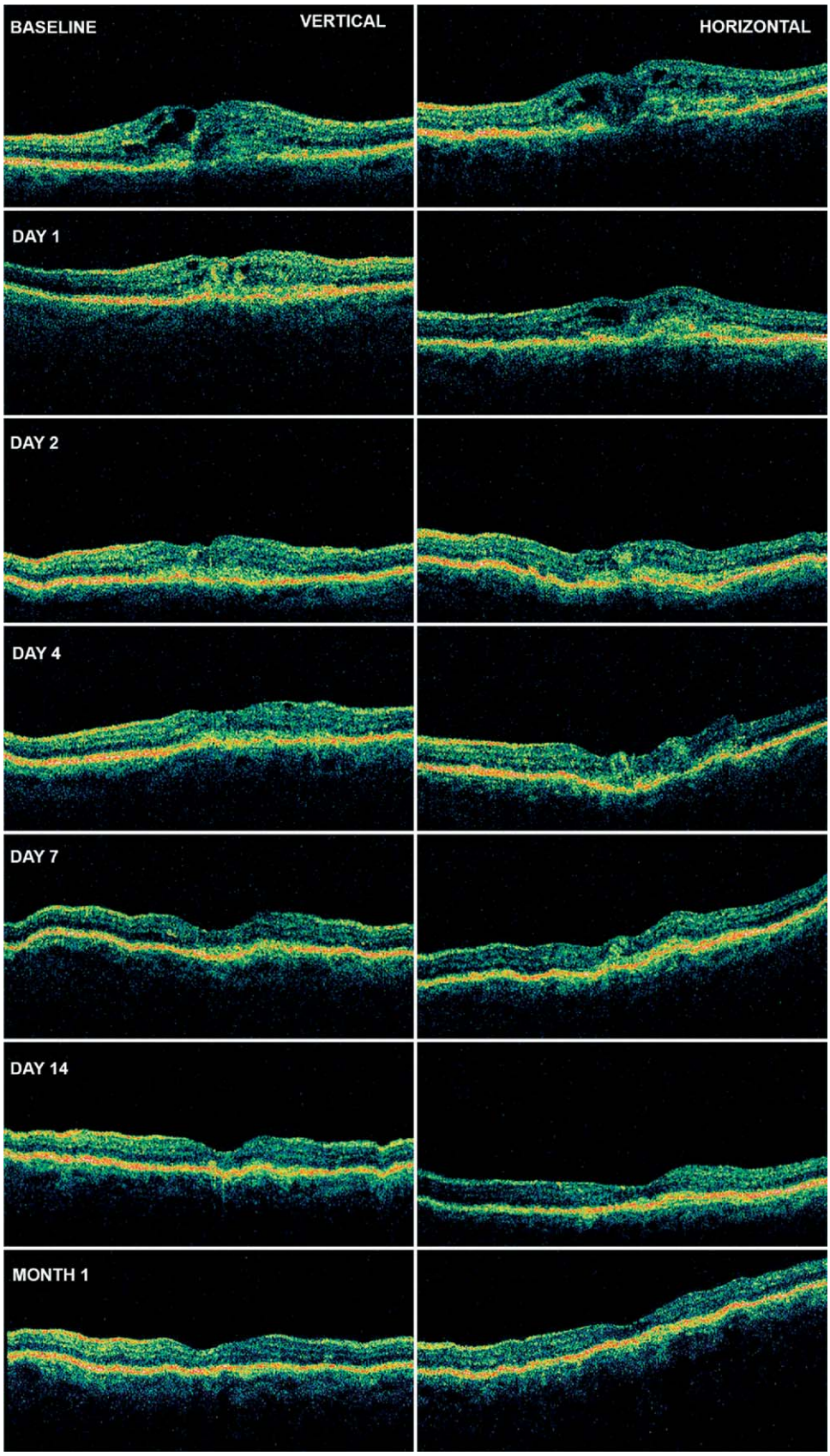

Petitioner Fresenius Ex. 1045, 0007

resumed, and the total number of injections received by a patient during one year.

For the mean visual acuity letter scores and central retinal thickness measurements during the first 12 months, the data were statistically compared with mean baseline values using the paired Student *t* test. Median measurements were compared with median baseline values using the paired Wilcoxon signed-rank test. The influence of baseline fluorescein angiographic lesion types on the number of injections over 12 months was assessed using one-way analysis of variance and the Kruskal-Wallis test. The influence of baseline acuity and lesion size in disk areas on the number of injections and the influence of the number of injections on visual acuity outcomes were assessed using the Pearson correlation analysis and Spearman nonparametric correlation analysis. Statistical significance was defined as $P < .05$.

RESULTS

• **BASELINE CHARACTERISTICS:** Between August 2004 and April 2005, 69 patients were screened for the study and 40 patients were enrolled. Twenty-nine patients were excluded from the study for the following reasons: OCT central retinal thickness less than 300 μm (nine patients), declined participation in the study after screening because of the rigorous follow-up schedule (seven patients), visual acuity either better than 20/40 or worse than 20/400 (four patients), inability to obtain reproducible OCT central retinal thickness measurements because of unreliable boundary detection (three patients), localized retinal detachment (two patients), previous enrollment in a clinical trial involving anti-angiogenic drugs (two patients), RPE tear (one patient), and no evidence of macular neovascularization (one patient). Of the 40 patients enrolled in the study, the mean age was 83.5 years (standard deviation [SD] =7.2) and the median age was 83 years (range, 69 to 100 years), 26 were women (65%), and all the participants were white. Fifteen eyes (37.5%) were phakic and 25 eyes (62.5%) were pseudophakic. Fourteen of the 40 eyes had undergone some prior treatment for neovascular AMD including intravitreal pegaptanib (four eyes), photodynamic therapy (PDT) alone (three eyes), PDT with intravitreal triamcinolone acetonide (five eyes), PDT followed by intravitreal pegaptanib (one eye), and laser photocoagulation (one eye).

At baseline, the mean and median visual acuity letter scores were 56 ($20/80^{+1}$) and 57 ($20/80^{+2}$), respectively (Table 3). Baseline mean and median OCT 1 mm central retinal thickness measurements were 394 μm and 385 μm, respectively (Table 4). The OCT findings at baseline included retinal cysts (36 eyes; 90%), subretinal fluid (30 eyes; 75%), PED (29 eyes; 72.5%), and epiretinal membrane (nine eyes, 22.5%; Table 5). At baseline, the neovascular lesions were categorized by fluorescein angiography as occult with no classic lesions (10 eyes; 25%), minimally classic lesions (23 eyes; 57.5%), and predominantly classic lesions (seven eyes; 17.5%). Overall, 10 of the 40 lesions (25%) were categorized as RAP lesions. The mean and median baseline lesion areas were 3.5 DAs (SD = 2.4) and 2.8 DAs (range, 0.6 to 10), respectively. The baseline mean systolic/diastolic blood pressure was 149/78.

• **VISUAL ACUITY AND OCT OUTCOMES AT THREE MONTHS:** After the first injection of ranibizumab at baseline, an improvement in visual acuity was detected by day 14, the first follow-up visit when visual acuity was measured after the first injection (Table 3; Figure 1). The mean and median visual acuity scores improved by 6.9 letters ($P < .001$) and 7.5 letters ($P < .001$), respectively. During the first three months, visual acuity continued to improve. By month three, one month after the third injection, there was a mean and median visual acuity increase of 10.8 letters ($P < .001$) and 10.5 letters ($P < .001$), respectively. At month three, 13 eyes (32.5%) gained at least 3 lines of visual acuity, with two eyes (5%) gaining at least 6 lines compared with baseline. One eye lost more than 3 lines of visual acuity by three months because a tear of the RPE developed within seven days after the first injection (Tables 5 and 6).

The improvement in visual acuity was associated with a decrease in central retinal thickness (Table 4, Figure 2). One day after the first injection of ranibizumab, a statistically significant decrease in the central retinal thickness was detected with the mean and median thickness measurements decreasing by 47 μm ($P < .001$) and 48.5 μm ($P < .001$), respectively. The central retinal thickness continued to decrease over the next three months. By month three, the mean and median central retinal thickness measurements had decreased by 189.7 μm ($P < .001$) and 198.5 μm ($P < .001$), respectively.

The correlations between the decrease in OCT central retinal thickness and the improvement in visual acuity were explored using both Pearson correlation and Spearman nonparametric correlation analyses. At one month, there were no statistically significant correlations between the decrease in central retinal thickness and the improve-

FIGURE 5. Case 1: Optical coherence tomography (OCT) response to the first ranibizumab injection from baseline through month 1 in an eye with neovascular age-related macular degeneration (AMD) and predominantly classic choroidal neovascularization (CNV). Vertical (left side) and horizontal (right side) OCT scans and central retinal thickness measurements of her left eye are shown at baseline (406 μm; visual acuity [VA]: 20/80), ranibizumab no. 1 injected; day 1 (327 μm); day 2 (307 μm); day 4 (281 μm); day 7 (225 μm); day 14 (219 μm; VA: 20/50); month 1 (183 μm; VA: 20/50), ranibizumab no. 2 injected.

Petitioner Fresenius Ex. 1045, 0008

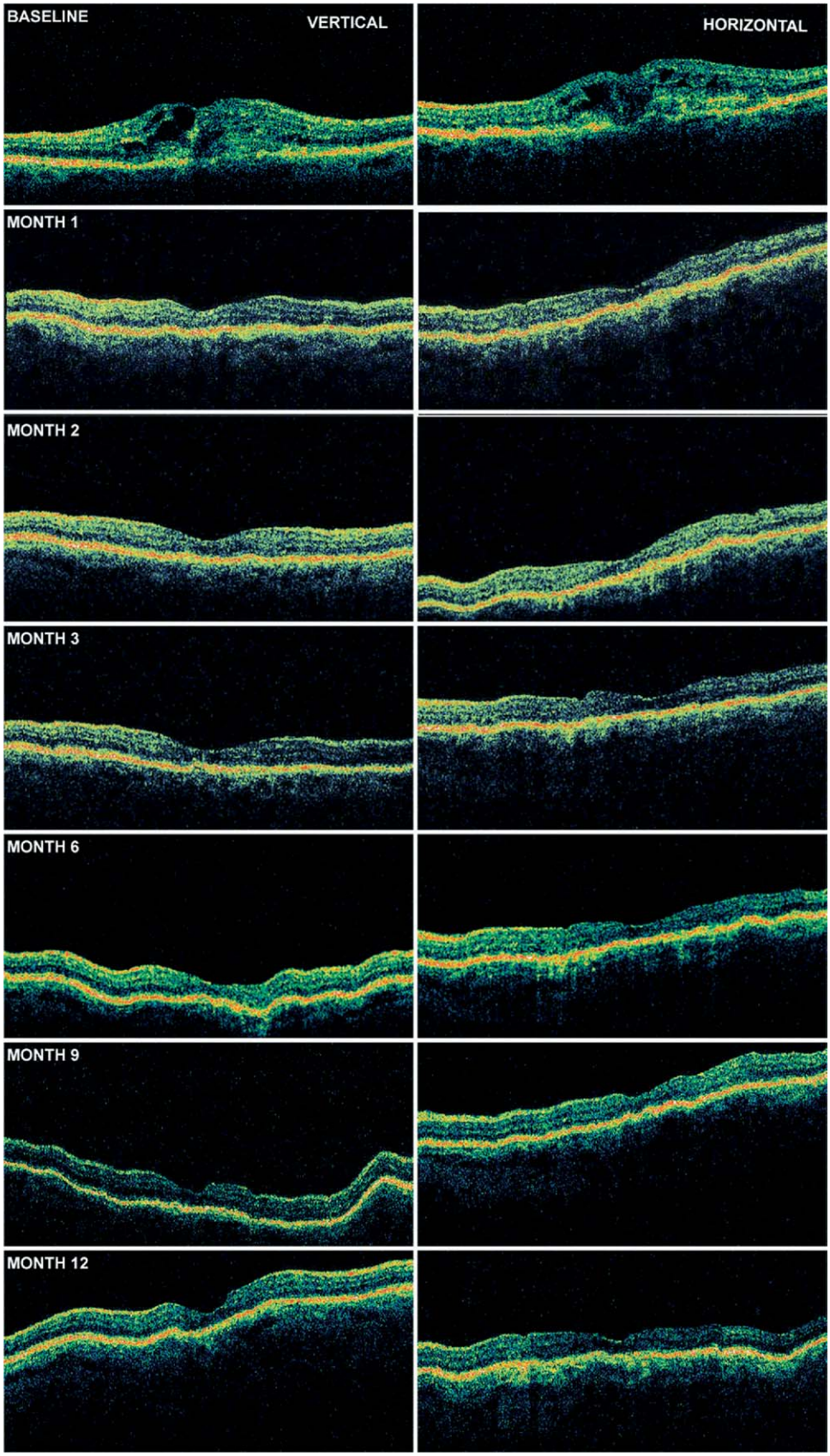

Petitioner Fresenius Ex. 1045, 0009

TABLE 7. Number of Reinjections With Ranibizumab Performed per Month in Eyes With Neovascular AMD Using the Variable-Dosing Regimen From Months 3 Through 12

Follow-up visit	Number (%) receiving the first reinjection after month 2 (n = 33)	Total number (%) reinjected at monthly follow-up visits(n = 33)
Month 3	3 (7.5)	3 (7.5)
Month 4	6 (15.0)	9 (22.5)
Month 5	10 (25.0)	14 (35.0)
Month 6	3 (7.5)	7 (17.5)
Month 7	3 (7.5)	11 (27.5)
Month 8	0	6 (15.0)
Month 9	2 (5.0)	14 (35.0)
Month 10	1 (2.5)	6 (15.0)
Month 11	2 (5.0)	13 (32.5)
Month 12	3 (7.5)	19 (47.5)

AMD = age-related macular degeneration.

ment in visual acuity (Pearson, $r = .25$, $P = .12$; Spearman, $r = .23$, $P = .15$). However, there were significant correlations between the decrease in central retinal thickness at one month and the subsequent improvement in visual acuity seen at two months (Pearson, $r = .57$, $P < .001$; Spearman, r = .47, $P = .002$) and three months (Pearson, $r = .51$, $P = .001$; Spearman, $r = .36$, $P = .021$). In addition, significant correlations were identified between the change in thickness at two months and the visual acuity changes at two months (Pearson, $r = .36$, $P = .023$; Spearman, $r = .41$, $P = .009$) and three months (Pearson, $r = .31$, $P = .05$; Spearman, $r = .38$, $P = .017$). Finally, significant correlations were observed between the decrease in retinal thickness and the improvement in visual acuity at three months (Pearson, $r = .36$, $P = .024$; Spearman, $r = .34$, $P = .034$).

The PrONTO OCT definition of fluid in the macula included retinal cysts and subretinal fluid, but not sub-RPE fluid, otherwise known as a PED. Of the 36 eyes with cystic changes in the retina at baseline, 30 eyes showed complete resolution of the retinal cysts by day 7 (Table 5). By one month after the injection, only six eyes were found to contain retinal cysts, with three eyes containing retinal cysts at month 2 and month 3. Of the 30 eyes with subretinal fluid at baseline as detected by OCT, 19 eyes continued to have subretinal fluid at day 7 after the first injection, nine eyes continued to have subretinal fluid at month 1, three eyes at month 2, and only one eye at month 3. At the month 3 visit, only three eyes required an injection of ranibizumab because of persistent fluid in the macula; two eyes with residual retinal cysts and one eye with both residual cysts and subretinal fluid (Table 5).

Fluid contained within a PED appeared to take longer to resolve compared with intraretinal cysts and subretinal fluid (Table 5). Of the 29 eyes with evidence of a PED at baseline, only 14 eyes showed resolution of the PED by month 3 with the remaining 15 eyes showing at least some decrease in the amount of fluid within the PED. One of the eyes with a PED at baseline was the same eye that developed a tear of the RPE within seven days after the first injection.

At the month 3 visit, 37 of the 40 eyes did not receive an injection. Of the three eyes that did receive an injection, two had persistent intraretinal cysts and one had both persistent cysts and subretinal fluid (Table 5). A fluid-free macula was eventually achieved in two of the eyes, with one eye requiring two more consecutive monthly injections and the other eye requiring three more consecutive monthly injections. One eye never became fluid-free during the first year of the study and required 13 injections through month 12.

• **RETREATMENT WITH RANIBIZUMAB FROM MONTH 3 TO MONTH 12:** At month 12, 100% of patients returned for follow-up. Of the 880 study visits scheduled during the first 12 months, only eight scheduled study visits were missed by different patients at different times resulting in an overall study compliance of 99.1%. A total of 11 unscheduled visits occurred primarily because of patients reporting a worsening of their visual acuity, and four of these visits resulted in a reinjection based on the retreatment criteria. All patients evaluated at an unscheduled visit returned for their next regularly scheduled visit.

After the month 2 visit, only one of the reinjection criteria needed to be fulfilled; however, at any given visit, several criteria could be fulfilled (Table 2). A total of 102 reinjections were performed beginning at month 3 through month 12 based on our retreatment criteria. The most common reason for reinjection was the loss of at least five letters of visual acuity in association with macular fluid detected by OCT. Two of the criteria did not require any OCT imaging, and these criteria were the presence of a new hemorrhage and the appearance of new classic CNV. Twenty of the 102 reinjections were performed because of

FIGURE 6. Case 1: Optical coherence tomography (OCT) response from baseline through month 12 in an eye with neovascular age-related macular degeneration (AMD) and predominantly classic choroidal neovascularization (CNV) given a total of three injections through month 2 with no additional injections performed through month 12. Vertical (left side) and horizontal (right side) OCT scans and central retinal thickness measurements are shown of her left eye at baseline (406 μm; visual acuity [VA]: 20/80), ranibizumab no. 1 injected; month 1 (183 μm; VA: 20/50), ranibizumab no. 2 injected; month 2 (180 μm; VA: 20/50), ranibizumab no. 3 injected; month 3 (184μm; VA: 20/32), observed; month 6 (179 μm; VA: 20/50), observed; month 9 (203 μm; VA: 20/50), observed; month 12 (180 μm; VA: 20/40), observed.

Petitioner Fresenius Ex. 1045, 0010

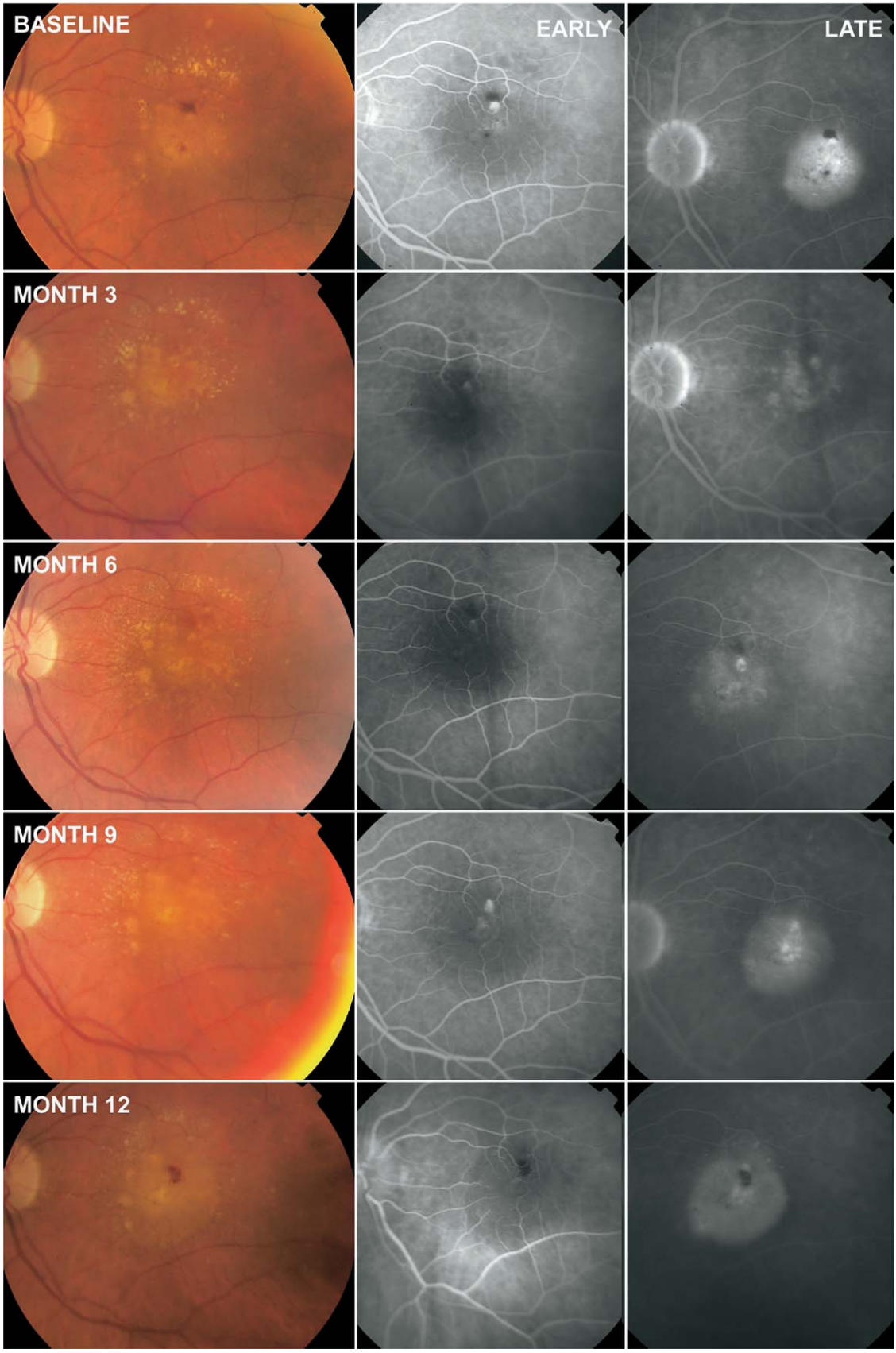

Petitioner Fresenius Ex. 1045, 0011

new hemorrhage or new classic CNV alone or in combination. Even though both of these retreatment criteria did not rely on OCT imaging, investigators did observe either an increase in intraretinal cysts or subretinal fluid at these visits, which are qualitative OCT changes consistent with the appearance of recurrent fluid. However, the increase in the OCT central retinal thickness measurements at these visits were less than the 100 μm increases required to trigger a retreatment.

The mean and median number of injections for the first year were 5.6 (SD 2.3) and 5.0 (range, three to 13), respectively, of a possible 13 injections from day 0 through month 12. Three of these injections were mandated by the protocol and given during the first three months. After the first three injections, seven patients never needed another injection (Figure 3). Figures 4, 5, and 6 show the images of an eye with a predominantly classic lesion that required a total of only three injections over 12 months. In contrast to the seven eyes that received just the three injections over 12 months, one eye never became fluid-free and received a total of 13 injections. Of the 39 eyes that eventually achieved a fluid-free macula, the mean and median number of monthly consecutive injections from baseline that were required to achieve a fluid-free macula were 1.5 (SD 1.1) and 1.0 (range, one to six), respectively.

Thus a total of 39 eyes eventually became fluid-free; 37 of these eyes eventually developed some recurrent fluid during the first year. Of the 37 eyes that developed some recurrent fluid, 32 received a retreatment during the first 12 months. Of the 39 eyes that became fluid-free, seven never needed another injection after the last scheduled injection at month 2. Therefore, five of the 37 eyes that developed some recurrent fluid did not meet any of the criteria for retreatment during the first year. For the 32 eyes that did develop recurrent fluid and were reinjected after month 2, the mean and median duration of the injection-free interval was 4.5 months (SD 2.7) and 3.0 months (range, two to 10 months), respectively. After achieving a fluid-free status following the last scheduled injection at month 2, Table 7 shows the monthly visit when eyes received their first reinjection based on the criteria in Table 2. Table 7 also shows the total number of eyes requiring any injection at each monthly visit. Of the 32 eyes that were reinjected, 27 eyes returned to a fluid-free state before month 12. The mean and median number of consecutive monthly reinjections required until the macula was once again fluid-free was 1.2 (SD 0.6) and one (range, one to four), respectively. Figures 7 to 10 show the images of an eye with a RAP lesion that required a total of seven injections with injection-free intervals ranging from two to three months.

• **VISUAL ACUITY AND OCT OUTCOMES AT 12 MONTHS:** At 12 months, the mean and median visual acuity scores improved compared with baseline by 9.3 letters ($P < .001$) and 11 letters ($P < .001$), respectively (Table 3; Figure 1). Fourteen eyes (35%) gained at least 3 lines of vision with three eyes (7.5%) gaining at least 6 lines of vision (Table 6). Thirty-three eyes (82.5%) avoided any loss of letters with 38 eyes (95%) avoiding a loss of at least three lines (15 letters) of visual acuity by 12 months. The overall improvement in visual acuity was associated with a decrease in central retinal thickness. The mean and median thickness measurements decreased by 177.8 μm ($P < .001$) and 185.5 μm ($P < .001$), respectively (Table 4; Figure 2). The correlations between the improvement in visual acuity and decrease in OCT central retinal thickness measurements at 12 months were found to be significant for the Pearson analysis, but borderline for the Spearman analysis (Pearson, $r = .38$, $P = .016$; Spearman, $r = .31$, $P = .051$). However, both analyses showed significance when the change in OCT central retinal thickness at one month was correlated with the eventual change in visual acuity at 12 months (Pearson, $r = .37$, $P = .019$; Spearman, $r = .38$, $P = .015$). These results suggest that the initial decrease in OCT measurements are predictive of future visual acuity improvements, whereas the subsequent OCT measurements that can fluctuate as part of a variable dosing regimen are less reliable predictors of visual acuity at any given month.

Retreatment was guided primarily by the presence of fluid in the macula as defined by intraretinal cysts and subretinal fluid which were also the major contributors to the overall central retinal thickness measurement, and a positive correlation was found between the central retinal thickness measurements and visual acuity outcomes. However, retreatment decisions were not guided by the presence or absence of a PED. One way to assess whether the existence of a PED was a variable that influenced visual acuity outcomes would be to analyze whether the presence or absence of a PED at baseline and after the first three consecutive monthly injections were associated with visual acuity outcomes at 12 months. Using the Student t test and the Mann-Whitney U nonparametric test, we found no association between a PED at baseline with visual

FIGURE 7. Case 2: A 82-year-old woman with neovascular age-related macular degeneration (AMD) and a history of three prior photodynamic therapy treatments to her left eye subsequently diagnosed with retinal angiomatous proliferation that appeared as occult with no classic choroidal neovascularization (CNV) by fluorescein angiography and received seven intravitreal injections of ranibizumab over 12 months. Color fundus images with early- and late-phase fluorescein angiographic images are shown at baseline, month 3 (1 month after the third injection), month 6, month 9, and month 12. Four additional ranibizumab injections were given at month 5, month 7, month 9, and month 12.

Petitioner Fresenius Ex. 1045, 0012

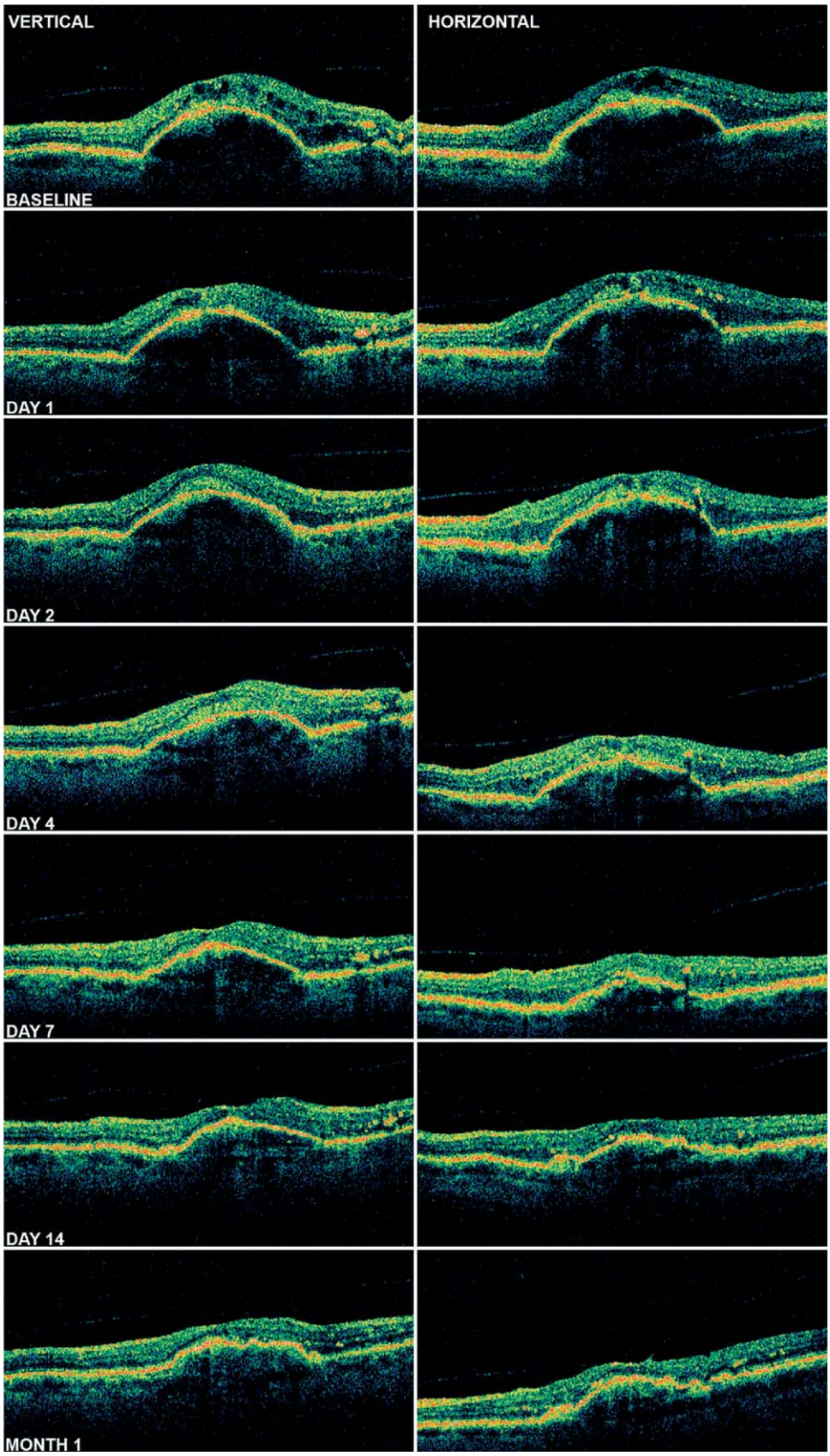

Petitioner Fresenius Ex. 1045, 0013

acuity at 12 months ($P = .78$; $P = .57$) or a PED at three months with visual acuity at 12 months ($P = .79$; $P = .68$).

There was no statistically significant correlation between the need for retreatment over 12 months and baseline visual acuity or baseline lesion size. The influence of baseline acuity and lesion size in disk areas on the number of reinjections was assessed with both Pearson correlation and Spearman nonparametric correlation analyses. No correlation was found between number of reinjections and baseline acuity (Pearson, $r = -.03$, $P = .88$; Spearman, $r = .14$, $P = .39$) or lesion size and (Pearson, $r = -.06$, $P = .71$; Spearman $r = -.04$, $P = .83$).

When the major baseline angiographic lesion types were analyzed over 12 months, they all required about the same number of injections. Overall, occult with no classic lesions (n = 10) received 5.4 injections (SD 2.2), minimally classic lesions (n = 23) received 5.6 injections (SD 2.1), and predominantly classic lesions (n = 7) received 5.7 injections (SD 3.4). A one-way parametric analysis of variance showed no statistically significant difference between these lesion types with respect to the number of injections performed ($P = .96$). However, there was statistical significance when comparing RAP lesions (n = 10) with non-RAP lesions (n = 30) ($P = .013$). RAP lesions received 7.1 injections (SD 2.2), whereas non-RAP lesions received 5.0 injections (SD 2.2). Similarly, when a one-way nonparametric analysis was performed (the Kruskal-Wallis test), no statistically significant difference was found between occult with no classic, minimally classic, or predominantly classic lesions with respect to the number of injections performed ($P = .89$); however, a significant difference was found when comparing RAP lesions with non-RAP lesions ($P = .003$).

The influence of reinjections on the change in visual acuity letter scores at 12 months was assessed with both Pearson and Spearman correlation analyses. Although no statistically significant correlation was found with either analysis (Pearson, $r = -.25$, $P = .13$; Spearman, $r = -.31$, $P = .054$), the results suggest a trend towards a possible correlation between more frequent injections and worse visual acuity outcome.

• **SAFETY:** There were no ocular or systemic adverse events attributable to the injection of ranibizumab. A total of 222 injections were performed and there were no episodes of endophthalmitis, uveitis, retinal detachment, retinal tear, vitreous hemorrhage, lens damage, cataract progression, or prolonged intraocular pressure elevation. No systemic thromboembolic events occurred and there were no deaths. No hypertension was newly diagnosed during the study. There was no cataract progression noted on clinical exam and no cataract surgery was performed. After one year, there was a mean change in systolic blood pressure of −8 mm Hg and a mean change in diastolic blood pressure of −5 mm Hg.

DISCUSSION

IN THE PRONTO STUDY, INTRAVITREAL INJECTIONS OF ranibizumab were shown to rapidly reduce the amount of macular fluid in eyes of patients with neovascular AMD while improving visual acuity. Within one day, both the mean and median OCT central retinal thickness measurements decreased significantly, and by day 14, both the mean and median visual acuity measurements had improved. Continued improvements were evident within the first 3 months after the three scheduled ranibizumab injections and these improvements were maintained through 12 months using a variable dosing regimen. After month 2, injections were stopped if the macula was found to be fluid-free and injections were resumed after certain retreatment criteria were met. When injections resumed, a single injection was usually sufficient to restore a fluid-free macula.

The PrONTO study visual acuity outcomes were similar to the results from the 0.5 mg treatment groups in the two Phase III clinical trials with ranibizumab that used a fixed monthly dosing regimen.[2,3] These two Phase III trials are known by the acronyms MARINA and ANCHOR. In the MARINA trial, mean visual acuity improved by 7.2 letters and in the ANCHOR trial, mean visual acuity improved 11.3 letters. In the PrONTO study, visual acuity improved by 9.3 letters at 12 months. Although patients in the MARINA and ANCHOR trials received 13 injections through 12 months, the patients in the PrONTO study received an average of just 5.6 injections with a median of five injections. Other visual acuity efficacy end points were similar as well. In the MARINA and ANCHOR trials, 94.6% and 96.4% of patient respectively avoided a 15-letter visual acuity decrease, whereas in the PrONTO study, 95% of patients avoided such a loss. In the MARINA and ANCHOR trials, 33.8% and 40.3% of patients gained at least 15 letters of visual acuity compared with 35% of patients in the PrONTO study. Finally, when comparing the proportion of patients with zero or more letters gained at 12 months, the MARINA and ANCHOR

FIGURE 8. Case 2: Optical coherence tomography (OCT) response to the first ranibizumab injection from baseline through month 1 in an eye with neovascular age-related macular degeneration (AMD) characterized as retinal angiomatous proliferation. Vertical (Left) and horizontal (Right) OCT scans and central retinal thickness measurements of the left eye are shown at baseline (305 μm; visual acuity [VA]: 20/50), ranibizumab no. 1 injected; day 1 (218 μm); day 2 (216 μm); day 4 (215 μm); day 7 (212 μm); day 14 (183 μm; VA: 20/40); month 1 (172 μm; VA: 20/40); ranibizumab no. 2 injected.

Petitioner Fresenius Ex. 1045, 0014

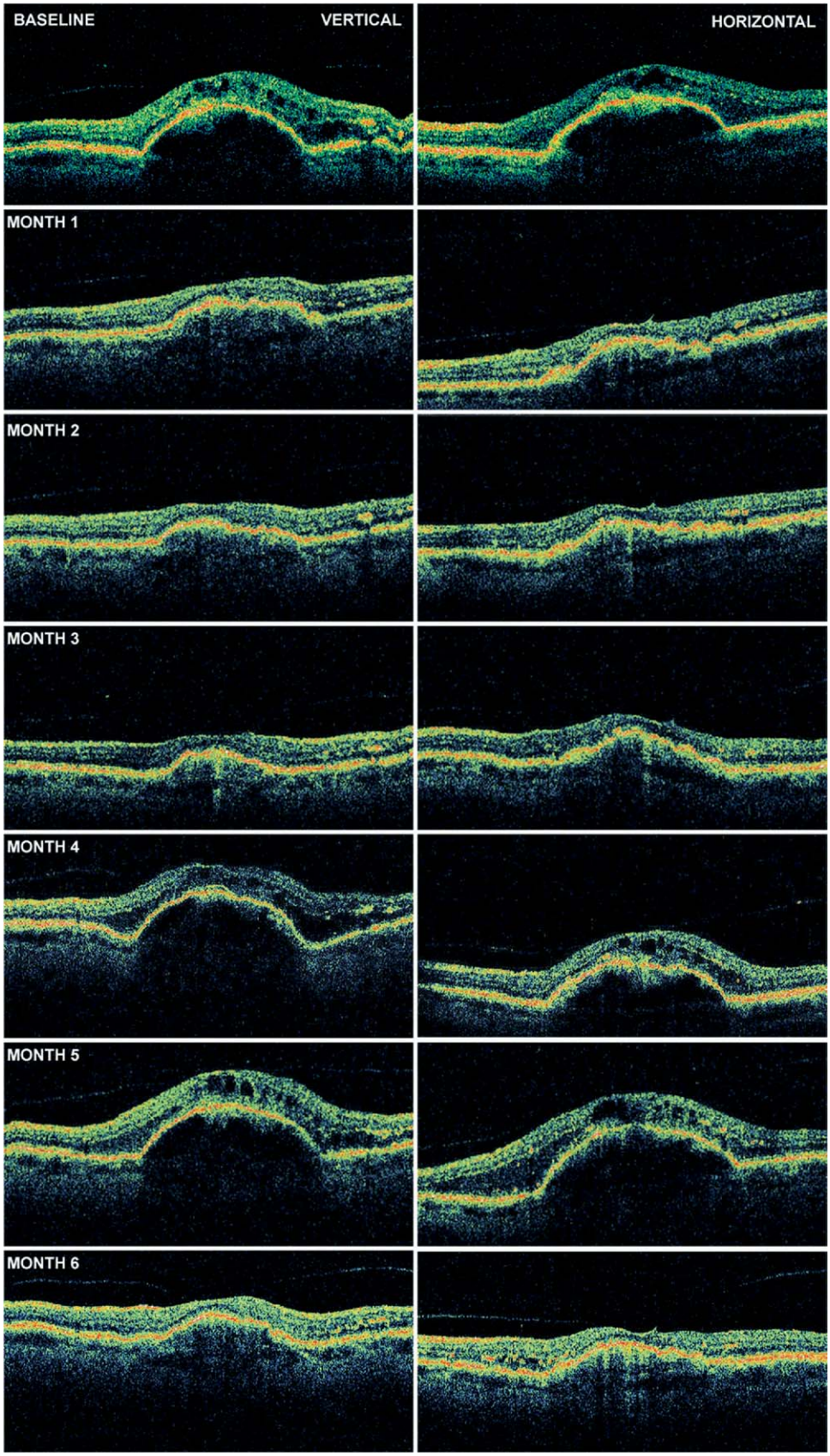

Petitioner Fresenius Ex. 1045, 0015

studies reported 71.3% and 77.7%, respectively, whereas the PrONTO study had 82.5% of patients without any letters lost.

While it is encouraging that the results of the PrONTO Study are similar to both the MARINA and ANCHOR trials, there are several differences between the studies that limit such comparisons. In contrast to these large, double-masked, randomized, controlled, Phase III clinical trials, the PrONTO study was a much smaller, open-label, unmasked study. The PrONTO study further differed from the Phase III trials by enrolling a heterogeneous population of neovascular lesions with prior therapy permitted and selected primarily by the presence of macular fluid as detected using OCT. As a result, the PrONTO study included both minimally classic and occult with no classic lesions as in the MARINA trial as well as predominantly classic lesions as in the ANCHOR trial; however, the lesions in the phase III trials were selected based on angiographic criteria and no prior therapy was permitted.

Perhaps it would be more appropriate to compare the PrONTO results alongside the PIER trial, another Phase III ranibizumab trial that included all the major angiographic lesion subtypes of neovascular AMD. [4] In the PIER trial, patients received three scheduled monthly injections as in the PrONTO Study, but after the second month, the PIER protocol followed a fixed dosing regimen of every three months. In contrast to the PrONTO study, the mean visual acuity decreased at month 12 by 0.2 letters. The other secondary visual acuity end points showed a similar decrease in efficacy compared with the MARINA and ANCHOR trials. The most likely explanation for these disappointing outcomes from the PIER trial is the need for more frequent retreatment in some patients as shown from the results of the PrONTO study.

The retreatment criteria chosen for the PrONTO were based on clinical observations made following the completion of the Phase I/II ranibizumab studies and during the extension study when patients could be retreated at the discretion of the investigator. From these observations, it appeared that OCT could detect the earliest signs of recurrent fluid in the macula after the ranibizumab injections were stopped. The signs of recurrent fluid included the appearance of macular cysts or subretinal fluid, and these signs were thought to represent the earliest manifestations of recurrent CNV. The PrONTO study was designed to demonstrate that if these early signs were observed and followed over time, then more fluid would eventually accumulate within the macula, leading to vision loss, hemorrhage, or classic CNV. For this reason, the OCT retreatment criteria chosen for the PrONTO study required that a large amount of fluid reaccumulate in the macula (100 μm) or vision loss occur before retreatment was offered. Although the vast majority of reinjections in the PrONTO used one of the OCT-based criteria, some eyes were reinjected because of new hemorrhage or new classic CNV. However, regardless of the criteria used, the need for retreatment could have been predicted based on qualitative OCT changes alone. Whenever new hemorrhage or new classic CNV was present, the OCT always showed recurrent fluid in the macula, but of a level insufficient to trigger a retreatment based on the criteria used in this study. Even in months before an increase in central retinal thickness of at least 100 μm or a five letter visual acuity decrease associated with fluid in the macula, there were always qualitative changes on the OCT images suggestive of new fluid in the macula. Therefore, one possible strategy for future ranibizumab studies would be to use any qualitative OCT change that suggests recurrent fluid such as the appearance of any cysts or subretinal fluid as the basis for retreatment. Perhaps, current PrONTO results would have been even better if patients had been reinjected as soon as the recurrent fluid was detected by OCT rather than waiting until more fluid accumulated or vision deteriorated.

A direct head-to-head trial will be necessary to unequivocally conclude that a variable dosing regimen using OCT is as good as a fixed monthly dosing regimen, but it is unlikely such a study will ever be performed now that ranibizumab is commercially available, and an ongoing Phase IIIb clinical safety study with more than 2,000 patients uses an open-label, variable-dosing regimen similar to the regimen used in the PrONTO study. This Phase IIIb study is known by the acronym SAILOR.[4] Most likely, future studies with ranibizumab in neovascular AMD will focus on ways to further reduce the overall number of ranibizumab injections while achieving the same or better visual acuity outcomes. This approach will be particularly useful for RAP lesions. A decrease in the number of injections would reduce the potential risk of injection-related complications, and an increase in the injection-free interval

FIGURE 9. Case 2: Optical coherence tomography (OCT) response from baseline through month 6 after ranibizumab injections at month 1, month 2, month 3, and month 5 in an eye with neovascular age-related macular degeneration (AMD) characterized as retinal angiomatous proliferation. Vertical (Left) and horizontal (Right) OCT scans and central retinal thickness measurements are shown of her left eye at baseline (305 μm, visual acuity [VA]: 20/50), ranibizumab no. 1 injected; month 1 (172 μm; VA: 20/40), ranibizumab no. 2 injected; month 2 (172 μm; VA: 20/32), ranibizumab no. 3 injected; month 3 (173 μm; VA: 20/32), observed; month 4 (251 μm; VA: 20/40), observed; month 5 (328 μm; VA: 20/32), ranibizumab no. 4 injected; month 6 (147 μm; VA: 20/32), observed.

Petitioner Fresenius Ex. 1045, 0016

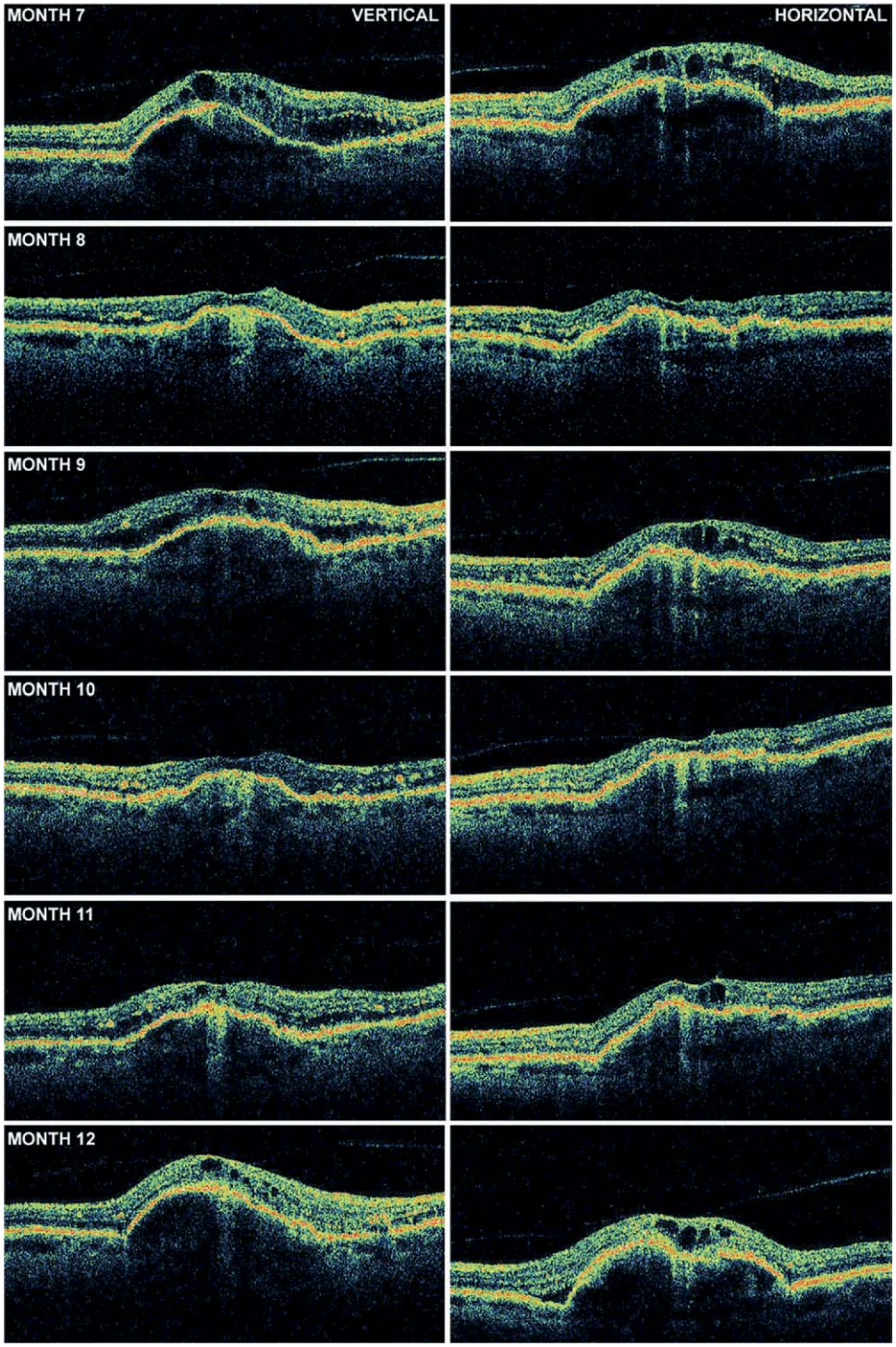

FIGURE 10. Case 2: Optical coherence tomography (OCT) response from month 7 through month 12 after ranibizumab injections at month 7, month 9, and month 12 for a total of seven ranibizumab injections over 12 months in an eye with neovascular age-related macular degeneration (AMD) characterized as retinal angiomatous proliferation. Vertical (Left) and horizontal (Right) OCT scans and central retinal thickness measurements are shown of her left eye at month 7 (277 μm; VA: 20/40), ranibizumab no. 5 injected; month 8 (144 μm; visual acuity [VA]: 20/32), observed; month 9 (277 μm; VA: 20/40), ranibizumab no. 6 injected; month 10 (151 μm; VA: 20/40), observed; month 11 (201μm; VA: 20/40), observed; month 12 (280 μm; VA: 20/50), ranibizumab no. 7 injected.

Petitioner Fresenius Ex. 1045, 0017

would reduce the burden of frequent follow-up evaluations.

In conclusion, a variable dosing regimen with ranibizumab resulted in an average of 5.6 injections over one year with visual acuity and OCT improvements that were statistically and clinically significant. These results were similar to the outcomes obtained using 13 monthly injections over one year in the fixed-dosing Phase III regimens. The outcomes from the PrONTO study suggest that OCT can be useful for guiding retreatment with intravitreal ranibizumab in neovascular AMD, and the use of such an OCT-guided, variable-dosing regimen should decrease the injection burden without sacrificing improvements in visual acuity.

THIS STUDY WAS SUPPORTED IN PART BY GENENTECH, INC SOUTH SAN FRANCISCO, CALIFORNIA, AN UNRESTRICTED grant from Research to Prevent Blindness, Inc, New York, New York, NEI core grant P30 EY014801; and by the German Research Foundation (DFG), Bonn, Germany. Drs Fung and Rosenfeld have received additional clinical research grants from Genentech, Inc. Drs Rosenfeld, Fung, Flynn, Jr, and Puliafito have received payment for participating on Genentech Advisory Boards. Drs Rosenfeld and Fung have participated in the Genentech speaker's bureau program and received lecture fees. Dr Rosenfeld has participated in scientific advisory boards from competing companies: Eyetech Pharmaceuticals, Melville, New York, Novartis Ophthalmics, East Hanover, New Jersey, Protein Design Labs, Fremont, California, Allergan, Irvine, California, BioAxone, Saint-Laurent, Quebec, Quark Inc, Fremont, California, Jerini AG, Berlin, Germany, Genaera, Plymouth Meeting, Pennsylvania, Tanox, Houston, Texas, and Athenagen, South San Francisco, California. Dr Fung has participated in scientific advisory boards from competing companies: Eyetech Pharmaceuticals and Santen, Napa, California. Dr Michels has participated in scientific advisory boards from competing companies: Pfizer, New York, New York, and Novartis Ophthalmics. Dr Puliafito has participated in scientific advisory boards from the competing company Eyetech Pharmaceuticals. Dr Davis has participated in scientific advisory boards from the competing company Bausch & Lomb, Rochester, New York. Dr Fynn, Jr, has participated in scientific advisory boards from competing companies: Alcon, Fort Worth, Texas, Allergan, Eyetech Pharmaceuticals, Novartis Ophthalmics, and Lilly, Indianapolis, Indiana. Dr Rosenfeld has indicated support for lecture fees from the following competing companies: Eyetech Pharmaceuticals and Novartis Ophthalmics. Dr Michels has indicated support for lecture fees from the following competing companies: Alcon and Novartis Ophthalmics. Dr Puliafito has indicated support for lecture fees from the following competing company: Eyetech Pharmaceuticals. Dr Flynn, Jr, has indicated support for lecture fees from the following competing companies: Eyetech and Lilly. Dr Rosenfeld has received clinical research grants from the following competing companies: Eyetech Pharmaceuticals, QLT, Inc, Fort Collins, Colorado, Novartis Ophthalmics, and Alcon Laboratories. Dr Davis has received clinical research grants from the following competing companies: Bausch & Lomb, Inspire Pharmaceutical, Durham, North Carolina, and Allergan Pharmaceuticals. Dr Puliafito is designated on a patent for optical coherence tomography and receives royalties. Involved in conception and design of study (P.J.R., S.M., C.A.P.); analysis and interpretation (A.E.F., G.A.L., P.J.R., W.F., M.E.), writing the article (A.E.F., G.A.L., P.J.R., W.F., M.E.); critical revisions (S.R.D., S.M., C.A.P., J.L.D., H.W.F.); final approval (A.E.F., G.A.L., P.J.R., S.R.D., S.M., W.F., C.A.P., J.L.D., H.W.F., M.E.); data collection (A.E.F., G.A.L., P.J.R., S.R.D., S.M., J.L.D., M.E.); provision of patients and resources (P.J.R., S.R.D., C.A.P., J.L.D., H.W.F.); statistical expertise (W.F.); obtaining funding (P.J.R., C.A.P.); literature search (A.E.F., G.A.L., P.J.R., S.M.); and research technical and administrative support (A.E.F., W.F., C.A.P., M.E.).

Both Anne E. Fung, MD, and Geeta A. Lalwani, MD, contributed equally to the success of this clinical study. The authors gratefully acknowledge the following medical retina fellows from the Bascom Palmer Eye Institute for their expert clinical assistance in evaluating the PrONTO patients: Ryan M. Rich, MD, Bascom Palmer Eye Institute, Miami, Florida; Richard C. Lin, MD, PhD, University of Chicago, Department of Ophthalmology, Chicago, Illinois; and Jackie K. Nguyen, MD, Tufts University, Department of Ophthalmology, Medford, Massachusetts.

REFERENCES

1. Gragoudas ES, Adamis AP, Cunningham ET Jr, et al. VEGF Inhibition Study in Ocular Neovascularization Clinical Trial Group. Pegaptanib for neovascular age-related macular degeneration. N Engl J Med 2004;351:2805–2816.
2. Rosenfeld PJ, Brown DM, Heier JS, et al. Ranibizumab for neovascular age-related macular degeneration. N Engl J Med 2006;355:1419–1431.
3. Brown DM, Kaiser PK, Michels M, et al. Ranibizumab vs verteporfin for neovascular age-related macular degeneration. N Engl J Med 2006;355:1432–1444.
4. Preliminary results from a phase IIIb study showed patients with wet AMD treated with Lucentis quarterly experienced a 16-letter benefit over the control group at one year. [press release]. South San Francisco, California: Genentech; June 2, 2006. Available at: http://www.gene.com/gene/news/press-releases/display.do?method=detail&id=9747. Accessed Date: August 26, 2006.
5. Chen Y, Wiesmann C, Fuh G, et al. Selection and analysis of an optimized anti-VEGF antibody: crystal structure of an affinity-matured Fab in complex with antigen. J Mol Biol 1999;293:865–881.
6. Heier JS, Antoszyk AN, Pavan PR, et al. Ranibizumab for treatment of neovascular age-related macular degeneration: a phase I/II multicenter, controlled, multidose study. Ophthalmology 2006;113:642 e1–e4.
7. Rosenfeld PJ, Heier JS, Hantsbarger G, et al. Tolerability and efficacy of multiple escalating doses of ranibizumab (Lucentis) for neovascular age-related macular degeneration. Ophthalmology 2006;113:632 e1.
8. Treatment of Age-Related Macular Degeneration with Photodynamic Therapy (TAP) Study Group. Photodynamic therapy of subfoveal choroidal neovascularization in age-related macular degeneration with verteporfin: one-year results of 2 randomized clinical trials TAP report 1. Arch Ophthalmol 1999;117:1329–1345.

Petitioner Fresenius Ex. 1045, 0018

Biosketch

Anne E. Fung, MD, graduated with honors in Chinese Studies and Economics from Wellesley College in 1993 and received her MD from Cornell University Medical College in 1999. After completing residency at Stanford University, she pursued a research fellowship at the Smith Kettlewell Eye Research Institute. In 2005, she completed a Medical Retina fellowship at the Bascom Palmer Eye Institute and returned to San Francisco to join her father at Pacific Eye Associates/California Pacific Medical Center where she continues clinical research in age-related macular degeneration.

Petitioner Fresenius Ex. 1045, 0019

Biosketch

Geeta A. Lalwani, MD, is currently a surgical retina fellow at the Bascom Palmer Eye Institute in Miami, Florida. She received an AB from Smith College, and an MD from the MCP-Hahnemann School of Medicine, where she was elected into the Alpha Omega Alpha honor society. She will complete her fellowship in July 2007.

View publication stats

Petitioner Fresenius Ex. 1045, 0020