Invited Review

Digestion

Digestion 2015;92:175–184
DOI: 10.1159/000439523

Received: July 7, 2015
Accepted: August 17, 2015
Published online: September 16, 2015

New Advances in the Treatment of Metastatic Pancreatic Cancer

Marvin Schober[a] Muhammad A. Javed[d] G. Beyer[b] Nha Le[e] Alessio Vinci[g] Malin Sund[f] Albrecht Neesse[c] Sebastian Krug[a]

[a]University of Halle, Department of Gastroenterology and Hepatology, Halle, [b]Department of Medicine A, University Medicine, Greifswald University, Greifswald, and [c]University Medical Centre Göttingen, Department of Gastroenterology and Gastrointestinal Oncology, Göttingen, Germany; [d]NIHR Liverpool Pancreas Biomedical Research Unit, Department of Molecular and Clinical Cancer Medicine, Royal Liverpool University Hospital, Liverpool, UK; [e]Semmelweis University, Second Internal Medicine Department, Gastroenterology Division, Budapest, Hungary; [f]University of Umea, Department of Surgical and Perioperative Sciences, Umea, Sweden; [g]University of Pavia, Department of Surgery, IRCCS S. Matteo University Hospital Foundation, Pavia, Italy

Key Words
Chemotherapy · Pancreatic ductal adenocarcinoma · FOLFIRINOX · Nab-paclitaxel · Chemoresistance

Abstract
Background: Pancreatic ductal adenocarcinoma (PDAC) is characterised by an extremely poor overall survival (OS) compared to other solid tumours. As the incidence of the disease is rising and the treatment options are limited, PDAC is projected to be the 2nd leading cause of cancer-related deaths in the United States by 2030. A majority of patients are not eligible for curative resection at the time of diagnosis, and those that are resected will often relapse within the first few years after surgery. ***Summary:*** Until recently, the nucleoside analogue gemcitabine has been the standard of care for patients with non-resectable PDAC with only marginal effects on OS. In 2011, the gemcitabine-free FOLFIRINOX regimen (folinic acid, fluorouracil, irinotecan and oxaliplatin) showed a significant survival advantage for patients with metastatic PDAC in a phase III trial. In 2013, the Metastatic Pancreatic Adenocarcinoma Trial phase III trial with nanoformulated albumin-bound paclitaxel (nab-paclitaxel) in combination with gemcitabine also resulted in a significant survival extension compared to gemcitabine monotherapy. However, both intensified therapy regimens show a broad spectrum of side effects and patients need to be carefully selected for the most appropriate protocol. ***Key Message:*** In this study, recent advances in the chemotherapeutic options available to treat metastatic PDAC and their implications for today's treatment choices are reviewed.

© 2015 S. Karger AG, Basel

Introduction

Pancreatic ductal adenocarcinoma (PDAC) is considered to be one of the most lethal solid organ tumour. The extraordinarily poor prognosis can be attributed to the lack of early clinical symptoms and good biomarkers, early metastatic dissemination and an unusually high resistance to targeted and cytotoxic agents. The incidence of pancreatic cancer ranges worldwide from 1 to 10 cases per 100,000, out of which 85% are adenocarcinomas [1]. The

KARGER 125

E-Mail karger@karger.com
www.karger.com/dig

© 2015 S. Karger AG, Basel
0012–2823/15/0923–0175$39.50/0

Albrecht Neesse, MD, PhD
Department of Gastroenterology and Gastrointestinal Oncology
University Medical Centre Göttingen
Robert-Koch-Strasse 40, DE–37075 Göttingen (Germany)
E-Mail albrecht.neesse@med.uni-goettingen.de

Table 1. Currently recruiting and ongoing clinical phase III trials with intensive chemotherapy

Design	Compound/specifics	Clinical trial
Adjuvant		
Gemcitabine + nab vs. gemcitabine		NCT01964430
Gemcitabine vs. FOLFIRINOX		NCT02355119
Gemcitabine vs. mFOLFIRINOX		NCT01526135
Neoadjuvant		
Surgery + gemcitabine adjuvant vs. FOLFIRINOX neoadjuvant – surgery – FOLFIRINOX adjuvant		NCT02172976
Surgery + PEXG adjuvant vs. PEXG neoadjuvant + surgery + adjuvant vs. gemcitabine adjuvant		NCT01150630
Palliative 1st-line		
Gemcitabine vs. FOLFOX	hENT1 expression	NCT01586611
Gemcitabine + nab + ibrutinib vs. gemcitabine + nab	Bruton's tyrosine kinase inhibitor	NCT02436668

incidence is slightly higher in developed countries, among men, and a number of risk factors as well as genetic syndromes/mutations that are associated with pancreatic cancer have been identified [1, 2]. The genetic hallmark of PDAC is an activating KRAS mutation, followed by the deletion or the inactivation of mutations in tumour-suppressor genes such as p16, DPC4 and p53 [3–5]. Extensive experimental studies in mice and men have identified and characterised a molecular and histological progression model ranging from early to advanced precursor lesions (so called pancreatic intraepithelial neoplasia lesions, PanIN I–III), to frank adenocarcinoma. Moreover, PDAC is typically accompanied by an extensive desmoplastic stroma reaction contributing to a hypovascular and hypoxic microenvironment, which possibly affects the delivery and efficacy of chemotherapeutic agents, reprogramming of cellular metabolism and evasion of tumour immunity [6–8].

Clinical symptoms of PDAC patients are often very unspecific and hard to detect early. Patients may complain of abdominal discomfort (with no signs of peritoneal irritation), weight loss, painless jaundice and unspecific back pain [9, 10]. Onset of type II diabetes as well as unexplained deep vein thrombosis may also indicate the development of PDAC, but also occur for many other reasons in the elderly. Once the diagnosis of PDAC is suspected, a multi-modal diagnostic work-up using modalities such as sonography, endosonography, multi-slice CT as well as MRI should be performed in a multi-disciplinary team. In case of a metastatic disease, histological confirmation prior to cytotoxic treatment is obligatory. Surgical resection is the only potentially curative treatment and criteria of surgical resectability are based on the involvement of the local vessels [11] and presence or absence of metastatic disease. Until now, only about 20–25% of patients are eligible for surgical resection. Current treatment standards advocate the use of adjuvant chemotherapy following surgery. For locally advanced pancreatic adenocarinomca (LAPC), there is growing interest in the use of neoadjuvant approaches, which are being evaluated, as in the currently recruiting Conko 007 trial (EUDRACT Nr. 2009-014476-21). This phase III trial is evaluating the role of a combined chemoradiotherapy after leading-in with chemotherapy in patients with LAPC, interestingly already making use of FOLFIRINOX as a potential treatment arm. The currently enrolling NEONAX-trial, a phase II trial conducted by the AIO (EUDRACT-Nr. 2013-005559-34), is addressing the question of whether or not a neoadjuvant combination treatment with nab-paclitaxel and gemcitabine plus adjuvant or only adjuvant gemcitabine and nab-paclitaxel treatment can downstage the tumour prior to surgery in patients with resectable PDAC (table 1). Despite numerous clinical trials in stage IV (metastatic) PDAC, there has only been a modest improvement of median survival rates for this group of patients [12–15]. In the last 2 decades, biomarker discovery and validation has been a key area of research to stratify patients, predict response to treatment and enable the development of a tailored treatment approach. The aim of this review is to provide a comprehensive overview of the development of chemotherapeutic regimens that have been used for the treatment of metastatic PDAC with a particular focus on the recently introduced gemcitabine-free FOLFIRINOX regimen (folinic acid, fluorouracil, irinotecan and oxaliplatin) and nab-paclitaxel + gemcitabine.

Ipsen Ex. 2016, Page 2 of 10

Table 2. The evolution of approved therapeutic regimens in patients with metastatic PDAC

	Burris et al. 1997	Moore et al. 2007	Conroy et al. 2011	Von Hoff et al. 2013
Regimen	Gemcitabine vs. 5-FU	Gemcitabine + erlotinib vs. gemcitabine	Gemcitabine vs. FOLFIRINOX	Gemcitabine vs. gemcitabine + nab
Number of patients	126	569	342	861
Population	Advanced PDAC	Advanced PDAC (24.3% LAPC) (~8% prior resection of primary tumour)	Metastatic PDAC	Metastatic PDAC
Characteristics				
Biliary stent	Not mentioned	Not mentioned	15.8%	17%
Head tumors	Not mentioned	Not mentioned	39.2%	43%
ECOG/Karnofsky PS	PS 80–90~30% PS 50–70~70%	ECOG 0–1~80% ECOG 2~20%	ECOG 0–1~99 ECOG 2~1%	PS 90–100~60% PS 60–90~40%
Objective response rate, %	5.4 vs. 0	8.6 vs. 8	9.4 vs. 31.6	7 vs. 23
Disease control rate, %	44.4 vs. 19	57.5 vs. 49.2	50.9 vs. 70.2	33 vs. 48
mPFS/TTP*	9 vs. 4 w*	3.75 vs. 3.55 m	3.3 vs. 6.4 m	3.7 vs. 5.5 m
mOS, m	5.65 vs. 4.41	6.24 vs. 5.91	6.8 vs. 11.1	6.7 vs. 8.5
Survival rates 12 m, %	18 vs. 2	23 vs. 17	20.6 vs. 48.4	22 vs. 35
Treatment effect in subgroup analyses	Not mentioned	PS 2, HR 0.61 Pain-Score <20, HR 0.71 Age <65, HR 0.75	Age >65, HR 0.48 ECOG 1, HR 0.55 Two metastatic sites HR 0.39 No biliary stent HR 0.56	Age <65, HR 0.65 PS 70–80%, HR 0.61 Liver mets HR 0.69 CA 19–9 >59 ULN, HR 0.61
Specifics	CBR	– More female in the combination arm – Female associated with longer OS	– 'French-only' study – ~15% not radiologically evaluable – 38% head tumours	– Only 'North Americans' benefited – 42% head tumours

Current Management of Metastatic Disease

From 5-Fluorouracil to Gemcitabine

5-Fluorouracil (5-FU) was considered the only chemotherapeutic option for about 20 years until the introduction of gemcitabine [13, 16–18]. Several clinical studies could show that chemotherapy in advanced pancreatic cancer patients indeed leads to a modest survival benefit as well as improved quality of life (QoL) compared to best supportive care alone [19–21], but the combination of 5-FU with other drugs did not prove to be superior to the single anti-metabolite treatment [16, 22]. During the 1990s, several trials were designed to find new active drugs in pancreatic cancer treatment and the nucleoside analogue gemcitabine (2′-deoxy-2′,2′-difluorocytinide) was studied [12, 23]. In 1997, gemcitabine became the first line choice for PDAC patients due to fewer side effects (compared to 5-FU) and a significant survival benefit (table 2). This clinical study also implemented the concept of clinical benefit response (CBR) that was defined as a ≥50% reduction in pain intensity, daily analgesia consumption or ≥20 point improvement in Karnofsky performance status (PS) for ≥4 consecutive weeks. CBR was significantly improved in gemcitabine-treated patients ($p = 0.0022$) [13]. The CBR was shown to be 23.8% in gemcitabine-treated patients (1,000 mg/m^2 over 30 min) compared to 4.8% in 5-FU-treated patients (400 mg/m^2 over 30 min), and the median survival time in the gemcitabine group was 5.65 months compared to 4.41 months in the 5-FU-group, respectively ($p = 0.0025$). In the gemcitabine group, 18% compared to 2% for the 5-FU survived the first 12 months [13]. Several phase III trials with gemcitabine monotherapy revealed a median survival of 5–7 months with a

Ipsen Ex. 2016, Page 3 of 10

1-year survival of about 1–25%. Therefore, subsequent chemotherapy trials in PDAC needed to show superiority over standard of care gemcitabine monotherapy. This could be achieved by either of the 2 strategies: (1) combining gemcitabine with a new drug or (2) directly comparing a novel monotherapy or combination therapy against gemcitabine.

Gemcitabine and Fluoropyrimidines

While the results of gemcitabine clearly improved therapeutic efficacy and 1-year survival, its impact on median overall survival (OS) remained at the margin of significance. More intensive combination chemotherapies involving fluoropyrimidines and platinum analogues were investigated in numerous phase II and III trials. Two randomised phase III trials evaluated the combination of gemcitabine and 5-FU compared to gemcitabine alone. In short, the experimental arm did not improve the objective response or median OS [24, 25].

Capecitabine is an oral, tumour-selective fluoropyrimidine carbamate and pro-drug that is activated by a 3-step-targeted process (carboxylesterases, cytidine deaminase and thymidine phosphorylase, respectively). Capecitabine can be used in schedules that provide prolonged fluorouracil exposure at lower peak concentrations, thus mimicking continuous infusion of fluorouracil. Preclinical studies have shown no synergistic effect of capecitabine anti-tumour activity when combined with gemcitabine; however, relevant toxicity was noted in genetically engineered mice of pancreatic cancer more recently [26]. Herrmann and Cunningham published 2 randomised phase III trials of gemcitabine +/– capecitabine (650 or 830 mg/m^2 twice daily) in patients with metastatic PDAC. There was no statistically significant improvement of the median OS in the combination arm (8.4 vs. 7.2 m and 7.4 vs. 6.0 m; p = 0.234 and p = 0.08). However, a subgroup of patients with good PS (Karnofsky performance score 90–100) benefited (10.1 vs. 7.4 months, respectively; p = 0.014) from the combination treatment. In addition, in the Cunningham et al. [27] study, gemcitabine and capecitabine significantly improved the response rate (RR) (19.1 vs. 12.4%, p = 0.034) and progression-free survival (HR 0.78, p = 0.004). Interestingly, by pooling the data set of these 2 phase III trials and the phase II trial of Schreithauer in 935 patients, statistical significance could be achieved for median OS (HR 0.86; 95% CI 0.75–0.98, p = 0.02) [19, 20, 28]. Independently from this data, Hubner et al. [29] presented single-centre results of the gemcitabine plus capecitabine combination, leading to a median OS of 8.7 m (95% CI 6.7–10.7) and 1-year survival rate of 34%. Despite the fact that gemcitabine combined with fluoropyrimidine has reliable activity in metastatic PDAC, the QoL did not significantly differ between the 2 treatment arms [29–31]. Based on this data, the combination GEMCAP has replaced 5-FU therapy in clinical practice, especially in the United Kingdom.

Gemcitabine in Combination with Platinum-Derivates and Topoisomerase Inhibitors

There have been numerous phase II and III studies attempting to improve the efficacy and OS of chemotherapy in metastatic PDAC by using gemcitabine-based combination therapies. The combination of gemcitabine with platinum-derivates was evaluated in 11 trials in more than 2,000 patients [31]. One of the most promising trials was the GERCOR/GISCAD study where the combination of gemcitabine and oxaliplatin improved the PFS (5.58 vs. 3.7 months), CBR (38.2 vs. 26.9%) and RR (26.8 vs. 17.3%). However, no statistical significance was reached for OS [32] and the subsequent phase III trials did not confirm these encouraging results [33–35]. A recently published meta-analysis compared gemcitabine plus oxaliplatin with gemcitabine alone. Here, ORs of 1.33 (95% CI 1.05–1.69, p = 0.019) for OS and ORs of 1.38 (95% CI 1.08–1.76, p = 0.011) for PFS demonstrated and showed statistical significance [19, 20, 28, 31].

Similar results were obtained for gemcitabine and topoisomerase inhibitors (irinotecan and exatecan) combinations. Although preliminary data suggested a relevant clinical activity for topoisomerase inhibitors, 4 randomised clinical trials revealed no significant improvement of PFS or OS [36–39]. Finally, in the Cancer and Leukemia Group B (CALGB) study, 3 relevant combination therapies (gemcitabine plus cisplatin, gemcitabine plus docetaxel, gemcitabine plus irinotecan) vs. gemcitabine monotherapy demonstrated no relevant 6-month survival benefit for the experimental arms [36]. Therefore, the authors made a decision to refrain from further investigating gemcitabine-based combinations for PDAC.

Gemcitabine and Erlotinib

The epidermal growth factor receptor inhibitor erlotinib was the first drug that was shown to be beneficial in combination with gemcitabine in patients with advanced pancreatic cancer (table 2). In the PA.3 trial, 569 patients were randomised with both locally advanced and metastatic disease to receive gemcitabine or gemcitabine plus erlotinib. Though OS was significantly improved with combination therapy (median survival of 6.2 vs. 5.9

Ipsen Ex. 2016, Page 4 of 10

months), clinical relevance of a 2-week survival benefit had to be questioned [40]. This marginal benefit also came at the expense of toxicity with 6 treatment-related deaths reported during the study – all within the combination therapy group. Eight patients from the study (7 from the erlotinib cohort) also developed interstitial lung disease and the risk-benefit of this drug combination remains a controversial topic [41].

Interestingly, the combination of erlotinib and gemcitabine achieved astonishing response in a small subset of patients. It was noted that those patients developing a rash of grade ≥2 in severity showed a median survival of 10.5 months and 1-year survival of 43% in contrast with 5.3 months and 16% respectively in patients with no rash. Therefore, the German S3-guideline for exocrine pancreatic cancer recommends an initial therapeutic attempt with erlotinib and gemcitabine for an 8-week period. After this time, treatment should be continued only if a skin rash develops [11]. This interesting finding could be recapitulated in another study by Vaccaro et al. [42]; however, dose-escalation did not yield further therapeutic efficacy.

Folinic Acid, Fluorouracil, Irinotecan and Oxaliplatin (FOLFIRINOX)

Several studies were performed to investigate gemcitabine-based polychemotherapy regimens comprising several cytotoxic drugs. The PEFG protocol compared cisplatin, epirubicin, 5-FU and gemcitabine to gemcitabine alone [43]. The same group introduced another 2, 4-drug combinations based on the PEFG regimen called PEXG (cisplatin, epirubicin, capecitabine and gemcitabine) and PDGX (cisplatin, docetaxel, capecitabine and gemcitabine). Although median OS of 11 m were reached in this phase II study, the results were interpreted with caution, since only 2/3 of the patients had metastatic disease [44]. Another regimen called G-FLIP comprised CPT-11 (irinotecan), gemcitabine, 5-FU, leucovorin and cisplatin [45], and subsequently FOLFOX-6 and FOLFIRI-3 were evaluated in the first-line setting of advanced PDAC [46, 47]. Despite median OS times between 8 and 12 months and higher RRs, increased major toxicities, the inhomogeneity of the patient cohorts and the insufficient inclusion criteria gave rise to doubts whether polychemotherapy was the adequate treatment strategy.

FOLFIRINOX is a chemotherapy regimen comprising 4 drugs – folinic acid, 5-FU, irinotecan and oxaliplatin. This combination of drugs was supported by preclinical studies demonstrating either single agent efficacy against pancreatic cancer or synergistic activity in combination with a fellow agent. Based on ambitious phase I/II data in which FOLFIRINOX revealed a good safety profile and appealing RRs, Conroy et al. [48] conducted a French phase II/III trial (PRODIGE) with OS as primary objective, and PFS, QoL, RR and toxicity as secondary endpoints [48, 49]. In total, 342 patients were enrolled and FOLFIRINOX was administered with the following dose: oxaliplatin at a dose of 85 mg/m^2 over 2 h followed by leucovorin at a dose of 400 mg/m^2 given as a 2-hour intravenous infusion and irinotecan at a dose of 180 mg/m^2 in a 90-minute intravenous infusion [50]. This treatment was immediately followed by 5-FU at a dose of 400 mg/m^2, administered by intravenous bolus, followed by a continuous intravenous infusion of 2,400 mg/m^2 over a 46-hour period every 2 weeks. The patients on FOLFIRINOX demonstrated a median survival of 11.1 months, which was clearly superior when compared to the 6.8 months of the gemcitabine control group (table 2). The median progression-free survival was 6.4 months in FOLFIRINOX-treated patients versus 3.3 months in patients who received gemcitabine [50]. Compared to treatment with gemcitabine, treatment with FOLFIRINOX resulted in a superior tumour RR (9.4 vs. 31.6%); however, 50 patients (25 per arm) were not radiologically assessable. Yet in 2005, this regime showed promising results, when it had been administered to a heterogeneous group of patients just defined as histologically proven advanced PDAC, but containing both LAPC and metastatic PDAC. Thus, the treatment regimen was not exclusively restricted to patients suffering from metastatic disease [48]. However, in order to achieve the benefits shown, the FOLFIRINOX regimen requires a careful selection of patients, which implicates strict limitations as the potential real-life first line option. In the study by Conroy et al., only patients with nearly unrestricted ECOG-PS of 0–1, below 76 years of age, no cardiac ischemia within 1 year before entry, and total bilirubin levels below 1.5 times the upper normal limit were included. Interestingly, only 35–40% suffered from a pancreatic head adenocarcinoma and therefore, solely 15% received stenting of the biliary duct. No single cholangitis had been observed during the course of the trial. This difference may be related to the exclusion of patients with elevated bilirubin levels, because of the increased risk of irinotecan-induced toxicity [51]. As shown by Conroy et al., even de-escalation (n = 80 received second-line treatment in the FOLFIRINOX arm) might be necessary; yet it resulted in an impressive median OS of 4.4 months from the beginning of second-line chemotherapy. Particularly, this accounts as one explanation for the 1-year survival rate of 48.4% for patients

Ipsen Ex. 2016, Page 5 of 10

treated with FOLFIRINOX versus 20.6% for patients receiving gemcitabine ($p < 0.001$). Despite the strict selection criteria for the study, patients on FOLFIRINOX suffered more frequently from adverse events or severe side effects compared to the patients on gemcitabine. Forty five percent of the FOLFIRINOX patients developed neutropenia and 5.4% showed febrile neutropenia. In addition, thrombocytopenia (9.1%), diarrhea (12.7%) and sensory neuropathy (9.0%) occurred significantly more often in FOLFIRINOX patients, which implies a need for increased clinical routine check-up intervals for patients receiving this intensive regime. Moreover, supportive therapies such as nutritional support, G-CSF treatment or antibiotics are more often needed, and the discontinuation of the therapy may be required. However, G-CSF was not recommended in this trial to prevent neutropenia. Two years after the publication of the primary study data, QoL evaluations were presented [52]. Although FOLIRINOX had remarkable side effects, it significantly reduced QoL impairment compared with gemcitabine in patients with metastatic PDAC. Only diarrhea was significantly increased in the FOLFIRINOX arm. Beyond the PS, age >65 years and low serum albumin were seen as independent prognostic factors for poor survival in this situation.

Gemcitabine and Nab-Paclitaxel

In 2013, a second intensified combination-chemotherapy regimen – gemcitabine with nab-paclitaxel – was presented for the treatment of patients suffering from metastatic PDAC Metastatic Pancreatic Adenocarcinoma Trial (MPACT-Trial).

Nab-paclitaxel is a nanoparticle-sized, albumin-bound paclitaxel, which was originally developed to avoid toxic and immunogenic solvents of hydrophobic paclitaxel, and was first approved by the FDA in breast cancer patients in 2005 [7, 53–57].

In PDAC, Von Hoff et al. [53, 54] demonstrated in a phase II trial that patients with SPARC (secreted protein acidic and rich in cysteine) positive tumours revealed a highly significant benefit in OS when treated with gemcitabine plus nab-paclitaxel. Therefore, it was hypothesised that stromal SPARC as an albumin-binding protein would bind albumin-coated paclitaxel molecules, thereby selectively increasing drug delivery. However, preclinical data with genetically ablated SPARC mice showed comparable nab-paclitaxel concentrations within the endogenous murine pancreatic tumours compared to neoplasms overexpressing SPARC [58]. Controversial data in men and mice exist regarding the potential of nab-paclitaxel to deplete abundant tumour stroma in PDAC [55, 59, 60]. Therefore, it remains questionable whether nab-paclitaxel exerts any tumour-selective/targeted effect beyond its cytotoxicity as a mitotic inhibitor.

Nevertheless, the international multi-centre MPACT-trial revealed significant clinical benefits, achieving disease control rates of 67% in treated patients and a median OS of 8.5 months [53, 54, 61] (table 2).

MPACT trial patients (n = 431) receiving the combination treatment of gemcitabine plus nab-paclitaxel showed a 1-year survival rate of 35 vs. 22% when compared to the gemcitabine monotherapy group (n = 430), and 9% compared to 4% at the second year of follow-up. Moreover, a median progression-free survival of 5.5 months in the combination therapy cohort versus 3.7 months in the gemcitabine monotherapy group had been achieved. Severe neutropenia was significantly more frequent in the combination therapy group of the MPACT trial (gemcitabine + nab-paclitaxel: 38%, gemcitabine: 27%), while febrile neutropenia occurred in 3% of the patients. The same was true for the incidence of fatigue (17 vs. 7%) and neuropathy (17 vs. 1%) that occurred significantly more often in the nab-paclitaxel group than in the gemcitabine monotherapy group [53].

Strikingly, immunohistochemical analysis from MPACT phase III patients failed to confirm that SPARC is a prognostic biomarker [62], confirming the earlier published preclinical data [58].

In a recently published phase-III-trial (n = 861 patients) by Goldstein et al. [63], analysing the long-term-survival of patients receiving the nab-paclitaxel plus gemcitabine combination-treatment, the superior OS and PFS could be confirmed. Moreover, subgroup analysis emphasised the relevance of CA 19–9 and neutrophil to lymphocyte ratio as reasonable prognostic markers. High CA 19–9 levels and neutrophil to lymphocyte ratio before treatment was associated with a worse OS. Survivors of more than 3 years were exclusively identified in the nab-paclitaxel plus gemcitabine arm (4%) [63]. By performing post-hoc analyses of the MPACT collective, Tabernero et al. [64] described PS score, liver metastases, age and number of metastatic sites as consistent and valid predictors of survival that are easily available clinical markers that help in decision making regarding treatment.

Notably, a retrospective analysis showed that the eligibility criteria itself for both the PRODIGE and MPACT trial, were associated with an improved survival [65]. The authors demonstrated that patients who simply fulfilled the inclusion criteria for either FOLFIRINOX or nab-paclitaxel/gemcitabine, without actually receiving the treat-

Ipsen Ex. 2016, Page 6 of 10

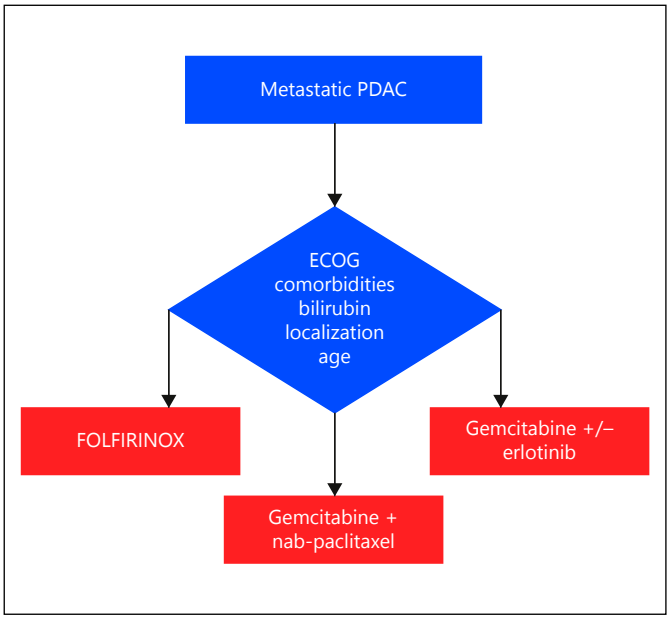

Color version available online

Fig. 1. Decision-making algorithm in patients with metastatic PDAC.

ments, had a better median OS compared to patients who failed to meet them. When comparing the FOLFIRINOX-eligible population with the nab-paclitaxel-eligible group, it becomes apparent that ECOG 2 patients were excluded in the FOLFIRINOX trial. These results were consistent with the fact that eligibility was no longer a significant prognostic factor after accounting for patient's ECOG performance. Strictly following the trials inclusion criteria, the authors demonstrated that the majority of patients with metastatic PDAC were not eligible for either of the intensified polychemotherapeutic regimens. Comparing only eligibility for treatment for nab-paclitaxel plus gemcitabine versus the FOLFIRINOX protocol, nearly twice as many patients could have been candidates for nab-paclitaxel due to less restrictive ECOG performance criteria for this regimen in trials [65].

Furthermore, novel drug formulations that improve the pharmacokinetic properties of hydrophobic paclitaxel have been investigated. For instance, Löhr et al. [66] have shown in a phase II trial that paclitaxel embedded in cationic liposomes, the so-called EndoTAG-1, was generally well tolerated and achieved a median OS of 8.1–9.3 months when combined with gemcitabine.

Ongoing clinical trials are investigating nab-paclitaxel as the backbone for novel targeted therapies. Examples are ruxolitinib, a janus-kinase inhibitor in combination with gemcitabine or nab-paclitaxel plus gemcitabine (NCT01822756), INCB039110 a JAK1 inhibitor in combination with nab-paclitaxel plus gemcitabine (NCT01858883), or the indoleamine-2,3-dioxygenase inhibitor Indoximod in combination with nab-paclitaxel plus gemcitabine in advanced PDAC (NCT02077881). Those results might help to optimise the selection of adequate patient cohorts eligible for nab-paclitaxel, and moreover provide additional insights into novel targeted treatment avenues (table 1).

Conclusion

It is evident from the existing data that there is a significant survival benefit of intensive chemotherapy treatment regimens FOLFIRINOX and gemcitabine + nab-paclitaxel for metastatic PDAC. Although OS rates may be overestimated due to very stringent enrolment criteria for these trials, national and international guidelines recommend them as first-line therapy for metastatic PDAC. However, careful patient selection based on clinical and laboratory findings represents a major challenge for physicians and oncologists in the palliative situation (fig. 1). Currently, no biomarker can reliably predict the response to treatment to nab-paclitaxel + gemcitabine or FOLFIRINOX. Therefore, a careful clinical and biochemical follow-up is required to optimise the treatment effects while minimising the side effects. Often, dose reductions are a feasible approach to cope with the enhanced toxicity profile of these protocols. For the future, intensified chemotherapies such as nab-paclitaxel and FOLFIRINOX may also be extended to selected patients with LAPC in a neoadjuvant setting, as well as for adjuvant treatment strategies. Furthermore, intensified chemotherapy protocols are currently investigated as backbone for novel investigational PDAC therapies, such as anti-stromal approaches or immune cell checkpoint antagonists.

Acknowledgements

This review was conceptualised and written within the Pancreas 2000 educational and research leadership program (course No. 7). The Pancreas 2000 program is supported by the European Pancreas Club, United European Gastroenterologists and Celgene.

Disclosure Statement

The authors declare no conflict of interest.

Ipsen Ex. 2016, Page 7 of 10

References

1 Siegel RL, Miller KD, Jemal A: Cancer statistics, 2015. CA Cancer J Clin 2015;65:5–29.
2 Ryan DP, Hong TS, Bardeesy N: Pancreatic adenocarcinoma. N Engl J Med 2014;371: 2140–2141.
3 Löhr M, Klöppel G, Maisonneuve P, Lowenfels AB, Lüttges J: Frequency of K-ras mutations in pancreatic intraductal neoplasias associated with pancreatic ductal adenocarcinoma and chronic pancreatitis: a meta-analysis. Neoplasia 2005;7:17–23.
4 Almoguera C, Shibata D, Forrester K, Martin J, Arnheim N, Perucho M: Most human carcinomas of the exocrine pancreas contain mutant c-K-ras genes. Cell 1988;53:549–554.
5 Hezel AF, Kimmelman AC, Stanger BZ, Bardeesy N, Depinho RA: Genetics and biology of pancreatic ductal adenocarcinoma. Genes Dev 2006;20:1218–1249.
6 Feig C, Gopinathan A, Neesse A, Chan DS, Cook N, Tuveson DA: The pancreas cancer microenvironment. Clin Cancer Res 2012;18: 4266–4276.
7 Neesse A, Michl P, Frese KK, Feig C, Cook N, Jacobetz MA, Lolkema MP, Buchholz M, Olive KP, Gress TM, Tuveson DA: Stromal biology and therapy in pancreatic cancer. Gut 2011;60:861–868.
8 Neesse A, Algül H, Tuveson DA, Gress TM: Stromal biology and therapy in pancreatic cancer: a changing paradigm. Gut 2015;64: 1476–1484.
9 Modolell I, Guarner L, Malagelada JR: Vagaries of clinical presentation of pancreatic and biliary tract cancer. Ann Oncol 1999;10(suppl 4):82–84.
10 Porta M, Fabregat X, Malats N, Guarner L, Carrato A, de Miguel A, Ruiz L, Jariod M, Costafreda S, Coll S, Alguacil J, Corominas JM, Solà R, Salas A, Real FX: Exocrine pancreatic cancer: symptoms at presentation and their relation to tumour site and stage. Clin Transl Oncol 2005;7:189–197.
11 Seufferlein T, Porzner M, Becker T, Budach V, Ceyhan G, Esposito I, Fietkau R, Follmann M, Friess H, Galle P, Geissler M, Glanemann M, Gress T, Heinemann V, Hohenberger W, Hopt U, Izbicki J, Klar E, Kleeff J, Kopp I, Kullmann F, Langer T, Langrehr J, Lerch M, Löhr M, Lüttges J, Lutz M, Mayerle J, Michl P, Möller P, Molls M, Münter M, Nothacker M, Oettle H, Post S, Reinacher-Schick A, Röcken C, Roeb E, Saeger H, Schmid R, Schmiegel W, Schoenberg M, Siveke J, Stuschke M, Tannapfel A, Uhl W, Unverzagt S, van Oorschot B, Vashist Y, Werner J, Yekebas E; Guidelines Programme Oncology AWMF; German Cancer Society eV; German Cancer Aid: [S3-guideline exocrine pancreatic cancer]. Z Gastroenterol 2013;51:1395–1440.
12 Rothenberg ML, Moore MJ, Cripps MC, Andersen JS, Portenoy RK, Burris HA 3rd, Green MR, Tarassoff PG, Brown TD, Casper ES, Storniolo AM, Von Hoff DD: A phase II trial of gemcitabine in patients with 5-FU-refractory pancreas cancer. Ann Oncol 1996;7:347–353.
13 Burris HA 3rd, Moore MJ, Andersen J, Green MR, Rothenberg ML, Modiano MR, Cripps MC, Portenoy RK, Storniolo AM, Tarassoff P, Nelson R, Dorr FA, Stephens CD, Von Hoff DD: Improvements in survival and clinical benefit with gemcitabine as first-line therapy for patients with advanced pancreas cancer: a randomized trial. J Clin Oncol 1997;15:2403–2413.
14 Löhr M: Is it possible to survive pancreatic cancer? Nat Clin Pract Gastroenterol Hepatol 2006;3:236–237.
15 Löhr JM: Medical treatment of pancreatic cancer. Expert Rev Anticancer Ther 2007;7: 533–544.
16 Ducreux M, Rougier P, Pignon JP, Douillard JY, Seitz JF, Bugat R, Bosset JF, Merouche Y, Raoul JL, Ychou M, Adenis A, Berthault-Cvitkovic F, Luboinski M; Groupe Digestif of the Fédération Nationale des Centres de Lutte Contre le Cancer Digestif: A randomised trial comparing 5-FU with 5-FU plus cisplatin in advanced pancreatic carcinoma. Ann Oncol 2002;13:1185–1191.
17 Moertel CG, Frytak S, Hahn RG, O'Connell MJ, Reitemeier RJ, Rubin J, Schutt AJ, Weiland LH, Childs DS, Holbrook MA, Lavin PT, Livstone E, Spiro H, Knowlton A, Kalser M, Barkin J, Lessner H, Mann-Kaplan R, Ramming K, Douglas HO Jr, Thomas P, Nave H, Bateman J, Lokich J, Brooks J, Chaffey J, Corson JM, Zamcheck N, Novak JW: Therapy of locally unresectable pancreatic carcinoma: a randomized comparison of high dose (6000 rads) radiation alone, moderate dose radiation (4000 rads + 5-fluorouracil), and high dose radiation + 5-fluorouracil: the gastrointestinal tumor study group. Cancer 1981;48: 1705–1710.
18 Moertel CG, Douglas HO Jr, Hanley J, Carbone PP: Treatment of advanced adenocarcinoma of the pancreas with combinations of streptozotocin plus 5-fluorouracil and streptozotocin plus cyclophosphamide. Cancer 1977;40:605–608.
19 Sultana A, Tudur Smith C, Cunningham D, Starling N, Tait D, Neoptolemos JP, Ghaneh P: Systematic review, including meta-analyses, on the management of locally advanced pancreatic cancer using radiation/combined modality therapy. Br J Cancer 2007;96:1183–1190.
20 Sultana A, Smith CT, Cunningham D, Starling N, Neoptolemos JP, Ghaneh P: Meta-analyses of chemotherapy for locally advanced and metastatic pancreatic cancer. J Clin Oncol 2007;25:2607–2615.
21 Yip D, Karapetis C, Strickland A, Steer CB, Goldstein D: Chemotherapy and radiotherapy for inoperable advanced pancreatic cancer. Cochrane Database Syst Rev 2006;3: CD002093.
22 Ducreux M, Mitry E, Ould-Kaci M, Boige V, Seitz JF, Bugat R, Breau JL, Bouché O, Etienne PL, Tigaud JM, Morvan F, Cvitkovic E, Rougier P: Randomized phase II study evaluating oxaliplatin alone, oxaliplatin combined with infusional 5-FU, and infusional 5-FU alone in advanced pancreatic carcinoma patients. Ann Oncol 2004;15:467–473.
23 Rothenberg ML: New developments in chemotherapy for patients with advanced pancreatic cancer. Oncology (Williston Park) 1996;10(9 suppl):18–22.
24 Berlin JD, Catalano P, Thomas JP, Kugler JW, Haller DG, Benson AB 3rd: Phase III study of gemcitabine in combination with fluorouracil versus gemcitabine alone in patients with advanced pancreatic carcinoma: eastern cooperative oncology group trial E2297. J Clin Oncol 2002;20:3270–3275.
25 Di Costanzo F, Carlini P, Doni L, Massidda B, Mattioli R, Iop A, Barletta E, Moscetti L, Recchia F, Tralongo P, Gasperoni S: Gemcitabine with or without continuous infusion 5-FU in advanced pancreatic cancer: a randomised phase II trial of the Italian oncology group for clinical research (GOIRC). Br J Cancer 2005; 93:185–189.
26 Courtin A, Richards FM, Bapiro TE, Bramhall JL, Neesse A, Cook N, Krippendorff BF, Tuveson DA, Jodrell DI: Anti-tumour efficacy of capecitabine in a genetically engineered mouse model of pancreatic cancer. PLoS One 2013;8:e67330.
27 Cunningham D, Chau I, Stocken DD, Valle JW, Smith D, Steward W, Harper PG, Dunn J, Tudur-Smith C, West J, Falk S, Crellin A, Adab F, Thompson J, Leonard P, Ostrowski J, Eatock M, Scheithauer W, Herrmann R, Neoptolemos JP: Phase III randomized comparison of gemcitabine versus gemcitabine plus capecitabine in patients with advanced pancreatic cancer. J Clin Oncol 2009;27:5513–5518.
28 Heinemann V, Boeck S, Hinke A, Labianca R, Louvet C: Meta-analysis of randomized trials: evaluation of benefit from gemcitabine-based combination chemotherapy applied in advanced pancreatic cancer. BMC Cancer 2008; 8:82.
29 Hubner RA, Worsnop F, Cunningham D, Chau I: Gemcitabine plus capecitabine in unselected patients with advanced pancreatic cancer. Pancreas 2013;42:511–515.
30 Bernhard J, Dietrich D, Scheithauer W, Gerber D, Bodoky G, Ruhstaller T, Glimelius B, Bajetta E, Schüller J, Saletti P, Bauer J, Figer A, Pestalozzi BC, Köhne CH, Mingrone W, Stemmer SM, Tàmas K, Kornek GV, Koeberle D, Herrmann R; Central European Cooperative Oncology Group: Clinical benefit and quality of life in patients with advanced pancreatic cancer receiving gemcitabine plus capecitabine versus gemcitabine alone: a randomized multicenter phase III clinical trial – SAKK 44/00-CECOG/PAN.1.3.001. J Clin Oncol 2008;26:3695–3701.

Ipsen Ex. 2016, Page 8 of 10

31 Hu J, Zhao G, Wang HX, Tang L, Xu YC, Ma Y, Zhang FC: A meta-analysis of gemcitabine containing chemotherapy for locally advanced and metastatic pancreatic adenocarcinoma. J Hematol Oncol 2011;4:11.
32 Louvet C, Labianca R, Hammel P, Lledo G, Zampino MG, André T, Zaniboni A, Ducreux M, Aitini E, Taïeb J, Faroux R, Lepere C, de Gramont A; GERCOR; GISCAD: Gemcitabine in combination with oxaliplatin compared with gemcitabine alone in locally advanced or metastatic pancreatic cancer: results of a GERCOR and GISCAD phase III trial. J Clin Oncol 2005;23:3509–3516.
33 Poplin E, Feng Y, Berlin J, Rothenberg ML, Hochster H, Mitchell E, Alberts S, O'Dwyer P, Haller D, Catalano P, Cella D, Benson AB 3rd: Phase III, randomized study of gemcitabine and oxaliplatin versus gemcitabine (fixed-dose rate infusion) compared with gemcitabine (30-minute infusion) in patients with pancreatic carcinoma E6201: a trial of the eastern cooperative oncology group. J Clin Oncol 2009;27:3778–3785.
34 Heinemann V, Quietzsch D, Gieseler F, Gonnermann M, Schönekäs H, Rost A, Neuhaus H, Haag C, Clemens M, Heinrich B, Vehling-Kaiser U, Fuchs M, Fleckenstein D, Gesierich W, Uthgenannt D, Einsele H, Holstege A, Hinke A, Schalhorn A, Wilkowski R: Randomized phase III trial of gemcitabine plus cisplatin compared with gemcitabine alone in advanced pancreatic cancer. J Clin Oncol 2006;24:3946–3952.
35 Colucci G, Giuliani F, Gebbia V, Biglietto M, Rabitti P, Uomo G, Cigolari S, Testa A, Maiello E, Lopez M: Gemcitabine alone or with cisplatin for the treatment of patients with locally advanced and/or metastatic pancreatic carcinoma: a prospective, randomized phase III study of the gruppo oncologia dell'italia meridionale. Cancer 2002;94:902–910.
36 Kulke MH, Tempero MA, Niedzwiecki D, Hollis DR, Kindler HL, Cusnir M, Enzinger PC, Gorsch SM, Goldberg RM, Mayer RJ: Randomized phase II study of gemcitabine administered at a fixed dose rate or in combination with cisplatin, docetaxel, or irinotecan in patients with metastatic pancreatic cancer: CALGB 89904. J Clin Oncol 2009;27:5506–5512.
37 Abou-Alfa GK, Letourneau R, Harker G, Modiano M, Hurwitz H, Tchekmedyian NS, Feit K, Ackerman J, De Jager RL, Eckhardt SG, O'Reilly EM: Randomized phase III study of exatecan and gemcitabine compared with gemcitabine alone in untreated advanced pancreatic cancer. J Clin Oncol 2006;24:4441–4447.
38 Stathopoulos GP, Syrigos K, Aravantinos G, Polyzos A, Papakotoulas P, Fountzilas G, Potamianou A, Ziras N, Boukovinas J, Varthalitis J, Androulakis N, Kotsakis A, Samonis G, Georgoulias V: A multicenter phase III trial comparing irinotecan-gemcitabine (IG) with gemcitabine (G) monotherapy as first-line treatment in patients with locally advanced or metastatic pancreatic cancer. Br J Cancer 2006;95:587–592.
39 Rocha Lima CM, Green MR, Rotche R, Miller WHJr, Jeffrey GM, Cisar LA, Morganti A, Orlando N, Gruia G, Miller LL: Irinotecan plus gemcitabine results in no survival advantage compared with gemcitabine monotherapy in patients with locally advanced or metastatic pancreatic cancer despite increased tumor response rate. J Clin Oncol 2004;22:3776–3783.
40 Moore MJ, Goldstein D, Hamm J, Figer A, Hecht JR, Gallinger S, Au HJ, Murawa P, Walde D, Wolff RA, Campos D, Lim R, Ding K, Clark G, Voskoglou-Nomikos T, Ptasynski M, Parulekar W; National Cancer Institute of Canada Clinical Trials Group: Erlotinib plus gemcitabine compared with gemcitabine alone in patients with advanced pancreatic cancer: a phase III trial of the national cancer institute of canada clinical trials group. J Clin Oncol 2007;25:1960–1966.
41 Péron J, Roy P, Ding K, Parulekar WR, Roche L, Buyse M: Assessing the benefit-risk of new treatments using generalised pairwise comparisons: the case of erlotinib in pancreatic cancer. Br J Cancer 2015;112:971–976.
42 Vaccaro V, Bria E, Sperduti I, Gelibter A, Moscetti L, Mansueto G, Ruggeri EM, Gamucci T, Cognetti F, Milella M: First-line erlotinib and fixed dose-rate gemcitabine for advanced pancreatic cancer. World J Gastroenterol 2013;19:4511–4519.
43 Reni M, Cordio S, Milandri C, Passoni P, Bonetto E, Oliani C, Luppi G, Nicoletti R, Galli L, Bordonaro R, Passardi A, Zerbi A, Balzano G, Aldrighetti L, Staudacher C, Villa E, Di Carlo V: Gemcitabine versus cisplatin, epirubicin, fluorouracil, and gemcitabine in advanced pancreatic cancer: a randomised controlled multicentre phase III trial. Lancet Oncol 2005;6:369–376.
44 Reni M, Cereda S, Rognone A, Belli C, Ghidini M, Longoni S, Fugazza C, Rezzonico S, Passoni P, Slim N, Balzano G, Nicoletti R, Cappio S, Doglioni C, Villa E: A randomized phase II trial of two different 4-drug combinations in advanced pancreatic adenocarcinoma: cisplatin, capecitabine, gemcitabine plus either epirubicin or docetaxel (PEXG or PDXG regimen). Cancer Chemother Pharmacol 2012;69:115–123.
45 Goel A, Grossbard ML, Malamud S, Homel P, Dietrich M, Rodriguez T, Mirzoyev T, Kozuch P: Pooled efficacy analysis from a phase I-II study of biweekly irinotecan in combination with gemcitabine, 5-fluorouracil, leucovorin and cisplatin in patients with metastatic pancreatic cancer. Anticancer Drugs 2007;18:263–271.
46 Ghosn M, Farhat F, Kattan J, Younes F, Moukadem W, Nasr F, Chahine G: FOLFOX-6 combination as the first-line treatment of locally advanced and/or metastatic pancreatic cancer. Am J Clin Oncol 2007;30:15–20.
47 Taïeb J, Lecomte T, Aparicio T, Asnacios A, Mansourbakht T, Artru P, Fallik D, Spano JP, Landi B, Lledo G, Desrame J: FOLFIRI.3, a new regimen combining 5-fluorouracil, folinic acid and irinotecan, for advanced pancreatic cancer: results of an association des gastro-enterologues oncologues (gastroenterologist oncologist association) multicenter phase II study. Ann Oncol 2007;18:498–503.
48 Conroy T, Paillot B, François E, Bugat R, Jacob JH, Stein U, Nasca S, Metges JP, Rixe O, Michel P, Magherini E, Hua A, Deplanque G: Irinotecan plus oxaliplatin and leucovorin-modulated fluorouracil in advanced pancreatic cancer – a groupe tumeurs digestives of the federation nationale des centres de lutte contre le cancer study. J Clin Oncol 2005;23:1228–1236.
49 Ychou M, Conroy T, Seitz JF, Gourgou S, Hua A, Mery-Mignard D, Kramar A: An open phase I study assessing the feasibility of the triple combination: oxaliplatin plus irinotecan plus leucovorin/ 5-fluorouracil every 2 weeks in patients with advanced solid tumors. Ann Oncol 2003;14:481–489.
50 Conroy T, Desseigne F, Ychou M, Bouché O, Guimbaud R, Bécouarn Y, Adenis A, Raoul JL, Gourgou-Bourgade S, de la Fouchardière C, Bennouna J, Bachet JB, Khemissa-Akouz F, Péré-Vergé D, Delbaldo C, Assenat E, Chauffert B, Michel P, Montoto-Grillot C, Ducreux M; Groupe Tumeurs Digestives of Unicancer; PRODIGE Intergroup: FOLFIRINOX versus gemcitabine for metastatic pancreatic cancer. N Engl J Med 2011;364:1817–1825.
51 Ueno H, Okusaka T, Funakoshi A, Ishii H, Yamao K, Ishikawa O, Ohkawa S, Saitoh S: A phase II study of weekly irinotecan as first-line therapy for patients with metastatic pancreatic cancer. Cancer Chemother Pharmacol 2007;59:447–454.
52 Gourgou-Bourgade S, Bascoul-Mollevi C, Desseigne F, Ychou M, Bouché O, Guimbaud R, Bécouarn Y, Adenis A, Raoul JL, Boige V, Bérille J, Conroy T: Impact of FOLFIRINOX compared with gemcitabine on quality of life in patients with metastatic pancreatic cancer: results from the PRODIGE 4/ACCORD 11 randomized trial. J Clin Oncol 2013;31:23–29.
53 Von Hoff DD, Ervin T, Arena FP, Chiorean EG, Infante J, Moore M, Seay T, Tjulandin SA, Ma WW, Saleh MN, Harris M, Reni M, Dowden S, Laheru D, Bahary N, Ramanathan RK, Tabernero J, Hidalgo M, Goldstein D, Van Cutsem E, Wei X, Iglesias J, Renschler MF: Increased survival in pancreatic cancer with nab-paclitaxel plus gemcitabine. N Engl J Med 2013;369:1691–1703.
54 Von Hoff DD, Ramanathan RK, Borad MJ, Laheru DA, Smith LS, Wood TE, Korn RL, Desai N, Trieu V, Iglesias JL, Zhang H, Soon-Shiong P, Shi T, Rajeshkumar NV, Maitra A, Hidalgo M: Gemcitabine plus nab-paclitaxel is an active regimen in patients with advanced pancreatic cancer: a phase I/II trial. J Clin Oncol 2011;29:4548–4554.

Ipsen Ex. 2016, Page 9 of 10

55 Frese KK, Neesse A, Cook N, Bapiro TE, Lolkema MP, Jodrell DI, Tuveson DA: Nab-paclitaxel potentiates gemcitabine activity by reducing cytidine deaminase levels in a mouse model of pancreatic cancer. Cancer Discov 2012;2:260–269.
56 Infante JR, Jones SF, Bendell JC, Spigel DR, Yardley DA, Weekes CD, Messersmith WA, Hainsworth JD, Burris HA 3rd: A phase I, dose-escalation study of pomalidomide (CC-4047) in combination with gemcitabine in metastatic pancreas cancer. Eur J Cancer 2011;47:199–205.
57 Gradishar WJ, Tjulandin S, Davidson N, Shaw H, Desai N, Bhar P, Hawkins M, O'Shaughnessy J: Phase III trial of nanoparticle albumin-bound paclitaxel compared with polyethylated castor oil-based paclitaxel in women with breast cancer. J Clin Oncol 2005;23:7794–7803.
58 Neesse A, Frese KK, Chan DS, Bapiro TE, Howat WJ, Richards FM, Ellenrieder V, Jodrell DI, Tuveson DA: SPARC independent drug delivery and antitumour effects of nab-paclitaxel in genetically engineered mice. Gut 2014;63:974–983.
59 Alvarez R, Musteanu M, Garcia-Garcia E, Lopez-Casas PP, Megias D, Guerra C, Muñoz M, Quijano Y, Cubillo A, Rodriguez-Pascual J, Plaza C, de Vicente E, Prados S, Tabernero S, Barbacid M, Lopez-Rios F, Hidalgo M: Stromal disrupting effects of nab-paclitaxel in pancreatic cancer. Br J Cancer 2013;109:926–933.
60 Neesse A, Michl P, Tuveson DA, Ellenrieder V: Nab-paclitaxel: novel clinical and experimental evidence in pancreatic cancer. Z Gastroenterol 2014;52:360–366.
61 Von Hoff DD, Ramanathan R, Borad M, Laheru D, Smith L, Wood T, Korn R, Desai N, Iglesias J, Hidalgo M: SPARC correlation with response to gemcitabine (G) plus nab-paclitaxel (nab-P) in patients with advanced metastatic pancreatic cancer: a phase I/II study. J Clin Oncol 2009;27:4525.
62 Hidalgo M, Plaza C, Illei P, et al: SPARC Analysis in the Phase III MPACT Trial of Nab-Paclitaxel (nab-p) Plus Gemcitabine (gem) vs Gem Alone for Patients with Metastatic Pancreatic Cancer. Barcelona, 16th World Congress on Gastrointestinal Cancer, 2014.
63 Goldstein D, El-Maraghi RH, Hammel P, Heinemann V, Kunzmann V, Sastre J, Scheithauer W, Siena S, Tabernero J, Teixeira L, Tortora G, Van Laethem JL, Young R, Penenberg DN, Lu B, Romano A, Von Hoff DD: Nab-paclitaxel plus gemcitabine for metastatic pancreatic cancer: long-term survival from a phase III trial. J Natl Cancer Inst 2015; 107:pii.
64 Tabernero J, Chiorean EG, Infante JR, Hingorani SR, Ganju V, Weekes C, Scheithauer W, Ramanathan RK, Goldstein D, Penenberg DN, Romano A, Ferrara S, Von Hoff DD: Prognostic factors of survival in a randomized phase III trial (MPACT) of weekly nab-paclitaxel plus gemcitabine versus gemcitabine alone in patients with metastatic pancreatic cancer. Oncologist 2015;20:143–150.
65 Peixoto RD, Ho M, Renouf DJ, Lim HJ, Gill S, Ruan JY, Cheung WY: Eligibility of metastatic pancreatic cancer patients for first-line palliative intent nab-paclitaxel plus gemcitabine versus FOLFIRINOX. Am J Clin Oncol 2015, Epub ahead of print.
66 Löhr JM, Haas SL, Bechstein WO, Bodoky G, Cwiertka K, Fischbach W, Fölsch UR, Jäger D, Osinsky D, Prausova J, Schmidt WE, Lutz MP; CT4001 Study Group: Cationic liposomal paclitaxel plus gemcitabine or gemcitabine alone in patients with advanced pancreatic cancer: a randomized controlled phase II trial. Ann Oncol 2012;23:1214–1222.