APMIS ACTA PATHOLOGICA, MICROBIOLOGICA ET IMMUNOLOGICA SCANDINAVICA

APMIS 122: 482–489
© 2013 APMIS. Published by John Wiley & Sons Ltd.
DOI 10.1111/apm.12195

Prostate-specific membrane antigen expression in tumor-associated vasculature of breast cancers

ALLA GABRIELLA WERNICKE,[1] SONAL VARMA,[2] ELENI A. GREENWOOD,[1] PAUL J. CHRISTOS,[3] K. S. CLIFFORD CHAO,[1] HE LIU,[4] NEIL H. BANDER[4] and SANDRA J. SHIN[2]

[1]Department of Radiation Oncology, Stich Radiation Center, Weill Cornell Medical College, New York, NY; [2]Department of Pathology and Laboratory Medicine, Weill Cornell Medical College, New York, NY; [3]Division of Biostatistics and Epidemiology, Department of Public Health, Weill Cornell Medical College, New York, NY; and [4]Department of Urology, Weill Cornell Medical College, New York, NY, USA

Wernicke AG, Varma S, Greenwood EA, Christos PJ, Chao KSC, Liu HE, Bander NH, Shin SJ. Prostate-specific membrane antigen expression in tumor-associated vasculature of breast cancers. APMIS 2014; 122: 482–489.

Prostate-specific membrane antigen (PSMA) has been found to be expressed in the tumor-associated neovasculature of multiple solid tumor types including breast cancers. However, thus far, the number of cases studied from some tumor types has been limited. In this study, we set out to assess PSMA expression in the tumor-associated vasculature associated with invasive breast carcinomas in a sizable cohort of patients. One hundred and six patients with AJCC stage 0-IV breast cancer were identified. Ninety-two of these patients had primary breast cancer [invasive breast carcinoma with or without co-existing ductal carcinoma *in situ* (DCIS) (74) or DCIS alone (18)]. In addition, 14 patients with breast cancer metastases to the brain were identified. Immunohistochemical staining for PSMA and CD31 was performed on parallel representative tumor sections in each case. Tumor-associated vascular endothelial cell PSMA immunoreactivity was semi-quantitatively assessed based on two parameters: overall percent of endothelial positivity and staining intensity. PSMA expression for tumor-associated vascular endothelial cells was scored 0 if there was no detectable PSMA expression, 1 if PSMA staining was detectable in 5–50%, and 2 if PSMA expression was positive in >50% of microvessels. CD 31 staining was concurrently reviewed to confirm the presence of vasculature in each case. Tumor-associated vasculature was PSMA-positive in 68/92 (74%) of primary breast cancers and in 14/14 (100%) of breast cancers metastatic to brain. PSMA was not detected in normal breast tissue or carcinoma cells. All but 2 cases (98%) showed absence of PSMA expression in normal breast tissue-associated vasculature. The 10-year overall survival was 88.7% (95% CI = 80.0%, 93.8%) in patients without brain metastases. When overall survival (OS) was stratified based on PSMA score group, patients with PSMA scores of 0, 1, and 2 had 10-year OS of 95.8%, 96.0%, and 79.7%, respectively ($p = 0.12$). When PSMA scores of 0 and 1 were compared with 2, there was a statistically significant difference in OS (96.0% vs 79.7%, respectively, $p = 0.05$). Patients with a PSMA score of 2 had a significantly higher median tumor size compared with patients in the lower PSMA score groups ($p = 0.04$). Patients with higher nuclear grade were more likely to have a PSMA score of 2 compared with patients with lower nuclear grade ($p < 0.0001$). Patients with a PSMA score of 2 had a significantly higher median Ki-67 proliferation index compared with patients in the lower PSMA score groups ($p < 0.0001$). Patients with estrogen receptor (ER)-negative tumors were more likely to have a PSMA score of 2 compared with patients with ER-positive tumors ($p < 0.0001$). Patients with progesterone receptor (PR)-negative tumors were more likely to have a PSMA score of 2 compared with patients with PR-positive tumors ($p = 0.03$). No significant association was observed between PSMA score group status and lymph node involvement ($p = 0.95$). Too little variability was present in Human epidermal growth factor receptor-2 (Her2/neu) amplified tumors to correlate with PSMA score group status. To date, this is the first detailed assessment of PSMA expression in the tumor-associated vasculature of primary and metastatic breast carcinomas. Further studies are needed to evaluate whether PSMA has diagnostic and/or potential therapeutic value.

Key words: Prostate-specific membrane antigen; breast cancer; anti-angiogenesis.

Alla Gabriella Wernicke, Weill-Cornell Medical College, Stich Radiation Oncology 525 East 68th Street New York, NY 10065 USA. e-mails: gaw9008@med.cornell.edu, mey2004@med.cornell.edu

Received 8 February 2013. Accepted 30 July 2013

Curium US LLC, Exhibit 1029
IPR2025-01582

Selective inhibitory targeting of angiogenesis either by interfering with angiogenic growth factors or by directly targeting tumor-associated blood vessels is an important strategy in the treatment of cancers (1). Exploiting this mechanism implies that endothelial cells comprising the (neo)vasculature of tumors demonstrate altered protein expression patterns relative to those of normal endothelium (1–3). As such, proteins selectively expressed in tumor-associated endothelial cells represent candidate targets for tumor-specific anti-angiogenic cancer therapy.

Prostate-specific membrane antigen (PSMA, folate hydrolase 1, glutamate carboxypetidase II), a zinc-dependent exopeptidase, is predominantly expressed in the prostate gland (4) where low levels are present in the normal prostatic secretory epithelium and significantly higher levels have been detected in prostatic adenocarcinomas (5). In recent years, several approaches targeting PSMA have been developed for diagnostic and therapeutic purposes (6–12). In the setting of metastatic prostate cancer, two clinical trials using a radiolabeled monoclonal antibody against PSMA have supported the potential of targeting PSMA (10, 11).

The extracellular domain of PSMA not only serves as a promising therapeutic target (13) in prostate cancer, but additionally, PSMA has been found to be selectively expressed in the vasculature of other solid tumors, but not in normal tissue vasculature (12, 14–16). These findings suggest that PSMA may have broader potential as a tumor-associated (neo-) vascular target in addition to one that is tumor-specific (prostate). Successful targeting of metastatic tumor sites in two clinical trials in patients with various solid tumor malignancies was accomplished using a humanized anti-PSMA antibody (J591), thus, demonstrating proof-of-principle that PSMA allows targeting of the neovasculature in solid tumors in addition to prostatic adenocarcinoma (17, 18).

To date, with the exception of GI (16) and oral cavity cancers, PSMA expression in the neovasculature of solid tumors has been limited in both the range of tumor types studied as well as small cohort sizes (12–16). Microvessel density is a well-characterized surrogate marker for angiogenesis/neovascularization in tumors; and has been shown to negatively correlate with prognosis in many studies (19, 20). We set out to assess PSMA expression in the tumoral microvessels in a large cohort of patients with primary and metastatic breast carcinomas to evaluate the diagnostic and/or therapeutic potential of PSMA in these patients.

MATERIALS AND METHODS

Patients' tumors specimens

After Institutional Review Board approval, 92 patients who had undergone surgical resection of their breast cancers were identified. Representative formalin-fixed paraffin-embedded tumor blocks from these specimens were obtained from the Department of Pathology and Laboratory Medicine of Weill Cornell Medical Center/New York Presbyterian Hospital. In addition, formalin-fixed paraffin-embedded tissue from brain metastases of 14 patients with breast cancer were obtained. Clinical and pathologic characteristics of all patients are summarized in Table 1. Primary breast tumor grade was assigned by applying the 'Elston-Ellis modified Scarff-Bloom-Richardson grading system' used in routine clinical practice as recommended by the College of American Pathologists (CAP) and American Joint Committee on Cancer (AJCC) (21). The proliferation index using Ki-67 immunostaining was scored as <10%, 10–14%, and >14% based on the percentage of tumor cells showing nuclear reactivity for Ki-67. These cut-off points have been shown to be prognostically significant in large landmark studies and are used in routine clinical practice to categorize the proliferation index (22). The 7th edition of AJCC staging manual was used to assign the pathological tumor stage (23).

Immunohistochemistry

Four-μm-thick tissue sections from representative tumor blocks were mounted on glass slides, deparaffinized by Histo-Clear (National Diagnostics, Atlanta, GA, USA), and rehydrated. Parallel slides from each case were stained with anti-PSMA and anti-CD31 as follows. For CD31, antigen retrieval was accomplished by pressure-cooking the slides for 1 min in 10 mmol/L citrate buffer (pH 6.0); for PSMA, slides were incubated in Target Retrieval Solution (pH 9.0; DAKO, Carpinteria, CA, USA) at 95 °C for 30 min. Endogenous peroxidase activity was blocked with Peroxidase Block (Envision System kit; DAKO) for 5 min. Slides were then incubated for 60 min with either anti-CD31 (clone 1A10; Novocastra/Vision BioSystems, Inc, Norwell, MA, USA) or anti-PSMA antibody (clone 3E6; DAKO) diluted 1:25 and 1:20, respectively, in Antibody Diluent (DAKO). Slides were then further treated with anti-mouse HRP polymer-labeled secondary antibodies for 60 min followed by 8 min in diaminobenzidine (DAB) solution (Envision System HRP; DAKO). Lastly, slides were counterstained with Harries Modified Hematoxylin (Fisher Scientific, Pittsburgh, PA; USA). In all assays, negative control slides were incubated with isotype-matched immunoglobulin. Positive controls consisted of prostatic adenocarcinoma specimens and tonsillar tissue for PSMA and CD31 staining, respectively.

Scoring

CD 31-stained slides were used in each case to confirm the presence of tumor-associated and non-tumor vasculature. Vascular endothelial cell immunoreactivity for PSMA was semi-quantitatively scored for both the intensity of staining and the proportion of tumor vessels that were positive.

© 2013 APMIS. Published by John Wiley & Sons Ltd

Table 1. A summary of patient and tumor characteristics

	Number	Percentage
Total number	106	100
Primary	92	87
Metastases	14	13
Median age, at diagnosis years (range)	57 (32–92)	
Median size of invasive tumor (cm)	1.2 (0.1–7.0)	
T stage (total number)	92	100
pTis	18	20
pT1mic	2	2
pT1a	11	12
pT1b	12	13
pT1c	35	38
pT2	13	14
pT3	1	1
N stage (total number)	92	100
pNx	18	20
pN0	52	57
pNmic	3	3
pN1	14	15
pN2	3	3
pN3	2	2
M stage (total number)	106	100
M0	92	87
M1	14	13
Histology of primary breast cancer	92	100
DCIS	18	20
IDC	64	70
ILC	10	10
Receptor status	106	100
ER+	94	89
ER−	12	11
PR+	81	76
PR−	25	24
Her2neu+	27	25
Her2neu−	79	75
Ki-67 Index (%)	106	100
≤14	65	61
>14	41	39
Lymphovascular invasion	106	100
Present	27	25
Absent	79[1]	75
Nuclear grade	106	100
1	30	29
2	47	44
3	29	27

DCIS, ductal carcinoma *in situ*; IDC, invasive ductal carcinoma; ILC, invasive lobular carcinoma.
[1]Excludes DCIS cases.

Positive PSMA expression was defined as membranous with or without cytoplasmic staining of endothelial cells lining microvessels. The method by which sampling, identification and selection of vessels was performed was similar to that used in other studies (19). After scanning the entire H&E stained tumor section at low power (100×), 'hot-spots' with highest microvessel density were identified. PSMA staining in microvessesls was then evaluated at high magnification (200×) in at least three high power fields. The larger vessels were excluded. Small clusters of

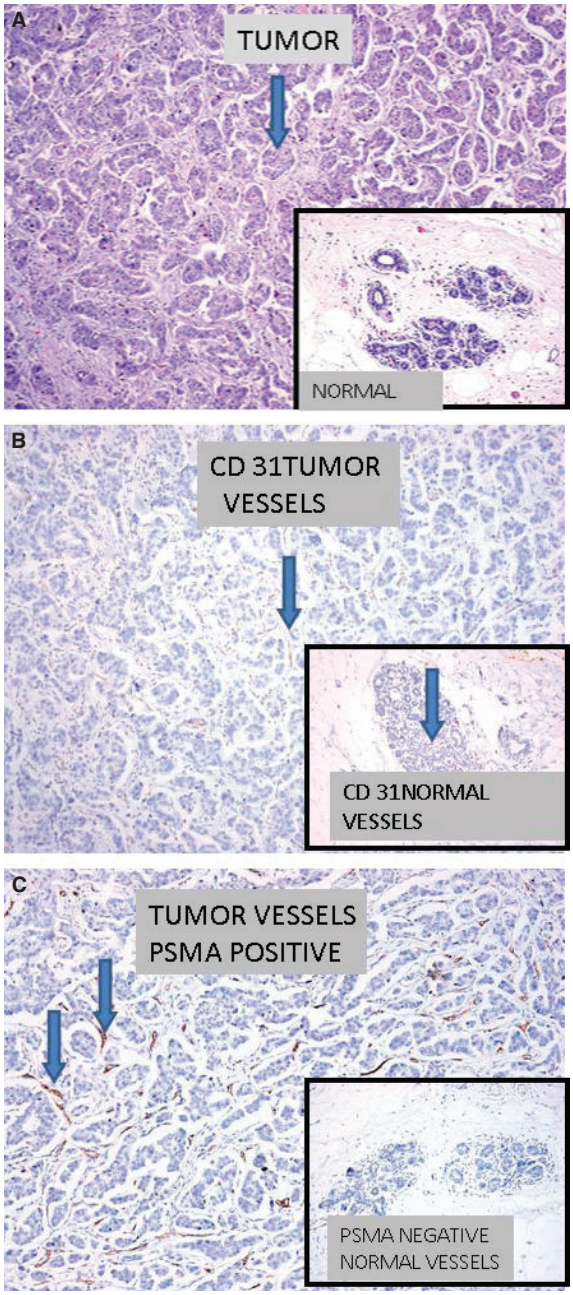

Fig. 1. PSMA expression in tumor-associated endothelium of primary invasive breast carcinoma. (A) H&E staining of the invasive breast cancer in a lumpectomy specimen, with the insert demonstrates normal breast tissue within the resected clear margin (an arrow points toward the vessel within the tumor). (B) CD31 staining demonstrates staining of the vasculature of the tumor and the normal endothelium in the breast tissue (arrows point to the CD31 staining of the vessels in both). (C) PSMA expression is demonstrated in the vasculature of the tumor only with the PSMA staining >50% (score 2) (arrows), but lack PSMA expression (score 0) is observed in normal breast tissue or its endothelial cells.

© 2013 APMIS. Published by John Wiley & Sons Ltd

endothelial cells (even without a discernible lumen) were considered as a single microvessel. In the majority of cases, staining intensity directly correlated with extent of staining in tumor-associated vessels and as such, the score of each case was simplified as follows: tumors with no detectable endothelial PSMA expression were scored as '0'; tumors with PSMA staining in 5–50% of vessels were scored as '1'; and tumors that showed PSMA-positive staining in >50% of tumor-associated vessels were scored as '2'.

Statistical analysis

Statistical considerations – Descriptive statistics (including mean, standard deviation, median, frequency, percent) were calculated to characterize the study cohort. The ANOVA test was used to compare mean age among the three PSMA expression score groups (0, 1, and 2). The Kruskal–Wallis test was used to compare median tumor size and median Ki-67 proliferation index among the three PSMA expression score groups. The chi-square test was used to assess the association between PSMA expression score group and (i) histologic type, (ii) lymphovascular invasion, (iii) lymph node positivity, (iv) nuclear grade, (v) ER status, (vi) progesterone receptor [PR] status, and (vii) Human epidermal growth factor receptor-2 (Her2neu) status. Kaplan–Meier survival analysis was performed to calculate overall survival for the study cohort and the log-rank test was employed to compare overall survival among the three PSMA expression score groups. All p-values are two-sided with statistical significance evaluated at the 0.05 alpha level. Ninety-five percent confidence intervals (95% CI) for 10-year overall survival estimates were calculated to assess the precision of the obtained estimates. All analyses were performed in STATA Version 12.0 (StataCorp, College Station, TX, USA) and SPSS Version 20.0 (SPSS Inc., Chicago, IL, USA).

Table 2. Expression of PSMA in tumor-associated vasculature of breast cancer

	Total number	PSMA score (number per score group)
Primary breast cancer	92	0 = 24
		1 = 26
		2 = 42
Brain metastases from breast cancer	14	0 = 0
		1 = 0
		2 = 14

RESULTS

CD 31 positivity in vasculature was confirmed in all cases and was seen in both the tumor-associated and normal tissue-associated endothelial cells.

Primary breast carcinomas

Prostate-specific membrane antigen positivity was restricted to tumor-associated vasculature in 90 of 92 cases of invasive breast cancers (98%) (Fig. 1). In the remaining two cases, weak staining of a sub-

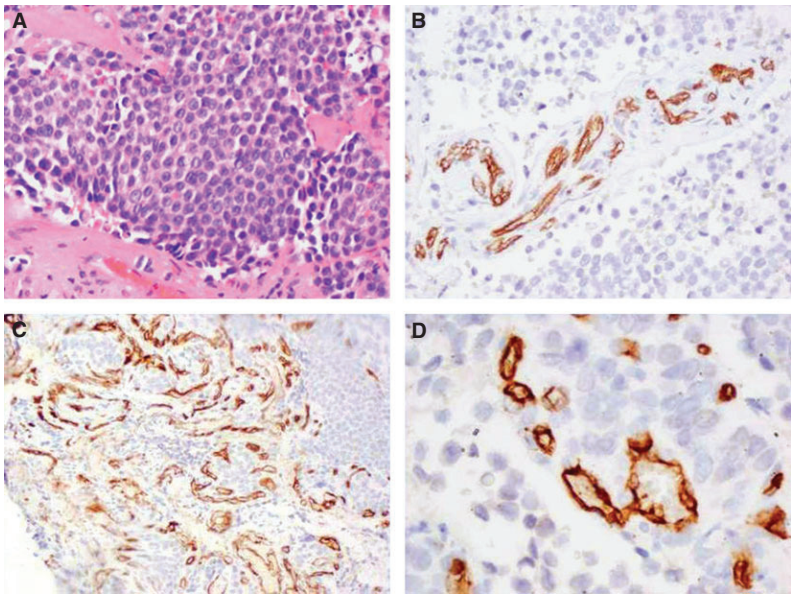

Fig. 2. PSMA expression in tumor-associated endothelium of metastatic breast cancer to the brain. (A) H&E staining of the resected brain metastasis. (B) CD31 staining demonstrates staining of the vasculature of the tumor. (C) PSMA expression in the vasculature of the tumor. (D) High power demonstration of the PSMA expression in the endothelial vessels of the brain metastasis.

© 2013 APMIS. Published by John Wiley & Sons Ltd

set of normal tissue-associated vasculature by PSMA was also seen in addition to tumor-associated vasculature.

Normal glandular breast tissue and carcinoma cells were PSMA-negative in all studied cases. PSMA staining was not identified in any CD31-negative vessels within the tumor. The PSMA expression score ranged from 0 to 2 (Table 2). In 24/92 (26%) cases, no PSMA was detectable (score 0). The remaining 68/92 (74%) of tumors stained positive for PSMA to a varying degree (scores 1 and 2). No statistically significant association was observed between PSMA score group status and histologic type (invasive ductal carcinoma (IDC) vs invasive lobular carcinoma (ILC), p = 0.34). Similarly, patient age (p = 0.30) or presence of lymphovascular invasion (p = 0.31) was not associated with the increasing PSMA score group.

Brain metastases secondary to invasive breast carcinomas

All 14 breast cancers metastatic to brain demonstrated PSMA expression (Fig. 2). There were no PSMA scores 0 or 1, resulting in a PSMA score 2 in all 14 cases (Table 2). Of interest, 10 of the cases of metastases were compared with their respective primary breast carcinomas. In each of these cases, the metastatic lesions had the same PSMA expression score (i.e., 2) as their respective primary tumors.

The 10-year overall survival in this series of patients was 88.7% (95% CI = 80.0%, 93.8%) in patients without brain metastases (Fig. 3A). When the survival was stratified based on the PSMA score, patients with a score of 0 had a 10-year OS of 95.8% (95% CI = 73.9%, 99.4%), patients with a score of 1 had a 10-year OS of 96.0% (95% CI = 74.8%, 99.4%), and patients with a score of 2 had a 10-year OS of 79.7% (95% CI = 63.4%, 89.3%) (P = 0.12 by log-rank test) (Fig. 3B). When the OS was analyzed based on less than 50% staining vs more, patients with PSMA scores of 0 and 1 (50 patients, 6 deaths) had a 10-year OS of 96.0% (95% CI = 84.8%, 99.0%) as compared with the patients with a PSMA score of 2 (42 patients, 11 deaths) whose 10-year OS was 79.7% (95% CI = 63.4%, 89.3%) (Fig. 2C) (p = 0.05 by log-rank test).

PSMA expression was examined in relation to clinicopathological parameters in invasive breast carcinomas **(Table** 3**)**. Patients with a PSMA score of 2 had a significantly higher median tumor size compared with patients in the lower PSMA score groups (p = 0.04). Patients with higher nuclear grade were more likely to have a PSMA score of 2 compared with patients with lower nuclear grade

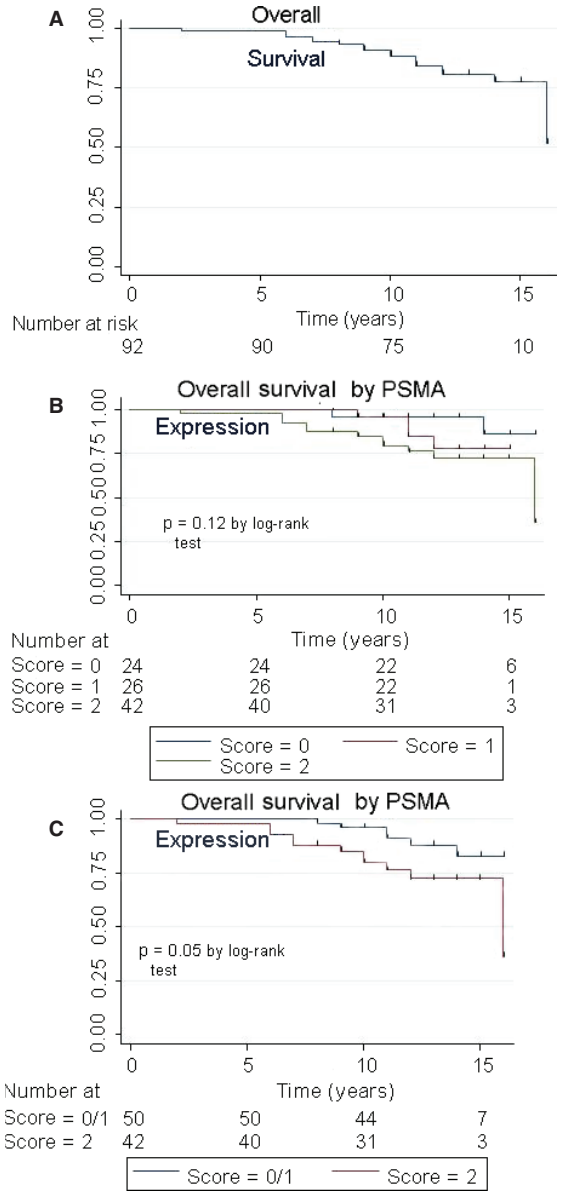

Fig. 3. Kaplan–Meier Survival Curves (A) Kaplan–Meier survival curve showing cumulative overall survival for patients with primary breast cancer (excluding brain metastases). (B) Kaplan–Meier survival curve showing overall survival for patients with based on a PSMA score. **(C)** Kaplan–Meier survival curve showing overall survival for patients with based on a PSMA score, when grouped by scores 0 and 1 (PSMA staining <50%) vs 2 (PSMA staining >50%).

(p < 0.0001). Patients with a PSMA score of 2 had a significantly higher median Ki-67 proliferation index (20%) compared with patients in the lower PSMA score groups (10% for scores of 0 and 1 each), (p < 0.0001). Patients with ER-negative

© 2013 APMIS. Published by John Wiley & Sons Ltd

Table 3. Relationship of PSMA expression to clinicopathological parameters in invasive breast carcinomas

Tumor Characteristics	PSMA score 0 (N) 24	PSMA score 1 (N) 26	PSMA score 2 (N) 42	p-value
Median tumor size (cm)	1.00	0.95	1.4	0.04
Nuclear grade (% of total cases)	Grade 1 = 15 (63%) Grade 2 = 8 (33%) Grade 3 = 1 (4%)	Grade 1 = 13 (50%) Grade 2 = 10 (39%) Grade 3 = 3 (11%)	Grade 1 = 2 (5%) Grade 2 = 21 (50%) Grade 3 = 19 (45%)	< 0.0001
Lymph node Involvement (% of total cases)	3 (14%)	10 (45%)	9 (41%)	0.95
ER -negative tumors (% of total cases)	2 (8%)	0 (0%)	21 (50%)	< 0.0001
PR-negative tumors (% of total cases)	6 (25%)	9 (35%)	23 (55%)	0.03
Her2neu-expressing tumors (% of total cases)	0 = 3 (13%) 1+ = 2 (8%) 2+ = 18 (75%) 3+ = 1(4%)	0 = 0 (0%) 1+ = 1 (4%) 2+ = 23 (89%) 3+ = 2 (7%)	0 = 2 (5%) 1+ = 6 (14%) 2+ = 30 (71%) 3+ = 4 (10%)	0.35
Ki 67 index by increasing PSMA score (% of total cases)				< 0.0001
Ki67 score <10%	4 (16%)	9 (35%)	4 (10%)	
Ki67 score 10–14%	17 (71%)	12 (46%)	12 (29%)	
Ki67 score >14%	3 (13%)	5 (19%)	25 (61%)	
	Median – 10%	Median – 10%	Median – 20%	

tumors were more likely to have a PSMA score of 2 compared with patients with ER-positive tumors ($p < 0.0001$). Patients with PR-negative tumors were more likely to have a PSMA score of 2 compared with patients with PR-positive tumors ($p = 0.03$). No significant association was observed between PSMA score group status and lymph node involvement ($p = 0.95$). Too little variability was present in Her2neu-amplified tumors to correlate with PSMA score group status.

DISCUSSION

Treatment of solid tumors with anti-angiogenic agents has become an established paradigm in cancer therapy (1, 24–26). The search for novel molecular targets has led to the discovery of PSMA as a neovascular target across a broad range of tumor types; however, studies of neovascular PSMA expression have been limited in tumor type and case number (14–16).

Neovascular PSMA expression levels appear to differ among different tumor types (27, 28). Our data indicate that PSMA expression in the neovasculature of primary breast cancers (74%) as well as (distant) metastatic disease (100%) is largely restricted to endothelial cells within the pathologically defined tumor area. Consistent with prior experience in gastric, colorectal (16) and head and neck cancer, there was no PSMA immunoreactivity in either normal breast tissue or carcinoma cells and only rarely in normal tissue-associated vasculature, albeit weak and focal. Furthermore, invasive breast carcinomas with unfavorable clinicopathologic features such as larger tumor size, higher nuclear grade, ER/PR negativity, and high Ki-67 index demonstrated significantly higher PSMA expression than cancers lacking these features. If this finding is validated by other studies, PSMA expression levels may provide helpful prognostic information in the future aiding the selection of patients for adjuvant systemic therapies.

We found high PSMA expression in brain metastases from primary breast carcinomas as well as in some primary invasive breast carcinomas (Table 2). The identical pattern of PSMA expression in 10 primary carcinomas and metastatic lesions from the same patient suggest that high PSMA expression may be conserved throughout cancer progression including distant metastases. Although assessed in a limited number of cases, if confirmed, the similarity of pattern of PSMA expression between the primary and metastatic sites should allow PSMA typing of the metastatic tumor vasculature by evaluating PSMA expression at the primary site. Such an approach may aid in selecting high PSMA-expressing tumors for PSMA-directed therapy. Haffner et al. demonstrated a similar correlation of patterns in the neovasculatures of gastrointestinal malignancies examined for PSMA expression (16).

Recently, an *in vitro* model of PSMA expression by primary human umbilical vein endothelial cells (HUVECs) cultured in Matrigel and induced by tumor-conditioned medium (TCM) derived from human breast cancer cells (MDA-MB-231) was described (29). In contrast to vascular endothelial growth factor (VEGF)-containing endothelial cell medium, TCM induced higher expression of PSMA in HUVECs. This *in vitro* model may enable studies

© 2013 APMIS. Published by John Wiley & Sons Ltd

aimed at understanding the mechanism of PSMA expression in breast and other cancers (29).

We saw no significant difference between the PSMA score and overall survival in our study (Fig. 3B). However, when we examined OS based on ≤50% or >50% PSMA expression, we did see a statistically significant difference (Fig. 3C). Because there were only 17 deaths in this series, that probably precluded an adequate multivariate analysis.

A variety of methodologies have been developed to target PSMA - monoclonal antibodies (13, 30), peptides (6), RNA aptamers (8), vaccines (9), and small molecules (7, 31). Using these approaches for imaging and therapy of solid tumors would open new avenues in anti-angiogenic therapy. This molecule has already been studied widely as a target in metastatic prostate cancer (13, 30, 32). Two recent studies using a 111. In-labeled monoclonal antibody J591 against PSMA in patients with multiple solid tumor types demonstrated targeting of tumor sites and provided clinical evidence that an antibody-based approach against PSMA can be exploited for vascular targeting therapies (17, 18). Selection of patients most likely to benefit, that is, those with high PSMA expression, could be accomplished by immunohistochemical typing of a tumor specimen or by a PSMA imaging study.

CONCLUSION

This study provides evidence that PSMA is expressed in the tumor-associated vasculature of primary breast cancers and distant (brain) metastases. The use of PSMA targeting approaches in primary and metastatic breast cancers may therefore represent an alternative or adjunct to currently available treatment strategies.

CONFLICTS OF INTEREST

None.

This project was supported by the David H. Koch Foundation and the Robert Dow Philanthropic Fund. Dr. Paul Christos was partially supported by the following grant: Clinical Translational Science Center (CTSC) (2UL1TR000457-06).

REFERENCES

1. Neri D, Bicknell R. Tumour vascular targeting. Nat Rev Cancer 2005;5:436–46.
2. St Croix B, Rago C, Velculescu V, Traverso G, Romans KE, Montgomery E, et al. Genes expressed in human tumor endothelium. Science 2000;289:1197–202.
3. Seaman S, Stevens J, Yang MY, Logsdon D, Graff-Cherry C, St Croix B. Genes that distinguish physiological and pathological angiogenesis. Cancer Cell 2007;11:539–54.
4. Rajasekaran AK, Anilkumar G, Christiansen JJ. Is prostate-specific membrane antigen a multifunctional protein? Am J Physiol Cell Physiol 2005;288:C975–81.
5. Ross JS, Sheehan CE, Fisher HA, Kaufman RP Jr, Kaur P, Gray K, et al. Correlation of primary tumor prostate-specific membrane antigen expression with disease recurrence in prostate cancer. Clin Cancer Res 2003;9:6357–62.
6. Aggarwal S, Singh P, Topaloglu O, Isaacs JT, Denmeade SR. A dimeric peptide that binds selectively to prostate-specific membrane antigen and inhibits its enzymatic activity. Cancer Res 2006;66:9171–7.
7. Foss CA, Mease RC, Fan H, Wang Y, Ravert HT, Dannals RF, et al. Radiolabeled small-molecule ligands for prostate-specific membrane antigen: in vivo imaging in experimental models of prostate cancer. Clin Cancer Res 2005;11:4022–8.
8. Lupold SE, Hicke BJ, Lin Y, Coffey DS. Identification and characterization of nuclease-stabilized RNA molecules that bind human prostate cancer cells via the prostate-specific membrane antigen. Cancer Res 2002;62:4029–33.
9. Slovin SF. Targeting novel antigens for prostate cancer treatment: focus on prostate-specific membrane antigen. Expert Opin Ther Targets 2005;9:561–70.
10. Bander NH, Milowsky MI, Nanus DM, Kostakoglu L, Vallabhajosula S, Goldsmith SJ. Phase I trial of [177] lutetium-labeled J591, a monoclonal antibody to prostate-specific membrane antigen, in patients with androgen-independent prostate cancer. J Clin Oncol 2005;23:4591–601.
11. Davis MI, Bennett MJ, Thomas LM, Bjorkman PJ. Crystal structure of prostate-specific membrane antigen, a tumor marker and peptidase. Proc Natl Acad Sci U S A 2005;102:5981–6.
12. Milowsky MI, Nanus DM, Kostakoglu L, Vallabhajosula S, Goldsmith SJ, Bander NH. Phase I trial of yttrium-90-labeled anti-prostate-specific membrane antigen monoclonal antibody J591 for androgen independent prostate cancer. J Clin Oncol 2004;22: 2522–31.
13. Liu H, Moy P, Kim S, Xia Y, Rajasekaran A, Navarro V, et al. Monoclonal antibodies to the extracellular domain of prostate-specific membrane antigen also react with tumor vascular endothelium. Cancer Res 1997;57:3629–34.
14. Chang SS, O'Keefe DS, Bacich DJ, Reuter VE, Heston WD, Gaudin PB. Prostate-specific membrane antigen is produced in tumor associated neovasculature. Clin Cancer Res 1999; 5:2674–81.
15. Silver DA, Pellicer I, Fair WR, Heston WD, Cordon-Cardo C. Prostate-specific membrane antigen expression in normal and malignant human tissues. Clin Cancer Res 1997;3:81–5.
16. Haffner MC, Kronberger IE, Ross JC. Prostate-specific membrane antigen expression in the neovasculature of gastric and colorectal cancers. Hum Pathol 2009;40:1754–61.

© 2013 APMIS. Published by John Wiley & Sons Ltd

17. Milowsky MI, Nanus DM, Kostakoglu L, Sheehan CE, Vallabhajosula S, Goldsmith SJ, et al. Vascular targeted therapy with anti-prostate-specific membrane antigen monoclonal antibody J591 in advanced solid tumors. J Clin Oncol 2007;25:540–7.
18. Morris MJ, Pandit-Taskar N, Divgi CR, Bender S, O'Donoghue JA, Nacca A, et al. Phase I evaluation of J591 as a vascular targeting agent in progressive solid tumors. Clin Cancer Res 2007;13:2707–13.
19. Uzzan B, Nicolas P, Cucherat M, Perret GY. Microvessel density as a prognostic factor in women with breast cancer: a systematic review of the literature and meta-analysis. Cancer Res 2004;64:2941–55.
20. Meert A-P, Paesmans M, Martin B, Delmotte P, Berghmans T, Verdebout JM, et al. The role of microvessel density on the survival of patients with lung cancer: a systematic review of the literature with meta-analysis. Brit J Cancer 2002;87: 694–701.
21. Elston CW, Ellis IO. Pathological prognostic factors in breast cancer. I. The value of histological grade in breast cancer: experience from a large study with long-term follow-up. Histopathology 1991;19:403–10.
22. Cheang MC, Chia SK, Voduc D, Gao D, Leung S, Snider J, et al. Ki67 index, HER2 status, and prognosis of patients with luminal B breast cancer. J Natl Cancer Inst 2009;101:736–50.
23. Edge SB, Byrd DR, Compton CC, Fritz AG, Greene FL, Trotti A, editors AJCC Cancer Staging Manual. 7th ed. New York: Springer, 2010:345–76.
24. Folkman J. Angiogenesis. Annu Rev Med 2006;57:1–18.
25. Kerbel R, Folkman J. Clinical translation of angiogenesis inhibitors. Nat Rev Cancer 2002;2:727–39.
26. Hurwitz H, Fehrenbacher L, Novotny W, Cartwright T, Hainsworth J, Heim W, et al. Bevacizumab plus irinotecan, fluorouracil, and leucovorin for metastatic colorectal cancer. N Engl J Med 2004;350:2335–42.
27. Wernicke AG, Edgar MA, Lavi E, Liu H, Salerno P, Bander NH, et al. Prostate-specific membrane antigen as a potential novel vascular target for treatment of glioblastoma multiforme. Arch Pathol Lab Med 2011; 135:1486–9.
28. Zeng C, Ke ZF, Yang Z, Wang Z, Yang SC, Luo CQ, et al. Prostate-specific membrane antigen: a new potential prognostic marker of osteosarcoma. Med Oncol 2012;29:2234–9.
29. Liu T, Jabbes M, Nedrow-Byers JR, Wu LY, Bryan JN, Berkman CE. Detection of prostate-specific membrane antigen on HUVECs in response to breast tumor-conditioned medium. Int J Oncol 2011;38: 1349–55.
30. Bander NH, Nanus DM, Milowsky MI, Kostakoglu L, Vallabahajosula S, Goldsmith SJ. Targeted systemic therapy of prostate cancer with a monoclonal antibody to prostate-specific membrane antigen. Semin Oncol 2003;30:667–76.
31. Zhou J, Neale JH, Pomper MG, Kozikowski AP. NAAG peptidase inhibitors and their potential for diagnosis and therapy. Nat Rev Drug Discov 2005;4: 1015–26.
32. Galsky MD, Eisenberger M, Moore-Cooper S, Kelly WK, Slovin SF, DeLaCruz A, et al. Phase I trial of the prostate-specific membrane antigen-directed immunoconjugate MLN2704 in patients with progressive metastatic castration-resistant prostate cancer. J Clin Oncol 2008;26:2147–54.

© 2013 APMIS. Published by John Wiley & Sons Ltd

Copyright of APMIS is the property of Wiley-Blackwell and its content may not be copied or emailed to multiple sites or posted to a listserv without the copyright holder's express written permission. However, users may print, download, or email articles for individual use.