molecules

MDPI

*Review*

# Clinical Perspectives of Theranostics

**Shozo Okamoto [1,2], Tohru Shiga [3] and Nagara Tamaki [4,*]**

[1] Department of Radiology, Obihiro-Kosei General Hospital, Obihiro 080-0024, Japan; shozo@med.hokudai.ac.jp
[2] Department of Diagnostic Radiology, Hokkaido University Graduate School of Medicine, Sapporo 060-8638, Japan
[3] Advanced Clinical Research Center, Fukushima Global Medical Science Center, Fukushima 960-1295, Japan; tshiga@fmu.ac.jp
[4] Department of Radiology, Kyoto Prefectural University of Medicine, Kyoto 602-8566, Japan
* Correspondence: natamaki@koto.kpu-m.ac.jp

**Abstract:** Theranostics is a precision medicine which integrates diagnostic nuclear medicine and radionuclide therapy for various cancers throughout body using suitable tracers and treatment that target specific biological pathways or receptors. This review covers traditional theranostics for thyroid cancer and pheochromocytoma with radioiodine compounds. In addition, recent theranostics of radioimmunotherapy for non-Hodgkin lymphoma, and treatment of bone metastasis using bone seeking radiopharmaceuticals are described. Furthermore, new radiopharmaceuticals for prostatic cancer and pancreatic cancer have been added. Of particular, F-18 Fluoro-2-Deoxyglucose (FDG) Positron Emission Tomography (PET) is often used for treatment monitoring and estimating patient outcome. A recent clinical study highlighted the ability of alpha-radiotherapy with high linear energy transfer (LET) to overcome treatment resistance to beta–particle therapy. Theranostics will become an ever-increasing part of clinical nuclear medicine.

**Keywords:** PET; theranostics; radionuclide therapy; cancer; prognosis

check for updates

**Citation:** Okamoto, S.; Shiga, T.; Tamaki, N. Clinical Perspectives of Theranostics. *Molecules* **2021**, *26*, 2232. https://doi.org/10.3390/molecules26082232

Academic Editors: Kazuma Ogawa and João D. G. Correia

Received: 12 February 2021
Accepted: 6 April 2021
Published: 13 April 2021

**Publisher's Note:** MDPI stays neutral with regard to jurisdictional claims in published maps and institutional affiliations.

**Copyright:** © 2021 by the authors. Licensee MDPI, Basel, Switzerland. This article is an open access article distributed under the terms and conditions of the Creative Commons Attribution (CC BY) license (https://creativecommons.org/licenses/by/4.0/).

## 1. Introduction

Theranostics is a re-emerging new medical term of combination of diagnostic and therapeutic techniques using suitable drug combination [1]. The aim of theranostics is to provide personalized medicine to patients with cancer by suitable radionuclide imaging and radiotherapeutics which targets specific biological pathways and receptors.

Theranostics has long been applied to treat thyroid cancer and neuroblastomas using suitable radiolabeled compounds, I-131 iodine and I-131-iodine-meta-iodobenzylguanidine (MIBG). More recently, theranostics has been refocused with the advent of new therapeutic antibodies and small molecules which can be transformed into theranostic agents through radio-conjugating with radioactive isotope materials [2]. A number of PET compounds labeled with Ga-68 or F-18 have been used for imaging, while beta- or alfa-emitting sister compounds are applied for therapy [3–5].

Theranostics plays an important role for both detection of malignant lesions throughout the body using tumor affinity compounds, and also treating lesions with radiotherapy emitted from beta- or alfa-emission from the same targeted radiolabeled compounds. Table 1 summarizes various combinations of diagnostic imaging and internal therapy with radiopharmaceuticals for the same target molecule. Thus, systematic imaging and radioisotope therapy is permitted with the use of suitable radiolabeled compounds. There are a number of reports indicating not only the diagnostic values but also better prognostic values of oncology therapy as compared to the conventional systemic chemotherapy [6,7].

This is important to find a suitable cell target for specific radionuclide imaging in combination with target radiotherapy. The first three fields cover specific targets accumulated in the cancer cells (internalization) using suitable radiolabeled agents. Radiolabeled iodine

Patent Owner Exhibit 2188
IPR2025-01582

is accumulated in thyroid cancer. Radiolabeled MIBG goes into cancer cells in malignant pheochromocytoma and paraganglioma. Radiolabeled somatostatin receptor is trapped in neuroendocrine tumors (Table 1). On the other hand, radiolabeled agents do not go into the cancer cells in non-Hodgkin lymphoma or bone metastasis (not internalization). Instead, these agents accumulate near cancer cells with specific targets, such as CD20 antigen on the surface of tumor cell membranes in lymphoma and bone reaction near tumor cells in osteoblastic bone metastases (Table 1).

**Table 1.** Combination of diagnostic imaging and radionuclide with radiopharmaceuticals for the same target disease.

| Target Disease | Target | Companion Diagnostics for Theranostics | Radionuclide Therapy |
|---|---|---|---|
| Differentiated thyroid cancer | Iodine affinity for hormone synthesis | I-131 | I-131 [8–10] |
| Malignant pheochromocytoma, Paraganglioma | Norepinephrine transporter | I-123 MIBG<br>I-131 MIBG | I-131 MIBG [11,12] |
| Neuroendocrine tumor | Somatostatine receptor | In-111 Pentetreotide<br>Ga-68 DOTATE<br>Ga-68 DOTATOC | Lu-177 DOTATATE [13]<br>Lu-177 DOTATOC<br>Y-90 DOTATATE<br>Y-90 DOTATOC |
| B-cell non-Hodgkin malignant lymphoma | Anti-CD20 receptor | In-111 Ibritumomab Tiuxetan<br>I-131 rituximab | Y-90 Ibritumomab Tiuxetan [14]<br>Lu-177 rituximab |
| Bone metastasis | Bone turnover | Tc-99m bone scan | Sr-89 [15,16]<br>Sm-153 EDTMP [16]<br>Ra-223 [17] |
| Castration-resistant prostatic cancer | Prostate specific membrane antigen | Ga-68 PSMA<br>F-18 PSMA | Lu-177 PSMA [18]<br>Ac-225 PSMA [19] |

## 2. Prognostic Value of Theranostics for Thyroid Cancer

Radioiodine therapy with I-131 iodine is a traditional and well-established treatment modality for adjuvant postsurgical ablation of thyroid remnant tissue and therapy of nonresectable local recurrences, lymph node, and distant metastases [8–10].

Differentiated thyroid cancer has strong affinity to I-131 and thus, shows good response to iodine treatment. Dedifferentiated thyroid cancer lesions, on the other hand, tend to lose radioiodine affinity, but instead show an increased glucose metabolism [20]. Both histological and imaging studies provide evidence that increased glucose uptake correlates with a higher grade of malignancy and a worse prognosis [21–24]. Accordingly, FDG PET is considered a valuable tool for the detection of radioiodine-negative metastases in the follow-up of patients with DTC [25–28] (Figures 1 and 2). In addition, FDG-PET holds a promise as a valuable tool for predicting long prognosis of thyroid cancer.

We have analyzed the predictive value of FDG-PET in comparison with radioiodine uptake in 141 high-risk patients with differentiated thyroid cancer with radioiodine therapy after total thyroidectomy [29]. Our results indicate that FDG PET was more predictive for long-term survival, whereas radioiodine uptake was more important for short-term response. Therefore, FDG PET after thyroid remnant ablation should hold a prognostic value for management of high-risk patients with differentiated thyroid cancer [29].

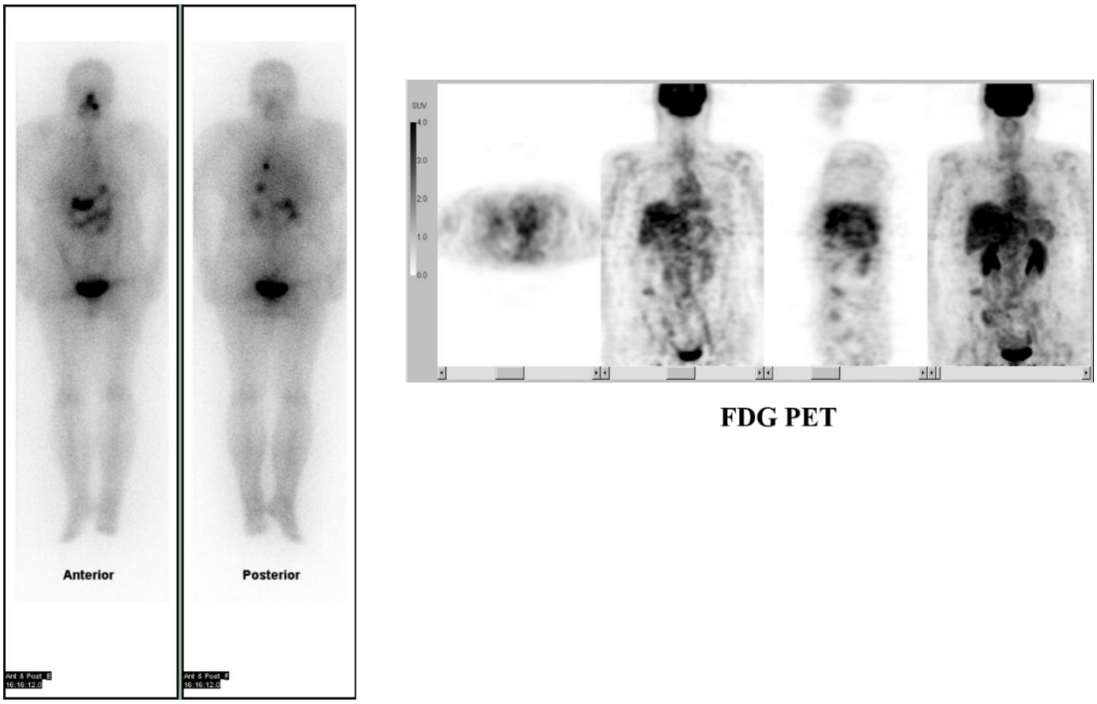


**Figure 1.** A case with thyroid cancer showing positive I-131 and negative FDG uptake in the lung.

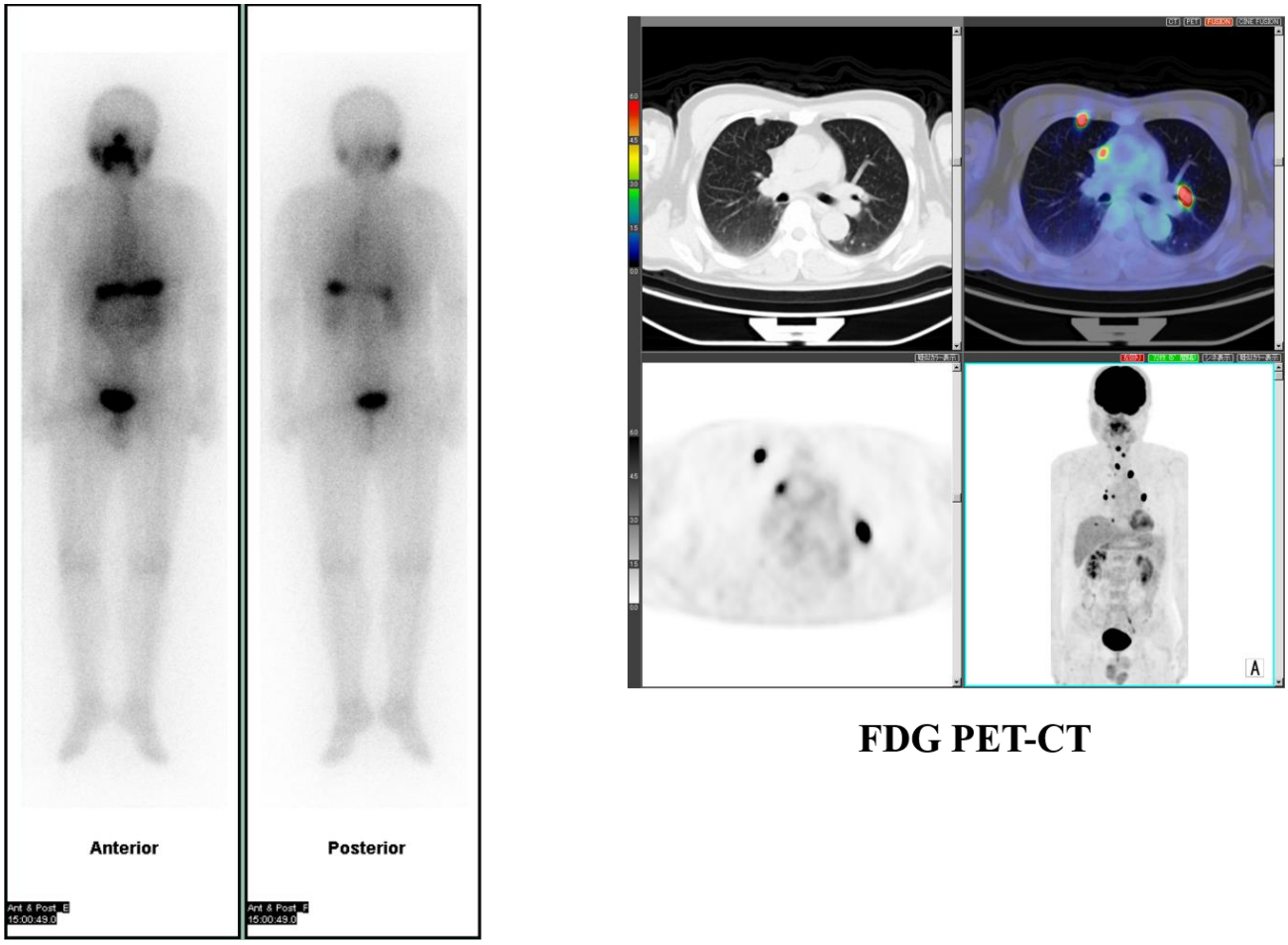


**Figure 2.** A case with thyroid cancer showing negative I-131 and positive FDG uptake in the lung.

## 3. Prognostic Value of Theranostics for Neuroendocrine Tumor

Pheochromocytoma and paraganglioma may develop metastatic lesions. The mean expected survival time with pheochromocytoma is 20.7 years and with paraganglioma is 9.8 years [11,30]. After surgery, systemic chemotherapy is commonly performed for treating remaining and metastatic lesions; however, the survival benefits are not clear because of the lack of prospective comparative studies [31–33].

Iodine-131-meta-iodobenzylguanidine (I-131 MIBG) is a substrate of the norepinephrine transporter system and the structure is similar to norepinephrine [34]. Norepinephrine works as a neurotransmitter in the central and autonomic nervous systems. The concentrations of norepinephrine in the nervous systems are regulated by the norepinephrine transporter. I-131 MIBG also accumulates; however, unlike norepinephrine, I-131 MIBG has little or no affinity for adrenergic receptors [35]. I-131 MIBG radiotherapy has been used to treat neuroendocrine tumors (NETs), including metastatic pheochromocytoma, paraganglioma, neuroblastoma, medullary thyroid carcinoma, and carcinoid tumors that have the uptake-1 mechanism [12,34,36].

I-131 MIBG radiotherapy has shown some survival benefits in metastatic NETs. The European Association of Nuclear Medicine (EANM) clinical guidelines for I-131 MIBG radiotherapy suggest a repeated treatment protocol, although none currently exists [37]. The existing single-high-dose I-131 MIBG radiotherapy (444 MBq/kg) has been shown to have some benefits for patients with metastatic NETs. However, this protocol increases adverse effects and it requires alternative therapeutic approaches.

A previous study reported that FDG PET maximum standardized uptake value (SUVmax) was reduced after I-131 MIBG radiotherapy in patients considered to have responded, suggesting the value of FDG PET imaging for treatment evaluation in patients with PPGL after I-131 MIBG radiotherapy [38] (Figure 3).

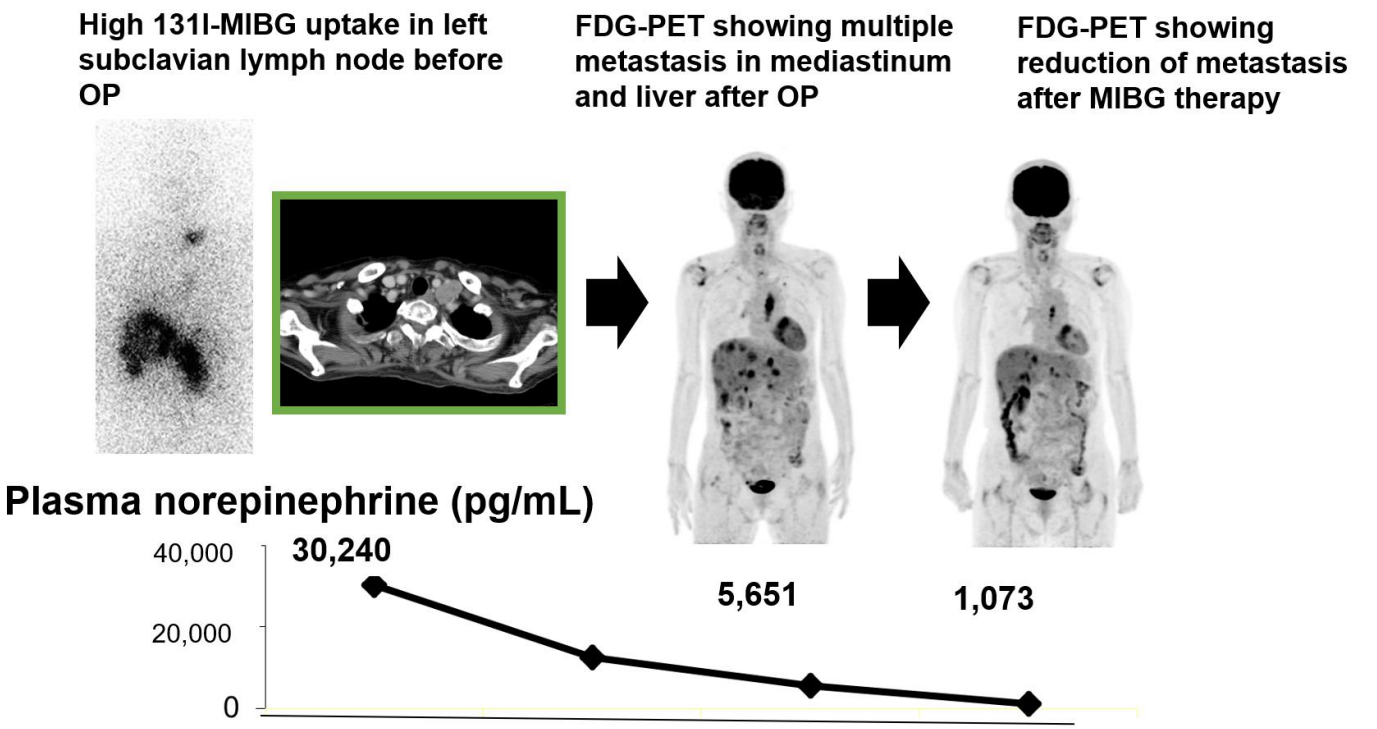


**Figure 3.** A case with pheochromocytoma.

Accordingly, we have evaluated the effects of repeated I-131 MIBG therapy on tumor size and tumor metabolic response in patients with metastatic NETs to find reduced tumor size and tumor metabolic activities according to lesion-based analysis in about one-third of patients and stabilized a majority with this therapy [39]. Thus, we concluded that this

relatively short-term repeated I-131 MIBG treatment may have potential as one option in a therapeutic protocol for metastatic NETs [39].

Theranostics has recently been applied for NETs with somatostatin receptor targeting small molecule tracers such as Ga-68 DOTATATE PET, In-111 Pentetreotide, and Peptide Receptor Radionuclide Therapy (PRRT) with Lu-177 DOTATATE therapy. The patients with positive uptake in Ga-68 DOTATATE PET or In-111 Pentetreotide are indication for Lu-177 DOTATATE treatment in the European Medicine Agency (EMA) and Food and Drug Administration (FDA). Progression free survival (PFS) rate at 20 months was significantly increased from 11% for patients in the control group to 65% in the Lu-177 DOTA-TATE group ($p < 0.0001$) [13].

## 4. Prognostic Value of Radioimmunotherapy of Non-Hodgkin Lymphoma

Non-Hodgkin lymphoma is a common malignancy where I-131 compound has been used for theranostics. Initially 131-iodine-tositumomab was used for imaging and Y-90-ibritumomab-tiuxetan (Zevalin) was used for therapy [14]. However, these initial theranostic trials have failed to become incorporated into mainstream oncologist practice. More recently, lymphoma is effectively treated with 131-iodine-anti-CD20 radioimmunotherapy (RIT) in relapsed/refractory disease following traditional R-CHOP chemotherapy [40,41]. There was no significant toxicity, and also this single-shot theranostic study seems to be superior to all standard therapies. The recent substitution of Lu-177 rituximab, in place of 131-iodine radiolabelling, will facilitate outpatient therapy by minimizing radiation exposure of medical staffs, while retaining the ability to perform individual prospective dosimetry [42]. A recent clinical study using Lu-177 lilotomab satetraxan anti-CD37 monoclonal antibody RIT suggested that tumor radiation absorbed doses comparable with those achieved with 131-iodine-tositumomab anti-CD20 Mab were attained, at red marrow doses below the 2 Gy threshold for myelotoxicity [43].

## 5. Prognostic Value of Theranostics for Bone Metastasis

The skeleton is the most common metastatic site in patients with advanced cancer, particularly in prostatic cancer. Pain is a major healthcare problem in patients with bone metastases. Bone-seeking radionuclides indicating an increase in bone turnover that selectively accumulate in the bone are used to treat cancer-induced bone pain. The goals of these guidelines are to assist nuclear medicine practitioners in evaluating patients who might be candidates for radionuclide treatment of bone metastases using beta-emitting radionuclides such as strontium-89 and Samarium-153 ethylenediaminetetramethylenephosphonic acid (EDTMP) [15]. Strontium-89 is an element that behaves biologically like calcium. The accumulation of strontium is identical to that of Tc-99m MDP (methylene diphosphonate). The distribution of Samarium-153 EDTMP is also identical to Tc-99m MDP [16,44].

On the other hand, theranostic approaches for osseous metastasis have long been focused for alpha therapy using Ra-223 for various solid tumors, such as thyroid cancer and prostatic cancer. It is important that radionuclide therapy has not only a palliative effect but also a potential for prolonging progression-free and overall survival [17,45,46]. This important randomized control study nicely showed 3.6 months longer survival by Ra-223 therapy for bone metastasis from castrate-resistant prostatic cancer [17]. Accordingly, the Japanese government has approved insurance coverage for Ra-223 therapy for those with multiple bone metastasis from prostatic cancer [47].

## 6. Alpha vs. Beta-Emitting Isotope Radiochemistry

As previously described, theranostics has been applied by using suitable therapeutic radioisotopes, including alpha- and beta-emission ones over the last century. Beta-emitting radioisotopes have the longest particle pathlength ($\leq$12 mm) and lowest linear energy transfer (LET) (~0.2 keV/μm), supporting the effectiveness in medium to large tumors. Long beta-particle range is advantageous in evenly distributing a radiation dose in heterogeneous tumors. It can also, though, result in the irradiation of healthy tissue surrounding

the tumor site causing a relatively large side effect. Alpha-particles have a moderate path-length (50–100 μm) and high LET (80 keV/μm) that render them especially suitable for small neoplasms or micro-metastases with such smaller side effects in the surrounding normal organ. A recent clinical study highlighted the ability of alpha-radiotherapy to overcome treatment resistance to beta-particle therapy, prompting a paradigm shift in the approach toward radionuclide therapy [19,48].

## 7. Future Perspectives of Theranostics

More recently, a number of new radio-labeled pharmaceutical compounds have been investigated for promoting theranosticis. One of the most exciting new theranostic agents is the prostate specific membrane antigen (PSMA) binding compound for prostatic cancer developed at Heidelberg University and in many researches worldwide [49]. Prostatic cancer is the second most common cancer in men worldwide with an estimated about a million 1,276,000 new patients. About 30% of men experience biochemical recurrence, often progress to castration resistant prostate cancer (CRPC), and there were 359,000 deaths in 2018 [50,51].

New therapeutic agents such as abiraterone, enzalutamide, and cabazitaxel have been developed in the last decade [52]. On the other hand, diagnostic tools with radionuclide such as Ga-68 or F-18 labelled PSMA have been used for whole body PET imaging to identify metastatic lesions [53–56]. In addition, Lu-177 or Ac-225 labeled PSMA therapies are expected to have a therapeutic effect by a unique mechanism using radiopharmaceuticals [18,19,57,58]. Lu-177 or Ac-225 PSMA therapies are the main strategies in theranostics at present. PSMA PET detects recurrent and metastatic tumors more accurately than conventional imaging diagnostic tools such as computed tomography (CT), bone scintigraphy (BS), or F-18 Fluciclovine PET [53–56]. In the study of our group at the Technical University of Munich, the accuracy of Ga-68 PSMA PET was 99.8% which was significantly higher than BS (84.3%) and BS + Single Photon Emission Computed Tomography (SPECT). In another international trial of Ga-68 PSMA-PET in biochemical recurrence, 75% of patients had a positive lesion detected, and both the positive predictive value and sensitivity were 92% [56]. The FDA approved Ga-68 PSMA-PET for patients with suspected prostate cancer metastasis and with suspected prostate cancer recurrence based on elevated serum prostate-specific antigen (PSA) levels in December 2020. Our group also reported that similar uptake is shown between pretherapeutic Ga-68 PSMA-PET and Lu-177 PSMA therapy; therefore, Ga-68 PSMA PET avid lesions are expected the effect of Lu-177 PSMA therapy (Figure 4) [57]. Up to 4 cycles treatments with 6 weeks interval are a standard course of Lu-177 PSMA therapy considered for a kidney absorbed dose at a risk organ.

The remarkable therapeutic effect of Lu-177 PSMA therapy for CRPC has been described in several reports. PSA decline from baseline was seen in 68% of patients [59], greater than or equal to 50% seen in 44–64% of patients [18,58–62]. At least 80% decline was seen in 44% of patients, and 16% achieved an at least 98% PSA decline [58]. Regarding toxicity, there were no treatment-related deaths, and grade 2 or less xerostomia was reported in 8–66% of patients. Grade 1–2 nausea was seen in 6–48%, respectively. Grade 3–4 toxicity was primarily hematologic, including leukopenia (3–32%), thrombocytopenia (5–10%), and anemia (10%). Grade 1–2 renal injury occurred in 10% of patients [58,59]. Ac-225 PSMA therapy is expecting excellent therapeutic effect even for PC resistant to Lu-177 PSMA therapy [63]. PSA decline of more than 50% from baseline was observed in 21–63% of the patients [63–65]. This rate is similar to the biochemical response rates of Lu-177 PSMA therapy; however, note that many patients who underwent Ac-225 PSMA therapy were refractory to previous Lu-177 PSMA therapy.

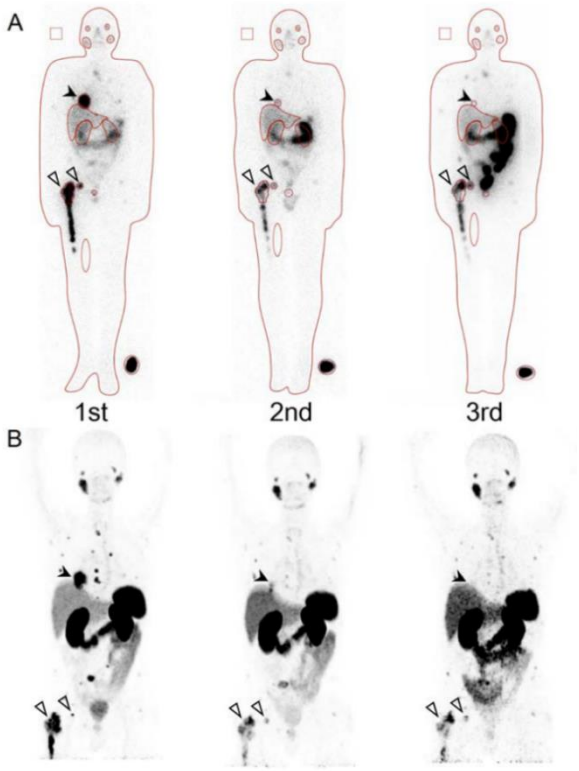


**Figure 4.** A patient with multiple metastases in lung (black arrow) and bone (white arrows): (**A**): Posttherapeutic Lu-177 prostate specific membrane antigen (PSMA) scintigraphy; (**B**): Pretherapeutic Ga -68 PSMA PET. Copyright 2017, with permission from J. Nucl. Med. [56].

Another exciting theranostic trial is in applying for cancer with poor prognosis. Most theranostic radiopharmaceuticals have so far been applied for cancer with relatively good prognosis. On the other hand, pancreatic adenocarcinoma has an extremely poor prognosis. Five years survival rate of metastatic pancreatic adenocarcinoma is less than 5% [66]. At the time of diagnosis, most patients are ineligible for surgery due to metastatic spread or local invasion. For metastatic disease, cytotoxic chemotherapy is the only treatment choice on most occasions [67]. Neurotensin receptor 1 is highly expressed in ductal pancreatic adenocarcinoma as well as hepatic metastasis but not in normal pancreatic tissue or chronic pancreatitis [67,68]. 3BP-227 is a DOTA-conjugated neurotensin receptor 1 antagonist and Lu-177 labeled 3BP-227 significantly inhibited tumor growth [68]. The first clinical trial of Lu-177 labeled 3BP-227 indicated feasibility of treatment of ductal pancreatic adenocarcinoma [69]. More clinical experiences are warranted to see whether this new agent may prolong survival of this disease.

In external-radiation therapy, the radiation treatment plan is designed to focus the dose on the malignant tumor and to minimize damage to the surrounding tissues. On the other hand, in conventional radionuclide therapy, doses are administered empirically, and there are no guidelines for dosimetry and no personalization. In radionuclide theranostics, dosimetry can be measured in the following two ways: one is to estimate the dose from the kinetic analysis of companion diagnostics, and the other is to measure the dose of the first treatment. The AHASA (as high dose as safety administrated) approach is proposed for radionuclide therapy [70]. Evidence on the relationship between dose and treatment or side effect is now gradually accumulating [71–74]. A study of theranostics for neuroendocrine tumors reported that dose escalation based on organ risk improved outcome [74]. In this study, they conducted a prospective observational study of 200 patients with advanced metastatic NETs. Patients received additional cycles of treatment until the cumulative renal dose reached 23 Gy or was discontinued due to toxicity. Overall survival was significantly longer when treatment was given until the cumulative renal dose reached 23 Gy. Once the

evidence is established, a personalized, dosimetry-based treatment planning will become the mainstream for the purpose of more effective treatment and avoidance of serious side effects.

As in many other radionuclide studies, the injected drug dose is quite small with minimal side effects. On the other hand, a careful attention should be used for suitable radiation dose to each patient. A rapid grow of theranostics for diagnosis and treatment combination has increased a need for nuclear medicine practitioners with suitable training in the field of new nuclear medicine and radionuclide therapy.

## 8. Conclusions

Theranostics is an elegant technique using suitable pairs of radionuclide imaging and radiotherapeutics which targets specific biological pathways and receptors.

This review has outlined old as well as recently developed nuclear theranostics which have entered the clinic as well as evolving imaging and therapy. In particular, new trends toward patient outcome have been focused upon. Theranostics will become an ever-increasing part of clinical nuclear medicine. This will lead to adaptation of personalized molecular targeted radionuclide therapy as a mainstream oncology practice throughout world.

**Author Contributions:** Conceptualization, N.T.; methodology, N.T.; writing—original draft preparation, S.O., T.S. and N.T.; writing—review and editing, S.O., T.S. and N.T. All authors have read and agreed to the published version of the manuscript.

**Funding:** This research received no external funding.

**Institutional Review Board Statement:** Not Applicable.

**Informed Consent Statement:** Not Applicable.

**Data Availability Statement:** No new data were created or analyzed in this study. Data sharing is not applicable to this article.

**Conflicts of Interest:** The authors declare no conflict of interest.

## References

1. Gilban, I. Theranostics—An emerging tool in drug discovery and commercialisation. *Drug Discov. World.* **2002**, *1*, 17–23.
2. DeNardo, G.L.; DeNardo, S.J. Concepts, Consequences, and Implications of Theranosis. *Semin. Nucl. Med.* **2012**, *42*, 147–150. [CrossRef]
3. Sharma, H.; Mishra, P.K.; Talegaonkar, S.; Vaidya, B. Metal nanoparticles: A theranostic nanotool against cancer. *Drug Discov. Today* **2015**, *20*, 1143–1151. [CrossRef]
4. Feng, G.; Liu, B. Aggregation-Induced Emission (AIE) Dots: Emerging Theranostic Nanolights. *Acc. Chem. Res.* **2018**, *51*, 1404–1414. [CrossRef] [PubMed]
5. Zhou, W.; Ding, J.; Liu, J. Theranostic DNAzymes. *Theranostics* **2017**, *7*, 1010–1025. [CrossRef]
6. Siegel, R.L.; Miller, K.D.; Jemal, A. Cancer statistics, 2019. *CA Cancer J. Clin.* **2019**, *69*, 7–34. [CrossRef] [PubMed]
7. Bray, F.; Ferlay, J.; Soerjomataram, I.; Siegel, R.L.; Torre, L.A.; Jemal, A. Global cancer statistics 2018: GLOBOCAN estimates of incidence and mortality worldwide for 36 cancers in 185 countries. *CA Cancer J. Clin.* **2018**, *68*, 394–424. [CrossRef]
8. Luster, M.; Clarke, S.E.; Dietlein, M.; Lassmann, M.; Lind, P.; Oyen, W.J.G.; Tennvall, J.; Bombardieri, E. Guidelines for radioiodine therapy of differentiated thyroid cancer. *Eur. J. Nucl. Med. Mol. Imaging* **2008**, *35*, 1941–1959. [CrossRef] [PubMed]
9. Haugen, B.R.; Alexander, E.K.; Bible, K.C.; Doherty, G.M.; Mandel, S.J.; Nikiforov, Y.E.; Pacini, F.; Randolph, G.W.; Sawka, A.M.; Schlumberger, M.; et al. 2015 American Thyroid Association Management Guidelines for Adult Patients with Thyroid Nodules and Differentiated Thyroid Cancer: The American Thyroid Association Guidelines Task Force on Thyroid Nodules and Differentiated Thyroid Cancer. *Thyroid* **2016**, *26*, 1–133. [CrossRef]
10. Mazzaferri, E.L.; Jhiang, S.M. Long-term impact of initial surgical and medical therapy on papillary and follicular thyroid cancer. *Am. J. Med.* **1994**, *97*, 418–428. [CrossRef]
11. Neumann, H.P.H.; Young, W.F., Jr.; Eng, C. Pheochromocytoma and Paraganglioma. *N. Engl. J. Med.* **2019**, *381*, 552–565. [CrossRef]
12. Kinuya, S.; Yoshinaga, K.; Higuchi, T.; Jinguji, M.; Kurihara, H.; Kawamoto, H. Guideline Drafting Committee for Radiotherapy with 131I-MIBG, Committee for Nuclear Oncology and Immunology, The Japanese Society of Nuclear Medicine. *Ann. Nucl. Med.* **2015**, *29*, 543–552. [CrossRef]
13. Strosberg, J.; El-Haddad, G.; Wolin, E.; Hendifar, A.; Yao, J.; Chasen, B.; Mittra, E.; Kunz, P.L.; Kulke, M.H.; Jacene, H.; et al. Phase 3 Trial of 177Lu-Dotatate for Midgut Neuroendocrine Tumors. *N. Engl. J. Med.* **2017**, *376*, 125–135. [CrossRef]

14. Wagner, H.N., Jr.; Wiseman, G.A.; Marcus, C.S.; Nabi, H.A.; Nagle, C.E.; Fink-Bennett, D.M.; Lamonica, D.M.; Conti, P.S. Administration guidelines for radioimmunotherapy of non-Hodgkin's lymphoma with (90)Y-labeled anti-CD20 monoclonal antibody. *J. Nucl. Med.* **2002**, *43*, 267–272. [PubMed]
15. Bauman, G.; Charette, M.; Reid, R.; Sathya, J. Radiopharmaceuticals for the palliation of painful bone metastases—A systematic review. *Radiother. Oncol.* **2005**, *75*, 258.E1–258.E13. [CrossRef]
16. Kuroda, I. Effective use of strontium-89 in osseous metastases. *Ann. Nucl. Med.* **2012**, *26*, 197–206. [CrossRef] [PubMed]
17. Parker, C.; Nilsson, S.; Heinrich, D.; Helle, S.; O'Sullivan, J.; Fosså, S.; Chodacki, A.; Wiechno, P.; Logue, J.; Seke, M.; et al. Alpha Emitter Radium-223 and Survival in Metastatic Prostate Cancer. *N. Engl. J. Med.* **2013**, *369*, 213–223. [CrossRef]
18. Hofman, M.S.; Violet, J.; Hicks, R.J.; Ferdinandus, J.; Thang, S.P.; Akhurst, T.; Iravani, A.; Kong, G.; Ravi Kumar, A.; Murphy, D.G.; et al. [($^{177}$)Lu]-PSMA-617 radionuclide treatment in patients with metastatic castration-resistant prostate cancer (LuPSMA trial): A single-centre, single-arm, phase 2 study. *Lancet Oncol.* **2018**, *19*, 825–833. [CrossRef]
19. Kratochwil, C.; Bruchertseifer, F.; Giesel, F.L.; Weis, M.; Verburg, F.A.; Mottaghy, F.; Kopka, K.; Apostolidis, C.; Haberkorn, U.; Morgenstern, A. $^{225}$Ac-PSMA-617 for PSMA-targeted $\alpha$-radiation therapy of metastatic castration-resistant prostate cancer. *J. Nucl. Med.* **2016**, *57*, 1941–1944. [CrossRef]
20. Feine, U.; Lietzenmayer, R.; Hanke, J.P.; Wöhrle, H.; Müller-Schauenburg, W. 18FDG whole-body PET in differentiated thyroid carcinoma. Flipflop in uptake patterns of 18FDG and 131I. *Nuklearmedizin* **1995**, *34*, 127–134. [PubMed]
21. Schoenberger, J.; Rüschoff, J.; Grimm, D.; Marienhagen, J.; Rümmele, P.; Meyringer, R.; Kossmehl, P.; Hofstaedter, F.; Eilles, C. Glucose Transporter 1 Gene Expression is Related to Thyroid Neoplasms with an Unfavorable Prognosis: An Immunohistochemical Study. *Thyroid* **2002**, *12*, 747–754. [CrossRef]
22. Robbins, R.J.; Wan, Q.; Grewal, R.K.; Reibke, R.; Gonen, M.; Strauss, H.W.; Tuttle, R.M.; Drucker, W.; Larson, S.M. Real-Time Prognosis for Metastatic Thyroid Carcinoma Based on 2-[18F]Fluoro-2-Deoxy-d-Glucose-Positron Emission Tomography Scanning. *J. Clin. Endocrinol. Metab.* **2006**, *91*, 498–505. [CrossRef]
23. Deandreis, D.; Al Ghuzlan, A.; Leboulleux, S.; Lacroix, L.; Garsi, J.P.; Talbot, M.; Lumbroso, J.; Baudin, E.; Caillou, B.; Bidart, J.M.; et al. Do histological, immunohistochemical, and metabolic (radioiodine and fluorodeoxyglucose uptakes) patterns of metastatic thyroid cancer correlate with patient outcome? *Endocrine-Related Cancer* **2011**, *18*, 159–169. [CrossRef] [PubMed]
24. Yoshio, K.; Sato, S.; Okumura, Y.; Katsui, K.; Takemoto, M.; Suzuki, E.; Katayama, N.; Kaji, M.; Kanazawa, S. The Local Efficacy of I-131 for F-18 FDG PET Positive Lesions in Patients With Recurrent or Metastatic Thyroid Carcinomas. *Clin. Nucl. Med.* **2011**, *36*, 113–117. [CrossRef] [PubMed]
25. Stokkel, M.P.M.; Duchateau, C.S.J.; Dragoiescu, C. The value of FDG-PET in the follow-up of differentiated thyroid cancer: A review of the literature. *Q. J. Nucl. Med. Mol. Imaging* **2006**, *50*, 78–87.
26. Reske, S.N.; Kotzerke, J. FDG-PET for clinical use. *Eur. J. Nucl. Med. Mol. Imaging* **2001**, *28*, 1707–1723. [CrossRef] [PubMed]
27. Nanni, C.; Rubello, D.; Fanti, S.; Farsad, M.; Ambrosini, V.; Rampin, L.; Banti, E.; Carpi, A.; Muzzio, P.; Franchi, R. Role of 18F-FDG-PET and PET/CT imaging in thyroid cancer. *Biomed. Pharmacother.* **2006**, *60*, 409–413. [CrossRef] [PubMed]
28. Shiga, T.; Tsukamoto, E.; Nakada, K.; Morita, K.; Kato, T.; Mabuchi, M.; Yoshinaga, K.; Katoh, C.; Kuge, Y.; Tamaki, N. Comparison of (18)F-FDG, (131)I-Na, and (201)Tl in diagnosis of recurrent or metastatic thyroid carcinoma. *J. Nucl. Med.* **2001**, *42*, 414–419. [PubMed]
29. Gaertner, F.C.; Okamoto, S.; Shiga, T.; Ito, Y.M.; Uchiyama, Y.; Manabe, O.; Hattori, N.; Tamaki, N. FDG PET Performed at Thyroid Remnant Ablation Has a Higher Predictive Value for Long-Term Survival of High-Risk Patients with Well-Differentiated Thyroid Cancer Than Radioiodine Uptake. *Clin. Nucl. Med.* **2015**, *40*, 378–383. [CrossRef] [PubMed]
30. Ayala-Ramirez, M.; Feng, L.; Johnson, M.M.; Ejaz, S.; Habra, M.A.; Rich, T.; Busaidy, N.; Cote, G.J.; Perrier, N.D.; Phan, A.; et al. Clinical Risk Factors for Malignancy and Overall Survival in Patients with Pheochromocytomas and Sympathetic Paragangliomas: Primary Tumor Size and Primary Tumor Location as Prognostic Indicators. *J. Clin. Endocrinol. Metab.* **2011**, *96*, 717–725. [CrossRef]
31. Lenders, J.W.; Eisenhofer, G.; Mannelli, M.; Pacak, K. Phaeochromocytoma. *Lancet* **2005**, *366*, 665–675. [CrossRef]
32. Jimenez, P.; Tatsui, C.; Jessop, A.; Thosani, S.; Jimenez, C. Treatment for Malignant Pheochromocytomas and Paragangliomas: 5 Years of Progress. *Curr. Oncol. Rep.* **2017**, *19*, 83. [CrossRef] [PubMed]
33. Björklund, P.; Pacak, K.; Crona, J. Precision medicine in pheochromocytoma and paraganglioma: Current and future concepts. *J. Intern. Med.* **2016**, *280*, 559–573. [CrossRef] [PubMed]
34. Taieb, D.; Jha, A.; Treglia, G.; Pacak, K. Molecular imaging and radionuclide therapy of paraganglioma and pheochromocytoma. *Endocr. Relat. Cancer* **2019**, *26*, R627–R652. [CrossRef]
35. Jimenez, C.; Erwin, W.D.; Chasen, B. Targeted Radionuclide Therapy for Patients with Metastatic Pheochromocytoma and Paraganglioma: From Low-Specific-Activity to High-Specific-Activity Iodine-131 Metaiodobenzylguanidine. *Cancers* **2019**, *11*, 1018. [CrossRef]
36. Jackson, M.R.; Falzone, N.; Vallis, K.A. Advances in Anticancer Radiopharmaceuticals. *Clin. Oncol.* **2013**, *25*, 604–609. [CrossRef] [PubMed]
37. Giammarile, F.; Chiti, A.; Lassmann, M.; Brans, B.; Flux, G. EANM procedure guidelines for 131I-meta-iodobenzylguanidine (131I-mIBG) therapy. *Eur. J. Nucl. Med. Mol. Imaging* **2008**, *35*, 1039–1047. [CrossRef] [PubMed]
38. Tokue, A.; Higuchi, T.; Oriuchi, N.; Arisaka, Y.; Endo, K. Clinical significance of 2-[18F]fluoro-2-deoxy-d-glucose positron emission tomography for the assessment of 131I-metaiodobenzylguanidine therapy in malignant phaeochromocytoma. *Eur. J. Nucl. Med. Mol. Imaging* **2011**, *38*, 1869–1875. [CrossRef]

39. Yoshinaga, K.; Abe, T.; Okamoto, S.; Uchiyama, Y.; Manabe, O.; Ito, Y.M.; Tamura, N.; Ito, N.; Yoshioka, N.; Washino, K.; et al. Effects of Repeated 131I-meta-iodobenzylguanidine Radiotherapy on Tumor Size and Tumor Metabolic Activities in Patients with Metastatic Neuroendocrine Tumors. *J. Nucl. Med.* **2020**. Online ahead of print. [CrossRef]
40. Leahy, M.F.; Turner, J.H. Radioimmunotherapy of relapsed indolent non-Hodgkin lymphoma with 131I-rituximab in routine clinical practice: 10-year single-institution experience of 142 consecutive patients. *Blood* **2011**, *117*, 45–52. [CrossRef]
41. McQuillan, A.D.; Macdonald, W.B.; Turner, J.H. Phase II study of first-line (131)I- rituximab radioimmunotherapy in follicular non-Hodgkin lymphoma and prognostic (18)F-fluorodeoxyglucose positron emission tomography. *Leuk. Lymphoma* **2015**, *56*, 1271–1277. [CrossRef] [PubMed]
42. Kesavan, M.; McQuillan, A.D.; Macdonald, W.B.G.; Turner, J.H. First-line radioimmunotherapy of advanced follicular non-Hodgkin lymphoma with 131-I-rituximab; Ten year follow-up. *Leuk. Lymphoma* **2017**, *35*, 366–367.
43. Forrer, F.; Oechslin-Oberholzer, C.; Campana, B.; Herrmann, R.; Maecke, H.R.; Mueller-Brand, J.; Lohri, A. Radioimmunotherapy with 177Lu-DOTA-rituximab: Final results of a phase I/II Study in 31 patients with relapsing follicular, mantle cell, and other indolent B-cell lymphomas. *J. Nucl. Med.* **2013**, *54*, 1045–1052. [CrossRef] [PubMed]
44. Pandit-Taskar, N.; Batraki, M.; Divgi, C.R. Radiopharmaceutical therapy for palliation of bone pain from osseous metastases. *J. Nucl. Med.* **2004**, *45*, 1358–1365.
45. Du, Y.; Carrio, I.; De Vincentis, G.; Fanti, S.; Ilhan, H.; Mommsen, C.; Nitzsche, E.; Sundram, F.; Vogel, W.; Oyen, W.; et al. Practical recommendations for radium-223 treatment of metastatic castration-resistant prostate cancer. *Eur. J. Nucl. Med. Mol. Imaging* **2017**, *44*, 1671–1678. [CrossRef]
46. Maffioli, L.S.; Florimonte, L.; Costa, D.C.; Castanheira, J.C.; Grana, C.; Luster, M.; Bodei, L.; Chinol, M. New radiopharmaceutical agents for the treatment of castration-resistant prostate cancer. *Q J. Nucl. Med. Mol. Imaging* **2015**, *59*, 420–438.
47. Hosono, M.; Ikebuchi, H.; Nakamura, Y.; Yanagida, S.; Kinuya, S. Introduction of the targeted alpha therapy (with Radium-223) into clinical practice in Japan: Learnings and implementation. *Ann. Nucl. Med.* **2019**, *33*, 211–221. [CrossRef]
48. Poty, S.; Francescpni, L.C.; McDevitt, M.R.; Morris, M.J.; Lewis, J.S. α-emisstiers for radiotherapy: From basic radiochemistry to clinical studies. Part 1. *J. Nucl. Med.* **2018**, *59*, 878–884. [CrossRef]
49. Afshar-Oromieh, A.; Haberkorn, U.; Eder, M.; Eisenhut, M.; Zechmann, C.M. [68Ga]Gallium-labelled PSMA ligand as superior PET tracer for the diagnosis of prostate cancer: Comparison with 18F-FECH. *Eur. J. Nucl. Med. Mol. Imaging* **2012**, *39*, 1085–1086. [CrossRef]
50. Culp, M.; Soerjomataram, I.; Efstathiou, J.A.; Bray, F.; Jemal, A. Recent Global Patterns in Prostate Cancer Incidence and Mortality Rates. *Eur. Urol.* **2020**, *77*, 38–52. [CrossRef]
51. Center, M.M.; Jemal, A.; Lortet-Tieulent, J.; Ward, E.; Ferlay, J.; Brawley, O.W.; Bray, F. International Variation in Prostate Cancer Incidence and Mortality Rates. *Eur. Urol.* **2012**, *61*, 1079–1092. [CrossRef] [PubMed]
52. Komura, K.; Sweeney, C.J.; Inamoto, T.; Ibuki, N.; Azuma, H.; Kantoff, P.W. Current treatment strategies for advanced prostate cancer. *Int. J. Urol.* **2018**, *25*, 220–231. [CrossRef] [PubMed]
53. Eiber, M.; Maurer, T.; Souvatzoglou, M.; Beer, A.J.; Ruffani, A.; Haller, B.; Graner, F.P.; Kübler, H.; Haberkorn, U.; Eisenhut, M.; et al. Evaluation of Hybrid $^{68}$Ga-PSMA Ligand PET/CT in 248 Patients with Biochemical Recurrence After Radical Prostatectomy. *J. Nucl. Med.* **2015**, *56*, 668–674. [CrossRef] [PubMed]
54. Pyka, T.; Okamoto, S.; Dahlbender, M.; Tauber, R.; Retz, M.; Heck, M.; Tamaki, N.; Schwaiger, M.; Maurer, T.; Eiber, M. Comparison of bone scintigraphy and 68Ga-PSMA PET for skeletal staging in prostate cancer. *Eur. J. Nucl. Med. Mol. Imaging* **2016**, *43*, 2114–2121. [CrossRef]
55. Calais, J.; Ceci, F.; Eiber, M.; Hope, T.A.; Hofman, M.S.; Rischpler, C.; Bach-Gansmo, T.; Nanni, C.; Savir-Baruch, B.; Elashoff, D.; et al. 18F-fluciclovine PET-CT and 68Ga-PSMA-11 PET-CT in patients with early biochemical recurrence after prostatectomy: A prospective, single-centre, single-arm, comparative imaging trial. *Lancet Oncol.* **2019**, *20*, 1286–1294. [CrossRef]
56. Fendler, W.P.; Calais, J.; Eiber, M.; Flavell, R.R.; Mishoe, A.; Feng, F.Y.; Nguyen, H.G.; Reiter, R.E.; Rettig, M.B.; Okamoto, S.; et al. Assessment of 68Ga-PSMA-11 PET Accuracy in Localizing Recurrent Prostate Cancer: A Prospective Single-Arm Clinical Trial. *JAMA Oncol.* **2019**, *5*, 856–863. [CrossRef]
57. Okamoto, S.; Thieme, A.; Allmann, J.; D'Alessandria, C.; Maurer, T.; Retz, M.; Tauber, R.; Heck, M.M.; Wester, H.-J.; Tamaki, N.; et al. Radiation Dosimetry for 177 Lu-PSMA I&T in Metastatic Castration-Resistant Prostate Cancer: Absorbed Dose in Normal Organs and Tumor Lesions. *J. Nucl. Med.* **2017**, *58*, 445–450. [CrossRef]
58. Violet, J.; Sandhu, S.; Iravani, A.; Ferdinandus, J.; Thang, S.-P.; Kong, G.; Kumar, A.R.; Akhurst, T.; Pattison, D.A.; Beaulieu, A.; et al. Long-Term Follow-up and Outcomes of Retreatment in an Expanded 50-Patient Single-Center Phase II Prospective Trial of 177Lu-PSMA-617 Theranostics in Metastatic Castration-Resistant Prostate Cancer. *J. Nucl. Med.* **2020**, *61*, 857–865. [CrossRef]
59. Rahbar, K.; Ahmadzadehfar, H.; Kratochwil, C.; Haberkorn, U.; Schäfers, M.; Essler, M.; Baum, R.P.; Kulkarni, H.R.; Schmidt, M.; Drzezga, A.; et al. German Multicenter Study Investigating 177 Lu-PSMA-617 Radioligand Therapy in Advanced Prostate Cancer Patients. *J. Nucl. Med. Off. Publ. Soc. Nucl. Med.* **2017**, *58*, 85–90. [CrossRef]
60. Ahmadzadehfar, H.; Wegen, S.; Yordanova, A.; Fimmers, R.; Kürpig, S.; Eppard, E.; Wei, X.; Schlenkhoff, C.; Hauser, S.; Essler, M. Overall survival and response pattern of castration-resistant metastatic prostate cancer to multiple cycles of radioligand therapy using [177Lu]Lu-PSMA-617. *Eur. J. Nucl. Med. Mol. Imaging* **2017**, *44*, 1448–1454. [CrossRef]

61. Bräuer, A.; Grubert, L.S.; Roll, W.; Schrader, A.J.; Schäfers, M.; Bögemann, M.; Rahbar, K. 177Lu-PSMA-617 radioligand therapy and outcome in patients with metastasized castration-resistant prostate cancer. *Eur. J. Nucl. Med. Mol. Imaging* **2017**, *44*, 1663–1670. [CrossRef] [PubMed]
62. Baum, R.P.; Kulkarni, H.R.; Schuchardt, C.; Singh, A.; Wirtz, M.; Wiessalla, S.; Schottelius, M.; Mueller, D.; Klette, I.; Wester, H.-J. 177Lu-Labeled Prostate-Specific Membrane Antigen Radioligand Therapy of Metastatic Castration-Resistant Prostate Cancer: Safety and Efficacy. *J. Nucl. Med.* **2016**, *57*, 1006–1013. [CrossRef] [PubMed]
63. Kratochwil, C.; Bruchertseifer, F.; Rathke, H.; Hohenfellner, M.; Giesel, F.L.; Haberkorn, U.; Morgenstern, A. Targeted $\alpha$-Therapy of Metastatic Castration-Resistant Prostate Cancer with 225Ac-PSMA-617: Swimmer-Plot Analysis Suggests Efficacy Regarding Duration of Tumor Control. *J. Nucl. Med.* **2018**, *59*, 795–802. [CrossRef] [PubMed]
64. Yadav, M.P.; Ballal, S.; Sahoo, R.K.; Tripathi, M.; Seth, A.; Bal, C. Efficacy and safety of 225Ac-PSMA-617 targeted alpha therapy in metastatic castration-resistant Prostate Cancer patients. *Theranostics* **2020**, *10*, 9364–9377. [CrossRef] [PubMed]
65. Zacherl, M.J.; Gildehaus, F.J.; Mittlmeier, L.; Boening, G.; Gosewisch, A.; Wenter, V.; Schmidt-Hegemann, N.-S.; Belka, C.; Kretschmer, A.; Casuscelli, J.; et al. First clinical results for PSMA targeted alpha therapy using 225Ac-PSMA-I&T in advanced mCRPC patients. *J. Nucl. Med.* **2020**. [CrossRef]
66. Ducreux, M.; Cuhna, A.S.; Caramella, C.; Hollebecque, A.; Burtin, P.C.; Goéré, D.; Seufferlein, T.; Haustermans, K.; Van Laethem, J.L.; Conroy, T.; et al. Cancer of the pancreas: ESMO Clinical Practice Guidelines for diagnosis, treatment and follow-up. *Ann. Oncol.* **2015**, *26*, v56–v68. [CrossRef]
67. Körner, M.; Waser, B.; Strobel, O.; Büchler, M.W.; Reubi, J.C. Neurotensin receptors in pancreatic ductal carcinomas. *EJNMMI Res.* **2015**, *5*, 17. [CrossRef]
68. Schulz, J.; Rohracker, M.; Stiebler, M.; Goldschmidt, J.; Stöber, F.; Noriega, M.; Pethe, A.; Lukas, M.; Osterkamp, F.; Reineke, U.; et al. Proof of therapeutic efficacy of a novel 177Lu-labeled neurotensin receptor 1 antagonist in a colon carcinoma xenograft model. *J. Nucl. Med.* **2017**, *58*, 936–941. [CrossRef]
69. Baum, R.P.; Singh, A.; Schuchardt, C.; Kulkarni, H.R.; Klette, I.; Wiessalla, S.; Osterkamp, F.; Reineke, U.; Smerling, C. $^{177}$Lu-3BP-227 for Neurotensin Receptor 1–Targeted Therapy of Metastatic Pancreatic Adenocarcinoma: First Clinical Results. *J. Nucl. Med.* **2018**, *59*, 809–814. [CrossRef]
70. Chiesa, C.; Sjogreen Gleisner, K.; Flux, G.; Gear, J.; Walrand, S.; Bacher, K.; Eberlein, U.; Visser, E.P.; Chouin, N.; Ljungberg, M.; et al. The conflict between treatment optimization and registration of radiopharmaceuticals with fixed activity posology in oncological nuclear medicine therapy. *Eur. J. Nucl. Med. Mol. Imaging* **2017**, 1783–1786. [CrossRef] [PubMed]
71. Svensson, J.; Hagmarker, L.; Magnander, T.; Wängberg, B.; Bernhardt, P. Radiation exposure of the spleen during (177)Lu-DOTATATE treatment and its correlation with haematological toxicity and spleen volume. *EJNMMI Phys.* **2016**, *3*, 15. [CrossRef] [PubMed]
72. Bergsma, H.; Konijnenberg, M.W.; Kam, B.L.; Teunissen, J.J.; Kooij, P.P.; de Herder, W.W.; Franssen, G.J.; van Eijck, C.H.; Krenning, E.P.; Kwekkeboom, D.J.; et al. Subacute haematotoxicity after PRRT with (177)Lu-DOTA-octreotate: Prognostic factors, incidence and course. *Eur. J. Nucl. Med. Mol. Imaging* **2016**, *43*, 453–463. [CrossRef] [PubMed]
73. Van den Hoven, A.F.; Rosenbaum, C.E.; Elias, S.G.; de Jong, H.W.; Koopman, M.; Verkooijen, H.M.; Alavi, A.; van den Bosch, M.A.; Lam, M.G. Insights into the Dose-Response Relationship of Radioembolization with Resin 90Y-Microspheres: A Prospective Cohort Study in Patients with Colorectal Cancer Liver Metastases. *J. Nucl. Med.* **2016**, *57*, 1014–1019. [CrossRef] [PubMed]
74. Garske-Román, U.; Sandström, M.; Fröss Baron, K.; Lundin, L.; Hellman, P.; Welin, S.; Johansson, S.; Khan, T.; Lundqvist, H.; Eriksson, B.; et al. Prospective observational study of $^{177}$Lu-DOTA-octreotate therapy in 200 patients with advanced metastasized neuroendocrine tumours (NETs): Feasibility and impact of a dosimetry-guided study protocol on outcome and toxicity. *Eur. J. Nucl. Med. Mol. Imaging* **2018**, *45*, 970–988. [CrossRef] [PubMed]