Best Practice & Research Clinical Rheumatology 30 (2016) 802–825

Contents lists available at ScienceDirect

Best Practice & Research Clinical Rheumatology

journal homepage: www.elsevierhealth.com/berh

2

The eye and inflammatory rheumatic diseases: The eye and rheumatoid arthritis, ankylosing spondylitis, psoriatic arthritis

Philip Ian Murray*, Saaeha Rauz

Academic Unit of Ophthalmology, Institute of Inflammation and Ageing, University of Birmingham, Birmingham and Midland Eye Centre, Birmingham B18 7QU, UK

Keywords:
Dry eye
Peripheral ulcerative keratitis
Scleritis
Anterior uveitis

A B S T R A C T

Rheumatoid arthritis, ankylosing spondylitis and psoriatic arthritis are associated with potentially sight-threatening inflammatory eye disease. Although the ocular manifestations associated with ankylosing spondylitis and psoriatic arthritis are similar, such as anterior uveitis, this differs from rheumatoid arthritis where dry eye, peripheral ulcerative keratitis and scleritis are the major ocular complications. Apart from causing sight loss, these conditions are painful, debilitating, often recurrent or chronic and may require long-term therapy. Treatments such as ocular lubricant, topical corticosteroid, systemic corticosteroid and systemic immunosuppression are often similar for the underlying systemic disease. Yet for the treatment of the ocular complications, the evidence base is weak. Close collaboration with a rheumatologist is often essential, particularly in the management of these patients.
© 2016 Elsevier Ltd. All rights reserved.

The eye and rheumatoid arthritis

Ocular complications of rheumatoid arthritis

The ocular complications of rheumatoid arthritis (RA) more commonly affect the front (anterior segment) than the back of the eye (posterior segment) [1]. Anterior segment disease includes dry eye,

* Corresponding author. Tel.: +44 121 507 6851; fax: +44 121 507 6853.
E-mail address: p.i.murray@bham.ac.uk (P.I. Murray).

http://dx.doi.org/10.1016/j.berh.2016.10.007
1521-6942/© 2016 Elsevier Ltd. All rights reserved.

Janssen Biotech, Inc.
Exhibit 2088
Accord v. Janssen
IPR2026-00256
Ex. 2088-001

peripheral ulcerative keratitis (PUK), episcleritis and anterior scleritis [2]. Posterior segment disease includes posterior scleritis and rarely a retinal vasculitis [3].

What is the most frequent ocular manifestation of RA?

The most frequent ocular manifestation in patients with RA is dry eye disease (DED, keratoconjunctivitis sicca) with up to 45% of patients having clinical features consistent with dry eye and 38% of patients being symptomatic [4]. It is defined as a multifactorial disease of the tears and ocular surface that results in symptoms of discomfort, visual disturbance and tear film instability with potential damage to the ocular surface, accompanied by increased osmolarity of the tears and inflammation of the ocular surface [5]. A vicious cycle of hyperosmolarity and chronic inflammation leads to increased friction and eventual ocular surface damage. The ocular surface is a highly intricate and specialised mucosa, with the epithelium running from the meibomian gland orifices into the meibomian glands, along the tarsal conjunctival epithelium (on the back surface of the eyelids), the forniceal conjunctiva (deep in the natural gutter between the eyelid and eye ball), the epithelium of the lacrimal gland and the bulbar conjunctival epithelium (overlying the eyeball), merging into the corneal epithelium at the limbus. Each specialised layer of the ocular surface contributes to a component of the tear film. The lacrimal and accessory glands produce the central nutritive aqueous component; the Meibomian glands, the oily outer lipid that provides tear film stability; and the conjunctival goblet cells, the inner 'surfactant' mucin that primarily improves the wettability of the ocular surface. The eyelids and lashes provide fundamental protection through the blink mechanism, as well as wiping away debris from the ocular surface and replenishing surface with a fresh layer of tears. All components of the ocular surface are linked functionally by the key 'systems' (neural, vascular, endocrinological and immunological) that are vital for ocular surface homoeostasis and defence [4]. The ocular surface system has a unique function to maintain optical clarity of ocular tissues through provision of protective mechanisms, resisting trauma and pathogens. Deficiency of any component of the ocular surface system may lead to DED that is classically defined as aqueous deficient or evaporative. Both forms are prevalent in RA where the majority of patients have mixed disease. Risk factors include older age, female gender, reduced androgen levels, use of exogenous oestrogens, imbalance in the dietary intake of omega-3 and omega-6 fatty acids and the use of antidepressants.

What is the impact of dry eyes on a patient's life?

DED is a significant global public health problem and there is yet no effective treatment [6]. Symptoms are variable and include itching or burning, sensation of a foreign object in the eye, crusty material clinging to the eyelashes, light sensitivity, intermittent blurred vision and complaint of scant or broken eyelashes. Visual disturbances lead to problems associated with activities such as reading, computer use, cooking, navigating stairs, and driving a car, together with lower professional work performance, role limitations, lower vitality and poorer general health [7]. Several studies have indicated that the health-related quality of life (HRQoL) burden increases with the severity of disease and 2 utility assessment studies have shown that utilities for severe DED are similar to those reported for renal dialysis and severe angina [8,9]. The impact of DED on mental health is also apparent. In a study evaluating 7207 patients with dry eyes correcting for factors associated with systemic disease, adjusted odds ratio for DED and anxiety was found to be 2.8 (95% confidence interval [CI] 2.6–3.0) and for depression 2.9 (95% CI 2.7–3.1) [10]. In a meta-analysis, dry eye patients with rheumatic disease were more likely to suffer from depression [11].

Objective symptomatology is graded according to a range of patient reported outcome utility instruments specific for ocular surface disease, dry eye diagnosis, epidemiological studies and clinical trials. The questionnaires interrogate disease in different ways; for example, diagnosis alone, to identify precipitating factors or to quantify the impact on quality of life. The time taken to administer a questionnaire and mode of administration (self, interviewer and phone) influence the choice of questionnaire. The most commonly used in an ophthalmology setting is the Ocular Surface Disease Index measuring the severity of DED in the form of a 12-item questionnaire subdivided into 3 domains (visual function (6), ocular symptoms (3), environmental triggers (3)) providing a scoring algorithm

ranging from 100 for complete disability to 0 for no disability (Table 1). By contrast, The National Eye Institute Visual Functioning Questionnaire-25 is a generic tool that compares vision-targeted HRQoL applicable to multiple ocular conditions, offering 25 items that examine the frequency and severity of a symptom and how this affects activities of daily living within multiple domains (near vision, general health, social problems, distance vision). Ocular symptomatology scoring is also integrated into rheumatology scoring systems most commonly for primary Sjögren's syndrome (SS) such as Profile of Fatigue and Discomfort, Sicca Symptoms Inventory and European League Against Rheumatism Sjögren's Syndrome Patient Reported Index, correlating with disease activity or damage scores (SS Disease Activity Index, SS Clinical Activity Index, EULAR SS Disease Activity Index). There are no RA activity and damage instruments that incorporate ocular symptoms or vision-related quality of life.

What are the signs of DED?

The cardinal signs of DED are ocular surface (conjunctiva and cornea) staining, reduced Schirmer's test score, increased tear film instability, accumulation of tear film debris or mucus clumping with or without filamentary keratitis, conjunctival hyperaemia, increased osmolarity and features of ocular surface failure (meibomian gland dysfunction, trichiasis, ulceration, conjunctival scarring) [12]. Grading and staging of disease facilitate therapeutic targeting. Nevertheless, there are a significant number of patients who have disproportionate symptomatology to the clinical signs that is thought to occur secondary to nociceptive sensory receptor hypersensitivity [13].

Schirmer's test

Schirmer's test I without anaesthetic is the rheumatology 'Gold Standard' for quantitative measurement of tear production. Filter paper strips (5 × 35 mm Whatman grade No 1) bent at the notch are hooked over the lower eyelid midway between the middle and outer third of the lower lid margin with the patient asked to gently close their eyes throughout the duration of the test in an *unanesthetised* eye.

Table 1
Ocular surface disease index.

Circle the number in the box that best represents each answer						
Have you experienced any of the following *during the last week*?	All of the time	Most of the time	Half of the time	Some of the time	None of the time	
1. Eyes that are sensitive to light?	4	3	2	1	0	
2. Eyes that feel gritty?	4	3	2	1	0	
3. Painful or sore eyes?	4	3	2	1	0	
4. Blurred vision?	4	3	2	1	0	
5. Poor vision?	4	3	2	1	0	
Subtotal score for answers 1 to 5. **A**=						
Have problems with your eyes limited you in performing any of the following *during the last week*?	**All of the time**	**Most of the time**	**Half of the time**	**Some of the time**	**None of the time**	**N/A**
6. Reading?	4	3	2	1	0	N/A
7. Driving at night?	4	3	2	1	0	N/A
8. Working with a computer or bank machine (ATM)	4	3	2	1	0	N/A
10. Watching TV?	4	3	2	1	0	N/A
Subtotal score for answers 6 to 10. **B**=						
Have your eyes felt uncomfortable in any of the following situations *during the last week*?	**All of the time**	**Most of the time**	**Half of the time**	**Some of the time**	**None of the time**	**N/A**
10. Windy conditions?	4	3	2	1	0	N/A
11. Places or areas with low humidity (very dry)?	4	3	2	1	0	N/A
12. Areas that are air conditioned	4	3	2	1	0	N/A
Subtotal score for answers 10 to 12. **C**=						
Add subtotals A, B and C to obtain D.						
Total number of questions answered (do not include questions answered N/A)						
OSDI = [(sum of scores (D)) × 25]/(number of questions answered)						

The strips are read at 5 min with a cut-off of ≤5.5 mm considered to be abnormal. Schirmer's test II *with anaesthetic* is conducted in the same way but after the instillation of anaesthetic eye drops and estimates basal secretion of tears. Schirmer's test II involves induction and measurement of 'reflex' secretion by anaesthetising the eye with topical anaesthetic and irritating the nasal mucosa with a cotton tipped applicator or smelling an irritant substance. Neither are routinely used for DED assessment.

Ocular surface staining

Several scoring systems have been proposed to quantify ocular surface staining in DED. The most commonly used partition the exposed ocular surface into 3 components: nasal and temporal conjunctiva and the cornea. The clinically used vital dyes that grade ocular surface damage are lissamine green and fluorescein. Lissamine green identifies devitalised epithelial cells present on an intact ocular surface, whereas fluorescein stains epithelial defects. In the Oxford staining schema, the clinician is provided with a series of panels labelled A–E, in order of increasing staining severity, reproducing the staining patterns encountered in DED. Each ocular surface component is scored of 5 giving a total maximal score of 15. The van Bijsterveld (VB) schema is commonly used in grading ocular surface dryness in rheumatic disorders. This system evaluates the intensity of lissamine green in the 2 exposed conjunctival zones and cornea scored to a maximum of 3 for each zone with a cumulative maximal score of 9. The ocular staining score (OSS) is a more elaborate system gaining acceptance for scoring severity of ocular dryness in SS and uses both lissamine and fluorescein vital dyes. Lissamine green is reserved for evaluating the conjunctival staining score and fluorescein for corneal staining with each of the 3 zones scored between 0 and 3. Confluent and pupillary area fluorescein staining together with the presence of filaments add weight to the corneal score resulting in a maximal OSS of 12 for each eye [14].

Tear film instability

The tear film breakup time (TFBUT) measures the stability of the tear film and how quickly this evaporates. It is defined as the interval between the last complete blink and the first appearance of a dry spot or disruption in the tear film. It is performed after instillation of a drop of 2% sodium fluorescein onto the bulbar conjunctiva and using a Wratten 12 yellow filter on a standard slit-lamp magnification (×10); the duration of the tear film integrity over the cornea is observed. A TFBUT ≥10 s is considered to be normal, and ≤5 s is reduced.

Hyperosmolarity

Osmolarity tear analysis is determined by lab-on-a-chip technology using a nanolitre collecting tool providing an absolute numerical measurement with a mean average of >308 mOsm/L generally indicative of DED. Because of the large overlap between the normal distribution curves between those with and without dry eye, longitudinal follow-up of patients is essential to monitor changes. There are many patients who fall in the normal range but have significant symptomatology and staining pattern and there are those with severe DED when it is not consistently possible to obtain an osmolarity reading with the current technologies available.

Which treatments are used for DED and when?

A hierarchy of symptoms and clinical features provide dry eye severity scales that inform potential therapeutic strategies based on recommendations from the Dry Eye Workshop [9] and Meibomian Gland Dysfunction Workshop (Table 2) [15]. Interventions can broadly be classified into environmental optimisation, treatment of meibomian gland dysfunction, tear supplementation, retention and stimulation, use of anti-inflammatories and specialised interventions. Treatments should be tailored to patient's needs, severity of dry eye and symptoms, and frequently, the optimal regime is based on patient's preference and tolerability.

Strategies for removing desiccating stress are cardinal to the management of DED. Avoidance of irritating substances including cigarette smoke, pollution or peri-ocular cosmetics and low humidity atmospheres such as central heated houses, aeroplanes and windy locations is vital. Drugs that precipitate dryness should be avoided (antihistamines, antidepressants) as well as limiting activities that

Table 2
Dry eye management summary (based on the International Dry Eye Workshop (DEWS) and the Meibomian Gland Dysfunction Workshop).[a]

Level 1: mild dry eye	Level 2: moderate dry eye	Level 3/4: severe dry eye (ophthalmology only)

Features
TFBUT: >9 s
Staining: VB score = 0 to 3, OSS = 0
Management
• Educational and environmental
• Lubricants
  • Hypromellose (preserved)
  • Carbomer gels (preserved)
  • Carmellose 0.5% (non-preserved)
• Ointments
• Warm compresses, meibomian gland massage and lid hygiene
• Liposomal sprays available over the counter to replace tear film oil layer
	Features
	TFBUT: 5–9 s
	Staining: VB score = 4 to 5, OSS = 1–6
	***As for mild plus*:**
	• Moisture chamber spectacles
	• Lubricants (non-preserved)
	  • Carmellose 1% eye
	  • Low concentration hydroxypropylguar eye drops
	  • Sodium hyaluronate eye drops 0.1%–0.18%
	• For corneal inflammation, consider prednisolone 0.5% non-preserved 2–3 times daily (ophthalmology only)
	• For blepharitis, consider metallomatrix proteinase inhibitors, e.g., doxycycline 50 mg once daily (ophthalmology only)
	• Punctal plugging—punctal or intracanalicular plugs (ophthalmology only)
	• Secretagogues
	  -Oral pilocarpine max 5 mg 4 × per day (start with 2.5 mg od and build up)
	  -Pilocarpine 4% (3 drops = 5 mg) for those who are unable to swallow (palliative care pathway)
		Features
		TFBUT: <5 s
		Staining: VB score = 7–12, OSS = 5–12
		***As for moderate plus*:**
		• Lubricants (non-preserved)
		  • High concentration hyaluronates 0.2%–0.4%
		  • Hyaluronates with xanthan gum
		  • Soybean with phospholipids
		• Mucolytics for filaments e.g. acetylcysteine
		• Higher strength topical steroids for short-term use e.g., dexamethasone 0.1%
		• Cyclosporin containing drops or ointment
		• Nutritional tear substitutes
		  - Autologous or allogeneic serum eye drops (available via specialist commissioned centres only)
		• Permanent punctal occlusion via cautery of all 4 puncta
		• Periorbital botulinum toxin for significant blepharospasm
		• 'Bandage' or therapeutic contact lenses
		• Amniotic membrane overlay or corneal grafting for significant corneal ulceration and corneal melt or perforation

OSS, ocular surface staining score; TFBUT, tear film breakup time; VB, van Bijsterveld Schema.
[a] Adapted from The British Society for Rheumatology (BSR) and British Health Professionals in Rheumatology (BHPR) Guideline for the Management of Adults with Primary Sjögren's Syndrome 2016 (in press).

promote tear film instability (prolonged reading or computer work). Increasing humidity with a cool mist humidifier is recommended and the wearing of moisture chamber glasses created by using a soft, compressible eye cup or gasket affixed to the frame. Dietary modifications by increasing omega-3 fatty acids (eicosapentaenoic acid (EPA)) or linoleic acid and gamma-linolenic acid (flaxseed oil, that is, metabolised to EPA before entering the anti-inflammatory cascade) has been shown to have clinical benefit by inhibiting proinflammatory lipid mediators (prostaglandin E2 and leukotriene B4) and blocking the production of IL-1 and anti-tumour necrosis factor-α (TNF-α). The benefit of omega 7 (sea buckthorn oil) supplementation has also been observed.

Stagnated meibum oils, hypercolonisation of the lid margin by staphylococcal species, chronic inflammation, lid margin hyperkeratinisation, cicatrisation and irreversible blockage of meibomian glands may be controlled by, warm glandular expression, lid margin hygiene, topical emollient lubrication, oral low dose tetracyclines (used as anti-inflammatories) and antitopical lubricant and inflammatory therapy. Effective lid margin hygiene is essential requiring warm compresses for up to 30 min twice daily (using warm flannel or proprietary devices) to increase the fluidity of the stagnant oils within the glands easing expression when the lids are massaged by a firm stroking motion towards the lid margins. Expressed matter should be cleansed lightly with a cotton tipped applicator moistened with boiled cooled water or with proprietary lid wipes. In the presence of extensive glandular and duct atrophy associated with thickened and indurated lids, cicatrisation and negligible excreta, response may only be partial or even refractory.

Tear supplementation is designed primarily to reduce biomechanical trauma caused by dry eye states and dilute toxic mediators on the surface of the eye. The supplements do not replace the intricate composition of the tear film and therefore have limited patient satisfaction. For mild DED, preserved eye drops may be used but dosing is critical. If dosing is more than 4–6 drops per day of the total number of eye drops, non-preserved tear supplementation and those not containing benzalkonium chloride (BAK) should be administered into the eye [16]. BAK damages the ocular surface epithelium causing chronic ocular surface inflammation and paradoxical aggravation of disease. Carboxymethylcellulose containing compounds have higher ocular surface retention and facilitate epithelial proliferation [17] and those with sodium hyaluronate glycosaminoglycans (CD44 ligand) facilitate wound healing, reduce inflammation and have longer lasting lubrication. Tear retention can be achieved not only by wearing moisture chamber spectacles conserving the tear film meniscus on the ocular surface, but also by punctal occlusion with either punctal plugs or punctal cautery. Punctal occlusion can increase proinflammatory cytokine expression so timing of occlusion is critical [18]. Secretagogues have been used with variable success in DED. Oral cholinergic agonists, pilocarpine, reportedly improve symptoms and possibly increase goblet cell density in the conjunctiva [19]. Use is frequently limited by intolerable systemic cholinergic symptoms. Alternative use of topical pilocarpine 4% eye drops administered orally has been used with variable effect. Approximately 3 drops provide an equivalent dose of 5 mg (Table 2).

Topical corticosteroids remain the mainstay to targeting the inflammatory component DED (prednisolone 0.5%, dexamethasone 0.1%) but ophthalmological surveillance is mandatory because of the risk of steroid-induced raised intraocular pressure (IOP) causing permanent optic neuropathy or cataract formation. The anti-metalloproteinase properties of long-term oral tetracyclines (such as doxycycline 50 mg once daily for a minimum of 3 months or longer term maintenance) provide anti-inflammatory (anti-TNF-α, IL-1) treatment. Tetracyclines are additionally antibacterial and anti-angiogenic thus conducive to promoting an optimal ocular surface microenvironment in DED states. The introduction of topical calcineurin inhibitors (cyclosporin A—Restasis, Ikervis) has also been found to improve the clinical signs of dry eye together with subjective improvement in symptoms in patients who are refractory to ocular lubricants alone. These agents can only be initiated by an ophthalmologist and are reported to increase goblet cell density and reduce lymphocyte activation markers, while sparing the local adverse effects of topical corticosteroids. Other specialist interventions include the use of contact lenses that protect and hydrate the ocular surface but introduce a risk of corneal neovascularisation or sight-threatening corneal infection. The contact lens material enables high oxygen permeability, extended overnight wear and/or continuous use (maximum 3 months). Rigid gas permeable scleral-supported contact lenses with no corneal touch create a corneal reservoir behind the lens to enable capture of tears and therapeutically applied agents to be retained within reservoir.

In severe cases or those with exposure, resistant filamentary keratitis taping the lids or surgical tarsorrhaphy may be required or amniotic membrane transplant to the corneal surface. Salivary gland autotransplantation is reserved only for severe clinical states where the mouth is not excessively dry. The only true biological tear substitutes are serum eye drops (either autologous or allogeneic). The epitheliotrophic potential of serum drops has been shown to be beneficial because of the similarities of the large number of biological substances that are present in tears [20].

Patients whose symptoms disproportionate to clinical signs may benefit from pain management strategies including tramadol, gabapentin and pregabalin [13].

How common is PUK in patients with RA?

PUK is a rare manifestation of RA with a reported frequency of 3 per million population per year [21]. It is characterised by a progressive thinning of the peripheral cornea secondary to immune complex disease accompanied by complement activation, release of collagenases and proteases in the region of the limbal vasculature and avascular cornea [22]. This leads to keratolysis that may be with or without ulceration. The triggers for PUK are largely unknown but are broadly categorised as infectious or non-infectious, the latter due mainly to underlying systemic disease or trauma (such as surgical intervention) with the progression of disease compounded by the presence of DED. Patients may clinically have quiescent eyes and present incidentally with gradual reduction of vision secondary to

circumcorneal keratolysis with subsequent corneal distortion or more rarely with a painful eye, severe inflammation and/or corneal perforation. This is frequently independent of systemic disease marker activity although a single study has indicated that ocular manifestations in RA may correlate with anti-cyclic citrullinated peptide antibodies but only 4 of a total 77 patients had PUK [23]. An underlying infective cause or secondary infection must be excluded and treated before instituting immunosuppressive therapy and the classical features (red eye, corneal abscess) masked because of concomitant immunosuppression for the systemic component of disease. Mortality after the diagnosis of PUK in 34 patients has been reported as high as 53% compared with patients with PUK on immunosuppression (5%) [24]. In a more recent study evaluating a 10-year single centre review of 70 patients with PUK [25], subgroup comparison of 46 patients with RA was made with a historic published cohort from the same centre 10 years earlier [26], showing mortality rates of 15% and 28%, respectively. In addition, there was significant improvement in visual outcomes (VA vs than 6/60, 3.4% vs 34%), fewer perforations (14% vs 65%) and fewer enucleations (0% vs 10%).

How is PUK treated?

Exclude and treat infection

An underlying infective cause or secondary infection must be excluded and treated before instituting immunosuppressive therapy and the classical features (red eye, corneal abscess) may be masked due to concomitant immunosuppression for the systemic component of disease or topical corticosteroids or cyclosporin for dry eye. Corneal scraping for microscopy, culture and antibiotic sensitivity of cultured organisms is essential. Corneal scrapes have the added advantage of debriding necrotic tissue and enhancing topical therapy penetration. Because of the small inoculum size, ocular specimens are inoculated directly onto the culture media to reduce false negatives. Some of the pathogens isolated from ocular infections particularly in patients who are immunosuppressed are considered to be normal flora by non-ocular microbiologists, so it is important for ophthalmologists to liaise closely with the laboratory. The clinical course is broadly categorised into sterilisation, healing and remodelling phases. This is a continuum with cut-offs being dependent on factors related to virulence of underlying organisms (if present) and patient factors (immunosuppression, severity of DED, etc.).

Control inflammation and promote healing

Generally, sterilisation is achieved with intensive (day and night, hourly) broad spectrum antibiotics together with 'healing' strategies to optimise the ocular surface including doxycycline (a metallomatrix proteinase inhibitor), ascorbate (a free radical scavenger) and lubricants to promote epithelial wound closure. Ancillary anti-inflammatory/antiscarring treatment in the form of topical glucocorticoids is usually commenced around 2–3 days when sterilisation is likely to be complete. With pending perforations of the cornea or actual perforations, rapid control of inflammation is achieved through implementing rescue therapy with pulsed intravenous glucocorticoid given early (usually at 24 h) followed by high dose oral glucocorticoids in conjunction with steroid-sparing antiproliferative agents (e.g., mycophenolate mofetil, methotrexate and azathioprine) or T-cell inhibitors (e.g., cyclosporin, tacrolimus) if the patient is not already on these Disease-modifying antirheumatic drugs (DMARDs). If patients are on existing immunosuppression, a step-up in dose or a switch to more potent therapy should be considered. For severely active necrotising disease associated with scleritis, pulsed oral or pulsed intravenous cyclophosphamide therapy should be considered [24]. More recently, biological therapies (e.g., TNF-α family, anti CD-20 (rituximab)) have been introduced for both induction of remission and maintenance but there are no randomised controlled trials to support use (see scleritis).

How are corneal perforations sealed?

Corneal perforation is an ophthalmic surgical emergency. The primary aim is to seal the perforation and prevent an endophthalmitis that may lead to loss of eye. In the presence of a corneal perforation, holes less than 2 mm in diameter, tissue adhesives using higher cyanoacryalate esters (enbucrilate, N-Butyl-2 cyanoacrylate $C_8H_{11}NO_2$) that polymerise on contact with moisture on the ocular surface, together with a 4-mm polythene patch and a therapeutic contact lens (applied to reduce the discomfort associated with the irregular surface of the polymerised glue) are used. A series of glue

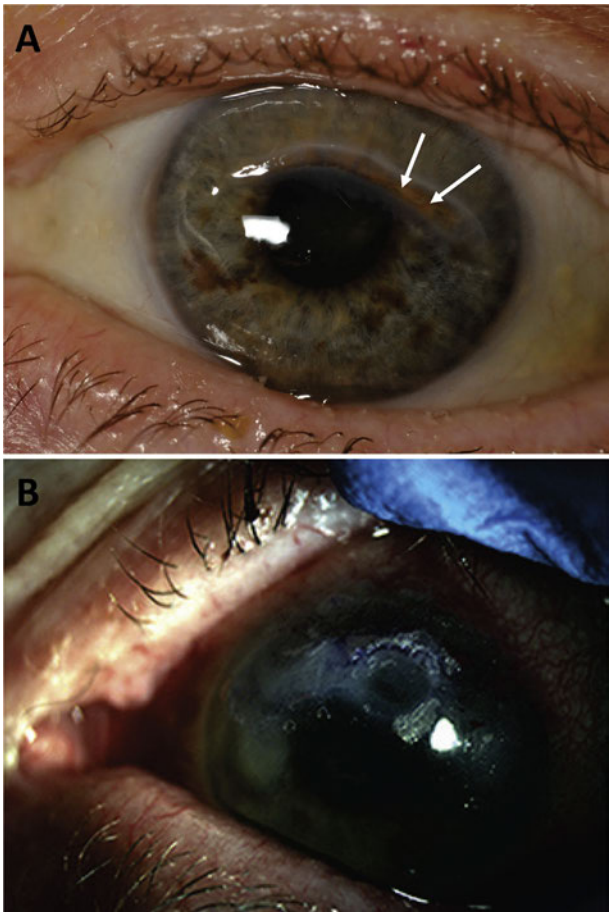

Fig. 1. (a) PUK with corneal perforation and iris drawn to the wound (arrows), (b) same patient with a series of enbucrilate glue and polythene patches sealing the melt.

patches are frequently required for more arcuate lesions. Larger holes are sealed with layered amniotic membrane glued with fibrin and sutured to the cornea (Fig. 1). If glue or amniotic membrane fails to seal a perforation in an acute situation, ocular surface reconstructive surgery with lamellar or full thickness keratoplasty (allogeneic corneal transplantation) with amniotic membrane overlay with or without a tarsorraphy is undertaken combined with supplementary intravenous steroids to reduce surgically induced aggravation of disease with remission induced with pulsed cyclophosphamide.

Practice points

- Dry eye symptoms frequently outweigh the signs due to neuropathic pain.
- There is no consistently effective treatment for DED.
- Morbidity from DED can be as debilitating as moderate angina.
- Necrotising PUK may occur in the absence of raised inflammatory markers of RA.

Research agenda

- A synthetic tear substitute that replicates the highly intricate structure and biological properties of the tear film is required.
- Development of RA activity and damage scores that incorporates ocular manifestations of disease.
- Randomised controlled trials for the use of biologics and biosimilars in the management of severe necrotising PUK.

What is scleritis?

Scleritis is an uncommon but extremely painful and potentially blinding ocular condition and forms part of the differential diagnosis of a red eye. It is a heterogeneous group of diseases defined as inflammation of the opaque outer eye wall or sclera [28]. It may be due to local or systemic infections or immune-mediated diseases. It is associated with systemic disease in around 40% of patients, most of which are cases of a rheumatic disease, such as RA, granulomatosis with polyangiitis, relapsing polychondritis, systemic lupus erythematosus (SLE), sarcoidosis, polyarteritis nodosa, inflammatory bowel disease, psoriatic arthritis (PsA), ankylosing spondylitis (AS) and gout [29]. It is the most common in middle-aged women and is bilateral in 50% of cases, but both eyes may not be affected at the same time [30]. It often involves adjacent structures such as the episclera, cornea and uvea. Vision loss occurs in about 10% of patients and more likely to occur with severe disease that is not adequately treated. Scleritis occurs in 1%–6% of patients with RA, and in up to 14% of patients with rheumatoid vasculitis [29–31]. It is classified according to location—anterior 90% or posterior10%.

What are the ocular features of anterior scleritis?

Anterior scleritis can be further classified by (a) distribution: diffuse where there are areas of scleral oedema that typically occupy one or more quadrants of the anterior sclera (Fig. 2b) that may occasionally be mild and self-limiting and resolve without treatment, or nodular with one or more localised raised areas (nodules) of tender scleral thickening (Fig. 2c) that are commonly associated with corneal involvement, usually stromal keratitis and (b) destruction: necrotising or non-necrotising. The most severe type is necrotising anterior scleritis with inflammation. White avascular areas surrounded by injected oedematous sclera are present that may lead to scleral necrosis that can be a threat to the integrity of the globe. Necrotising disease may also occur without inflammation and of greatest concern is scleromalacia perforans (Fig. 3), in which scleral destruction is not typically painful and not associated with visible signs of inflammation [29,32]. Although the appearance can be dramatic with ectatic blue/black sclera, despite its name, globe perforation does not occur.

The scleral inflammation associated with RA may present with severe pain and can be diffuse or nodular, anterior or posterior, and necrotising or non-necrotising [32]. Necrotising anterior scleritis with inflammation seen in the context of RA is associated with increased mortality [24].

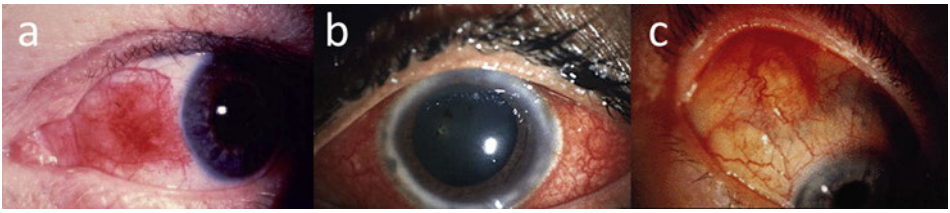

Fig. 2. (a) Episcleritis, (b) diffuse anterior scleritis and (c) nodular anterior scleritis.

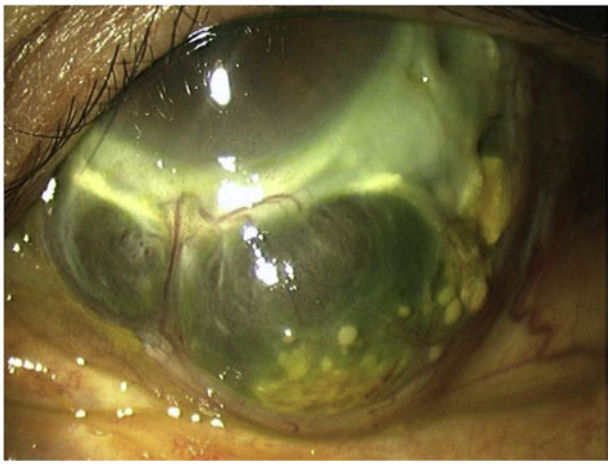

Fig. 3. Scleromalacia perforans with ectatic sclera.

The pain of scleritis is typically severe, boring in nature, retrobulbar (behind the eye) in location and may radiate to the forehead and temporal region. It may mimic the pain seen with temporal arteritis and trigeminal neuralgia. It can be so excruciating to wake the patient from sleep in the early hours of the morning. The globe may be very tender to touch and it is not uncommon for the patient to be holding their hand over the eye and temple and dread having the eye examined. The vision is often normal and there is no discharge (differentiating it from conjunctivitis that also causes an uncomfortable rather than painful eye) and no photophobia (unless there is an associated keratitis or anterior uveitis (AU)).

Active anterior scleritis gives an intense red/dark red appearance to the sclera. In some cases of inactive disease, there may be evidence of a bluish/black hue to the sclera implying scleral thinning from previous active scleritis (Fig. 4). The hue is a result of the underlying blue/black uveal tissue (choroid) showing through the translucent sclera. Up to 50% of patients with nodular scleritis show evidence of scleral thinning. The thinning can eventually result in high degrees of astigmatism because of a change in shape of the eyeball. This will cause reduced vision that will be very difficult to correct

Fig. 4. Scleral thinning with blue/black discolouration following necrotising anterior scleritis.

with spectacles. The degree of redness and scleral thinning is more easily appreciated under room light or in daylight than by the halogen light of the slit lamp.

If a patient complains of a very painful eye and the eye appears white, then a diagnosis of scleritis should still be considered. If there is reduced vision, this could be posterior scleritis (see below); alternatively, ask the patient to look down and gently lift their upper lid. There may be an area of intense redness at the top of the eye indicating anterior scleritis that was not obvious as it was hidden under the upper lid. Both may also be associated with a slight upper lid ptosis.

What are the ocular complications of anterior scleritis?

The presence of an associated AU suggests advanced disease. Other complications include PUK, acute stromal keratitis, sclerosing keratitis, cataract, astigmatism, glaucoma and globe perforation. All of which could lead to devastating loss of vision.

What are the ocular features of posterior scleritis?

Posterior scleritis is uncommon but probably underdiagnosed. It is a potentially sight-threatening condition. It is associated with systemic disease (usually RA or a systemic vasculitis) in up to one-third of cases [33]. It may be overlooked on account of more obvious anterior scleral inflammation or because there is isolated posterior disease, and thus, the eye appears white (often despite severe symptoms). There is mild/severe deep pain (may be referred to brow or jaw), reduced vision and a hypermetropic shift (the thickened posterior sclera 'pushes' the retina forward and the eye becomes hypermetropic i.e., longsighted). It may be associated with lid oedema, proptosis, lid retraction, restricted ocular motility with diplopia, shallow anterior chamber, choroidal folds, annular choroidal detachment, exudative retinal detachments, macular oedema and optic disc oedema. Diagnosis (and response to therapy) may be assisted by B-scan ultrasonography with the measurement of scleral thickening (Fig. 5) and fluid in Tenon's space (T-sign).

What is the management of scleritis?

Treatment is undertaken in a stepwise approach [1]. Mild non-necrotising anterior scleritis may be managed with oral non-steroidal anti-inflammatory drugs (NSAIDs), in particular flurbiprofen [34], but necrotising disease nearly always requires systemic corticosteroid. Topical corticosteroids are often

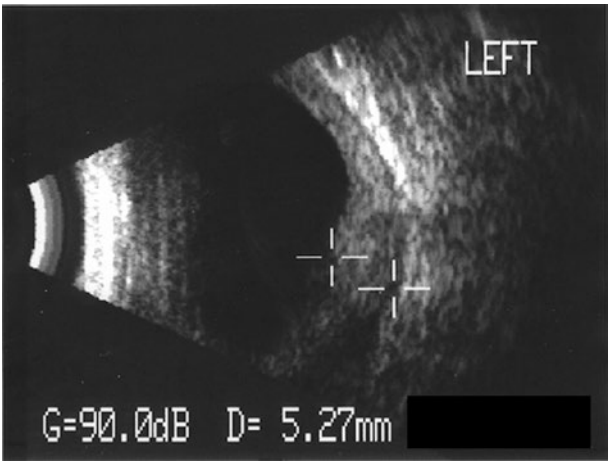

Fig. 5. B-scan ultrasound of left eye with thickened posterior sclera (between crosshairs) of 5.27 mm (normal posterior scleral thickness is 1.0–1.5 mm).

prescribed but as an adjunct to, rather than instead of, systemic therapy. Subconjunctival corticosteroid has been advocated [35] but it is not in mainstream use. Uncontrolled ocular inflammation warrants escalation of systemic treatment that should be coordinated with a rheumatologist. This is usually the addition of DMARDs, such as methotrexate, mycophenolate mofetil [36] and azathioprine. If this is insufficient to achieve remission then a biologic, such as an anti-TNF agent [37] or rituximab [38], is required [39]. Occasionally pulsed intravenous cyclophosphamide is used [27]. Sight-threatening inflammation, such as necrotising scleritis or corneal melt, requires urgent rescue therapy with pulsed intravenous methylprednisolone [31]. In our practice, we administer up to 3 pulses of 1000 mg methylprednisolone on consecutive days that is usually followed by commencing or increasing a course of oral corticosteroid (in addition to DMARD/biological therapy). Nevertheless, there is a lack of high-quality Randomised Controlled Trials (RCTs) for the treatment of scleritis. An improvement is judged by a reduction of pain and redness. Although several grading systems have been devised, there is no accepted one used in clinical practice [40,41]. Posterior scleritis is managed in a similar fashion. Despite appropriate therapy, scleritis is a relapsing condition.

What is the difference between episcleritis and anterior scleritis?

Episcleritis, a relatively common condition, is a benign, recurrent inflammation of the episclera (the layer of tissue between the sclera and conjunctiva). Being superficial, it is distinguished from deeper scleral inflammation in that it is much less painful and instillation of topical phenylephrine 2.5% causes blanching of the more superficial episcleral vessels but does not change the engorgement of deeper scleral vessels and thus differentiating between scleritis and episcleritis (Fig. 2a and b). It is more common in young women, often self-limiting, and may require little or no treatment. It is not usually associated with any systemic disease, although around 10% may have an underlying rheumatic disease, and may be seen in the context of RA [32,42]. When treatment is required, oral NSAIDs and ocular lubricants can be given, and in recalcitrant cases, a short course of topical corticosteroid. Prompt discrimination between episcleritis and scleritis is of therapeutic importance, as management, prognosis and complications differ for these diseases [43].

Practice points

- Scleritis is one of the most painful ocular conditions and may lead to blindness.
- Patients suspected of having scleritis should be referred urgently to an ophthalmologist.
- Most cases of scleritis require systemic therapy in the form of corticosteroid, with the possible addition of a DMARD and a biologic, although the evidence base for treatment is weak.

Research agenda

- Randomised controlled clinical trials for the treatment of anterior scleritis.

The eye and AS

What is the most common ophthalmic manifestation of AS?

The most common ophthalmic manifestation is acute anterior uveitis (AAU) that occurs in 40% of patients with AS with males more commonly affected than females, occurring typically in young adults between the ages of 20 and 40 years [44,45]. It is estimated that up to one-third of patients with AAU

have AS [46], and that 50% of patients presenting with AAU in the Western world are likely to be HLA-B27 positive [47].

Uveitis comprises a diverse group of conditions involving inflammation of the uveal tract (the iris, ciliary body and choroid) although it is frequently associated with inflammation of adjacent structures, such as the vitreous, retina and optic nerve. Most patients are aged between 20 and 50 years (although uveitis is well recognised in children when associated with juvenile idiopathic arthritis), can result in blindness and have important socioeconomic consequences [48]. Uveitis is classified anatomically into anterior, intermediate, pan and posterior uveitis with anterior the most common subtype [49]. AU was previous termed iritis or iridocyclitis. The onset can be sudden or insidious, the duration limited or persistent and the course acute, recurrent or chronic [49]. Uveitis can also be classified clinically into (a) infectious such as herpes simplex virus, varicella zoster virus, *Cytomegalovirus*, *Toxoplasma gondii*, *Mycobcaterium tuberculosis*, *Treponema pallidum* and *Candida albicans*; (b) non-infectious purely isolated to the eye(s) or part of an associated systemic disease, such as HLA-B27-related diseases, sarcoidosis, Behçet's disease, multiple sclerosis; and (c) masquerade where a condition such as a primary vitreoretinal B-cell lymphoma can mimic the signs of uveitis [50]. Although uveitis involving the back of the eye (intermediate, pan, posterior uveitis) is more likely to cause loss of vision, there are a small percentage of eyes in patients with AS whose AU runs an intractable course unresponsive to therapy leading to blindness. Verhagen et al. reported that 20/212 (9%) of patients became permanently visually impaired or blind in at least one eye because of uveitis, after a median of 9.7 years [51].

AAU symptoms

AAU is always symptomatic with a red, painful and photophobic eye. The eye is not sticky and vision is usually blurred rather than a dramatic loss of vision. Although both eyes can be affected, normally only one eye is involved at any one time. The first attack of AAU is frequently misdiagnosed as conjunctivitis; thus, it is often that when the patient eventually presents to an ophthalmologist, the attack may be quite severe. Recurrences are common with one study reporting an average frequency of recurrence of 1.1 ± 0.8 per year in patients <5 years from their initial attack and 0.8 ± 0.6 per year in patients >5 years from their first attack, suggesting that recurrence may become less frequent with longer duration of disease [44]. AAU seen in association with AS often has a typical pattern where the uveitis recurs several in the same eye, then affects the fellow eye and finally switches back to the eye that was originally involved, a 'flip-flop' or 'unilateral alternating' pattern (Table 3) [46,52]. Recurrences can vary in severity between patients and in the same patient, with the time between recurrences varying greatly. Patients may also experience a slight 'feeling/twinge' in the eye as premonitory symptom of a recurrence. Some patients will state that stress can precipitate a recurrence.

AAU signs

AAU cannot be accurately diagnosed without using a slit lamp. Circumcorneal redness, a small and often irregularly shaped pupil would be highly indicative of AAU. The characteristic signs of AU are keratic precipitates (KPs), cells and flare in the anterior chamber and posterior synechiae (PS). KPs are inflammatory cellular deposits on the inner aspect on the cornea (corneal endothelium). These can vary in shape and distribution with different types of AU, but in HLA-B27-related AAU, the KPs are characteristically small (fine) and arranged in a triangular pattern on the inferior third of the corneal

Table 3
HLA-B27-positive AAU seen in AS versus HLA-B27-negative AAU. Adapted from Ref. [52].

Feature	HLA-B27-positive AAU	HLA-B27-negative AAU
Laterality	Unilateral alternating	Bilateral
Pattern of uveitis	Acute/recurrent	Chronic
KPs	Fine	Medium/large
Fibrin in anterior chamber	Yes	No
Hypopyon	Yes	No

AAU, acute anterior uveitis; AS, ankylosing spondylitis; KP, keratic precipitate.

endothelium with the apex of the triangle towards the centre of the cornea, known as Arlt's triangle. Breakdown of the blood-aqueous barrier (the endothelial cells of the iris venules) allows leakage of leucocytes ('cells') into the clear, colourless aqueous humour. The more cells that are seen in the anterior chamber using the slit lamp (they appear as tiny white dots floating around in the aqueous humour) correlate with increasing inflammation and this can be graded using a validated scoring system (Table 4) [49]. In a severe attack of AAU, there are so many cells in the aqueous humour that they settle to the bottom of the anterior chamber forming a white sediment known as a hypopyon (Fig. 6). The main differential diagnoses for a hypopyon are HLA-B27-related AAU and the uveitis seen in association with Behçet's disease. Albumin also leaks into the aqueous humour causing it to become milky/opaque and this is known as flare. The more opaque the aqueous humour, the more flare that has resulted from blood-aqueous barrier breakdown, and this is also graded (Table 5) [49]. Severe flare results in a fibrin clot in the anterior chamber that is characteristic of HLA-B27-associated AAU (Table 3) (Fig. 7). PS are adhesions between the iris and anterior lens capsule. This results in a small and irregularly shaped pupil (Fig. 8). In the normal eye, the iris rests on the anterior lens capsule. When the iris becomes inflamed and the aqueous humour becomes more proteinaceous, the iris adheres to the anterior lens capsule to give an irregularly shaped pupil. Unless these adhesions can be broken, the pupil will maintain that shape for life and not be able to dilate normally.

Management of AAU

The standard treatment is frequent potent topical corticosteroid to eradicate the anterior chamber cells and flare by restoring the blood aqueous barrier. Drops such as prednisolone acetate 1%, are

Table 4
Grading of anterior chamber cells using the slit lamp. Adapted from Ref. [49].

Anterior chamber cells (number)[a]	Grade
0	0
1–5	+0.5
6–15	+1.0
16–25	+2.0
26–50	+3.0
>50	+4.0

[a] Using a 1 mm × 1 mm slit-lamp beam.

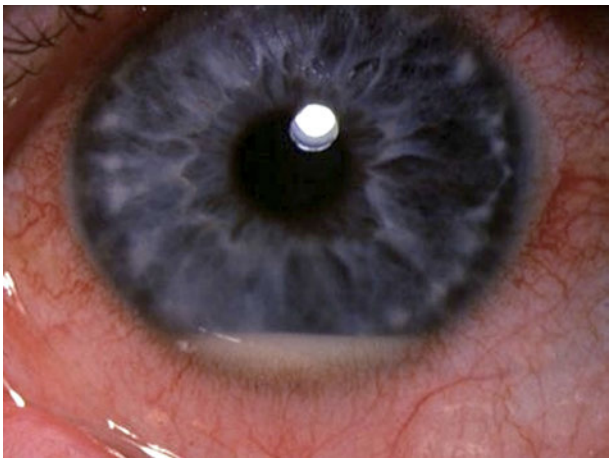

Fig. 6. Hypopyon (white sediment of leucocytes) in anterior chamber in a patient with HLA-B27-positive acute anterior uveitis.

Table 5
Grading of anterior chamber flare using the slit lamp.
Adapted from Ref. [49].

Description	Grade
None	0
Faint	+1.0
Moderate	+2.0
Marked	+3.0
Intense (fibrin)	+4.0

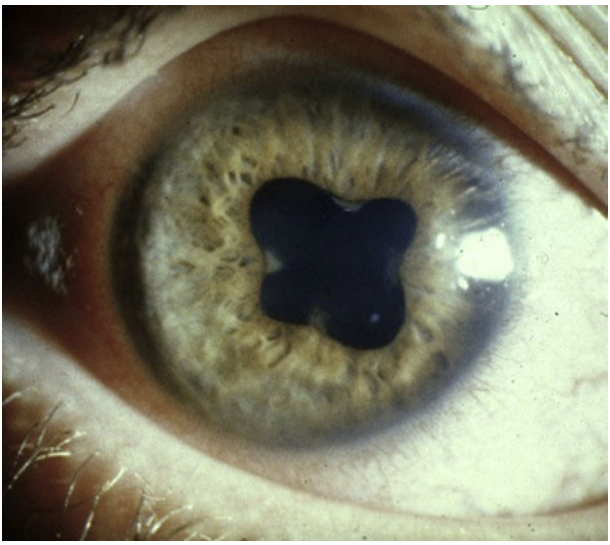

Fig. 7. Irregular shaped pupil with adhesions between iris and anterior lens capsule (posterior synechiae).

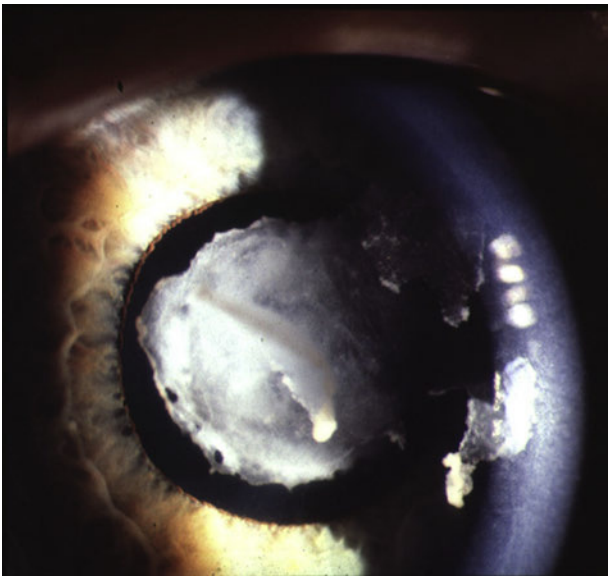

Fig. 8. Fibrin clot in anterior chamber in a patient with HLA-B27-positive acute anterior uveitis.

prescribed every 1–2 h and tapered off after 6–8 weeks depending on the severity of the attack, that is, the amount of cells and flare in the anterior chamber. These are given with a drop to dilate the pupil, such as cyclopentolate hydrochloride 1% usually 3 times a day. By dilating the pupil (a mydriatic action), it prevents PS formation as the iris will be further away from the anterior lens capsule as well as breaking any PS that have freshly formed (it will not break long-standing PS) to enable the pupil to become round again. It also paralyses the ciliary muscle (stops accommodation—cycloplegic action) thus reducing pain but will cause blurred vision particularly for reading. The action of cyclopentolate should wear off within 24 h once the drops are discontinued. In severe cases where there may be fibrin and a hypopyon in the anterior chamber, often the patient's first attack, an initial subconjunctival injection of betamethasone 0.1% combined with Mydricaine No. 2 (contains procaine hydrochloride, atropine sulphate and adrenaline acid tartrate) to dilate the pupil is required. If intensive topical corticosteroids do not give a rapid improvement, a short course of oral prednisolone (40–60 mg a day for 1 week) may be needed. Nevertheless, the majority of cases of AAU continue to be treated successfully with topical corticosteroids and cycloplegics. The course of the disease may change in some patients with frequent recurrences of AAU to pursue a chronic course requiring long-term therapy. A small number of patients fail to respond to conventional therapy and require systemic treatment and tend to go along the pathway of systemic corticosteroid, then an immunosuppressant and finally a biologic.

Ocular complications of AAU

Secondary raised IOP/secondary glaucoma

There are several mechanisms that can cause a rise in IOP >21 mmHg (normal range 10–21 mmHg) that could result in an irreversible optic neuropathy and visual field loss, that is, glaucoma. Two of these mechanisms are explained in greater detail.

Pupil block 'glaucoma'

If the iris completely sticks to anterior lens capsule, that is, PS for 360° that may occur after repeated attacks of AAU, then the aqueous humour that is produced in the ciliary processes will not be able to pass between iris and anterior lens capsule through the pupil and into the anterior chamber. This results in a build-up of aqueous humour behind the iris bowing it forward into the anterior chamber, known as iris bombé. There is a rapid increase of IOP to about 50 mmHg with severe pain, reduced vision, redness and a hazy cornea. Treatment initially is medical to reduce the IOP and treat the AU. The definitive treatment is to make a hole in the iris to allow the aqueous humour to pass into the anterior chamber and this is undertaken using a Nd:YAG (neodymium-doped yttrium aluminium garnet) laser.

Corticosteroid-induced rise in IOP

This is often incorrectly referred to in the ophthalmic literature as a 'steroid responder'. Several weeks after starting (usually potent) topical corticosteroids about 30% of patients will develop a rise in IOP > 21 mmHg. Corticosteroids appear to decrease the outflow of aqueous humour by inhibiting the degradation and/or enhancing the deposition of extracellular matrix material within the trabecular meshwork and/or cross-linking of actin fibres between trabecular meshwork cells. There is often a family history of primary open angle glaucoma. The rise in IOP will be gradual and is unlikely to be >40 mmHg; thus, the eye does not become red or painful, that is, the patient will not be able to recognise that the IOP has risen. Patients who require long-term daily topical corticosteroid must undergo regular IOP checks and any raised IOP is treated to prevent the development of irreversible glaucomatous optic neuropathy.

Apart from pupil block glaucoma, the mainstay of treatment to reduce IOP is medical. If corticosteroid induced and the uveitis still requires treatment, then a less potent topical corticosteroid is prescribed, such as loteprednol 0.5%. Drops to lower the IOP can be given singly or in combination if one agent is unable to reduce the IOP to an acceptable level. There are 4 classes of drops that are used: beta-blockers, prostaglandin analogues, carbonic anhydrase inhibitors and alpha-2 agonists. If despite a combination of drops, the IOP cannot be reduced enough or if there is evidence of progressive glaucomatous optic neuropathy, then surgery is undertaken—either a trabeculectomy combined with application of mitomycin C at the surgical site or drainage valve/tube surgery. The choice of operation is often surgeon's preference.

Cataract

Repeated attacks of AU may result in lens permeability changes causing lens opacification, that is, cataract. This is usually the posterior subcapsular type and occurs at the back of the lens in the visual axis. This means that light entering the eye will hit the area of opacification causing the light to be scattered giving symptoms of glare. One does not need a large amount of cataract to cause glare and patients often complain of being dazzled by sunlight or car headlights when driving. The decision to undertake cataract surgery is often determined by the degree of glare the patient experiences. Cataract surgery (phacoemulsification with insertion of an acrylic intraocular lens) can give an excellent restoration of vision but surgery may be technically challenging and strict preoperative and post-operative control of the uveitis is essential (Fig. 9) [53].

Cystoid macular oedema

Cystoid macular oedema (CMO) is one of the major causes of vision loss in patients with uveitis. Although usually a complication of uveitis affecting the posterior segment of the eye (intermediate, pan, posterior uveitis), it is recognised as relatively uncommon complication of AAU seen in association with AS. It normally occurs 3–4 weeks after starting treatment when the AU has settled and the eye is white and pain free. Fluid accumulates in the macular area of the retina, particularly the fovea causing a significant reduction of vision. The macula is the most sensitive part of the retina, is full of cones and is responsible for central (reading) vision. The fovea is avascular and the thinnest and most important part of the macula. Macular oedema is assessed using optical coherence tomography (OCT) that is a non-contact, non-invasive medical imaging technology. With OCT, reflected light is used to produce high-resolution cross-sectional and 3D images of the eye (most commonly of the retina). The most popular use involves looking at detailed views of the macula and fovea (the latter having a normal thickness of about 250 μm). The size of the machine is not much larger than that of a normal slit lamp and within a minute a detailed scan be acquired (Fig. 10). One of the most common types of treatment for CMO is a periocular injection of the corticosteroid, triamcinolone 40 mg.

How can recurrences of AAU be prevented?

It is impossible to predict when a recurrence of AAU will occur and in which eye. Some patients may experience a recurrence after a few weeks of stopping treatment or it could be as long as decades. This makes evaluation of therapies problematic. Conventional immunosuppressants have been used in

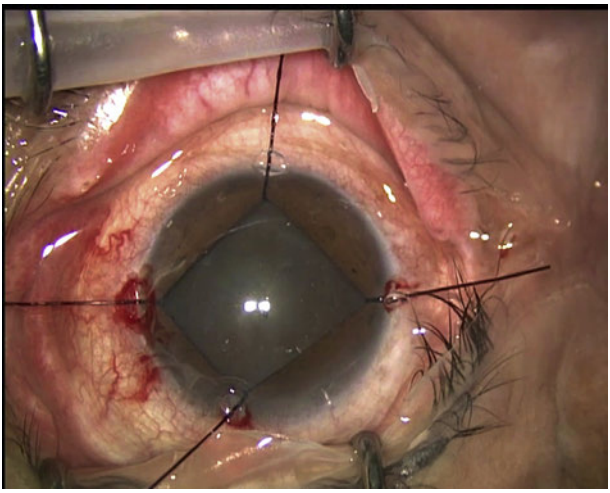

Fig. 9. Showing 4 polypropylene iris retractors enlarging the pupil in a uveitic eye with posterior synechiae to allow cataract surgery to be performed.

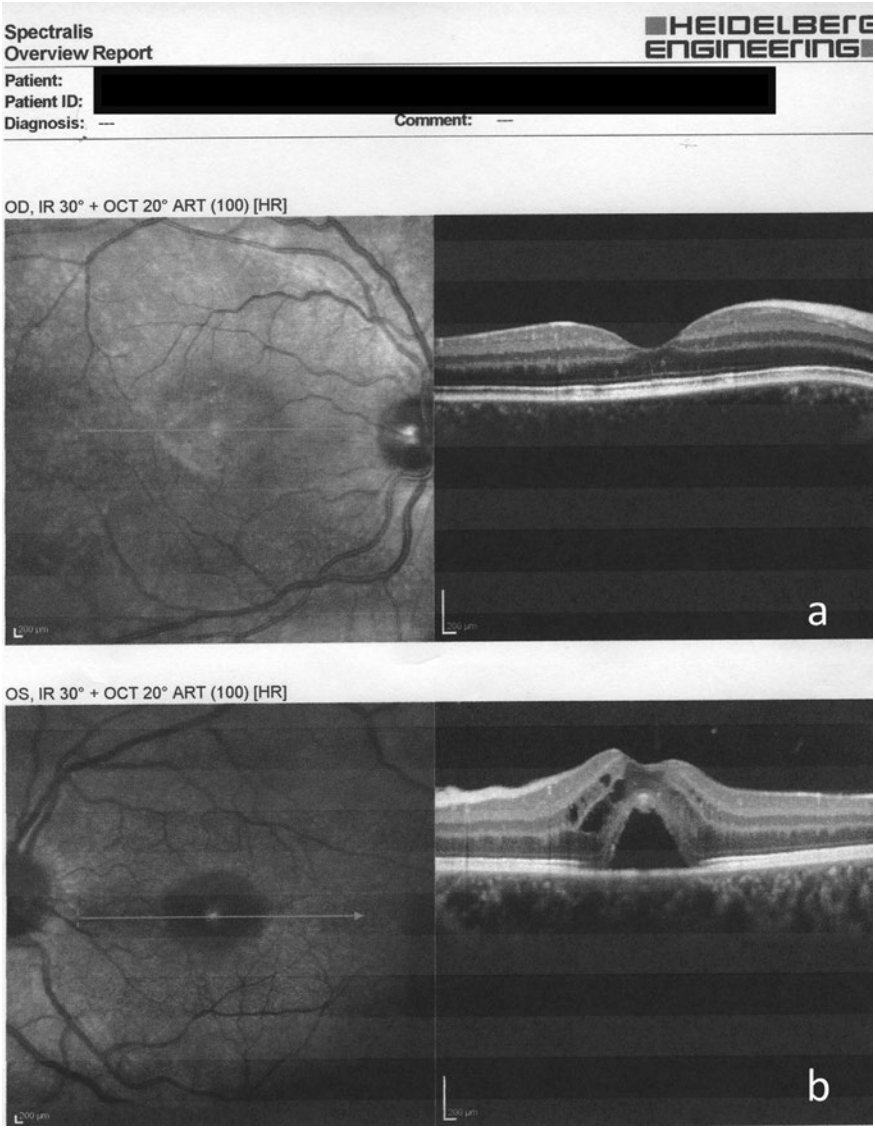

Fig. 10. OCT scan of (a) normal macula with foveal dip and (b) showing CMO (black fluid filled spaces) with a thickened fovea.

refractory patients. Sulfasalazine has been shown to reduce the frequency and severity of uveitis [54,55], but both studies were undertaken on very small numbers of patients. Methotrexate also lowers the number of uveitis relapses but this study was on even fewer patients (n = 9) [56]. Most published studies have involved the use of the anti-TNF agents such as infliximab, adalimumab and etanercept, with small case series on golimumab and certolizumab. Etanercept does not appear to be as effective as other anti-TNF agents. There appears to be a reduction in flares of uveitis in patients with AS on anti-TNF therapy. Cobo-Ibanez et al. reported the incidence of uveitis in patients on infliximab was 61.73 cases per 100 patient-years before treatment, and this number decreased to 2.64 after starting the therapy. In patients on etanercept, the incidence changed from 34.29 before treatment to 60 cases per 100 patient-years after starting therapy. This evolution of the uveitis flares was found to be significantly

different between both groups ($P = 0.041$). Only 1 of 10 patients developed a new uveitis flare during infliximab treatment. Six of the 10 patients on etanercept had new uveitis flares during the treatment [57]. Guignard et al. undertook a retrospective observational study of all patients with spondylarthropathy with at least 1 uveitis flare treated with anti-TNF in 1 centre (December 1997–December 2004). The number of uveitis flares per 100 patient-years was compared before and during anti-TNF treatment; each patient was his or her own control. Patients were followed for 15.2 years (mean) before anti-TNF versus 1.2 years during anti-TNF treatment. The mean number of uveitis flares per patient before and during anti-TNF treatment was 6.3 versus 0.2 with all anti-TNF drugs. The number of uveitis flares per 100 patient-years before and during anti-TNF treatment was 51.8 versus 21.4 with all anti-TNF drugs ($P = 0.03$), 54.6 versus 58.5 with etanercept ($P = 0.92$), 47.4 versus 9.0 with infliximab ($P = 0.008$) and 60.5 versus 0 with adalimumab ($P = 0.04$). The limitations of this study were that it was retrospective and uveitis flares were based solely on patient report [58]. Rudwaleit et al. evaluated the effect of adalimumab on the frequency of AU flares in patients with active AS. They determined the history of AU diagnosed by the ophthalmologist in 1250 patients with active AS who were enrolled in a multinational, open-label, uncontrolled clinical study. During adalimumab treatment, the rate of AU flares was reduced by 51% in all patients, by 58% in 274 patients with a history of AU, by 68% in 106 patients with a recent history of AU, by 50% in 28 patients with symptomatic AU at baseline and by 45% in 43 patients with chronic uveitis. AU flares during adalimumab treatment were predominantly mild. The authors concluded that adalimumab had a substantial preventive effect on AU flares in patients with active AS, including patients with a recent history of AU flares [59]. Braun et al. analysed data from 4 placebo-controlled studies with anti-TNF agents in AS (2 with etanercept and 2 with infliximab) and 3 open-label studies were analysed for the prestudy prevalence and the incidence of reported flares of AU (usually defined in the studies as 'as diagnosed by an ophthalmologist'). The frequency of flares of AU in the placebo group was 15.6 per 100 patient-years (95% CI 7.8–27.9), whereas the patients treated with anti-TNF agents had a mean of only 6.8 AU flares per 100 patient-years ($P = 0.01$). Flares of AU occurred less frequently (although not significantly) in patients treated with infliximab than in patients treated with etanercept (3.4 per 100 patient-years and 7.9 per 100 patient-years, respectively) [60]. Wu et al. performed a meta-analysis to evaluate the effect of anti-TNF therapy on the frequency of extraarticular manifestations in patients with AS. Anti-TNF therapy was associated with less uveitis than placebo in patients with AS (OR: 0.35, 95% CI: 0.15–0.81, $P = 0.01$). They concluded that anti-TNF therapy was preventive for flares or new onset of uveitis in patients with AS, and might be an alternative for these patients [61].

One study concluded that adalimumab therapy was associated with a significantly lower risk of developing uveitis compared with etanercept therapy in AS with no prior history of uveitis, but the risk was not different between adalimumab and infliximab [62]. As this study only had a follow-up period of 1 year, it is difficult to come to any firm conclusions. There is debate on whether etanercept itself can cause uveitis [57,62–65].

The use of powerful systemic immune modulators to prevent recurrences of AU that are normally not sight threatening and can be unpredictable should be balanced against the potential side effects [66] and cost–benefit analysis of treatment. Gao et al. assessed uveitis flare rates in patients with AS treated with anti-TNF agents and examined the economic burden of uveitis. Economic analysis indicated substantial costs associated with AU flares secondary to AS in France and Germany. Clinician-estimated AS-related uveitis direct medical costs were €1410 (Germany) and €1812 (France) [67]. Unless indicated for their AS, it would seem appropriate to reserve these therapies for patients whose uveitis is refractory to more conventional treatments.

Should all patients initially presenting with typical signs of HLA-B27-related AAU be referred to a rheumatologist?

Although the rheumatologic symptoms precede the first attack of uveitis in >80% of cases, it is not uncommon for patients to first present to an ophthalmologist with an attack of AAU [44]. As a prolonged delay in diagnosis is common among patients with AS, the ophthalmologist plays an important role in diagnosis as he or/and she may be the first physician to suspect AS [68,69]. A novel evidence-based algorithm called the Dublin Uveitis Evaluation Tool (DUET) has been proposed to guide

ophthalmologists to refer appropriate patients with AAU to rheumatologists [70]. Using this simple to apply algorithm, 29/72 (40%) of patients presenting with idiopathic AAU were noted to have undiagnosed spondyloarthropathy. The DUET algorithm was found to have excellent sensitivity (96%) and specificity (97%) with a positive likelihood ratio of 41.5 and negative likelihood ratio of 0.03.

Other ophthalmic complications of AS

Scleritis can also be associated with AS, most commonly anterior scleritis. The incidence of scleritis associated with seronegative arthritides ranges between 4% and 20% [39]. The symptoms, signs and treatment have been covered under 'Rheumatoid Arthritis'.

Practice points

- AAU is the most common ocular manifestation of AS, is always symptomatic and can only be accurately diagnosed using a slit lamp
- An ophthalmologist may be the first physician to recognise AS.
- Usually only one eye is affected at a time and most attacks respond well to topical corticosteroid but recurrences are unpredictable.
- Recognised ocular complications include secondary glaucoma, cataract and macular oedema.
- Anti-TNF drugs should be considered for refractory cases where vision may be compromised.

Research agenda

- The development of non-corticosteroid agents for the treatment of AAU.
- Randomised controlled clinical trials of anti-TNF drugs for treatment and prevention of AAU.

The eye and PsA

What is the most common ophthalmic manifestation of PsA?

Ophthalmic manifestations are estimated to occur in 10% of patients with psoriasis [71], and 31% of patients with PsA [72], with the most common manifestation of PsA being uveitis, but seen at a lesser frequency (7%) than in AS [73]. Egeberg et al. performed a nationwide cohort study of the Danish population from 1 January 1997 through 31 December 2011 and included 74,129 Danish patients with psoriasis who were 18 years or older. They identified 74,129 cases of psoriasis and PsA and 13,114 cases of uveitis. The incidence rates (95% CIs) for uveitis were 2.02 (1.99–2.06), 2.88 (2.33–3.56), 4.23 (2.40–7.45) and 5.49 (3.36–8.96) for the reference population and those with mild psoriasis, severe psoriasis and PsA, respectively [74].

In a review by Cantini et al. in early PsA, they found the frequency of AU to be 9%. They suggested that the wide range of prevalence reported in PsA may be explained by the variable sets of classification criteria used for patient selection and the different length of follow-up [75]. Abbouda et al. studied 117 patients affected by uveitis and psoriasis or PsA (92 and 25 patients, respectively) from 2003 to 2013. Axial PsA was associated with unilateral uveitis onset compared with the peripheral pattern ($P < 0.03$). They concluded that uveitis in patients with psoriasis and PsA may have distinguishing clinical features; patients with PsA having more ocular complications than those with psoriasis [76]. Similar to AS, the uveitis may precede the onset of PsA.

Does the uveitis associated with PsA differ from that seen with AS?

Although the most common type of uveitis in both is recurrent AAU, but when associated with PsA, it does not appear to follow the 'flip-flop' or 'unilateral alternating' pattern and both eyes can be affected simultaneously. Paiva et al. compared the nature of uveitis in PsA with that seen with a previous cohort of patients with spondyloarthropathy. They reported that PsA-associated uveitis was more likely to be insidious in onset (19% vs 3%), bilateral (38% vs 7%), chronic in duration (31% vs 6%) or posterior (44% vs 17%) [77]. The complications of secondary raised IOP/glaucoma, cataract and CMO are similar [76].

What are the other ocular manifestations of PsA?

Conjunctivitis (up to 20%), episcleritis, scleritis, keratoconjunctivitis sicca and keratitis have also been reported [71,72]. Psoralen combined with ultraviolet A (PUVA) photochemotherapy for psoriasis has been implicated in cataract formation, but this was prior to protective eyewear becoming mandatory [78].

What is the treatment of the ocular disease?

PsA-associated AAU is treated as any type of AAU with intensive topical corticosteroids and dilating the pupil, but more persistent AU may require prolonged treatment. The complications are managed similarly to those seen in association with AS.

Practice points

- Uveitis is the commonest ocular manifestation of PsA but occurs less frequently than in association with AS.
- The pattern of uveitis may differ from the typical AAU seen with AS.
- Recognised ocular complications of secondary glaucoma, cataract and macular oedema are similar to those seen in association with AS.

Summary

RA, AS and PsA all have sight-threatening ocular complications. In RA, DED is the most common ocular manifestation with significant impact on the patient's life. Treatment options largely depend on patient preference. PUK is relatively rare but can lead to globe perforation. Underlying corneal infection must be excluded and urgent reconstructive surgery may be required. Systemic immunomodulation similar to scleritis is necessary. Scleritis causes an intense red eye with excruciating pain and usually requires systemic corticosteroid, often an immunosuppressant and sometimes a biologic. The necrotising type has the worst prognosis and resolution results in scleral thinning. AU is a feature of both AS and PsA. Presentation patterns may vary between the 2 conditions. In AS, it is of sudden onset with redness, pain, photophobia, blurred vision with the uveitis recurring in the same eye before involving the fellow eye then returning to the first eye. In PsA, the AU may involve both eyes simultaneously and can pursue a chronic rather than limited course. Characteristic features of HLA-B27-positive AU include fibrin in the anterior chamber, hypopyon with frequent but unpredictable recurrences of varying severity. The treatment (topical corticosteroid and cycloplegia) and complications (raised IOP/glaucoma, cataract and CMO) of AU are identical for both AS and PsA. In severe or recalcitrant cases, systemic corticosteroid and often an immunosuppressant may be required, but there is low-level evidence for this. There is good evidence to show that anti-TNF agents such as infliximab and adalimumab can prevent flares of AU but not etanercept that itself may induce uveitis.

Conflict of interest/financial disclosure

Neither author has any conflict of interest nor any financial support, personal financial interest or commercial relationship relevant to the subject matter of this manuscript.

References

[1] Artifoni M, Rothschild PR, Brézin A, et al. Ocular inflammatory diseases associated with rheumatoid arthritis. Nat Rev Rheumatol 2014;10:108–16.
[2] Wakefield D, Di Girolamo N, Thurau S, et al. Scleritis: challenges in immunopathogenesis and treatment. Discov Med 2013;16:153–7.
[3] Giordano N, D'Ettorre M, Biasi G, et al. Retinal vasculitis in rheumatoid arthritis: an angiographic study. Clin Exp Rheumatol 1990;8:121–5.
[4] Andonopoulos AP, Drosos AA, Skopouli FN, et al. Secondary Sjögren's syndrome in rheumatoid arthritis. J Rheumatol 1987;14:1098–103.
[5] No_authors_listed. The definition and classification of dry eye disease: report of the definition and classification subcommittee of the international dry eye WorkShop. Ocul Surf 2007;5:75–92.
[6] Sullivan DA, Hammitt KM, Schaumberg DA, et al. Report of the TFOS/ARVO Symposium on global treatments for dry eye disease: an unmet need. Ocul Surf 2012;10:108–16.
[7] McDonald M, Patel DA, Keith MS, et al. Economic and humanistic burden of dry eye disease in Europe, North America, and Asia: a systematic literature review. Ocul Surf 2016;14:144–67.
[8] Buchholz P, Steeds CS, Stern LS, et al. Utility assessment to measure the impact of dry eye disease. Ocul Surf 2006;4:155–61.
[9] Schiffman RM, Walt JG, Jacobsen G, et al. Utility assessment among patients with dry eye disease. Ophthalmology 2003;110:1412–9.
[10] van der Vaart R, Weaver MA, Lefebvre C, et al. The association between dry eye disease and depression and anxiety in a large population-based study. Am J Ophthalmol 2015;159:470–4.
[11] Wan KH, Chen LJ, Young AL. Depression and anxiety in dry eye disease: a systematic review and meta-analysis. Eye 2016. http://dx.doi.org/10.1038/eye.2016.186 [published Online First: Epub Date].
*[12] No authors listed. Management and therapy of dry eye disease: report of the management and therapy subcommittee of the international dry eye WorkShop. Ocul Surf 2007;2007(5):163–78.
[13] Rosenthal P, Inna B, Jacobs D. Corneal pain without stain: is it real? Ocul Surf 2009;7:28–40.
[14] Whitcher JP, Shiboski CH, Shiboski SC, et al. A simplified quantitative method for assessing keratoconjunctivitis sicca from the Sjögren's syndrome International Registry. Am J Ophthalmol 2010;149:405–15.
*[15] Geerling G, Tauber J, Baudouin C, et al. The international workshop on meibomian gland dysfunction: report of the subcommittee on management and treatment of meibomian gland dysfunction. Invest Ophthalmol Vis Sci 2011;52:2050–64.
[16] Geerling G, Daniels JT, Dart JKG, et al. Toxicity of natural tear substitutes in a fully defined culture model of human corneal epithelial cells. Invest Ophthalmol Vis Sci 2001;42:948–56.
[17] Garrett Q, Simmons PA, Xu S, et al. Carboxymethylcellulose binds to human corneal epithelial cells and is a modulator of corneal epithelial wound healing. Invest Ophthalmol Vis Sci 2007;48:1559–67.
[18] Tong L, Beuerman R, Simonyi S, et al. Effects of punctal occlusion on clinical signs and symptoms and on tear cytokine levels in patients with dry eye. Ocul Surf 2016;14:233–41.
[19] Aragona P, Di Pietro R, Spinella R, et al. Conjunctival epithelium improvement after systemic pilocarpine in patients with Sjögren's syndrome. Br J Ophthalmol 2006;90:166–70.
[20] Tsubota K, Goto E, Fujita H, et al. Treatment of dry eye by autologous serum application in Sjogren's syndrome. Br J Ophthalmol 1999;83:390–5.
[21] McKibbin M, Isaacs JD, Morrell AJ. Incidence of corneal melting in association with systemic disease in the Yorkshire Region, 1995–7. Br J Ophthalmol 1999;83:941–3.
[22] Tong L, Thumboo J, Tan YK, et al. The eye: a window of opportunity in rheumatoid arthritis? Nat Rev Rheumatol 2014;10:552–60.
[23] Vignesh AP, Srinivasan R. Ocular manifestations of rheumatoid arthritis and their correlation with anti-cyclic citrullinated peptide antibodies. Clin Ophthalmol 2015;9:393–7.
[24] Foster CS, Forstot SL, Wilson LA. Mortality rate in rheumatoid arthritis patients developing necrotizing scleritis or peripheral ulcerative keratitis. Ophthalmology 1984;91:1253–63.
[25] Knox Cartwright NE, Tole DM, Georgoudis P, et al. Peripheral ulcerative keratitis and corneal melt: a 10-year single center review with historical comparison. Cornea 2014;33:27–31.
[26] Malik R, Culinane AB, Tole DM, et al. Rheumatoid keratolysis: a series of 40 eyes. Eur J Ophthalmol 2006;16:791–7.
[27] Khan IJ, Barry RJ, Amissah-Arthur KN, et al. Ten-year experience of pulsed intravenous cyclophosphamide and methylprednisolone protocol (PICM protocol) in severe ocular inflammatory disease. Br J Ophthalmol 2013;97:1118–22.
[28] Cunningham Jr ET, McCluskey P, Pavesio C, et al. Scleritis Ocul Immunol Inflamm 2016;24:2–5.
[29] Akpek EK, Thorne JE, Qazi FA, et al. Evaluation of patients with scleritis for systemic disease. Ophthalmology 2004;111:501–6.
[30] Galor A, Thorne JE, Jabs DA. Rheumatic disease and scleritis. Ophthalmology 2007;114:1232.
[31] Galor A, Thorne JE. Scleritis and peripheral ulcerative keratitis. Rheum Dis Clin North Am 2007;33:835–54.
*[32] Watson PG, Hayreh SS. Scleritis and episcleritis. Br J Ophthalmol 1976;60:163–91.
[33] Lavric A, Gonzalez-Lopez JJ, Majumder PD, et al. Posterior scleritis: analysis of epidemiology, clinical factors, and risk of recurrence in a cohort of 114 patients. Ocul Immunol Inflamm 2016;24:6–15.

[34] Agrawal R, Lee CS, Gonzalez-Lopez JJ, et al. Flurbiprofen: a nonselective cyclooxygenase (COX) inhibitor for treatment of noninfectious, non-necrotizing anterior scleritis. Ocul Immunol Inflamm 2016;24:35–42.
[35] Sohn EH, Wang R, Read R, et al. Long-term, multicenter evaluation of subconjunctival injection of triamcinolone for non-necrotizing, noninfectious anterior scleritis. Ophthalmology 2011;118:1932–7.
[36] Sen HN, Suhler EB, Al-Khatib SQ, et al. Mycophenolate mofetil for the treatment of scleritis. Ophthalmology 2003;110:1750–5.
[37] Sen HN, Sangave A, Hammel K, et al. Infliximab for the treatment of active scleritis. Can J Ophthalmol 2009;44:e9–12.
[38] Suhler EB, Lim LL, Beardsley RM, et al. Rituximab therapy for refractory scleritis: results of a phase I/II dose-ranging, randomized, clinical trial. Ophthalmology 2014;121:1885–91.
*[39] Wakefield D, Di Girolamo N, Thurau S, et al. Scleritis: immunopathogenesis and molecular basis for therapy. Prog Retin Eye Res 2013;35:44–62.
[40] McCluskey PJ, Wakefield D. Prediction of response to treatment in patients with scleritis using a standardized scoring system. Aust N. Z J Ophthalmol 1991;19:211–5.
[41] Sen HN, Sangave AA, Goldstein DA, et al. A standardized grading system for scleritis. Ophthalmology 2011;118:768–71.
[42] Akpek EK, Uy HS, Christen W, et al. Severity of episcleritis and systemic disease association. Ophthalmology 1999;106:729–31.
[43] Diaz DJ, Sobol EK, Gritz DC. Treatment and management of scleral disorders. Surv Ophthalmol 2016;61:702–17.
[44] Monnet D, Breban M, Hudry C, et al. Ophthalmic findings and frequency of extraocular manifestations in patients with HLA-B27 uveitis: a study of 175 cases. Ophthalmology 2004;111:802–9.
[45] Pathanapitoon K, Dodds EM, Cunningham Jr ET, et al. Clinical spectrum of HLA-B27-associated ocular inflammation. Ocul Immunol Inflamm 2016 Jul 18:1–8 [Epub ahead of print].
[46] Rothova A, van Veenedaal WG, Linssen A, et al. Clinical features of acute anterior uveitis. Am J Ophthalmol 1987;103:137–45.
[47] Kopplin LJ, Mount G, Suhler EB. Review for disease of the year: epidemiology of HLA-B27 associated ocular disorders. Ocul Immunol Inflamm 2016;24:470–5.
*[48] de Smet MD, Taylor SR, Bodaghi B, et al. Understanding uveitis: the impact of research on visual outcomes. Prog Retin Eye Res 2011;30:452–70.
*[49] Jabs DA, Nussenblatt RB, Rosenbaum JT. Standardization of uveitis nomenclature (SUN) working group. Standardization of uveitis nomenclature for reporting clinical data. Results of the first international workshop. Am J Ophthalmol 2005;140:509–16.
[50] Deschenes J, Murray PI, Rao NA, et al. International uveitis study group. International uveitis study group (IUSG): clinical classification of uveitis. Ocul Immunol Inflamm 2008;16:1–2.
[51] Verhagen FH, Brouwer AH, Kuiper JJ, et al. Potential predictors of poor visual outcome in Human Leukocyte Antigen-B27-associated uveitis. Am J Ophthalmol 2016;165:179–87.
*[52] Chang JH, McCluskey PJ, Wakefield D. Acute anterior uveitis and HLA-B27. Surv Ophthalmol 2005;50:364–88.
[53] Tomlins PJ, Sivaraj RR, Rauz S, et al. Long-term biocompatibility and visual outcomes of a hydrophilic acrylic intraocular lens in patients with uveitis. J Cataract Refract Surg 2014;40:618–25.
[54] Muñoz-Fernández S, Hidalgo V, Fernández-Melón J, et al. Sulfasalazine reduces the number of flares of acute anterior uveitis over a one-year period. J Rheumatol 2003;30:1277–9.
[55] Benitez-Del-Castillo JM, Garcia-Sanchez J, Iradier T, et al. Sulfasalazine in the prevention of anterior uveitis associated with ankylosing spondylitis. Eye (Lond) 2000;14:340–3.
[56] Muñoz-Fernández S, García-Aparicio AM, Hidalgo MV, et al. Methotrexate: an option for preventing the recurrence of acute anterior uveitis. Eye (Lond) 2009;23:1130–3.
[57] Cobo-Ibáñez T, del Carmen Ordóñez M, Muñoz-Fernández S, et al. Do TNF-blockers reduce or induce uveitis? Rheumatol Oxf 2008;47:731–2.
[58] Guignard S, Gossec L, Salliot C, et al. Efficacy of tumour necrosis factor blockers in reducing uveitis flares in patients with spondylarthropathy: a retrospective study. Ann Rheum Dis 2006;65:1631–4.
[59] Rudwaleit M, Rødevand E, Holck P, et al. Adalimumab effectively reduces the rate of anterior uveitis flares in patients with active ankylosing spondylitis: results of a prospective open-label study. Ann Rheum Dis 2009;68:696–701.
[60] Braun J, Baraliakos X, Listing J, et al. Decreased incidence of anterior uveitis in patients with ankylosing spondylitis treated with the anti-tumor necrosis factor agents infliximab and etanercept. Arthritis Rheum 2005;52:2447–51.
*[61] Wu D, Guo YY, Xu NN, et al. Efficacy of anti-tumor necrosis factor therapy for extra-articular manifestations in patients with ankylosing spondylitis: a meta-analysis. BMC Musculoskelet Disord 2015;16:19.
[62] Wendling D, Joshi A, Reilly P, et al. Comparing the risk of developing uveitis in patients initiating anti-tumor necrosis factor therapy for ankylosing spondylitis: an analysis of a large US claims database. Curr Med Res Opin 2014;30:2515–21.
[63] Lim LL, Fraunfelder FW, Rosenbaum JT. Do tumor necrosis factor inhibitors cause uveitis? A registry-based study. Arthritis Rheum 2007;56:3248–52.
[64] Brito-Zerón P, Perez-Alvarez R, Ramos-Casals M. BIOGEAS Study Group. Etanercept and uveitis: friends or foes? Curr Med Res Opin 2015;31:251–2.
[65] Raffeiner B, Ometto F, Bernardi L, et al. Inefficacy or paradoxical effect? Uveitis in ankylosing spondylitis treated with etanercept. Case Rep Med 2014;2014:471319.
[66] Kim M, Won JY, Choi SY, et al. Anti-TNFα treatment for HLA-B27 positive ankylosing spondylitis-related uveitis. Am J Ophthalmol 2016;170:32–40.
[67] Gao X, Wendling D, Botteman MF, et al. Clinical and economic burden of extra-articular manifestations in ankylosing spondylitis patients treated with anti-tumor necrosis factor agents. J Med Econ 2012;15:1054–63.
[68] Wach J, Maucort-Boulch D, Kodjikian L, et al. Acute anterior uveitis and undiagnosed spondyloarthritis: usefulness of Berlin criteria. Graefes Arch Clin Exp Ophthalmol 2015;253:115–20.
[69] Khan MA, Haroon M, Rosenbaum JT. Acute anterior uveitis and spondyloarthritis: more than meets the eye. Curr Rheumatol Rep 2015;17:59.
*[70] Haroon M, O'Rourke M, Ramasamy P, et al. A novel evidence-based detection of undiagnosed spondyloarthritis in patients presenting with acute anterior uveitis: the DUET (Dublin Uveitis Evaluation Tool). Ann Rheum Dis 2015;74:1990–5.

[71] Rehal B, Modjtahedi BS, Morse LS, et al. Ocular psoriasis. J Am Acad Dermatol 2011;65:1202–12.
[72] Lambert JR, Wright V. Eye inflammation in psoriatic arthritis. Ann Rheum Dis 1976;35:354–6.
*[73] Rosenbaum JT. Uveitis in spondyloarthritis including psoriatic arthritis, ankylosing spondylitis, and inflammatory bowel disease. Clin Rheumatol 2015;34:999–1002.
[74] Egeberg A, Khalid U, Gislason GH, et al. Association of psoriatic disease with uveitis: a Danish nationwide cohort study. JAMA Dermatol 2015;151:1200–5.
[75] Cantini F, Nannini C, Cassarà E, et al. Uveitis in spondyloarthritis: an overview. J Rheumatol Suppl 2015;93:27–9.
[76] Abbouda A, Abicca I, Fabiani C, et al. Psoriasis and psoriatic arthritis-related uveitis: different ophthalmological manifestations and ocular inflammation features. Semin Ophthalmol 2016 Jul 15:1–6 [Epub ahead of print].
[77] Paiva ES, Macaluso DC, Edwards A, et al. Characterisation of uveitis in patients with psoriatic arthritis. Ann Rheum Dis 2000;59:67–70.
[78] DePry J, Brescoll J, Szczotka-Flynn L, et al. Phototherapy-related ophthalmologic disorders. Clin Dermatol 2015;33:247–55.