Psoriatic Arthritis Mutilans: Characteristics and Natural Radiographic History

Deepak R. Jadon, Gavin Shaddick, William Tillett, Eleanor Korendowych, Graham Robinson, Nicola Waldron, Charlotte Cavill, and Neil J. McHugh

ABSTRACT. ***Objective.*** (1) To compare clinical characteristics of patients with psoriatic arthritis (PsA) with PsA mutilans (PAM) and without PAM, and (2) to determine the rate of PAM radiographic progression.

Methods. A retrospective cohort study was conducted of all patients with PsA attending a teaching hospital. The most recent hand and feet radiographs were screened for PAM. Serial radiographs (earliest to most recent) were quantitatively scored for osteolysis, erosion, joint space narrowing, and osteoproliferation.

Results. Out of the 610 cases, 36 PsA cases had PAM (5.9%). PAM cases were younger at diagnosis of PsA than non-PAM cases ($p = 0.04$), had more prevalent psoriatic nail dystrophy (OR 5.43, $p < 0.001$), and worse health assessment questionnaire score (1.25 vs 0.63, $p < 0.04$). Radiographic axial disease (OR 2.31, adjusted $p = 0.03$) and especially radiographic sacroiliitis (OR 2.99, adjusted $p = 0.01$) were more prevalent in PAM. PAM were more likely than non-PAM cases to have used a disease-modifying antirheumatic drug (DMARD; OR 16.36, $p < 0.001$). Out of 33 cases, 29 PAM cases had initiated a synthetic DMARD and 4/13 had initiated anti-tumor necrosis factor (anti-TNF) prior to first demonstration of PAM. A median 5 radiographs were scored for each PAM case (interquartile range 3–7). PAM progressed from monoarticular (60%) to polyarticular (80%) involvement. Osteolysis was initially rapid and progressive in the hands and feet, tapering later during disease course. Nail dystrophy predicted more severe osteolysis ($p = 0.03$).

Conclusion. Compared with non-PAM cases, PAM cases have earlier age at PsA diagnosis, poorer function, more prevalent nail dystrophy, and more radiographic axial disease/sacroiliitis. The rate of osteolysis is higher in earlier disease, and more severe in those with nail dystrophy. DMARD and anti-TNF therapy appear not to prevent PAM occurrence. (J Rheumatol First Release May 15 2015; doi:10.3899/jrheum.150083)

Key Indexing Terms:
PSORIATIC ARTHRITIS NATURAL HISTORY MALFORMED NAIL
RADIOGRAPHS TUMOR NECROSIS FACTOR-α

Psoriatic arthritis (PsA) is a chronic inflammatory disease of the musculoskeletal system that can also affect extraarticular structures. Five patterns of PsA were described in 1973 by Moll and Wright: asymmetric oligoarthritis, symmetric polyarthritis, distal interphalangeal joint-predominant arthritis, spondylitis, and arthritis mutilans[1]. The most extreme, albeit rarest form of PsA, is PsA mutilans (PAM).

From the Rheumatology Department, Royal National Hospital for Rheumatic Diseases, Bath, UK.

The authors have an unrestricted educational grant from Pfizer Pharmaceuticals.

D.R. Jadon, MRCP, Research Fellow – Rheumatology, Rheumatology Department, Royal National Hospital for Rheumatic Diseases; G. Shaddick, PhD, Reader of Mathematics, Mathematics Department, University of Bath; W. Tillett, MRCP, Consultant Rheumatologist; E. Korendowych, FRCP, Consultant Rheumatologist; G. Robinson, FRCR, Consultant Radiologist; N. Waldron, MSc, Research Nurse; C. Cavill, MSc, Database Manager; N.J. McHugh, FRCP, Consultant Rheumatologist, Rheumatology Department, Royal National Hospital for Rheumatic Diseases.

Address correspondence to Dr. D. Jadon, Department of Rheumatology, Royal National Hospital for Rheumatic Diseases, Upper Borough Walls, Bath, BA1 1RL, UK. E-mail: jadondr@yahoo.com

Accepted for publication March 16, 2015.

Arthritis mutilans is a condition characterized by severe destruction of the joint and adjacent bone through erosion and subsequent osteolysis. As a result of soft tissue laxity and loss of bone stock, fingers and toes can shorten, giving rise to thick transverse folds of skin, and digits that can be elongated with traction. Two such cases were first described in 1913 by Marie and Leri, who compared the phenomena with the telescopic action of an opera glass (*la main en lorgnette*)[2]. Earlier in 1888, Bourdillon first reported a resorptive arthropathy associated with psoriasis[3]. Arthritis mutilans can occur in association with several diseases, including PsA (PAM)[1], rheumatoid arthritis[4,5], chronic reactive arthritis, juvenile chronic arthritis, and mixed connective tissue disease[6]. Its pathogenesis is unknown.

Research of PAM has been impeded by the rarity of the subphenotype and the lack of an agreed clinical or radiographic definition. Estimates of the prevalence of PAM in PsA cohorts range from 0.6% to 21%[1,7,8,9,10,11], but are likely to be closer to 5% as was originally described by Moll and Wright[1] and subsequently by others[9,10,11]. A population-based study estimated the prevalence of PAM in the adult Nordic

Personal non-commercial use only. The Journal of Rheumatology Copyright © 2015. All rights reserved.

Downloaded from www.jrheum.org on May 31, 2015 - Published by The Journal of Rheumatology

Janssen Biotech, Inc.
Exhibit 2074
Accord v. Janssen
IPR2026-00257
Ex. 2074-001

population to be 3.69 per million inhabitants, and with similar sex distribution[12]. Studies to date have been cross-sectional, with no longitudinal data. Reports are mostly case series[13,14,15], with a few studies of between 6 to 24 cases each[9,10,16,17,18,19], and only 1 large study of 59 cases[12]. The majority of studies simply note the occurrence of PAM in a general PsA cohort. To our knowledge, the natural clinical and/or radiographic history of PAM has never been described.

Our study objectives were (1) to compare the clinical characteristics of patients with PsA with PAM and without PAM (non-PAM), and (2) to determine the rate of PAM radiographic progression.

MATERIALS AND METHODS

A retrospective cohort study was conducted of all patients with PsA attending a dedicated PsA outpatient clinic at a secondary care teaching hospital. Patients attending the clinic had plain radiographs of hands and feet performed at intervals determined by usual clinical care, and dated from 1974 to December 1, 2013 (census). The case notes and clinical data collection proforma (from other prospective longitudinal studies at our institution) of PsA cases provided clinical data including sex, date of birth, age at psoriasis symptom onset, age at psoriasis diagnosis, age at PsA arthritis symptom onset, age at PsA diagnosis, smoking history (never, ever, current), alcohol consumption (never, ever, current), nail dystrophy at any time during disease course, most recent Stanford Health Assessment Questionnaire (HAQ) Disability Index[20], anticyclic citrullinated peptide antibodies serology, synthetic disease-modifying antirheumatic drug (DMARD) use (agent, date of initiation, date of cessation), biological therapy use [in particular anti-tumor necrosis factor-α (anti-TNF; agent, number of biologicals used, date of initiation, date of cessation)], and corticosteroid use (in oral, intramuscular, or intravenous form).

Peripheral radiographic scoring methods. Because no existing plain radiographic score for PsA detects the various radiographic features of PAM, components of existing radiographic tools were used. Plain radiographs of hands and feet were quantitatively scored for osteolysis, erosion (using the PsA-modified Sharp score; mSS)[21,22], joint space narrowing (JSN; mSS), osteoproliferation (PsA Ratingen Score)[23], periostitis (mSS), tuft resorption (mSS), and osteopenia using the PsA-modified Steinbrocker score[24]. A new domain to score osteolysis was devised to aid the detection of PAM and record progression with a range of 0 to 12, and based upon lysis of bone from the articular surface of the epiphysis, through the metaphysis, to the diaphysis (Figure 1).

Reading strategy and reliability exercise. Standard digital anteroposterior (AP) radiographs of the hands and feet were viewed and scored using the hospital's Picture Archiving and Communication System (PACS). Historical hard-film plain radiographs, preceding the advent of PACS in our institution (February 2007), were digitized to HiPAX Image Viewer for scoring. All images were read on the same viewing monitor preserved at the original 1:1 ratio. All radiographs included a "phantom phalanx" as a reference for normal bone mineral density.

The 2 readers (DJ, WT) underwent prestudy training in the precise definitions of radiographic findings of PsA[25], and had practice, supervision, and discussion with an experienced consultant musculoskeletal radiologist (GR). To determine interrater reliability, 10 random pairs of hand and feet radiographs were scored by both readers in random order.

Identification of PAM cases. In keeping with previous publications on PAM[8,16,17], plain radiographic PAM was defined as osteolysis affecting ≥ 50% of the visualized articular surface on both sides of the joint. A large erosion was qualified as osteolysis once the epiphyseal plate was encroached. PAM was, therefore, only called once the osteolysis score in an individual joint was ≥ 4 units.

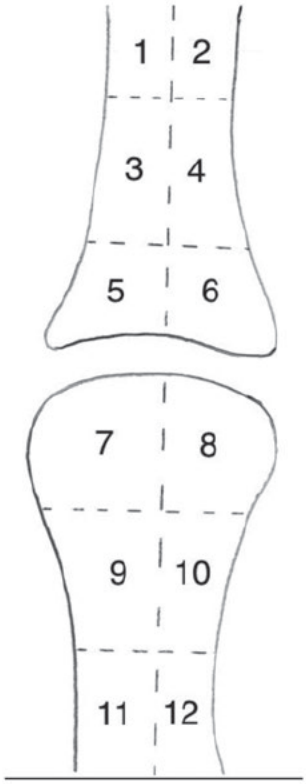

Figure 1. Osteolysis score (range 0–12). Osteolysis is scored as blocks of bone. Either side of the joint, there are 2 blocks in the epiphysis, 2 blocks in the metaphysis, and 2 blocks in the diaphysis.

The most recent plain radiographs of hands and feet were evaluated for PAM (DJ). Group consensus (DJ, WT, NM, GR) was sought for uncertain cases. All available radiographs of PAM cases (earliest to most recent) were then randomized and scored by the 2 readers (DJ, WT).

Axial radiographic scoring methods. All cases had their most recent axial plain radiographs (cervical spine, lumbar spine, and sacroiliac joints as available) scored for evidence of radiographic spondylitis and/or sacroiliitis by 1 reader (DJ) following education and practice with GR. In keeping with previous publications[26,27], radiographic axial disease was defined as the presence of the New York criteria unilateral grade ≥ 3, or bilateral grade ≥ 2 sacroiliitis on AP pelvic radiograph, and/or ≥ 1 marginal/paramarginal syndesmophyte(s) of the cervical or lumbar spine.

Statistical analysis. Data were analyzed using "R"[28]. Interrater reliability testing was performed using ICC.

For univariate analyses, continuity-corrected chi-square tests were used to test for differences between categorical variables, and independent Student t tests or Mann-Whitney U tests used for normally or non-normally distributed continuous variables, respectively. Unadjusted OR, associated 95% CI, and p values using an α-level of 0.05 were calculated.

Multivariate analysis was performed to compare the prevalence of axial radiographic disease in PAM and non-PAM using a logistic regression with adjustment for sex and age at most recent pelvis radiograph. Multivariate analysis was performed to compare HAQ scores in PAM and non-PAM using a zero-inflated Poisson regression[29] with adjustment for sex and age at HAQ assessment.

Patterns and rates of deterioration of individual joints over time were examined for all patients. Initial analysis consisted of plotting the data together with locally weighted polynomial regression smoothers (LOWESS)[30]. Formal modeling of the changes in scores over time was

Personal non-commercial use only. The Journal of Rheumatology Copyright © 2015. All rights reserved.

Downloaded from www.jrheum.org on May 31, 2015 - Published by The Journal of Rheumatology

performed using generalized additive mixed models[31] using penalized splines to assess the complexity of the model required for each joint and allowing a random effect for each patient. For each joint, the required complexity was expressed as the effective degrees of freedom (EDF). An EDF of 1 signifies a linear change in scores over time, i.e., a constant rate of deterioration from date of diagnosis, with larger values indicating that rates of deterioration over time are more complex.

Ethical considerations. Ethical approval for the study was given by the local regional ethics committee and informed written consent obtained from participants.

RESULTS

A total of 610 PsA cases fulfilling the ClASsification for Psoriatic ARthritis (CASPAR) criteria[32,33] were screened for the presence or absence of plain radiographic PAM. Of the 610 cases, 36 (5.9%) had PAM, with 35/36 having serial radiographs. Of the 610 cases, 483 had no evidence of PAM, and 91 either had no radiographs of hands and feet or only 1 of the 2 sites were imaged, and therefore although unlikely, PAM could not be excluded.

Interrater reliability of plain radiographic scoring. The interrater reliability of peripheral plain radiographic scoring was very high: ICC 0.99 (95% CI 0.98–1.00) for osteolysis, ICC 0.95 (95% CI 0.91–0.99) for erosion, ICC 0.97 (95% CI 0.95–0.99) for osteoproliferation, and ICC 0.90 (95% CI 0.84–0.93) for osteopenia.

Clinical characteristics of PAM and non-PAM cases. The proportion of women in the PAM and non-PAM cohorts were similar (52.78 vs 47.20%, respectively, p = 0.52). PAM cases were younger at PsA diagnosis than non-PAM cases (median age 33.00 vs 40.00 years, p = 0.04), but no different in terms of age at PsA arthritis symptom onset (p = 0.119), psoriasis symptom onset (p = 0.86), psoriasis diagnosis (p = 0.79), or age at census (p = 0.05; Table 1).

Psoriatic nail dystrophy was far more prevalent in PAM cases than non-PAM cases (OR 5.43, 95% CI 2.21–13.30, p < 0.001; Table 2).

Physical function, as measured by the total HAQ, was more impaired in PAM cases compared to non-PAM cases on univariate analyses (median HAQ 1.25 vs 0.63, p = 0.04; Table 1). Using zero-inflated Poisson regression, the adjusted risk ratio (RR) was 1.12 (95% CI 0.86–1.45, adjusted p = 0.41). Differences in subdomains of the HAQ between the PAM and non-PAM cases were clinically significant, and approached statistical significance for the HAQ-reach domain (RR 1.34, p = 0.05) and the HAQ-activity domain (RR 1.50, p = 0.09), with differences in other subdomains being statistically nonsignificant.

For the patients in whom anticitrullinated protein antibodies (ACPA) serology was available, no difference was demonstrated in ACPA positivity in PAM (0/16) compared with non-PAM cases (8/226, p = 0.44; Table 2).

PAM cases were more likely to have radiographic axial

Table 1. Clinical characteristics of PAM and non-PAM cases (numerical variables).

Clinical Variables		PAM, n = 36		Non-PAM, n = 483		RR	p	Adjusted p
		Median	IQR	Median	IQR			
Age at, yrs	Psoriasis symptom onset	29.00	16.00–45.00	28.00	18.00–42.00		0.86	
	Psoriasis diagnosis	30.00	16.00–52.00	33.00	21.00–47.00		0.79	
	PsA symptom onset	32.00	23.00–45.00	38.00	28.00–49.00		0.12	
	PsA diagnosis	33.00	24.00–45.00	40.00	30.00–51.00		0.04	
	Census	67.37	51.56–73.53	59.05	48.54–67.73		0.05	
HAQ, n = 34/36 PAM, 439/483 non-PAM	Total score	1.25	0.38–2.13	0.63	0.13–1.38	1.12*	0.04	0.41*
	HAQ-dressing	1.00	0.00–2.00	1.00	0.00–2.00	1.22*	0.17	0.31*
	HAQ-rising	1.00	0.00–2.00	1.00	0.00–1.00	1.36*	0.35	0.22*
	HAQ-eating	1.00	0.00–2.00	1.00	0.00–1.00	1.34*	0.03	0.11*
	HAQ-walking	1.00	0.00–2.00	0.00	0.00–2.00	0.94*	0.04	0.81*
	HAQ-hygiene	2.00	0.00–3.00	1.00	0.00–2.00	1.02*	0.04	0.93*
	HAQ-reach	2.00	1.00–3.00	1.00	0.00–2.00	1.34*	0.002	0.05*
	HAQ-grip	2.00	0.00–2.00	0.00	0.00–2.00	1.18*	0.02	0.43*
	HAQ-activity	1.00	0.00–2.00	1.00	0.00–1.00	1.50*	0.49	0.09*
Radiographic events	No. films scored per case	5.00	3.00–7.00					
	Interval: earliest to most recent film, yrs	10.87	5.48–16.51					
Age at, yrs	Earliest film	47.37	37.45–61.71					
	Recent film	64.54	49.71–70.37					
	Census	67.37	51.56–73.53					
PAM first demonstrated, restricted to cases with PAM onset during followup	Age, yrs	49.70	42.92–68.21					
	Yrs after diagnosis of PsA	12.50	6.00–18.00					

* Zero-inflated Poisson regression (adjusted for covariates: age at HAQ and sex). PAM: psoriatic arthritis mutilans; IQR: interquartile range; RR: risk ratio; PsA: psoriatic arthritis; HAQ: Health Assessment Questionnaire.

Personal non-commercial use only. The Journal of Rheumatology Copyright © 2015. All rights reserved.

Downloaded from www.jrheum.org on May 31, 2015 - Published by The Journal of Rheumatology

Table 2. Clinical characteristics of PAM and non-PAM cases (categorical variables).

Clinical Variable	PAM, n = 36		Non-PAM, n = 483		OR	95% CI	p	Adjusted p*
	Proportion	%	Proportion	%				
Female	19/36	52.78	228/483	47.20	1.25	0.63–2.46	0.52	
Nail dystrophy present								
	30/36	83.33	211/440	47.95	5.43	2.21–13.30	< 0.001	
ACPA-positive	0/16	0.00	8/226	3.54			0.44	
Axial disease								
Radiographic axial disease	16/29	55.17	129/366	35.25	2.31*	1.07–4.97*	0.04	0.03
Radiographic spondylitis	10/30	33.33	93/380	24.47	1.46*	0.65–3.28*	0.29	0.36
Cervical spine	6/27	22.22	57/352	16.19	1.35*	0.51–3.56*	0.42	0.54
Lumbar spine	5/24	20.83	44/332	13.25	1.64*	0.57–4.74*	0.30	0.36
Radiographic sacroiliitis	11/29	37.93	69/384	17.97	2.99*	1.33–6.73*	0.01	0.01
Symmetry								
Unilateral	2/11	18.18	13/69	18.84				
Bilateral	9/11	81.82	56/69	81.16				
Grade								
2	0/11	0.00	12/69	17.39				
3	7/11	63.63	52/69	75.36				
4	4/11	36.37	5/69	7.25				
DMARD use								
Yes	33/36	91.67	236/470	50.21	16.36	3.88–68.96	< 0.001	
Methotrexate	28/36	77.78	189/470	40.21	5.20	2.32–11.66	< 0.001	
Sulfasalazine	23/36	63.89	136/470	28.94	4.71	2.28–9.73	< 0.001	
Leflunomide	10/36	27.78	22/419	5.25	6.94	2.98–16.18	< 0.001	
Other	14/36	38.89	24/470	5.11				
DMARD initiated prior to PAM onset								
Yes	29/33	87.88						
No	4/33	12.12						
Never used DMARD	3/36	8.33						
Anti-TNF use								
Yes	13/36	36.11	150/483	31.06	1.25	0.62–2.54	0.53	
Anti-TNF initiated prior to PAM onset								
Yes	4/13	30.77						
No	6/13	46.15						
PAM onset date unknown	3/13	23.08						
Corticosteroid use								
Yes	15/36	41.67						

* Adjusted for sex and age at most recent pelvic radiograph. PAM: psoriatic arthritis mutilans; ACPA: anticitrullinated protein antibodies; DMARD: synthetic disease-modifying antirheumatic drug; anti-TNF: anti-tumor necrosis factor–α.

disease than non-PAM cases (adjusted OR 2.31, 95% CI 1.07–4.97, adjusted p = 0.03; Table 2). PAM cases were more likely to have radiographic sacroiliitis than non-PAM cases (adjusted OR 2.99, 95% CI 1.33–6.73, adjusted p = 0.01). When sacroiliitis was present in PAM cases, it tended to be bilateral (9/11, 81.82%) and of grade ≥ 3 (11/11, 100%; Table 2). PAM cases were no more likely to have radiographic spondylitis than non-PAM cases (adjusted OR 1.46, 95% CI 0.65–3.28, adjusted p = 0.36). When spondylitis was present in PAM cases, it affected both the cervical (6/27, 22.22%) and lumbar spines (5/24, 20.83%).

During the course of disease, PAM cases were more likely than non-PAM cases to have used a synthetic DMARD (OR 16.36, 95% CI 3.88–68.96, p < 0.001), including methotrexate (p < 0.001), sulfasalazine (p < 0.001), and leflunomide (p < 0.001; Table 2). Of particular note, 29/33 PAM cases (87.88%) had initiated a DMARD before PAM was first observed radiographically (a median of 6 yrs before), implying that DMARD did not prevent the onset of PAM.

PAM cases were no more likely than non-PAM cases to have been treated with an anti-TNF agent (OR 1.25, 95% CI 0.62–2.54, p = 0.53; Table 2). Four out of 13 PAM cases had initiated an anti-TNF before the onset of radiographic PAM (5.67, 3.89, 3.72, and 1.08 yrs beforehand). Six out of 13 PAM cases initiated an anti-TNF agent after PAM onset. Three out of 13 cases already had PAM at their earliest radiograph.

Fifteen out of 36 PAM cases (41.67%) had used corticosteroids during the course of their disease in oral, intramuscular, or intravenous form (Table 2).

Radiographic characteristics of PAM cases. The median number of films (pairs of hands and feet) scored per patient was 5 [interquartile range (IQR) 3–7; Table 1]. The median interval from baseline to most recent film (i.e., duration of

Personal non-commercial use only. The Journal of Rheumatology Copyright © 2015. All rights reserved.

Downloaded from www.jrheum.org on May 31, 2015 - Published by The Journal of Rheumatology

Ex. 2074-004

radiographic followup) was 10.87 years (IQR 5.48–16.51). The median age of PAM cases at the earliest film was 47.37 years (IQR 37.45–61.71), and at the most recent film was 64.54 years (IQR 49.71–70.37; Table 1).

While radiographic PAM was evident in the earliest film in 13/35 cases (37.14%), the majority of cases (22/35, 62.86%) developed it during the course of their followup (Table 3). In the 22 cases where PAM developed during the course of followup, the time from diagnosis of PsA to onset of radiographic PAM was a median of 12.50 years (IQR 6.00–18.00), at a median age of 49.70 years (IQR 42.92–68.21; Table 1).

PAM was most commonly monoarticular (21/35, 60%) when first demonstrated, but progressed to being polyarticular at the most recent film (28/35, 80%; Table 3). At the most recent film, the most frequently affected joint was the big toe interphalangeal joint (IPJ1; 8.81%), followed in equal frequency (6.92%) by the thumb metacarpophalangeal joint (MCPJ1), index finger distal interphalangeal joint (DIPJ2), little finger proximal interphalangeal joint (PIPJ5), and feet metatarsophalangeal joints 2 to 5 (MTPJ2–5; Figure 2).

Of note, 12/35 PAM cases (34.29%) had concurrent evidence of joint osteolysis and ankylosis within the same hand or foot (Table 3). Two out of 35 patients with PAM had proceeded to having surgery on the joint affected by PAM because of impaired hand function in 1 case, and pain in the other (Table 3).

Radiographic progression of PAM. Thirty-five out of 36 PAM cases had serial radiographs available for scoring. For hands and feet combined, at the most recent film, the median osteolysis score was 2.00 units (IQR 0.00–15.00), erosion score 9.00 units (IQR 0.00–26.00), JSN score 14.00 units (IQR 0.00–31.00), osteoproliferation score 3.00 units (IQR 0.00–6.00), and osteopenia score 0.00 units (IQR 0.00–2.00).

A significant change in osteolysis score over time was observed for all joints ($p < 0.008$). After allowing for patient differences in a random effects model, there was a strong indication that different joints had different patterns of deterioration over time ($p < 0.001$).

Table 3. Radiographic characteristics of PAM cases with serial radiographs (n = 35).

Radiographic Characteristics	n	%
PAM present on earliest radiograph	13/35	37.14
PAM pattern on earliest radiograph		
Monoarticular	21/35	60.00
Polyarticular	14/35	40.00
PAM pattern on most recent radiograph		
Monoarticular	7/35	20.00
Polyarticular	28/35	80.00
Concurrent joint ankylosis in hand/foot	12/35	34.29
Surgery to joint affected by PAM	2/35	5.710

PAM: psoriatic arthritis mutilans.

Figure 3 shows curves from the generalized additive mixed model, including data from all 159 joints affected by PAM. The best fit regression curve, 95% CI bands, and the EDF for each curve are shown for the hands and feet joints separately. In the feet, there is an initial high rate of osteolysis, followed by a tapering rate, and eventually little further progression of osteolysis (EDF = 3.1). However, in the hands, the curve is more complex (EDF = 4.3) with an initially high increase in osteolysis, followed by a tapering in the rate. For some patients, there was indication of a second surge of osteolysis in some joints later during disease course, adjusted for the time since diagnosis.

PAM cases with a history of psoriatic nail dystrophy (30/36) had significantly higher overall osteolysis scores in topographically related joints (DIPJ/PIPJ/IPJ) of the hands than those without nail dystrophy (6/36; mean scores 3.0 with nail dystrophy, 1.3 without nail dystrophy; $p = 0.03$).

DISCUSSION

We have taken advantage of a well-characterized cohort of patients with PsA followed longitudinally in a single center to compare the clinical characteristics of PAM and non-PAM cases, and to investigate the natural radiographic history of PAM. To our knowledge, this is the largest sample of PAM cases with a detailed description of plain radiographic characteristics, and the first study to report on radiographic progression.

A previous study by our group showed that nail dystrophy is more common in patients with PsA with DIP joint disease, and is significantly associated with adjacent DIP joint disease[33]. Here we demonstrate that psoriatic nail dystrophy is a clinical biomarker of both PAM occurrence and of having more severe osteolysis in topographically adjacent joints (hand DIP, PIP, and IP joints). This has not previously been reported, to our knowledge. Further, PAM was most commonly seen in the weight-bearing joints of the feet (MTPJ2–5, IPJ1) and hand joints involved in power/precision grip (DIPJ2, MCPJ1). Little is known about the pathogenesis or trigger for PAM. The concept of altered biomechanical loads or stress on the synovial-entheseal complex being involved in the pathogenesis of spondyloarthritis, as proposed by McGonagle, *et al*[34,35], is supported by our current findings in PAM.

There has been debate as to whether involvement of a single joint is sufficient for a case to be defined as PAM[36]. Our data indicate that 7/35 patients have monoarticular PAM (20%), even after several years of followup. Review of these 7 cases in our outpatient clinic demonstrated clinical evidence of PAM, with shortened telescopic digits. We therefore propose that PAM can be monoarticular, although it is more frequently polyarticular and the notion is supported by data from other studies[1,12,13,18].

Several of our results corroborate those of the CASPAR dataset[18], which showed that PAM cases are usually poly-

Personal non-commercial use only. The Journal of Rheumatology Copyright © 2015. All rights reserved.

Downloaded from www.jrheum.org on May 31, 2015 - Published by The Journal of Rheumatology

Ex. 2074-005

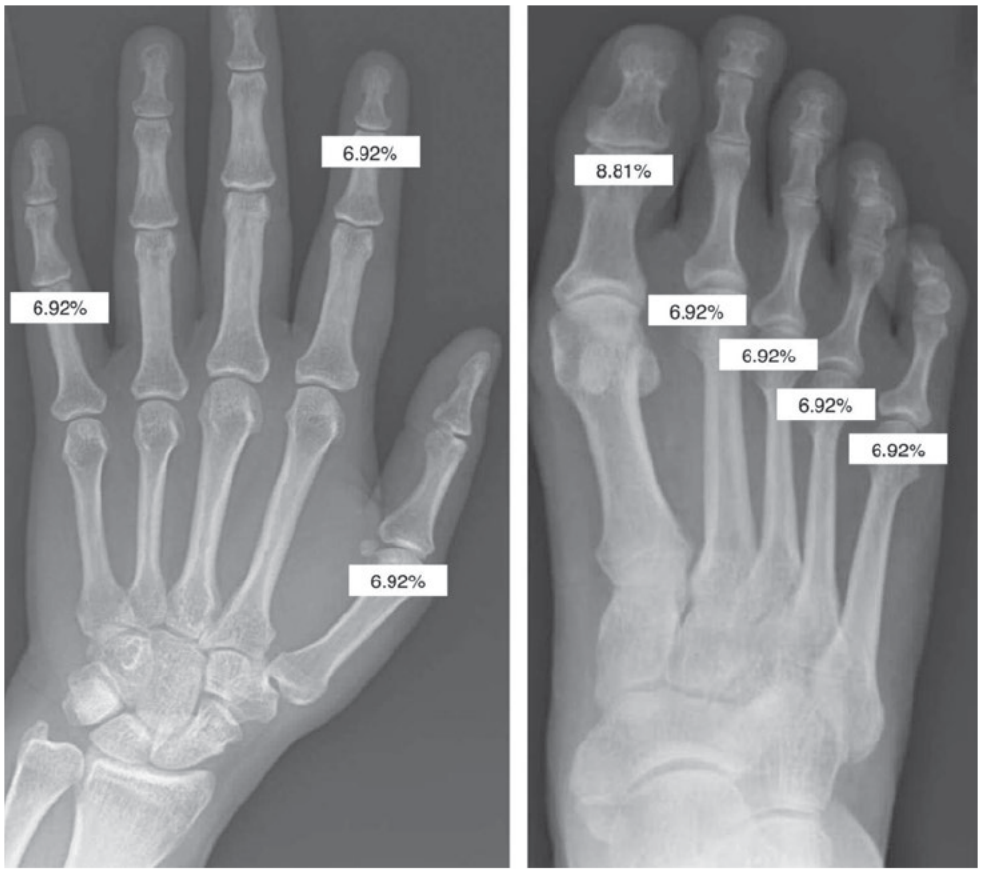

Figure 2. Eight joints most commonly affected by PAM at the most recent radiograph (frequency in percentages). PAM: psoriatic arthritis mutilans.

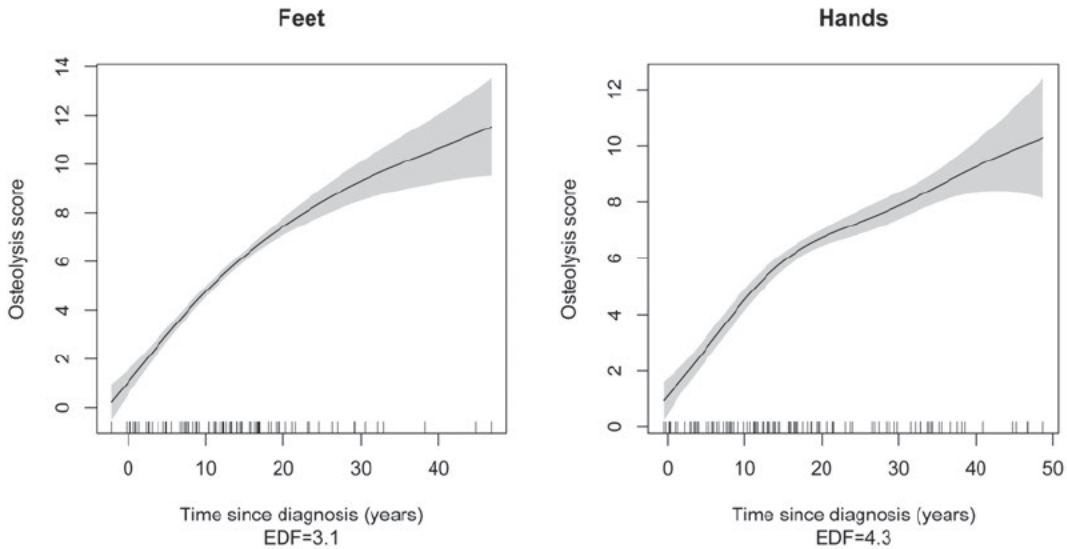

Figure 3. Rate of osteolysis progression over time (additive mixed model of all joints). Smoothed regression line (black), 95% CI bands (grey), and EDF (effective degrees of freedom).

Personal non-commercial use only. The Journal of Rheumatology Copyright © 2015. All rights reserved.

Downloaded from www.jrheum.org on May 31, 2015 - Published by The Journal of Rheumatology

articular, of long disease duration, and are more prone to spinal involvement compared with their non-PAM counterparts. In our cohort, there was a higher prevalence and severity of sacroiliitis in PAM cases than in non-PAM cases, and there was some increase in other features of spondylitis. However, we did not replicate the CASPAR findings of more frequent ACPA positivity (albeit of low titer) in PAM compared with non-PAM cases. Joint surgery rates in our cohort of PAM cases were far lower than the 48% reported by Helliwell[18].

A further intriguing issue is the nature of the relationship between osteolysis and ankylosis. In our dataset, 12/35 cases (34.29%) had concurrent osteolysis and ankylosis in the same hand or foot. Occasionally, osteolysis progressed to joint ankylosis in the same joint, but more commonly we saw JSN progressing to ankylosis, suggesting that there are 2 separate pathological processes, although both may occur in the same patient. Axial osteoproliferation causing cervical myelopathy in PAM despite peripheral bone erosion has been described[37].

None of our PAM cases had improvement of osteolysis, erosion, or osteoproliferation scores. JSN, osteopenia, and periostitis scores fluctuated with both regression and progression. There are emerging reports in the literature of improvement in erosion[38,39] and JSN[39] scores following anti-TNF use, implying filling-in or "healing" of previous structural damage. However, a paper reporting the followup of 3 PAM cases treated with etanercept demonstrated no improvement in deformities resulting from several years of progressive disease[14]. Further, our data suggest that neither synthetic DMARD nor anti-TNF prevent the onset of radiographic PAM. Our findings need to be interpreted with caution in a retrospective study where the radiographs were not taken at fixed-time intervals, hence sensitivity to detect PAM onset was reduced, and the doses of some agents such as methotrexate were lower than those currently used.

The sequence of pathological events leading to the frank osteolysis of PAM is of much interest, particularly because it could prompt the clinician to instigate more intensive disease-modifying therapy. Magnetic resonance imaging has demonstrated higher bone proliferation and edema scores in PAM compared with non-PAM cases, and has therefore been proposed as a potential radiological biomarker of progressing to PAM[16]. In our study, we did not see osteopenia or periostitis preceding the onset of erosions or osteolysis. Neither did we overtly see progressive erosions prior to the onset of osteolysis. However, we acknowledge that the varied time interval between radiographs may have reduced our sensitivity to track such changes. In our general observations, we noted progressive JSN prior to the onset of osteolysis.

We acknowledge that our study has limitations. While it appears that 36/519 of our cohort had PAM (6.94%), we are aware that 91/610 PsA cases had insufficient or no radiographs to assess the presence or absence of PAM. The lack of radiographs may imply minimal disease activity at these sites, or may be because of nonclinical factors. Assuming that all 91 were non-PAM cases, the prevalence of PAM in our cohort falls to 36/610 (5.90%). However, both estimates are within the range of prevalence described by other authors[1,7,8,9,10,11], especially those using a radiographic rather than clinical definition of PAM. Our hospital takes unselected secondary care referrals from the local community, spanning the spectrum of mild to severe PsA. Second, because the interval between films was determined by clinical need rather than predefined intervals, we were unable to determine the incidence of PAM onset. Because PAM was evident in the earliest available radiograph in 13/35 cases (37.14%), the initial rate of radiographic progression could not be determined in this subgroup of patients.

PAM is a rare but severely destructive subphenotype of PsA. Further research is needed to investigate the pathogenesis of PAM, the chronology of pathological events, genetic and/or serum soluble biomarkers of PAM, and whether anti-TNF or anti-resorptive agents may offer therapeutic efficacy.

REFERENCES

1. Moll J, Wright V. Psoriatic arthritis. Semin Arthritis Rheum 1973;3:55-78.
2. Marie P, Leri A. [A rare variety of chronic rheumatism: opera glass hands]. [Article in French] Bull Soc Med Hosp Paris 1913;36:104-7.
3. Bourdillon C. [Psoriasis and arthropathies]. [Article in French] Paris: 1888.
4. Nalebuff EA, Garrett J. Opera-glass hand in rheumatoid arthritis. J Hand Surg 1976;1:210-20.
5. Mody GM, Meyers OL. Resorptive arthropathy in rheumatoid arthritis. J Rheumatol 1988;15:1075-7.
6. Alarcón-Segovia D, Uribe-Uribe O. Mutilans-like arthropathy in mixed connective tissue disease. Arthritis Rheum 1979;22:1013-8.
7. Dhir V, Aggarwal A. Psoriatic arthritis: a critical review. Clin Rev Allergy Immunol 2013;44:141-8.
8. Haddad A, Chandran V. Arthritis mutilans. Curr Rheumatol Rep 2013;15:321.
9. Nossent JC, Gran JT. Epidemiological and clinical characteristics of psoriatic arthritis in northern Norway. Scand J Rheumatol 2009;38:251-5.
10. Reich K, Krüger K, Mössner R, Augustin M. Epidemiology and clinical pattern of psoriatic arthritis in Germany: a prospective interdisciplinary epidemiological study of 1511 patients with plaque-type psoriasis. Br J Dermatol 2009;160:1040-7.
11. Gladman DD, Antoni C, Mease P, Clegg DO, Nash P. Psoriatic arthritis: epidemiology, clinical features, course, and outcome. Ann Rheum Dis 2005;64 Suppl 2:ii14-7.
12. Gudbjornsson B, Ejstrup L, Gran JT, Iversen L, Lindqvist U, Paimela L, et al. Psoriatic arthritis mutilans (PAM) in the Nordic countries: demographics and disease status. The Nordic PAM study. Scand J Rheumatol 2013;42:373-8.
13. Bruzzese V, Marrese C, Ridola L, Zullo A. Psoriatic arthritis mutilans: case series and literature review. J Rheumatol 2013;40:1233-6.
14. Pomerantz RG, Mody E, Husni ME, Qureshi AA. Follow-up of psoriatic arthritis mutilans patients treated with anti-TNF-alpha therapy. J Drugs Dermatol 2009;8:406-12.
15. Bell L, Murphy CL, Wynne B, Cunnane G. Acute presentation of arthritis mutilans. J Rheumatol 2011;38:174-5.
16. Tan YM, Østergaard M, Doyle A, Dalbeth N, Lobo M, Reeves Q, et

Personal non-commercial use only. The Journal of Rheumatology Copyright © 2015. All rights reserved.

Downloaded from www.jrheum.org on May 31, 2015 - Published by The Journal of Rheumatology

al. MRI bone oedema scores are higher in the arthritis mutilans form of psoriatic arthritis and correlate with high radiographic scores for joint damage. Arthritis Res Ther 2009;11:R2.
17. Marsal S, Armadans-Gil L, Martínez M, Gallardo D, Ribera A, Lience E. Clinical, radiographic and HLA associations as markers for different patterns of psoriatic arthritis. Rheumatology 1999;38:332-7.
18. Helliwell PS. Established psoriatic arthritis: clinical aspects. J Rheumatol Suppl. 2009 Aug;83:21-3.
19. Rodriguez-Moreno J, Bonet M, Del Blanco-Barnusell J, Castaño C, Clavaguera T, Mateo-Soria L, et al. Mutilating/resorptive arthritis. A study of 24 patients in a series of 360 patients with psoriatic arthritis. Reumatol Clin 2013;9:38-41.
20. Blackmore MG, Gladman DD, Husted J, Long JA, Farewell VT. Measuring health status in psoriatic arthritis: the Health Assessment Questionnaire and its modification. J Rheumatol 1995;22:886-93.
21. Sharp JT, Bluhm GB, Brook A, Brower AC, Corbett M, Decker JL, et al. Reproducibility of multiple-observer scoring of radiologic abnormalities in the hands and wrists of patients with rheumatoid arthritis. Arthritis Rheum 1985;28:16-24.
22. Mease PJ, Kivitz AJ, Burch FX, Siegel EL, Cohen SB, Ory P, et al. Etanercept treatment of psoriatic arthritis: safety, efficacy, and effect on disease progression. Arthritis Rheum 2004;50:2264-72.
23. Wassenberg S, Fischer-Kahle V, Herborn G, Rau R. A method to score radiographic change in psoriatic arthritis. Z Rheumatol 2001;60:156-66.
24. Rahman P, Gladman DD, Cook RJ, Zhou Y, Young G, Salonen D. Radiological assessment in psoriatic arthritis. Br J Rheumatol 1998;37:760-5.
25. Taylor WJ, Porter GG, Helliwell PS. Operational definitions and observer reliability of the plain radiographic features of psoriatic arthritis. J Rheumatol 2003;30:2645-58.
26. Jadon D, Tillett W, Wallis D, Cavill C, Bowes J, Waldron N, et al. Exploring ankylosing spondylitis-associated ERAP1, IL23R and IL12B gene polymorphisms in subphenotypes of psoriatic arthritis. Rheumatology 2013;52:261-6.
27. Chandran V, Barrett J, Schentag CT, Farewell VT, Gladman DD. Axial psoriatic arthritis: update on a longterm prospective study. J Rheumatol 2009;36:2744-50.
28. Core TR. R: a language and environment for statistical computing. R foundation for statistical computing. [Internet. Accessed April 9, 2015.] Available from: www.r-project.org
29. Hall DB. Zero-inflated Poisson and binomial regression with random effects: a case study. Biometrics 2000;56:1030-9.
30. Cleveland WS. LOWESS: A program for smoothing scatterplots by robust locally weighted regression. Am Stat 1981;35:54.
31. Wood SN. Generalized additive models: an introduction with R. London: Chapman and Hall/CRC Press; 2006.
32. Taylor W, Gladman D, Helliwell P, Marchesoni A, Mease P, Mielants H; CASPAR Study Group. Classification criteria for psoriatic arthritis: development of new criteria from a large international study. Arthritis Rheum 2006;54:2665-73.
33. Tillett W, Costa L, Jadon D, Wallis D, Cavill C, McHugh J, et al. The ClASsification for Psoriatic ARthritis (CASPAR) criteria—a retrospective feasibility, sensitivity, and specificity study. J Rheumatol 2012;39:154-6.
34. McGonagle D, Thomas RC, Schett G. Spondyloarthritis: may the force be with you? Ann Rheum Dis 2014;73:321-3.
35. McGonagle D, Lories RJ, Tan AL, Benjamin M. The concept of a "synovio-entheseal complex" and its implications for understanding joint inflammation and damage in psoriatic arthritis and beyond. Arthritis Rheum 2007;56:2482-91.
36. Chandran V, Gladman DD, Helliwell PS, Gudbjörnsson B. Arthritis mutilans: a report from the GRAPPA 2012 annual meeting. J Rheumatol 2013;40:1419-22.
37. Ly J, Pinto C, Doyle A, Dalbeth N, McQueen FM. Axial bone proliferation causing cervical myelopathy in the mutilans form of psoriatic arthritis despite peripheral bone erosion. Ann Rheum Dis 2009;68:443-4.
38. Garcia-Valladares I, Cuchacovich R, Espinoza LR. Psoriatic arthritis: radiographic joint repair following etanercept therapy. J Rheumatol 2012;39:185.
39. Eder L, Chandran V, Gladman DD. Repair of radiographic joint damage following treatment with etanercept in psoriatic arthritis is demonstrable by 3 radiographic methods. J Rheumatol 2011;38:1066-70.

Personal non-commercial use only. The Journal of Rheumatology Copyright © 2015. All rights reserved.

Downloaded from www.jrheum.org on May 31, 2015 - Published by The Journal of Rheumatology