Eur Spine J
DOI 10.1007/s00586 014 3203 4

REVIEW ARTICLE

Ageing and degenerative changes of the intervertebral disc and their impact on spinal flexibility

Fabio Galbusera · Marc van Rijsbergen · Keita Ito · Jacques M. Huyghe · Marco Brayda-Bruno · Hans-Joachim Wilke

Received: 19 December 2012 / Revised: 16 January 2014 / Accepted: 17 January 2014
© Springer Verlag Berlin Heidelberg 2014

Abstract
Purpose Degeneration of the intervertebral disc is associated with various morphological changes of the disc itself and of the adjacent structures, such as reduction of the water content, collapse of the intervertebral space, disruption and tears, and osteophytes. These morphological changes of the disc are linked to alterations of the spine flexibility. This paper aims to review the literature about the ageing and degenerative changes of the intervertebral disc and their link with alterations in spinal biomechanics, with emphasis on flexibility.
Methods Narrative literature review.
Results Clinical instability of the motion segment, usually related to increased flexibility and hypothesized to be connected to early, mild disc degeneration and believed to be responsible for low back pain, was tested in numerous in vitro studies. Despite some disagreement in the findings, a trend toward spinal stiffening with the increasing degeneration was observed in most studies. Tests about tears and fissures showed inconsistent results, as well as for disc collapse and dehydration. Vertebral osteophytes were found to be effective in stabilizing the spine in bending motions.
Conclusions The literature suggests that the degenerative changes of the intervertebral disc and surrounding structures lead to subtle alteration of the mechanical properties of the functional spinal unit. A trend toward spinal stiffening with the increasing degeneration has been observed in most studies.

Keywords Disc degeneration · Biomechanics · Annular tears · Osteophytes · Disc collapse · Motion segment

F. Galbusera (✉) · M. Brayda Bruno
IRCCS Istituto Ortopedico Galeazzi, via Galeazzi 4, 20161 Milan, Italy
e mail: fabio.galbusera@grupposandonato.it

M. van Rijsbergen · K. Ito · J. M. Huyghe
Orthopaedic Biomechanics, Department of Biomedical Engineering, Eindhoven University of Technology, Eindhoven, The Netherlands

H. J. Wilke
Institute of Orthopedic Research and Biomechanics, Center of Musculoskeletal Research Ulm, University of Ulm, Ulm, Germany

Introduction

Degeneration of the intervertebral disc is associated with various morphological changes of the disc itself and of the adjacent structures, such as collapse of the intervertebral space, water and proteoglycan content reduction and damage and sclerosis of the vertebral endplates or osteophytosis [12, 76]. These changes have an influence on the biomechanics of the motion segment, which may exhibit abnormal mobility and loss of its mechanical properties, therefore having in turn an impact on the progression of the degenerative disease.

This paper reviews published studies on the biomechanics of intervertebral discs showing macroscopic changes due to degenerative disc disease, with special emphasis on the spinal flexibility. Following an introduction to the functional anatomy and biomechanics of the healthy disc, macroscopic degenerative changes are described with focus on their possible relevance to low back pain. Published studies on the biomechanical impact of the most important degenerative changes of the disc, i.e. tears and fissures, osteophytes, dehydration and collapse of

Published online: 31 January 2014

MEDTRONIC EXHIBIT 1021

the intervertebral space, are also presented and discussed. Relevant topics not directly linked to the degeneration of the intervertebral disc (e.g. disc herniation and endplate lesions) were not included in the present paper. Furthermore, disc loading and its alteration due to degeneration were out of the scope of the present review, since they are covered in another paper in the same issue [48].

It should be noted that the reviewed biomechanical studies, being mainly based on the mechanical response of cadaveric specimens or numerical simulations, do not directly address the mechanisms of low back pain and have therefore little value in determining why disc degeneration may result in a painful condition, and why in some cases degenerated discs are asymptomatic.

Functional anatomy of the intervertebral disc

The intervertebral disc is a fibrocartilaginous joint connecting two adjacent vertebral bodies, which distributes loads to the osseous structures and allows for a certain degree of motion in different directions (Fig. 1) [75]. The central nucleus pulposus (NP) consists of a water-based gel-like substance rich in proteoglycans (approximately 250 μg/mg dry tissue weight [33]) and a small amount of collagen type II and elastin fibers [75]. The annulus fibrosus (AF) encloses the nucleus with a collagen type I-based concentric lamellar structure. Within each lamella, the collagen fibers are aligned approximately 30° with respect to the transverse plane of the vertebral endplates. The angle of collagen fibers also alternates with respect to the same plane between adjacent lamellae. Between lamellae, there are occasional radial connecting collagen bundles [60], but most of the lamellae are filled with a proteoglycan-rich gel. The intervertebral disc is connected to the vertebral bodies through the endplates, which consist of osseous and hyaline-cartilaginous layers [75]. The cartilaginous endplate covers only the NP and the inner AF; the collagen fibers of the outer AF anchor directly into the bone of the apophyseal ring [61]. The collagen fibers of the inner AF and the NP are contiguous with that in the cartilage endplate and can transmit considerable tensile loads to the osseous endplates [72]. Between the NP and the inner AF there is no distinct border; rather a slow transition between tissue type. This is often referred to as the transition zone [14, 73].

Due to its specific structure, the IVD is capable to withstand high compressive loads. Proteoglycans synthesized by the NP cells, in particular aggrecan, are highly negatively charged. These fixed charges are electrically balanced by positive cations in the interstitial fluid. This higher concentration of cations gives the disc an osmotic pressure (Donnan equilibrium) with respect to the external

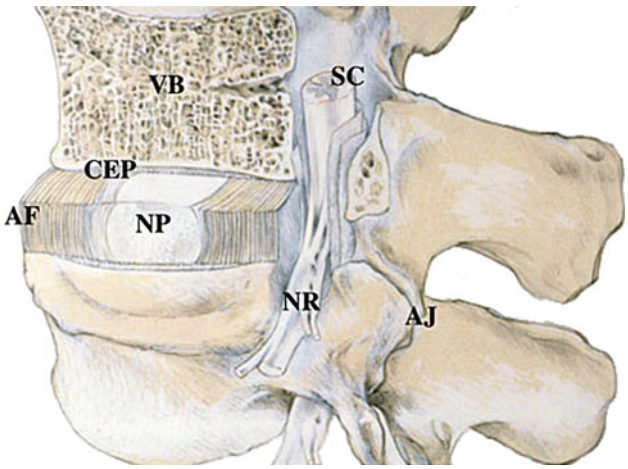

Fig. 1 A schematic of the intervertebral disc: the central nucleus pulposus (*NP*), surrounded by lamellae of the annulus fibrosus (*AF*), located between the vertebral bodies (*VB*) and separated by the cartilaginous endplates (*CEP*). Spinal cord (*SC*), nerve roots (*NR*) and apophyseal joints (*AJ*) are also shown (reproduced from [67])

environment and, thus, the capacity to attract and imbibe water [66]. Due to its high water content, low permeability and osmotic properties, the nucleus is, therefore, able to sustain high compressive forces [4]. The NP swelling pressure is balanced by the hydrostatic pressure, which is a result of the NP being contained by the endplates and the AF. Both at rest and under active loading, the pressure in the NP is balanced by tensile stresses in the AF, which limit bulging and avoid collapse of the disc under compression [75]. To withstand the other types of loading from daily activities, such as bending and shear in multiple directions, the unique lamellar structure of alternating collagen fibers in the AF is loaded primarily in tension, similar to the fiber reinforcement of a tire, when combined with an almost iso-volumetric NP core.

Finally, the endplates contribute to the even distribution of the pressure acting within the nucleus and tension in the annulus on the vertebral bodies [2]. The viscous fluid flows through the endplates, allowed by their permeable nature, and the viscoelastic stretching nature of collagen networks in the annulus allows the disc to dampen loads. Due to this fluid exchange, the IVD exhibits the creep and relaxation behavior under sustained loads typical of a damper, i.e. when subjected to the body weight for 4 h, a lumbar IVD expels 10 15 % of its water content through the endplates [1].

Ageing and degenerative changes of the intervertebral disc

The ageing intervertebral disc usually shows several changes in comparison to the young, healthy disc, even in asymptomatic subjects [28]. The boundary between

physiologic disc ageing and degenerative disc disease is not always clear, since in most cases ageing and degenerative changes do not substantially differ. Disc degeneration has been defined as an accelerated ageing process including structural failure [4]. Nevertheless, purely physiological ageing changes such as water loss and thus the so-called "black disc" have been also referred to as disc degeneration [52], thus promoting confusion in the literature due to different definitions of disc degeneration. The following paragraphs are based on the aforementioned definition by Adams [4].

Cellular and matrix changes

In general, physiological ageing changes start in the endplates and then sequentially affect the nucleus and the annulus [4]. Cell density in the intervertebral disc starts to decrease during childhood [68]. The loss of cellularity leads to a decrease and fragmentation of the proteoglycan content [13], especially in the nucleus, and to a reduction of matrix turnover which, in turn, induces cross-linking of collagen fibrils that reduces the self-repairing capability of the disc [16, 59]. The loss in proteoglycan content is further worsened by a reduction in the per-cell synthesis rate, which is probably related to cell senescence [44].

These cellular and biochemical changes determine alterations in the extracellular matrix. During the whole ageing sequela, a progressive loss of the water fraction in the whole disc (due to the reduction of the proteoglycan content and, therefore, of the osmotic gradient) and a corresponding increase in the fibrotic tissue are generally observed [3, 4]. Within the nucleus pulposus, the water content was found to decrease from 5.8 gH_2O/g dry weight at an age of 14 years (85 % volume fraction) to 3.3 gH_2O/g dry weight at age 91 years (75 %) [66]. For the NP, primarily, a loss of proteoglycans was observed [7, 34]. For the AF, a change in water content, although to a more limited extent in comparison with the NP, as well as collagen content is observed during ageing [7]. The decrease in the proteoglycan content is linked to a reduction of the swelling pressure, for which values ranging from 0.19 MPa (age of 37 years) to 0.05 MPa (age of 91 years) were measured [66].

Structural changes

In addition to or perhaps because of matrix content changes, the intervertebral disc also undergoes structural failure showing tears and clefts [69] (Fig. 2). Although these abnormalities may be related to each other, and gradually overlap the physiological ageing course [12], in most of the literature they are described and defined as degenerative disc disease [4, 76] and are, therefore, clearly distinct from natural ageing. An analysis of midsagittal sections of cadaveric specimens showed that more than 50 % of intervertebral discs in the third and fourth decade of life exhibit annular tears and fissures [40]. Tears were shown to have different orientations and extents and are classified following the terminology shown in Fig. 3 (adapted from [69]). Concentric and radial tears were found to be frequent in young discs as well as in specimens harvested from elderly donors. However, studies showed that the presence of radial tears increases with ageing [28, 30]. Rim lesions and endplate separations had higher incidence in the 50 80 age group [69].

Changes to the endplate are also observed [52, 76]. During degeneration, the endplates calcify and become sclerotic [8, 57, 58]. Although the hypothesis of an endochondral ossification process in the cartilaginous endplate related to changes in load transfer from the NP to the AF is, as yet, unproven, it does have several biomechanical consequences; for example, significantly less flexible endplates that are prone to fracture, altered load transfer to vertebrae and reduced water and solute exchange between the disc and the vertebrae.

Disc height is generally not affected [10, 18] or even slightly increased [6] in the physiological ageing process, whereas collapse of the intervertebral space is common in pathological disc degeneration [46, 52, 64, 76].

Finally, formation of osteophytes around the margins of the vertebral bodies is a common observation associated with disc degeneration [52, 64, 76]. It has been estimated that 25 % of subjects in their third decade and 90 % in their sixth decade have at least one vertebral osteophyte [47]. Osteophytes are believed to be an adaptive remodeling process that stabilizes an unstable spine segment. This statement has been confirmed by in vivo experiments in rabbits in which osteophyte growth was observed in the adjacent vertebrae after artificial lesions in the anterior annulus fibrosus [43].

Discogenic pain

Degenerative disc disease is believed to be the major cause of mechanical or axial back pain [15, 42], defined as back pain determined by loss of integrity of the spinal structures. Degenerated discs with structural abnormalities have been found to be more strongly correlated with discogenic pain than the normal changes with age [17]. Severely degenerated discs, including collapsed, prolapsed discs and discs showing leaking radial tears, exhibited a higher penetration of nociceptive nerve fibers toward the nucleus center [17, 70, 71]; this phenomenon has been associated with increased back pain [22]. Endplate lesions and irregular endplate loading were also found to be correlated with back pain history [74]. In addition to this, due to the loss of

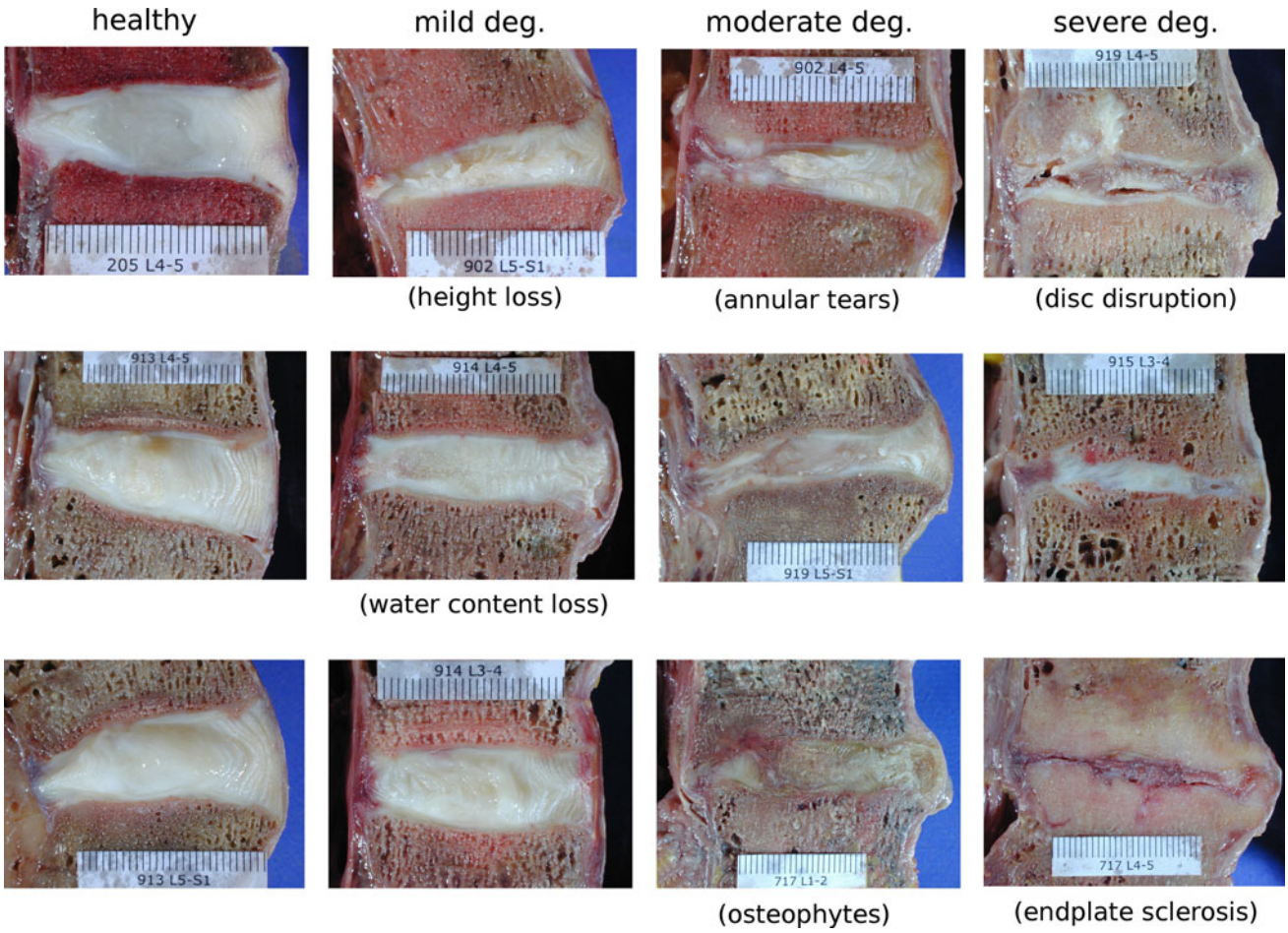

Fig. 2 Sagittal sections of human lumbar intervertebral discs in various stages of degeneration. The most relevant degenerative changes observable are pointed out in brackets

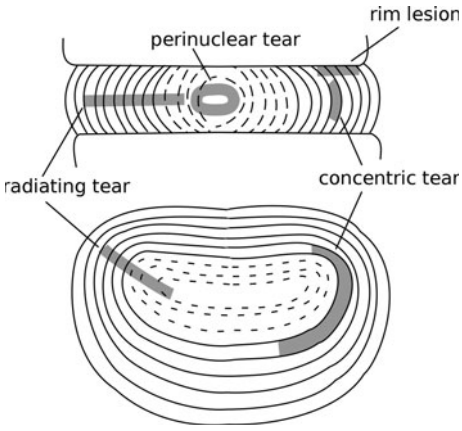

Fig. 3 Classification of tears of the intervertebral disc (adapted from [69])

height, the vertebral bodies approach one another. Because the vertebral body is not only moving downwards but also backwards, in some cases the nerve root may be displaced cranially into a small space, close to the capsule joint, thus determining radicular pain [29]. Pain due to disc degeneration is usually exacerbated by specific body positions, e.g. sitting [36], and certain movements, for example twisting and lifting weights [11], because the facet impinges against the nerve root which leads to pain. Another important cause of axial back pain is facet joint osteoarthritis, which consists in the decrease of the thickness and regularity of the cartilage layer of the facet joints, also called apophyseal or zygoapophysial joints. Disc degeneration and facet joint osteoarthritis are commonly observed together in the same patient and spinal level [20, 26, 35] and a possible correlation between these two pathologies is currently debated [62].

Biomechanics of the degenerated motion segment

Flexibility

The aforementioned degenerative changes of the intervertebral disc are believed to be significantly correlated with alterations of the flexibility of the motion segment.

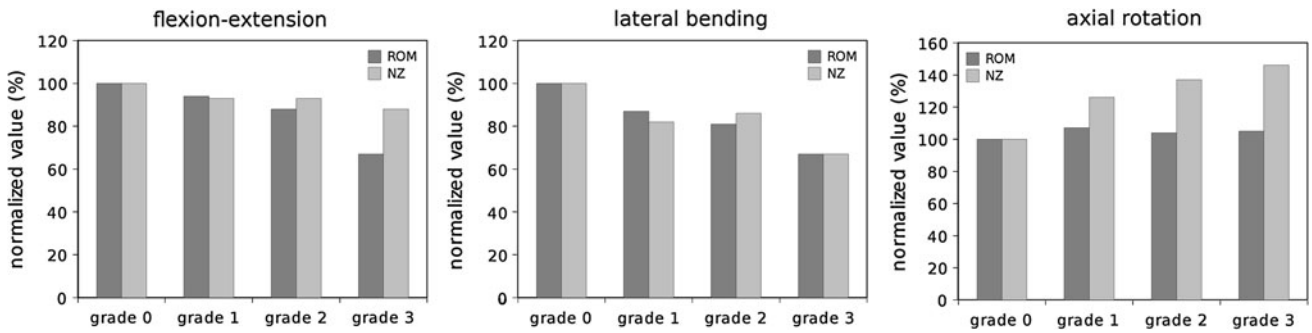

Fig. 4 Mean values of the range of motion (*ROM*) and neutral zone (*NZ*) for motion segments in different degrees of degeneration relative to non degenerated (grade 0) specimens [37]. The degenerative degree is graded radiographically following the scale introduced by Wilke et al. [76]

Kirkaldy-Willis and Farfan [38] hypothesized that the course of disc degeneration is characterized by three stages: temporary dysfunction, instability and stabilization. Instability was, therefore, connected to early, mild disc degeneration and believed to be the main factor responsible for low back pain. Other papers further developed the subject, e.g. providing a clear definition for spinal instability as an abnormal response to physiological loads, with reduced spinal stiffness and greater motion [55]. This rationale provided a basis for fusion techniques [19], with which the mobility of the spinal segment is eliminated. However, 10 years later, the first follow-up study reporting on a surgical implant that restricts the flexibility of the motion segment [25], but preserved some degree of possible motion, i.e. dynamic stabilization devices, was published. Since then, multiple devices were developed and are currently widely employed.

The hypothesis of increased flexibility for early, mildly degenerated discs was tested in numerous in vitro studies. Some papers have reported an increment in spinal flexibility for mild degeneration [20, 41, 63] while other investigations have found either an increase in spinal stiffness with progressing degeneration [37, 45, 78] or a combination of both [50]. Tanaka et al. [63] found maximal flexibility in axial rotation in the lower lumbar spine for the grade III of the Thompson scale [64], whereas minimal changes in the spine motion were found in flexion, extension and lateral bending. Similar results were reported by Fujiwara et al. [20] who found maximal range of motion for spine specimens of grade IV of the Thompson scale in flexion, extension and axial rotation, and for grade III in lateral bending. Both papers showed reduced mobility for severely degenerated spines (grade V). Krismer et al. [41] did not analyze flexion extension, but found increased flexibility of lumbar specimens in axial rotation and lateral bending starting from grade III. On the contrary, a recent study [9] reported increased range of motion only in axial rotation for severely degenerated specimens (grade IV, V), whereas in flexion extension and lateral bending disc degeneration was correlated with decreased flexibility. These findings are in general good agreement with the widely cited study by Mimura et al. [45], which showed reduced flexibility in flexion extension and lateral bending and higher flexibility in axial rotation. The most comprehensive study consisted of a retrospective analysis of a large database of in vitro results, including tests carried out on 203 motion segments harvested from 111 donors; it showed that spinal stiffness increased in flexion/extension and lateral bending from no to severe degeneration (Fig. 4) [37]. No changes in the range of motion were observed in axial rotation. However, some specific motion segments showed reduced stiffness for mild degeneration.

As a matter of facts, there is no evidence supporting a clear clinical significance of instability in the diagnosis and treatment of disc degeneration. These findings pose questions on the current indications of dynamic stabilization systems, which may be restricted to cases in which the instability is actually proven, e.g. with radiographic investigations or when decompression, and subsequent iatrogenic destabilization is necessary. It should be noted, however, that these findings were derived under different conditions and are therefore only partially comparable.

Neutral zone

A parameter frequently involved in the analysis of clinical instability is the neutral zone [51]. Based on the observation that patients suffering from low back pain had increased anteroposterior translation in the lumbar spine [24, 39], Panjabi redefined the concept of clinical instability based on the capability of the stabilization systems of the spine (passive structures, muscles, possible instrumentation) to restrain the neutral zone within the physiological limits. The evaluation of the neutral zone of spine specimens as an indicator of clinical instability was therefore a logical consequence and was therefore performed in a number of studies.

From early studies, consensus about an increase of the size of the neutral zone in all the three main directions for degenerated discs seemed to emerge [45, 51]. More recently, other studies either confirmed these trends [23] or showed no or hardly any change in its size between healthy and degenerated motion segments [63]. In the aforementioned retrospective paper about a wide number of degenerated specimens [37], an increase in the neutral zone was found only in axial rotation, and was not limited to mild degeneration, but progressed with the presence of severe degenerative changes (Fig. 4). However, the hypothesis that neutral zone may be more sensitive to the degree of disc degeneration in comparison with the range of motion [51] seems to be reasonable. The use of dynamic stabilization devices may therefore find a more solid justification as means to reduce the neutral zone rather than the range of motion.

Influence of the specific degenerative changes on the motion segment biomechanics

Disruptions and tears

The consequences and influence of the presence of tears on the biomechanics of the motion segment are still a debated research question that has been investigated in a few papers. It is generally believed that disc disruptions and tears are the main factors responsible for the clinical instability in mild degeneration, as hypothesized by Kirkaldy-Willis and Farfan [38]. This statement is not supported by available biomechanical studies, which are, however, not conclusive. Tanaka et al. [63], for example, showed increased flexibility of human spine segments exhibiting radial tears but other degenerative changes were also present in the investigated specimens, thus disguising the specific mechanical effect of tears. This topic was more specifically investigated in another in vitro study on 15 sheep non-degenerated lumbar motion segments in which concentric, radial tears and rim lesions were artificially created in fixed locations [65]. Rim lesions were the only type of disruptions that reduced the stiffness of the motion segment, especially in lateral bending and axial rotation. Concentric and radial tears had no effect on the joint stability, in terms of flexibility and neutral zone. However, all tears changed the hysteresis energy dissipation characteristics of the specimens, indicating that the stress distribution inside the intervertebral disc has been altered. The authors concluded that this alteration may lead to overloading of the other structures, i.e. ligaments and facet joints, thereby inducing a progression of the degeneration of the motion segment. In another study [56], rim lesions have been shown to have a negligible effect in determining the stresses inside the intervertebral disc when compared to endplate fractures.

Osteophytosis

Few in vitro studies investigating the mechanical effects of vertebral osteophytes exist but the concept that osteophytes are an adaptive reaction to stabilize the motion of unstable spines, rather than a degenerative phenomenon, seems to be supported by the currently available data. Tanaka et al. [63] and Fujiwara et al. [20] showed that there is a stiffness increase in the degenerative degrees including osteophytosis. However, these studies cannot be considered conclusive in this regard due to the presence of other degenerative changes of the spine such as disc disruption and disc height collapse. A more specific in vitro investigation conducted on 20 human motion segments showed comparable results [5]. Vertebral osteophytes were found to stabilize the spine from 35 to 49 % in bending motions, and less effectively (15 %) in compression. The mechanical effect of osteophytes tended to increase with the size of the spurs.

Matrix changes

Disc degeneration compromises the capacity of the intervertebral disc to imbibe water and swell. As shown by Johannessen et al. for the NP [34] and Iatridis et al. [31, 32] and Gu et al. [27] for the AF, these changes affect the biomechanical behavior of the disc. Due to the reduction of the proteoglycan content in the NP, the swelling capacity of the NP tissue decreases significantly; at the same time, due to breakdown of collagen, the permeability of the tissue increases. Because of these changes, the water can be more easily squeezed out of the tissue and the NP tissue may not be as successful in withstanding high loads for a long period of time compared to a healthy NP. With regard to the AF, a disappearance of nonlinear behavior under compression, which can be explained by the change in water and collagen content [32], has been reported. Permeability of the AF tissue changes from a highly anisotropic behavior to a more uniform behavior, independent of the direction. Due to the stiffening of AF and the reduced load carrying capacity of the NP, the AF becomes the major load bearing component of the intervertebral disc [4].

The mechanical effect of these degenerative changes is not fully understood and scarcely investigated, although Zhao et al. [77] showed increased flexibility and neutral zone after dehydration of the NP in vitro by applying a sustained compressive load that caused a reduction of the disc height. This indicates that these changes lead to instability of the whole motion segment.

Collapse of the intervertebral space

Numerical models were used to assess the effect of the reduction of disc height as a consequence of dehydration. This approach allows for studying the effect of single degenerative parameters, keeping the other degenerative characteristics unaltered. Coherently with Tanaka et al. [63], Galbusera et al. [21] found increased compressive and flexion extension stiffness of the spinal segment with the decreasing disc height. These results were confirmed by a probabilistic numerical model targeted to the investigation of the effect of the anatomical variability of the spine [49].

Besides the biomechanics of the spine, the reduction in height of the disc directly effects the adjacent vertebrae; it can lead to an increase of more than 50 % of the compressive force on the lumbar spine being resisted by the neural arch [54], while, at the same time, a reduction of force in the vertebral bodies could lead to bone mass loss due to unloading [53]. Such changes in loading pattern, as well as narrowing discs, are also associated with osteoarthritis in the apophyseal joints [20].

Conclusions

Biomechanical investigations do not provide insights about the mechanisms of low back pain, but have great value for the understanding of progression of disc degeneration and possible surgical treatments. The literature suggests that the degenerative changes of the intervertebral disc and surrounding structures lead to subtle alteration of the mechanical properties of the functional spinal unit. A trend toward spinal stiffening with increasing degeneration has been observed in most studies, although conclusive studies regarding some aspects are lacking. Evidence supporting a general increase of spinal instability with disc degeneration could not be found.

Acknowledgments All co authors of this review wish to thank Dr. Michelle Kümin for her helpful revision of this manuscript. Part of the studies cited in the present review has received funding from the European Community's Seventh Framework Programme Genodisc (FP7, 2007 2013) under Grant agreement No. HEALTH F2 2008 201626.

Conflict of interest None.

References

1. Adams MA, Hutton WC (1983) The effect of posture on the fluid content of lumbar intervertebral discs. Spine (Phila Pa 1976) 8:665 671
2. Adams MA, McMillan DW, Green TP, Dolan P (1996) Sustained loading generates stress concentrations in lumbar intervertebral discs. Spine (Phila Pa 1976) 21:434 438
3. Adams MA, McNally DS, Dolan P (1996) 'Stress' distributions inside intervertebral discs. The effects of age and degeneration. J Bone Joint Surg Br 78:965 972
4. Adams MA, Roughley PJ (2006) What is intervertebral disc degeneration, and what causes it? Spine (Phila Pa 1976) 31:2151 2161
5. Al Rawahi M, Luo J, Pollintine P, Dolan P, Adams MA (2011) Mechanical function of vertebral body osteophytes, as revealed by experiments on cadaveric spines. Spine (Phila Pa 1976) 36:770 777
6. Amonoo Kuofi HS (1991) Morphometric changes in the heights and anteroposterior diameters of the lumbar intervertebral discs with age. J Anat 175:159 168
7. Antoniou J, Steffen T, Nelson F, Winterbottom N, Hollander AP, Poole RA, Aebi M, Alini M (1996) The human lumbar inter vertebral disc: evidence for changes in the biosynthesis and denaturation of the extracellular matrix with growth, maturation, ageing, and degeneration. J Clin Invest 98:996 1003
8. Benneker LM, Heini PF, Alini M, Anderson SE, Ito K (2005) 2004 Young Investigator Award Winner: vertebral endplate marrow contact channel occlusions and intervertebral disc degeneration. Spine (Phila Pa 1976) 30:167 173
9. Berg S, Isberg B, Josephson A, Fallman M (2012) The impact of discography on the surgical decision in patients with chronic low back pain. Spine J 12:283 291
10. Berlemann U, Gries NC, Moore RJ (1998) The relationship between height, shape and histological changes in early degen eration of the lower lumbar discs. Eur Spine J 7:212 217
11. Blankenbaker DG, Haughton VM, Rogers BP, Meyerand ME, Fine JP (2006) Axial rotation of the lumbar spinal motion seg ments correlated with concordant pain on discography: a pre liminary study. AJR Am J Roentgenol 186:795 799
12. Boos N, Weissbach S, Rohrbach H, Weiler C, Spratt KF, Nerlich AG (2002) Classification of age related changes in lumbar intervertebral discs: 2002 Volvo Award in basic science. Spine (Phila Pa 1976) 27:2631 2644
13. Buckwalter JA (1995) Aging and degeneration of the human intervertebral disc. Spine (Phila Pa 1976) 20:1307 1314
14. Cassidy JJ, Hiltner A, Baer E (1989) Hierarchical structure of the intervertebral disc. Connect Tissue Res 23:75 88
15. Cheung KM, Karppinen J, Chan D, Ho DW, Song YQ, Sham P, Cheah KS, Leong JC, Luk KD (2009) Prevalence and pattern of lumbar magnetic resonance imaging changes in a population study of one thousand forty three individuals. Spine (Phila Pa 1976) 34:934 940
16. Duance VC, Crean JK, Sims TJ, Avery N, Smith S, Menage J, Eisenstein SM, Roberts S (1998) Changes in collagen cross linking in degenerative disc disease and scoliosis. Spine (Phila Pa 1976) 23:2545 2551
17. Freemont AJ, Peacock TE, Goupille P, Hoyland JA, O'Brien J, Jayson MI (1997) Nerve ingrowth into diseased intervertebral disc in chronic back pain. Lancet 350:178 181
18. Frobin W, Brinckmann P, Biggemann M, Tillotson M, Burton K (1997) Precision measurement of disc height, vertebral height and sagittal plane displacement from lateral radiographic views of the lumbar spine. Clin Biomech (Bristol, Avon) 12(Suppl 1):S1 S63
19. Frymoyer JW, Selby DK (1985) Segmental instability. Rationale for treatment. Spine (Phila Pa 1976) 10:280 286
20. Fujiwara A, Lim TH, An HS, Tanaka N, Jeon CH, Andersson GB, Haughton VM (2000) The effect of disc degeneration and facet joint osteoarthritis on the segmental flexibility of the lumbar spine. Spine (Phila Pa 1976) 25:3036 3044
21. Galbusera F, Schmidt H, Neidlinger Wilke C, Wilke HJ (2011) The effect of degenerative morphological changes of the inter vertebral disc on the lumbar spine biomechanics: a poroelastic finite element investigation. Comput Methods Biomech Biomed Engin 14:729 739

22. Garcia Cosamalon J, del Valle ME, Calavia MG, Garcia Suarez O, Lopez Muniz A, Otero J, Vega JA (2010) Intervertebral disc, sensory nerves and neurotrophins: who is who in discogenic pain? J Anat 217:1 15
23. Gay RE, Ilharreborde B, Zhao K, Boumediene E, An KN (2008) The effect of loading rate and degeneration on neutral region motion in human cadaveric lumbar motion segments. Clin Bio mech (Bristol, Avon) 23:1 7
24. Gertzbein SD, Seligman J, Holtby R, Chan KW, Ogston N, Kapasouri A, Tile M (1986) Centrode characteristics of the lumbar spine as a function of segmental instability. Clin Orthop Relat Res 208:48 51
25. Grevitt MP, Gardner AD, Spilsbury J, Shackleford IM, Basker ville R, Pursell LM, Hassaan A, Mulholland RC (1995) The Graf stabilisation system: early results in 50 patients. Eur Spine J 4:169 175 discussion 135
26. Gries NC, Berlemann U, Moore RJ, Vernon Roberts B (2000) Early histologic changes in lower lumbar discs and facet joints and their correlation. Eur Spine J 9:23 29
27. Gu WY, Mao XG, Foster RJ, Weidenbaum M, Mow VC, Rawlins BA (1999) The anisotropic hydraulic permeability of human lumbar anulus fibrosus. Influence of age, degeneration, direction, and water content. Spine (Phila Pa 1976) 24:2449 2455
28. Haefeli M, Kalberer F, Saegesser D, Nerlich AG, Boos N, Paesold G (2006) The course of macroscopic degeneration in the human lumbar intervertebral disc. Spine (Phila Pa 1976) 31:1522 1531
29. Harris RI, Macnab I (1954) Structural changes in the lumbar intervertebral discs; their relationship to low back pain and sci atica. J Bone Joint Surg Br 36 B:304 322
30. Hirsch C, Schajowicz F (1952) Studies on structural changes in the lumbar annulus fibrosus. Acta Orthop Scand 22:184 231
31. Iatridis JC, Setton LA, Foster RJ, Rawlins BA, Weidenbaum M, Mow VC (1998) Degeneration affects the anisotropic and non linear behaviors of human anulus fibrosus in compression. J Biomech 31:535 544
32. Iatridis JC, Kumar S, Foster RJ, Weidenbaum M, Mow VC (1999) Shear mechanical properties of human lumbar annulus fibrosus. J Orthop Res 17:732 737
33. Iatridis JC, MacLean JJ, O'Brien M, Stokes IA (2007) Mea surements of proteoglycan and water content distribution in human lumbar intervertebral discs. Spine (Phila Pa 1976) 32:1493 1497
34. Johannessen W, Elliott DM (2005) Effects of degeneration on the biphasic material properties of human nucleus pulposus in con fined compression. Spine (Phila Pa 1976) 30:E724 E729
35. Kalichman L, Hunter DJ (2007) Lumbar facet joint osteoarthritis: a review. Semin Arthritis Rheum 37:69 80
36. Karadimas EJ, Siddiqui M, Smith FW, Wardlaw D (2006) Posi tional MRI changes in supine versus sitting postures in patients with degenerative lumbar spine. J Spinal Disord Tech 19:495 500
37. Kettler A, Rohlmann F, Ring C, Mack C, Wilke HJ (2011) Do early stages of lumbar intervertebral disc degeneration really cause instability? Evaluation of an in vitro database. Eur Spine J 20:578 584
38. Kirkaldy Willis WH, Farfan HF (1982) Instability of the lumbar spine. Clin Orthop Relat Res 165:110 123
39. Knutsson F (1944) The instability associated with disk degener ation in the lumbar spine. Acta Radiol 25:593 609
40. Krismer M, Haid C, Ogon M, Behensky H, Wimmer C (1997) Biomechanics of lumbar instability. Orthopade 26:516 520
41. Krismer M, Haid C, Behensky H, Kapfinger P, Landauer F, Rachbauer F (2000) Motion in lumbar functional spine units during side bending and axial rotation moments depending on the degree of degeneration. Spine (Phila Pa 1976) 25:2020 2027
42. Kuslich SD, Ulstrom CL, Michael CJ (1991) The tissue origin of low back pain and sciatica: a report of pain response to tissue stimulation during operations on the lumbar spine using local anesthesia. Orthop Clin North Am 22:181 187
43. Lipson SJ, Muir H (1980) Vertebral osteophyte formation in experimental disc degeneration. Morphologic and proteoglycan changes over time. Arthritis Rheum 23:319 324
44. Maeda S, Kokubun S (2000) Changes with age in proteoglycan synthesis in cells cultured in vitro from the inner and outer rabbit annulus fibrosus. Responses to interleukin 1 and interleukin 1 receptor antagonist protein. Spine (Phila Pa 1976) 25:166 169
45. Mimura M, Panjabi MM, Oxland TR, Crisco JJ, Yamamoto I, Vasavada A (1994) Disc degeneration affects the multidirectional flexibility of the lumbar spine. Spine (Phila Pa 1976) 19:1371 1380
46. Murata M, Morio Y, Kuranobu K (1994) Lumbar disc degener ation and segmental instability: a comparison of magnetic reso nance images and plain radiographs of patients with low back pain. Arch Orthop Trauma Surg 113:297 301
47. Nathan M, Pope MH, Grobler LJ (1994) Osteophyte formation in the vertebral column: a review of the etiologic factors Part II. Contemp Orthop 29:113 119
48. Neidlinger Wilke C, Galbusera F, Pratsinis H, Mavrogonatou E, Mietsch A, Kletsas D, Wilke HJ (2013) Mechanical loading of the intervertebral disc: from the macroscopic to the cellular level. Eur Spine J 16:1858 1866
49. Niemeyer F, Wilke HJ, Schmidt H (2012) Geometry strongly influences the response of numerical models of the lumbar spine a probabilistic finite element analysis. J Biomech 45:1414 1423
50. Oxland TR, Lund T, Jost B, Cripton P, Lippuner K, Jaeger P, Nolte LP (1996) The relative importance of vertebral bone den sity and disc degeneration in spinal flexibility and interbody implant performance. An in vitro study. Spine (Phila Pa 1976) 21:2558 2569
51. Panjabi MM (1992) The stabilizing system of the spine. Part II. Neutral zone and instability hypothesis. J Spinal Disord 5:390 396 discussion 397
52. Pfirrmann CW, Metzdorf A, Zanetti M, Hodler J, Boos N (2001) Magnetic resonance classification of lumbar intervertebral disc degeneration. Spine (Phila Pa 1976) 26:1873 1878
53. Pollintine P, Dolan P, Tobias JH, Adams MA (2004) Interverte bral disc degeneration can lead to "stress shielding" of the anterior vertebral body: a cause of osteoporotic vertebral frac ture? Spine (Phila Pa 1976) 29:774 782
54. Pollintine P, Przybyla AS, Dolan P, Adams MA (2004) Neural arch load bearing in old and degenerated spines. J Biomech 37:197 204
55. Pope MH, Panjabi M (1985) Biomechanical definitions of spinal instability. Spine (Phila Pa 1976) 10:255 256
56. Przybyla A, Pollintine P, Bedzinski R, Adams MA (2006) Outer annulus tears have less effect than endplate fracture on stress distributions inside intervertebral discs: relevance to disc degeneration. Clin Biomech (Bristol, Avon) 21:1013 1019
57. Roberts S, Menage J, Eisenstein SM (1993) The cartilage end plate and intervertebral disc in scoliosis: calcification and other sequelae. J Orthop Res 11:747 757
58. Roberts S, Urban JP, Evans H, Eisenstein SM (1996) Transport properties of the human cartilage endplate in relation to its composition and calcification. Spine (Phila Pa 1976) 21:415 420
59. Roughley PJ (2004) Biology of intervertebral disc aging and degeneration: involvement of the extracellular matrix. Spine (Phila Pa 1976) 29:2691 2699
60. Schollum ML, Robertson PA, Broom ND (2008) ISSLS prize winner: microstructure and mechanical disruption of the lumbar

disc annulus: part I: a microscopic investigation of the transla mellar bridging network. Spine (Phila Pa 1976) 33:2702 2710
61. Setton LA, Zhu W, Weidenbaum M, Ratcliffe A, Mow VC (1993) Compressive properties of the cartilaginous end plate of the baboon lumbar spine. J Orthop Res 11:228 239
62. Suri P, Miyakoshi A, Hunter DJ, Jarvik JG, Rainville J, Guermazi A, Li L, Katz JN (2011) Does lumbar spinal degeneration begin with the anterior structures? A study of the observed epidemi ology in a community based population. BMC Musculoskelet Disord 12:202
63. Tanaka N, An HS, Lim TH, Fujiwara A, Jeon CH, Haughton VM (2001) The relationship between disc degeneration and flexibility of the lumbar spine. Spine J 1:47 56
64. Thompson JP, Pearce RH, Schechter MT, Adams ME, Tsang IK, Bishop PB (1990) Preliminary evaluation of a scheme for grading the gross morphology of the human intervertebral disc. Spine (Phila Pa 1976) 15:411 415
65. Thompson RE, Pearcy MJ, Barker TM (2004) The mechanical effects of intervertebral disc lesions. Clin Biomech (Bristol, Avon) 19:448 455
66. Urban JP, McMullin JF (1985) Swelling pressure of the iner vertebral disc: influence of proteoglycan and collagen contents. Biorheology 22:145 157
67. Urban JP, Roberts S (2003) Degeneration of the intervertebral disc. Arthritis Res Ther 5:120 130
68. Urban JP, Smith S, Fairbank JC (2004) Nutrition of the inter vertebral disc. Spine (Phila Pa 1976) 29:2700 2709
69. Vernon Roberts B, Moore RJ, Fraser RD (2007) The natural history of age related disc degeneration: the pathology and sequelae of tears. Spine (Phila Pa 1976) 32:2797 2804
70. Videman T, Battie MC, Gibbons LE, Maravilla K, Manninen H, Kaprio J (2003) Associations between back pain history and lumbar MRI findings. Spine (Phila Pa 1976) 28:582 588
71. Videman T, Nurminen M (2004) The occurrence of anular tears and their relation to lifetime back pain history: a cadaveric study using barium sulfate discography. Spine (Phila Pa 1976) 29:2668 2676
72. Wade KR, Robertson PA, Broom ND (2011) A fresh look at the nucleus endplate region: new evidence for significant structural integration. Eur Spine J 20:1225 1232
73. Wade KR, Robertson PA, Broom ND (2012) On the extent and nature of nucleus annulus integration. Spine (Phila Pa 1976) 37:1826 1833
74. Wang Y, Videman T, Battie MC (2012) ISSLS prize winner: Lumbar vertebral endplate lesions: associations with disc degeneration and back pain history. Spine (Phila Pa 1976) 37:1490 1496
75. White AA, Panjabi MM (1990) Clinical biomechanics of the spine. Lippincott Williams & Wilkins, Philadelphia
76. Wilke HJ, Rohlmann F, Neidlinger Wilke C, Werner K, Claes L, Kettler A (2006) Validity and interobserver agreement of a new radiographic grading system for intervertebral disc degeneration: Part I. Lumbar spine. Eur Spine J 15:720 730
77. Zhao F, Pollintine P, Hole BD, Dolan P, Adams MA (2005) Discogenic origins of spinal instability. Spine (Phila Pa 1976) 30:2621 2630
78. Zirbel SA, Stolworthy DK, Howell LL, Bowden AE (2013) Intervertebral disc degeneration alters lumbar spine segmental stiffness in all modes of loading under a compressive follower load. Spine J 13:1134 1147