BIOLOGY OF REPRODUCTION 56, 1133–1141 (1997)

Mechanism of Infertility in Male Guinea Pigs Immunized with Sperm PH-20[1]

Kenneth S.K. Tung,[2,6] Paul Primakoff,[3,7] Laura Woolman-Gamer,[4,7] and Diana G. Myles[5,7]

Department of Pathology and Microbiology,[6] University of Virginia, Charlottesville, Virginia 22908
Department Physiology,[7] University of Connecticut Health Center, Farmington, Connecticut 06030

ABSTRACT

PH-20, a testis-specific protein first expressed in haploid germ cells, is present on the posterior head plasma membrane and inner acrosomal membrane of mature guinea pig sperm. PH-20 is bifunctional, having a hyaluronidase activity that allows sperm to penetrate the cumulus layer and a separate activity required for binding of acrosome-reacted sperm to the zona pellucida. The immunization of male guinea pigs with PH-20 reproducibly results in infertility with a duration of 6–12 mo or longer. In this study, we analyzed the immunopathology in the reproductive tract of PH-20-immunized males to probe the mechanism(s) responsible for the induced infertility and found two separate effects. Remarkably, in almost all infertile, PH-20-immunized males, the caudae epididymides were empty (contained no sperm) or contained only abnormal sperm. The complete loss of normal sperm in the epididymis apparently results in infertility. A second effect was the induction of experimental autoimmune orchitis (EAO), representing the first report of EAO induced by a purified testis/sperm molecule of known functions. PH-20-induced EAO differed from EAO induced by crude testis antigens in two respects: 1) an absence of epididymitis with abscess and granuloma and 2) the presence of antibody on germ cells within seminiferous tubules and inside the cauda epididymidis. The former suggests that crude testis antigens other than PH-20 are responsible for epididymitis, and the latter suggests a possible role of antibody in EAO pathogenesis and infertility induction. Return to fertility, after 6–12 mo, was accompanied by regression of EAO and reappearance of spermatozoa in the caudae epididymides.

INTRODUCTION

In current research on contraceptive vaccines, gamete proteins comprise one group of potentially useful antigens under study. When sperm antigens are used in males and zona pellucida antigens in females, the goal is to achieve contraception through induction of autoimmune responses. The induced autoimmunity must have the desired contraceptive effects without undesired pathological effects of any kind. If such a contraceptive approach is to prove feasible, the scope of autoimmune responses elicited must be limited. Successful strategies to achieve this with zona pellucida antigens are being actively pursued [1].

We have found that immunization of male guinea pigs with the sperm surface protein PH-20 leads reproducibly to infertility [2]. It will be important to define the range of responses elicited in the infertile males in order to be able to develop strategies that provoke a contraceptive response without concomitant pathological consequences. Clinical studies of some infertile men have detected antibodies bound to the surface of their sperm in the absence of other autoimmune responses in the testis or reproductive tract, suggesting that this contraceptive approach may be feasible [3, 4].

In this study, we examined the reproductive tracts of male guinea pigs that became infertile after immunization with PH-20. Two effects were found in these animals. The first is novel, the loss of normal sperm from the caudae epididymides. The second is the induction of experimental autoimmune orchitis (EAO), which developed in the majority of animals.

Several guinea pig orchitogenic molecules have been isolated; however, their identity and function are unknown, and the testicular autoimmune diseases that they elicited were not investigated [5–8]. The present experiments represent the first known case of EAO induction with a purified testis/sperm molecule of known functions and provide a useful model for dissecting the mechanisms of testicular autoimmunity. This autoimmune disease in humans may present clinically as granulomatous orchitis, aspermatogenesis, and/or sperm-bound antibodies and is an important cause of human male infertility [9].

The pathogenetic role of antibody in EAO is an important issue in considering sperm- and testis-specific antigenic molecules in male contraceptive vaccine development. Past studies on guinea pig EAO have also shown that the disease was transferred to normal recipients by lymph node and peritoneal T cells [10, 11]. Although some pathology in the epididymis was reported in recipients of antibody, this occurred only when the recipients were given complete Freund's adjuvant (CFA) [12–15]. If antibody does not cause testicular disease, but can access the epididymal lumen and eliminate the spermatozoa or impede their function, a potential reversible vaccine would be worthy of consideration.

Here we present data on the various changes found in the reproductive tract of PH-20-immunized males and discuss the relationship of these changes to the initial infertility and eventual return to fertility in some of these animals.

MATERIALS AND METHODS

Animals, PH-20 Purification, Immunization, and Fertility Testing

Male Hartley guinea pigs (~300 g or ~650 g at the time of first injection) were immunized with purified PH-20 and tested for fertility as described [2].

Histopathology

The testes and epididymides were fixed in Zenker's fixative overnight. Five transverse blocks of the testis and caput epididymidis and coronal section of the cauda epididymidis through the plane of the vas were made. The tissue blocks were fixed for 6 h or more and embedded in paraffin. Five-micrometer tissue sections were stained with periodic acid-Schiff hematoxylin stain.

Accepted November 12, 1996.
Received August 23, 1996.
[1]The study was supported in part by HD29099, AI-41236 (K.S.K.T.), and by U54-HD29125 (P.P. and D.G.M.).
[2]Correspondence: Kenneth Tung, Department of Pathology, Box 214, Charlottesville, VA 22908. FAX: (804) 924–8060; e-mail: kst7k@virginia.edu
[3]Current address: Department of Cell Biology and Human Anatomy, School of Medicine University of California, Davis, CA 95616.
[4]Current address: Genetics Institute, Cambridge, MA 02140.
[5]Current address: Section of Molecular and Cell Biology, University of California, Davis, CA 95616.

Downloaded from https://academic.oup.com/biolreprod/article/56/5/1133/2760778 by guest on 04 September 2024

Petitioner Merck, Ex. 1023, p. 1133

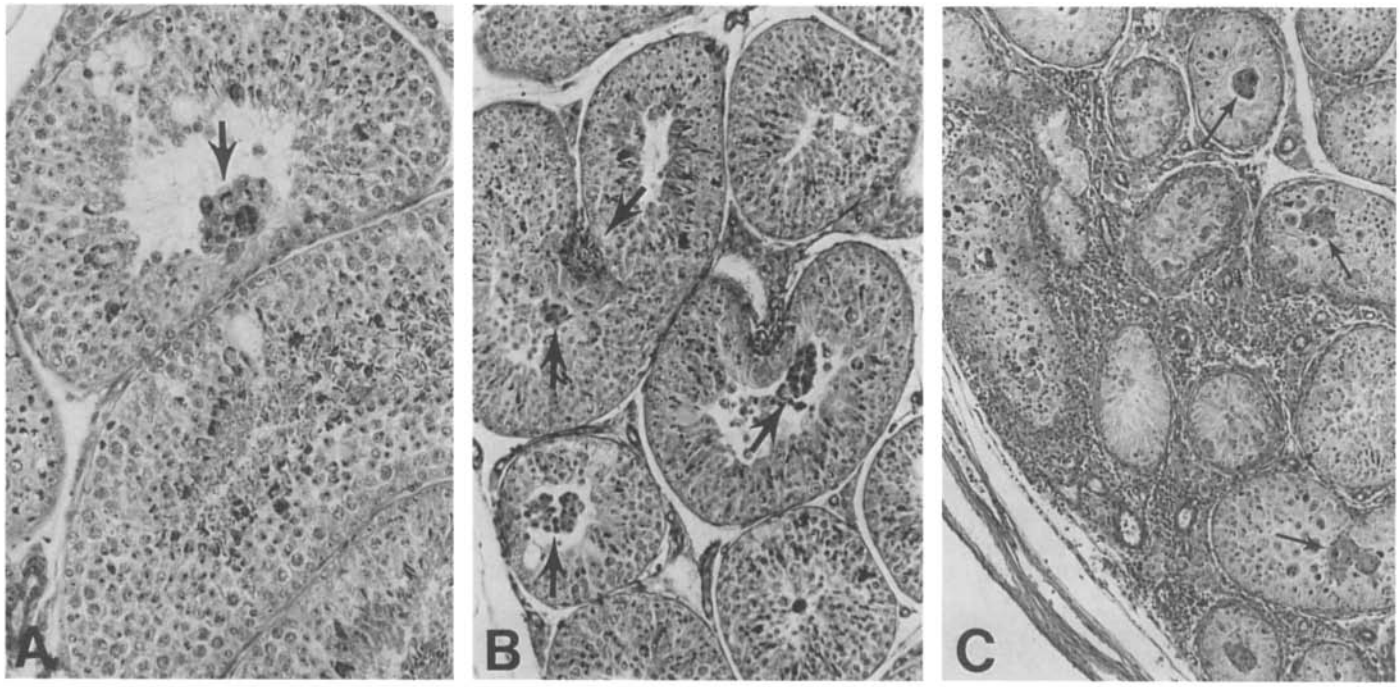

FIG. 1. Orchitis in 300-g guinea pig immunized with PH-20. **A**) In focal orchitis, rare intratubular clusters of lymphoid cells are found within seminiferous tubules (×380). **B**) Multiple clusters of intra-tubular lymphoid cells are detected in multifocal orchitis (×190). **C**) In diffuse orchitis, heavy inflammatory mononuclear cell infiltration exists between aspermatogenic tubules with intratubular lymphoid clusters (×95). Arrows point to clusters of lymphoid cells within the seminiferous tubules.

The histopathology of EAO, illustrated in Figures 1–3, was graded as follows. Aspermatogenic tubules were scored as percentage of total number of tubules counted. Tubules with partial or complete loss of germ cells were scored as aspermatogenic tubules. Orchitis was designated as focal when fewer than 5–6 lesions of macrophagic invasion of the seminiferous tubules (see Fig. 1A) were noted. Diffuse orchitis indicated extensive infiltration of mononuclear cells both between and within seminiferous tubules (see Fig. 1C). Multifocal orchitis denoted multiple lesions with intensity between focal and diffuse (see Fig. 1B). Macrophagic phagocytosis of spermatozoa in the lumen of rete testis was graded + to +++ depending on the relative density of macrophages present.

Immunofluorescence (IF) Study

Direct IF was used to detect cell- or tissue-bound immune reactants, including IgG, C3, and fibrinogen. Fluorescein isothiocyanate-labeled antiserum reagents for the study were prepared as previously described [13]. The testes and epididymides were snap-frozen in toto in liquid nitrogen. Frozen sections 5 μm thick were fixed in 95% ethanol. Two transverse sections of the testis, and one coronal section of the cauda epididymidis were stained with each of the above conjugated antisera. On adjacent sections, PH-20 was stained by indirect IF with a murine monoclonal antibody (PH-22) directed to PH-20 [16], followed by fluorescein-labeled rabbit antiserum IgG to mouse IgG (Cappel Corp., Durham, NC). All IF slides were examined and photographed with a Zeiss fluorescence microscope. Fluorescence intensities were arbitrarily graded from + to +++.

Statistical Analysis

Chi-square analysis and Student's *t*-test were used to compare results of different groups of animals.

RESULTS

Some (arbitrarily selected) guinea pigs from the groups of males immunized with PH-20 [2] were studied for histological changes in the testis and/or reproductive tract. The changes were assessed at various times after the initial PH-20 injection.

Spectrum of Histological Changes Induced by PH-20 Immunization

Guinea pigs immunized with PH-20 in CFA and subsequently in incomplete Freund's adjuvant (IFA) developed 4 types of histopathologic changes: 1) orchitis, 2) loss of germ cells (aspermatogenesis), 3) macrophage phagocytosis of spermatozoa in the lumen of the rete testis and proximal cauda epididymidis, and 4) abnormal spermatozoa or the absence of sperm in the distal cauda epididymal lumen.

Orchitis was focal, multifocal, or diffuse (Fig. 1; Tables 1 and 2). The typical orchitis lesions consisted of small clusters of lymphocytes and macrophages that penetrated the blood-testis barrier to reach the tubular lumen (Fig. 1A). More severe EAO was accompanied by orchitis that was multifocal (Fig. 1B) or diffuse (Fig. 1C). In general, orchitis was more extensive in males given higher doses of PH-20 (Tables 1 and 2).

Although aspermatogenesis may occur without associated orchitis (Fig. 2A), extensive aspermatogenesis was found in those testes with severe orchitis (Table 1; Fig. 2B). In some tubules, only Sertoli cells were found, but in most, residual germ cells were evident (Fig. 2). Phagocytosis of spermatozoa by macrophage-like cells was often observed in the lumen of the rete testis and within the proximal cauda epididymidis (Fig. 2, C and D).

Downloaded from https://academic.oup.com/biolreprod/article/56/5/1133/2760778 by guest on 04 September 2024

TABLE 1. Testicular histopathology of guinea pigs (GP) injected with PH-20 in CFA studied at 3 mo.

GP no.*	Group (No)*	Total PH-20 dose (μg)	Littersizes (mo studied)	Orchitis	Aspermatogenesis (%)	Rete testis	Cauda epididymis
1	II (1)	30	0,0 (2)	Diffuse	50	0	Empty
2	II (5)	40	0,0 (2)	Diffuse	50	+	Empty
3	II (7)	20	0,0 (2)	Multifocal	50	+	Empty
4	II (8)	20	0,0 (2)	Multifocal	60	+	Empty
5	II (12)	10	0,0 (2)	Multifocal	95	0	Empty
6	II (13)	10	0,0 (2)	Multifocal	10	+	Abnormal sperm
7	II (17)	5	0,0 (2)	Multifocal	50	+	Abnormal sperm
8	IV (9)	0.25	0,0 (2)	Focal	30	+	Abnormal sperm
9	IV (1)	4	0,0 (2)	Focal	2	0	Full
10	IV (8)	0.5	0,0 (2)	None	5	+	Full
11	IV (6)	1.0	3,0 (2)	Focal	40	+	Abnormal sperm
12	IV (2)	2.0	3,4 (2)	None	0	++	Full
13	IV (3)	2.0	3,4 (2)	None	0	+	Full
14	IV (4)	2.0	3,4 (2)	None	0	0	Full
15	IV (7)	0.5	4,0 (2)	None	0	0	Full
16	IV (5)	1.0	4,4 (2)	None	0	0	Full

* Group or guinea pig number within the group in this column corresponds to the numbering system used in the accompanying paper [2]; the same designations apply to guinea pigs in Tables 2 and 4.

Timing and Conditions for the Induction of EAO by PH-20 Immunization

Among 16 males (~300 g BW at first injection) immunized with PH-20 in CFA/IFA and studied here, 10 developed EAO 3 mo later (Table 1). Disease induction depended on the total antigen dose (as single or two injections): all 7 (100%) of the animals receiving ≥ 5 μg PH-20 were infertile and developed extensive EAO. In contrast, only 3 of 9 (33%) animals that received ≤ 4 μg became infertile, and 6 of these 9 had testicular pathology. However, the pathology was mild except in 2 of these animals (Table 1, nos. 8 and 11). Six controls injected with CFA/IFA and studied 3 or 12 mo later were fertile and had normal gonads (data not shown).

Lesions of EAO induced by PH-20 tended to diminish but persist. The results in Tables 1 and 2 are expressed as findings in individual males, or in the two testes of the same male at two different times. Of 14 guinea pigs or testes studied at 12 or 21 mo after initial injection (animals received ≥ 5 μg total PH-20), only 1 was completely free of EAO (Table 2, no. 20).

Changes in the Cauda Epididymidis

The caudae epididymides of controls or of fertile males with EAO were packed with spermatozoa that formed rouleaux (Fig. 3A). Nineteen of 31 testes from males injected with varying doses of PH-20 had abnormal caudae epididymides (Tables 1 and 2), and of these, 12 were devoid of spermatozoa (Fig. 3C) and 7 contained abnormal spermatozoa (Fig. 3B). Abnormal sperm showed a loss of the acrosome, disruption of the sperm rouleaux, and presence of large periodic acid-Schiff-positive acellular structures. However, neutrophil-rich epididymitis, with granuloma and abscesses, which has been reported in about 25% of testes with EAO elicited by crude testis antigens [17], was not observed in PH-20-immunized animals.

TABLE 2. Testicular histopathology of guinea pigs (GP) injected with PH-20 in CFA at or beyond 12 mo.*

GP No.†	Group (No.)†	Mo studied	Total PH-20 dose (μg)	Litter size (mo)	Orchitis	Aspermatogenesis (%)	Rete testis	Cauda epididymis
300-g GP								
17	I (5)	12	10	4,5 (11)	Focal	5	++	Full
18	II (16)	21	5	2,3 (11)	Focal	5	0	Full
19	I (4)	12	20	3,4 (11)	None	0	++	Full
20	II (6)	21	20	3,4 (11)	None	0	0	Full
21	I (1)	12	100	3,0 (11)	Focal	40	+	Abnormal sperm
22	II (2)	12	30	NS	Diffuse	100	++	Empty
23R	II (4) R	12	40	0,0 (11)	Focal	40	+	Empty
23L	II (4) L	21	40	0,0 (11)	Focal	80	+++	Empty
650-g GP								
24R	III (2)R	12	100	4,0 (11)	Focal	30	0	Full
24L	III (2)L	12	100	4,0 (11)	Focal	5	0	Abnormal sperm
25R	III (1)R	12	200	0,0 (11)	Focal	50	+	Empty
25L	III (1)L	20	200	NS	Focal	80	+	Empty
26	III (3)	12	100	0,0 (11)	Focal	5	+	Empty
27	III (4)	12	50	0,0 (11)	Focal	5	0	Abnormal sperm
28R	III (5)R	12	40	0,0 (11)	Focal	70	0	Empty
28L	III (5)L	15	40	NS	Focal	80	0	Empty

* Reproductive performance of some guinea pigs was not determined (NS) or was only studied once, while testes were studied at two different times; in one guinea pig (#24), the pathological findings of both testes are shown because they are different.
† See Table 1 footnote.

Downloaded from https://academic.oup.com/biolreprod/article/56/5/1133/2760778 by guest on 04 September 2024

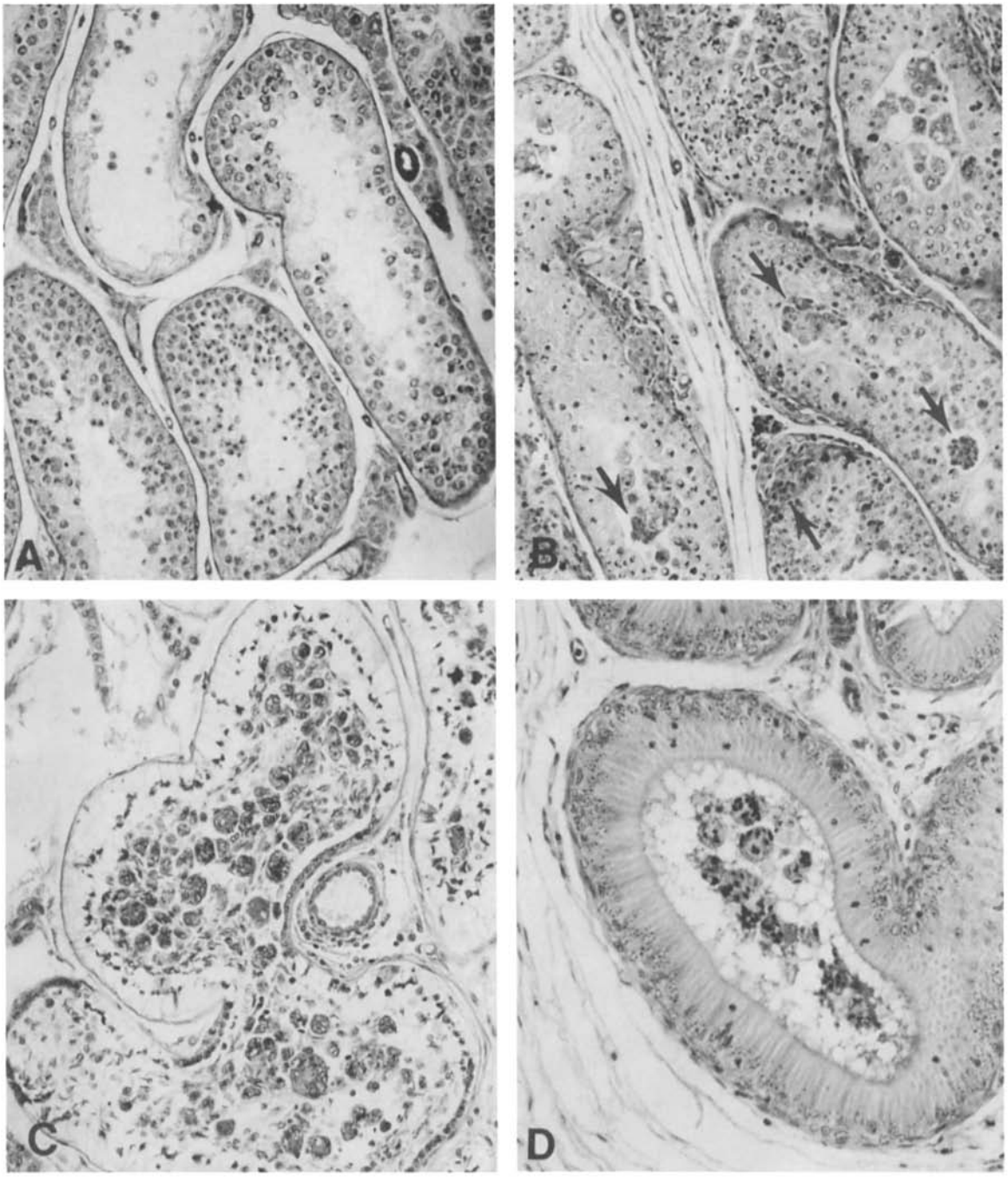

FIG. 2. Aspermatogenesis and macrophage phagocytosis of spermatozoa in 300-g guinea pig immunized with PH-20. **A** and **B**) Desquamation of germ cells occur in the absence (**A**) or presence (**B**) of orchitis (arrows; ×200). The opposite testes of these guinea pig show detectable IgG on spermatids and spermatozoa within seminiferous tubules, as illustrated in Figure 5. **C**) Numerous macrophages with phagocytosed spermatozoa inside lumen of the rete testis (×200). **D**) Macrophages with phagocytosed spermatozoa inside proximal cauda epididymidis (×400).

Downloaded from https://academic.oup.com/biolreprod/article/56/5/1133/2760778 by guest on 04 September 2024

Correlation between Histological Changes and Male Infertility

Among 28 animals whose fertility was determined around the time of study on their testes, 12 were fertile (total dose ≤ 4 μg) and 16 were infertile (total dose ≥ 5 μg). There was a correlation between infertility and orchitis severity, extent of aspermatogenesis, and presence of cauda epididymal abnormalities (Table 3). In contrast, no significant correlation was found between infertility and rete testis changes.

However, exceptions to these correlations were observed. First, 2 males with abnormal cauda epididymal spermatozoa tested as fertile during the month before histological samples were taken (Table 1, no. 11; Table 2, no. 21). More interesting were 2 other males that had perfectly normal caudal spermatozoa but were infertile (Table 1, nos. 9 and 10; Fig. 3A).

Immunohistochemical Findings

The anti-PH-20 antibodies produced in immunized animals reacted with the posterior head region and the inner acrosomal membrane of spermatozoa, where previous studies have shown PH-20 to be localized on acrosome-intact or acrosome-

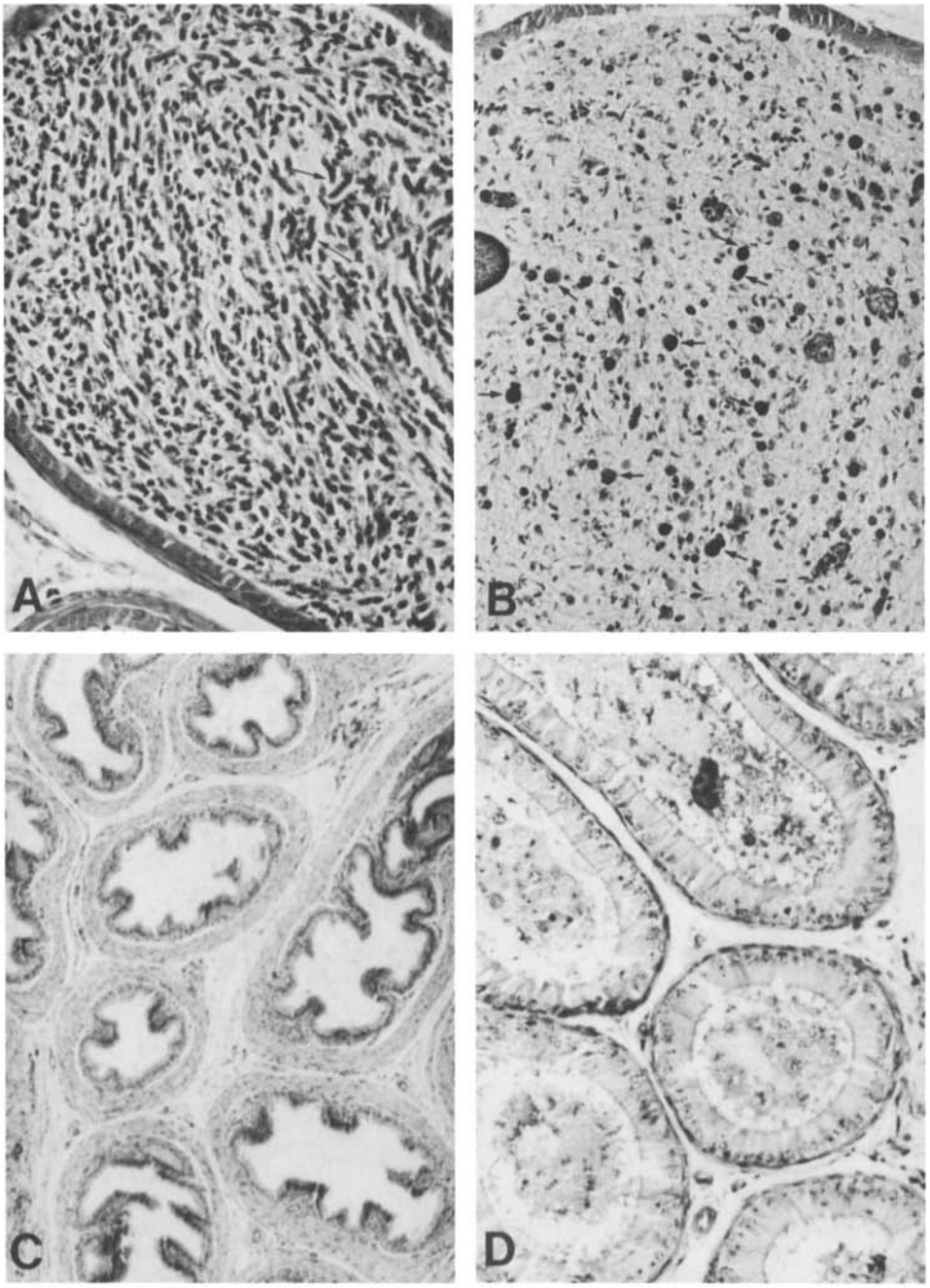

FIG. 3. Epididymal pathology in 300-g guinea pig immunized with PH-20. **A**) Normal spermatozoa with rouleaux (arrows) fill the lumen of distal cauda epididymidis of a control guinea pig (×400). However, the cauda epididymidis of occasional infertile guinea pig has an appearance similar to that of **A**. **B**) Abnormal spermatozoa are present in cauda epididymidis of infertile guinea pig (×400). Note that the spermatozoa are in disarray, most are without acrosome, rouleaux are not found, and some periodic acid-Schiff-positive structures (arrows) are present. **C**) Empty cauda epididymidis of an infertile guinea pig (×100). **D**) Abnormal spermatozoa in proximal cauda epididymidis of an infertile guinea pig (×200). On the opposite testis of this gonad, IgG is detected on the spermatozoa of the cauda epididymidis (see Fig. 4D).

reacted sperm [16]. The testes and caudae epididymides of 7 males immunized with PH-20 were studied for deposition of IgG as evidence of in vivo tissue-bound antibodies, and adjacent sections were studied for PH-20 antigen that reacts with a monoclonal antibody (Table 4). In 2 fertile males with mild and focal orchitis, IgG was absent, and abundant PH-20 was detected in the spermatids and epididymal spermatozoa (Table 4, nos. 9 and 19; Fig. 4, A, C, and E).

In 4 of 5 animals with more severe EAO, IgG was readily detected in PH-20-positive testicular spermatozoa or spermatids within the seminiferous tubules (Table 4, nos. 2, 6, 4, and 21; Fig. 5). The histology of the contralateral testes of these

TABLE 3. Correlation between histopathology and fertility in guinea pigs (300-g and 650-g) injected with PH-20 in CFA.

Fertility state	n*	Orchitis				Aspermatogenic tubules (%) (means ± SEM)	Rete testis changes			Cauda epididymis	
		None	Focal	Multifocal	Diffuse		0	+	++	Full	Empty or abnormal
Fertile	12	7	5	0	0	10 ± 2.9	6	3	3	10	2
Infertile	16	1	8	5	2	43 ± 8.0	5	9	2	2	14
p value			7.8×10^{-3}			2.5×10^{-3}		0.25		7.7×10^{-4}	

* Number of GP or testes.

Downloaded from https://academic.oup.com/biolreprod/article/56/5/1133/2760778 by guest on 04 September 2024

TABLE 4. Detection of IgG and PH-20 in testes and epididymides of guinea pigs injected with PH-20 in CFA.

GP No.*	Group (No.)*	Month studied	Histopathology			Testis deposits		Cauda epididymis deposits	
			Orchitis	Aspermatogenesis (%)	Cauda epididymis	IgG	PH-20	IgG	PH-20
9	IV (9)	3	Focal	2	Full	0	+++	0	+++
19	I (4)	12	None	0	Full	0	+++	0	
2	II (5)	3	Diffuse	50	Empty	+++	++	0	+
6	II (13)	3	Multifocal	10	Abnormal sperm	+++	+++	+++	++
4	II (8)	3	Multifocal	50	Empty	++	+	0	0
21	I (1)	12	Focal	40	Abnormal sperm	+	++	NS	NS
22	II (12)	12	Diffuse	100	Empty	0	+	++	+

* See Table 1 footnote.

males showed desquamation of germ cells and mononuclear infiltration (Fig. 2, A and B). In addition, the location of the granular IgG and PH-20 deposits suggested that they might be present inside cells that line the seminiferous tubules, perhaps within the Sertoli cells (Fig. 5, B and D).

The lumenal contents of the caudae epididymides in most males with EAO were free of IgG (Fig. 4, A and C). This, along with the intense interstitial IgG staining, is indicative of a barrier for IgG at the epididymal epithelium (Fig. 4, A and B). However, in 2 males with EAO (Table 4, nos. 6 and 22), diffuse IgG was detected in the lumenal contents of the proximal cauda epididymidis (Fig. 4, B and D), with streaks of positive IgG present between epithelial cells (Fig. 4B). Moreover, IgG was detected on the inner acrosomal membrane of the spermatozoa inside the epididymal ducts (Fig. 4D). The PH-20 staining revealed that the spermatozoa had lost their acrosomes, and some were in close contact with the lining epithelial cells (Fig. 4F). Figure 3D illustrates the histopathology of the proximal cauda epididymidis from the opposite testis of the males illustrated in Figure 4, B, D, and F. Complement component C3 was not detectable in any of the testes or epididymides examined (data not shown).

Comparison of Early and Late Histological Changes in ~300-g Guinea Pigs Immunized with PH-20

Among 14 males (~300 g at time of first injection) immunized with ≥ 5 μg (total) PH-20 in CFA/IFA, we studied 7 at 3 mo (Table 1, nos. 1–7) and the other 7 at 12 or 21 mo (Table 2, nos. 17–23). All animals at 3 mo were infertile, their testes contained extensive orchitis and aspermatogenesis, and their caudae epididymides were abnormal. In contrast, of the 6 mated guinea pigs examined at 12 or 21 mo, 5 were fertile; and with one exception (Table 2, no. 21), the testes of the fertile males had focal lesions and normal caudae epididymides. These findings strongly suggest that the early orchitis and loss of sperm from the epididymis observed in the infertile males can reverse with time, with return of fertility.

Comparison of Late Histological Changes of ~300-g and ~650-g Guinea Pigs

The body weight (or age) of the male at the time of first injection might influence the fertility rate 12 mo later [2]. We therefore compared the histological changes in the 300-g males and the 650-g males (Table 2). A discernible difference appeared to be the persistent abnormalities in the caudae epididymides of the 650-g males. For example, 2 infertile animals, 650 g at time of initial injection, had severe cauda epididymal abnormalities even though their testes contained only focal orchitis and minimal aspermatogenic tubules (Table 2, nos. 26 and 27).

DISCUSSION

The contraceptive action of PH-20 immunization is revealed by our data to have a probable major and minor basis. Most males that became infertile after PH-20 immunization (and all that received a total dose ≥ 5 μg) showed either a complete loss of sperm from the caudae epididymides or the presence of only abnormal sperm in the caudae. Thus the infertility of these males can be explained by the absence of ejaculated spermatozoa. The minority case comprised 2 infertile males (receiving a total dose ≤ 4 μg) that had an apparently normal complement of sperm in their caudae epididymides. The basis for the infertility of these animals is unclear but is potentially of interest since it may represent a model for infertility mediated by antibody-binding to viable sperm.

Induction of EAO by PH-20 provides conclusive immunological evidence that PH-20 contains antigenic epitopes specific to the male germ cells. Male outbred Hartley guinea pigs, immunized with PH-20, produced sperm autoantibodies, became infertile, and developed typical histopathology of EAO. EAO prevalence and severity parallel the immunizing dose of PH-20; 100% of males injected with ≥ 5 μg PH-20 had severe pathology and were infertile at 3 mo. Histopathology of EAO was persistent and remained detectable in most of the animals examined at 12 or 21 mo. PH-20 would need to be modified to retain its contraceptive effect without orchitogenic capacity if it were to be employed as a contraceptive vaccine antigen.

However, the severity of EAO clearly declined with time. Many males that received a high dose (≥ 5 μg) of PH-20, and therefore would have been predicted to have severe EAO and be infertile at 3 mo, were fertile when studied at 12 mo. Moreover, their testicular pathology was milder than that of the males examined at 3 mo. Thus testicular and epididymal pathology and male infertility that follow PH-20 immunization are potentially reversible. This is consistent with the findings in several experimental autoimmune diseases induced by self antigen in adjuvant, where recovery from disease is also the rule [18–20]. In the case of ovarian autoimmune disease induced by a ZP3 peptide, regression of oophoritis was also associated with return of fertility [20].

In previous studies, the histopathology of EAO in male guinea pigs immunized with crude testicular homogenates in CFA was described to consist typically of orchitis, aspermatogenesis, and epididymitis [17]. IgG, undetectable in the seminiferous tubules, was localized on spermatozoa within the lumen of the rete testis and rarely within the

Downloaded from https://academic.oup.com/biolreprod/article/56/5/1133/2760778 by guest on 04 September 2024

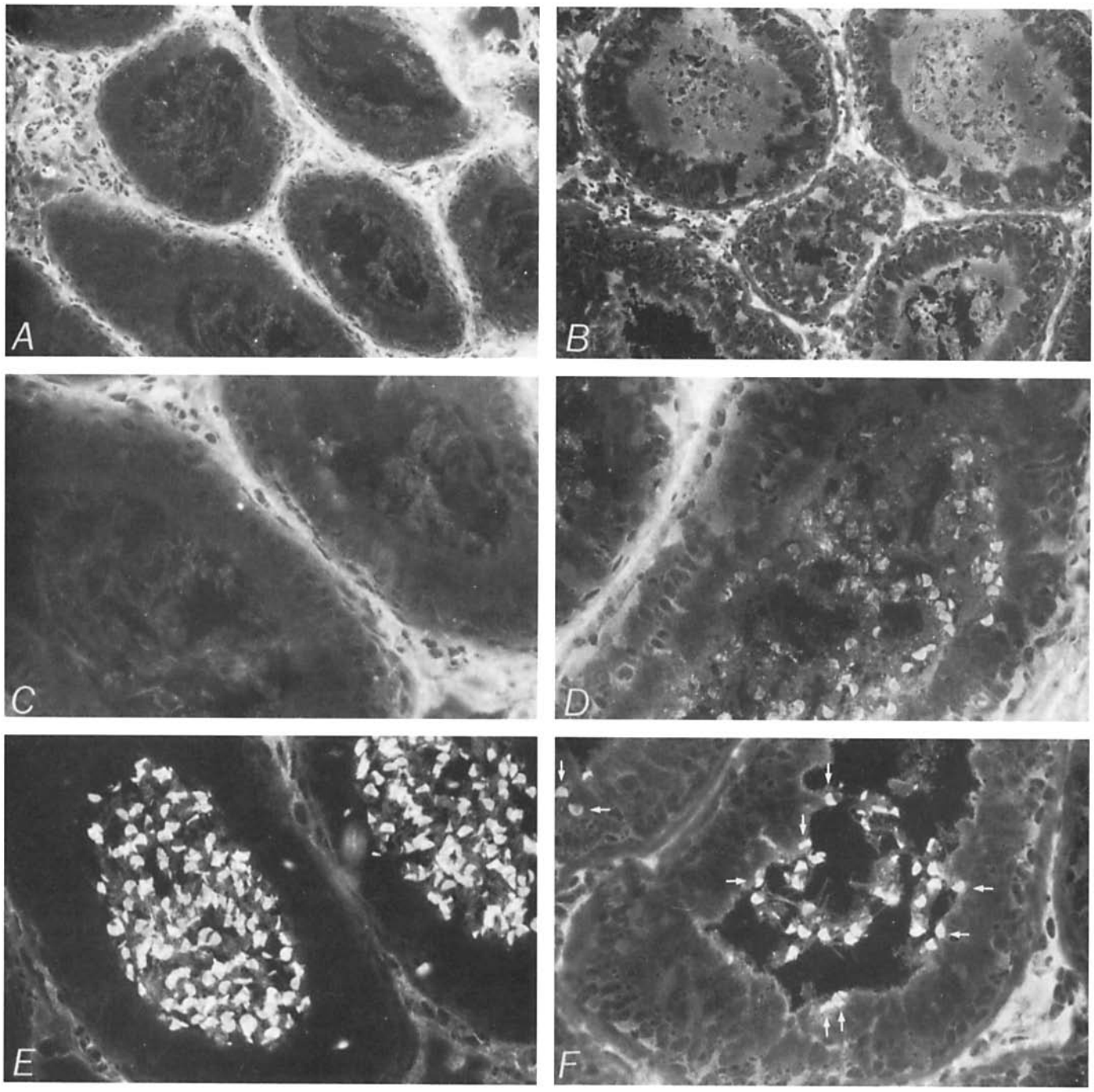

FIG. 4. Detection of IgG (**A–D**) and PH-20 antigen (**E, F**) by immunofluorescence. **A**, **C**, and **E** show the caudae epididymides of a 300-g fertile normal guinea pig, and **B**, **D**, and **F** show the caudae epididymides of a 300-g infertile guinea pig, injected with PH-20 in CFA. **A**) Strong IgG staining is present in the interstitium and absent in the lumen; and at higher magnification (**C**), IgG is not detected in the epithelial cells. **E**) Strong PH-20 staining is noted on the epididymal spermatozoa of the fertile guinea pig. **B**) IgG is detected in the interstitium and the inside lumen of the proximal cauda epididymidis of the infertile guinea pig. Note streaking of IgG between the epithelial cells. **D**) IgG is detected on the inner acrosomal membrane of spermatozoa within the epididymal lumen of the infertile guinea pigs. **F**) A few residual PH-20-positive spermatozoa are present in the epididymis of the infertile guinea pig. Note PH-20 staining is on the inner acrosomal membrane, indicative of acrosome loss; and some spermatozoa are in close contact with epithelial cells (arrows in **F**). **A** and **B**, ×96; **C-F**, ×384.

proximal cauda epididymidis [17]. Epididymitis typically had abundant neutrophilic infiltration and was sometimes associated with disruption of the epithelial barrier and the formation of abscesses and granuloma. Although not formally proven, disruption of epididymal architecture in such animals might be expected to lead to irreversible damage of the male reproductive tract.

A major difference observed in the PH-20-immunized males (compared to males immunized with testis homogenate) is the preservation of a normal cauda epididymidis and absence of epididymitis. After PH-20 immunization, the epididymides were normal but were often devoid of spermatozoa or contained only abnormal spermatozoa. The absence of epididymitis in PH-20-induced EAO supports the observation in a murine EAO study based on major histocompatibility complex (MHC) congenic mice, in

Downloaded from https://academic.oup.com/biolreprod/article/56/5/1133/2760778 by guest on 04 September 2024

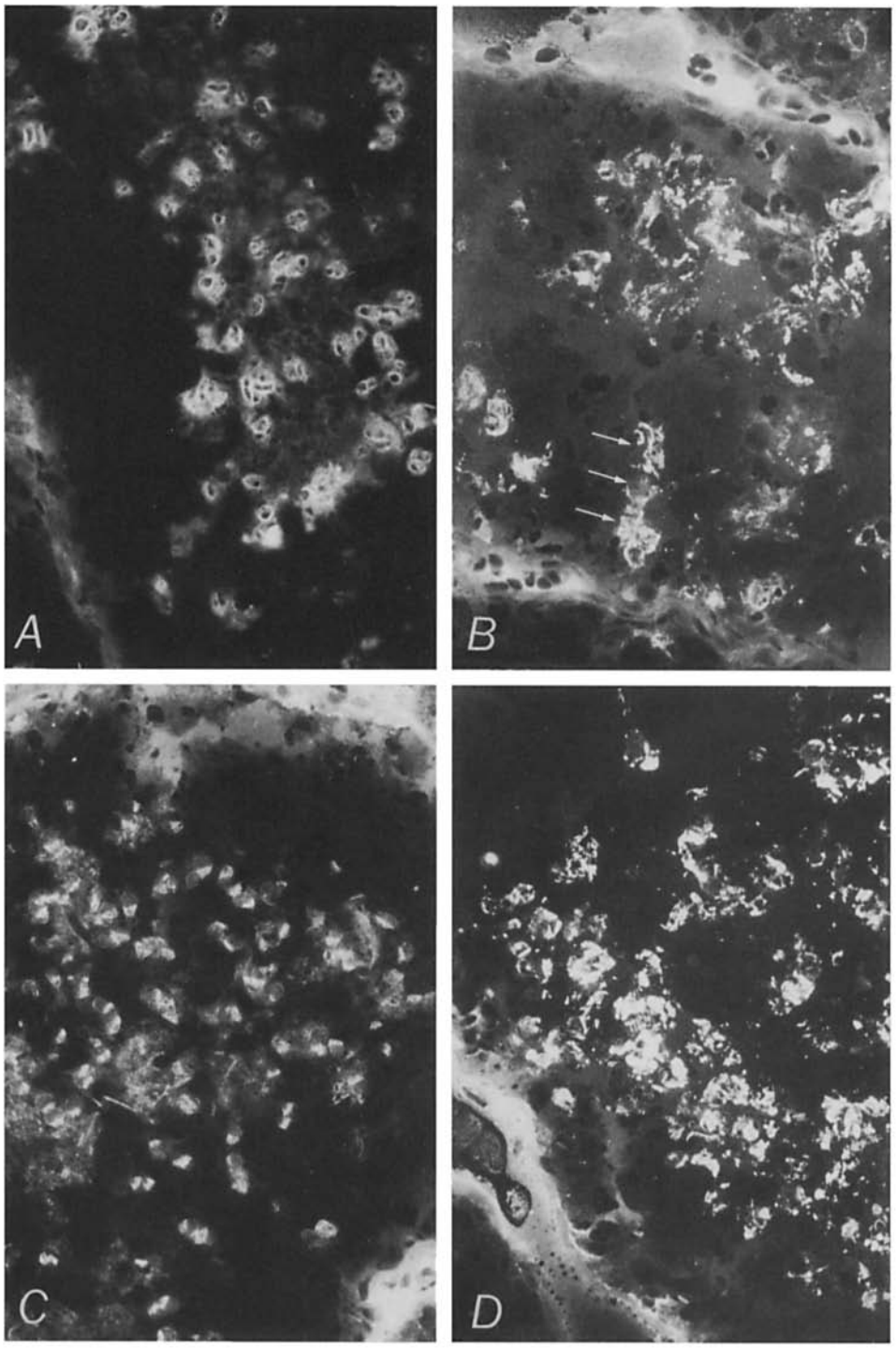

FIG. 5. Detection by immunofluorescence of IgG (**A, B**) and PH-20 antigen (**C, D**) in the testis of a 300-g guinea pig immunized with PH-20 in CFA. **A**) Strong IgG staining of the spermatids is detected in testis with EAO. **C**) Spermatids and spermatozoa with positive postacrosomal PH-20 staining is noted in the section adjacent to **A**. **B**) Granular IgG is noted within the seminiferous tubules with EAO. **D**) PH-20 with distribution similar to that of IgG shown in **B** is detected on the adjacent section of **B**. The distribution of IgG and PH-20 in **B** and **D** suggest formation of PH-20 immune complexes putatively located within Sertoli cells (arrow in **B**). ×800.

which it was shown that orchitis and epididymitis developed in mice of different MHC haplotypes [21]. Since peptide recognition by T cells is controlled by the polymorphic MHC molecule, one interpretation is that orchitis and epididymitis are mediated by different antigenic peptides within the crude testicular homogenates. The present finding therefore provides evidence that the responses to different testicular antigenic molecules are responsible for lesions in two different anatomical sites in the male reproductive system, and that testicular antigens other than PH-20 are required for epididymitis in the guinea pig.

In PH-20-immunized males, correlations were found between infertility and three histopathological changes: abnormal caudae epididymides, orchitis, and extensive aspermatogenesis. While the absence of epididymal spermatozoa is the obvious cause of male infertility, orchitis and aspermatogenesis may contribute to the epididymal changes by reducing germ cell production or causing excessive germ cell destruction in the testis. Excessive sperm phagocytosis observed along the male reproductive tract may also contribute to loss of germ cells, notwithstanding the lack of statistical correlation between infertility and the extent of sperm phagocytosis in the rete testis per se. Finally, abnormal spermatozoa found in many of the caudae epididymides of infertile animals may indicate direct sperm cytotoxicity within the epididymal lumen. The mechanism respon-

Downloaded from https://academic.oup.com/biolreprod/article/56/5/1133/2760778 by guest on 04 September 2024

sible for such sperm cytotoxicity in the epididymal lumen is unknown but apparently very effective.

Because EAO is transferrable by CD4+T cells from diseased donors, past studies on guinea pig and murine EAO have focused largely on the T-cell mechanism in these autoimmune diseases. Focal to extensive orchitis was induced by T cells injected directly into testes of syngeneic normal guinea pigs, and focal aspermatogenesis followed as a consequence [10, 11]. In murine EAO induced by crude testis homogenates, the pathogenic T cells were identified to be CD4+CD8− [22]. Moreover, the Th1 subset of CD4+T cells had the capacity to cause EAO since all orchitogenic T-cell clones and lines produced interleukin (IL) 2 and not IL4 when stimulated by testis antigens in vitro [23]. This is supported by the ability of antibody to tumor necrosis factor α to block disease transfer [23]. In contrast to a T-cell mechanism, transfer of guinea pig EAO by antibody occurred only in recipients given CFA, and this has not been demonstrated in murine EAO.

In this study, extensive antibody binding to testicular spermatids and spermatozoa was observed. Entrance of antibody to the seminiferous tubules had most likely followed the loss of blood-testis barrier integrity between Sertoli cells, as this is known to occur in guinea pig and murine EAO [24, 25]. At present, it is unclear why similar antibody binding is not detected on testicular germ cells in guinea pig EAO or in murine EAO induced by crude testis antigens [13, 25]. With PH-20 immunization, we now acquire evidence that antibody can access germ cells behind the blood-testis barrier and is therefore a potential player in the mechanism of EAO.

Antibody binding to germ cells can facilitate their removal through opsonization, as evidenced by macrophage phagocytosis of spermatozoa in the rete testis and the proximal caudae epididymides. In addition, the granular PH-20 and IgG detected within the walls of the seminiferous tubules may represent cytolysis and formation of immune complexes between sperm surface protein PH-20 antigen and antibody. Their distribution suggests tentatively that the immune complexes might be taken up by Sertoli cells. Antibody binding to spermatozoa can potentially activate the complement pathway and further facilitate cellular destruction. However, complement component C3 was not observed in these animals.

In the fertility study [2], return of fertility was observed after 6–12 mo in the ~300-g males but not in the ~650-g males. The latter usually remained infertile at 12 mo. In this study of the pathology, some of the testes of the ~650-g males had focal orchitis and minimal aspermatogenic tubules, yet their caudae epididymides were empty or they contained abnormal spermatozoa. The loss of epididymal sperm in males of different body weights (or ages) is apparently based on mechanisms that we do not yet understand. A systematic, longitudinal study on ~650-g males will be required to resolve this important observation.

REFERENCES

1. Lou YH, Ang J, Thai H, McElveen F, Tung KSK. A zona pellucida 3 peptide vaccine induces antibodies and reversible infertility without ovarian pathology. J Immunol 1995; 155:2715–2720.
2. Primakoff P, Woolman-Gamer L, Tung KSK, Myles DG. Reversible contraceptive effect of sperm PH-20 immunization in male guinea pigs. Biol Reprod 1997; 56:1142-1146.
3. Haas G Jr, Bronson RA, Cruz OJ, Fusi FM. Antisperm antibodies and infertility. In: Bronson RA, Alexander NJ, Anderson D, Ware Branch D, Kutteh WH (eds.), Reproductive Immunology. Blackwell Science Publishers; 1996: 171–211.
4. Bronson RA, Cooper GW, Rosenfeld D. Sperm antibodies: their role in infertility. Fertil Steril 1980; 42:171–183.
5. Jackson JJ, Hagopian A, Carlo DJ, Limjuco GA. Experimental allergic aspermatogenic orchitis. I. Isolation of a spermatozoal protein (AP1) which induces allergic aspermatogenic orchitis. J Biol Chem 1975; 250:6141–6150.
6. Hagopian A, Jackson JJ, Carlo DJ, Limjuco GA, Eylar EH. Experimental allergic aspermatogenic orchitis. III. Isolation of spermatozoal glycoproteins and their role in allergic aspermaotgenic orchitis. J Immunol 1975; 115:1731–1743.
7. Teuscher C, Wild GC, Tung KSK. Acrosomal autoantigens of guinea pig sperm. I. The purification of an aspermatogenic protein, AP2. J Immunol 1983; 130:317–322.
8. Teuscher C, Wild GC, Tung KSK. Experimental allergic orchitis: the isolation and partial characterization of an aspermatogenic polypeptide (AP3) with an apparent sequential disease-inducing determinant(s). J Immunol 1983; 130:2683–2688.
9. Tung KSK, Teuscher C. Mechanisms of autoimmune disease in the testis and ovary. Hum Reprod Update 1995; 1:35–50.
10. Tung KSK, Unanue ER, Dixon FJ. Pathogenesis of experimental allergic orchitis. I. Transfer with immune lymph node cells. J Immunol 1971; 106:1453–1462.
11. Tung KSK, Leong C, McCarty TA. Pathogenesis of experimental allergic orchitis. III. T-lymphocyte requirement in local adoptive transfer by peritoneal exudate cells. J Immunol 1977; 188:1774–1779.
12. Pokorna Z. Passive transfer of experimental autoimmune aspermatogenesis by noncellular cytophilic material in recipients treated with amethopterin. Folia Biol (Prague) 1970; 16:222–224.
13. Tung KSK, Unanue ER, Dixon FJ. Pathogenesis of experimental allergic orchitis. II. The role of antibody. J Immunol 1971; 106:1463–1472.
14. Willson JT, Jones NA, Katsh S. Penetration of the testicular-tubular barrier by horseradish peroxidase induced by adjuvant. Anat Rec 1973; 176:85–100.
15. Toullet F, Voisin GA. Passive transfer of specific lesions by anti-autoantigenic antibodies of spermatozoa. Ann Inst Pasteur 1972; 123:116.
16. Primakoff P, Hyatt H, Myles DG. A role for the migrating sperm surface antigen, PH-20, in guinea pig sperm binding to the egg zona pellucida. J Cell Biol 1985; 101:2239–2244.
17. Tung KSK, Unanue ER, Dixon FJ. The immunopathology of experimental allergic orchitis. Am J Pathol 1970; 60:313–328.
18. Willenborg DO. Experimental allergic encephalomyelitis in the Lewis rat: studies on the mechanism of recovery from disease and acquired resistance to reinduction. J Immunol 1979; 123:1145–1150.
19. Karpus WJ, Swanborg RH. Suppressor cells inhibit the function of effector cells of experimental autoimmune encephalomyelitis through a mechanism involving transforming growth factor-β. J Immunol 1991; 146:1163–1168.
20. Lou YH, McElveen F, Adams S, Tung KSK. Altered target organ, a mechanism of postrecovery resistance to murine autoimmune oophoritis. J Immunol 1995; 155:3667–3673.
21. Tung KSK, Teuscher C, Smith S, Ellis L, Dufau ML. Factors that regulate the development of testicular autoimmune diseases. In: Catt KJ, Dufau ML (eds.), Hormone Action and Testicular function. Ann NY Acad Sci 1985; 70:171–188.
22. Mahi-Brown CA, Tung KSK. Activation requirements of donor T cells and host T cell recruitment in adoptive transfer of murine experimental autoimmune orchitis (EAO). Cell Immunol 1989; 124:368–379.
23. Yule TA, Tung KSK. Experimental autoimmune orchitis induced by testis and sperm antigen-specific T cell clones: an important pathogenic cytokine is tumor necrosis factor. Endocrinology 1993; 133: 1098–1107.
24. Pelletier R-M, Nemirovsky MS, Calvert R, Hugon JS. Effects of immunization with Freund's complete adjuvant and isologous spermatozoa on the seminiferous epithelium and blood-testis barrier in guinea pigs. Anat Rec 1981; 199:197–211.
25. Kohno S, Munoz JA, Williams TM, Teuscher C, Bernard CCA, Tung KSK. Immunopathology of murine experimental allergic orchitis. J Immunol 1983; 130:2675–2682.

Downloaded from https://academic.oup.com/biolreprod/article/56/5/1133/2760778 by guest on 04 September 2024