108 Nails

MARK HOLZBERG

Definition

The nail is an infolding of skin that occurs at the terminal end of each digit, creating four specialized components: proximal nail fold, matrix, nail bed, and hyponychium (Figure 108.1). The epidermis of each component may form a modified horny material at each site: the undersurface of the proximal nail fold forms the cuticle and the matrix forms the hard nail plate. The whitish crescent-shaped lunula is the portion of the matrix that can be seen through the transparent nail plate proximal to the pink nail bed. Nails protect the terminal phalanges and assist in grasping minute objects.

Technique

Examination of the nail in a systematic manner is not unlike the systematic examination of the cardiovascular system. For the heart, there is a proper position for examination, at the patient's right side, and a proper sequence in examination, beginning at the upper right sternal border and sequentially moving to the apex. At each location, inspection, palpation, and auscultation are performed. A systematic examination of the nail is equally imperative. For the nail, the digit is held in the observer's hand so that the nail is closest for observation. Each component of the nail is examined sequentially, pausing at each location for the detection of abnormalities in color or shape:

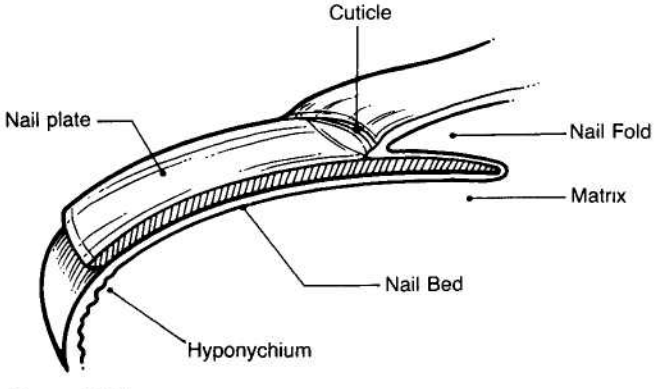

Figure 108.1
Normal nail.

Step 1: Examine the nail folds for abnormalities in color and shape.

Step 2: Examine the lunula for abnormalities in color and shape.

Step 3: Examine the nail bed for abnormalities in color and shape.

Step 4: Examine the hyponychium for abnormalities in color and shape.

Step 5: Return to the nail plate and examine it for abnormalities in color and shape.

When examining each component of the nail system, realize that the delicate interaction between vascular, melanocytic, and regenerative structures can easily be disturbed by a change in the body's normal homeostasis. Each change can produce a characteristic pattern of disruption. Swelling in paronychia or vascular changes in collagen vascular disease can be more easily appreciated in the nail fold where the dermis is thinned. In the matrix, fingernail is produced at a rate of 0.1 mm per day. Any condition causing change in the matrix regenerative ability is recorded in the outgrowing nail plate just as a climatological change is recorded in the rings of a tree. Since it takes approximately 3 to 4 months for the nail plate to grow out completely, the date of an illness causing a depression of plate growth (Beau's line) or abnormal nucleated cell growth (Mees' line) can be approximated. The specialized vascular system is responsible for the pink color of the nail bed. Deciding whether a change is present in the plate or bed can be difficult. For example, Muehrcke lines (edema pushing the overlying nail plate away from the nail bed in characteristic white transverse bands of pallor) may be confused with Mees' lines. Three simple tests will help distinguish between a nail bed process and a nail plate process. First, examination of the nail over time will reveal that a bed process will not "grow out" with the plate. Second, nail bed processes are generally less opaque than plate processes. Third, pressure on the distal plate will blanche the bed vasculature and sometimes alter the appearance of a neighboring nail bed process.

Each nail on every digit must be examined in a systematic manner. The clue to diagnosing a patient's fever of unknown origin may lie in the splinter hemorrhage found in only one nail. Systematic examination and an understanding of patterns of disturbance can aid in the diagnosis of over 160 disorders.

Basic Science

The nail assists in grasping small objects and functions as a protective covering to the end of the digit. The hard nail

Olaplex EX2008
Page 1 of 4 Wella v. Olaplex
PGR2026-00010

plate is made up of flattened cells, with closely apposed and interlocking plasma membranes, and keratin, with a high content of cystine disulfide bonds. The plate is transparent due to the absence of nuclei within these cells. Through the nail plate, the proximal half-moon lunula and distal nail bed can be seen. The lunula is the distalmost part of the matrix that can be seen. The matrix appears white due to the thickened epidermis in this region and the light-scattering effect of nucleated cells. The epidermis of the nail bed is thinner and more vascular and is therefore clinically pinker. The epidermis and dermis of the nail bed are oriented in ridges parallel to the direction of nail growth. Each ridge contains fine capillaries that, when disrupted, can lead to a small "splinter" hemorrhage that fills a neighboring valley. The epidermis of the nail bed contributes a small amount of keratin to the underside of the nail plate. This allows the nail plate to adhere to the underlying nail bed and glide smoothly as it grows.

Fingernails grow faster than toenails. A thumbnail grows at a rate of approximately 0.1 mm per day. Toenails grow one-third to one-half as fast. The nail plate may thin, incorporate pigment, or retain clinically white nucleated cells during a systemic disease. These examples are but a few of the multiple ways in which the nail can be used as a record of past events.

Clinical Significance

The Nail Fold

Nail fold telangiectasia is present in a number of disorders. Dilated capillary loops in patients with collagen vascular disease can be appreciated more easily if they are visualized through a drop of oil placed on the nail fold and viewed with an ophthalmoscope set at +40 (×10). Thick "sausage" vessels in a bushy pattern are characteristic of dermatomyositis, scleroderma, and Raynaud's phenomenon; thinner, more meandering vessels are associated with systemic lupus erythematosus.

Bywaters' lesions are characterized as small, painless, reddish-brown infarcts in the nail fold (Figure 108.2), which may darken and fall off, leaving a tiny pitlike depression. Vasculitis, especially rheumatologic, produces these lesions.

Paronychia, swelling and inflammation of the proximal or lateral nail folds, can be acute or chronic. An acute paronychia represents an abscess or cellulitis usually preceded by a traumatic event. Chronic paronychia is usually related to moisture. The onset is vague, it may cause matrix abnormalities leading to Beau's lines, and it is usually associated with an absent cuticle creating an excellent entry site for *Candida.*

Warts are the most common *tumor* of the nail fold. Verrucous in quality, these can be easily differentiated from the smooth, round appearance of a myxoid cyst. Smooth, more linear, periungual angiofibromas (Koenen's tumors) can be seen in 50% of patients with tuberous sclerosis. Skin malignancies are also found in the nail fold.

The Lunula

The normally white lunula may become blue in Wilson's disease or argyria. The lunula may become red in cardiac failure or carbon monoxide poisoning.

The lunula normally increases in size in fingers closest to the thumb; however, the lunula becomes smaller or absent in old age.

The Nail Bed

A thin, 0.5 to 3.0 mm, red to brown distal transverse band characterizes *Terry's nails* (Figure 108.3). When the proximal pallorous nail bed is congested with blood by manually occluding venous outflow, this band must still be easily distinguishable. Terry's nails normally occur in older patients, but suspicion of cirrhosis, chronic congestive heart failure, and adult-onset diabetes mellitus should be raised in younger patients. Vascular telangiectasias in the distal nail bed produce the color change.

A brown distal band occupying approximately 20 to 50% of the nail bed, termed *Lindsay's nail (half and half nail),* is associated with chronic renal failure (Figure 108.4). Abnormal melanin pigment may be responsible for the disorder.

In *Muehrcke's nail,* edema of the nail bed causes characteristic pale transverse bands when the serum albumin falls below 2.2 gm/dl (Figure 108.5). Muehrcke lines disappear when the serum albumin surpasses 2.2 gm/dl.

Splinter hemorrhages are an important diagnostic sign. The vascular nail bed is organized into parallel longitudinal dermal ridges oriented along the axis of nail growth. If the blood vessels in these ridges are disrupted, a small amount of hemorrhage fills the valley between two ridges, giving

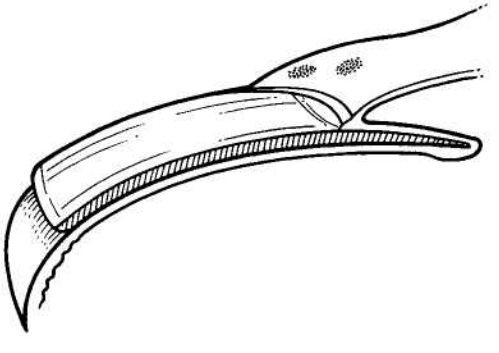

Figure 108.2
Bywater's lesion.

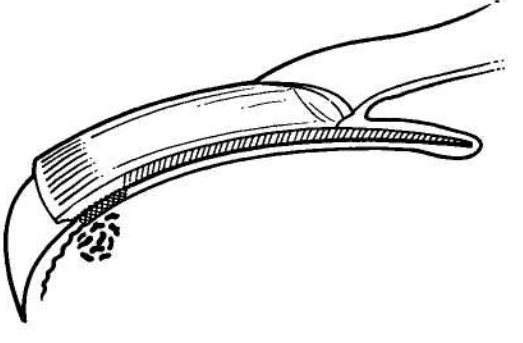

Figure 108.3
Terry's nail.

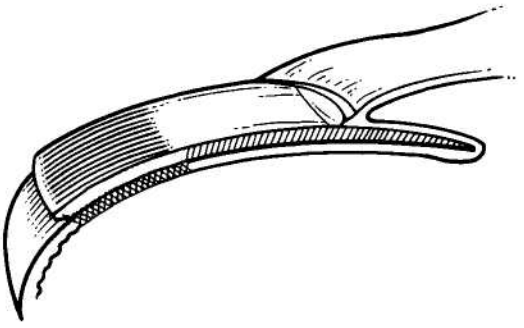

Figure 108.4
Lindsay's nail.

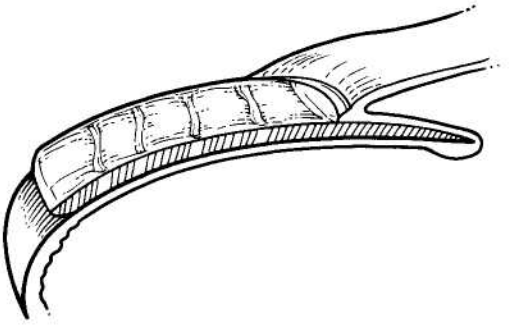

Figure 108.6
Mees' lines.

the characteristic appearance of a splinter. Splinter hemorrhages are most commonly associated with light trauma; however, when associated with fever and cardiac murmur, bacterial endocarditis must be suspected. Cirrhosis, vasculitis, and scurvy will also produce splinter hemorrhage, but when all nails are simultaneously affected, trichinosis becomes an important consideration.

Carbon monoxide poisoning produces cherry red nail beds due to bright red carboxyhemoglobin. Polycythemia will also produce a red-appearing nail bed, just as anemia produces pallor.

Separation of the nail bed from the overlying plate creates a white-appearing proximal extension of free air, termed *onycholysis*. The space may fill with dirt, accentuating the change. Both exogenous and endogenous (systemic and dermatologic disease) etiologies should be considered. Trauma, maceration, Pseudomonas, fungal infection, chemicals, and nail cosmetics can cause this separation. Photoinduced onycholysis can be caused by tetracycline derivatives, oral contraceptives, and chlorpromazine. Systemic endocrine causes of onycholysis are hypothyroidism, thyrotoxicosis (usually of the fourth finger), pregnancy, and diabetes mellitus. Hyperkeratotic plaques of psoriasis can push the overlying plate away from the bed.

The Hyponychium

The hyponychium is at the most distal region of the nail bed and marks the transition to normal skin. Tumors such as warts or Koenen's subungual angiofibromas of tuberous sclerosis are seen in the hyponychium. Fungi enter the nail unit in this area, causing onychomycosis.

The Nail Plate

Leukonychia (opaque white discoloration) may be linear (Mees' lines), punctate, or diffuse. *Mees' lines* are transverse white lines present in the same relative position on more than one nail (Figure 108.6). Many systemic conditions can cause an insult to the matrix, which in turn produces abnormal nucleated cells, creating a white appearance in a normally transparent plate. Classically, arsenic produces Mees' lines; however, these white lines can also be produced by other pharmacologic, infectious, or systemic assaults on nail plate-forming cells. Local trauma to an isolated area of the matrix most commonly produces a punctate leukonychia. Congenital conditions or fungus produce diffuse whitening of the plate.

A small focus of pigment-producing cells in the nail matrix will deposit pigment into the section of plate it produces, creating a longitudinal brown band oriented along the direction of nail growth. *Longitudinal brown streaks* are most commonly seen in junctional nevi in the matrix of black patients (Figure 108.7). However, a nevus presenting in an older white patient is very unusual. A search for generalized hyperpigmentation, especially in the palmar creases and in the oral mucosa, must be performed when considering adrenal insufficiency. Digital and perioral melanotic macules in association with longitudinal brown streaks can be seen

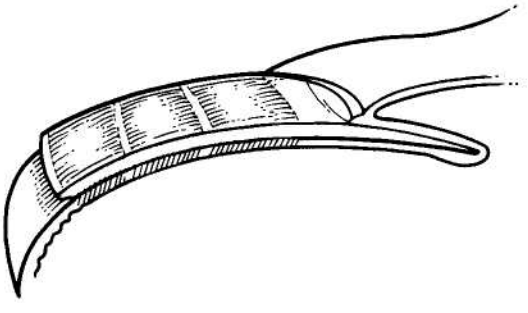

Figure 108.5
Muehrcke's nail.



Figure 108.7
Junction nevus.

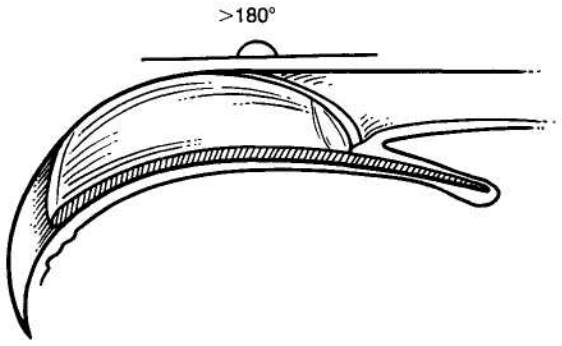

Figure 108.8
Clubbing.



Figure 108.10
Onychorrhexis.

in Peutz-Jeghers syndrome. If no underlying association can be found, malignant melanoma must be considered as a cause.

Other discolorations may occur from a variety of causes. Diffuse yellowing of the nail plate is seen in yellow nail syndrome, a condition associated with lymphedema and pulmonary complications. Diffuse brown discoloration can be found in patients with acanthosis nigricans, adrenal insufficiency, or in patients on cancer chemotherapeutics. Brownish discoloration is seen in cigarette smokers due to local deposits of nicotine and tar. Silver-blue nail plates are associated with Wilson's disease, argyria, and antimalarial drug use. Pyocyanin production by Pseudomonas will tint the plate green.

Clubbing (Hippocratic nail) occurs when local cyanosis produces hypervascularity beneath the nail matrix, elevating it further above underlying bone. In doing so, the angle between the proximal nail fold and nail plate (Lovibond's angle) exceeds 180 degrees (Figure 108.8). A bulbous "watchglass" appearance accompanies this change. Clubbing may be familial or it may be acquired, most commonly due to a hypoxia-associated thoracic condition. Chronic, infectious, or malignant bronchopulmonary disease or cardiovascular disease is often implicated. Less frequent causes are cirrhosis and inflammatory bowel diseases.

A characteristic concave *koilonychia* (spoon nail) may be inherited or acquired. Iron deficiency anemia and other hematologic conditions, syphilis, and thyroid disease are acquired disease states producing koilonychia.

During a significant illness or infection, matrix function diminishes producing a thinner than normal plate. Following resolution of the illness, matrix function returns to normal. The transverse depression produced, termed a *Beau's line* (Figure 108.9), grows out, with nail growth enabling the observer to date the original illness. Febrile and infectious disease states, dermatologic disease, treatment with antimitotic drugs, myocardial infarction, and surgical operations are associated with Beau's lines.

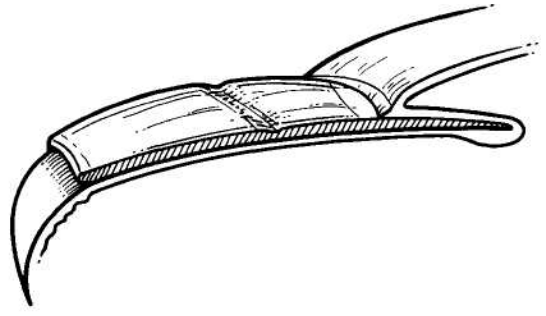

Figure 108.9
Beau's line.

Pitting has several causes. Focal abnormal keratinization of the nail plate leaves pitlike depressions in patients with psoriasis. Pitting is less irregular, more geometric, and shallower in patients with alopecia areata or eczematous dermatitis.

Onychorrhexis (longitudinal ridging) in the nail plate due to irregularities in matrix shape are seen in nails of the elderly and in patients with rheumatoid arthritis (Figure 108.10). Ridges may take on a beaded "sausage link" appearance in older patients.

Onychogryphosis occurs when the nail plate thickens, the nail bed is hyperkeratotic, and uneven growth occurs at the matrix. The thick nail grows spirally like a ram's horn. Onychogryphosis occurs commonly in the elderly but can occur in younger patients in onychomycosis or due to matrix injury.

Fungal infection entering from the distal nail can cause disruption of the plate, friability, and destruction. Abnormal keratinization in psoriasis produces a similar pattern.

References

Bywaters EG. Peripheral vascular obstruction in rheumatoid arthritis and its relationship to other vascular lesions. Ann Rheum Dis 1957;16:84–103.

Daniel CR, Osment LS. Nail pigmentation abnormalities. Their importance and proper examination. Cutis 1980;25:595–560.

DeNicola P, Morsiani M. Nail diseases in internal medicine. Springfield: Charles C Thomas, 1974.

Holzberg M, Walker HK. Terry's nails: revised definition and new correlations. Lancet 1984;1:896–99.

Kechijian P. Onycholysis of the fingernails: evaluation and management. J Am Acad Dermatol 1985;12:552–60.

Kenik JG, Maricq HR, Bole GG. Blind evaluation of the diagnostic specificity of nailfold capillary microscopy in the connective tissue diseases. Arthritis Rheum 1981;24:885–91.

Lindsay PG. The half-and-half nail. Arch Intern Med 1967;119:583–87.

Pierre M, ed. The nail. Edinburgh: Churchill Livingstone, 1981.

Zaias N. The nail in health and disease. New York: Spectrum, 1980.

Zaias N, Baden HP. Nails. In: Fitzpatrick TB, et al., eds. Dermatology in general medicine. 2nd ed. New York: McGraw-Hill, 1979;418–37.