This material may be protected by Copyright law (Title 17 U.S. Code)

The Journal of Foot & Ankle Surgery 52 (2013) 465–469

Contents lists available at ScienceDirect

The Journal of Foot & Ankle Surgery

journal homepage: www.jfas.org

Fixation of Lapidus Arthrodesis with a Plantar Interfragmentary Screw and Medial Locking Plate: A Report of 88 Cases

James M. Cottom, DPM, FACFAS [1], Anand M. Vora, MD [2]

[1] Department of Orthopedic Surgery, Sarasota Orthopedic Associates, Sarasota, FL
[2] Illinois Bone and Joint Institute, Libertyville, IL

ARTICLE INFO

Level of Clinical Evidence: 3
Keywords:
bunion
cuneiform
fusion
hallux valgus
internal fixation
metatarsal
weightbearing

ABSTRACT

Lapidus arthrodesis is a powerful procedure that can be used to correct pathologic features within the forefoot or midfoot. Many different methods of fixation for this procedure have been reported. The use of plating constructs has been shown to provide increased stability compared with screw-only constructs. The technique we have described consists of a plantar to dorsal retrograde lag screw across the arthrodesis site, coupled with a low-profile medial locking plate. A total of 88 consecutive patients were treated with this modification of the Lapidus procedure by 2 surgeons and were retrospectively evaluated. All patients followed an early postoperative weightbearing protocol. Patient age, gender, follow-up duration, interval to weightbearing and radiographic fusion, preoperative and postoperative intermetatarsal angle, hardware removal, preoperative and postoperative American Orthopaedic Foot and Ankle Society midfoot scores, and adjunct procedures were analyzed. The mean follow-up period was 16.76 ± 5.9 (range 12 to 36) months, and all healed fusions demonstrated radiographic union at a mean of 51 ± 19.1 (range 40 to 89) days. The patients were treated with weightbearing starting a mean of 10.90 ± 4.1 (range 5 to 28) days postoperatively. Complications included 15 patients (17%) requiring hardware removal, 2 cases (2%) of hallux varus, 6 cases (7%) of radiographic recurrent hallux valgus, and 2 patients (2%) with first metatarsocuneiform nonunion. The results of the present study have demonstrated that plantar lag screw fixation with medial locking plate augmentation for Lapidus arthrodesis allows for early weightbearing with satisfactory outcomes, improved clinical and radiographic alignment, and improved American Orthopaedic Foot and Ankle Society scores.

© 2013 by the American College of Foot and Ankle Surgeons. All rights reserved.

More than 130 procedures have been described for the treatment of hallux abductovalgus (HAV) (1). Indications for the Lapidus procedure include the presence of hypermobility in the first ray, a large first intermetatarsal angle (IMA), arthrosis of the first metatarsocuneiform joint, recurrent HAV, instability of the medial column, and some cases of juvenile HAV. Many different internal fixation options have been described for the Lapidus procedure. Furthermore, a number of surgeons have recommended a postoperative course of non-weightbearing for up to 6 to 8 weeks or longer after Lapidus arthrodesis. In the present retrospective cohort study, we have described an alternative internal fixation option for the Lapidus procedure that will provide increased construct stability and, ultimately, allow the patient to bear weight on the operated foot early in the postoperative period. The construct consists of the combination of a retrograde plantar to dorsal lag screw directed from the plantar aspect of the first metatarsal to the superior aspect of the medial cuneiform, combined with a low-profile, medially applied, locking plate placed across the arthrodesis site.

Patients and Methods

To be included in the cohort, consecutive patients had to have undergone Lapidus arthrodesis with a plantar to dorsal retrograde lag screw combined with a low-profile locking plate applied medially across the arthrodesis site and to have had a minimum of 1 year of follow-up. Two surgeons (J.M.C., A.M.V.) performed all the procedures, and the patients were identified in the surgeons' practices. A retrospective chart assessment was performed of all patients with a minimal follow-up of 1 year, and the data were reviewed by both of us (J.M.C., A.M.V.). Additional inclusion criteria were a painful HAV deformity for which conservative treatment had failed, an IMA greater than 10°, clinical or radiographic evidence of first MTC instability in the coronal or sagittal plane (ie, plantar gapping of first MTC joint on lateral view), clinical signs of systemic laxity, and any revision hallux valgus correction procedure. The exclusion criteria included any previous attempted Lapidus fusion, Charcot neuropathy, diabetes, an intermetatarsal angle less than 10°, and first metatarsal-phalangeal joint arthritis.

The demographic variables, including gender, age, extremity involved, pre- and postoperative first IMAs, follow-up duration, and interval to full weightbearing were recorded. The radiographic review included evaluation of the interval to union of the arthrodesis site and evaluation of the weightbearing preoperative and postoperative

Financial Disclosure: None reported.
Conflict of Interest: Drs. Cottom and Vora are consultants for Arthrex, which had no role in the design of the investigation, data analysis, or writing of the report.
Address correspondence to: James M. Cottom, DPM, FACFAS, Department of Orthopedic Surgery, Sarasota Orthopedic Associates, Sarasota, FL 34239.
E-mail address: jamescottom300@hotmail.com (J.M. Cottom).

1067-2516/$ - see front matter © 2013 by the American College of Foot and Ankle Surgeons. All rights reserved.
http://dx.doi.org/10.1053/j.jfas.2013.02.013

Paragon 28 v. Treace Medical Concepts
PGR2026-00020
Paragon Ex. 1012

first IMAs. The first IMA was measured and compared using the technique described by Sangeorzan and Hansen (2) with a digital caliper. Osseous union was ascertained by the presence of trabeculation across the fusion site on 3 radiographic views taken with a digital x-ray machine and evaluated by us (J.M.C., A.M.V.). Any hardware complications were recorded, along with the removal of hardware and the mean interval to removal. Adjunct procedures performed in conjunction with the Lapidus arthrodesis were also recorded. In addition, the American Orthopaedic Foot and Ankle Society preoperative and postoperative midfoot scores were compared (3,4).

The data were considered in regard to type and distribution. Statistical comparisons were made between the preoperative and postoperative radiographic values and American Orthopaedic Foot and Ankle Society scores. Statistical significance was defined at the 5% level ($p \leq .05$).

Surgical Technique

The surgical procedure was performed according to the technique described by Cottom (5). A standard lateral release of the first metatarsal-phalangeal joint was performed. Next, after meticulous preparation of the fusion site, a guide wire for a 4.5-mm screw was placed in the central aspect of the first metatarsal base and driven inferior, aiming for the proximal metaphyseal–diaphyseal junction of the first metatarsal (Fig. 1). The wire was driven though the plantar skin under the first metatarsal; the tip of the wire should just be visible within the first metatarsal so that the joint surfaces can be apposed. If deemed necessary, demineralized bone matrix (used by J.M.C.) or autogenous bone (used by A.M.V.) can be placed within the fusion site. The first IMA was then reduced with a large, pointed, bone reduction clamp. This was done by placing 1 arm of the clamp on the lateral aspect of the second metatarsal head through the incision used to perform the lateral release, with the other arm placed over the medial aspect of the first metatarsal. The clamp was then closed, and the first IMA was "dialed" to the desired amount of correction (Fig. 2). The hallux was then dorsiflexed, and the surgeon was able to compress the fusion site and manipulate the base of the first metatarsal in the sagittal plane to the desired level. The guide wire was then driven in a retrograde manner into the medial cuneiform. Placement of the wire was confirmed with both anteroposterior and lateral views intraoperatively to ensure the navicular–cuneiform joint was not compromised (Fig. 3). Through a small stab incision plantarly, and with careful retraction of the soft tissues, a 4.5-mm cannulated screw was then inserted and compression of the arthrodesis site noted. At that point, a low-profile, locking plate (LPS Lapidus Plate, Arthrex, Naples, FL) was positioned along the medial aspect of the first metatarsal and medial cuneiform. Careful attention must be given to avoid transecting the insertion of the anterior tibial tendon. A small "pocket" was then created with a small hemostat, lifting as little as possible of the anterior tibial tendon off the medial aspect of the medial cuneiform, to create room for the plate. The plate was then provisionally fixed to the medial column and the position checked using fluoroscopy (Fig. 4). Occasionally, a bony prominence will be noted at the base of the first metatarsal and must be resected to allow the plate to lie flush with the bone. Once the position was confirmed, locking screws were inserted proximally within the plate into the medial cuneiform. Next, the compression slot within the plate was drilled, aiming either proximally across the fusion site between the locking screws or, alternatively, eccentrically and perpendicular to the shaft of the second metatarsal. If the screw was to be placed proximally, it was inserted using a lag technique. Finally, the distal locking screw was inserted within the plate, and the bone reduction clamp was removed. At this point, the hypertrophic bone at the medial aspect of the head of the first metatarsal can be resected if necessary (Fig. 5). Closure was performed in anatomic layers, and a sterile gauze bandaged was applied. Postoperatively, the patient used a short-leg boot walker and crutches. Postoperatively, the patient was kept non-weightbearing for 7 to 10 days until skin wound healing had occurred. The patient was then allowed full weightbearing in the boot walker, with an attempted return to regular shoe gear at 6 to 8 weeks postoperatively, as allowed by the swelling about the operative site. In addition, once the patient returned to regular shoe gear, physical therapy was initiated.

Fig. 2. Bone reduction clamp placed on the first and second metatarsal heads and the first intermetatarsal angle is reduced and checked with fluoroscopy. One must be careful not to fracture the metatarsal heads with this maneuver.

Results

A total of 88 patients met our inclusion criteria and were included in the analyses. No patients were lost to follow-up. The mean duration of follow-up was 16.76 (range 12 to 36) months. Of the 88 patients, 72 were females (81.82%) and 16 were males (18.18%). Their mean age

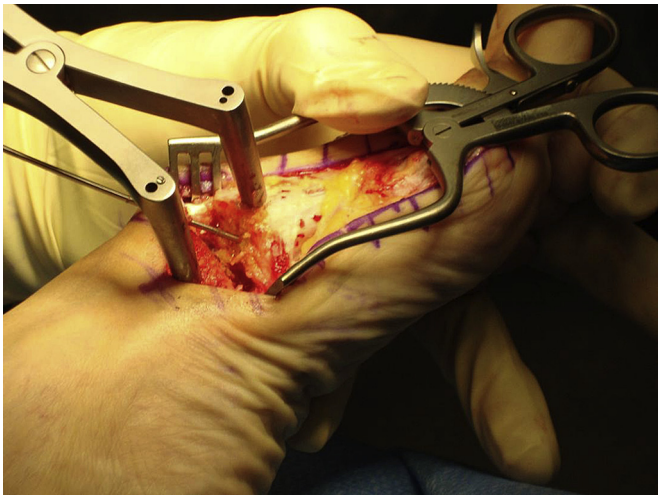

Fig. 1. Guide wire for 4.5-mm cannulated screw introduced into base of first metatarsal and directed out the plantar aspect of the first metatarsal at the proximal diaphyseal–metaphyseal junction. The wire should exit the plantar aspect of the foot. Note, the central placement of the wire in the first metatarsal base.

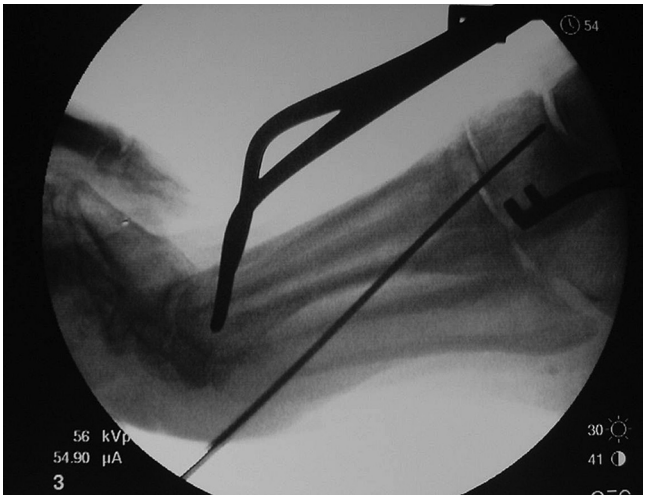

Fig. 3. The hallux is dorsiflexed and the Windlass mechanism engaged. The first metatarsal can be manipulated in the sagittal plane and the fusion site compressed. The guide wire is then moved retrograde into the medial cuneiform. The position of the wire is checked using fluoroscopy.

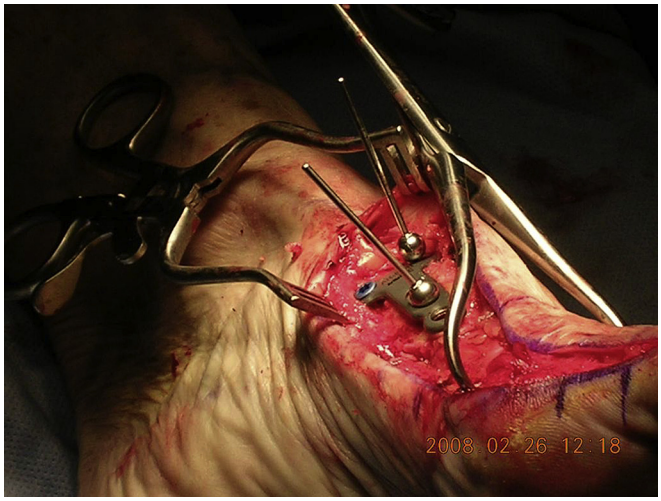

Fig. 4. Low-profile locking plate applied to the medial aspect of the fusion site. Careful attention should be paid not to disrupt the insertion of the anterior tibial tendon. The position of the plate is checked with fluoroscopy before definitive fixation is placed.

was 61.9 (range 22 to 81) years at surgery. The right foot was involved in 55 cases (63%) cases and the left in 33 (37%). No bilateral cases were included in the present series. The mean interval to full weightbearing in a controlled ankle motion walking boot was 10.9 (range 7 to 28) days. Radiographic union at the Lapidus arthrodesis site was deemed complete at a mean of 51 (range 41 to 68) days. Adjunct procedures included distal soft tissue first metatarsophalangeal joint lateral release in all 88 patients (100%). Additional procedures included bone marrow aspiration from the ipsilateral calcaneus and deposited at the fusion site in 66 (75%), autogenous calcaneal bone graft harvest and interposition at the fusion site in 22 (25%), Weil osteotomy of a lesser metatarsal in 51 (57.8%), DuVries lesser metatarsal head condylectomy in 19 (21.6%), tailor's bunionette correction in 4 (4.55%), Youngswick-modified chevron bunionectomy in 4 (4.55%), and an Akin hallux osteotomy in 10 (11.36%). In 2 patients, (2.27%), nonunion occurred at the Lapidus fusion site; 1 patient (1.14%) underwent revision at 6 months and the other at 9 months postoperatively. One of the nonunion cases was revised with hardware removal, distal tibial bone graft, and revision plate and screw fixation. In this revision, a similar construct with an additional dorsal to plantar screw was used. The plate was applied further dorsally than normally to allow for better screw purchase, given the bone void from the previous plate and screw construct medially. The second nonunion case was suspicious for infection; thus, this patient underwent hardware removal and bone biopsy. The bone biopsy did not reveal any microorganism growth and was deemed an aseptic nonunion. To date, the latter patient has remained minimally symptomatic and has not required revision of the arthrodesis.

The first IMA was measured and compared with a weightbearing radiograph both preoperatively and postoperatively once the patients were full weightbearing after their Lapidus fusion procedure. The mean preoperative first IMA was 19.73° (range 10.5° to 31°); postoperatively, it was 4.32° (range 0° to 6.5°; $p < .001$). The American Orthopaedic Foot and Ankle Society midfoot scoring system was used in the present study and demonstrated a mean preoperative score of 54.48 (range 37 to 78) and a mean postoperative score of 88.24 (range 72 to 95), and this improvement was statistically significant ($p < .001$). The overall change in the preoperative and postoperative scores was +33.76 (range 12 to 73). A total of 15 medial low-profile locking plates (17%) were removed at an average of 22.5 (range 12 to 32) months because of symptomatic prominence of the hardware in all 15 patients. Six patients (6.82%) displayed radiographic evidence of recurrent hallux valgus, defined as the hallux drifting laterally more than 20° postoperatively; however, none was clinically symptomatic or required additional surgery. Two patients (2.27%) developed hallux varus, 1 (1.14%) of whom underwent subsequent surgical revision. The other patient with hallux varus was asymptomatic and has not required additional surgery to date. Two patients (2.27%) developed nonunion of the arthrodesis site. One patient (1.14%) remained asymptomatic with a pseudoarthrosis and has not required additional surgical intervention. In the 1 patient (1.14%) who underwent revision surgery for nonunion of the Lapidus arthrodesis, the patient also had dorsiflexion malunion and transfer metatarsalgia that was addressed surgically during the revision procedure. No other patients in the present series developed transfer metatarsalgia symptomatic enough to require additional surgical intervention.

Discussion

Hypermobility of the first ray and medial column has been associated with the onset of hallux valgus and lesser metatarsal overload (6–8). Albrecht (9) was the first to describe a first tarsometatarsal arthrodesis in 1911. In 1934, Lapidus (10) described his technique for correcting hallux valgus through a wedge osteotomy of the first metatarsal and fusion into the medial cuneiform, with fusion of the first and second metatarsal bases without internal fixation. Since

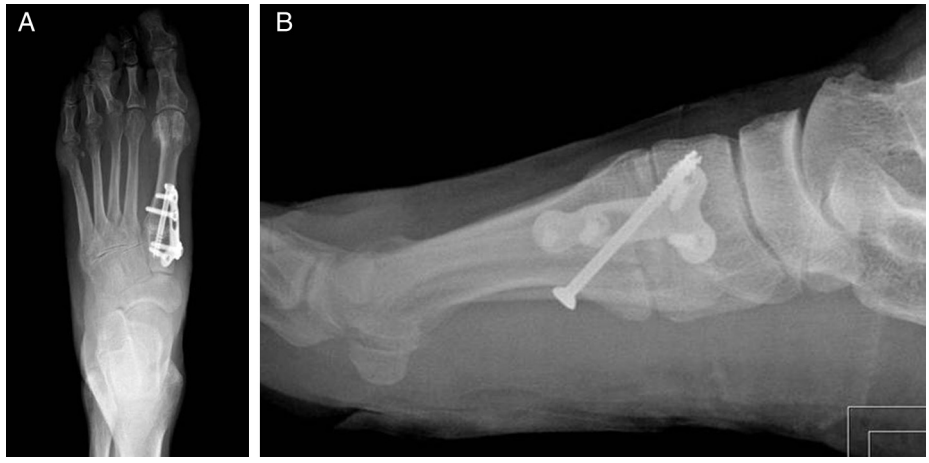

Fig. 5. (*A*) Anteroposterior radiograph showing excellent reduction of the first intermetatarsal angle with all hardware in good position. (*B*) Lateral view demonstrating placement of the plantar interfragmentary screw and plate fixation.

then, numerous modifications to the original Lapidus procedure have been introduced, including minimal bone resection and the addition of multiple screws and/or plates to assist fusion (7,9,11–17). Multiple fixation constructs have been well documented within published studies of first metatarsal–medial cuneiform arthrodesis. In 2010, Klos et al (6) reported on the stability of a medial locking plate with a dorsal to plantar compression screw versus fixation with 2 crossed screws. Eight pairs of fresh-frozen human specimens were used in a matched pair test. In the plate and screw group, an "X-plate" (X-locking plate 2.4/2.7 Synthes, Solothurn, Switzerland) was used. The plates were first secured into the first metatarsal by screws into the distal holes. Next, a 4-mm-diameter, cannulated, partially threaded, stainless steel screw was inserted dorsally into the first metatarsal and driven into the plantar aspect of the medial cuneiform. Then, screws were inserted into the proximal holes within the plate. In the crossed screw group, two 4-mm-diameter, cannulated, partially threaded, stainless steel screws were inserted, the first from dorsally to plantarly from the first metatarsal into the medial cuneiform and the second from dorsally to plantarly from the medial cuneiform into the proximal aspect of the first metatarsal. The screws crossed at a point on the longitudinal axis of the first metatarsal. The specimens were then tested in a 4-point bending test. The investigators found that during cyclic loading conditions, the construct using a medial locking plate with adjunct compression screw was superior to the construct using 2 crossed screws.

Saxena et al (18) compared the outcomes of the Lapidus procedure fixated with crossed lag screws versus a dorsal-medial locking plate with a plantar lag screw. A total of 40 patients were included in their retrospective study, with 19 patients in the crossed screw group and 21 in the plate with plantar lag screw group. In the plate group, a solid 3.5-mm screw was inserted plantarly from the base of the first metatarsal into the medial cuneiform with a Darco Modular Rearfoot System LPS Lapidus Plating System (Wright Medical Technology, Arlington, TN) locking plate. The plate was applied dorsomedially across the fusion site. This method was compared with 2 crossing 3.5-mm cortical fully threaded titanium screws applied in lag fashion. One was directed from the plantar–medial aspect of the first metatarsal into the medial cuneiform and the other from the dorsolateral aspect of the first metatarsal into the medial cuneiform. The investigators noted no statistically significant differences related to postoperative complications between the 2 groups but did note that the plate group allowed for earlier weightbearing (4 weeks versus 6 weeks in the screw group).

Scranton et al (17) reported on 10 matched pairs of cadaver feet that had either undergone the standard crossed 4.0-mm compression screw or fixation with a medial LPS locking Lapidus Plate (Arthrex). The cadaver constructs were stressed to failure using the INSTRON (Norwood, MA) and Wavemaker software (San Diego, CA) and noted that the load to failure was greater with the Lapidus plate and that the increased rigidity provided by these plates might minimize the risk of nonunion or malunion. A similar biomechanical study comparing the construct mentioned in our report and in the study by Scranton et al (17) was completed by 1 of us (J.M.C.). The study is pending publication in the "Journal of Foot and Ankle Surgery" and has demonstrated an increase in the strength of the fixation construct by 86.4%.

In 2008, Gruber et al (13) reported on 10 matched lower extremity pairs that either underwent a Lapidus procedure with 2 crossed, 4.0-mm, partially threaded, cannulated screws or a dorsomedial locking plate (Darco Modular Rearfoot System) LPS Lapidus Plating System (Wright Medical Technology), with a 4.0-mm, partially threaded, cannulated screw inserted from the dorsal aspect of the first metatarsal into the medial cuneiform. The specimens were then loaded in 4-point bend configuration until failure or 3 mm of deformation. The results demonstrated no difference in the load to failure or stiffness between the 2 groups, and the plate construct did not show different rigidity compared with the screw group.

Sorensen et al (8) reported on 21 patients who underwent a modified Lapidus procedure with a dorsomedial locking plate. Of the 21 patients, 19 had concomitant application of an interfragmentary screw, which was a partially threaded cannulated titanium screw. The investigators did not describe the orientation of the interfragmentary screw in their series. The locking plate was applied after screw fixation. They reported an average of 6.95 weeks to radiographic fusion, an average of 2 weeks to ambulation, a 9.52% rate of asymptomatic malunion, a 0% rate of delayed union or nonunion, and no revisions.

Klos et al (14) completed a cadaver study in 2011 to investigate the possible benefit of a compression screw combined with a plantarly applied, anatomically precontoured, plate versus a plate applied dorsomedially. Six pairs of human cadavers were randomized to receive either a dorsomedial H-shaped plate (Wright Medical Deutschland GmbH, Raisting, Germany) or a plantar Lapidus plate (Wright Medical Deutschland GmbH). In all samples, a 4-mm, cannulated, self-tapping, compression screw with a partial thread pattern was introduced first from the dorsal cortex of the first metatarsal into the medial cuneiform. The specimens were then loaded quasistatically, followed by cyclic loading to failure. The investigators noted in the static tests that the plantar plate construct was superior to the dorsomedial plate construct (14). They, therefore, concluded that plantar plating appears to offer a biomechanical benefit in the Lapidus arthrodesis (14).

We believe that the fixation construct we have described is a useful option for the Lapidus procedure. When a segment of bone is loaded vertically, there is congruent contact between the ends of the bone. During the stance phase of gait, potential disruptive distraction forces are created at the inferior aspect of the fusion site. Placement of a lag screw on the tension side of the arthrodesis can actually convert those forces into compression. Biomechanically, this should be a more stable and an inherently stronger fixation construct than the construct with a screw oriented across the dorsal aspect of the fusion site. Additional augmentation of plantar screw fixation with a medial locking plate might provide greater stability and strength to the fusion.

The present study had several limitations, primarily those inherent to all retrospective studies. First, just as with any radiographic evaluation, errors in patient positioning and rotation of the foot might account for some variability in radiographic measurements. We attempted to keep these errors to a minimum by having 1 of us (J.M.C.) perform all the measurements using a digital caliper. The small number of patients in the present series, the absence of a control group, and the relatively short follow-up period, all contributed to a less than perfect model. In addition, with the present study, we noted an increased rate of complications, most of the additional issues was related to the need for hardware removal only and were easily addressed once the hardware had been removed. We believe that hardware removal might be justified by the significantly lower percentage of nonunion and recurrence in deformity, which are more difficult to salvage, such as noted within our study.

The techniques described within the present report are additional modifications to the Lapidus procedure and provide a rigid internal fixation construct. In addition, this method has allowed early weightbearing with reproducible and reliable results. The traditional concept of the Lapidus procedure as a technically challenging procedure with high risks, prolonged non-weightbearing, and extensive postoperative recovery can perhaps be mitigated by this rigid construct design.

References

1. Vanore JV, Christensen JC, Kravitz SR, Schuberth JM, Thomas JL, Weil LS, Zlotoff HJ, Mendicino RW, Couture SD. Diagnosis and treatment of first

metatarsophalangeal joint disorders. Section 3: hallux varus. J Foot Ankle Surg 42:137–142, 2003.
2. Sangeorzan BJ, Hansen ST Jr. Modified Lapidus procedure for hallux valgus. Foot Ankle Int 9:262–266, 1989.
3. Kitaoka HB, Alexander IJ, Adelaar RS, Nunley JA, Myerson MS, Sanders M. Clinical rating systems for the ankle-hindfoot, midfoot, hallux, and lesser toes. Foot Ankle Int 15:349–353, 1994.
4. Ibrahim T, Beiri A, Azzabi M, Best AJ, Taylor GJ, Menon DK. Reliability and validity of the subjective component of the American Orthopaedic Foot and Ankle Society clinical rating scales. J Foot Ankle Surg 46:65–74, 2007.
5. Cottom JM. Fixation of the Lapidus arthrodesis with a plantar interfragmentary screw and a medial low profile locking plate. J Foot Ankle Surg 51:517–522, 2012.
6. Klos K, Gudorguiev B, Muckley T, Frober R, Gunther HO, Schwieger K, Windolf M. Stability of medial locking plate and compression screw versus two crossed screws for lapidus arthrodesis. Foot Ankle Int 31:158–163, 2010.
7. Patel S, Ford LA, Etcheverry J, Rush S, Hamilton GA. Modified lapidus arthrodesis: rate of non-union in 227 cases. J Foot Ankle Surg 43:37–42, 2004.
8. Sorensen MD, Hyer CF, Berlet GC. Results of lapidus arthrodesis and locked plating with early weight bearing. Foot Ankle Spec 2:227–233, 2009.
9. Albrecht GH. The pathology and treatment of hallux valgus. Russk Vrach 10:14–19, 1911.
10. Lapidus PW. The operative correction of metatarsus varus primus in hallux valgus. Surg Gynecol Obstet 58:183–191, 1934.
11. Faber FW, Mulder PG, Verhaar JA. Role of first ray hypermobility in the outcome of the Hohmann and the Lapidus procedure: a prospective, randomized trial involving one hundred and one feet. J Bone Joint Surg Am 86:486–495, 2004.
12. Fuhrmann RA. Arthrodesis of the first tarsometatarsal joint for correction of the advanced splayfoot accompanied by hallux valgus. Oper Orthop Traumatol 17:195–210, 2005.
13. Gruber F, Sinkov VS, Su-Young B, Parks BG, Schon LC. Crossed screws versus dorsomedial locking plate with compression screw for first metatarsocuneiform arthrodesis: a cadaver study. Foot Ankle Int 29:927–930, 2008.
14. Klos K, Simons P, Hajduk A, Hoffmeier L, Ing D, Gras F, Frober R, Hofmann G, Muckly T. Plantar versus dorsomedial locked plating for Lapidus arthrodesis: a biomechanical comparison. Foot Ankle Int 32:1081–1085, 2011.
15. Myerson MS, Allon S, McGarvy W. Metatarsocuneiform arthrodesis for management of hallux valgus and metatarsus primus varus. Foot Ankle Int 13:107–115, 1992.
16. Myerson MS, Badekas A. Hypermobility of the first ray. Foot Ankle Clin 5:469–484, 2000.
17. Scranton PE, Coetzee CJ, Carreira D. Athrodesis of the first meatarsocuneiform joint: a comparative study of fixation methods. Foot Ankle Int 30:341–345, 2009.
18. Saxena A, Nguyen A, Nelsen E. Lapidus bunionectomy: early evaluation of crossed lag screws versus locking plate with plantar lag screw. J Foot Ankle Surg 48:170–179, 2009.