This material may be protected by Copyright law (Title 17 U.S. Code)

The Journal of Foot & Ankle Surgery 52 (2013) 348–354

Contents lists available at ScienceDirect

The Journal of Foot & Ankle Surgery

journal homepage: www.jfas.org

Relationship of Frontal Plane Rotation of First Metatarsal to Proximal Articular Set Angle and Hallux Alignment in Patients Undergoing Tarsometatarsal Arthrodesis for Hallux Abducto Valgus: A Case Series and Critical Review of the Literature

Paul Dayton, DPM, MS, FACFAS [1], Mindi Feilmeier, DPM, FACFAS [2], Merrell Kauwe, BS [3], Jordan Hirschi, BS [3]

[1] *Director, Podiatric Medicine and Surgery Residency, Trimark Physicians Group, Trinity Regional Medical Center; and Adjunct Professor, College of Podiatric Medicine and Surgery, Des Moines University, Fort Dodge, IA*
[2] *Assistant Professor, Des Moines University College of Podiatric Medicine and Surgery, Des Moines, IA*
[3] *Podiatric Medical Student, Des Moines University College of Podiatric Medicine and Surgery, Des Moines, IA*

ARTICLE INFO

Level of Clinical Evidence: 4
Keywords:
bunion
CORA
fixation
Lapidus arthrodesis
surgery
toe
triplane deformity

ABSTRACT

Rotation of the first metatarsal, as a component of hallux abducto valgus, is rarely discussed and is not addressed as a component of most hallux valgus corrective procedures. We believe frontal plane rotation of the first metatarsal to be an integral component of hallux abducto valgus deformity (the "third plane of deformity") and believe de-rotation is necessary for complete deformity correction. We observed the change in angular measurements commonly used in the evaluation of hallux valgus deformity in patients who underwent a modified lapidus procedure. We measured the intermetatarsal angle, hallux abductus angle, proximal articular set angle, and tibial sesamoid position on weightbearing radiographs of 25 feet in 24 patients who had undergone tarsal metatarsal corrective arthrodesis and lateral capsular release. Specific attention was given to reduction of the frontal plane rotation of the first metatarsal during correction. Our results showed a change in the angular measurements observed by 4 investigators as follows. The mean change in the intermetatarsal angle was 10.1° ($p < .0001$). The mean change in the hallux abductus angle was 17.8° ($p < .0001$). The mean change in the proximal articular set angle was 18.7° ($p < .0001$). The mean change in the tibial sesamoid position was 3.8 ($p < .0001$). Also, a consistent valgus, or everted position of the first metatarsal, was noted as a component of the hallux abducto valgus deformity in our patient population and was corrected by varus rotation or inversion of the metatarsal. We also reviewed the current literature related to anatomic changes in the first ray in the patient with hallux valgus deformity and reviewed our hypothesis regarding the reduction in the proximal articular set angle, which we believe to be related to frontal plane rotation of the first metatarsal, resulting in a radiographic artifact.

© 2013 by the American College of Foot and Ankle Surgeons. All rights reserved.

Measurement of the 2-dimensional radiographic angular relationships has become an integral part of the evaluation and management of hallux abducto valgus (HAV) deformity. The intermetatarsal angle (IMA), hallux abductus angle (HAA), proximal articular set angle (PASA), and tibial sesamoid position are all commonly measured in an attempt to define the continuum of the HAV deformity. Although these measurements are common in practice, we question whether these 2-dimensional parameters accurately describe the HAV deformity. We know from studying anatomic reports that the first ray deformity associated with HAV is actually a triplane deformity with components of the deformity in the transverse, sagittal, and the third, or frontal, plane (1,2). A review of the published data revealed a question regarding the accuracy and reproducibility of these angular measurements, especially the PASA (3,4). Chi et al (4), in 2002, questioned the accuracy and validity of the PASA. They noted in a series of patients who underwent proximal first ray procedures a consistent reduction in the PASA without distal procedures (4). We have noted in our series that this reduction in PASA was consistent and quite dramatic after tarsal–metatarsal corrective arthrodesis. We hypothesized that this reduction resulted from attention to frontal plane rotational correction in addition to transverse plane and sagittal plane correction. From our observations, we believe the PASA might be a radiographic artifact, rather than a fixed deformity of the first metatarsal head. Using this concept of frontal plane rotational correction, we have been able to obtain excellent correction of the HAA, IM, and PASA with no metatarsal head procedures. Additionally, we have questioned the necessity of the commonly used first metatarsophalangeal joint (MTPJ) release

Financial Disclosure: None reported.
Conflict of Interest: None reported.
Address correspondence to: Paul Dayton, DPM, MS, FACFAS, Director, Podiatric Medicine and Surgery Residency, Trimark Physicians Group, Trinity Regional Medical Center, 804 Kenyon Road, Suite 310, Fort Dodge, IA 50501.
E-mail address: daytonp@me.com (P. Dayton).

1067-2516/$ - see front matter © 2013 by the American College of Foot and Ankle Surgeons. All rights reserved.
http://dx.doi.org/10.1053/j.jfas.2013.01.006

Paragon 28 v. Treace Medical Concepts
PGR2026-00020
Paragon Ex. 1028

and soft tissue balancing. A case series is presented, along with a literature review, to support our hypothesis.

Patients and Methods

The radiographic records of patients who had undergone a tarsal metatarsal corrective arthrodesis procedure for HAV from 2009 to 2011 by 2 of us (P.D., M.F.) were retrospectively reviewed. The Des Moines University institutional review board approved the record review. Only patients who had undergone tarsal metatarsal arthrodesis for HAV with limited soft tissue release and no other osseous procedures in the first ray were included in the present review. Limited soft tissue release was defined as lateral capsular release through a medial intracapsular approach. An additional inclusion criterion was the availability of preoperative and postoperative weightbearing anterior posterior radiographs of sufficient quality to make angular measurements. All 4 of us evaluated the IM, HAA, PASA, and tibial sesamoid position measurements independently. The measurement technique was consistent with the recommendations from Gerbert (5). The measurements were recorded, and the mean change in each measurement from preoperatively to postoperatively was calculated. The statistical analysis included calculation of the mean change in the preoperative and postoperative values after the patients were able to ambulate independently and perform full weightbearing for radiographic examination. We then used a paired *t* test to determine whether the pre- and postoperative measurements differed in each of the 4 characteristics that were measured.

The determination of outcomes such as union rate and patient satisfaction were considered to be outside the scope of the present review. We studied only the radiographic changes in position resulting from the procedure.

Surgical Procedure

All patients were evaluated and determined to be satisfactory candidates for the surgical procedure from a medical and anesthetic standpoint. Conservative care and preoperative consent were in accordance with the accepted standards of the American College of Foot and Ankle Surgeons treatment guidelines (6). The procedures were performed using general anesthesia or local anesthesia with sedation, as determined by medical appropriateness and patient preference. All procedures were performed with the patient in the supine position with standard extremity preparation and a single dose of prophylactic antibiotic given within 30 minutes of the initial incision. In general, tourniquet hemostasis was used. The first step involved a lateral sesamoid ligament release through a medial midline incision without subcutaneous separation. The plantar joint pouch was entered, and the sesamoids were retracted plantarly, allowing access to the lateral capsule. The lateral capsule was incised in the transverse plane only. No additional soft tissue release was performed, including no release or dissection of the dorsal capsule, no tendon releases or transfers, and no capsular plication. In most cases, no medial metatarsal head resection was performed.

The incision for the tarsal–metatarsal fusion was placed dorsally, directly over the joint. Again, dissection was minimal, avoiding plane separation and preserving the perforating blood supply. Most of the tissue separation was subcapsular and subperiosteal. Initially, we simply observed the frontal plane rotation needed to realign the joint. In later cases, before release of the tarsometatarsal joint (TMTJ) and resection of the articular surfaces, 2 smooth, 2-mm, pins were placed directly in the sagittal plane and parallel, 1 in the base of the metatarsal and 1 in the cuneiform. These pins were used as a reference to more easily visualize the rotation of the metatarsal in the frontal plane. The joint surfaces were next resected, including the cartilage and all subchondral bone. The cuts were oriented to correct the transverse and sagittal components, as needed, with the first metatarsal cut perpendicular to the long axis of the metatarsal. The cuneiform cut was made such that the distal medial portion of the cuneiform was left intact. This allowed reduction of the IMA without sacrificing the length of the first ray. Next, the rotation of the metatarsal was addressed by rotating the bone in a varus, or inverted, direction until congruous alignment of the first MTPJ and sesamoids was observed clinically and on the fluoroscopic examination. We found that using the reference pins allowed us to better note the direction of the rotation (Fig. 1).

The segments were next temporarily stabilized with smooth wires. The final fixation in our cases consisted of multiple methods, including 2 small, flexible, locking plates placed dorsally and medially, single- and double-screw fixation, and anatomic locking plate with compression screw. The fusion site was positioned with the dorsal and medial cortices flush in all cases. No sliding offset was performed in any plane. Thus, all correction in the sagittal and transverse planes was angular.

Results

A total of 24 patients with 25 procedures were identified as having met the inclusion criteria for the present study. All patients reviewed had undergone tarsal–metatarsal arthrodesis, with the only other first

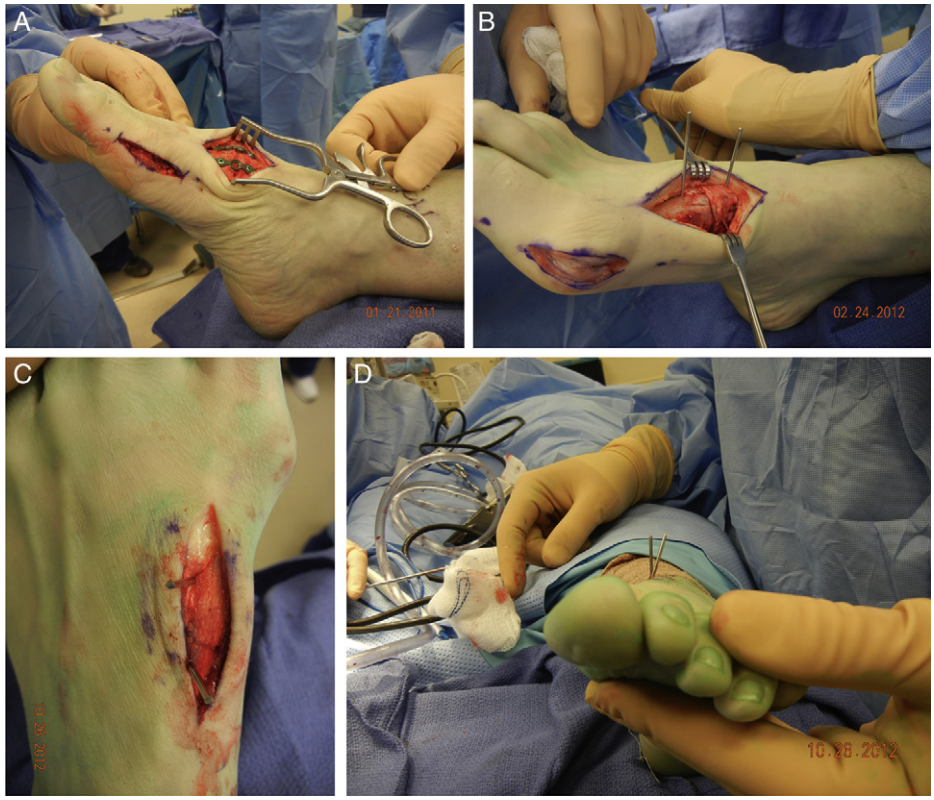

Fig. 1. (*A*) Two-incision approach with medial midline first metatarsal phalangeal incision and 2-plate fixation technique, with (*B*) positioning of reference wires to observe rotation (1 wire in metatarsal base and 1 parallel wire in first cuneiform). (*C*) Varus or inversion rotation of metatarsal indicated by reference wire position after anatomic alignment of first metatarsal and first metatarsal phalangeal joint. (*D*) Second case after correction showing smaller degree but varus or inversion rotation once correction is complete.

ray procedure a limited lateral capsular release through a medial midline incision. Of the 24 patients, 20 were female and 4 were male. The mean age at the procedure was 30.8 (range 14 to 52) years. Four of the patients also underwent lesser metatarsal procedures: 1, an isolated second metatarsal cuneiform arthrodesis; 2, a second and third metatarsal cuneiform arthrodesis; and 1, a fifth metatarsal osteotomy. The preoperative and postoperative IMAs of the 3 patients with the second metatarsal cuneiform arthrodesis procedures were not used in our IMA calculations.

Our first observation was made intraoperatively. In all cases, inversion or varus rotation of the metatarsal was noted when anatomic joint alignment was achieved. Anatomic alignment was determined by congruous reduction of the first MTPJ, anatomic alignment of the HAA, and a normal sesamoid position by both clinical examination and fluoroscopy. Only the direction of the metatarsal or reference pin offset was noted, and no attempt was made to quantify the amount of rotation needed to achieve accurate alignment.

The IMA, HAA, PASA, and tibial sesamoid position were measured on the preoperative and postoperative weightbearing radiographs. The results for each measurement of the 4 investigators were averaged, resulting in a composite mean value. The mean postoperative measurements were significantly lower than the preoperative measurements for each of the 4 traits measured ($p < .0001$, for all tests). The pre- and postoperative measurements for the 4 traits in each patient are shown in Fig. 2.

The mean preoperative IMA was 14.9° (range 10.5° to 23.5°). The mean postoperative IMA was 4.7° (range 1.3° to 7.5°). The mean change in the IMA was 10.1° ($p < .0001$). The mean preoperative HAA was 30.3° (range 18.0° to 48.3°). The mean postoperative HAA was 17.8° (range 4.3° to 21°). The mean change in the HAA was 17.8° ($p < .0001$). The mean preoperative PASA was 25.2° (range 12.8° to 39.3°). The mean postoperative PASA was 6.6° (range 1.3° to 15.0°). The mean change in the PASA was 18.7° ($p < .0001$). The mean preoperative tibial sesamoid position was 5.6 (range 3.3 to 7.0). The mean postoperative tibial sesamoid position was 1.7 (range 1.0 to 4.0). The mean change in the tibial sesamoid position was 3.8 ($p < .0001$).

No complications were noted in the observed postoperative period, including no deep infections, no wound healing issues, and no need for a return to surgery. The healing rates and healing times and postoperative function scoring were not observed and were considered outside the scope of the present review.

Discussion

The surgical approaches for HAV include a myriad of procedures with countless modifications of osteotomies and soft tissue balancing procedures. The procedures are typically classified into metatarsal head, metatarsal shaft, metatarsal base, and distal or proximal arthrodesis. A combination of these procedures is often recommended. The search for consistent and effective procedures has continued for decades, and the attempts to classify the HAV deformity are numerous. Many have attempted to define the HAV by the etiology and progression of the deformity (7–10). Although many descriptions and opinions have been published, disagreement exists regarding the elemental cause and progression of HAV deformity.

According to Kelikian (7), Carl Hueter first introduced the term "hallux valgus" in 1870. Hueter described the great toe moving away from the midline of the body with a first metatarsal that deviates toward the midline of the body (7). This deformity was termed "metatarsus primus varus" by Walter Truslow (8) in 1925. After noting a bone deformity on radiographs at the first metatarsal cuneiform joint and none at the MTPJ, Truslow concluded, "any operative procedure that does not include the correction of the deformity at its proximal focus is unscientific and inadequate." Although this association of hallux and metatarsal deviation has been widely accepted, which is the primary deformity giving rise to the other has not been.

Munuera et al (9) in 2006 studied the relationship of the HVA to the IMA of metatarsals 1 and 2. They found that a mild HVA deformity

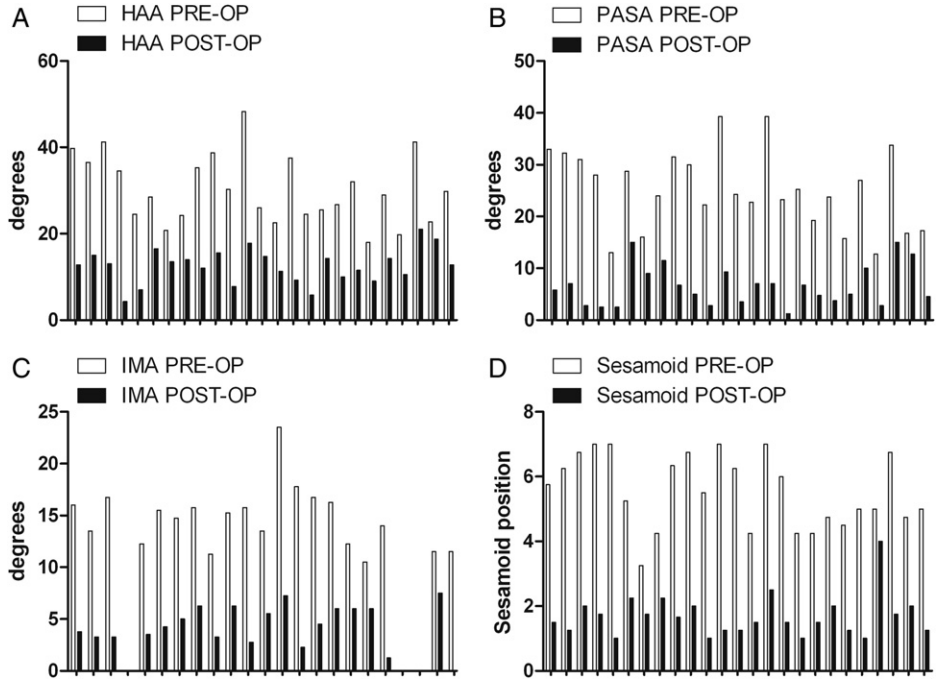

Fig. 2. Results of angular measurements of 25 procedures on preoperative (PRE-OP) and postoperative (POST-OP) weightbearing radiographs, with mean reduction of hallux abductus angle (HAA) of 17.8°, mean reduction of proximal articular set angle (PASA) of 18.7°, mean reduction of intermetatarsal angle (IMA) of 10.1°, and mean reduction of tibial sesamoid position of 3.8.

preceded a clinically meaningful increase in the IMA, leading them to conclude that hallux valgus leads to metatarsus primus varus (9).

Snjeiders et al (10) used a biomechanical study in which they used force vectors to show that walking produced force about a moment arm that deviated the hallux laterally, thereby causing the "spread foot" or medial deviation of the first metatarsal, and recommended that a first MTPJ arthrodesis should be the procedure of choice in addressing HVA deformities (10). Studies have shown that first MTPJ fusions can improve the metatarsus primus varus or IMA without any proximal procedures, possibly because of relief of retrograde buckling of the hallux on the metatarsal (11–13).

Even before Truslow, others had identified the first TMTJ as the apex of the deformity (14,15). Subsequently, other investigators, including Lapidus (16), also suggested that the tarsal metatarsal articulation is the apex and primary deformity in a bunion (17–19).

Although clear etiology and an agreed on progression of HAV deformity eludes us, we must still attempt to define the deformity clinically. Currently, it is taught that the radiographic parameters such as PASA, IMA between the first and second metatarsal, and the HAA must be used to define the deformity and to choose a specific procedure or combination of procedures to correct the HAV deformity. Using these severity-based algorithms, HAV is treated as a continuum of deformities rather than a single deformity. We consider HAV to be a singular deformity, with a consistent level of deformity or center of rotation angulation (CORA), as described by Paley (20). Additionally, we have identified the importance of 3 planar components of the CORA, with the frontal plane rotation ("third plane") playing a central role in the deformity.

Although it might not be intuitive because of generations of teaching and the use of algorithms, the level of the deformity and, therefore, the CORA, as it relates to the evaluation of the HAV deformity, must be considered. All deformities have a position or level at which the deformity originates. As taught by Paley (20), failure to respect this level of deformity prevents accurate alignment of the anatomic and mechanical axes and creates new deformities. Identification of the CORA is vital if we are to correct a deformity without introducing secondary deformities (Fig. 3). If our angulation correction axis, which dictates the level of the osteotomy we make, is located at our CORA, the deformity can be corrected without creating additional or secondary deformities. If we do not address the deformity at the CORA, we will inevitably create secondary deformities in the bone (20). We believe that because most common procedures focus osteotomy or correction at a point in the metatarsal rather than at the metatarsal cuneiform joint, which we believe is the CORA, these procedures will not completely correct the deformity. Many osteotomies create a second deformity while allowing the initial deformity to persist (Fig. 3).

Despite the universality of radiographic analysis of the HAV deformity, disagreement exists regarding the significance and reliability of even our most common measurements. Vanore et al (6), in their clinical guide, defined the PASA as the lateral adaptation of the distal first metatarsal articular surface that occurs with long-standing HAV. PASA is typically assessed on the radiograph but can also be observed qualitatively by direct intraoperative inspection. This angle has also been described as the distal metatarsal articular angle (DMAA). The normal values are 0° to 8°; however, interobserver variability exists, and the value might not correlate with the intraoperative observations (3,4,21–23).

Piggott (24) in 1960 conducted a radiographic study of adolescents and proposed that 4 types of changes occurred at the head of the metatarsal and that those changes determine the severity of the HAV deformity. He determined that these changes at the DMAA were the pre-existing condition that caused the deviation of the metatarsal and the bony prominence of the medial aspect of the foot (24). He also stated that when the DMAA is shifted laterally, it decreases the amount of correction that can be achieved (24). Piggott (24) believed the deformity would be likely to revert back to its preoperative state unless correction has been made at the DMAA.

Coughlin (25), in 1997, took the information that Piggott (24) presented in 1960 and applied it to surgical correction. Coughlin (25) agreed with Piggott (24) and concluded that the reason behind undercorrection of hallux valgus deformities, or the high rate of recurrence seen, resulted from the lack of correction of the DMAA. McInnes and Bouché (26) in 2001 agreed with that tenent and stated that the PASA is responsible for undercorrection of the hallux valgus angle, even if the IMA was completely reduced. They also advised that when performing a modified Lapidus procedure, we should consider a head procedure to correct for the PASA (26).

In 2001, Coughlin and Freund (3) concluded, "The interobserver reliability in the assessment of the DMAA is questioned." Physicians participating in the study did not consistently measure the DMAA with the precision with which they measured the IMA and HAA. Coughlin and Freund (3) further stated that the decreased reliability of this measurement between the different observers resulted from the "difficulty in consistently determining the medial and lateral

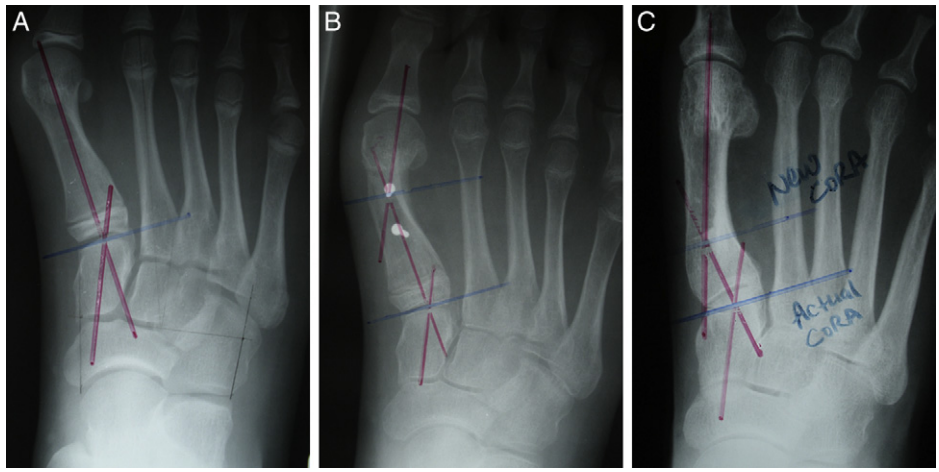

Fig. 3. Evaluation of hallux abducto valgus (HAV) using center of rotation angulation (CORA) principle. Deformity level was at metatarsal cuneiform joint, with no deformity noted in the metatarsal. (*A*) Alignment after midshaft sliding osteotomy showing persistence of original intermetatarsal angle (IMA), nonanatomic alignment of first metatarsophalangeal joint (MTPJ) and sesamoids and new deformity CORA in the metatarsal. (*B*) Alignment after basilar osteotomy using the CORA principle and showing residual CORA at original deformity, a new deformity in the metatarsal, and nonanatomic alignment of the first MTPJ.

extent of the distal metatarsal articular surface." Vittetoe et al (21) and Robinson et al (22) also confirmed that the PASA measurement was unreliable between observers. In both studies, they radiographically measured a cadaveric first metatarsal and found that with frontal plane rotation of the metatarsal, the PASA measurements changed.

Martin (23), in 1993, presented a different perspective on the changes at the head of the metatarsal in his critical analysis of the PASA. Martin (23) found that the preoperative PASA is rarely visualized intraoperatively and was often decreased postoperatively without any procedure to address the PASA or the head of the metatarsal. The study by Chi et al (4) in 2002 also showed a decreased PASA with proximal bunion repair procedures using pre- and postoperative radiographic measurements.

The results from our series agree with the observations of first metatarsal phalangeal realignment and a decreased PASA (18.7° in our series) after tarsal metatarsal corrective arthrodesis. We believe that it is the frontal plane rotation of the metatarsal ("third plane of deformity") that changes the appearance of the articular surface of the metatarsal head on radiographs. Furthermore, we have noted that rotation also allows accurate realignment of the joint and a substantial decrease in the HAA (17.8° in our series). Because the metatarsal head is an imperfect sphere, any change in rotation will have a corresponding change in the direction and profile of the articular surface, both clinically and radiographically. This could be the basis for the changes seen on the pre- and postoperative radiographs (Fig. 4).

We recognize that in some instances the distal metatarsal articular surface might appear deviated on direct inspection. Thordarson and Krewer (27) discussed the idea that the medial cartilage loss resulting from abnormal forces of the deviated hallux might be responsible for the apparent enlargement of the medial eminence. They noted that although the head was more exposed medially, it was not necessarily enlarged (27). Perera et al (28), in 2011, discussed the PASA and noted changes in the angle over time, indicating it might be a developmental, not a fixed or intrinsic, deformity. We believe that this loss of medial cartilage could also change the intraoperative appearance of the articular surface enough to give the appearance of a deviated PASA. This, however, does not, in reality, change the alignment and congruency of the first MTPJ, which is determined by the intrinsic bone shape and position of the first metatarsal in the transverse, sagittal, and frontal planes.

Because of these same observations, we question whether routine resection of the so-called medial eminence is necessary or prudent. We believe the often-described medial eminence enlargement might be accentuated on anteroposterior radiographic examination owing to the abnormal profile caused by eversion, or valgus positioning, of the metatarsal. We rarely find it necessary to resect any significant portion of the metatarsal head once the frontal plane rotation has been corrected. We believe it is prudent to wait until the abnormal frontal plane position is addressed before excising any metatarsal head. We have noted a persistent medial bump in some cases and have found this to be largely due to thickening of the medial capsule. We have found it necessary to thin the capsule to decrease the clinical appearance of medial prominence if noted on clinical inspection after deformity correction.

Reviewing again the common radiographic relationships used to assess the HAV deformity, the measurements are taken in 2 dimensions, with an emphasis on the transverse plane components of the deformity. A lower priority is typically placed on the sagittal plane component of the deformity. The least consideration is given to the frontal plane rotation in both the radiographic evaluation and the procedure choice. Although rotation of the first metatarsal as a component of the HAV deformity has been described, the definitions have been inconsistent. Some investigators have been in favor of inversion of the first ray on dorsiflexion. Hicks (29), in 1953, used 5 normal amputated feet and, after attaching pulleys and springs, isolated the motion of extension and supination in the first ray (i.e., dorsiflexion and inversion). Ebisui (30), in 1968, found that as he applied internal and external rotary forces to 15 freshly amputated legs, dorsiflexion of the first ray occurred with internal rotation of the leg. This happened about the axis Hicks had determined and carried with it concomitant inversion of the first ray. In 1982, Kelso et al (31) manually moved the first ray on an immobile hindfoot into

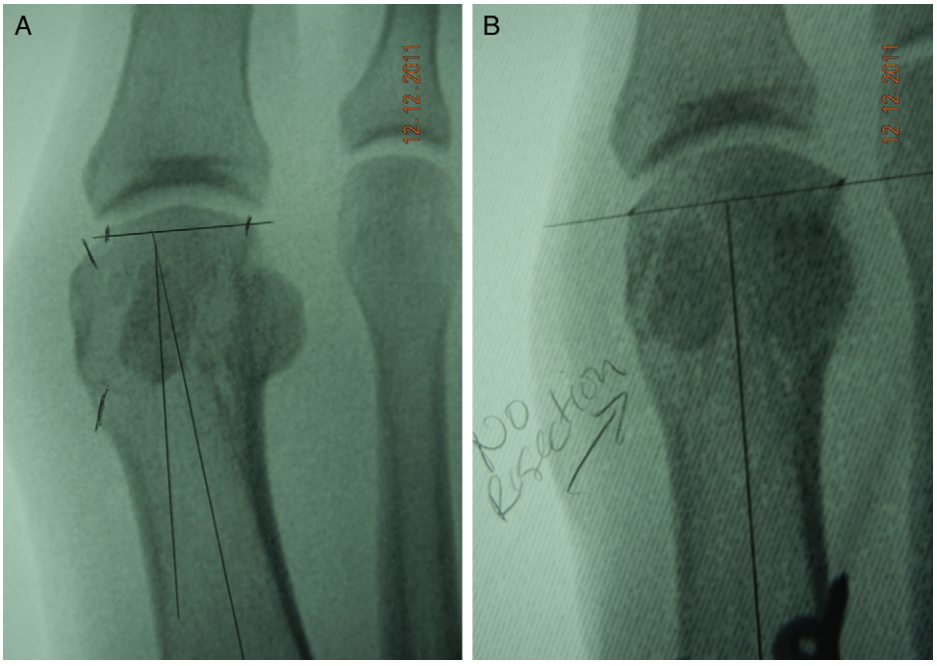

Fig. 4. (*A*) Preoperative first metatarsophalangeal joint alignment and apparent prominence of medial eminence. (*B*) Postoperative first metatarsophalangeal joint alignment showing reduction in proximal articular set angle after rotation and reduction in apparent prominence of medial eminence without bone resection.

dorsiflexion and plantarflexion. Using pins as reference points, they found that inversion occurred as the first ray was dorsiflexed (31).

These findings of dorsiflexion and inversion have been opposed in a number of studies starting in 1974 with Inman (32). Inman (32) used a pin in the hallux to show that as the leg was internally rotated, the foot pronated and the hallux everted into a valgus rotated position. He interpreted this to mean that the entire first ray everted as it dorsiflexed (32). In 1979, D'Amico and Schuster (33) used pins to visually show that as they manually moved 5 cadaver feet from a neutral to a pronated position the dorsal surface of the first metatarsal moved medially and inferiorly. Therefore, it everted as it was dorsiflexed (33). Also, in 1979, Oldenbrook and Smith (34) used accelerometers to measure first ray motion in 5 cadaveric feet. All the specimens showed dorsiflexion and eversion occurring in tandem as they internally rotated the leg (34).

Other interesting studies by Scranton and Rutkowski (1) and by Grode and McCarthy (2) investigated feet with bunion deformities. Scranton and Rutkowski (1) used 35 cadaveric and fresh feet. On anatomic inspection, they found that the hallux was in a valgus position and that pronation of the metatarsal head had occurred (1). They hypothesized that this pronation of the metatarsal was the cause of the plantar migration of the abductor hallucis muscle. Grode and McCarthy (2) took 3 cadaveric specimens and subjected them to a cryomicrotomic study. They found that the crista and orientation of the head of the metatarsal in feet with bunion deformities showed clear eversion.

Thus, it is clear that there is no final recommendation on the topic of first ray motion. In our recent experience, we have found consistent valgus rotation, or eversion, of the first metatarsal in association with HAV deformity. In our series, we directly observed varus rotation, or inversion, of the metatarsal to have occurred when the joint was corrected into congruous alignment using TMTJ corrective arthrodesis (Fig. 1). We believe this supports the hypothesis of valgus rotation or eversion of the metatarsal associated with the metatarsus primus adductus seen in hallux valgus. This has led us to our recommendation that rotational correction be considered when correcting the HAV deformity. Unlike most head, shaft, and base osteotomy procedures, TMTJ arthrodesis allows triplane correction at the deformity's CORA. Although measurement and calculation of the absolute amount of rotation were outside the scope of the present review, the direction of rotation we observed was consistent in all patients. Additional prospective studies could be designed to measure the mean amount of rotation and would help to clarify the rotational component of the deformity.

If we can accept that HAV deformity is triplane, it follows that each of these planes should be addressed in the corrective operation. Nearly all head, shaft, and basilar procedures provide measurable correction only in the transverse plane. Many others have attempted correction in the sagittal plane; however, when simple geometry is used, very little sagittal plane correction can be obtained with most angular and sliding metatarsal osteotomies. Also, the location of popular osteotomies is placed within the metatarsal. When considering the deformity correction rules, we question whether sound osteocorrective principles are being used with these procedures if the correction is attempted at a point other than at the CORA. In addition, the fact is evident from intrinsic geometry that most procedures, especially sliding procedures, cannot address frontal plane rotation.

However, tarsal metatarsal corrective arthrodesis can address all 3 planes of the HAV deformity. In our series, joint alignment, including a decrease in the PASA and HAA, was seen concurrently with minimal or no soft tissue balancing and no distal osteotomy. Our preferred lateral capsule/sesamoid ligament release was done from a medial midline incision through the plantar joint pouch. The entire dorsal joint pouch was maintained, and no additional tendon release, tendon balancing, capsulorrhaphy, or other soft tissue procedure was performed to attempt additional correction at the first MTPJ. We believe this further supports the idea of the HAV deformity as a triplane

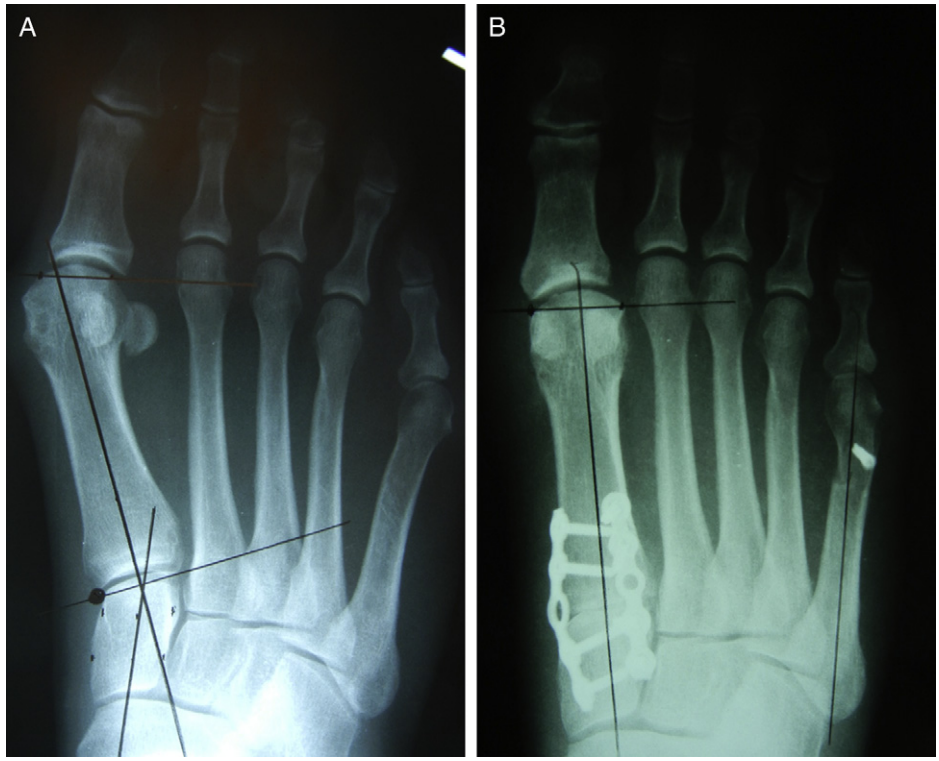

Fig. 5. Alignment of first ray and first metatarsophalangeal joint before (*A*) and after (*B*) tarsal metatarsal corrective arthrodesis. Triplane correction resulted in anatomic alignment of first metatarsophalangeal joint without distal procedures or medial eminence resection.

deformity and indicates that "third plane" or rotational correction is necessary to obtain anatomic alignment at the first metatarsal phalangeal joint and of the sesamoids (Fig. 5). We hypothesized that some de-rotation of the first ray might occur with other procedures and could be based on relieving the retrograde buckling forces that the deformed hallux and first metatarsal phalangeal joint have on the proximal first ray. This example is clear in the case of reduction of the IMA, which is seen after first MTPJ fusion.

Our series has shown a dramatic and consistent reduction in the PASA by simply inverting, or rotating, the metatarsal in a varus direction, with transverse plane and sagittal plane correction during tarsal metatarsal corrective arthrodesis. We consider this the "third" plane of deformity in HAV. As we have noted, most procedures have focused primary attention on the transverse plane of the deformity and have attempted to correct a metatarsal deformity that does not exist. We believe that 2-dimensional radiographic analysis does not accurately define the HAV deformity, because it does not address the third plane. We believe that the frontal plane component is a key component of first MTPJ misalignment in HAV deformity and must be addressed during correction to provide anatomic alignment of the first MTPJ.

Acknowledgment

The authors wish to thank John "Keoni" Kauwe, PhD, Assistant Professor, Department of Biology, Brigham Young University, for technical assistance and statistical analysis of our data.

References

1. Scranton PE, Rutkowski R. Anatomic variations in the first ray—part 1: anatomic aspects related to bunion surgery. Clin Orthop Rel Res 151:244–255, 1980.
2. Grode SE, McCarthy DJ. The anatomical implications of hallux abducto valgus: a cryomicrotomic study. J Am Podiatr Med Assoc 70:539–551, 1980.
3. Coughlin MJ, Freund E, Roger A. Mann award: the reliability of angular measurements in hallux valgus deformities. Foot Ankle Int 22:369–379, 2001.
4. Chi TD, Davitt J, Younger A, Holt S, Sangeorzan BJ. Intra- and inter-observer reliability of the distal metatarsal articular angle in adult hallux valgus. Foot Ankle Int 23:722–726, 2002.
5. Gerbert J, editor. *Textbook of Bunion Surgery*, WB Saunders, New York, 2001.
6. Vanore JV, Christensen JC, Kravitz SR, Schuberth JM, Thomas JL, Weil LS, Zlotoff HJ, Mendicino RW, Couture SD. Clinical Practice Guideline First Metatarsophalangeal Joint Disorders Panel of the American College of Foot and Ankle Surgeons. Diagnosis and treatment of first metatarsophalangeal joint disorders. Section 1: hallux valgus. J Foot Ankle Surg 42:112–123, 2003.
7. Kelikian H. *Hallux Valgus, Allied Deformities of the Forefoot and Metatarsalgia*, WB Saunders, Philadelphia, 1965.
8. Truslow W. Metatarsus primus varus or hallux valgus. J Bone Joint Surg Am 7:98–108, 1925.
9. Munuera PV, Dominquez G, Polo J, Rebollo J. Medial deviation of the first metatarsal in incipient hallux valgus deformity. Foot Ankle Int 27:1030–1035, 2006.
10. Snjeiders CJ, Snijder JG, Philippens MM. Biomechanics of hallux valgus and spread foot. Foot Ankle Int 7:26–39, 1986.
11. Cronin JJ, Limbers JP, Kutty S, Stephens MM. Intermetatarsal angle after first metatarsophalangeal joint arthrodesis for hallux valgus. Foot Ankle Int 27:104–109, 2006.
12. Mann RA, Katcherian DA. Relationship of metatarsophalangeal joint fusion on the intermetatarsal angle. Foot Ankle Int 10:8–11, 1989.
13. Dayton P, LoPiccolo J, Kiley J. Reduction of the intermetatarsal angle after first metatarsophalangeal joint arthrodesis in patients with moderate and severe metatarsus primus adductus. J Foot Ankle Surg 41:316–319, 2002.
14. LeBoucq H. Le développement du premier merararsien et de son articulation arsienne chez l'homme. Arch Biol 3:335, 1882.
15. Picque L. Note sur une cas d'hallux valgus. Bull Mem Soc Chir 28:518–525, 1902.
16. Lapidus P. A quarter century experience with the operation. Bull Hosp Joint Dis 17:404–421, 1956.
17. Tanaka Y, Takakura Y, Kumai T, Samoto N, Tamai S. Radiographic analysis of hallux valgus: a two dimensional coordinate system. J Bone Joint Surg Am 77:205–213, 1995.
18. Morton DJ. Metatarsus atavicus: the identification of a distinctive type of foot disorder. J Bone Joint Surg 9:531–544, 1927.
19. Mashima N, Yamamoto H, Tsuboi I, Tsuchiya H, Tanaka Y, Watanabe S. Correction of hallux valgus deformity using the center of rotation of angulation method. J Orth Sci 14:377–384, 2009.
20. Paley D, Herzenber JE, editors. *Principles of Deformity Correction*, Springer-Velag, Berlin, 2005.
21. Vittetoe DA, Saltzman CL, Krieg JC, Brown TD. Validity and reliability of the first distal metatarsal articular angle. Foot Ankle Int 15:541–547, 1994.
22. Robinson AH, Cullen NP, Chhaya NC, Sri-Ram K, Lynch A. Variation of the distal metatarsal articular angle with axial rotation and inclination of the first metatarsal. Foot Ankle Int Am 27:1036–1040, 2006.
23. Martin DE. Preoperative radiographic evaluation in HAV surgery: a critical analysis of PASA and other soft tissue adaptation. In: *Reconstructive Surgery of the Foot and Leg*, edited by CA Camasta, NS Vickers, JA Ruch, Podiatry Institute, Tucker, GA, 1993.
24. Piggott H. The natural history of hallux valgus in adolescence and early adult life. J Bone Joint Surg Br 42:749–760, 1960.
25. Coughlin MJ. Hallux valgus in men: effect of the distal metatarsal articular angle on hallux valgus correction. Foot Ankle Int 18:463–470, 1997.
26. McInnes BD, Bouché RT. Critical evaluation of the modified Lapidus procedure. J Foot Ankle Surg 40:71–90, 2001.
27. Thordarson DB, Krewer P. Medial eminence thickness with and without hallux valgus. Foot Ankle Int 23:48–50, 2002.
28. Perera AM, Mason L, Stephens MM. Current concepts review: the pathogenesis of hallux valgus. J Bone Joint Surg 93:1650–1661, 2011.
29. Hicks JH. The mechanics of the foot. Part I: the joints. J Anat 87:345–357, 1953.
30. Ebisui JM. The first ray axis and the first metatarsal phalangeal joint: an anatomical and pathomechanical study. J Am Podiatr Med Assoc 58:160–168, 1968.
31. Kelso SF, Richie DH Jr, Cohen IR, Weed JH, Root ML. Direction and range of motion of the first ray. J Am Podiatr Med Assoc 72:600–605, 1982.
32. Inman VT. Hallux valgus: a review of etiologic factors. Orthop Clin North Am 5:59–66, 1974.
33. D'Amico JC, Schuster RO. Motion of the first ray: clarification through investigation. J Am Podiatr Med Assoc 69:17–23, 1979.
34. Oldenbrook LL, Smith CE. Metatarsal head motion secondary to rearfoot pronation and supination: an anatomical investigation. J Am Podiatr Med Assoc 69:24–28, 1979.