Surgery, Gynecology and Obstetrics

An International Magazine
Published Monthly

EDITORIAL STAFF

FOR AMERICAN COLLEGE OF SURGEONS

WILLIAM J. MAYO, M.D.

GEORGE W. CRILE, M.D. JOHN M. T. FINNEY, M.D.

WALTER W. CHIPMAN, M.D. HARVEY CUSHING, M.D. J. BENTLEY SQUIER, M.D.

WALLACE I. TERRY, M.D. PHILIP H. KREUSCHER, M.D. WILLIAM H. WILMER, M.D.

CHARLES H. FRAZIER, M.D. FREDERIC A. BESLEY, M.D. WILLIAM R. CUBBINS, M.D.

DONALD C. BALFOUR, M.D. ROBERT B. GREENOUGH, M.D. ALTON OCSHNER, M.D.

FOR THE BRITISH EMPIRE

LORD MOYNIHAN, K.C.M.G., C.B., M.S., F.R.C.S.

A. JAMES WALTON, M.S., F.R.C.S. THOMAS W. EDEN, M.D., F.R.C.S.

GEORGE GREY TURNER, M.S., F.R.C.S. DAVID P. D. WILKIE, M.D., F.R.C.S.E.

SIR WILLIAM I. DEC. WHEELER, M.D., F.R.C.S.I.

FRANKLIN H. MARTIN, M.D., Managing Editor

ALLEN B. KANAVEL, M.D., Associate Editor

LOYAL DAVIS, M.D., Associate Editor

VOLUME LVIII

JANUARY TO JUNE, 1934

PUBLISHED BY

THE SURGICAL PUBLISHING COMPANY OF CHICAGO

54 EAST ERIE STREET, CHICAGO

1934

Paragon 28 v. Treace Medical Concepts
PGR2026-00022
Paragon Ex. 1010

Copyright by
THE SURGICAL PUBLISHING COMPANY
OF CHICAGO
1934

OPERATIVE CORRECTION OF THE METATARSUS VARUS PRIMUS IN HALLUX VALGUS

PAUL W. LAPIDUS, M.D., F.A.C.S., NEW YORK

Assistant Adjunct Orthopedic Surgeon, Hospital for Joint Diseases.[1] Assistant Orthopedic Surgeon, Hospital for Ruptured and Crippled[2]

THE enormous wealth and great diversity of the operative procedures devised for the correction of hallux valgus deformity is eloquent proof that this problem is far from being adequately solved. However, it is not within the scope of this preliminary communication to go into any review of the very abundant literature on this subject.

The operation for correction of hallux valgus, as given below, is the result of the writer's personal study of this condition. There is no priority or originality claimed by the writer, except for the details of the operation, as he is fully aware, after a review of the literature, that there were a few surgeons in this country, as well as abroad, who had approached this problem in more or less a similar way to the one here presented.

The purpose of this paper is to stress the mechanical importance of the metatarsus varus primus, as one of the most frequent and most prominent factors of the hallux valgus deformity.

The cases of hallux valgus may be classified under three groups.

1. Cases with congenital predisposition toward hallux valgus formation, due to metatarsus varus primus. (The deformity may appear in early youth (Fig. 1) and is often hereditary.)
2. Arthritic hallux valgus, due to inflammatory periarticular contractures.
3. Paralytic hallux valgus, caused by loss of muscular balance.

It is unnecessary to say that this classification is more or less artificial, and there are possibilities of combinations of any of the features of these three classes in the same case.

The first group is the largest one, and the one mainly considered in the presentation.

It is admitted that in the process of phylogenetic development, the *homo sapiens* went through an arboreal stage of life. During this period, the foot had to adapt itself to a grasping motion when climbing trees, and therefore resembled the hand—because of greater mobility of the joints, and the presence of opposition of the big toe, similar to that of the thumb.

Sameness between the hand and the foot is also observed in primates, who use their feet for grasping. In man, the foot serves mainly as a supporting limb, and therefore the human foot had to lose its mobility—the hallux becoming strengthened, and the other toes diminishing. The hallux of primates resembles more the thumb, because of its freer range of motion, and the large angle formed by the first and second metatarsals (Fig. 2). To a lesser degree, it may be noted in the human embryo, and infants.

Among many changes that took place in the plantigrade human foot, due to special demands made upon it, in the course of human evolution, there is a marked differentiation between the hallux and the thumb. The first metatarsal in the well developed human foot is nearly parallel to the second (Figs. 3, A and B). Classical paintings and sculpture depict the long and rather narrow foot as an example of beauty and perfection, long before orthopedic surgeons thought of it. Thus it may be assumed that the adult foot, presenting marked fan-shaped spreading of the metatarsals (*spreiz-fuss* of German authors), with a large angle between the first and second metatarsals (metatarsus varus primus), and therefore with a large space between the first and second metatarsal heads, must be considered as an atavistic foot, which never became fully developed. This is a type of foot which most commonly forms a hallux valgus (Fig. 1) and thus the often observed hereditary predisposition toward this deformity can be readily understood.

An excellent illustration of this atavistic type of foot, with metatarsus varus primus, presenting congenital potential predisposition toward hallux valgus formation was observed by the author in a case of middle aged brother and sister. The sister developed "bunions" in young age, as a result of wearing the usual distorting ladies' shoes, while her brother's feet remained normal, because of wide, straightlast shoes, which checked this potential tendency (Fig. 4, A and B).

The first precursors of incipient "bunion" as a rule are observed in girls with atavistic foot at the age of about thirteen and fourteen when they first start to wear a narrow pointed shoe with a high heel. The weight bearing is thrown more on the forefoot, and the force of gravity itself tends to produce further spreading of metatarsals and to increase the metatarsus varus primus.

The thumb-like hallux has no room in the narrow, and often short, shoe. It is gradually de-

[1]From the service of Dr. Leo Mayer. [2]From the service of Dr. Percy Willard Roberts.

This material may be protected by Copyright law (Title 17 U.S. Code)

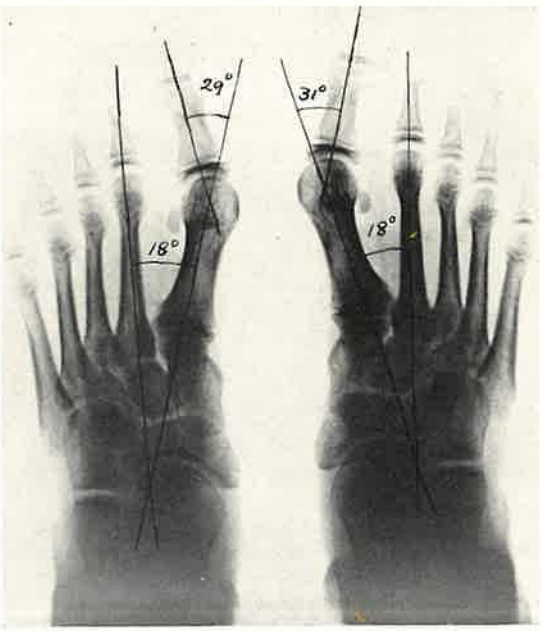

Fig. 1. Roentgenogram of feet of a girl 9 years old. Typical atavistic foot with metatarsus varus primus and hallux valgus deformity in spite of the fact that the child had never worn narrow shoes.

viated toward the second toe and adopts a valgus position, which consequently becomes fixed. The base of the proximal phalanx subluxates laterally upon the first metatarsal head and pushes the latter medially. The already congenitally relaxed transverse ligament between the first and second metatarsal heads becomes even more stretched, thus contributing to the increase of the original metatarsus varus primus.

The first metatarsal head protrudes medially and sometimes a bony proliferation forms over its medial part as a result of chronic trauma against the shoe. As pointed out by Hiss, the abductor hallucis is the only muscle preventing hallux valgus formation. This muscle is much weaker than the adductor hallucis, the latter's action favoring the valgus position of the big toe. Besides that the short and long flexors and extensors of the big toe also contribute to the hallux valgus deformity as they become displaced laterally to the first metatarsophalangeal joint and their pull increases the angulation between the first metatarsal and the basal phalanx. The lateral displacement of the sesamoids over which run the tendons of the two heads of the flexor hallucis brevis is a commonly observed condition (Fig. 5, A and others).

In cases of considerable varus position of the first metatarsal, there is a large space between the first and second toes. This space may accommodate the big toe in hallux valgus position (sometimes over 45 degrees) without the big toe overlapping the second or being overlapped by the latter. On the other hand, this overlapping of the big toe by the second, or the reverse, must necessarily take place, even in mild cases of hallux valgus deformity, without presence of the metatarsus varus primus, because the first and second toes lie very close to each other.

I believe that the congenital metatarsus varus primus in the majority of cases is the primary deformity leading to secondary formation of the hallux valgus. In other words, the medially opened angulation between the first cuneiform and the first metatarsal, causes the compensatory angulation open laterally between the big toe and the first metatarsal. This occurs in somewhat similar manner as the dorsal kyphosis of the spine is compensated by an increased lumbar lordosis. It can readily be seen that any attempt at correction of hallux valgus by only adducting medially the big toe and bringing it in alinement with the first metatarsal, will be futile, in a foot presenting metatarsus varus primus. In this case, after successful correction, the big toe will be widely separated from the second toe, and will protrude medially. This kind of foot with a *thumb-like hallux* would fit more easily into a glove than a shoe, unless the big toe were again brought back to hallux valgus position (Fig. 6).

Consequently any operative procedure designed only to straighten the secondary angulation between the first metatarsal and the big toe, or only correcting the hallux valgus itself, is prone to have a recurrence of the deformity, unless the varus position of the first metatarsal will also be corrected, as the latter is the primary underlying cause in the majority of cases of hallux valgus. A few operative procedures in the past aimed to correct the medial deviation of the first metatarsal, by means of varied osteotomies at different parts of this bone, or through the first cuneiform.

The only way to make a straight line of two lines forming an angle less than 180 degrees, is by moving the free end of one of the lines around the point of their cross section as a center, until the two lines will form an angle of 180 degrees. In order to correct any bony angulation, the osteotomy should be made at the apex of the angulation. The knock knee deformity is treated by an osteotomy as near the knee joint as possible, as the apex of the angulation between the tibia and the femur is usually located near this

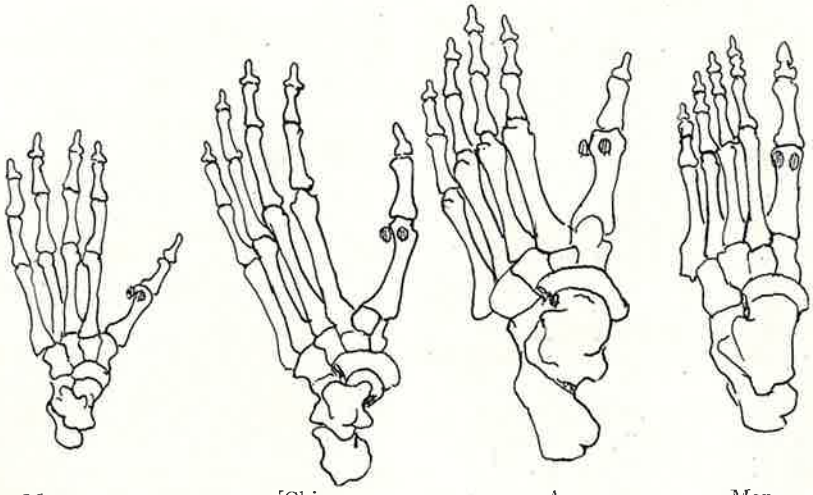

Fig. 2. Note the thumb-like big toe of primates with marked varus position of the first metatarsal. (Adapted with modification from Hiss, J. M. Am. J. Surg., 1931, xi, 53).

joint. No one would try to correct a knock knee by osteotomizing at the middle of the tibia, or of the femur, for example. Therefore, the only mechanically sound osteotomy for correction of metatarsus varus primus should be located at the first cuneiformometatarsal joint, which is the apex of the angulation between the first metatarsal and the first cuneiform.

Without going into detailed description of the anatomy of the region of the first cuneiformometatarsal joint, a few important points should be mentioned. The articulating facets of the first metatarsal and the first cuneiform resemble a lima bean, the long axis of which lies in a dorsiplantar direction. The concavity of the bean is toward the second cuneiform—the convexity toward the medial border of the foot. The plane of this joint extends from dorsal, anterior, and lateral to plantar, posterior, and medial directions; in other words, the articular facet of the first cuneiform, after removal of the first metatarsal, will face medially and slightly plantarward. The more medial slanting of the facet of the first cuneiform, the more pronounced is the varus position of the first metatarsal.

The occasionally present intermetatarsal articular facet and the lateral dorsal part of the first metatarsal base impinge against the adjacent medial aspect of the base of the second metatarsal, and prevents lateral abduction of the first metatarsal, toward the second metatarsal. That is why this part of first metatarsal base should be chiseled off in correcting metatarsus varus primus.

The second cuneiform is shorter than the first. Therefore the line of the second cuneiformometatarsal joint on the dorsum of the foot lies about 1 centimeter proximally from the line of the first cuneiformometatarsal joint. The dorsalis pedis artery with its plantar branch passes closely between the bases of the first and second metatarsal bones and should be spared during the operation.

DESCRIPTION OF THE OPERATION

The operation is better performed without the use of a tourniquet, as the bleeding is negligible, and it is preferable to control it during the operation.

A longitudinal incision, about 5 centimeters long, is made on the dorsimedial aspect of the foot. The incision should correspond to the line of the joint between the first and second cuneiforms. The line of the first cuneiformometatarsal joint should cross the middle of the incision. The tendon of the extensor hallucis longus is retracted medially without opening its synovial sheet. Occasionally it is necessary to lengthen this tendon. The first cuneiformometatarsal joint and the adjacent parts of the bases of the first and second metatarsals are exposed subperiosteally, care being taken not to cut the dorsalis pedis artery and its branches.

The tuberosity of the first metatarsal, impinging against the second metatarsal base, is chiseled off, the plane of the chisel being held parallel with the long axis of the first metatarsal, and strictly in dorsiplantar direction (Fig. 7, A). The adja-

A.

B.

Fig. 3. A, Long narrow feet. The big and second toes lie close together. B, Roentgenogram of the same feet showing first and second metatarsals almost parallel to each other. This type of foot had no potential tendency to hallux valgus formation. Note that even in this type of foot there is a slight "physiological hallux valgus." Two sisters and father of this patient had also similar type of feet.

cent part of the second metatarsal base is also roughened with a curette.

After that, a small wedge with the base laterally, is removed from the articular surfaces of the first metatarsal and the first cuneiform, only over their lateral aspect (Fig. 7, B and C). The medial part of the first cuneiformometatarsal joint should be left intact except being denuded from its cartilaginous covering. The base of either wedge removed from the first metatarsal and the first cuneiform should not be wider than about 3 or 4 millimeters each (somewhat more bone should be removed from the cuneiform). The last two points—(1) not to osteotomize the medial part of the adjacent articular surfaces of the first metatarsal and the first cuneiform; and (2) not to remove too wide a wedge—are of extreme importance, especially the first one. The aim of the operation is to produce a bony fusion of the first metatarsocuneiform joint and adjacent bases of the first and second metatarsals in corrected position. Too large a resection of bone, creating a large gap, may be not favorable for bony fusion.

Transverse resection of the whole first cuneiformometatarsal joint (also over its medial part) as advocated by a few surgeons, will produce a shortening of the first metatarsal, causing considerable disturbance of the statics and dynamics of the foot. The first metatarsal bone serves as a medial buttress of the foot, preventing its pronation. The head of the first metatarsal with the underlying two sesamoid bones, is the medial anterior weight-bearing point of the foot. Any shortening of the first metatarsal, will, therefore, result in an increase of pronation of the foot. Beside that, the second metatarsal head will be much longer, compared with the first, and will become the weight-bearing point, instead of the first metatarsal head, resulting in pain and formation of tender callosity, beneath the anterior arch.

The big toe plays an important part in the process of locomotion. There is a phase in walking, and especially in running, when the whole weight of the body is borne by the first metatarsal head, with the big toe in extreme dorsiflexion (Fig. 4, A, left foot). Shortening of the first metatarsal will weaken the action of the plantar and dorsal flexors of the big toe, because the distance between the origin and insertion of these muscles will become diminished. This will create some disturbance of gait.

Case 1 serves as a good illustration (Fig. 8). About a year following the operation, the patient developed pain and tender callosities beneath the metatarsal heads, especially the second, and markedly diminished power of motion of the big toe was also observed, as a result of the shortening of the first metatarsal. Thus any operation leading to the shortening of the first metatarsal should be emphatically condemned, because the sacrifice of functional disturbance of the foot is too great a price to pay for cosmetic correction of bunion.

A.

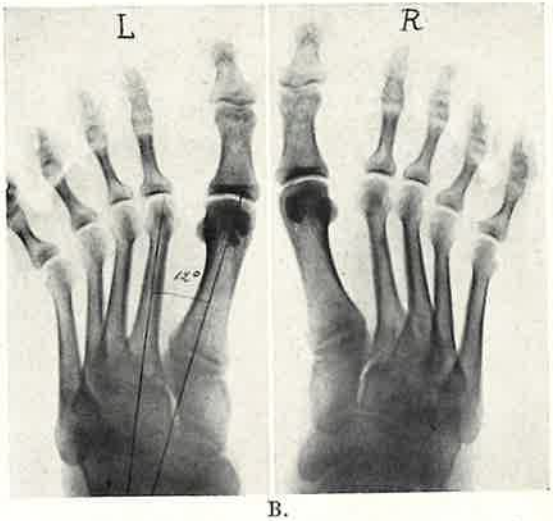

B.

Fig. 4. A, Square shaped atavistic feet with widely separated big and second toes. This type of foot has a potential tendency toward hallux valgus formation. The sister of this man, with same type of foot, developed hallux valgus. Left foot is shown during a phase of gait when the whole weight is borne mainly on the first metatarsal head with the big toe in extreme dorsiflexion. B, Roentgenogram of the same feet showing metatarsus varus primus of 12 degrees. Note wide space between big and second toes easily permitting lateral deviation of the big toe in hallux valgus position.

After the resection of the first cuneiformometatarsal joint described, the first metatarsal head can be abducted laterally, without much effort, bringing it closer to the second metatarsal head, and thereby easily correcting the metatarsus varus primus. The capsule and the ligaments of the first cuneiformometatarsal joint should be preserved as much as possible, especially over its plantar aspect.

Most cases of hallux valgus are also associated with a weak foot, presenting flattening of the longitudinal arch and pronation. This is, to some extent, due to the dorsiflexed attitude of the first metatarsal in the cuneiformometatarsal joint. It is advisable, therefore, when resecting the first cuneiformometatarsal joint, to remove slightly more bone over the plantar aspect of this joint, creating, in this way, another wedge with a plantar base. The plantar flexion attitude of the first metatarsal is thereby produced and will increase the longitudinal arch and diminish pronation.

A second incision, also about 5 centimeters long, is made over the dorsimedial aspect of the first metatarsophalangeal joint. The medial part of the joint capsule is bluntly exposed. A tongue-shaped flap, with its base attached to the proximal phalanx, is made over the medial part of the joint capsule. The bony projection over the medial, and often over the dorsal, part of the first metatarsal head is chiseled off, care being taken to remove all the bony projections interfering with motion of the big toe, especially in its dorsiflexion. The adductor tendon and the lateral part of the joint capsule are tenotomized, if necessary, so that the big toe may now be freely brought in an overcorrected position, without using any force. Usually the big toe in hallux valgus has a tendency toward a slight internal rotation, around its long axis, so that the nail is facing medially (Figs. 5, A, 10, A). That tendency may be a remainder of opposition of the big toe, present in primates, and should be taken into consideration during the suturing of the capsule. A heavy chromic mattress suture is inserted first over the plantar distal part of the capsule in front and medially to the tibial sesamoid. The needle is then brought through the dorsal proximal part of the joint capsule and the deep aponeurosis. This suture crosses obliquely the medial part of the first metatarsophalangeal from its plantar and distal toward the dorsal and proximal parts.

After tying of this suture four important points are gained: (1) the big toe is fixed in adduction medially; (2) the internal rotation of the big toe is corrected; (3) the lateral displacement of the sesamoids together with the plantar flexors of the

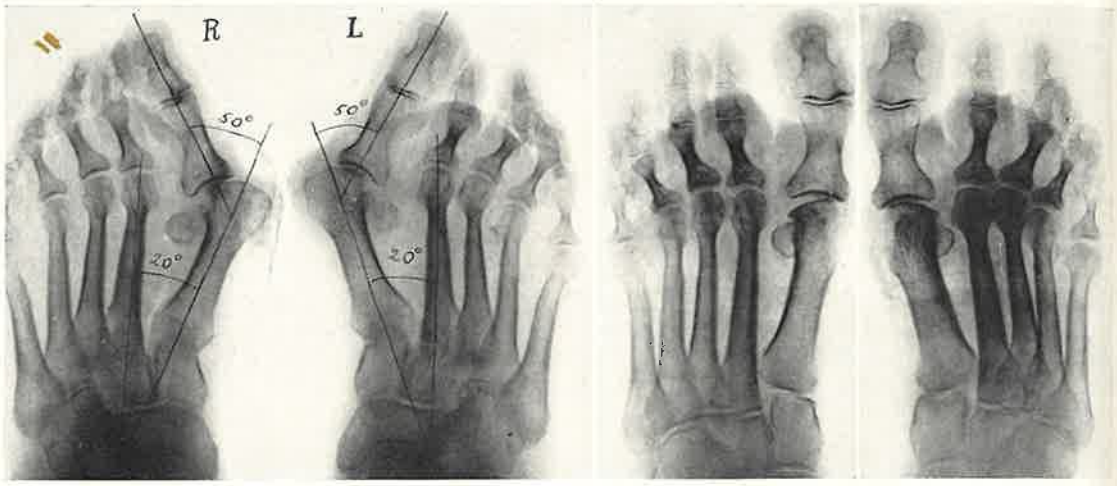

A. B.

Fig. 5. A, Case of "bunion" with marked medial protrusion of the first metatarsal head and lateral subluxation of the big toe. Note the lateral displacement of the sesamoids and inward rotation of the big toes, the nail facing medially. The foot is very wide across metatarsal heads. B, Same feet after the operation. Note also the correction of internal rotation of the big toe and practically normal position of the sesamoids.

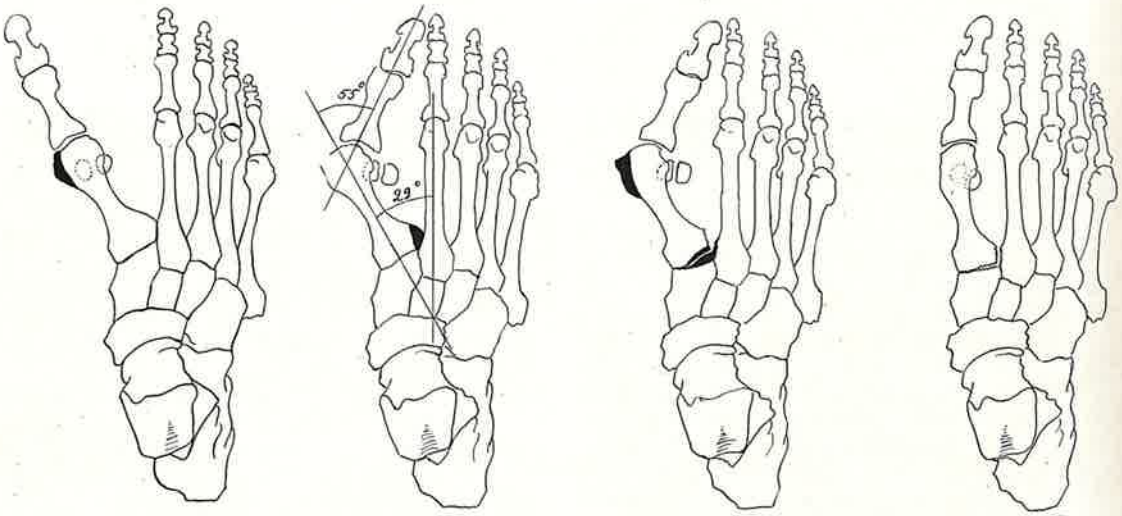

Fig. 6. Fig. 7, A Fig. 7, B Fig. 7, C

Fig. 6. Imaginary postoperative appearance of the foot in case of successful straightening of the big toe without correcting the metatarsus varus primus. (All relations slightly exaggerated.) Note close resemblance with the foot of primates shown in Figure 2. Black area shows the bony prominence which is usually removed.

Fig. 7. Varus position of the first metatarsal is slightly exaggerated for the sake of demonstrability. (The angle between first and second metatarsals is made 29 degrees, while it is seldom over 20 degrees; hallux valgus of 55 degrees is rather common.) Black areas show the parts of bone which are removed. Note the lateral displacement of sesamoids. A, Lateral part of the base of the first metatarsal impinging against the second, is removed. B, Resection of the first cuneiformometatarsal joint over its lateral part only. Note that slightly more bone is removed from the first cuneiform. The adjacent part of the second metatarsal base is roughened with a curette. Removal of the bony proliferation over the first metatarsal head and plastic of the capsule over the medial aspect of the first metatarsophalangeal joint. C, Metatarsus varus primus and hallux valgus are corrected. Note the sesamoids returned to their normal location.

big toe is reduced and this reduction maintained; (4) the deep dorsal aponeurosis with the extensor hallucis longus tendon is pulled medially preventing lateral displacement of this tendon. The tongue-shaped flap of the capsule is now resutured, with the big toe held in adduction, and slight external rotation. The tendon of the abductor hallucis may also be reattached to the medial flap of the joint capsule, thus providing active force, correcting the hallux valgus deformity. The removal of the lateral prominence of the fifth metatarsal heads may also be indicated in some cases.

The deformity must be entirely corrected by the operative procedure alone, so that the big toe will maintain this correction, even if left unsupported. A tight flannel bandage is applied over the well padded forefoot keeping the metatarsals closely approximated. In about 2 or 3 weeks a plaster-of-paris casing is applied to the foot maintaining the correction of metatarsus varus primus. The big toe is not included in the casing and its active and passive motion is encouraged.

A few points in pre-operative preparation of the skin are worth mentioning, as insuring primary union of the wound. It is advisable to prepare the skin over the "bunion" by means of shaving off the callosity and applying salicylic acid ointment a few days or sometimes a few weeks before the operation. A very often present, but usually overlooked, trichophytosis of the foot should be cured before the operation is undertaken.

The writer also believes that the often used oval excision of the skin around the "bunion" should not be practiced, as it may cause tension when the skin is resutured and lead to separation and sloughing of the wound edges. No attempt to remove the bursa is made by me, as a rule, as both the callosity and the bursa readily disappear after the underlying cause—the undue pressure—is eliminated with the correction of the deformity.

It is also important to stress the postoperative care in these cases. A rigid metal plate should be worn by every patient for a few months following the operation, as the keystone of the longitudinal arch—the first cuneiformometatarsal joint—is weakened by this operation, and has to be protected until it will regain its strength. Full weight bearing should not be allowed before 6 or 7 weeks in order to insure solid fusion of the resected cuneiformometatarsal joint.

The somewhat prolonged period of postoperative disability and the resection of the joint supporting the longitudinal arch may be considered the weak points of this operative procedure. The

Fig. 8. Case 1. Right foot of girl 21 years old before and after the operation. (Operated upon April 8, 1931.) Excellent correction of the hallux valgus. Note the marked postoperative shortening of the first metatarsal. About one year after the operation this patient developed heavy callosity over the whole anterior arch, which became markedly convexed. There was tenderness over projecting plantarward second metatarsal head. When she stood the big toe was kept above the floor and there was marked loss of power on motion of the big toe. Functional result is therefore considered by the author as unsatisfactory because of shortening of the first metatarsal.

number of cases is too small as yet, and the time following the operation too short, to make any definite conclusions. (The first case was operated upon April 8, 1931.) However, the writer feels that both the functional and cosmetic results thus far obtained are more than encouraging, and therefore warrants giving this operation further trial in cases of hallux valgus with metatarsus varus primus (Fig. 9, A, B, C, D, 10, A, B).

Not every patient with "bunion" should be operated upon, operation being limited to cases of functional disturbance, or where cosmetics plays an important part. Each case requires individual study.

SUMMARY

1. In a great majority of cases of hallux valgus, there is metatarsus varus primus, which is the primary underlying cause of the deformity—hallux valgus occurring secondarily because of shoe pressure.

2. Hallux valgus, or "bunion," is not so much a lateral deviation of the big toe, as the medial

A. C.

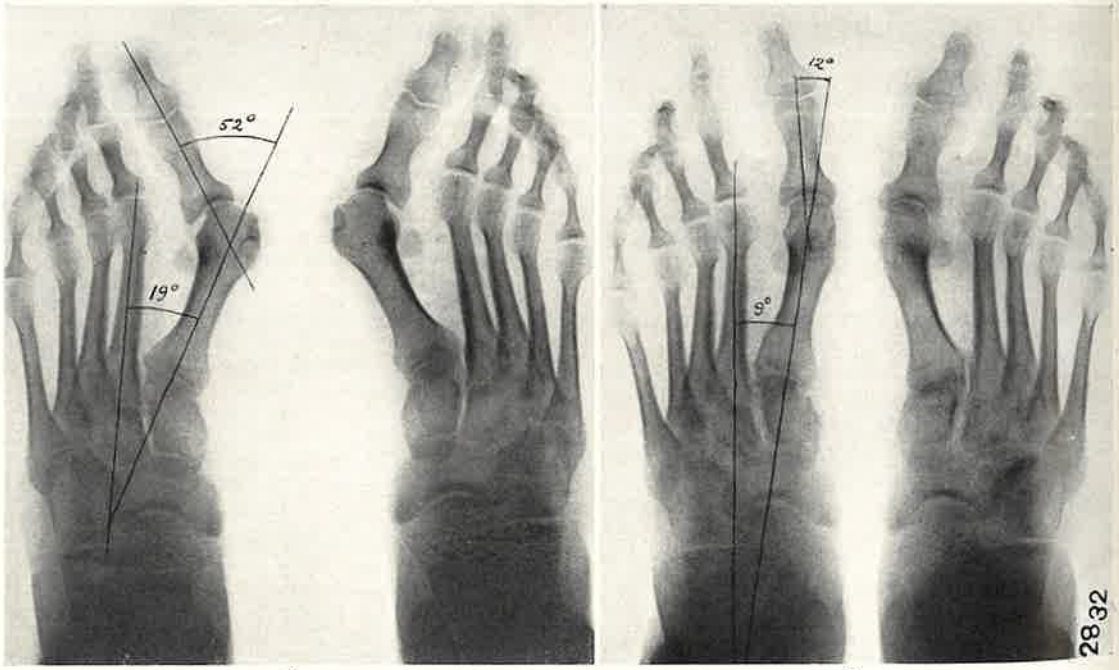

B. D.

Fig. 9. Case 2. A, Feet of a girl 21 years old. Note that in spite of very marked hallux valgus deformity, there is no overlapping of the big and second toes. B, Roentgenogram in the same case showing atavistic feet with metatarsus varus primus of 19 degrees and hallux valgus of 52 degrees. C, Appearance of the same feet 6 weeks after the operation performed on February 3, 1932. Excellent cosmetic and functional result. The circumference of the foot across metatarsal heads became about 2 centimeters less than before the operation. D, Postoperative roentgenogram in the same case. The metatarsus varus primus is reduced from 19 degrees to 9; the hallux valgus from 52 degrees to 12.

protrusion of the first metatarsal head forming bony proliferation because of constant trauma.

3. There is a type of square foot, with a widely spread metatarsal head and metatarsus varus primus. This foot closely resembles that of primates and is considered atavistic. In a well developed human foot, the first and second metatarsals lie almost parallel; the latter type very seldom developing "bunion."

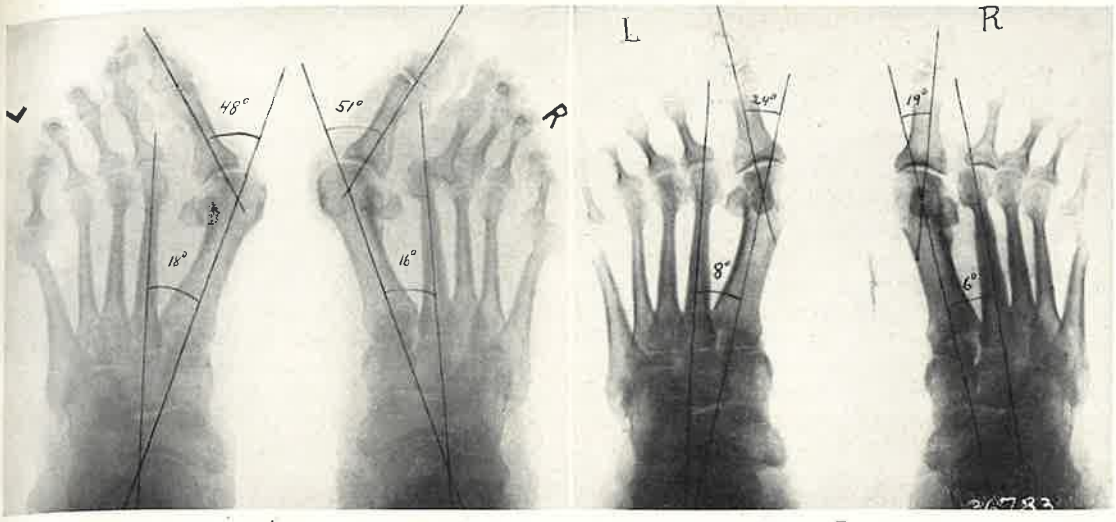

A. B.

Fig. 10. Case 3. A, Feet of woman 35 years old. Note also dorsal subluxation of the basal phalanx of the right second toe and the lateral projection of the fifth metatarsal heads. B .Postoperative roentgenogram in the same case.

4. This atavistic foot has a congenital potential tendency toward hallux valgus formation, and therefore hallux valgus is often hereditary, appearing in youth, mostly in women, because of their type of shoe.

5. No operative procedure is satisfactory, unless correction of the metatarsus varus primus is accomplished.

6. Operation for correction of metatarsus varus primus by resection of a small wedge, at the lateral part of the first cuneiformometatarsal joint, is described.

7. Any operation creating shortening of the first metatarsal, or the big toe, is emphatically condemned as unphysiological, and causing static and dynamic disturbance of the foot.

8. Conservatism and individualization in indication for operative correction of "bunion" is advocated.

Indebtedness is acknowledged to Dr. Leo Mayer, for kind permission to use this operation on his service.

BIBLIOGRAPHY

Erlacher, P. J. Die Technick des orthopaedischen Eingriffs. Eine Operationslehre aus dem Gesamtgebiet der Orthopaedie. Vienna: Julius Springer, 1928.

Hass, J. Welche von den zahlreichen Operationsmethoden beim Hallux valgus sollen wir anwenden? Zentralbl. f. Chir., 1932, xxvi, 1561–1564.

Hiss, J. M. Hallux valgus, its cause and simplified treatment. Am. J. Surg., 1931, xi, 51–57.

Juvara, E. Le Hallux-Valgus: Son Traitement Opératoire. Rev. d. Chir., 1932, li, 322–348.

Kleinberg, S. The operative cure of hallux valgus and bunions. Am. J. Surg., 1932, xv, 75–81.

Soutter, R. Technique of Operations on the Bones, Joints, Muscles and Tendons, p. 118. New York: Macmillian Co., 1917.

Timmer, H. Die Behandlung des Hallux valgus. Leipzig: J. A. Barth, 1930.

Truslow, W. Metatarsus primus varus or hallux valgus. J. Bone & Joint Surg., 1925, vii, 98–108.