Clinical Orthopaedics

ANTHONY F. DePALMA
Editor-in-Chief

With the Assistance of the
ASSOCIATE EDITORS
THE BOARD OF ADVISORY EDITORS
THE BOARD OF CORRESPONDING EDITORS

Number Sixteen

J. B. LIPPINCOTT COMPANY
Philadelphia and Montreal

Paragon 28 v. Treace Medical Concepts
PGR2026-00031
Paragon Ex. 1018

COPYRIGHT ©, 1960, BY J. B. LIPPINCOTT COMPANY

This book is fully protected by copyright and, with the exception of brief excerpts for review, no part of it may be reproduced in any form without the written permission of the publishers.

Distributed in Great Britain by Pitman Medical Publishing Co., Limited, London

Library of Congress Catalog Card Number 53-7647

Clinical Orthopaedics is designed for the publication of original articles offering significant contributions to the advancement of surgical knowledge. Any such articles should be forwarded prepaid to Dr. Anthony F. DePalma, 1025 Walnut Street, Philadelphia 7, Pa., and should comprise the original, typed manuscript and one carbon copy, together with a short synopsis of 200 to 250 words for translation into Interlingua, and illustrations. Further, all manuscripts submitted must be in English.

Manuscripts should be typed double spaced on one side of standard typewriter paper, leaving wide margins. While every effort will be made to guard against loss, it is advised that authors retain copies of manuscripts submitted. All pages should be numbered. Dorland's *American Illustrated Medical Dictionary* (edition 23) and Webster's *New International Dictionary* (edition 2) should be used as standard references. Scientific names for drugs should be used when possible. Copyright or trade names of drugs should be capitalized. Units of measurement, e.g., dosage, should be expressed in the metric system. Temperature should be expressed in degrees centigrade.

Black-and-white illustrations will be reproduced free of charge, but the publisher reserves the right to establish a reasonable limit upon the number. Ordinarily, colored illustrations cannot be published except at the author's expense. Black-and-white photographs should be in the form of glossy prints. **These should not be defaced in any way.** Any changes desired in them should be marked on a tissue overlay. This should be done before it is pasted to the print, since it is important not to mar the print in any way. Or any changes may be indicated on a separate sheet of paper. Line and wash drawings should be on white art board, with lettering in black India ink large enough to be readable after necessary reduction. Large or bulky illustrations should be accompanied by smaller glossy reproductions of the same to facilitate their circulation among the members of the editorial board. Illustrations should be numbered, the tops indicated, and the author's name and the title of the article in brief should appear on the back. **However, this should be done lightly, so as to leave no imprint on the face of the illustration.** A separate typewritten sheet of legends for the illustrations should be supplied.

A bibliography of numbered references *in alphabetic order* should appear at the end of the manuscript with corresponding numbering in the text. Bibliographies should conform to the style of the *Quarterly Cumulative Index Medicus:*

If a book:

Author's name, title of book, edition if there is more than one, page numbers if it is wished to direct the reader to a specific section of the book, city in which publisher is located, publisher's name, year of publication of book, *in the order named.*

If an article in a journal:

Author's name, title of article, volume number, inclusive page numbers, year of publication, *in the order named.*

Following are the general subjects of forthcoming issues of *Clinical Orthopaedics:*

Clinical Physiology and Pathology of Bone, 1960
Internal Derangement of the Knee Joint, 1960
Soft-Tissue Tumors, 1961
Disorders of the Shoulder Joint, 1961
Back Disorders in Children, 1961
Diseases of the Hip in Children, 1961
Disorders of the Cervical Spine, 1962
Gait and Posture, 1962
Athletic Injuries, 1962
Medicolegal Problems, 1962
The Elbow, 1963

617.305
CO
no.16
Serial
Health Sci.

All contributors desiring to submit articles for consideration for publication on the topics listed above or in the general sections of this publication should submit them to the editor at least six months in advance of the date of the issue for which they are intended.

PRINTED IN THE UNITED STATES OF AMERICA

This material may be protected by Copyright law (Title 17 U.S. Code)

12

The Author's Bunion Operation From 1931 to 1959

PAUL W. LAPIDUS, M.D.*

The author's bunion operation was first performed at the Hospital for Joint Diseases on April 8, 1931, and thus far has stood the test of time; it is still being done successfully. The details of it were published as a preliminary communication in February, 1934.

The purpose of this chapter is to describe our present-day approach to the bunion problem. Since the earliest days of his orthopaedic practice, the author has been aware of the frequent association of the metatarsus varus primus with bunions. What he was *not* aware of at that time was the fact that the same observation was made by anthropologists long before orthopaedic surgeons thought of it. Already in 1882, Leboucq pointed out that the divergence of the first metatarsal was due to the extreme angle made by the plane of the distal articular facet of the first cuneiform bone with the

* New York, N. Y.

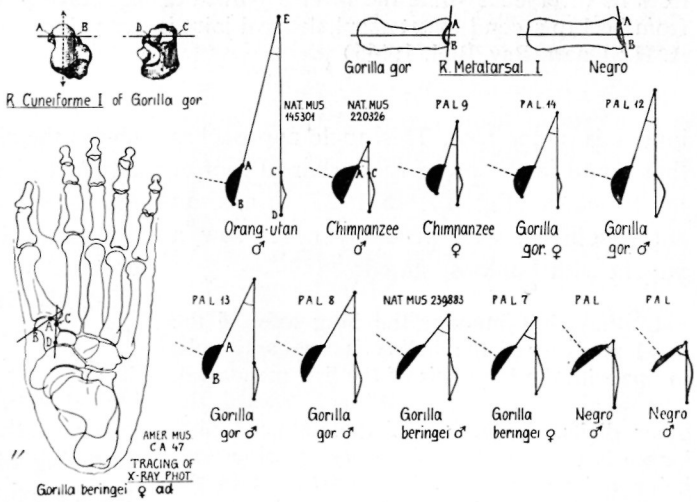

FIG. 1. Tracing of the roentgenogram of the skinned foot of an adult female mountain gorilla (beringei) showing the location of the section through the joint of the hallux and the first cuneiform. Figures on the right are accurate copies of these sections through the first cuneiform bones of various higher primates. Line A-B represents a section through the center of the first cuneiform-metatarsal joint in the plane roughly parallel to the sole of the foot. Line C-D is drawn through the middle of the joint between the first and the second cuneiforms and was found always to have practically the same direction as the morphologic axis at the foot. The angle B-E-D (see orangutan) determines the medial slant of the plane of the first cuneiform-metatarsal joint. The greater this angle the less the slant and, likewise, the divergence of the first metatarsal. According to Schultz, in man this angle is 56 to 50°; in the terrestrial gorilla beringei it is 39 to 35°; in the arboreal Gorilla gorilla it is 30 to 18°; and in monkeys it is 24 to 13°. The black semicircle represents the shape of the first cuneiform-metatarsal joint, which is more ball-and-socketlike in movable hallux of the lower primates and becomes flattened in higher primate and especially in man, with the loss of mobility of the first metatarsal. (Reprinted from Human Biology, vol. 2, no. 3 [chapter entitled "The Skeleton of the Trunk and Limbs of Higher Primates," by Adolph H. Schultz] by permission of the Wayne State University Press)

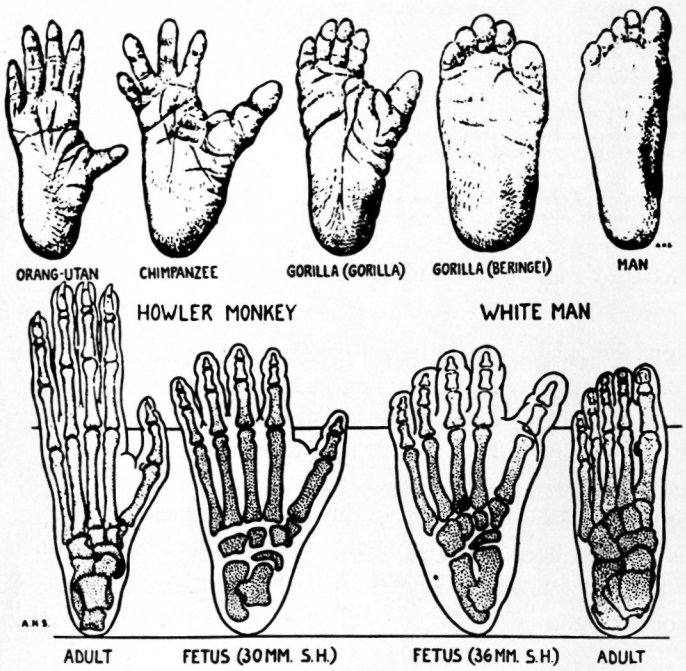

FIG. 2. Note the shortening of the hallucial ray from man to orangutan and also the increased divergence of the big toe in prehensile foot of lower primates as compared with man (upper row). The difference between the big toe in gorilla beringei and that of the Gorilla gorilla is most interesting. Although they are very closely related, the first spends a great deal of time walking on the ground; therefore, his big toe resembles very closely that of man, while the hallux of the prevailingly arboreal Gorilla gorilla still retains simian features and is more like that of the chimpanzee. In the lower row is a semidiagrammatic drawing of feet of fetal and adult man, and howling monkey, showing ontogenetic reduction of the lesser digits in adult man and their increase in a grown-up monkey. Also note that the hallucial elements are almost similar in both embryos, but the first ray of the adult man becomes stouter and loses its divergence while the reverse growth changes take place in the monkey's foot. Distance from heel to second metatarsophalangeal joint is same absolute length in all 4 drawings. (Schultz, A. H.: Quart. Rev. Biol. 1:465)

long axis of the foot. This angle approaches that found in the prehensile arboreal foot of the primates (Fig. 1). In 1927, Straus, an anthropologist, who probably never saw a patient with bunions, stated:

> In the adult human, the long axis of the basal phalanx of the hallux is not, as a rule, in line with the long axis of the first metatarsal. The phalangeal portion is bent toward the other digits. Adduction of the hallucial phalanges is the rule for all human development, being quite as marked in the fetus as in the adult. This condition cannot be ascribed to wearing boots, for it is general among the lower primates and was present in a howler fetus as well. In man it persists most likely as a relic of the days when the foot was a grasping organ and the hallux was bent as a hook toward the other toes.

Figure 2 (Schultz, 1926) illustrates the trend of ontogenetic development of the foot in the howling monkey and man, and also shows the changes of the big toe as it gradually lost its prehensile functions from ape to man.

Figure 1 (Schultz, 1930) shows the changes of the first cuneiformometatarsal joint, also from ape to man. The two cardinal features are (1) diminution of medial slant of the first cuneiformometatarsal joint and, consequently, also of the medial divergence of the first metatarsal, and (2) the flattening of the first cuneiformometatarsal articulation, which is more ball-and-socket-like in the mobile hallux of the lower primates.

The following table (Straus, 1927) brings out the fact that the varus of the first metatarsal, measured by the angle between the long axes of the first and the second metatarsals, is more marked in the human embryo, being 32.0° in an eight-week human fetus, and diminishes to 6.2° in an adult

ANGLE (APPROXIMATE) BETWEEN LONG AXES OF METATARSI I AND II DURING GROWTH OF MAN AND HOWLING MONKEY AND IN SOME OTHER PRIMATES

AGE	AVERAGE IN DEGREES	RANGE OF VARIATION IN DEGREES
Man		
8th week fetus	32.0	
3rd mo. fetuses	18.7	14.0–30.0
4th mo. fetuses	11.1	3.5–14.0
5–6 mo. fetuses	10.1	6.5–15.5
7–8 mo. fetuses	6.1	3.0– 9.5
9th mo. fetuses	8.9	3.0–19.5
Newborn	5.8	4.0– 8.0
Juvenile	5.0	2.0– 8.0
Adult	6.2	3.0– 9.0
Anthropoid Apes		
Orangutan, adult	46.2	42.0–49.5
Chimpanzee, juvenile	42.0	
Chimpanzee, adult	39.0	
Gorilla, juvenile	25.0	18.0–30.0
Gorilla, adult	25.0	20.0–30.0
Hylobates, adult	17.5	11.0–33.0
New World Monkeys		
Alouatta, fetus 111 mm., C.R.	55.0	
Alouatta, newborn	40.0	
Alouatta, adult	23.0	

Note gradual ontogenetic diminution of hallucial divergence in man from 32.0° in the 8th month fetus to 6.2° in adult. Anthropoids have a much greater angle, which reaches an average of 46.2° in prevailingly arboreal orang-utan. It is interesting to note the diminution of divergence with growth also in Alouatta (howling monkey) (Straus, W. L., Jr.: Contrib. Embryol., No. 101, **19**:119)

man. In other words, the hallux of the human embryo has simian features that gradually are lost with growth.

The above-quoted anthropologic works seem to support the postulations made by the author in his preliminary report in 1934, that the bunion is more prone to develop in an "atavistic" foot with metatarsus varus primus. This type of foot apparently became arrested in its ontogenetic development and retained some features normally present in the human embryo and in the adult foot of the lower primates. It may be considered as a reversion to a primitive state, presenting "congenital potential predisposition toward hallux valgus formation, and thus the often observed hereditary predisposition toward this deformity can be readily understood" (Lapidus, 1934). When harelip and cleft palate are repaired, or an operation for undescended testicle is performed both being typical examples of an arrest of ontogenetic development, the surgeon attempts to complete the process that normally takes place during natural growth. By the same token, if the persistence of the metatarsus varus primus, together with hypermobility and the apelike shape of the first cuneiformometatarsal joint, allowing excessive tibial abduction of the first metatarsal in an adult man, is accepted as an arrest of development and is one of the main predisposing factors for bunion formation in a great number of patients, it is only logical to conclude that surgical repair should also consist of correction of metatarsus varus primus. If the divergence of the first metatarsal in an adult is explained as a failure of nature to complete its normal cycle of growth, then it is up to the surgeon to complete what nature failed to do, similar to harelip, cleft palate or undescended testicle.

The idea that the metatarsus varus primus is a primary factor with subsequent formation of hallux valgus is not a new one. It has been advanced by a number of orthopaedic surgeons, as can be seem from Figure 3 (after Timmer), a schematic illustration of some of the numerous operative procedures devised for correction of the bunion. Once more the author wishes to repeat that, except for the details of the operation, he does not claim priority or originality. Quite a few surgeons in the past and a number of them today approached this problem in somewhat similar manner, attempting to correct the metatarsus varus primus.

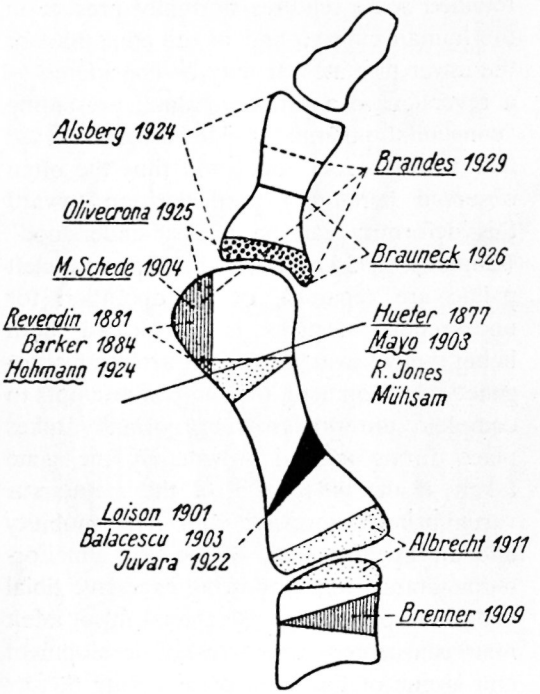

FIG. 3. Schematic drawing of various operative procedures devised for correction of bunion. The name of the author and the year of description of the operation are indicated. (Timmer, H.: Die Behandlung des Hallux valgus, Leipzig, Barth)

As already stated, the degree of divergence of the first metatarsal away (tibialward) from the second depends upon the shape and the range of motion in the first metatarsocuneiform joint. The long axis of the first metatarsal forms an obtuse angle, open tibialward, with the long axis of the first cuneiform; the apex of this angle is at the first cuneiformometatarsal joint.

Osteotomy to correct an angulation deformity of any long bone is performed usually at the apex of the angulation, and not distally or proximally to it; otherwise, a bayonet-shaped deformity is produced. An ankylosed knee joint with genu valgum or with flexion deformity is best corrected by an osteotomy placed right through the former line of the joint and not over the femur or the tibia. Therefore, it is the author's preference to correct the metatarsus varus primus at the first cuneiformometatarsal joint; numerous and variable osteotomies of the first metatarsal shaft, and particularly so over its distal part, never have seemed to the author to be mechanically sound (Fig. 3).

Furthermore, any osteotomies require adequate and prolonged immobilization to prevent displacement of fragments and to ensure their firm bony union. This, again, makes them undesirable. In another group of operative technics, attempt is made to utilize soft tissues (muscles, tendons or fascia) to approximate the first metatarsal head to the second and, thus, to correct the metatarsus varus primus. For a number of years it has been our preoperative routine in bunion cases to take dorsiplantar roentgenograms of the foot tightly bandaged across the metatarsal heads in addition to other routine exposures. We learned that in some cases we were unable to approximate closely the first and the second metatarsal heads, with some persistence of metatarsus varus primus even on tight bandaging. This was obviously due to a fixed tibial abduction contracture at the first cuneiformometatarsal joint. Consequently, is it reasonable to expect a small intrinsic muscle of the foot, as, for instance, the abductor hallucis, when it is transplanted onto the first metatarsal neck, to adduct the first metatarsal fibularward, and especially when there is fixed tibial abduction contracture present in the joint? Fascial or tendinous transplants anchored to the metatarsal necks to correct their spreading, advocated by some surgeons today, have also been tried by the author (1933) but were abandoned in favor of the bony fusion of the first metatarsocuneiform joint with creation of a bone bridging the first and the second metatarsal bases. Of course, it goes without saying that when correction of the first metatarsus varus is indicated, it is always combined with the correction of the valgus deformity of the big toe itself. In the latter procedure, not only do we depend on passive re-establishment

of balance between (tibial) abduction and (fibular) adduction of the big toe, but also we utilize the abductor hallucis muscle to supply the active power to maintain the big toe in proper alignment with the first metatarsal, as will be described below (Fig. 4).

Another group of operative technics consist of resection of the first metatarsophalangeal joint itself. The old Mayo-Küttner resection of the first metatarsal head never appealed to the author, and he is even more convinced now than he was in 1934 that "any operation creating shortening of the first metatarsal, or of the big toe, is emphatically condemned as unphysiological, and causing static and dynamic disturbance of the foot."

The resection of the base of the proximal phalanx according to the Keller-Brandes procedure has gained some popularity recently, mainly because of its simplicity and allegedly short postoperative disability. However, not infrequently after this procedure the big toe becomes a short, dangling appendage held above the ground, and the important "shove-off" function of the big toe may be lost permanently. Consequently, if one wishes to obtain as close as possible restoration of normal anatomic and physiologic relations, one cannot accept the Keller-Brandes operation.

INDICATION FOR OPERATION

Bunions are very common, especially in females, who, using their feet primarily for sex appeal, locomotor function being given only secondary consideration, succumb to the dictates of fashion and develop the deformity. The poorly fitting, narrow woman's shoe with a high heel is a factor in developing the malformation in a foot, which most of the time possesses a congenital and often hereditary predisposition toward bunion formation. In this respect, the shoe may be compared with a developing solution that only brings out the picture in a previously exposed photographic film.

We have operated upon a large number of female feet. Only a few male patients have sought surgical correction. A large percentage of bunion feet give very little, if any, discomfort, and can be treated adequately with properly fitted shoes. On the other hand, even mild bunions, especially in females, may produce a great many complaints, especially while "breaking in" a new shoe.

In addition to actual functional disturbances and disability, quite a few patients request the operation for cosmetic reasons. As a rule, we limit our surgical correction to selected cases in which functional and cosmetic consideration seem to warrant it. Therefore, although for the past many years we have operated upon a large number of patients, they represent only a small percentage of extremely numerous patients with bunions treated conservatively. Furthermore, if surgical procedure is undertaken, we do not attempt to correct the metatarsus varus primus as frequently as we did originally. We must admit that with the accumulation of larger experience through many years, we have become more conservative and in a number of cases have limited our procedure to correction of the hallux valgus alone. It has been our observation that after satisfactory correction of hallux valgus, using our modification of the Silver procedure, the varus of the first metatarsal may diminish simultaneously, provided that there is adequate mobility of the first cuneiformometatarsal joint to allow the approximation of the first and the second metatarsal heads. This mobility is estimated on roentgenograms with tight bandaging across the metatarsal heads, as already described. It has been our impression that in spite of the fact that metatarsus varus primus may be the main factor, hallux valgus developing subsequently, in a number of cases successful correction and maintenance of this correction of the big toe deformity are more important and often may be performed alone. On the other hand, additional correction of the first metatarsus varus, when it is

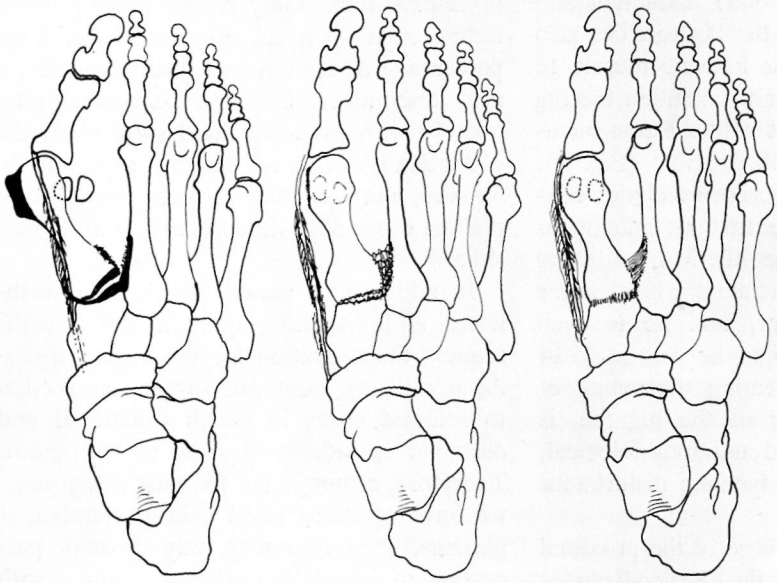

FIG. 4. Operative technic. (Lapidus, P. W.: Surg. Gynec. & Obst. 58:183.) Note the plantar displacement of the abductor hallucis in bunions and its action as a plantar flexor. It is relocated along the medial aspect of the first metatarsal, and its *abduction* action is re-established.

pronounced, with first and second metatarsals forming an angle of 10° to 12° or more, may ensure better results in the long run.

A survey of end-results of various operative procedures for correction of hallux valgus performed at the Hospital for Joint Diseases during 10 years (1931-1940) has seemed to indicate that better results were observed when metatarsus varus primus also was corrected.

We have operated upon a considerable number of patients under local anesthesia when we limited ourselves to correction of the hallux valgus alone. There is no need for a tourniquet in this procedure, which also requires less time to perform, and the postoperative recovery may be a few days shorter. On the other hand, when correction of metatarsus varus is undertaken, a tourniquet is used, and, therefore, general anesthesia is required. The decision, of course, should depend on the judgment and the personal experience of the surgeon, as well as on the condition and the requirements of each patient. If the patient is not too old and is robust, and is willing to invest an extra week or two in anticipation of a somewhat better eventual result, and if the surgeon is quite confident in his hospital facilities and is fully familiar with the foot, the combination of both procedures may be indicated. Otherwise, mere correction of hallux valgus alone will be a preferable and a safer undertaking, and may also give a very satisfactory final result.

OPERATIVE TECHNIC

The present operative technic remains essentially the same as described originally in 1934 (Fig. 4). If the correction of metatarsus varus primus is planned, the operation is performed under general anesthesia. An Esmarch rubber bandage is first applied from the toes up to the lower quarter of the leg, where it is bandaged tightly over a towel and is used as a tourniquet.

The operation over the big toe joint is performed first. A straight longitudinal incision about 3½ to 4 inches (9-10 cm.) long is made along the medial aspect of the big toe and the first metatarsal. The subcutaneous veins are ligated. The medial cutaneous nerve frequently seen in the wound is identified and retracted. The bursa over the bunion is opened, and further dissection is carried proximally in the same plane, as the

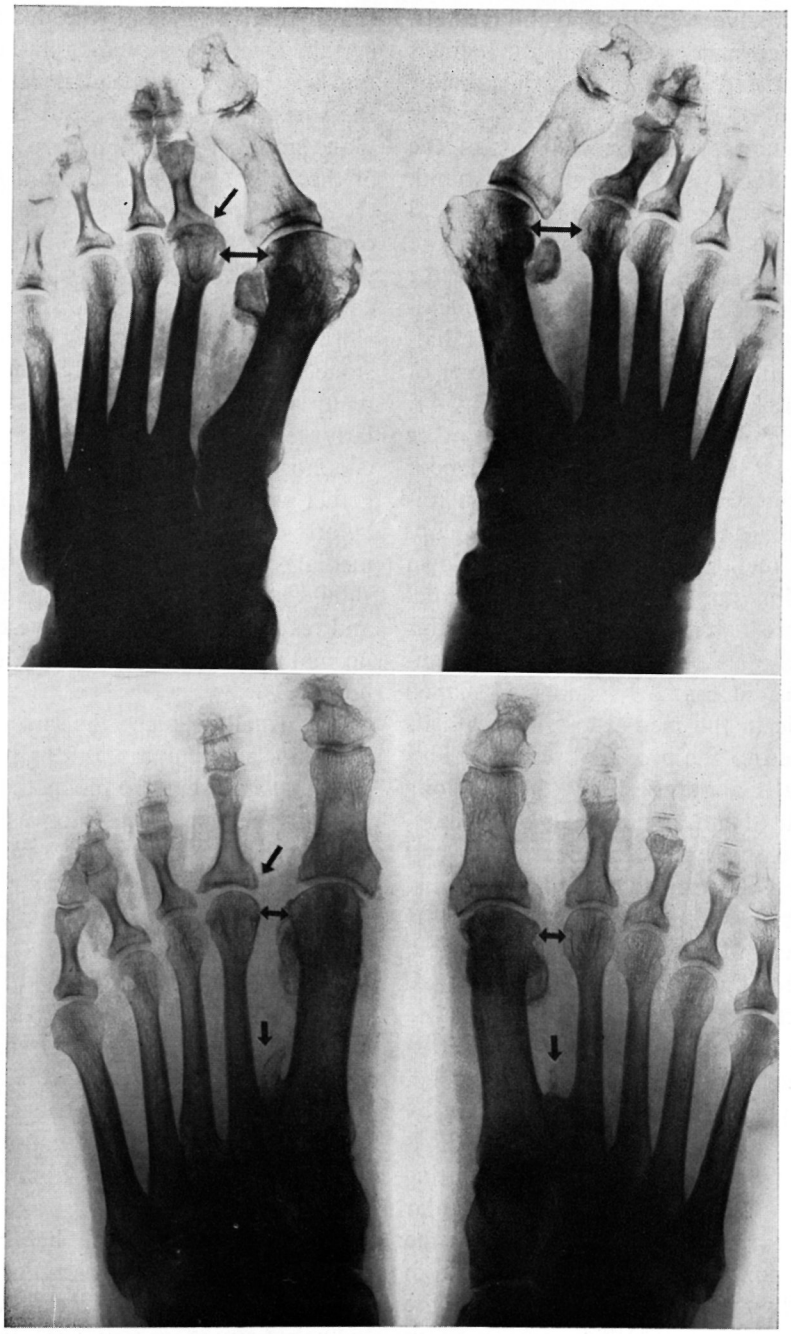

FIGS. 5 to 8, 3 cases (L.K., B.K. & A.S.) following correction of metatarsus varus primus in hallux valgus. (L.K. and A.S. also had bilateral second hammertoe operations; in Case A.S., the second toes also overlapped the big [see Fig. 7, *top*]). FIG. 5, L.K. (*Top*) Before operation. (*Bottom*) About 6 years after operation.

tissues here have very few blood vessels. The fascia covering the abductor hallucis muscle is incised longitudinally just below the insertion of this fascia along the first metatarsal shaft. A muscular belly of the abductor hallucis pops out into the wound. Its loose connection with the first metatarsal shaft may be separated by blunt dissection. As a rule, in nearly all bunions the abductor hallucis is found displaced plantarly, blending with the medial belly of the flexor hallucis brevis and acting as a plantar flexor of the big toe rather than its abductor (Fig. 4). These muscles are separated from each other also mostly by blunt dissection. The slender tendon of the abductor hallucis is then followed distally and separated from the capsule of the metatarsophalangeal joint down to its insertion onto the base of the proximal phalanx, care being taken not to sever this tendon or to open the joint capsule. The tendon is retracted plantarly, and a U-shaped flap is made in the medial capsule, with its base attached to the proximal phalanx. This flap usually is about ¾ inch (2 cm.) long and ⅜ inch (1 cm.) wide at its distal base, tapering proximally to the neck of the first metatarsal. The capsular flap is reflected distally, care being taken to dissect it from the medial aspect of the first metatarsal head, preserving its full thickness. Usually a small artery is cut over the metatarsal neck. The joint now is opened by reflecting the flap distally. The neck of the metatarsal is exposed. The "sagittal groove," so well described by Haines and McDougall (1954), is noted. It runs in dorsoplantar direction, separating the normal lateral cartilaginous articular surface that remains in contact with the laterally subluxated proximal phalanx from the fibrously degenerated cartilage of the medial part of the head. This groove often is quite deep in marked cases of bunion and is reddish, containing denuded rough bone. The "bunion" itself is represented usually by the dorsomedial prominence of the first metatarsal head. This prominence is shaved off so that the medial, the dorsal and, to a certain extent, the medioplantar flare-up of the first metatarsal head is removed. Now the medial part of the head is in the same plane and is the continuation of the cortex of the neck and the shaft of the metatarsal. Occasionally there is a dorsal prominence over the first metatarsal head, which likewise has to be shaved off. Small wood-carving chisels obtainable in any hardware store in a set, together with a sharpening stone, have been used by the author for many years and are indispensable, particularly for resection of the first metatarso-cuneiform joint. They are sterilized, together with the stone, and sharpened just before the operation. When resecting the medial part of the first metatarsal head, care should be taken to preserve its round shape, and especially its part covered with the normal cartilage, without excising too much bone.

We usually replace the capsular flap and the skin and palpate through them to be sure that no bony prominences are left.

The subcutaneous tenotomy and capsulotomy then are performed over the fibular aspect of the first metatarsophalangeal joint from a dorsal approach, while the big toe is forced gently into varus (10°-15°) position. A stout sharp tenotome should be used for this, and it should be inserted to hug the bone and the joint closely, as the blood vessels and nerves pass more superficially to bone in surrounding soft tissues. The medial tongue-shaped flap of the capsule is sutured to the tendon of the abductor hallucis longus with considerable tension, several No. 00 chromic stitches being used. The plantar and the dorsal capsular wounds are also closed. At the same time the abductor hallucis belly, together with its tendon, is shifted dorsally, running now along the medial aspect of the first metatarsal instead of plantarly to it, and its action as an "abductor" (tibialward) instead of a plantar flexor of the big toe now is re-estab-

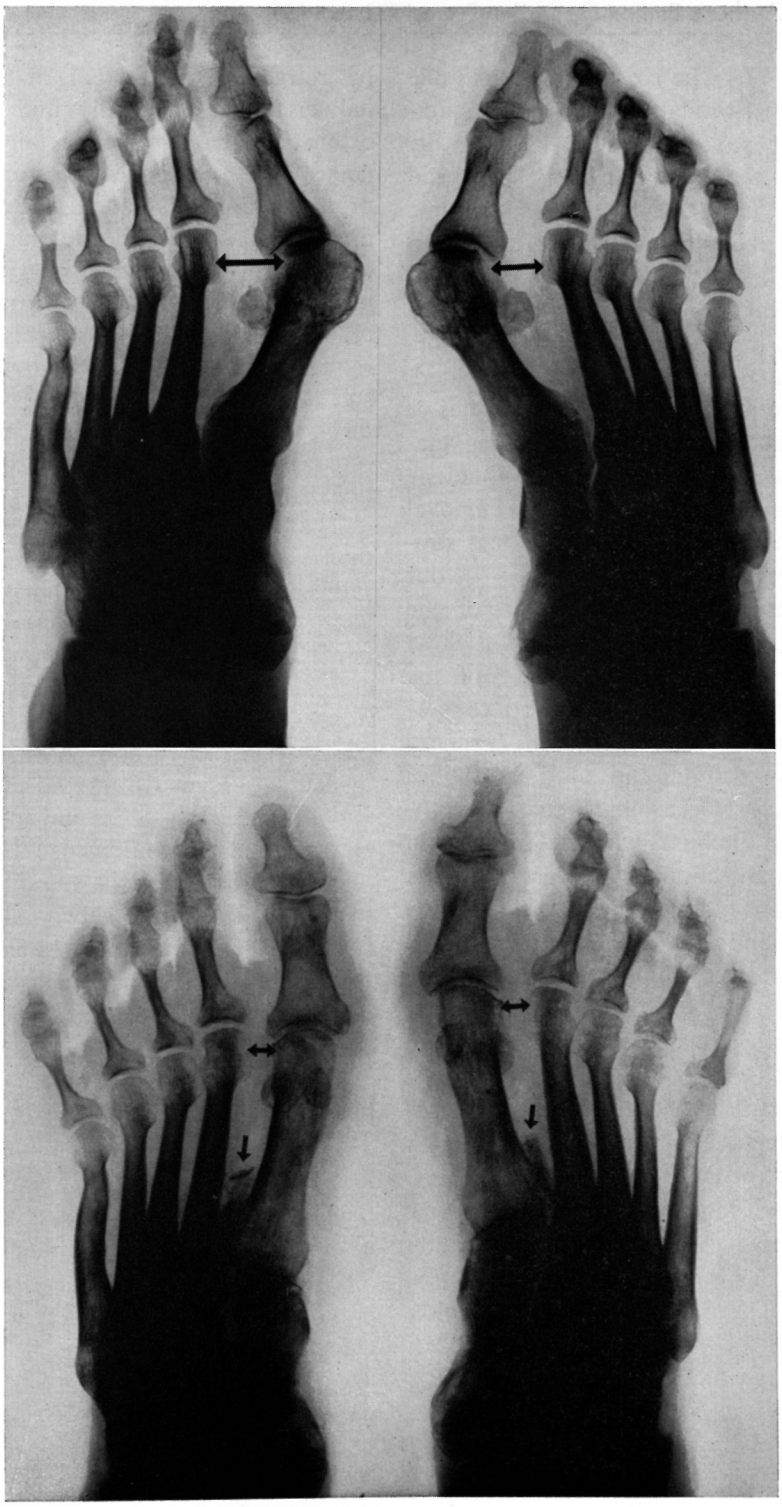

FIG. 6, B.K. (*Top*) Before operation. (*Bottom*) About 6 months after operation.

lished (Fig. 4). The closing of the capsule should be performed carefully and judiciously. All capsular slack produced by resection of the medial part of the head should be removed, but at the same time the capsule should not be sutured too tightly as later to cause limitation of motion of the big toe; a good balance between abduction and adduction and dorsal and plantar flexion should be created. As a rule, the big toe in hallux valgus is in internal rotation, so that both big toenails face each other. This also should be corrected. In ordinary cases no removal of the bursa is ever attempted unless suppurative bursitis is present. In a few of our patients, there was communication of the infected bursa with the joint. In these cases, after thorough débridement of the infected tissue, we were able also to perform the bunion operation with primary union of the wound and used antibiotics postoperatively. Occasionally there is communication of the bursa with the joint also in cases without infection. In one case there was a very extensive deposition of uric acid in the bursa, and the joint surfaces were canary yellow, all impregnated with uric acid crystals. Perfect primary healing was also obtained in this 69-year-old man. The skin is closed without suturing the subcutaneous structures. If the procedure is carried out adequately, the big toe remains well corrected without any external support.

As already stated, in a number of our cases we were able to obtain very satisfactory and lasting results after this procedure alone. If, however, the correction of the metatarsus varus primus is indicated, it is carried out as a second step following completion of the operation on the big toe. A longitudinal incision about 3½ inches (9 cm.) is made along the dorsum of the first metatarsal and the first cuneiform. The first cuneiformometatarsal joint is exposed by retracting the tendon of the extensor hallucis longus medially and that of the extensor hallucis brevis laterally. The cutaneous nerve branches are identified and protected. The V-shaped space between the first and the second metatarsal bases is exposed by dissection, hugging the first metatarsal closely. The perforating plantar branches of the dorsalis pedis vessels are retracted distally and fibularward with the soft tissues when exposing the second metatarsal base. Occasionally the veins are ruptured, but we have never had any complications from that.

The cortex from the adjacent surfaces of the base of the first and the second metatarsals is removed, leaving the bone chips in situ. The first cuneiformometatarsal joint is opened on its dorsal aspect. The adjacent cartilaginous articular surfaces of the first metatarsal and the first cuneiform are shaved off. Here a small wood-carving chisel about 5 inches (13 cm.) long and about ⅜ inch (about 1 cm.) wide, is indispensable! We learned that no real wedge resection was necessary, that mere shaving off of the articular cartilage down to subchondral bone was not only enough but also essential in order to produce close linear coaptation of the resected joint surfaces and ensure prompt "primary union" of the bones.

One has to become familiar with this bean-shaped joint, which measures almost 1⅛ inches (2.9 cm.) in dorsoplantar direction, and approximately ½ inch (1.3 cm.) from side to side in its widest dimension. It also faces plantarward and medially (Fig. 1). The articular facet of the first metatarsal is slightly concave, while that of the first cuneiform is correspondingly convexed in sagittal plane. There is also a similar concavity of the first metatarsal and convexity of the first cuneiform in the horizontal plane. A snug fitting and close approximation of the resected surfaces should be obtained. A hole is then made with a shoemaker's awl

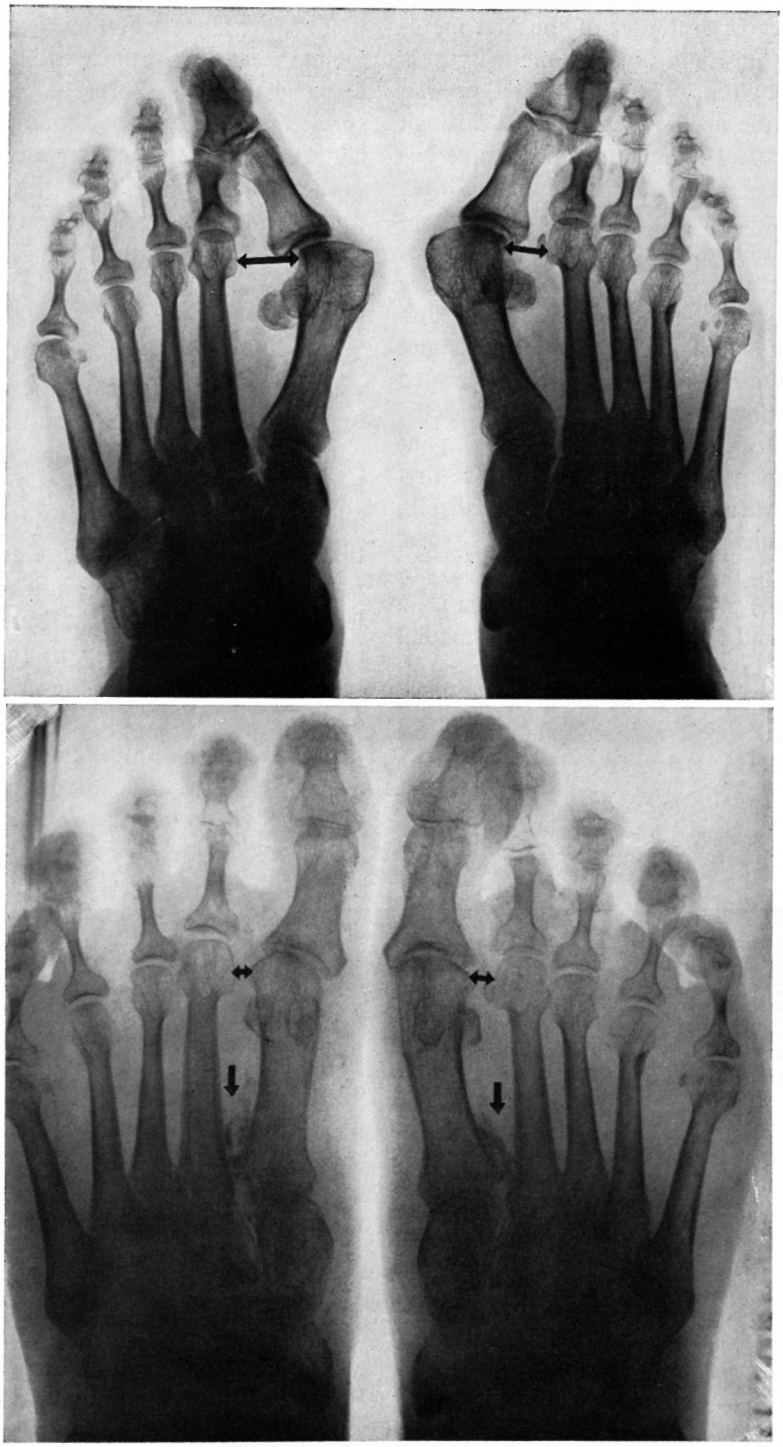

FIG. 7, A.S. (*Top*) Before operation. (*Bottom*) About 6 weeks post-operatively.

over the dorsolateral part of the first metatarsal base, and No. 0 chromic catgut is passed through it, using a curved needle. Proximally, the needle is introduced through the strong dorsal ligamentous structures between the first and the second cuneiforms. When this stitch is tied, a close approximation is maintained. The pieces of bone obtained from the first metatarsal head are denuded from soft tissue and cartilage and cut in very small bone chips, which are inserted abundantly between the denuded bases of the first and the second metatarsals. They later form a bony bridge that maintains permanently the correction of the first metatarsus varus. Skin is closed with silk without suturing the subcutaneous tissues. A 5-inch (about 12 cm.) long and 5/16-inch (7 mm.) wide steel corset stay is used as a splint and is inserted along the medial aspect of the first metatarsal over well-padded dressing. The big toe is strapped to it at about 10° of varus and in slight external rotation. The first dressing should be done snugly, but not too tightly. After adequate correction, one will find on postoperative roentgenograms complete correction of metatarsus varus primus without tight bandaging across the forefoot. Likewise, the splinting of the big toe should be done most carefully in order to avoid pressure over the suture line. This is very important. One should depend primarily on an adequate surgical correction, the splinting being aimed only at maintaining it, rather than on increasing the correction.

Since the introduction of the antibiotics we have applied an antibiotic ointment routinely to the suture line* and also given the patient an antibiotic starting from one day before the operation and continuing for about 1 week postoperatively. It was noted that better wound healing was gained with prophylactic use of the antibiotics. Particularly, the wound over the bunion showed a more frequent tendency to form stitch abscesses and to separate in our early cases, and that tendency appeared to be greatly decreased by the antibiotics. There was not a single case of true infection in our latest

* Lately we have been using only Telfa.

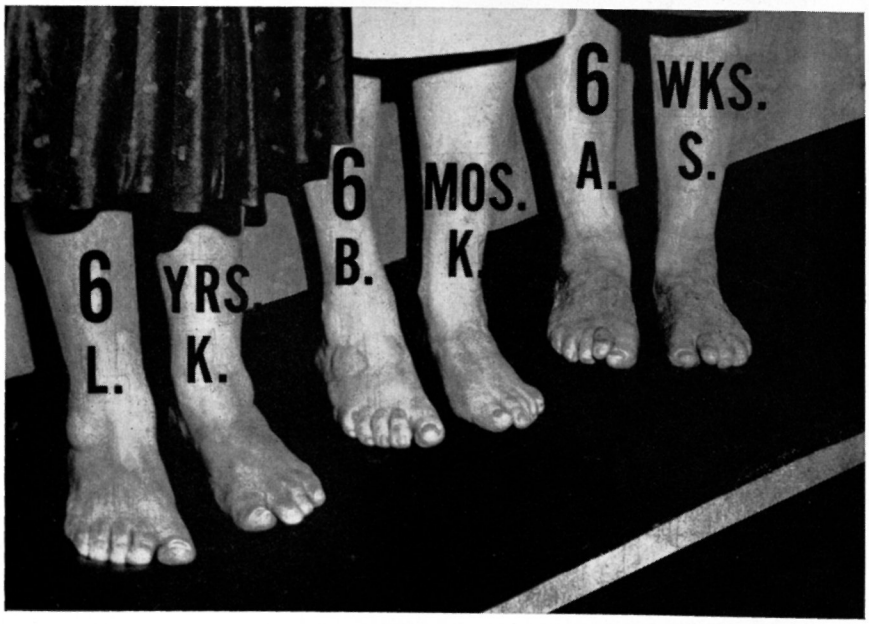

FIG. 8. Result at the time stated after operation.

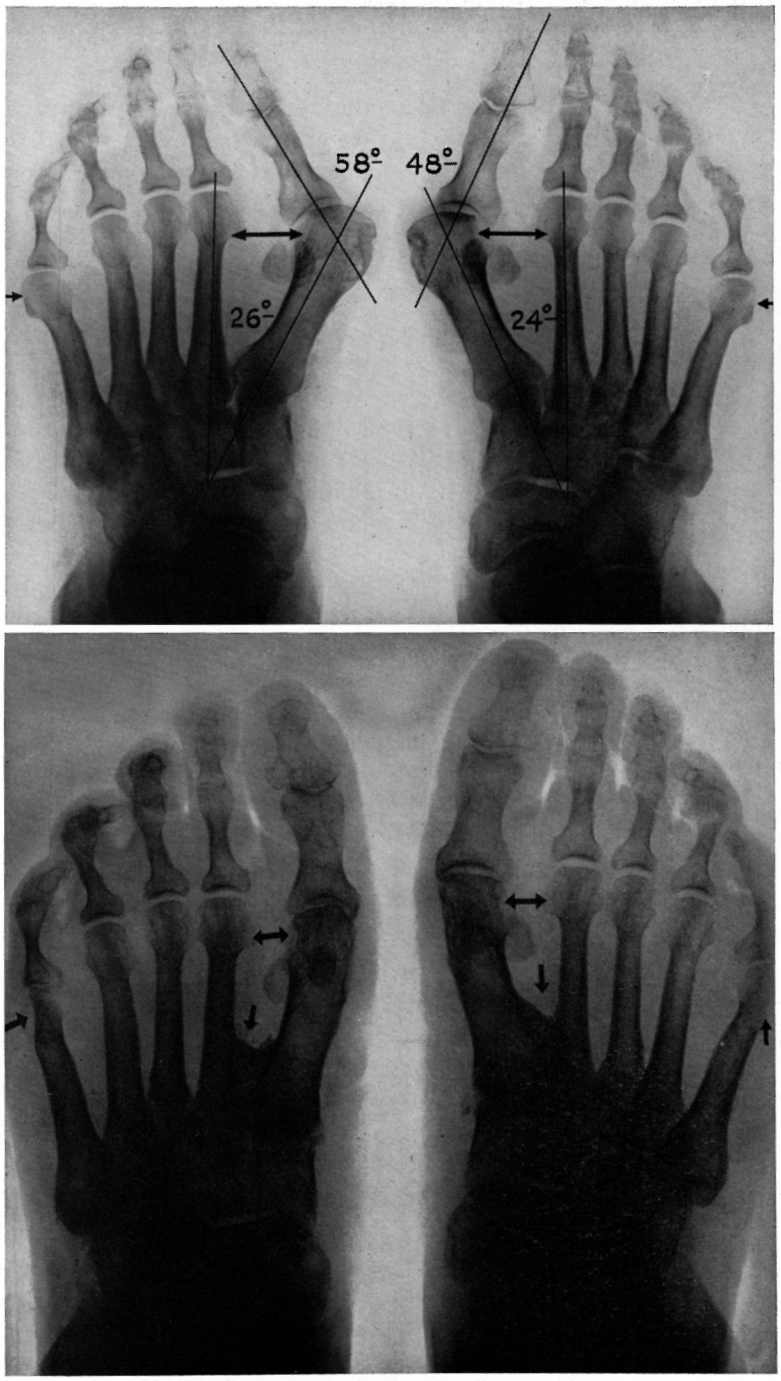

FIGS. 9 and 10, H.H., a 52-year-old female with metatarsus varus primus of 26° on the right and 24° on the left, and right hallux valgus of 48° and left of 58°. FIG. 9 (*Top*) Preoperative roentgenograms of both feet showing very marked deformity. (*Bottom*) Same feet about 2½ years after the operation performed on November 4, 1953. Note the heavy bone bridge between the first and the second metatarsals. Lateral prominence of both fifth metatarsal heads was also removed (arrow). (Lapidus, P. W.: Bull. Hosp. Joint Dis. **17**:404)

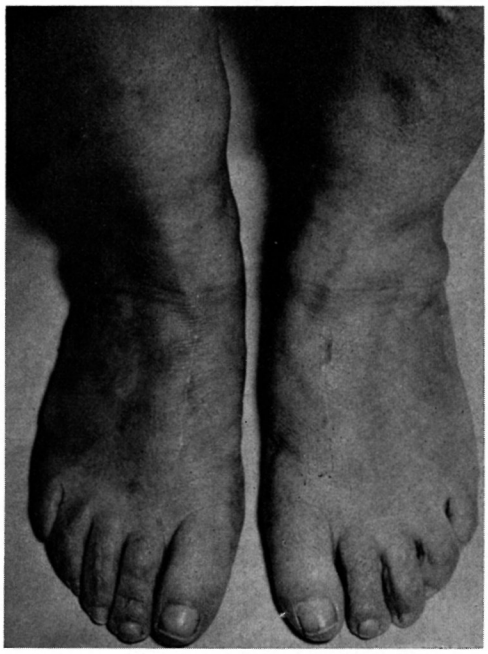

FIG. 10. Both feet on February 13, 1956, 2½ years after the operation. Patient still has very satisfactory correction at the present time. (Lapidus, P. W.: Bull. Hosp. Joint Dis. **17**:404)

(treated with antibiotics) cases. In two cases there was pressure necrosis of the soft tissue over the bunion; in one of these (not done by the author), a satisfactory result and complete healing were obtained 4 months after the operation. The second case subsequently developed involvement of the bone of the base of the proximal phalanx of one big toe that later required resection of the Keller-Brandes type. The postoperative disability lasted on and off for about 1 year, and the final result after the Keller-Brandes operation on one foot was considered to be unsatisfactory by our standards. Although we had only two cases with this complication in our large series, we recommend most careful postoperative after-care, especially during the first postoperative week. Usually we change the dressing on the second or the third postoperative day and replace carefully the steel corset stay, maintaining the big toe at 10° of varus. A great number of our patients have been able to go to the bathroom bearing weight on their heels on the second or the third postoperative day and were discharged from the hospital at the end of the first week after operation. Only a few patients required the use of crutches for the first week or two. A number of housewives were able to begin some light housework 2 or 3 weeks after the operation.

The stitches usually are removed at the end of 2 weeks, and snug bandaging and adhesive strapping across the metatarsal heads over an adequate padding are continued for about 4 to 6 weeks. The splinting of the big toes may be discontinued 3 or 4 weeks after the operation, depending on the amount of correction. During the first 2 weeks there may be slight overcorrection with a few degrees of varus of the big toe. This should not be allowed to remain permanently. Control postoperative dorsoplantar roentgenograms are taken to ascertain the amount of the approximation of the first and the second metatarsal heads and the relation of the big toe to its metatarsal. Also, they show the amount of bone bridge formation between the first and the second metatarsal bases and the degree of fusion of the first cuneiformometatarsal joint. Both are usually quite solid at the end of 3 months, with subsequent roentgenograms showing further consolidation of the intermetatarsal bridge.

At first, special canvas shoes or wool socks with leather soles are worn. During the second postoperative month, the patient may wear wide soft shoes or sandals. After

FIG. 11 (*on facing page*), C.J., a 16-year-old girl. About 2 years previously, she had been operated upon elsewhere. Bilateral osteotomy (large arrows) at the first metatarsal base was performed (Mitchell's procedure) in addition to bunionectomy; also successful correction of second and third hammertoes had been performed (arrows). There was prompt recurrence of

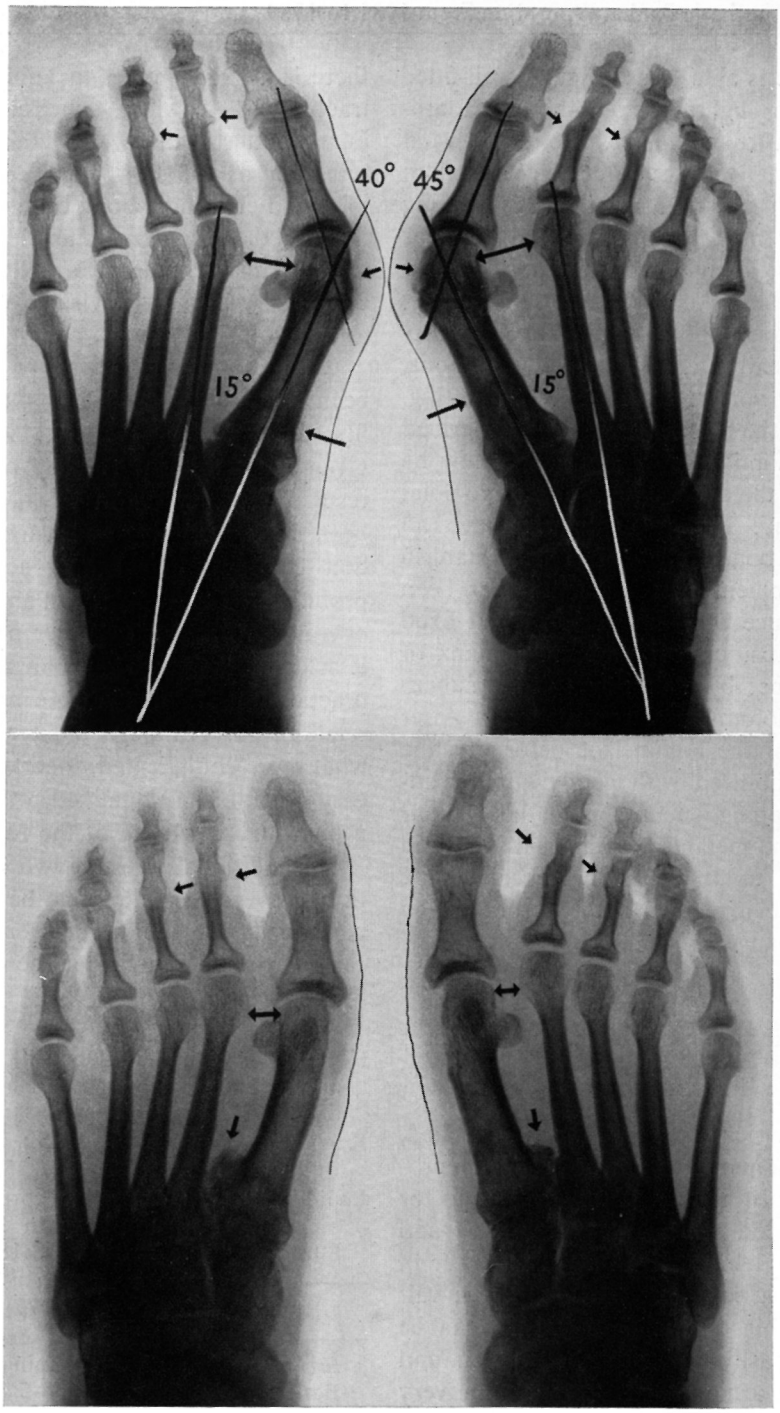

FIG. 11 (*Continued from facing page*)
bunions and extensive keloid formation over the postoperative scars (skin outline retouched over the bunions).

(*Top*) 1 year and 8 months following the first operation elsewhere. (*Bottom*) 3½ months after the second operation by the author. Note the distance between the first and the second metatarsal heads and bony bridging already present between their bases. Excellent correction is still maintained.

that time he is able to use regular well-fitted but perhaps slightly larger shoes. Housewives, as a rule, can resume their usual work about 2 months after the operation; patients having to do a great deal of walking or standing may require another week or two before going back to their 8-hour workday.

Hammertoes and overlapping hammertoes, frequently associated with bunions, usually are corrected at the same sitting. Essentially, the technic used is that described by the author in 1939, except that now he also resects the distal 3 mm. of the proximal phalanx, care being taken to remove all prominent bone edges and to establish proper alignment of the toe. He has been able to reduce the sometimes present fixed dorsal subluxation of the basal phalanx of the lesser toes by a thorough dorsal subcutaneous tenotomy and capsulotomy. After correction of the hammertoe deformity, the toe is immobilized with gently applied adhesive strapping, maintaining the plantar flexion at the metatarsophalangeal joint and dorsiflexion at the interphalangeal joints, care again being taken not to produce any ischemic changes.

SUMMARY

A very large number of our bunion cases were treated conservatively and required no surgery.

When surgical correction was indicated, we used our modification of the Silver procedure, consisting of anchoring the abductor hallucis tendon into mediocapsular flap and thereby supplying active muscular power in addition to a passive correction of the valgus of the big toe. This operation can be performed easily under local anesthesia and needs no tourniquet. It may give a very satisfactory result in cases without metatarsus varus primus or when the varus of the first metatarsal is not very extensive and is correctible.

In cases with pronounced and unreducible metatarsus varus—in other words, when there is a fixed abduction (tibialward) contracture of the first cuneiformometatarsal joint—better results were obtained following resection of the first cuneiformometatarsal joint and creating a bony bridge between the first and the second metatarsal bases in order to maintain permanent correction. This procedure is especially advisable in robust and not too old individuals.

Our present-day operative technic has been described in detail. Our operation, first performed on April 8, 1931, has been given adequate trial over the years, and our results—particularly in recent years—have been most gratifying and warrant continuation of our surgical approach in bunion problems. The popular Keller-Brandes type operation is a much simpler procedure, but it seldom, if ever, results in restoration of practically normal anatomic and functional relationship. Although our technic is somewhat more complicated, it certainly is within easy reach of any qualified orthopaedic surgeon with knowledge of the foot.

An additional week or two of postoperative recovery seems to us to be a very sound investment for the ultimate results in our cases reviewed years after the operation.

BIBLIOGRAPHY

Haines, R. W., and McDougall, A.: The anatomy of hallux valgus, J. Bone & Joint Surg. **36-B**:272-293, 1954.

Kaplan, E., and Nelson, L. S.: Hallux valgus, Bull. Hosp. Joint Dis. **3**:17-25, 1942.

Lapidus, P. W.: Operative correction of the metatarsus varus primus in hallux valgus, Surg., Gynec. & Obst. **58**:183-191, 1934.

———: Operative correction of hammer-toe, J. Bone & Joint Surg. **37**:977-982, 1939.

———: Transplantation of extensor tendon for correction of overlapping fifth toe, J. Bone & Joint Surg. **40**:555-559, 1942.

———: Anthropology and orthopaedic surgery, Bull. Hosp. Joint Dis. **11**:174-186, 1950.

———: A quarter of a century of experience with the correction of the metatarsus varus primus in hallux valgus, Bull. Hosp. Joint Dis. **17**:404-421, 1956.

Leboucq, H.: Le développement du premier

metatarsien et de son articulation tarsienne chez l'homme, Arch. biol. 3:335, 1882.
Schultz, A. H.: The skeleton of the trunk and limbs of higher primates, Human Biol. 2:303-438, 1930.
Silver, D.: The operative treatment of hallux valgus, J. Bone & Joint Surg. 21:225-234, 1923.
Straus, W. L.: Growth of the human foot and its evolutionary significance, Contrib. Embryol. 19 (No. 101):93-134, 1927.
Timmer, H.: Die Behandlung des Hallux Valgus, Leipzig, Barth, 1930.
Truslow, W.: Metatarsus primus varus or hallux valgus? J. Bone & Joint Surg. 23:98-108, 1925.

Le Operation del Autor ab 1931 Usque 1959

Summario in Interlingua

Es discutite le tractamento del tumescentia in le bursa mucose del eminentia al pollice del pede que es hic designate per le termino anglese "bunion."

Un grande numero de nostre casos de buniones esseva tractate conservatorimente e requireva nulle intervention chirurgic.

Quando un correction chirurgic esseva indicate, nos ha servite nos de nostre modification del technica de Silver que consiste in ancorar le musculo abductor del halluce in un panno del capsula medie pro provider active fortia muscular in ultra del correction passive del pollice valge. Iste operation es facile e effectuar sub anesthesia local e non require le uso de un tourniquet. Illo produce multo satisfacente resultatos in casos sin metatarso prime varo in que le aspecto var del metatarso prime non es extense e pote esser corrigite.

In casos con metatarso marcatemente e irreducibilemente var—in altere parolas: in casos con fixate contraction abductional (verso le tibia) in le prime articulation cuneiforme-metatarsal—melior resultatos esseva obtenite per primo resectionar le prime articulation cuneiforme-metatarsal e crear un ponte ossee inter le prime e le secunde base metatarsal pro assecurar le permanentia del correction. Iste technica es specialmente recommendate in subjectos robuste e de etate non troppo avantiate.

Le technica chirurgic que nos usa currentemente es describite in detalio. Nostre operation—primo effectuate le 8 de april 1931—ha essite testate satis perennemente, e nostre resultatos (particularmente in recente annos) ha essite multo incoragiante e justifica le continue uso de nostre methodo operatori in casos de bunion problematic. Le frequentemente usate typo de operation secundo Keller-Brandes es multo plus simple, sed illo resulta rarmente—si del toto—in le restauration de practicamente normal relationes anatomic e functional. Ben que nostre technica es un pauco plus complicate, illo certo non excede le capabilitates de un qualificate chirurgo orthopedic qui possede un bon cognoscentia del pede.

Un o duo septimanas additional de recuperation postoperatori impressiona nos como un molto sage investimento de tempore si on considera le ultime resultatos que nos ha obtenite per nostre methodo a judicar secundo un revista del casos annos post le execution del operation mesme.