UNITED STATES PATENT AND TRADEMARK OFFICE

BEFORE THE PATENT TRIAL AND APPEAL BOARD

PARAGON 28, INC.,
Petitioner,

v.

TREACE MEDICAL CONCEPTS, INC.
Patent Owner.

Case PGR2026-00031
Patent 12,349,941

**DECLARATION OF SYLVIA HALL-ELLIS, PH.D.
IN SUPPORT OF PETITION FOR *INTER PARTES* REVIEW OF
U.S. PATENT NO. 12,349,941**

I. INTRODUCTION

1. My name is Sylvia D. Hall-Ellis. I have been retained as an expert on behalf of Petitioners.

2. I have written this declaration to provide my expert opinion and basis for my opinion regarding the authenticity and public availability of several publications. My opinions are based on my education, experience and review of the information relevant to this matter discussed herein.

3. I reserve the right to supplement or amend my opinions, and bases for them, in response any additional evidence, testimony, discovery, argument, and/or other additional information that may be provided to me after the date of this declaration.

4. I am being compensated for my time spent working on this matter at my normal consulting rate, plus reimbursement for any additional reasonable expenses. My compensation is not in any way tied to the content of this report, the substance of my opinions, or the outcome of this proceeding. I have no other interests in this proceeding or with any of the parties.

5. All of the materials that I considered are discussed explicitly in this declaration.

II. QUALIFICATIONS

6. I am currently an Adjunct Professor in the School of Information at San José State University. I obtained a Master of Library Science from the University of North Texas in 1972 and a Ph.D. in Library and Information Science from the University of Pittsburgh in 1985. Over the last 50-plus years, I have held various positions in the field of library and information resources. I was first employed as a librarian in 1966 and have been involved in the field of library sciences since, holding numerous positions.

7. I am a member of the American Library Association (ALA) and its Association for Library Collections & Technical Services (ALCTS) Division, and I served on the Committee on Cataloging: Resource and Description (which wrote the new cataloging rules) and as the chair of the Committee for Education and Training of Catalogers and the Competencies and Education for a Career in Cataloging Interest Group. I also served as the Chair of the ALCTS Division's Task Force on Competencies and Education for a Career in Cataloging. Additionally, I have served as the Chair for the ALA Office of Diversity's Committee on Diversity, as a member of the REFORMA National Board of Directors, as a member of the Editorial Board for the ALCTS premier cataloging journal, *Library Resources and Technical Services,* as a Co-Chair of the Library Research Round Table (LRRT) for the American Library Association, and as a

member of the LRRT Nominating Committee. Currently I serve as a Member of the CORE Margaret Mann Citation Committee and as a Member of the CORE Awards & Scholarship Coordination Committee.

8. I have also given over one hundred presentations in the field, including several on library cataloging systems and Machine-Readable Cataloging ("MARC") standards. My current research interests include library cataloging systems, metadata, and organization of electronic resources.

9. My full curriculum vitae is attached hereto as Exhibit 1, and sets forth the dates for the professional positions I have held and additional information about my publications in the field of library sciences.

III. PRELIMINARIES

10. ***Scope of this declaration.*** I am not an attorney and will not offer opinions on the law. I am, however, rendering my expert opinion on the authenticity of the documents referenced herein and on when and how each of these documents was disseminated or otherwise made available to the extent that persons interested and ordinarily skilled in the subject matter or art ("POSA"), exercising reasonable diligence, could have located the documents of their respective publications below.

11. I am informed by counsel that a printed publication qualifies as publicly accessible as of the date it was disseminated or otherwise made available

such that a POSA in the relevant subject matter could locate it through the exercise of ordinary diligence.

12. While I understand that the determination of public accessibility under the foregoing standard rests on a case-by-case analysis of the facts particular to an individual publication, I also understand that a printed publication is rendered "publicly accessible" if it is cataloged and indexed by a library such that a POSA could locate it (*i.e.*, I understand that cataloging and indexing by a library is sufficient, though there are other ways that a printed publication may qualify as publicly accessible). One manner of sufficient indexing is indexing according to subject matter category. I understand that the cataloging and indexing by a single library of a single instance of a particular printed publication is sufficient, even if the single library is in a foreign country. I understand that, even if access to a library is restricted, a printed publication that has been cataloged and indexed therein is publicly accessible so long as a presumption is raised that the portion of the public concerned with the relevant subject matter would know of the printed publication. I also understand that the cataloging and indexing of information that would guide a person interested in the relevant subject matter to the printed publication, such as the cataloging and indexing of an abstract for the printed publication, is sufficient to render the printed publication publicly accessible.

13. I understand that routine business practices, such as general library cataloging and indexing practices, can be used to establish an approximate date on which a printed publication became publicly accessible.

14. ***Persons of ordinary skill in the art.*** I am told by counsel that the subject matter of this proceeding generally relates to methods and instrumentation used in bunion (foot) surgery.

15. I have been informed by counsel that a "person of ordinary skill in the art at the time of the [purported] invention" of the challenged patent is a hypothetical person who is presumed to be familiar with the relevant field and its literature at the time of the inventions. This hypothetical person is also a person of ordinary creativity, capable of understanding the scientific principles applicable to the pertinent field.

16. I am told by counsel that persons of ordinary skill in this subject matter or art would be an orthopedic surgeon or podiatrist having at least three years of experience performing foot and ankle surgery. Such a surgeon/podiatrist would also work as part of a team or consult with an engineer having a bachelor's degree in biomedical engineering, mechanical engineering, or a closely related discipline with experience designing surgical instrumentation, and who has at least three years of experience learning from these doctors about the use of such devices in foot and ankle surgeries. For individuals with different engineering

backgrounds, a person could still be of ordinary skill in the art if that person's additional experience, such as experience designing medical devices, compensates for any differences in that person's education.

17. It is my opinion that such a person would have been engaged in research, learning thorough study and practice in the field and possibly through formal instruction with the bibliographic resources relevant to his or her research. In the timeframe prior to July 2014, such a person would have had access to a vast array of long-established print resources in the area of foot surgery.

IV. LIBRARY CATALOGING PRACTICES

A. INDEXING

18. A researcher may discover material relevant to their topic in a variety of ways. A citation of a document by another is evidence that the document was publicly available and in use no later than the publication date of the citing document. One common means of discovery is to search for relevant information in an index of periodicals and other publications. Having found relevant material, the researcher will then normally obtain it online, look for it in libraries, or purchase it from a publisher, a bookstore, a document delivery service, or other provider. Sometimes, the date of a document's public accessibility will involve both indexing and library date information. However, date information for indexing entries is often unavailable. This is especially true for online indices.

19. Indexing services use a wide variety of controlled vocabularies to provide subject access and other means of discovering the content of documents. The formats in which these access terms are presented vary from service to service.

20. Online indexing services commonly provide bibliographic information, abstracts, and full-text copies of the indexed publications, along with a list of the documents cited in the indexed publication. These services also often provide lists of publications that cite a given document. A citation of a document is evidence that the document was publicly available and in use by researchers no later than the publication date of the citing document.

21. Before the widespread development of online databases to index articles in journals, magazines, conference papers, and technical reports, libraries purchased printed volumes of indices. Graduate library school education mandated that students learn about the bibliographic control of disciplines, the prominent indexing volumes, and searching strategies required to use them effectively and efficiently. Half of the courses that I studied in library school were focused on the bibliography and resources in academic disciplines.

22. Librarians consulted information seekers to verify citations, check availability in union catalogs, printed books catalogs, the OCLC database (discussed below), and make formal requests for materials (e.g., books, conference proceedings, journal articles). Requests were transmitted using Telex machines,

rudimentary email systems, and the United States Postal Service. During my career, I have performed and supervised staff who handled these resource sharing tasks.

23. A major firm known for the breadth of subjects and comprehensive treatment in the preparation of index volumes, the H. W. Wilson Company offered these reference resources since the firm was founded in 1898. The *Reader's Guide to Periodical Literature* is one of the best-known titles available from H. W. Wilson. Each volume includes a comprehensive index for 300 of the most popular and important periodicals published in the United States and Canada. Information seekers have subject access expressed in plain language terminology, author access, and cross references to find the desired results from their searches. The family of index titles included *Science & Technology Index*, *Business Periodicals*, *Applied Science & Technology Index, Humanities Index, Biological & Agricultural Index*, and *Industrial Arts Index*. These printed indices have been superseded by digital database offerings available to information seekers through Ebsco.

24. Information seekers also used printed versions of *Chemical Abstracts* and *Index Medicus* to locate articles, scientific reports, and research papers. *Chemical Abstracts* began publication in 1907 and by 2007 its databases

"contained more than 27 million records of journal and patent literature."[1] In 2010, *Chemical Abstracts* discontinued the print index. Access is now available through two electronic databases: *CAplus* and *Registry*.[2] *Index Medicus* is a bibliographic index to medical science information, started in 1879.[3] Currently, *PubMed* includes the content that had been published as *Index Medicus*.[4]

25. Established in 1836 as part of the Surgeon General of the Army's Office, the National Library of Medicine (NLM) has been instrumental in the development of access to medical books, journals, and research publications. In

---

[1] Chemical Abstracts Service, "CAS History," *available at* https://www.cas.org/about/cas-history (last accessed November 25, 2025); American Chemical Society, "Chemical Abstracts Service," *available at* https://www.acs.org/content/acs/en/education/whatischemistry/landmarks/cas.html (last accessed November 25, 2025).

[2] American Chemical Society, "Chemical Abstracts Service," *available at* https://www.acs.org/content/acs/en/education/whatischemistry/landmarks/cas.html (last accessed November 25, 2025).

[3] Stephen Greenberg and Patricia Gallagher, "The great contribution: *Index Medicus*, *Index-Catalogue*, and IndexCast," *Journal of Medical Library Association*, April 2009, available at https://www.ncbi.nlm.nih.gov/pmc/articles/PMC2670211/ (last accessed November 25, 2025).

[4] U.S. National Library of Medicine, "List of All Journals Cited in PubMed®," https://www.nlm.nih.gov/bsd/serfile_addedinfo.html (last accessed November 25, 2025).

the 1970s, NLM introduced MEDLINE, followed by "the establishment of the National Center for Biotechnology Information in 1988, the introduction of free MEDLINE in 1997, the creation of consumer-friendly MedlinePlus in 1998, and the introduction of ClinicalTrials.gov in 2000."[5]

26. Online indexing services such as Google Scholar[6] or ScienceDirect[7] commonly provide bibliographic information, abstracts, and full-text copies of the indexed publications, along with a list of the documents cited in the indexed publication. These services also often provide lists of publications that cite a given document.

27. Indexing services use a wide variety of controlled vocabularies to provide subject access and other means of discovering the content of documents. The Library of Congress Subject Authorities includes standard forms of terms and cross references that are included in bibliographic records. Subject headings are terms that an individual seeking a document regardless of format can enter in the search bar of the online catalog. Subjects also connect an authenticated term (one included in the Library of Congress subject headings list) with related, broader, and narrower terms. The formats in which these access terms are presented vary

---

[5] U.S. National Library of Medicine, "A Brief History of NLM," available at https://www.nlm.nih.gov/about/briefhistory.html

[6] https://scholar.google.com/

[7] https://www.sciencedirect.com/

from service to service.

B. MARC RECORDS AND THE ONLINE LIBRARY CATALOG

28. I am fully familiar with the library cataloging standard known as the MARC standard, which is an industry-wide standard method of storing and organizing library catalog information.[8] MARC was first developed in the 1960s by the Library of Congress. A MARC-compatible library is one that has a catalog consisting of individual MARC records for each of its items. Today, MARC is the primary communications protocol for the transfer and storage of bibliographic metadata in libraries.

29. MARC is a framework into which descriptive bibliographic data are transcribed to interact with the software in online library catalogs to provide access to books, journals, and other resources in the collection. The bibliographic data provide points of access and can be searched by a POSA (as discussed below) to identify and obtain resources in the library collection. An information seeker (or POSA) can search a local online library catalog or the holdings of a group of libraries in a state or region or in the global catalog WorldCat.

30. MARC records are not designed for public viewing. Although a significant number of libraries provide access to the MARC version of a

[8] The full text of the standard is available from the Library of Congress at http://www.loc.gov/marc/bibliographic/ (last visited November 25, 2025).

bibliographic record, the public display is designed to show information in a succinct manner that is quickly understood and useful to the information seeker. Libraries determine the default search for the online catalog to make the entry of search terms efficient and result in a successful search. Information seekers can enter a keyword, title, author, or standard number for the item. Libraries may also provide a search capability called "Summon" that allows the information seeker to enter known information about the item to conduct a search.

31. Since at least the early 1970s and continuing to the present day, MARC has been the primary communications protocol for the transfer and storage of bibliographic metadata in libraries.[9] As explained by the Library of Congress: *Why Is a MARC Record Necessary?* LIBRARY OF CONGRESS.[10]

32. Thus, almost every major library in the world is MARC-compatible. *See, e.g.*, *MARC Frequently Asked Questions (FAQ)*, LIBRARY OF CONGRESS.[11] ("MARC is the acronym for MAchine-Readable Cataloging. It defines a data

---

[9] A complete history of the development of MARC can be found in *MARC: Its History and Implications* by Henrietta D. Avram (Washington, DC: Library of Congress, 1975) and available online from the Hathi Trust (https://babel.hathitrust.org/cgi/pt?id=mdp.39015034388556;view=1up;seq=1; last visited November 25, 2025).

[10] http://www.loc.gov/marc/umb/um01to06.html#part2

[11] https://www.loc.gov/marc/faq.html

format that emerged from a Library of Congress-led initiative that began fifty years ago. It provides the mechanism by which computers exchange, use, and interpret bibliographic information, and its data elements make up the foundation of most library catalogs used today."). MARC is the ANSI/NISO Z39.2-1994 standard (reaffirmed in 2016) for Information Interchange Format. The full text of the standard is available from the Library of Congress.[12]

33. Examining the MARC records for a specific item reveals the comprehensive data transcribed about a particular item at the time that cataloging and classification occurred. In addition to the creator, title, subjects, and standard numbers, additional information may provide additional and relevant data depending on the type of resource. Understanding the full extent of bibliographic data for an item and the points of access associated with it provides essential information that can be used to determine the indexing and public availability for documents described in this declaration.

34. ***MARC records.*** A MARC record comprises several fields, each of which contains specific data about the cataloged resource. Each field is identified by a standardized, unique, three-digit code corresponding to the type of data that follow. For example, a work's title is recorded in Field 245; the primary author of the work is transcribed in Field 100; an item's International Standard Book

[12] http://www.loc.gov/marc/bibliographic/

Number ("ISBN") consisting of ten or thirteen digits is transcribed in Field 020; an item's International Standard Serial Number ("ISSN") is transcribed in Field 022; the Library of Congress classification notation is recorded in Field 050; and the publication date is recorded in Field 260 under the subfield "c." If a work is a periodical, then its publication frequency is recorded in Field 310, and the publication dates (e.g., the first and last publication) are recorded in Field 362, which is also referred to as the enumeration/chronology field.[13]

35. The library that created the record is recorded in Field 040 in subfield "a" with a unique library code. When viewing the MARC record online via Online Computer Library Center's ("OCLC") bibliographic database, I consulted the Directory of OCLC Libraries to identify the institution that created the MARC record.[14]

36. MARC records also include several fields that include subject matter classification information. An overview of MARC record fields is available through the Library of Congress.[15] For example, 6XX fields are termed "Subject Access Fields."[16] Among these, for example, is the 650 field; this is the "Subject

---

[13] http://www.loc.gov/marc/bibliographic/bd3xx.html

[14] https://www.oclc.org/en/contacts/libraries.html

[15] http://www.loc.gov/marc/bibliographic/

[16] http://www.loc.gov/marc/bibliographic/bd6xx.html

Added Entry – Topical Term" field.[17] The 650 field is a "[s]ubject added entry in which the entry element is a topical term." These entries "are assigned to a bibliographic record to provide access according to generally accepted thesaurus-building rules (e.g., *Library of Congress Subject Headings* (LCSH), *Medical Subject Headings* (MeSH))." *Id.* Further, MARC records include call numbers, which themselves include a classification number. For example, the 050 field is the "Library of Congress Call Number."[18] A defined portion of the Library of Congress Call (LCC) Number is the classification number, and "source of the classification number is *Library of Congress Classification* and the *LC Classification-Additions and Changes*." Thus, included in the 050 field is a subject matter classification. Further, the 082 field is the "Dewey Decimal Call Number."[19] A defined portion of the Dewey Decimal Call (DDC) Number is the classification number, and "source of the classification number is the *Dewey Decimal Classification and Relative Index*." Thus, included in the 082 field is a subject matter classification. Each item in a library has a single classification number. A library selects a classification scheme (*e.g.*, the Library of Congress classification scheme just described or a similar scheme such as the Dewey Decimal

[17] http://www.loc.gov/marc/bibliographic/bd650.html

[18] http://www.loc.gov/marc/bibliographic/bd050.html

[19] http://www.loc.gov/marc/bibliographic/bd082.html

classification scheme) and uses it consistently. When the Library of Congress assigns the LCC classification number, it appears as part of the 050 field. When the Library of Congress assigns the DDC classification number, it appears as part of the 082 field. If a local library assigns the classification number, it appears in a 090 field. In either scenario, the MARC record includes a classification number that represents a subject matter classification.

C. OCLC

37. The OCLC was created "to establish, maintain and operate a computerized library network and to promote the evolution of library use, of libraries themselves, and of librarianship, and to provide processes and products for the benefit of library users and libraries, including such objectives as increasing availability of library resources to individual library patrons and reducing the rate of rise of library per-unit costs, all for the fundamental public purpose of furthering ease of access to and use of the ever-expanding body of worldwide scientific, literary and educational knowledge and information."[20] Among other services, OCLC and its members are responsible for maintaining the WorldCat database (http://www.worldcat.org/), used by independent and institutional libraries

[20] Third Article, Amended Articles of Incorporation of OCLC Online Computer Library Center, Incorporated (available at https://www.oclc.org/content/dam/oclc/membership/articles-of-incorporation.pdf).

throughout the world.

38. OCLC also provides its members online access to MARC records through its OCLC bibliographic database. When an OCLC member institution acquires a work, it creates a MARC record for this work in its computer catalog system in the ordinary course of its business. MARC records created at the Library of Congress are tape-loaded into the OCLC database through a subscription to MARC Distribution Services daily or weekly. Once the MARC record is created by a cataloger at an OCLC member institution or is tape-loaded from the Library of Congress, the MARC record is then made available to any other OCLC members online and therefore made available to the public. Accordingly, once the MARC record is created by a cataloger at an OCLC member institution or is tape-loaded from the Library of Congress or another library anywhere in the world, any publication corresponding to the MARC record has been cataloged and indexed according to its subject matter such that a person interested in that subject matter could, with reasonable diligence, locate and access the publication through any library with access to the OCLC bibliographic database or through the Library of Congress.

39. When an OCLC member institution creates a new MARC record, OCLC automatically supplies the date of creation for that record. The date of creation for the MARC record appears in the Field (008), characters 00 through 05.

The MARC record creation date reflects the date on which, or shortly after which, the item was first acquired or cataloged. Initially, Field 005 of the MARC record is automatically populated with the date the MARC record was created in year, month, day format (YYYYMMDD) (some of the newer library catalog systems also include hour, minute, second (HHMMSS)). Thereafter, the library's computer system automatically updates the date in Field 005 every time the library modifies the MARC record (*e.g.*, to reflect that an item has been moved to a different shelving location within the library) and shows the most recent update and when the MARC record is printed to hardcopy—as is the case with the attachments to this declaration.

40. Once one library has cataloged and indexed a publication by creating a MARC record for that publication, other libraries that receive the publication do not create additional MARC records—the other libraries instead rely on the original MARC record. They may update or revise the MARC record to ensure accuracy, but they do not replace or duplicate it. This practice does more than save libraries from duplicating labor. It also enhances the accuracy of MARC records. Further, it allows librarians around the world to know that a particular MARC record is authoritative (in contrast, a hypothetical system wherein duplicative records were created would result in confusion as to which record is authoritative).

41. Catalogers can create MARC records for all types of print, online, and

digital resources. The date of creation of the MARC record by a cataloger at an OCLC member institution reflects when the underlying item is accessible to the public. Upwards of two-thirds to three-quarters of book sales and magazine subscriptions to libraries come from a jobber or wholesaler for online and print resources. These resellers make it their business to provide items to their customers as fast as possible, often providing turnaround times of only a single day after publication. Libraries purchase a significant portion of the balance of their books and journals directly from publishers themselves, which provide delivery on a similarly expedited schedule. In general, libraries make these purchases throughout the year and shelve the newly received items as soon thereafter as possible to make them available to their patrons. Libraries receive a significant number of serials (e.g., journals and newspapers); deliveries come every day. The goal is to receive them in acceptable condition, note the receipt, property stamp them, and place them in public areas within a short time (customarily a day or two).

42. ***Journals.*** Catalogers can create MARC records for all types of print, online, and digital resources. For example, MARC records cover serial publications, including both serially-published monographs and journals. OCLC hosts MARC records for more than 320 million serial publications. Serial publications are those publications that have the same collective title but are intended to be continued indefinitely with enumeration such as a volume or issue

number (*e.g.*, magazines, journals, etc.). In the OCLC bibliographic database, the first issue of the serial publication is typically cataloged (*i.e.*, a corresponding MARC record is created), but the date is left open-ended with the use of a punctuation mark such as a dash. OCLC serial publication MARC records represent the entire run of the serial title. With knowledge of the first issue published, future issues can be predicted based on the information provided in the MARC record, for example in field 362. In my extensive professional experience, is it highly unusual for a library to stop collecting and shelving a serial publication prior to the end of its publication run. If a subscription to a serial publication ends its run or is cancelled before the end of its run, the library will denote that it has stopped receiving new volumes by filling in the end date in the MARC record.

43. The handling of printed journal subscriptions is shown on the cover or the first few pages of individual issues. As was the best practice among libraries, issues arrived at a central facility and were immediately received, verified as part of a subscription, checked in, and stamped or labeled with the institution's name and date. Determining that the issue was part of the library subscription ensured that the entire set of publications for the year had been received so that they could be professionally bound and retained. This process also verified that all of the published issues arrived so that the library staff did not have to request or claim an issue that did not arrive as expected. In large public libraries with branches and

multi-campus libraries within academic institutions, the journals were sorted and delivered to the subscribing unit. The new issue was placed in the public area; the older issue was stored so that it remained available.

44. The foregoing process has been standard library practice longer than I have been working in the profession. I first learned the steps in the process in the late 1970s and later supervised it. Although the checking in process has become automated and now links electronically to holdings records for the MARC record for each serial title, the manual placement of a stamp or label and placing the issue in a public area has not changed for 50 years. Unless I note otherwise below in reference to a specific serial publication, it is my expert opinion that this standard protocol was followed for the serial publications discussed below, and I see no evidence to the contrary.

V. DOCUMENT 1: EXHIBIT 1005 ("DAYTON 2013")

45. Exhibit 1005 is a copy of the journal article titled "Relationship of Frontal Plane Rotation of First Metatarsal to Proximal Articular Set Angle and Hallux Alignment in Patients Undergoing Tarsometatarsal Arthrodesis for Hallux Abducto Valgus: A Case Series and Critical Review of the Literature" by Paul Dayton, Mindi Feilmeier, Merrell Kauwe, and Jordan Hirschi (hereafter "Dayton"). The Dayton article was published in Volume 52, Number 3 of the *Journal of Foot and Ankle Surgery* and I retrieved from the Mayo Clinic Libraries (Rochester,

Minnesota). The Mayo Clinic Libraries do not share their online catalogs outside of the organization. Exhibit 1005 is a true and correct copy in a condition that creates no suspicion about its authenticity. The Dayton article appears beginning on page 348 of this issue dated May-June 2013. Exhibit 1005 is a true and correct copy of the Dayton article (pages 348-354) that I understand is being submitted as an exhibit in this proceeding. Specifically, the text of the article is complete; no pages are missing, and the text on each page appears to flow seamlessly from one page to the next; further, there are no visible alterations to the document.

46. The Dayton article is available from the publisher, Elsevier, and lists an online publication date of March 5, 2013.[21]

47. Attached hereto as Attachment 1A is a true and correct copy of the MARC record for the *Journal of Foot and Ankle Surgery* obtained from the OCLC bibliographic database. As previously noted, the library that created the record is recorded in field 040 with a unique library code. For Attachment 1A, that library code is "NSD," which means that the MARC record for this serial was cataloged as part of the National Serials Data Program at the Library of Congress. As can be seen in field 008 ("Date entered on file") in the MARC record for this exhibit, a cataloger at the Library of Congress created OCLC record number 27182191 on December 30, 1992 ("921230"). The library continues to update and enhance this

[21] https://www.sciencedirect.com/science/article/abs/pii/S1067251613000227

MARC record to meet current cataloging rules. The most recent enhancement to Attachment 1A occurred on November 5, 2025, as shown in field 005 (20251105"). I personally identified and retrieved the MARC record that is Attachment 1A. The "BLvl" entry in Attachment 1A is "s," which indicates that the *Journal of Foot and Ankle Surgery* is a serial publication. Field 310 of Attachment 1A reads "Bimonthly." Accordingly, the MARC record for Exhibit 1005 corresponds to the *Journal of Foot and Ankle Surgery* from the time the serial adopted the current title and includes the date of the Dayton article.[22]

48. Attachment 1A includes an entry in field 050 ("RD560")—as described above, a subject matter classification number consistent with the Library of Congress classification system (analogous to the Dewey Decimal classification system), an entry in field 060 ("W1 $b JO652S"), a subject matter consistent with the National Library of Medicine classification system (analogous to the Dewey Decimal classification system), and an entry in field 082 ("617"), a subject matter consistent with the Dewey Decimal classification system. Attachment 1A includes four descriptor terms reading "Ankle $x Surgery $v Periodicals" (see Attachment 1B, Library of Congress subject heading sh85005320 and Attachment 1C, Library

[22] The publication was originally titled the *Journal of the American College of Foot Surgeons* (January 1962-December 1966), changed the title to *Journal of Foot Surgery* (January 1967-December 1992), and adopted the current title, *Journal of Foot and Ankle Surgery*, in January 1993.

of Congress subject heading sh85099890), "Foot $x Surgery $v Periodicals" (see Attachment 1D, Library of Congress subject heading sh85050391 and Attachment 1C, Library of Congress subject heading sh85099890), "Ankle $x surgery" (see Attachment 1E, National Library of Medicine subject heading D000842), and "Foot $x surgery" (see Attachment 1F, National Library of Medicine subject heading D005528) in the 650 fields. Thus, as of its cataloging, the publication corresponding to the MARC record attached hereto as Attachment 1A was indexed according to its subject matter by virtue of at least four independently sufficient classifications: the field 050 entry, the field 060 entry, the field 082 entry, and the field 650 entries. As of December 30, 1992, the MARC record attached hereto as Attachment 1A was accessible through any library with access to the OCLC bibliographic database or the online catalog at a library that subscribed to the serial, which means that the corresponding publication was publicly available on or before that same date through any library with access to the OCLC bibliographic database or through an individual library.

49. WorldCat indicates that the *Journal of Foot and Ankle Surgery* as cataloged at the Library of Congress is currently available from 1,145 libraries.[23] In view of the above, this issue of the *Journal of Foot and Ankle Surgery* was publicly available on or shortly after March 5, 2013, because by that date it had

[23] https://search.worldcat.org/title/27182191

been cataloged and indexed at the Library of Congress, made part of the OCLC bibliographic database, and received at the Mayo Clinic Libraries. For these reasons, it is my opinion that Exhibit 1005 was published and accessible to the public on or shortly after March 5, 2013.

50. In addition to library records, the fact that the Dayton article was cited in other works that were electronically published and published in paper copy prior to July 2014 supports its public availability:

a. For example, Exhibit 1005 is reference 4 in the article titled "Observed Changes in Radiographic Measurements of the First Ray After Frontal Plane Rotation of the First Metatarsal in a Cadaveric Foot Model" by P. Dayton, et al., published in the *Journal of Foot and Ankle Surgery*, volume 53, number 3, May-June 2014, pp. 274-278. PMID 24560551, doi: 10.1053/j.jfas.2014.01.002. Electronically published on: 2014 Feb 20.

VI. DOCUMENT 2: EXHIBIT 1011 ("MCGLAMRY, 4TH EDITION 2012")

51. Exhibit 1011 is a set of excerpts from the book published in two volumes titled *McGlamry's Comprehensive Textbook of Foot and Ankle Surgery*, 4th edition, edited by E. Dalton McGlamry, Joe T. Southerland, and Daniel F. Vickers (hereafter "McGlamry") and issued by Wolters Kluwer Health in 2013. Exhibit 1011 is a true and correct copy of the cover, title page, copyright page, table of contents, the preface and the following five chapters: Chapter 1,

"Instrumentation" by D. Scot Malay and Robyn Winner (pp. 3-14); Chapter 31, "Lapidus Bunionectomy: First Metatarsal-Cuneiform Arthrodesis" by Lawrence A. DiDomenico and M. Wargo-Dorsey (pp. 322-330); Chapter 34, "First Metatarsophalangeal Joint Arthroplasty" by John V. Vanore, William G. Montross, A. Louis Jimenez, and Jonnica S. Dozier (pp. 400-416); Chapter 36, "Complications in Hallux Abducto Valgus Surgery (Excluding Hallux Varus)" by Molly A. Judge (pp. 417-460); and, Chapter 55, "Principles of Arthrodesis" by Sean Patrick Dunn, Justin T. Meyer, and John A. Ruch (pp. 803-809). I obtained Exhibit 1011 from counsel and compared it with the McGlamry two-volume set held by the National Library of Medicine. I matched the ISBN numbers and other information in Exhibit 1011 with those from the National Library of Medicine. The text of the excerpts that make up Exhibit 1011 are complete; no pages are missing from each section, and the text on each page appears to flow seamlessly from one page to the next; further, there are no visible alterations to the document. Exhibit 1011 is a true and correct copy in a condition that creates no suspicion about its authenticity.

52. Attached hereto as Attachment 2A is a true and correct copy of the MARC record for this two-volume book from the National Library of Medicine online catalog. The library ownership is indicated by the presence of the library's code ("DNLM") in field 935. The library continues to update and enhance the

MARC record to meet current cataloging rules. The most recent enhancement to the MARC record occurred on December 4, 2021, as shown in field 005 ("20211204"). I personally identified and retrieved the library catalog record which is Attachment 2A.

53. The International Standard Book Number (ISBN) on Exhibit 1011 (978-0-07817-6580-0) matches the ISBN in field 020 of Attachment 2A. Therefore, Exhibit 1011 is excerpted from the same two-volume book as the one that the cataloger at the National Library of Medicine used to create the MARC record that is Attachment 2A. Therefore, the two-volume book titled *McGlamry's Comprehensive Textbook of Foot and Ankle Surgery*, 4th edition was present and cataloged in the Library of Congress for the National Library of Medicine as shown in field 008 ("Date entered on file") on December 15, 2012 ("1212115"). Therefore, a person of ordinary skill in the art would have been able to locate the McGlamry two-volume book by using the library catalog system as of this date.

54. Attached hereto as Attachment 2B is a true and correct copy of the MARC record for the McGlamry two-volume book titled *McGlamry's Comprehensive Textbook of Foot and Ankle Surgery*, 4th edition, obtained from the OCLC bibliographic database. I personally identified and retrieved the MARC record that is Attachment 2B. As previously noted, the library that created the record is recorded in field 040 with a unique library code. For Attachment 2B, that

library code is "DNLM/DLC," which means that the MARC record for this book was created at the Library of Congress as part of the Cataloging in Publication (CIP) Program.[24] A cataloger prepares basic information about the forthcoming book which is included on the verso of the title page (also called the copyright page). The information is provided to save time needed for the cataloging process at the library after the book is purchased. The CIP data includes the author (field 100), title and subtitle (field 245), ISBN (field 020), suggested subject headings (field 650), classification numbers for the Library of Congress classification number (field 050), and the Dewey Decimal classification number (field 082). These data elements are included in the MARC record that the Library of Congress contributes to the OCLC bibliographic database (see Attachment 2B). As can be seen in field 008 ("Date entered on file") of the MARC record for this exhibit, a cataloger at the Library of Congress created OCLC record number 777364374 on February 15, 2012 ("120215"). The library continues to update and enhance this MARC record to meet current cataloging rules. The most recent enhancement to Attachment 2B occurred on December 4, 2021, as shown in field 005 ("20211204").

55. Attachment 2B further includes an entry in field 050 ("RD563 $b .C657 2013")—as described above, this includes a subject matter classification

[24] https://www.loc.gov/publish/cip/

number consistent with the Library of Congress classification system (analogous to the Dewey Decimal classification system), an entry in field 060 ("WE880 $b M478 2013")—as described above, this includes a subject matter classification number consistent with the National Library of Medicine classification system (analogous to the Dewey Decimal classification system), and an entry in field 082 ("617.5/85059"), a subject matter consistent with the Dewey Decimal classification system. Attachment 2B further includes eight descriptor terms reading "Foot $x Surgery" (see Attachment 1D, Library of Congress subject heading sh85050391), "Ankle $x Surgery" (see Attachment 1B, Library of Congress subject heading sh85005320), "Foot $x Wounds and injuries $x Surgery" (see Attachment 2C, Library of Congress subject heading sh85050397), "Ankle $x Wounds and injuries $x Surgery" (see Attachment 2D, Library of Congress subject heading sh85005321 and Attachment 2E, Library of Congress subject heading sh85130766), "Foot $x surgery" (see Attachment 1F, National Library of Medicine subject heading D005528), "Ankle $x surgery" (see Attachment 1E, National Library of Medicine subject heading D000842), "Foot Deformities $x surgery" (see Attachment 2F, National Library of Medicine subject heading D005530), and "Foot Injuries $x surgery" (see Attachment 2G, National Library of Medicine subject heading D018409) in the 650 fields. Thus, as of its cataloging, the publication corresponding to the MARC record attached hereto as Attachment 2B was indexed

according to its subject matter by virtue of at least four independently sufficient classifications: the field 050 entry, the field 060 entry, the field 082 entry, and the field 650 entries. Further, as of February 15, 2012, the MARC record attached hereto as Attachment 2B was accessible through any library with access to the OCLC bibliographic database or the online catalog at a library that added this two-volume book to its collection, which means that the corresponding publication was publicly available on or before that same date through any library with access to the OCLC bibliographic database or through an individual library.

56. Further supporting my opinion that Exhibit 1011 was publicly accessible to ordinarily skilled and interested researchers in the field is the fact that the two-volume book titled *McGlamry's Comprehensive Textbook of Foot and Ankle Surgery*, 4th edition, was registered with the U. S. Copyright Office as item TX0007719465 on April 9, 2013, and indicated a publication date of November 9, 2012 (see Attachment 2H, U. S. Copyright Office Public Catalog). As noted above, this would have provided a POSA with keyword searching capabilities and other tools to locate this book.

57. WorldCat indicates that the two-volume book titled *McGlamry's Comprehensive Textbook of Foot and Ankle Surgery*, 4th edition, as cataloged at the Library of Congress is currently available from 367 libraries.[25] In view of above,

[25] https://search.worldcat.org/title/777364374

the McGlamry two-volume book was publicly available on or shortly after November 9, 2012, because by that date it had been cataloged and indexed at the Library of Congress, made part of the OCLC bibliographic database, and received in the National Library of Medicine. For these reasons, it is my opinion that Exhibit 1007 was published and accessible to the public on or shortly after November 9, 2012.

VII. DOCUMENT 3: EXHIBIT 1016 ("COTTOM")

58. Exhibit 1016 is a copy of the journal article titled "Fixation of Lapidus Arthrodesis with a Plantar Interfragmentary Screw and Medial Locking Plate: A Report of 88 Cases" by James M. Cottom and Anand M. Vora (hereafter "Cottom"). The Cottom article was published in Volume 52, Number 4 of *The Journal of Foot & Ankle Surgery* and I retrieved from the Mayo Clinic Libraries (Rochester, Minnesota). Exhibit 1016 is a true and correct copy in a condition that creates no suspicion about its authenticity. The Cottom article appears beginning on page 465 of this issue dated July-August 2013. Exhibit 1016 is a true and correct copy of the Cottom article (pages 465-469) that I understand is being submitted as an exhibit in this proceeding. Specifically, the text of the article is complete; no pages are missing, and the text on each page appears to flow seamlessly from one page to the next; further, there are no visible alterations to the document.

59. The Cottom article is available from the publisher, Elsevier and lists an online publication date of May 24, 2012.[26]

60. Attached hereto as Attachment 9A is a true and correct copy of the MARC record for *The Journal of Foot & Ankle Surgery* obtained from the OCLC bibliographic database. As previously noted, the library that created the record is recorded in field 040 with a unique library code. For Attachment 9A, that library code is "NSD," which means that the MARC record for this serial was cataloged as part of the National Serials Data Program at the Library of Congress. As can be seen in field 008 ("Date entered on file") in the MARC record for this exhibit, a cataloger at the Library of Congress created OCLC record number 27182191 on December 30, 1992 ("921230"). The library continues to update and enhance this MARC record to meet current cataloging rules. The most recent enhancement to Attachment 9A occurred on November 5, 2025, as shown in field 005 (20251105"). I personally identified and retrieved the MARC record that is Attachment 9A. The "BLvl" entry in Attachment 9A is "s," which indicates that *The Journal of Foot & Ankle Surgery* is a serial publication. Field 310 of Attachment 9A reads "Bimonthly." Accordingly, the MARC record for Exhibit 1016 corresponds to *The Journal of Foot & Ankle Surgery* from the time the serial

[26] https://www.sciencedirect.com/science/article/abs/pii/S1067251612001779

adopted the current title and includes the date of the Cottom article.[27]

61. Attachment 9A includes an entry in field 050 ("RD560")—as described above, a subject matter classification number consistent with the Library of Congress classification system (analogous to the Dewey Decimal classification system), an entry in field 060 ("W1 $b JO652S"), a subject matter consistent with the National Library of Medicine classification system (analogous to the Dewey Decimal classification system), and an entry in field 082 ("617"), a subject matter consistent with the Dewey Decimal classification system. Attachment 9A includes four descriptor terms reading "Ankle $x Surgery $v Periodicals" (see Attachment 1B, Library of Congress subject heading sh85005320 and Attachment 1C, Library of Congress subject heading sh85099890), "Foot $x Surgery $v Periodicals" (see Attachment 1D, Library of Congress subject heading sh85050391 and Attachment 1C, Library of Congress subject heading sh85099890), "Ankle $x surgery" (see Attachment 1E, National Library of Medicine subject heading D000842), and "Foot $x surgery" (see Attachment 1F, National Library of Medicine subject heading D005528) in the 650 fields. Thus, as of its cataloging, the publication corresponding to the MARC record attached hereto as Attachment 9A was indexed

[27] The publication was originally titled the *Journal of the American College of Foot Surgeons* (January 1962-December 1966), changed the title to *Journal of Foot Surgery* (January 1967-December 1992), and adopted the current title, *The Journal of Foot & Ankle Surgery*, in January 1993.

according to its subject matter by virtue of at least four independently sufficient classifications: the field 050 entry, the field 060 entry, the field 082 entry, and the field 650 entries. As of December 30, 1992, the MARC record attached hereto as Attachment 9A was accessible through any library with access to the OCLC bibliographic database or the online catalog at a library that subscribed to the serial, which means that the corresponding publication was publicly available on or before that same date through any library with access to the OCLC bibliographic database or through an individual library.

62. WorldCat indicates that *The Journal of Foot & Ankle Surgery* as cataloged at the Library of Congress is currently available from 1,145 libraries.[28] In view of the above, this issue of *The Journal of Foot & Ankle Surgery* was publicly available on or shortly after May 24, 2012, because by that date it had been cataloged and indexed at the Library of Congress, made part of the OCLC bibliographic database, and received at the Mayo Clinic Libraries. For these reasons, it is my opinion that Exhibit 1016 was published and accessible to the public on or shortly after May 24, 2012.

63. In addition to library records, the fact that the Cottom article was cited in other works that were electronically published and published in paper copy prior to July 2014 supports its public availability:

[28] https://search.worldcat.org/title/27182191

a. For example, Exhibit 1016 is reference 27 in: Schmid, Timo, and Fabian Krause. "The Modified Lapidus Fusion." Foot and Ankle Clinics, vol. 19, no. 2 (June 2014): 223-233. The Schmid article is available from the publisher, Elsevier, and through the National Library of Medicine. The publisher's website indicates that the Schmid article was available online on March 21, 2014.[29]

VIII. DOCUMENT 4: EXHIBIT 1017 ("BARAVARIAN")

64. Exhibit 1017 is a copy of the journal article titled "Lapidus Bunionectomy: Arthrodesis of the First Metatarsocunieform Joint" by Babak Baravarian, Gary B. Briskin, and Patrick Burns (hereafter "Baravarian"). The Baravarian article was published in Volume 21, Number 1 of the journal *Clinics in Podiatric Medicine and Surgery of North America* and I retrieved from the Library of Congress. Exhibit 1017 is a true and correct copy in a condition that creates no suspicion about its authenticity. The Baravarian article appears beginning on page 97 of this issue dated January 2004. Exhibit 1017 is a true and correct copy of the Baravarian article (pages 97-111) that I understand is being submitted as an exhibit in this proceeding. Specifically, the text of the article is complete; no pages are missing, and the text on each page appears to flow seamlessly from one page to the next; further, there are no visible alterations to the document.

[29] https://pubmed.ncbi.nlm.nih.gov/24878411/

65. The Baravarian article is available from the publisher, Elsevier,[30] and through the National Library of Medicine.[31]

66. Attached hereto as Attachment 6A is a true and correct copy of the MARC record for the journal *Clinics in Podiatric Medicine and Surgery of North America* from the Library of Congress online catalog. Library ownership is indicated by the presence of the library's code ("SERLOC") in field 992. The library continues to update and enhance this MARC record to meet current cataloging rules. The most recent enhancement to Attachment 6A occurred on November 7, 2025, as shown in field 005 ("20251107"). I personally identified and retrieved the MARC record that is Attachment 6A.

67. Based on finding a print copy of Exhibit 1017 in the Library of Congress and MARC record in its online library catalog attached as Attachment 6A, it is my opinion that the Baravarian article published in journal *Clinics in Podiatric Medicine and Surgery of North America* was publicly available on or shortly after March 12, 2004, as shown by the stamp on page 3 of Exhibit 1017. In common practice these stamps are applied at or around the time the volume is entered into the library's collection and the volume is made available to library

---

30 https://www.sciencedirect.com/science/article/abs/pii/S0891842203001125?via%3Dihub

31 https://pubmed.ncbi.nlm.nih.gov/15012034/

patrons within a short time thereafter.

68. Attachment 6A includes an entry in field 050 ("RD563 $b .C63")—as described above, a subject matter classification number consistent with the Library of Congress classification system (analogous to the Dewey Decimal classification system), an entry in field 060 ("W1 $b CL831DE")—as described above, a subject matter classification number consistent with the National Library of Medicine classification system (analogous to the Dewey Decimal classification system), and an entry in field 082 ("617/.585/005")—as described above, a subject matter classification number consistent with the Dewey Decimal classification system. Attachment 6A also shows that Exhibit 1017 was catalogued with four descriptor terms reading "Podiatry $v Periodicals" (see Attachment 3B, Library of Congress subject heading sh85103669 and Attachment 1C, Library of Congress subject heading sh85099890), "Foot $x Surgery $v Periodicals" (see Attachment 1D, Library of Congress subject heading sh85050391 and Attachment 1C, Library of Congress subject heading sh85099890), "Podiatry" (see Attachment 3C, National Library of Medicine subject heading D011032), and "Foot $x surgery" (see Attachment 1F, National Library of Medicine subject heading D005528) in the 650 fields.

69. As noted in the holdings information (362 field), the Library of Congress has received the journal *Clinics in Podiatric Medicine and Surgery of*

North America since January 1986 and continues to receive the publication. In view of the MARC record for Exhibit 1017, the Baravarian article was publicly available on or shortly after March 12, 2004, because the serial title had been received, cataloged, and indexed in the Library of Congress and made part of its online catalog database.

70. Attached hereto as Attachment 6B is a true and correct copy of the MARC record for the journal *Clinics in Podiatric Medicine and Surgery* obtained from the OCLC bibliographic database. As previously noted, the library that created the record is recorded in field 040 with a unique library code. For Attachment 6B, that library code is "CLU," which means that the MARC record for this serial was cataloged at the University of California – Los Angeles Libraries. As can be seen in field 008 ("Date entered on file") in the MARC record for this exhibit, a cataloger at the University of California – Los Angeles Libraries created OCLC record number 13324960 on March 21, 1986 ("860321"). The library continues to update and enhance this MARC record to meet current cataloging rules. The most recent enhancement to Attachment 6B occurred on November 5, 2025, as shown in field 005 ("20251105"). I personally identified and retrieved the MARC record that is Attachment 6B. The "BLvl" entry in Attachment 6B is "s," which indicates that the journal *Clinics in Podiatric Medicine and Surgery* is a serial publication. Field 310 of Attachment 6B reads

"Quarterly." Accordingly, the MARC record for Exhibit 1017 corresponds to the journal *Clinics in Podiatric Medicine and Surgery of North America* from the time the serial adopted the current title and includes the date of the Baravarian article.[32]

71. Attachment 6B includes an entry in field 050 ("RD563 $b .C63")—as described above, a subject matter classification number consistent with the Library of Congress classification system (analogous to the Dewey Decimal classification system), an entry in field 060 ("W1 $b CL831DE"), a subject matter consistent with the National Library of Medicine classification system (analogous to the Dewey Decimal classification system), and an entry in field 082 ("617/.585/005"), a subject matter consistent with the Dewey Decimal classification system. Attachment 6B includes four descriptor terms reading "Podiatry $v Periodicals" (see Attachment 3B, Library of Congress subject heading sh85103669 and Attachment 1C, Library of Congress subject heading sh85099890), "Foot $x Surgery $v Periodicals" (see Attachment 1D, Library of Congress subject heading sh85050391 and Attachment 1C, Library of Congress subject heading sh85099890), "Podiatry" (see Attachment 3C, National Library of Medicine subject heading D011032), and "Foot $x surgery" (see Attachment 1F, National

[32] The publication was originally titled *Clinics in Podiatry* (April 1984-October 1985) and adopted the current title, *Clinics in Podiatric Medicine and Surgery*, in January 1986.

Library of Medicine subject heading D005528) in the 650 fields. Thus, as of its cataloging, the publication corresponding to the MARC record attached hereto as Attachment 6B was indexed according to its subject matter by virtue of at least four independently sufficient classifications: the field 050 entry, the field 060 entry, the field 082 entry, and the field 650 entries. As of March 21, 1986, the MARC record attached hereto as Attachment 6B was accessible through any library with access to the OCLC bibliographic database or the online catalog at a library that subscribed to the serial, which means that the corresponding publication was publicly available on or before that same date through any library with access to the OCLC bibliographic database or through an individual library.

72. WorldCat indicates that the journal *Clinics in Podiatric Medicine and Surgery* as cataloged at the University of California—Los Angeles Libraries is currently available from 506 libraries.[33] In view of the above, this issue of the journal *Clinics in Podiatric Medicine and Surgery of North America* was publicly available on or shortly after March 12, 2004, because by that date it had been cataloged and indexed at the University of California – Los Angeles Libraries, made part of the OCLC bibliographic database, and received at the Library of Congress. For these reasons, it is my opinion that Exhibit 1017 was published and accessible to the public on or shortly after March 12, 2004.

[33] https://search.worldcat.org/title/13324960

73. In addition to library records, the fact that the Baravarian article was cited in other works that were electronically published and published in paper copy prior to July 2014 supports its public availability:

a. For example, Exhibit 1017 is reference 48 in: Exhibit 1011 (McGlamry, Chpt. 31, p. 330) published in 2012.

IX. DOCUMENT 5: EXHIBIT 1018 ("LAPIDUS 1960")

74. Exhibit 1018 is a copy of the journal article titled "The Author's Bunion Operation From 1931 to 1959" by Paul W. Lapidus (hereafter "Lapidus 1960"). The Lapidus 1960 article was published in Volume 16 of the journal *Clinical Orthopaedics* and I retrieved from the Ebling Health Sciences Library at the University of Wisconsin – Madison. Exhibit 1018 is a true and correct copy in a condition that creates no suspicion about its authenticity. The Lapidus 1960 article appears beginning on page 119. Exhibit 1018 is a true and correct copy of the Lapidus 1960 article (pages 119-135) that I understand is being submitted as an exhibit in this proceeding. Specifically, the text of the article is complete; no pages are missing, and the text on each page appears to flow seamlessly from one page to the next; further, there are no visible alterations to the document.

75. The Lapidus 1960 article is available through the National Library of Medicine.[34]

[34] https://pubmed.ncbi.nlm.nih.gov/14414101/

76. Attached hereto as Attachment 4A is a true and correct copy of the MARC record for the journal *Clinical Orthopaedics* from the Ebling Health Sciences Library at the University of Wisconsin – Madison online catalog. Library ownership is indicated by the presence of the library's name at the top of the page. The library continues to update and enhance this MARC record to meet current cataloging rules. The most recent enhancement to Attachment 4A occurred on September 27, 2025, as shown in field 005 ("20250927"). I personally identified and retrieved the MARC record that is Attachment 4A.

77. Based on finding a print copy of Exhibit 1018 in the Ebling Health Sciences Library at the University of Wisconsin—Madison and MARC record in its online library catalog attached as Attachment 4A, it is my opinion that the Lapidus 1960 article published in journal *Clinical Orthopaedics* was publicly available on or shortly after April 30, 1960.[35]

78. Attachment 4A includes an entry in field 050 ("RD701 $b .C55")—as described above, a subject matter classification number consistent with the Library

[35] The journal *Clinical Orthopaedics* was published quarterly and, therefore, new issues were available approximately 90 days. Based on the frequency of publication (see Exhibit 1020, page 2) and my years of experience working with serials, it is my opinion that issues would be published by the end of the first month in the quarter named on the issue. Therefore, a public availability date of April 30, 1960, is reasonable.

of Congress classification system (analogous to the Dewey Decimal classification system), an entry in field 060 ("W1 $b CL761")—as described above, a subject matter classification number consistent with the National Library of Medicine classification system (analogous to the Dewey Decimal classification system), and an entry in field 082 ("617.47")—as described above, a subject matter classification number consistent with the Dewey Decimal classification system. Attachment 4A also shows that Exhibit 1018 was catalogued with four descriptor terms reading "Orthopedics $v Periodicals" (see Attachment 4B, Library of Congress subject heading sh2010104613), "Orthopedic surgery $v Periodicals" (see Attachment 4C, Library of Congress subject heading sh85095812 and Attachment 1C, Library of Congress subject heading sh85099890), "Bone and Bones $v periodical" (see Attachment 4D, National Library of Medicine subject headings D001842), and "Orthopedics $v periodical" (see Attachment 4E, National Library of Medicine subject heading D009985) in the 650 fields.

79. As noted in the holdings information (362 field), the Ebling Health Sciences Library at the University of Wisconsin – Madison has received the journal *Clinical Orthopaedics* since 1953 and continues to receive the publication. In view of the MARC record for Exhibit 1018, the Lapidus 1960 article was publicly available on or shortly after April 30, 1960, because the serial title had been received, cataloged, and indexed in the Ebling Health Sciences Library at the

University of Wisconsin – Madison and made part of its online catalog database.

80. Attached hereto as Attachment 4F is a true and correct copy of the MARC record for the journal *Clinical Orthopaedics* obtained from the OCLC bibliographic database. As previously noted, the library that created the record is recorded in field 040 with a unique library code. For Attachment 4F, that library code is "DLC," which means that the MARC record for this serial was cataloged at the Library of Congress. As can be seen in field 008 ("Date entered on file") in the MARC record for this exhibit, a cataloger at the Library of Congress created OCLC record number 1778089 on November 1, 1975 ("751101"). The library continues to update and enhance this MARC record to meet current cataloging rules. The most recent enhancement to Attachment 4F occurred on November 5, 2025, as shown in field 005 ("20251105"). I personally identified and retrieved the MARC record that is Attachment 4F. The "BLvl" entry in Attachment 4F is "s," which indicates that the journal *Clinical Orthopaedics* is a serial publication. Accordingly, the MARC record for Exhibit 1018 corresponds to the journal *Clinical Orthopaedics* and includes the date of the Lapidus 1960 article.[36]

81. Attachment 4F includes an entry in field 050 ("RD701 $b .C55")—as

[36] The publication was originally titled *Clinical Orthopaedics* (January 1953-December 1962) and adopted the current title, *Clinical Orthopaedics and Related Research*, in January 1963.

described above, a subject matter classification number consistent with the Library of Congress classification system (analogous to the Dewey Decimal classification system) and an entry in field 060 ("W1 $b CL761"), a subject matter consistent with the National Library of Medicine classification system (analogous to the Dewey Decimal classification system). Attachment 4F includes three descriptor terms reading "Orthopedics $v Periodicals" (see Attachment 4B, Library of Congress subject heading sh2010104613), "Bone and Bones" (see Attachment 4D, National Library of Medicine subject headings D001842), and "Orthopedics" (see Attachment 4E, National Library of Medicine subject heading D009985) in the 650 fields. Thus, as of its cataloging, the publication corresponding to the MARC record attached hereto as Attachment 4F was indexed according to its subject matter by virtue of at least three independently sufficient classifications: the field 050 entry, the field 060 entry, and the field 650 entries. As of November 1, 1975, the MARC record attached hereto as Attachment 4F was accessible through any library with access to the OCLC bibliographic database or the online catalog at a library that subscribed to the serial, which means that the corresponding publication was publicly available on or before that same date through any library with access to the OCLC bibliographic database or through an individual library.

82. WorldCat indicates that the journal *Clinical Orthopaedics* as

cataloged at the Library of Congress is currently available from 520 libraries.[37] In view of the above, this issue of the journal *Clinical Orthopaedics* was publicly available on or shortly after April 30, 1960, because by that date it had been cataloged and indexed at the Library of Congress, made part of the OCLC bibliographic database, and received at the Ebling Health Sciences Library at the University of Wisconsin — Madison. For these reasons, it is my opinion that Exhibit 1018 was published and accessible to the public on or shortly after April 30, 1960.

83. In addition to library records, the fact that the Lapidus 1960 article was cited in other works that were electronically published and published in paper copy prior to July 2014 supports it public availability:

a. For example, Lapidus 1960 Exhibit 1018 is reference 19 in: Exhibit 1011 (McGlamry, Chpt. 31, p. 329) published in 2012;

b. Exhibit 1018 is also reference 16 in: Exhibit 1020 (Hofbauer) published in 1996; and

c. Exhibit 1018 is reference 12 in Exhibit 1016 (Cottom) published in 2013.

X. DOCUMENT 6: EXHIBIT 1019 ("LAPIDUS 1934")

84. Exhibit 1019 is a copy of the journal article titled "Operative

[37] https://search.worldcat.org/title/1778089

Correction of the Metatarsus Varus Primus in Hallux Valgus" by Paul W. Lapidus (hereafter "Lapidus 1934"). The Lapidus 1934 article was published in Volume 58 of the journal *Surgery, Gynecology & Obstetrics* and I retrieved from the Ebling Health Sciences Library at the University of Wisconsin – Madison. Exhibit 1019 is a true and correct copy in a condition that creates no suspicion about its authenticity. The Lapidus 1934 article appears beginning on page 183 of this volume dated January to June 1934. Exhibit 1019 is a true and correct copy of the Lapidus 1934 article (pages 183-191) that I understand is being submitted as an exhibit in this proceeding. Specifically, the text of the article is complete; no pages are missing, and the text on each page appears to flow seamlessly from one page to the next; further, there are no visible alterations to the document.

85. Attached hereto as Attachment 5A is a true and correct copy of the MARC record for the journal *Surgery, Gynecology & Obstetrics* from the Ebling Health Sciences Library at the University of Wisconsin – Madison online catalog. Library ownership is indicated by the presence of the library's name at the top of the page. The library continues to update and enhance this MARC record to meet current cataloging rules. The most recent enhancement to Attachment 5A occurred on March 2, 2009, as shown in field 005 ("20090302"). I personally identified and retrieved the MARC record that is Attachment 5A.

86. Based on finding a print copy of Exhibit 1019 in the Ebling Health

Sciences Library at the University of Wisconsin—Madison and MARC record in its online library catalog attached as Attachment 5A, it is my opinion that the Lapidus 1934 article published in journal *Surgery, Gynecology & Obstetrics* was publicly available on or shortly after June 30, 1934.

87. Attachment 5A includes an entry in field 050 ("RD1 $b .S8")—as described above, a subject matter classification number consistent with the Library of Congress classification system (analogous to the Dewey Decimal classification system), an entry in field 060 ("W1 [$b] SU748")—as described above, a subject matter classification number consistent with the National Library of Medicine classification system (analogous to the Dewey Decimal classification system), and an entry in field 082 ("617/.005")—as described above, a subject matter classification number consistent with the Dewey Decimal classification system. Attachment 5A also shows that Exhibit 1019 was catalogued with six descriptor terms reading "Surgery $v Periodicals" (see Attachment 5B, Library of Congress subject heading sh2008112392), "Gynecology $v Periodicals" (see Attachment 5C, Library of Congress subject heading sh2008118506), "Obstetrics $v Periodicals" (see Attachment 5D, Library of Congress subject heading sh2008108563), "Gynecology $v periodical" (see Attachment 5E, National Library of Medicine subject heading D006176), "Obstetrics $v periodical" (see Attachment 5F, National Library of Medicine subject heading D009974), and "General Surgery $v

periodical" (see Attachment 5G, National Library of Medicine subject heading D013502) in the 650 fields.

88. As noted in the holdings information (362 field), the Ebling Health Sciences Library at the University of Wisconsin – Madison has received the journal *Surgery, Gynecology & Obstetrics* since July 1905 and continues to receive the publication. In view of the MARC record for Exhibit 1019, the Lapidus 1934 article was publicly available on or shortly after June 30, 1934, because the serial title had been received, cataloged, and indexed in the Ebling Health Sciences Library at the University of Wisconsin – Madison and made part of its online catalog database.

89. Attached hereto as Attachment 5H is a true and correct copy of the MARC record for the journal *Surgery, Gynecology & Obstetrics* obtained from the OCLC bibliographic database. As previously noted, the library that created the record is recorded in field 040 with a unique library code. For Attachment 5H, that library code is "DLC," which means that the MARC record for this serial was cataloged at the Library of Congress. As can be seen in field 008 ("Date entered on file") in the MARC record for this exhibit, a cataloger at the Library of Congress created OCLC record number 1766861 on November 1, 1975 ("751101"). The library continues to update and enhance this MARC record to meet current cataloging rules. The most recent enhancement to Attachment 5H

occurred on November 5, 2025, as shown in field 005 ("20251105"). I personally identified and retrieved the MARC record that is Attachment 5H. The "BLvl" entry in Attachment 5H is "s," which indicates that the journal *Surgery, Gynecology & Obstetrics* is a serial publication. Field 310 of Attachment 5H reads "Monthly." Accordingly, the MARC record for Exhibit 1019 corresponds to the journal *Surgery, Gynecology & Obstetrics* began publication until a new title was adopted in January 1994 and includes the date of the Lapidus 1934 article.[38]

90. Attachment 5H includes an entry in field 050 ("RD1 $b .S8")—as described above, a subject matter classification number consistent with the Library of Congress classification system (analogous to the Dewey Decimal classification system), an entry in field 060 ("W1 $b SU748"), a subject matter consistent with the National Library of Medicine classification system (analogous to the Dewey Decimal classification system), and an entry in field 082 ("617/.005"), a subject matter consistent with the Dewey Decimal classification system. Attachment 5H includes six descriptor terms reading "Surgery $v Periodicals" (see Attachment 5B, Library of Congress subject heading sh2008112392), "Gynecology $v Periodicals" (see Attachment 5C, Library of Congress subject heading sh2008118506),

[38] The publication was originally titled *Surgery, Gynecology & Obstetrics* (July 1905-December 1993) and adopted the current title, *Journal of the American College of Surgeons*, in January 1994.

"Obstetrics $v Periodicals" (see Attachment 5D, Library of Congress subject heading sh2008108563), "Gynecology $v periodical" (see Attachment 5E, National Library of Medicine subject heading D006176), "Obstetrics $v periodical" (see Attachment 5F, National Library of Medicine subject heading D009974), and "General Surgery $v periodical" (see Attachment 5G, National Library of Medicine subject heading D013502) in the 650 fields. Thus, as of its cataloging, the publication corresponding to the MARC record attached hereto as Attachment 5 was indexed according to its subject matter by virtue of at least four independently sufficient classifications: the field 050 entry, the field 060 entry, the field 082 entry, and the field 650 entries. As of November 1, 1975, the MARC record attached hereto as Attachment 5H was accessible through any library with access to the OCLC bibliographic database or the online catalog at a library that subscribed to the serial, which means that the corresponding publication was publicly available on or before that same date through any library with access to the OCLC bibliographic database or through an individual library.

91. WorldCat indicates that the journal *Surgery, Gynecology & Obstetrics* as cataloged at the Library of Congress is currently available from 894 libraries.[39] In view of the above, this issue of the journal *Surgery, Gynecology & Obstetrics* was publicly available on or shortly after June 30, 1934, because by that date it had

[39] https://search.worldcat.org/title/1766861

been cataloged and indexed at the Library of Congress, made part of the OCLC bibliographic database, and received at the Ebling Health Sciences Library at the University of Wisconsin — Madison. For these reasons, it is my opinion that Exhibit 1019 was published and accessible to the public on or shortly after June 30, 1934.

92. In addition to library records, the fact that the Lapidus 1934 article was cited in other works that were electronically published and published in paper copy prior to July 2014 supports it public availability:

a. For example, Exhibit 1019 is reference 3 in: Exhibit 1011 (McGlamry, Chpt. 31, p. 329) published in 2012[40];

b. Exhibit 1019 is reference 14 in: Exhibit 1020 (Hofbauer) published in 1996; and

c. Exhibit 1019 is reference 10 in: Exhibit 1016 (Cottom) published in 2013.

XI. DOCUMENT 7: EXHIBIT 1020 ("HOFBAUER")

93. Exhibit 1020 is a copy of the journal article titled "The Lapidus Procedure" by Mark H. Hofbauer and Jordan P. Grossman (hereafter "Hofbauer"). The Hofbauer article was published in Volume 13, Number 3 of the journal *Clinics*

[40] I note there is a typographical error in the listing of Lapidus 1934 in McGlamry – it is inadvertently listed as being published in "1930".

in Podiatric Medicine and Surgery and I retrieved from the Ebling Health Sciences Library at the University of Wisconsin – Madison. Exhibit 1020 is a true and correct copy in a condition that creates no suspicion about its authenticity. The Hofbauer article appears beginning on page 485 of this issue dated July 1996. Exhibit 1020 is a true and correct copy of the Hofbauer article (pages 485-496) that I understand is being submitted as an exhibit in this proceeding. Specifically, the text of the article is complete; no pages are missing, and the text on each page appears to flow seamlessly from one page to the next; further, there are no visible alterations to the document.

94. The Hofbauer article is available from the publisher, Elsevier, and lists an online publication date of March 5, 2013.[41]

95. Attached hereto as Attachment 3A is a true and correct copy of the MARC record for the journal *Clinics in Podiatric Medicine and Surgery* from the Ebling Health Sciences Library at the University of Wisconsin – Madison online catalog. Library ownership is indicated by the presence of the library's name at the top of the page. The library continues to update and enhance this MARC record to meet current cataloging rules. The most recent enhancement to Attachment 3A occurred on November 6, 2025, as shown in field 005 ("20251106"). I personally identified and retrieved the MARC record that is Attachment 3A.

---

[41] https://www.sciencedirect.com/science/article/abs/pii/S0891842223008194

96. Based on finding a print copy of Exhibit 1020 in the Ebling Health Sciences Library at the University of Wisconsin—Madison and MARC record in its online library catalog attached as Attachment 3A, it is my opinion that the Hofbauer article published in journal *Clinics in Podiatric Medicine and Surgery* was publicly available on or shortly after July 31, 1996.[42]

97. Attachment 3A includes an entry in field 050 ("RD563 $b .C63")—as described above, a subject matter classification number consistent with the Library of Congress classification system (analogous to the Dewey Decimal classification system) and an entry in field 082 ("617/.585/005")—as described above, a subject matter classification number consistent with the Dewey Decimal classification system. Attachment 3A also shows that Exhibit 1020 was catalogued with three descriptor terms reading "Podiatry $v Periodicals" (see Attachment 3B, Library of Congress subject heading sh85103669 and Attachment 1C, Library of Congress subject heading sh85099890), "Foot $x Surgery $v Periodicals" (see Attachment 1D, Library of Congress subject heading sh85050391 and Attachment 1C, Library

[42] The journal *Clinics in Podiatric Medicine and Surgery* was published quarterly and, therefore, new issues were available approximately 90 days. Based on the frequency of publication (see Attachment 3A, field 310) and my years of experience working with serials, it is my opinion that issues would be published by the end of the first month in the quarter named on the issue. Therefore, a public availability date of July 31, 1996, is reasonable.

of Congress subject heading sh85099890), and "Podiatry" (see Attachment 3C, National Library of Medicine subject heading D011032) in the 650 fields.

98. As noted in the holdings information (362 field), the Ebling Health Sciences Library at the University of Wisconsin – Madison has received the journal *Clinics in Podiatric Medicine and Surgery* since January 1986 and continues to receive the publication. In view of the MARC record for Exhibit 1020, the Hofbauer article was publicly available on or shortly after July 31, 1996, because the serial title had been received, cataloged, and indexed in the Ebling Health Sciences Library at the University of Wisconsin – Madison and made part of its online catalog database.

99. Attached hereto as Attachment 3D is a true and correct copy of the MARC record for the journal *Clinics in Podiatric Medicine and Surgery* obtained from the OCLC bibliographic database. As previously noted, the library that created the record is recorded in field 040 with a unique library code. For Attachment 3D, that library code is "CLU," which means that the MARC record for this serial was cataloged at the University of California – Los Angeles Libraries. As can be seen in field 008 ("Date entered on file") in the MARC record for this exhibit, a cataloger at the University of California – Los Angeles Libraries created OCLC record number 13324960 on March 21, 1986 ("860321"). The library continues to update and enhance this MARC record to meet current

cataloging rules. The most recent enhancement to Attachment 3D occurred on November 5, 2025, as shown in field 005 ("20251105"). I personally identified and retrieved the MARC record that is Attachment 3D. The "BLvl" entry in Attachment 3D is "s," which indicates that the journal *Clinics in Podiatric Medicine and Surgery* is a serial publication. Field 310 of Attachment 3D reads "Quarterly." Accordingly, the MARC record for Exhibit 1020 corresponds to the journal *Clinics in Podiatric Medicine and Surgery* from the time the serial adopted the current title and includes the date of the Hofbauer article.[43]

100. Attachment 3D includes an entry in field 050 ("RD563 $b .C63")—as described above, a subject matter classification number consistent with the Library of Congress classification system (analogous to the Dewey Decimal classification system), an entry in field 060 ("W1 $b CL831DE"), a subject matter consistent with the National Library of Medicine classification system (analogous to the Dewey Decimal classification system), and an entry in field 082 ("617/.585/005"), a subject matter consistent with the Dewey Decimal classification system. Attachment 3D includes four descriptor terms reading "Podiatry $v Periodicals" (see Attachment 3B, Library of Congress subject heading sh85103669 and

[43] The publication was originally titled *Clinics in Podiatry* (April 1984-October 1985) and adopted the current title, *Clinics in Podiatric Medicine and Surgery*, in January 1986.

Attachment 1C, Library of Congress subject heading sh85099890), "Foot $x Surgery $v Periodicals" (see Attachment 1D, Library of Congress subject heading sh85050391 and Attachment 1C, Library of Congress subject heading sh85099890), "Podiatry" (see Attachment 3C, National Library of Medicine subject heading D011032), and "Foot $x surgery" (see Attachment 1F, National Library of Medicine subject heading D005528) in the 650 fields. Thus, as of its cataloging, the publication corresponding to the MARC record attached hereto as Attachment 3D was indexed according to its subject matter by virtue of at least four independently sufficient classifications: the field 050 entry, the field 060 entry, the field 082 entry, and the field 650 entries. As of March 21, 1986, the MARC record attached hereto as Attachment 3D was accessible through any library with access to the OCLC bibliographic database or the online catalog at a library that subscribed to the serial, which means that the corresponding publication was publicly available on or before that same date through any library with access to the OCLC bibliographic database or through an individual library.

101. WorldCat indicates that the journal *Clinics in Podiatric Medicine and Surgery* as cataloged at the University of California—Los Angeles Libraries is currently available from 506 libraries.[44] In view of the above, this issue of the journal *Clinics in Podiatric Medicine and Surgery* was publicly available on or

[44] https://search.worldcat.org/title/13324960

shortly after July 31, 1996, because by that date it had been cataloged and indexed at the University of California – Los Angeles Libraries, made part of the OCLC bibliographic database, and received at the Ebling Health Sciences Library at the University of Wisconsin — Madison. For these reasons, it is my opinion that Exhibit 1020 was published and accessible to the public on or shortly after July 31, 1996.

102. In addition to library records, the fact that the Hofbauer article was cited in other works that were electronically published and published in paper copy prior to July 2014 supports its public availability:

a. For example, Hofbauer Exhibit 1020 is listed as reference 5 in: Exhibit 1011 (McGlamry, Chpt. 31, p. 329) published in 2012.

XII. SUMMARY OF OPINIONS

103. In view of the foregoing, it is my opinion that the publications described above were publicly available to a POSA by the corresponding date listed in the table below, and thus before July 2014:

Document	Exhibit	Description	Publication Date
1	1005	Dayton, Paul, Mindi Feilmeier, Merrell Kauwe, and Jordan Hirschi. "Relationship of Frontal Plane Rotation of First Metatarsal to Proximal Articular Set Angle and Hallux Alignment in Patients	March 5, 2013

Document	Exhibit	Description	Publication Date
		Undergoing Tarsometatarsal Arthrodesis for Hallux Abducto Valgus: A Case Series and Critical Review of the Literature." Journal of Foot and Ankle Surgery, vol. 52, no. 3 (May-June 2013): 348-354.	
2	1011	*McGlamry's Comprehensive Textbook of Foot and Ankle Surgery*, 4th ed. 2 vols. Edited by E. Dalton McGlamry, Joe T. Southerland, and Daniel F. Vickers. Chapters 1, 31, 34, 36, and 55. Philadelphia, PA: Wolters Kluwer Health, 2013.	November 9, 2012
3	1016	Cottom, James M. and Anand M. Vora. "Fixation of Lapidus Arthrodesis with a Plantar Interfragmentary Screw and Medial Locking Plate: A Report of 88 Cases." *The Journal of Foot and Ankle Surgery*, vol. 52, no. 4 (July-August 2013): 465-469.	May 24, 2012
4	1017	Baravarian, Babak, Gary B. Briskin, and Patrick Burns. "Lapidus Bunionectomy: Arthrodesis of the First Metatarsocunieform Joint." Clinics in Podiatric Medicine and Surgery, vol. 21, no. 1 (January 2004): 97-111.	March 12, 2004
5	1018	Lapidus, Paul W. "The Author's Bunion Operation From 1931 to 1959." *Clinical Orthopaedics*, vol. 16 (1960): 119-135.	April 30, 1960
6	1019	Lapidus, Paul W. "Operative Correction of the Metatarsus Primus	June 30, 1934

Document	Exhibit	Description	Publication Date
		(January-June 1934): 183-191.	
7	1020	Hofbauer, Mark H., and Jordan P. Grossman. "The Lapidus Procedure." *Clinics in Podiatric Medicine and Surgery*, vol. 13, no. 3 (July 1996): 485-496.	July 31, 1996

104. In signing this declaration, I recognize that the declaration will be filed as evidence in a case before the Patent Trial and Appeal Board of the United States Patent and Trademark Office. I also recognize that I may be subject to cross-examination in the case. If cross-examination is required of me, I will appear within the United States during the time allotted for cross-examination.

105. I hereby declare that all statements made herein of my own knowledge are true and that all statements made on information and belief are believed to be true, and further that these statements were made with the knowledge that willful false statements and the like so made are punishable by fine or imprisonment, or both, under Section 1034 of Title 18 of the United States Code.

DATED: February 26, 2026 By: Sylvia D. Hall-Ellis

Sylvia D. Hall-Ellis, Ph.D.

Index of Exhibits and Attachments to Declaration of Sylvia Hall-Ellis, Ph.D. in Support of Petition for Post-Grant Review of U.S. Patent No. 12,349,941

Exhibit	Description
1	Curriculum Vitae of Sylvia Hall-Ellis, Ph.D.
1005	Dayton, Paul, Mindi Feilmeier, Merrell Kauwe, and Jordan Hirschi. "Relationship of Frontal Plane Rotation of First Metatarsal to Proximal Articular Set Angle and Hallux Alignment in Patients Undergoing Tarsometatarsal Arthrodesis for Hallux Abducto Valgus: A Case Series and Critical Review of the Literature." Journal of Foot and Ankle Surgery, vol. 52, no. 3 (May-June 2013): 348-354. ("Dayton 2013")
1011	*McGlamry's Comprehensive Textbook of Foot and Ankle Surgery*, 4th ed. 2 vols. Edited by E. Dalton McGlamry, Joe T. Southerland, and Daniel F. Vickers. Chapters 1, 31, 34, 36, and 55. Philadelphia, PA: Wolters Kluwer Health, 2013. ("McGlamry's 2013")
1016	Cottom, James M. and Anand M. Vora. "Fixation of Lapidus Arthrodesis with a Plantar Interfragmentary Screw and Medial Locking Plate: A Report of 88 Cases." *The Journal of Foot and Ankle Surgery*, vol. 52, no. 4 (July-August 2013): 465-469. ("Cottom")
1017	Baravarian, Babak, Gary B. Briskin, and Patrick Burns. "Lapidus Bunionectomy: Arthrodesis of the First Metatarsocunieform Joint." Clinics in Podiatric Medicine and Surgery, vol. 21, no. 1 (January 2004): 97-111. ("Baravarian")
1018	Lapidus, Paul W. "The Author's Bunion Operation From 1931 to 1959." *Clinical Orthopaedics*, vol. 16 (1960): 119-135. ("Lapidus 1960")
1019	Lapidus, Paul W. "Operative Correction of the Metatarsus Primus Varus in Hallux Valgus." *Surgery, Gynecology & Obstetrics,* vol. 58 (January-June 1934): 183-191. ("Lapidus 1934")
1020	Hofbauer, Mark H., and Jordan P. Grossman. "The Lapidus Procedure." *Clinics in Podiatric Medicine and Surgery*, vol. 13, no. 3 (July 1996): 485-496. ("Hofbauer)

Attachment Set	Description
1	**Dayton 2013** 1A: Library of Congress created OCLC record number 27182191 1B: Library of Congress subject heading sh85005320 1C: Library of Congress subject heading sh85099890 1D: Library of Congress subject heading sh85050391 1E: National Library of Medicine subject heading D000842 1F: National Library of Medicine subject heading D005528
2	**McGlamry (4th Edition, 2013)** 2A: National Library of Medicine - MARC record 2B: National Library of Medicine - MARC record contributed to OCLC bibliographic database record 2C: Library of Congress subject heading sh85050397 2D: Library of Congress subject heading sh85005321 2E: Library of Congress subject heading sh85130766 2F: National Library of Medicine subject heading D005530 2G: National Library of Medicine subject heading D018409 2H: U. S. Copyright Office Public Catalog
3	**Cottom** 9A: MARC record for *The Journal of Foot & Ankle Surgery* obtained from the OCLC bibliographic database
4	**Baravarian** 6A: MARC record for the journal *Clinics in Podiatric Medicine and Surgery of North America* from the Library of Congress online catalog 6B: MARC record for the journal *Clinics in Podiatric Medicine and Surgery* obtained from the OCLC bibliographic database

Attachment Set	Description
5	**Lapidus 1960** 4A: MARC record for the journal *Clinical Orthopaedics* from the Ebling Health Sciences Library at the University of Wisconsin – Madison online catalog 4B: Library of Congress subject heading sh2010104613 4C: Library of Congress subject heading sh85095812 4D: National Library of Medicine subject headings D001842 4E: National Library of Medicine subject heading D009985 4F: MARC record for the journal *Clinical Orthopaedics* obtained from the OCLC bibliographic database
6	**Lapidus 1934** 5A: MARC record for the journal *Surgery, Gynecology & Obstetrics* from the Ebling Health Sciences Library at the University of Wisconsin – Madison online catalog 5B: Library of Congress subject heading sh2008112392 5C: Library of Congress subject heading sh2008118506 5D: Library of Congress subject heading sh2008108563 5E: National Library of Medicine subject heading D006176 5F: National Library of Medicine subject heading D009974 5G: National Library of Medicine subject heading D013502 5H: MARC record for the journal *Surgery, Gynecology & Obstetrics* obtained from the OCLC bibliographic database
7	**Hofbauer** 3A: MARC record for the journal *Clinics in Podiatric Medicine and Surgery* from the Ebling Health Sciences Library at the University of Wisconsin – Madison online catalog 3B: Library of Congress subject heading sh85103669 3C: National Library of Medicine subject heading D011032 3D: MARC record for the journal *Clinics in Podiatric Medicine and Surgery* obtained from the OCLC bibliographic database

Exhibit 1

CURRICULUM VITAE SYLVIA D. HALL-ELLIS

EDUCATION

Ph.D., University of Pittsburgh, Pittsburgh, Pennsylvania, 1985
M.P.S., University of Denver, Denver, Colorado, 2014
Post Graduate Studies, University of Texas – San Antonio, Texas, 1975-1976
M.L.S., University of North Texas, Denton, Texas, 1972
B.A., Rockford University, Rockford, Illinois, 1971

PROFESSIONAL EXPERIENCE

1981- **Consultant for higher education, non-profit organizations, and corporations.**

2002- **Adjunct Professor, School of Information, San José State University, San José, California.** Serve as part-time faculty member teaching graduate students in technical services (cataloging, bibliographic control, classification), "core courses," and special topics.

2014-2016 **Director, Grants and Resource Development, Colorado Community College System.** Provided leadership and vision to foster the continued growth of rigorous scholarship, innovative projects, and creative work for statewide system, 13 campuses, and 50 teaching sites serving 155,000 students. Responsible for leadership and ensured efficient functioning of contract and grants in compliance with state & federal requirements and successful implementation and management. Served as a subject matter expert and liaison for college Grant Directors for all issues relating to grants and subcontracts.

2010-2014 **Senior Grant Administrator, Morgridge College of Education, University of Denver (Colorado).** Provided leadership and vision to foster continued growth of rigorous scholarship, innovative research, and creative work in the Morgridge College of Education. Ensure that contract and grants processes function effectively and efficiently for 60 faculty and researchers with a focus on the successful progression and efficient management of grants totaling $13M. Worked effectively and collegially with Department Chairs and Program Coordinators on operational grant-related management activities and with a broad range of internal and external constituencies. Supported the dissemination and promotion of faculty research and scholarship to outside constituents at conferences and through publications. Assisted Principal Investigators and grant project teams by coaching, mentoring, and financial management.

2011-2013 **Interim Director & Assistant Dean, Westminster Law Library, Sturm College of Law, University of Denver.** Planned, organized, and directed all administrative activities for the library serving students, faculty, and alumni; oversaw the employment, retention, promotion, transfer and termination of library personnel; represented the library at professional conferences and public meetings; created and promoted a climate and culture of acceptance for new programs and services, a positive high-quality image of the law library, and that reflect the organization's values, encourage excellent performance, and reward high productivity and innovation; provided leadership and set strategic direction of the organization; ensured that the library provided excellent customer service through solution-oriented staff response to patron needs and by responsiveness and continuous improvement of the organization; promoted, developed, and maintained positive working relationships with colleagues and customers including key stakeholders and groups, higher education institutions, the legal community, other regional libraries and districts statewide, and national library organizations.

2007-2014 **Associate Professor, Library & Information Science, Morgridge College of Education, University of Denver (Colorado).** Served in leadership role and worked collaboratively in program, college, campus and community environments. Advised and supervised students, taught core and specialized courses at the graduate level in an integrative, student-centered learning environment. Served on LIS, College, and University committees, and maintained working relationships with colleagues in other academic units and information professionals in the Rocky Mountain region and beyond. Served on and chair doctoral student dissertation committees. Oversaw and facilitated the College and LIS graduate student association.

2002-2007 **Assistant Professor, Library & Information Science, College of Education, University of Denver (Colorado).** Served as tenure-track faculty member teaching graduate students in "core courses," resource description and access, service learning, and independent studies. Advised graduate students, participate on LIS and College committees, and serve on doctoral student dissertation committees. Oversaw and facilitated the LIS graduate student association and alumni association.

2000-2002 **Affiliate Faculty, Library & Information Science, College of Education, University of Denver (Colorado).** Served as part-time faculty member teaching graduate students in technical services (cataloging, bibliographic control, classification), "core courses," and special topics. Oversaw and facilitated the LIS graduate student association and alumni association.

2000-2001 **Special Assistant to the Secretary's Regional Representative, U.S. Department of Education, Region VIII, Denver, Colorado.** Served as the principal advisor and representative of the U. S. Secretary of Education's Regional Representative (SRR). Ensured the implementation of major goals of the SRR and the Secretary. Provided leadership on behalf of the SRR in contacts with high-level officials in Region VIII requiring sensitive policy interpretation in communication with senior Department officials to solve problems and resolve issues raised by State and local education officials. Served as the primary contact for School-to-Work/Career, Children's Health Insurance Program, and Safe and Drug-Free Schools. Delivered technical assistance to local education agencies and institutions of higher education in technology, professional development, and school construction.

1999-2000 **Catalog Librarian, Jefferson County Public Library, Lakewood, Colorado.** Performed original, copy cataloging and classification of library materials (English and Spanish) using standard library protocols; completed original descriptive cataloging and subject analysis; enhanced brief catalog and authority records in III.

1997-1999 **Development Officer, McREL International, Aurora, Colorado.** Served as senior member of corporate management team in strategic planning, development of proposals and contracts, implementation, and evaluation of new services, products, and programs for educational agencies. Provided creative leadership to corporate committees to solicit ideas, identify goals and objectives, plan, develop, present, and evaluate professional development opportunities.

1995-1997 **Education Specialist, Education Service Center, Region One, Edinburg, Texas.** Served as member of Administrative Cabinet team in strategic planning, development of proposals and contracts, implementation, and evaluation of telecommunications capabilities, services, products, and programs for 40 school districts serving 283,000 students in 7 counties. Provided creative leadership to regional and state committees to solicit ideas, identify strategic goals and objectives, plan, develop, present, and evaluate funding opportunities and professional development for 400 librarians.

1993-1996 **Assistant Professor of Library Science, Sam Houston State University, Huntsville, Texas.** Served a faculty member teaching 400 graduate students in technical services (cataloging, bibliographic control, classification), automation, and networking. Participated in distance education program and coordinated annual conference. Conducted university and Texas Library Association-funded field research focused on library collection development and academic achievement.

1992-1993 **Head Librarian, Rocky Mountain College of Art & Design, Denver, Colorado.** Responsible for the daily operation, selection and acquisition of materials, formulation of policies for library operations, media center, and photography/slides archives. Designed and implemented library automation and delivery of electronic resources to college community.

1981-1985 **Development Officer, PRLC, Inc., Pittsburgh, Pennsylvania.** Served as senior member of corporate management team in strategic planning, development of proposals and contracts, implementation, and evaluation of new services, products, and programs for 100 institutional member organizations. Coordinated the development of proposals and contracts totaling $4,000,000 annually. Provided creative leadership to corporate committees to solicit ideas, identify goals and objectives, plan, develop, present, and evaluate professional development opportunities.

1981 **Director of Library Development, Pennsylvania Department of Education, Harrisburg, Pennsylvania.** Responsible for statewide development, technical assistance, professional development, resource sharing, children's services, institutional library services, networking, and state aid program for all libraries throughout the Commonwealth. Functioned as liaison to Governor's Advisory Council, LSCA Advisory Council, District Administrators, private colleges, universities, consortia managers, and network directors. Supervised $14,000,000 formula-based state aid program and $3,000,000 grant awards to individual libraries, consortia, and networks.

1978-1981 **Assistant Director, Southern Tier Library System, Corning, New York.** Coordinated operation of system-wide programs (technical assistance, professional development, resource sharing, technical services, outreach) to 40 public libraries in 5 counties serving 500,000 residents. Solicited ideas, identified goals, sponsored, and evaluated professional development opportunities and technical assistance sessions.

1976-1978 **Division Librarian for Technical Services, Corpus Christi Public Libraries, Corpus Christi, Texas.** Provided leadership in acquisitions, cataloging, serials control, and processing for main library and 4 branches serving 250,000 residents. Participated as senior member of library management team. Compiled and prepared technical evaluations, reports, and statistical analyses of Division operations to measure the achievement and cost of annual goals, objectives, and staff performance.

1975-1976 **System Coordinator, San Antonio Major Resource Center, San Antonio, Texas.** Served as senior member of the management team for District X Office, charged to provide technical assistance, resource sharing, media services, and professional development to librarians and staff representing 30 public library jurisdictions in 21 counties serving 1,500,000 residents. Functioned as liaison to System Director, staff, and members of governing bodies with the System Board of Directors and the Texas State Library and Historical Commission. Prepared LSCA grant applications and monitored awards totaling $1,100,000 annually.

1973-1975 **Bilingual Branch Librarian, San Antonio Public Library, San Antonio, Texas.** Worked as librarian providing reference, information, and readers' advisory services in branch serving 50,000 Spanish-speaking residents in southwest San Antonio. Participated in collection development and resource acquisition activities, specializing in children's work, Spanish language resources, and multicultural studies.

1972-1973 **Librarian, Holding Institute, Laredo, Texas.** Worked as high school librarian serving 500 boarding students in Spanish-speaking environment of private school. Provided reference, research assistance, and library instruction to students and 35 faculty members.

1966-1971 **Rockford Public Library, Rockford, Illinois.** Worked in branches as part-time as a Library Assistant, Clerk, and Page in city library serving 150,000 residents.

PUBLICATIONS

Editor-reviewed Monographs (Completed and in Progress)

Hall-Ellis, Sylvia D., and Mary Bolin. *Contemporary Cataloging in an RDA Environment: A Handbook for Students and Practitioners.* Chicago, IL: American Library Association. Under contract & In development.

RDA Testing: Lessons Learned and Challenges Revealed. Sylvia D. Hall-Ellis and Robert O. Ellett, Jr., eds. Binghamton, N.Y.: Haworth, 2012. 128 p.

Hall-Ellis, Sylvia D., Stacey L. Bowers, Christopher D. Hudson, and M. Claire Williamson. *Librarian's Handbook for Seeking, Writing, and Managing Grants.* Santa Barbara, Calif.: Libraries Unlimited, 2011. 315 p.

Hall-Ellis, Sylvia D., with Ann Jerabek, and Merrie W. Valliant. *Contemporary Cataloging: A Handbook for Practitioners and Students.* Open access text. Athens, GA: University of Georgia System Regents, 2011. 767 p.

Grealy, Deborah S. and Sylvia D. Hall-Ellis. *From Research to Practice: The Scholarship of Teaching and Learning in LIS Education.* Westport, Conn.: Libraries Unlimited, 2009. 175 p.

Hall-Ellis, Sylvia D. with J. Ann Jerabek. *Grants for School Libraries.* Westport, Conn.: Libraries Unlimited, 2003. 197 p.

Hall-Ellis, Sylvia D., Doris Meyer, Frank W. Hoffmann, with J. Ann Jerabek. *Grant Writing for Small Libraries and School Library Media Centers.* Boulder, Colo.: NetLibrary, 2001. 173 p.

Hall-Ellis, Sylvia D., Doris Meyer, Frank W. Hoffmann, with J. Ann Jerabek. *Grant Writing for Small Libraries and School Library Media Centers.* Englewood, Colo: Libraries Unlimited, 2000. 173 p.

Editor-reviewed Chapters (Completed and In Progress)

Hall-Ellis, Sylvia D. "Prepared to Lead: Talent, Skills, and Competencies." In *Telling the Technical Services Story*. Chicago, IL: American Library Association, 2020. Program Presentation for Re-Accreditation by the American Library Association, School of Information, San Jose State University, 2022.

Hall-Ellis, Sylvia D. "Grant Writing and Sponsored Research Funding for Academic Librarians." In *The New Librarianship.* Vol. 4. Bradford Lee Eden, ed. New York: Scarecrow Press, 2015. (pp. 163-174)

Hall-Ellis, Sylvia D. "Organizing Information: Technical Services." In *Information Services Today: An Introduction.* Sandra Hirsch, ed. Lantham, Md.: Rowman and Littlefield, 2015. (pp. 139-148)

Hall-Ellis, Sylvia D. "Metadata, MARC, and More." In *Rethinking Technical Services, Considering Our Profession and Ourselves: What's the Future of Our Profession?* Mary Beth Weber, ed. Lantham, Md.: Rowman and Littlefield, 2015. (pp. 29-55)

Hall-Ellis, Sylvia D., ed. "Contingent Faculty: Non-Tenure Track Faculty Series." In the *Faculty Personnel Guidelines Relating to Appointment, Promotion, and Tenure.* November 2011. Denver, Colo.: University of Denver, 2011. 42 p.

Hall-Ellis, Sylvia D., ed. "Standard VII: Information Resources." In the *Sturm College of Law Self-Study Presentation for Accreditation by the American Bar Association.* Denver, Colo.: University of Denver, Sturm College of Law, 2011. 20 p.

Hall-Ellis, Sylvia D. "Applying for Grants from Foundations, Corporations, or Government." In *The Volunteers' Guide to Fundraising: Raise Money for Your School Team, Library or Community Group.* 1st ed. Ilona M. Bray, ed. Berkeley, Calif.: Nolo, 2011. (pp. 1-38 on accompanying disc)

Hall-Ellis, Sylvia D., ed. "Standard III: The Faculty." In the *Library and Information Science Program Self-Study Document for Accreditation by the American Library Association.* Denver, Colo.: University of Denver, Morgridge College of Education, 2010. 22 p.

Hall-Ellis, Sylvia D. "Library and Information Science Programs and Education for Catalogers and Metadata Specialists: Challenges for the Twenty-first Century." In *Conversations with Catalogers in the Twenty-First Century.* Elaine R. Sanchez, ed. Santa Barbara, Calif.: ABC-Clio, 2010. (pp. 226-254)

Hall-Ellis, Sylvia D., ed. "Standard III: The Faculty." In the *Library and Information Science Program Self-Study Document for Accreditation by the American Library Association.* Denver, Colo.: University of Denver, College of Education, 2003. 15 p.

Lesesne, Teri S. and Sylvia D. Hall-Ellis. "The Selection, Evaluation, and Integration of Culturally Authentic Texts: A Case for Making the Online Catalog Reflect Parallel Cultures." In *Literacy: Traditional, Cultural, Technological.* Pittsburgh, Pa.: International Association of School Librarianship, 1995. (pp. 110-113)

Lesesne, Teri S. and Sylvia D. Hall-Ellis. *The Selection, Evaluation, and Integration of Culturally Authentic Texts: A Case for Making the Online Catalog Reflect Parallel Cultures.* In *Conference Proceedings* of the 23rd Annual International Association of School Librarianship, Pittsburgh, Pennsylvania, July 17-22, 1994. ERIC Document ED374816. 17 p.

Hall-Ellis, Sylvia D. "Curriculum Folio for School Library Media Specialist Programs." In the *National Council for Accreditation of Teacher Education Self-Study for Sam Houston State University.* Huntsville, Tex.: Sam Houston State University, College of Education and Applied Science, 1994. 25 p.

Bruntjen, Scott and Sylvia D. Hall. "Attempting to Automate: Lessons Learned Over Five Years." In *Advances in Library Administration*. Volume 4. Weston, Conn.: JAI Press, 1985. (pp. 177-192)

Peer-Reviewed Journal Articles (Completed and In Progress)

Hall-Ellis-Sylvia D. "Job Design for Cataloging and Metadata Librarians." Submitted to *Journal of Library Administration.* In progress.

Hall-Ellis, Sylvia D. "The Relationship of Situational Leadership and the Dreyfus Model of Skill Acquisition for Supervisors in Cataloging and Metadata Services." To be submitted to *Library Resources and Technical Services.* In progress.

Hall-Ellis, Sylvia D. *The Relationship of Core Competencies on Learning Outcomes and Employers' Expectations for Catalog Librarians and Metadata Specialists.* To be submitted to the *Journal of Education for Library and Information Science.* In progress.

Hall-Ellis, Sylvia D. "Building Cataloger Competencies: The Dreyfus Model as a Prototype for the Education and Professional Development of Catalog Librarians and Metadata Specialists in Bibliographic Control." To be submitted to the *Cataloging & Classification Quarterly.* In progress.

Hall-Ellis, Sylvia D. "Descriptive Impressions of Entry-Level Cataloger and Metadata Specialists Positions, 2000-2016: Reflections and Trends." To be submitted to *Library Resources and Technical Services.* In progress.

Hall-Ellis, Sylvia D. "Competencies for Metadata and Cataloging Leaders: What Employers Expect as Reflected in Position Descriptions, 2000-2016." *Cataloging & Classification Quarterly.* In progress.

Hall-Ellis, Sylvia D. "Stackable Micro-credentials – A Framework for the Future." *The Bottom Line 29*, no. 4 (April 2016), http://www.emeraldinsight.com/doi/pdfplus/10.1108/BL-02-2016-0006
Ellis, Sylvia D. "Succession Planning and Staff Development – A Winning Combination." *The Bottom Line*, 28 no. 3 (May 2015): 95-98.

Hall-Ellis, Sylvia D. "Succession Planning and Staff Development – A Winning Combination." *The Informed Librarian Online* (September 2015), http://www.informedlibrarian.com/featuredArticle.cfm?FILE=succession_1509.pdf

Hall-Ellis, Sylvia D. "Nudges and Decision Making: A Winning Combination." *The Bottom Line 28*, no. 4 (July 2015): 133-136.

Hall-Ellis, Sylvia D. "Succession Planning and Staff Development – A Winning Combination." *The Bottom Line 28*, no. 3 (May 2015): 95-98.

Hall-Ellis, Sylvia D. "Metadata Competencies for Entry-Level Positions: What Employers Expect as Reflected in Position Descriptions, 2000-2013." *Journal of Library Metadata 15*, no. 2 (June 2015): 102-134.

Hall-Ellis, Sylvia D. "Onboarding to Improve Library Retention and Productivity." *The Bottom Line 27*, no. 4 (October 2014).

Hall-Ellis, Sylvia D. "Accept, Coach, and Inspire: A Formula for Success." *The Bottom Line 27*, no. 3 (July 2014): 103-106.

Hall-Ellis, Sylvia D. *Reward Systems for Staff in Higher Education Institutions: Case Studies of 15 Higher Education Institutions in Colorado.* Capstone Thesis. Denver, Colo.: University of Denver, University College, 2014.

Hall-Ellis, Sylvia D. "Reward Systems Promote High-Performance Work Teams Achieving Library Mission." *The Bottom Line 27*, no. 2 (April 2014): 66-69.

Hall-Ellis, Sylvia D. "Investment in Staff Development for Seeking External Grant Funds." *The Bottom Line 27*, no. 1 (January 2014): 22-25.

Hall-Ellis, Sylvia D. "Staff Investments for High Performance Teams." *The Bottom Line 26*, no. 4 (October 2013): 149-152.

Hall-Ellis, Sylvia D. and Deborah S. Grealy. "Service Learning in LIS Education: A Case for Holistic Assessment." *Catholic Library World* 82, no. 3 (March 2012): 178-187.

Hall-Ellis, Sylvia D., and Deborah S. Grealy. "The Dreyfus Model of Skill Acquisition: A Career Development Framework for Succession Planning and Management in Academic Libraries." *College and Research Libraries* (June 2012). http://crl.acrl.org/content/early/2012/06/19/crl12-349.full.pdf+html

Hall-Ellis, Sylvia D. "Cataloger Competencies…What Do Employers Require?" *Cataloging & Classification Quarterly* 46, no. 3 (2008): 305-330. http://ccq.haworthpress.com/doi:10.1080/01639370802034565

Hall-Ellis, Sylvia D. "Subject Access for Readers' Advisory Services: Their Impact on Contemporary Spanish Fiction in Selected Public Library Collections." *Public Library Quarterly* 27, no.1 (2007): 1-18. http://plq.haworthpress.com/doi:10.1080/01616840802122377

Hall-Ellis, Sylvia D. "Language Proficiencies among Catalogers and Technical Services Librarians." *Technical Services Quarterly* 25, no. 2 (2007) 31-47. http://tsq.haworthpress.com/doi:10.1300/J124v25n02_03

Hall-Ellis, Sylvia D. "Cataloging Electronic Resources & Metadata: Employers' Expectations as Reflected in *American Libraries and AutoCAT,* 2000-2005." *Journal of Education for Library and Information Science* 47, no. 1 (2006): 38-51.

Hall-Ellis, Sylvia D. "Descriptive Impressions of Managerial & Supervisory Cataloger Positions as Reflected in *American Libraries, AutoCAT,* and the *Colorado State Library Jobline,* 2000-2004: A Content Analysis of Education, Competencies, and Experience." *Cataloging & Classification Quarterly* 42, no. 1 (2006): 55-88.

Hall-Ellis, Sylvia D. "Descriptive Cataloging Proficiencies among Beginning Students: A Comparison among Traditional and Virtual Class Students." *Journal of Library & Information Services in Distance Education* 2, no. 2 (2005): 13-44.

Hall-Ellis, Sylvia D. "Descriptive Impressions of Entry-Level Cataloger Positions as Reflected in *American Libraries, AutoCAT,* and the *Colorado State Library Jobline,* 2000-2003." *Cataloging & Classification Quarterly* 40, no. 2 (2005): 33-72.

Hall-Ellis, Sylvia D. and Mary Ann Berry. "The Impact of Library Resource Centers on Academic Achievement in Selected Public Schools in South Texas: Preliminary Findings." *Texas Library Journal* 71, no. 2 (Summer 1995): 94-97.

Hall-Ellis, Sylvia D. "Visual Arts as Foundation for Successful Library Automation: The Rocky Mountain College of Art & Design Experience." *Art Reference Serials Quarterly* 4 (1994): 43-54.

Hall, Sylvia D. *High School Databases: An Examination of Bibliographic Data Elements*. Dissertation. Pittsburgh, Pa.: University of Pittsburgh, School of Library and Information Science, 1985.

Technical Reports

Hall-Ellis, Sylvia D. *Preparing Catalogers and Metadata Specialists Through Competency-Based Education: The San José State University iSchool Experience.* Report for the 2021 Re-Accreditation Program Presentation to the American Library Association. San José, Calif.: San José State University iSchool, 2020.

Hall-Ellis, Sylvia D. *Colorado Community College System Grant Handbook.* Denver, Colo.: Colorado Community College System, 2015.

.

Faculty Voices: Testimonials from the Frontiers of a Development Education Redesign. Elaine DeLott Baker, Marilyn Smith, and Sylvia D. Hall-Ellis, eds. Denver, Colo.: Colorado Community College System, 2014.

Lewis, Melanie, Jamie M. Van Leeuwen, and Sylvia D. Hall-Ellis. *Project Homeless Connect 7 Event Evaluation.* Denver, Colo.: University of Colorado Denver, 2009.

Hall-Ellis, Sylvia D. *Grant Writing Tips and Resources.* Denver, Colo.: University of Denver, 2008-2014. http://portfolio.du.edu/grants

Hall-Ellis, Sylvia D. and Duan Zhang. *Project Homeless Connect 6 Event Evaluation.* Denver, Colo.: Center for Community Engagement and Service Learning, 2008.

Hall-Ellis, Sylvia D. *Strategic Plan for Denver Medical Library System: Final Report.* Denver, Colo.: HealthONE and Denver Medical Library, 2008.

Hall-Ellis, Sylvia D. and Duan Zhang. *Project Homeless Connect 5 Event Evaluation.* Denver, Colo.: Center for Community Engagement and Service Learning, 2008.

Hall-Ellis, Sylvia D. *Strategic Plan for Denver Medical Library System: Phase Two Report.* Denver, Colo.: HealthONE and Denver Medical Library, 2007.

Hall-Ellis, Sylvia D. and Duan Zhang. *Project Homeless Connect 4 Event Evaluation.* Denver, Colo.: Center for Community Engagement and Service Learning, 2007.

Hall-Ellis, Sylvia D. *Strategic Plan for Denver Medical Library System: Phase One Report.* Denver, Colo.: HealthONE and Denver Medical Library, 2007.

Hall-Ellis, Sylvia D. *Denver Public Library: Opportunities for Change.* Denver, Colo.: University of Denver, Colorado Community-Based Research Network & Metropolitan Organization of People, 2005.

Hall-Ellis, Sylvia D. *Resources in Grant Writing for Colorado Schools and Libraries.* Sponsored by the Colorado Department of Education, Educational Telecommunications Unit, 1999. Revised September 2000.

Hall-Ellis, Sylvia D. *Lewis & Clark Fellows Concept Paper for the Bicentennial Commemoration.* Vancouver, Wash.: Lewis and Clark Bicentennial Council, 1998.

Hall-Ellis, Sylvia D. and Mary Ann Berry. *The Impact of Library Resource Centers on Academic Achievement in Public Schools in Texas: The Final Report.* Prepared under the sponsorship of the Research Enhancement Fund award from Sam Houston State University, the Texas Association of School Librarians, the Children's Services Round Table, and the Young Adults' Services Round Table. Huntsville, Tex.: Sam Houston State University, College of Education and Applied Science, 1997.

Hall-Ellis, Sylvia D. *The Impact of Library Resource Centers on Academic Achievement in Selected Public Schools in Texas.* Huntsville, Tex.: Sam Houston State University, College of Education and Applied Science, 1997.

Hall-Ellis, Sylvia D. *Planning for Educational Technology: the Distance Education Implementation Phase: An Investigation of Technology and Telecommunication Needs for Region One Education Service Center, South Texas Community College, TCI Cablevision of South Texas, Inc., Tech Prep of the Rio Grande Valley, Inc., Texas State Technical College, Centro Cultural en el Valle de Texas, McAllen Independent School District, Harlingen Consolidated Independent School District, Donna Independent School District, Edinburg Consolidated Independent School District, La Joya Independent School District, Mercedes Independent School District, Pharr-San Juan-Alamo Independent School District, Sharyland Independent School District, Easter Seal Society of the Rio Grande Valley, Inc., and McAllen Memorial Library.* Harlingen, Tex.: Tech Prep of the Rio Grande Valley, 1996.

Hall-Ellis, Sylvia D. "Barcodes for the Texas Library Connection." Prepared under the sponsorship of the Office of Technology Services, Texas Education Agency. Austin, Tex.: TENET News and Conferences, March 1995.

Hall-Ellis, Sylvia D. *[et. al.] Planning for Educational Technology: A Study of Future Technology Needs for the Donna Independent School District, Region One Education Region Service Center, Tech Prep of the Rio Grande Valley, Inc. South Texas Community College, and the Department of Library Science, Sam Houston State University.* Research team: Sylvia D. Hall-Ellis, Ruth Ann Riggins, Noe Torres, Patricia G. Bubb, and Michael D. Bell. Harlingen, Tex.: Tech Prep of the Rio Grande Valley, 1994. Funded through a grant award from the Texas Education Agency.

Hall-Ellis, Sylvia D. and Mary Ann Berry. *The Impact of Library Resource Centers on Academic Achievement in Selected Public Schools in South Texas.* Huntsville, Tex.: Sam Houston State University, College of Education and Applied Science, 1993. Funded through a grant award from the Sam Houston State University Research Enhancement Fund.

Hall-Ellis, Sylvia D., Alice Krueger, and Linda Brannan. *Thesaurus Development for National Curriculum Materials Database at the Eisenhower National Clearinghouse for Mathematics and Science Education, Columbus, Ohio.* Developed under the sponsorship of Mid-Continent Regional Educational Laboratory Corporate Library, Aurora, Colo. Washington, D.C.: National Science Foundation; Columbus, Ohio: ERIC Clearinghouse for Mathematics and Science Education, 1993.

Hall-Ellis, Sylvia D. and Clarence L. Coffindaffer. *Partners in Progress: The 1992 Montana Library Federation Study Final Report*. Helena, Mont: Montana State Library and The Blue Bear Group, Inc., 1992.

Hall-Ellis, Sylvia D. and Clarence L. Coffindaffer. *Montana Federation Study Identification Paper*. Denver, Colo.: The Blue Bear Group, Inc., 1992.

Bruntjen, Scott and Sylvia D. Hall. *Recommendations on the Development of System-Wide Efforts of the Northern Waters Library Service.* Ashland, Wisc.: Northern Waters Library Service and The Blue Bear Group, Inc., 1989.

Hall, Sylvia D. *The Iowa Union List of Serials as A Part of The Iowa Locator: Planning Document*. Des Moines, Ia.: State Library of Iowa, 1988.

Hall, Sylvia D. *Iowa Computer-Assisted Network (ICAN Users' Manual. IBM Compatible Edition: Version 7.0.* Des Moines, Ia.: State Library of Iowa, 1988.

Hall, Sylvia D. *Iowa Computer-Assisted Network (ICAN Users' Manual. IBM Compatible Edition: Version 5.0.* Des Moines, Ia.: State Library of Iowa, 1986.

Hall, Sylvia D. *Iowa Computer-Assisted Network (ICAN Users' Manual. Apple MacIntosh Edition: Version 5.0.* Des Moines, Ia.: State Library of Iowa, 1986.

Bruntjen, Scott and Sylvia D. Hall. *The District of Columbia Public Library Planning for Retrospective Conversion of Bibliographic Records and Automation Issues for the 1990's: Final Report*. Central City, Colo.: The Blue Bear Group, Inc., 1986.

Bruntjen, Scott and Sylvia D. Hall. *The Iowa Locator: Final Report.* Central City, Colo.: The Blue Bear Group, Inc., 1986.

Bruntjen, Scott and Sylvia D. Hall. *Discovering Resource Sharing Treasures: Accessing Pennsylvania's High School Library Collections*. Harrisburg, Pa.: State Library of Pennsylvania, Bureau of School Library Media Resources, 1985.

Hall, Sylvia D. *Retrospective Conversion and the Completeness of Cataloging in Pennsylvania High School Libraries.* Pittsburgh, Pa.: PRLC, Inc., 1985.

Bruntjen, Scott and Sylvia D. Hall. *The Iowa Locator.* Des Moines, Ia.: State Library of Iowa, 1985- http://www.statelibraryofiowa.org/ld/silo/locator

Bruntjen, Scott and Sylvia D. Hall. *ICAN Analysis*. Des Moines, Ia.: State Library of Iowa, 1985.

Bruntjen, Scott and Sylvia D. Hall. *Zebras: Bar Codes, Standards, and Library Automation*. Central City, Colo.: The Blue Bear Group, Inc., 1985.

Hall, Sylvia D. and Scott Bruntjen. *Access Pennsylvania.* Harrisburg, Pa.: State Library of Pennsylvania, 1984- http://www.accesspa.org

Hall, Sylvia D. *Reconfiguration of the ITAC Cataloging Data Base to Machine Readable (MARC) Format*. Classified Document. Arlington, Va.: U. S. Army Intelligence and Threat Analysis Center, 1984.

Bruntjen, Scott and Sylvia D. Hall. *South Dakota Library Automation Plan: Final Report*. Pittsburgh, Pa.: PRLC, Inc., 1982. Reprinted by the South Dakota State Library, 1983.

Bruntjen, Scott and Sylvia D. Hall. *Altoona Automation Plan: Final Report prepared for the Altoona Area Public Library and the Altoona District Library Center*. Pittsburgh, Pa.: PRLC, 1983.

Bruntjen, Scott, Sylvia D. Hall and Paul J. Pugliese. *College Space Utilization Study*. Pittsburgh, Pa.: PRLC, Inc., 1983.

Hall, Sylvia D. *Pennsylvania Public Library Film Center Union Catalog Cataloging and Technical Services Procedures Manual*. Pittsburgh, Pa.: PRLC, Inc., 1982.

Hall, Sylvia D. *History of Library Development in Pennsylvania: A Review and Content Analysis of the Plans, 1955-1980*. Pittsburgh, Pa.: PRLC, Inc., 1982.

Hall, Sylvia D. *Newspapers on Microfilm: A Listing of Newspapers in Allegheny, Chemung, Schuyler, Steuben, and Yates Counties*. Ithaca, N.Y.: South Central Reference and Research Council, 1981.

Hall, Sylvia D. *OCLC/ILL Subsystem at Southern Tier Library System.* Albany, N.Y.: SUNY/OCLC Network, 1980.

Hall, Sylvia D. *Retrospective Conversion for Major Public Libraries in South Central New York State: A Technical Report*. 2 vols. Corning, N.Y.: Southern Tier Library System, 1979-1980.

Hall, Sylvia D. *The Librarian and the Mexican-American Patron in Texas.* Austin, Tex.: Texas State Library, 1978.

Other Publications

Hall-Ellis, Sylvia D., ed. *Library and Information Science Program Self-Study Document for Accreditation by the American Library Association.* St. Paul, MN: St. Catherine University, 2017. 255 p.

Hall-Ellis, Sylvia D., and Robert O. Ellett, Jr., guest editors. *RDA Testing: Lessons Learned and Challenges Revealed: A Special Issue of Cataloging & Classification Quarterly* 49, no. 7-8 (November 2011).

Hall-Ellis, Sylvia D. and Robert O. Ellett, Jr. *Fundamentals of Cataloging I: An Online ALCTS Course.* Chicago, Ill.: American Library Association, 2009.

Hall-Ellis, Sylvia D., Angela J. Kinney and Martha Ann Bace, editors. *Best Practices in Cataloging Education Identified at the 2007 ALCTS Pre-conference: A Special Issue of the Journal for Library and Information Science Education* 49, no. 2 (Spring 2008).

Hall-Ellis, Sylvia D. *Cataloging Education: A New Emphasis for the Library and Information Science Curriculum.* Presentation delivered to the ALCTS Pre-conference, 132nd Annual Conference, American Library Association, Washington, D.C., June 22, 2007. http://www.loc.gov/aba/professional/

Hall-Ellis, Sylvia D. "*Cataloger Competencies: Do the Employers Require What the Professors Teach?*" Presentation delivered to the ALCTS CCS Heads of Cataloging Discussion Group, 131st Annual Conference, American Library Association, New Orleans, Louisiana, June 26, 2006. http://dlist.sir.arizona.edu/

Hall-Ellis, Sylvia D., guest editor, with Deborah S. Grealy, Clara L. Sitter, and Tassos Petrou. *Library Students' Voices in Colorado: An Issue of Colorado Libraries* 31:1 (Spring 2005).

Hall-Ellis, Sylvia D., ed. *Library and Information Science Program Self-Study Document for Accreditation by the American Library Association.* Denver, Colo.: University of Denver, College of Education, 2003. 125 p. with CD-ROM.

Hall-Ellis, Sylvia D. and Deborah S. Grealy, guest editors. *Library Education in Colorado: An Issue of Colorado Libraries* 29, no. 2 (Summer 2003).

Hall-Ellis, Sylvia D., ed. *Library and Information Science Program Self-Study Document for Accreditation by the American Library Association.* Denver, Colo.: University of Denver, College of Education, 2003.

Hall-Ellis, Sylvia D. "Adaptive Furniture for the ADA-Qualified: An Investigative Study." 2001. Unpublished manuscript.

Hall-Ellis, Sylvia D. "Cataloging Electronic Serials: A Study in User Access and Article Delivery." 2001. Unpublished manuscript.

Hall-Ellis, Sylvia D. "E-books: Acquisition and Circulation Issues in Public Libraries." 2001. Unpublished manuscript.

Hall-Ellis, Sylvia D. "Authority Control and Its Importance in School Library Media Online Catalogs." 1999. Unpublished manuscript.

Hall, Sylvia D. "Cooperation Improving Service in San Antonio System." *Texas Libraries* XXXVII (Spring 1976): 27-29.

Hall, Sylvia D. "Summer is Sea Monstrously Fun!" *Texas Library Journal* L (December 1974): 224-226.

Hall, Sylvia D. "A Brief Annotated Bibliography of Non-book Materials on the Mexican American." *Texas Library Journal* XLVIII (October 1972): 213-232.

Book Reviews

ALA Book of Library Grant Money. Ann Kepler, ed. 8th ed. Chicago, IL: American Library Association, 2011. 978-0-8389-1058-0, $175.00 [*Colorado Libraries,* June 2012]

Developing a Compensation Plan for Your Library. Paula M. Singer and Laura L. Francisco, comps. 2nd ed. Chicago, IL: American Library Association, 2009. 978-0-8389-0985-0, $57.00 [*Colorado Libraries,* March 2012]

Frugal Librarian. Carol Smallwood, ed. Chicago, IL: American Library Association, 2011. 978-0-83891-075-7, $42.00 [*Colorado Libraries,* February 2012]

Dowlin, Ken. *Getting the Money: How to Succeed in Fundraising for Public and Nonprofit Libraries.* Westport, Conn.: Libraries Unlimited, 2008. 978-1-59158-597-X, $50.00 [*Colorado Libraries,* February 2009]

Lundahl, Mats. *Bebo de Cuba; Bebo Valdés y Su Mundo*, by Mats Lundahl. Traducción de Linda Oakeshott Dragó. Barcelona: RBA Libros, 2008. 978-849-86-7259-6, $33.99 [*Críticas*, November 2008]

Bonelli, Florencia. *Marlene*, by Florencia Bonelli. Buenos Aires: Aguilar, Altea, Taurus, Alfaguara, 2008. 978-987-04-0995-3, $24.95 [*Críticas*, October 2008]

Keret, Etgar. Traducción de Ana María Bejarano. *Pizzería Kamikaze y Otras Relatos.* México, D.F.: Editorial Sexto Piso, 2008. 968-5679-29-0, no price given [*Críticas*, September 2008]

Littauer, Marita, and Florence Littauer. *Enriquece tu Comunicación. Miami, Fla.: Editorial Unilit, 2008.* 978-0-7899-1521-4, $11.99 [*Críticas*, August 2008]

Martínez, Guillermo. *La Muerte Lenta de Luciana B.* New York: Rayo Planeta, 2008. 978-0-06-156551-9, $14.95 [*Críticas*, May 2008]

Matthews, Joseph R. *The Evaluation and Measurement of Library Services.* Westport, Conn.: Libraries Unlimited, 2007. 978-1-59158-532-9, $50.00 [*Colorado Libraries,* April 2008]

Gómez-Jurado, Juan. *A Masacre de Virginia Tech: Anatomía de una Mente Torturada.* Barcelona: Ediciones El Andén, 2007. 978-84-935789-4-7, €16.50 [*Críticas*, February, 2008]

Matthews, Joseph R. *Library Assessment in Higher Education.* Westport, Conn.: Libraries Unlimited, 2007. 978-1-59158-531-2, $45.00 [*Colorado Libraries,* February 2008]

Chacón, Inma. *La Princesa India: Cuando el Viento Azul.* México: Alfaguara, 2006. 970-770398-9, $19.95 [*Críticas*, June 2006]

Vargas Llosa, Mario. *Israel/Palestina: Paz o Guerra Santa.* fotogs. by Morgana Vargas Llosa. Spain/U.S.: Aguilar: Santillana, 2006. 84-03-09691-7, paper, $19.95 [*Críticas*, May 2006]

Findlay, Diane. *Digging into Dewey.* Fort Atkinson, Wisc.: Upstart Books, 2005. 978-1-932146-18-9, $16.95 [*Colorado Libraries,* May 2006]

Pequeñas Resistencias 4: Antología del Nuevo Cuento Norteamericano y Caribeño. Menéndez, Ronaldo, Ignacio Padilla & Enrique del Risco, eds. Madrid**:** Páginas de Espuma, 2005. 84-95642-59-X, paper, $36.95 [*Críticas*, April 2006]

Rueda, André. *Vengo a Salvar a España: Biografía de Un Franco Desconocido.* Madrid**:** Nowtilus (Investigación Abierta), 2005. photogs., bibliog. 84-9763-202-8, paper, $23.95 [*Críticas*, March 2006]

Becerra, Ángela. *El Penúltimo Sueño.* 1st ed. Barcelona: Planeta, 2005. 84-08-05795-2, $25.95. [*Críticas*, January 2006]

Aguilar Camín, Héctor. *La Conspiración de la Fortuna.* 1st ed. México: Planeta, 2005. 970-37-0368-2, $19.95 [*Críticas*, October 2005]

México en Sus Libros. Enrique Florescano with Pablo Mijangos, editors & compilers. 1st ed. México, D.F.: Taurus Aguilar, 2004. 968-19-0783-3, $16.95 [*Críticas*, September 2005]

Historia Económica de México. Coordinator, Enrique Semo. México: Universidad Nacional Autónoma de México, Editorial Oceano de México, 2004. 13 vols. 970-32-0805+3 (obra completa), $9.25 each [*Críticas*, August 2005]

Czarnowsky, Christyne A. and Michael H. Williams. *Managing Your Wired Workforce: A Practical Guide.* Denver, Colo.: Bradford Pub., 2003. 1-883726-79-4, $24.95 [*Colorado Libraries,* 2004]

Abraham Lincoln. Colección Grandes Biografías. Madrid: Edimat Libros, 2003. 84-8403-858-0, €4.95 [*Críticas*, 2004]

Alponte, Juan María. *Colón: el Hombre, el Navegante, la Leyenda.* México, D.F.: Aguilar, 2003. 968-19-1260-8, $16.95 [*Críticas*, 2004]

Olcese Salvatecci, Alfieri. *Cómo Estudiar con Ėxito: Téchnicas yHhábitos Para Aprender Major.* México, D.F.: Alfaomega Grupo Editor, 2002. 970-15-0764-9 [*Críticas*, 2003]

Mujeres Como Islas: Antología de Narradoras Cubanas, Dominicanas, Puertoriqueñas. Edición: Olga Marta Pérez, Thelma Jiménez, Andrés Blanco D., eds. Santo Domingo, República Dominicana: Ediciones Ferilibro, 2002. 959-209-419-5 [*Críticas*, 2003]

Tibol, Raquel. *Los Murales de Diego Rivera: Universidad Autónoma Chapingo.* México, D.F.: Editorial RM, Universidad Autónoma Chapingo, 2002. 968-5208-08-5 [*Críticas*, 2003]

Lindsay-Poland, John. *Emperors in the Jungle: the Hidden History of the U.S. in Panama.* Durham, N.C.: Duke University Press, 2003. 0-8223-3098-9, $18.95 [*Críticas*, 2003]

Kaplan, Allison G. and Ann Marlowe Riedling. *Catalog It! A Guide to Cataloging School Library Materials.* Worthington, Ohio: Linworth Pub., 2002. 1-58683-014-7, $44.95 [*Colorado Libraries,* 2002]

Bardach, Ann Louise. *Cuba Confidential: Love and Vengeance in Miami and Havana.* New York: Random, 2002. 0-375-50489-3, $25.95 [*Library Journal*, 2002]

Swan, James. *Fundraising for Libraries: 25 Proven Ways to Get More Money for Your Library.* New York: Neal Schuman, 2002. 1-55570-433-6, $69.95 [*Colorado Libraries,* 2002]

Puíg de Lange, Victoria. *Sol Con Agua.* Nashville, Tenn.: Editorial Vistazo/Ediciones Reio Negro, 2002. 0-9724506-0-2, $17.75 [*Críticas*, 2002]

The Encyclopedia of Latin American Politics. Edited by Diana Kapiszewski; assistant editor, Alexander Kazan. Westport, Conn.: Oryx Press, 2002. 1-57356-306-4, $74.95 [*Library Journal*, 2002]

Vargas Lizano, Isabel. *Y Si Quieres Saber de Mi Pasado.* Con la colaboración de J.C. Vales. Madrid: Santillana Ediciones Generales, S.L., 2002. 84-03-09278-4, $18.95 [*Críticas*, 2002]

Ruy Sánchez, Alberto. *Los Jardines Secretos de Mogador: Voces de Tierra.* México, D.F.: Alfaguara, S.A., 2001. 968-19-0879-1, $16.95 [*Críticas*, 2002]

Chávez, Ricardo and Celso Santajuliana. *El Final de las Nubes.* Barcelona: RBA Libros, S.A., 2001. 84-7901-760-0, $11.95 [*Críticas*, 2002]

The Power of Language / El Poder de la Palabra: Selected Papers from the Second REFORMA National Conference. Edited by Lillian Castillo-Speed and the REFORMA National Conference Publications Committee. Englewood, Colo.: Libraries Unlimited, 2001. 1-563089459, $35.00 [*Colorado Libraries,* 2001]

Martínez, Rubén. *Crossing Over: A Mexican Family on the Migrant Trail.* Metropolitan: Holt, 2001. 0-8050-4908-8, $26.00 [*Library Journal*, 2001]

Guevara, Ernesto "Che." *The African Dream: the Diaries of the Revolutionary War in the Congo.* Translated from the Spanish by Patrick Camiller. With an introduction by Richard Gott and a foreword by Aleida Guevara March. New York: Grove Press, 2001. 0-8021-3834-9, $13.00 [*Library Journal*, 2001]

Cooper, Gail and Garry Cooper. *New Virtual Field Trips.* Englewood, Colo.: Libraries Unlimited, 2001. 1-56308-887-8, $27.50 [*Colorado Libraries,* 2001]

NATIONAL SERVICE & PROFESSIONAL AFFILIATIONS

American Library Association, Life Member
Association for Library Collections & Technical Services (now CORE)
Cataloging, Classification, and Metadata Section
Awards & Scholarships Coordination Committee, 2025-
Margaret Mann Citation Committee, 2023-
ALCTS Editorial Board, Member, 2015-2019
Committee on Cataloging: Description and Access, Member, 2008-2012
Test Site for RDA, Manager, 2009-2011
Nominating Committee, Member, 2007-2008
Committee for Education and Training of Catalogers, Chair, 2006-2007, Member, 2003-2007
Competencies & Education for a Career in Cataloging Interest Group, Chair, 2010-2012; Member, 2010-
President's Program Committee, 2015-2016
Education Committee, Member, 2005-2007
Task Force on Competencies and Education for a Career in Cataloging, Chair, 2007-2009
2007 Annual Meeting Pre-conference, "What They Don't Teach in Library School: Competencies, Education and Employer Expectations for a Career in Cataloging," Steering Committee Chair
Fundraising Committee, Member, 2004-2006
Office of Diversity
Committee on Diversity, Chair, 2010-2011
Diversity Research Advisory Committee, Member, 2009-2010
Spectrum Scholar Mentor, 2009
Diversity Grants Review Committee, Member, 2007, 2010, 2012
Office of Statistics and Research
Research and Statistics Committee, Member, 2005-2007; Intern, 2003-2005
Library Research Round Table
Nominating Committee, 2022-2023
Membership Committee, 2019-2021
Board of Directors, Member At-Large, 2009-2012
Office of Accreditation
Accreditation Panel Member (training completed 2004)
Accreditation Review Panel Member (training completed 2004)

REFORMA, Life Member
National Board of Directors, 2005-2013
National Fundraising Chair, 2005-2013
National Recruiting and Mentoring Committee, 2008-2010
Colorado Chapter, Secretary, 2004-2005
Colorado Chapter Liaison to National Board of Directors, 2004-2013

American Association of Law Libraries (AALL), Life Member Online Audiovisual Catalogers Association (OLAC) Colorado Association of Law Librarians (CoALL)

American Association of University Women Association for Library and Information Science Education (ALISE)
University of Denver ALISE Representative, 2003-2008; 2010-2011
Membership Advisory Committee, 2007-2010
Technical Services Education Special Interest Group, 2003-
Garfield Doctoral Dissertation Award Reviewer, 2012
Garfield Doctoral Dissertation Scholarship Reviewer, 2014

American Association of University Professors (AAUP), 2006-
American Grant Writers Association, 2014- Grant Professionals Institute, 2016- National Grants Management Association, 2014-
Grant Reviewer (National and Regional Team Leader), U.S. Department of Education, 1998- Grant Reviewer, Broadband Technologies Opportunity Program, U.S. Department of Commerce, 2009
Grant Reviewer, Institute of Museum and Library Services, 1998-2000
Grant Reviewer, Colorado Department of Education, 2014-
Grant Reviewer, Colorado State Library, 1998-
Grant Reviewer, American Association of Community Colleges *Working Connections* program, 1999
Peer Reviewer, *Journal for Library and Information Science Education,* 2005-
Peer Reviewer, *Journal of Library Metadata,* 2009
Peer Reviewer, *International Journal of Library and Information Science,* 2011
Regular Columnist, *The Bottom Line*, 2013-2016
Book Reviewer, *Library Journal*, 2001
Book Reviewer, *Críticas*, 2002-2009
Book Reviewer, *Colorado Libraries,* 2000-2012

REGIONAL SERVICE & PROFESSIONAL AFFILIATIONS

Mountain Plains Library Association
Professional Development Grants Committee, Member, 2005-2006
Professional Development Policy and Guidelines Sub-committee Chair, 2006

Colorado Association of Libraries
"Student Voices" Column Editor, *Colorado Libraries,* 2005-2006
Conference Planning Committee, Member, 2002
Technical Services and Automation Division, Chair, 2002-2003; Member, 2000-
Academic Libraries Division, Peer Review Conference Papers Committee, Member, 2007-2009
Education Committee, Member, 1988-1993
Diverse Populations Committee, Member, 2009-2013

SERVICE TO THE UNIVERSITY OF DENVER
Center for Teaching and Learning Faculty Advisory Board, 2007-2008; 2010-2012
Center for Community Engagement and Service Learning Advisory Board, 2007-2012
Faculty Senate
Executive Committee, 2008-2013
Nominations, Rules & Credentials Committee, Chair, 2008-2013; Member 2007-2013
Appointment, Promotion, and Tenure Revision Committee, 2010-2012
Grievance Policy Committee Member, 2007-2010
Law Library Director Search Committee Chair, 2012-2013
PROF Grant Review, College Representative to the University Review Team, 2006, 2008
Project Homeless Connect Evaluations, Principal Investigator, 2006-2009
University Technology Council, 2007-2009
University of Denver Hyde Interviews for Incoming Freshmen, 2003-2012

SERVICE TO THE MORGRIDGE COLLEGE OF EDUCATION
Appointment, Tenure & Review Committee
Member, voting, 2003-2005; 2007- 2009
Chair, Clinical Faculty Promotion & Tenure Policy Subcommittee, 2008-2009
Member, Community Engagement Subcommittee, 2007-2009
Member, Tenure Review Panel, 2003
Advancement and Alumni Relations Committee, Chair, 2003-2007; Member, 2002-2007

College Building Committee Member, 2004-2010
College of Education Student Association, Faculty Advisor, 2004-2007; 2009-2010
Faculty Senator, 2007-2013
Research and Scholarship Committee, Chair, 2008-2009; Member, 2002-2003, 2008-2009
Research and Grant Mentoring Committee, Chair, 2009-2010
Research Task Force Member, 2010-2012
Search Committee Member, Assistant Professor for Curriculum & Instruction, 2010-2011
Workload Task Force Member, 2010-2011

SERVICE TO THE LIBRARY & INFORMATION SCIENCE PROGRAM

Library and Information Science Student and Alumni Association, Faculty Advisor, 2002-2008
ALA Student Chapter, Faculty Advisor, 2005-2008
Beta Phi Mu Phi Chapter, Faculty Advisor, 2004-2014
Steering Committee Member, Accreditation by the American Library Association, 2001-2004
Search Committee Member, Associate Professor for LIS, 2006
Search Committee Chair, Assistant Professors for LIS, 2003, 2005, 2006, 2007
Search Committee Ex-Officio Member, Director for LIS, 2004

SERVICE TO SAM HOUSTON STATE UNIVERSITY

Rio Roundup: South Texas Literature Conference, Conference Coordinator, 1993
External Relations, Fund Raising, Grants Committee, Chair, 1993-1995
Advisory Council Committee, Chair, 1993-1995
Students, Admissions, and Advisement Committee, Chair, 1994
Institutional Effectiveness Committee, Member, 1993-1995

SERVICE TO THE COLLEGE OF EDUCATION AND APPLIED SCIENCE

Faculty Affairs Committee, Member, 1993-1995
Curriculum Committee, Member, 1993-1995
Continuing Education Committee, Member, 1993-1995

SERVICE TO THE COMMUNITY

French Teacher & Student Exchange with Laon, France, Monarch High School, Boulder Valley School District (Boulder, Colorado), 2017-
Denver/Boulder Games 2022, Board of Directors, Secretary-Treasurer, 2015-2018
United Way Campaign Committee, College of Education, 2006
Arapahoe County, Election Judge for the County Clerk and Recorder, 2000-2005
Arthritis Foundation, Rocky Mountain Chapter, Certified Educator & Trainer, 1999-2008
Bonfils Blood Center, Silver Level Donor, 2000-2016
Denver Museum of Natural History, Docent, 1992
Tech Prep of the Lower Rio Grande Valley, Inc. (Harlingen, Texas) Board of Directors, 1995-1997
Executive Committee, 1996-1997; Chair, Development Committee, 1995-1997; Chair, Fiscal Agency Committee, 1995-1996; Chair, Colleges and Universities Committee, 1996-1997
Gilpin County (Colorado) Public Library Board of Trustees, 1986-1989; Vice President, 1987-1989
City of Central (Colorado) Economic Development Committee, 1987-1989
Columbine Family Health Centers, Inc. (Nederland and Black Hawk, Colorado) Board of Directors, 1988-1989

CERTIFICATION

Permanent Public Librarian Certificate - Pennsylvania, New York, Texas
Westlaw Expert Witness, 2008-
Certified Grant Writer®, 2016-

AWARDS AND HONORS

Advanced Practitioner for Service Learning and Community Engagement, University of Denver, 2011
Platinum Star Alumnae, College of Information, Library Science & Technologies, University of North Texas, 2009
Commendation for Integration of Technologies in Teaching & Learning Environment, University of Denver, 2006
Outstanding Adjunct Faculty Member Award, College of Education, University of Denver, 2002
Beta Phi Mu, Pi, University of Pittsburgh, 1985
Alpha Lambda Sigma, University of North Texas, 1972
Albert Nelson Marquis Lifetime Achievement Award, Who's Who in America
Who's Who in American Women
Who's Who of Women Executives
Dictionary of International Biography
Who's Who in the East
Who's Who in the South and Southwest
Who's Who in the World
Who's Who of Online Professionals
Who's Who in Library and Information Science
2,000 Notable Women
Who's Who of Emerging Leaders
Who's Who in Professional and Executive Women
Who's Who in American Education
International Who's Who of Professional and Business Women
International Leaders in Achievement
International Educator of the Year
Who's Who in Finance and Industry
Who's Who in Finance and Business

Invited International and National Conference Presentations

Hall-Ellis, Sylvia D. *Presentation of the Robert O. Ellett Endowed Scholarship.* Presentation delivered to the School of Information at San Jose State University Alumni & Student Program, American Library Annal Conference, San Diego, Calif., June 29, 2024.

Driscoll, Margaret, Christy Confetti Higgins, Scott Brown, and Sylvia D. Hall-Ellis. *A View from Within: Open House Tour of Three Canvas Core Courses*. Presentation to be delivered at the School of Information, San José State University Professional Development Seminar, San José, California, October 17, 2019.

Hall-Ellis, Sylvia D. *Invest in Me -- I'm Your Future: Succession Planning for Libraries.* Keynote presentation delivered at the ALCTS President's Symposium, Boston, Mass., January 8, 2016.

Seidel, Kent E. and Sylvia D. Hall-Ellis. *Making Grants Work for You: Strategies for Doctoral Students and Early Career Scholars.* Presentation delivered at the University Council for Educational Administration, Early Career Scholars Session, Indianapolis, Ind., November 9, 2013.

Hall-Ellis, Sylvia D. *So You Want to be a Manager; Leadership Skills and Competencies for Technical Services Managers and Administrators.* Presentation delivered at the 138th Annual Conference, American Library Association, Chicago, Ill., June 29, 2013.

Seidel, Kent E., Karen S. Riley, Lyndsay Agans, Susan Korach, and Sylvia D. Hall-Ellis. *Making Grants Work for You (Instead of Just Working for Grants).* A panel discussion delivered at the University Council for Educational Administration, Early Career Scholars Session, Denver, Colo., November 17, 2012.

Hall-Ellis, Sylvia D. *After the Great TS Reorganization: The Westminster Law Library.* Presentation delivered at the 137th Annual Conference, American Library Association, Anaheim, Calif., June 23, 2012.

Hall-Ellis, Sylvia D. *Conversations with Catalogers in the 21st Century.* A panel discussion sponsored by the ALCTS Competencies for a Career in Cataloging Interest Group, delivered at the 137th Annual Conference, American Library Association, Anaheim, Calif., June 22, 2012.

Hall-Ellis, Sylvia D., moderator. *Mid-Career Leaders Program.* A panel discussion sponsored by the ALA Committee on Diversity delivered at the 136th Annual Conference, American Library Association, New Orleans, La., June 26, 2011.

Hall-Ellis, Sylvia D., moderator. *Diversity Town Hall.* A community conversation sponsored by the ALA Committee on Diversity delivered at the 136th Annual Conference, American Library Association, New Orleans, La., June 24, 2011.

LaBarre, Kathryn, Sylvia D. Hall-Ellis, Karen Anderson, Rick Hasenyager, Christopher Cronin, and Penny Baker. *Briefings from RDA Test Participants.* A panel discussion delivered at the Midwinter Conference, American Library Association, San Diego, Calif., January 7, 2011.

Miksa, Shawne, Marjorie Bloss, and Sylvia D. Hall-Ellis. *Educating the Next Generation of Catalogers: Teaching RDA.* A panel discussion delivered at the 97th Annual Conference, Association for Library and Information Science Education, San Diego, Calif., January 7, 2011.

Hall-Ellis, Sylvia D., Robert Maxwell, John Hostage, and George Prager. *RDA Panel: What Cataloging Managers Need to Know.* Presentation delivered at the 103rd Annual Conference, American Association of Law Librarians, Denver, Colo., July 12, 2010.

Hall-Ellis, Sylvia D. and Stacey L. Bowers. *Catalogers in the RDA Environment: Skill Sets, Expectations and Challenges.* Presentation delivered at the 103rd Annual Conference, American Association of Law Librarians, Denver, Colo., July 11, 2010.

Hall-Ellis, Sylvia D. *Comfortable in Your Cataloging and Metadata Specialist Skin? Or, So You Want to Hire a Cataloger.* Presentation delivered to the ALCTS Research Group at the 134th Annual Conference, American Library Association, Chicago, Ill., July 11, 2009.

Perez, Megan, Sylvia D. Hall-Ellis, and Denise Anthony. *From Novice to Expert: Collaboration for Succession Planning.* A "hot topic" presentation delivered at the 14th ACRL Conference, Seattle, Wash., March 13, 2009.

Hall-Ellis, Sylvia D. *Cataloging in the RDA Environment: Skill Sets, Expectations and Challenges.* Presentation delivered to the ALCTS Research and Publications Committee at the Midwinter Conference, American Library Association, Denver, Colo., January 24, 2009.

Hall-Ellis, Sylvia D. *LIS Cataloging Education for the 21st Century: Expectations and Challenges.* A panel discussion held at the 95th Annual Conference, Association for Library and Information Science Education, Denver, Colo., January 23, 2009.

Chu, Clara, Sylvia D. Hall-Ellis, and Mark Winston. *The Doctoral Degree & Building a Career.* A panel discussion delivered at the ALA Office of Diversity Spectrum Doctoral Fellows E.J. Josey Leadership Institute, Midwinter Conference, American Library Association, Denver, Colo., January 20, 2009.

Hall-Ellis, Sylvia D. and Robert O. Ellett, Jr. *Fundamentals of Cataloging Course: An Overview of the ALCTS Online Course.* Presentation delivered to the ALCTS Big Heads Group, 133rd Annual Conference, American Library Association, Anaheim, Calif., June 30, 2008.

Hall-Ellis, Sylvia D. *Employers' Expectations for Technical Services Librarians: What We Don't Know.* Presentation delivered to the ALCTS Research and Publications Committee Program, 133rd Annual Conference, American Library Association, Anaheim, Calif., June 28, 2008.

Hall-Ellis, Sylvia D., Virginia R. Maloney, and Mary Stansbury. *Institutional Responses to Engaged Scholarship: The Carnegie Foundation Engaged University Classification at Two Universities.* Presentation delivered to the 94th Annual Conference, Association for Library and Information Science Education, Philadelphia, Pa., January 11, 2008.

Hall-Ellis, Sylvia D. *Puzzles, Problems, and Predicaments.* Presentation delivered to the ALCTS Research Discussion Group, 132nd Annual Conference, American Library Association, Washington, D.C., June 23, 2007.

Hall-Ellis, Sylvia D. *Cataloging Education: A New Emphasis for the Library and Information Science Curriculum.* Presentation delivered to the ALCTS Pre-conference, 132nd Annual Conference, American Library Association, Washington, D.C., June 22, 2007. http://www.loc.gov/catdir/cpso/careercat.html

Ellett, Jr., Robert O. and Sylvia D. Hall-Ellis. *Copy Cataloging Done Smarter.* Presentation delivered to the International Conference on Interdisciplinary Information Sciences and Technologies (InSciT2006), October 25-28, 2006.

Hall-Ellis, Sylvia D. and Robert O. Ellett, Jr. *Cooperative Cataloging: Challenges and Opportunities for Defense Libraries.* Presentation delivered to the 1st Annual Conference of Defense Libraries, Spanish Ministry of Defense, Madrid, Spain, July 7, 2006.

Hall-Ellis, Sylvia D. *Cataloger Competencies: Do the Employers Require What the Professors Teach?* Presentation delivered to the ALCTS CCS Heads of Cataloging Discussion Group, 131st Annual Conference, American Library Association, New Orleans, La., June 26, 2006.

Grealy, Deborah S. and Sylvia D. Hall-Ellis. *From Research to Practice: The Scholarship of Teaching and Learning in LIS Education.* Presentation delivered to the at the 92nd Annual Conference, Association for Library and Information Science Education, San Antonio, Tex., January 18, 2006.

Hall-Ellis, Sylvia D. *Employers' Expectations for Entry-Level Catalogers: What Position Announcement Data Indicate.* Research paper delivered to the Technical Services Special Interests Group, 91st Annual Conference, Association for Library and Information Science Education, Boston, Mass., January 12, 2005. http://dlist.sir.arizona.edu/

Hall-Ellis, Sylvia D. *Common Errors in MARC Records Prepared by LIS Students: What Does It Mean?* Research paper delivered to the ALCTS CCS Cataloging Norms Discussion Group, Mid-Winter Conference, 90th American Library Association, San Diego, Calif., January 10, 2004.

Hall-Ellis, Sylvia D. *Visual Arts as Foundation for Successful Library Automation: The Rocky Mountain College of Art & Design Experience.* Paper delivered at the 6th Annual Conference of Higher Education, Charleston, S. C., 1993.

Hall, Sylvia D. *Design Elements for Bibliographic Databases: An Overview.* Paper delivered at the 14th Online National Conference, New York, 1983.

Invited Regional Conference Presentations

Hall-Ellis, Sylvia D., Hudson, Christopher D., Brittany Cronin, and Kathryn Michaels. "The Colorado Law Project: Meeting the Public's Need for Legal Information." Panel discussion delivered at the Mountain Plains Library Association Conference, Billings, Mont., April 9, 2011.

Grealy, Deborah S. and Sylvia D. Hall-Ellis. *Education for Information Professionals in New Mexico: Library & Information Science Graduate Education at the University of Denver.* Presentation delivered at the New Mexico Library Education Summit, Las Vegas, N.M., September 26, 2005.

Hall-Ellis, Sylvia D. *Public Library-School Library Partnerships.* Presentation delivered at the 3rd Annual Colorado Association of Libraries Conference with the Mountain Plains Library Association, Denver, Colo., October 22, 2004.

Hall-Ellis, Sylvia D. *Learn All You Can – Educational Partnership Opportunities for the Lewis and Clark Bicentennial Commemoration.* Paper delivered at the 3rd Annual Lewis and Clark Bicentennial Council National Planning Conference, Bismarck, N.D., April 26, 1998.

Invited State Conference Presentations

Grealy, Deborah S. and Sylvia D. Hall-Ellis. *Academic Library Leadership Changes: Using Succession Planning and Mentoring*. Presentation delivered at the Minnesota Library Education Conference, St. Cloud, Minn., October 10, 2013.

Hall-Ellis, Sylvia D., Merrie Valliant, and Melissa Powell. *RDA: What Is It and What Do You Need To Do With It At Your Library?* Presentation delivered at the Colorado Library Consortium Spring Conference, Ft. Morgan, Colo., April 26, 2013.

Hall-Ellis, Sylvia D. *Service Learning and the Library & Information Science Graduate Education at the University of Denver.* Presentation delivered at the 4th LEADS Scholars Orientation, Denver, Colo., August 5, 2009.

Hall-Ellis, Sylvia D. *Service Learning: Enhancement to Library & Information Science Graduate Education at the University of Denver.* Presentation delivered at the 3rd LEADS Scholars Orientation, Denver, Colo., June 2008.

Hall-Ellis, Sylvia D. *Law Librarianship: A Community Conversation.* Sponsored by the Colorado Association of Law Libraries. Paper delivered at the Colorado Supreme Court Library, Denver, Colo., May 14, 2008.

Hall-Ellis, Sylvia D. *Opportunities and Challenges in Law Librarianship: A Community Conversation.* Presentation delivered at the Sturm College of Law, Denver, Colo., November 7, 2007.

Ellis, Sylvia D. *Grant Writing Resources for Nursing Professionals.* Presentation delivered at the Presbyterian / St. Luke's Health One Medical Center 1st Annual Research Symposium, Denver, Colo., October 17, 2007.

Hall-Ellis, Sylvia D. *Project Homeless Connect 4 Event Evaluation – Insights and Lessons Learned.* Presentation delivered at the Homelessness Research Symposium: What is DU Doing about Homelessness in Denver, Denver, Colo., September 14, 2007.

Hall-Ellis, Sylvia D. *Service Learning and the Library & Information Science Graduate Education at the University of Denver.* Presentation delivered at the 2nd LEADS Scholars Orientation, Denver, Colo., August 10, 2007.

Hall-Ellis, Sylvia D. *Education for Information Professionals in a Digital Environment: Library & Information Science Graduate Education at the University of Denver.* Presentation delivered at the 15th Spring Mountains and Plains Parapros Conference, Denver, Colo., February 24, 2007.

Hall-Ellis, Sylvia D. *Public Library Service to Spanish-Speaking and Latino Residents in Denver: A Case Study.* Presentation delivered at the 4th Annual Colorado Association of Libraries Conference, Denver, Colo., November 10, 2005.

Hall-Ellis, Sylvia D. *Education for Information Professionals in a Digital Environment: Library & Information Science Graduate Education at the University of Denver.* Presentation delivered at the 14th Annual Mountains and Plains Parapros Conference, Aurora, Colo., July 29, 2005.

Hall-Ellis, Sylvia D. *Educational Opportunities: Library & Information Science Graduate Education at the University of Denver.* Presentation delivered at the 13th Annual Mountains and Plains Parapros Conference, Centennial, Colo., August 6, 2004.

Hall-Ellis, Sylvia D. *Library Education & Training: Focus on the West: An LIS Faculty Member's Personal Response*. Presentation delivered at the 1st Annual Colorado Association of Libraries Conference, Keystone, Colo., October 18, 2002.

Hall-Ellis, Sylvia D. *Grant Writing for School Librarians.* Presentation delivered at the 2002 Annual Colorado Education Media Association Conference, Colorado Springs, Colo., February 15, 2002.

Hall-Ellis, Sylvia D. *Grants – Opportunities for the Future.* Paper delivered at the Southeast Regional Accountability Annual Conference, Lamar, Colo., November 12, 1998.

Hall-Ellis, Sylvia D. *The Texas Library Connection and Interlibrary Loan: An Experiment in Resource Sharing.* Paper delivered at the Texas Computer Educators' Association Annual Conference, Austin, Tex., February 6, 1997.

Hall-Ellis, Sylvia D. *Finding Grant Sources on the Internet: A Guide for Librarians.* Paper delivered at the 2nd Annual Institute for School Library Personnel, Pharr-San Juan-Alamo North High School, Pharr, Tex., July 29, 1996**.**

Hall-Ellis, Sylvia D. *Mathematical and Logical Thinking: A Critical Intelligence.* Paper delivered at the 3rd Annual Paraprofessional Conference at the University of Texas - Pan American, Edinburg, Tex., March 8, 1996.

Hall-Ellis, Sylvia D. *Cataloging Trends and Issues: Update Session.* Paper delivered at the 1st Annual Institute for School Library Personnel, South Texas Community College, McAllen, Tex., July 19, 1995.

Hall-Ellis, Sylvia D. *Grant Writing: Tips and Encouragement for School Librarians.* Paper delivered at the 1st Annual Institute for School Library Personnel, South Texas Community College, McAllen, Tex., July 18 and 19, 1995.

Hall-Ellis, Sylvia D. *How to Become an Expert Grant Writer.* Paper delivered at the 3rd Annual High School Principals' Academy, South Padre Island, Port Isabel, Tex., June 19, 1995.

Texas Library Study: Results from Regions I and II. Paper delivered at the 3rd Annual Technology Conference, Texas A&M University, College Station, Tex., November 18, 1994.

Hall-Ellis, Sylvia D. *Academic Achievement and Middle School Students.* Paper delivered at the 8th Annual Young Adult Conference, Sam Houston State University, Huntsville, Tex., November 5, 1994.

Hall-Ellis, Sylvia D. *Multimedia Resources for Library Leaders.* Paper delivered at the Institute for Librarians in A Multicultural Environment, Sam Houston State University, Huntsville, Tex., June 10, 1994.

Hall-Ellis, Sylvia D. *Finding the Resource: Empowering the User, or, the Case for Curriculum Based Subject Access to Learning Resource Center Collections.* Paper delivered at the 81st Annual Texas Library Association Conference, Corpus Christi, Tex., April 12-16, 1994.

Hall-Ellis, Sylvia D. and William H. Pichette. *Sam Houston State University Makes Use of OCLC/AMIGOS Collection Analysis CD.* Paper delivered at the 81st Annual Texas Library Association Conference, Corpus Christi, Tex., April 12-16, 1994.

Hall, Sylvia D. *Funding and Library Development in Pennsylvania: A Symbiotic Relationship.* Paper delivered at the Annual Graduate Student Colloquia, University of Pittsburgh, School of Library and Information Science, 1982.

Hall, Sylvia D. *Leadership for Public Library Trustees.* Paper delivered for the Trustees Division, Pennsylvania Library Association Annual Conference, Lancaster, Penn., 1981.

Seminar and Professional Development Presentations

Taylor, Meredith, and Sylvia D. Hall-Ellis. *Talent Management and Succession Planning.* ALCTS eForum, held March 22, 2017.

Hirsh, Sandra, Heather O'Brien, Michelle Holschuh Simmons, Michael Krasulski, and Sylvia D. Hall-Ellis. *Information Services Today: An Introduction. Part 3: Information Services: Roles in the Digital Age*. Rowan and Littlefield in partnership with Library Journal webinar, recorded February 5, 2015.

Hall-Ellis, Sylvia D. and Jennifer Sweda. *Copy Cataloging in an RDA Environment.* ALCTS eForum, held May 14 and 15, 2013.

Hall-Ellis, Sylvia D. *Law Librarianship: A Community Conversation.* Sponsored by the Colorado Association of Law Libraries, presented at the Colorado Supreme Court Library, Denver, Colo., May 14, 2008.

Hall-Ellis, Sylvia D. and Beatrice Z. Gerrish. *Reading and Libraries: Recent Research in Reading.* Presentation at the Ricks Center for Gifted Education, Denver, Colo., March 4, 2008.

Hall-Ellis, Sylvia D. *Cataloger Competencies: Do the Employers Require What the Professors Teach?* Presentation for the School of Library and Information Science, San José State University, February 12, 2008.

Hall-Ellis, Sylvia D. and Robert O. Ellett, Jr. *Cooperative Cataloging: Rules, Tools, and Conventions for Building a Multi-institutional Catalog.* Sponsored for the Spanish Ministry of Defense, Madrid, Spain, July 10, 2006.

Hall-Ellis, Sylvia D. *Cash for Kids: Grant Writing Opportunities for Youth Services Librarians.* Sponsored by the Colorado Young Adult Librarians; presented at Bemis Memorial Library, Littleton, Colo., November 13, 2002.

Hall-Ellis, Sylvia D. *MARC Records and Authority Control: Planning for Bibliographic Database Migration.* Sponsored and held at the Douglas County Public Library, Castle Rock, Colo., May 28, 2002.
Grant Writing: A Refresher for Librarians. Sponsored by Library and Information Science Program, College of Education, University of Denver; presented at University Center at Chaparral, August 12, 2000.

Hall-Ellis, Sylvia D. *Shaking the Money Tree – Basic Grant Writing for Colorado Educators.* Sponsored by the Office of Educational Telecommunications of the Colorado Department of Education.
Pikes Peak Community College, Colorado Springs, Colo., November 16, 1998.
Pueblo School District 60, Pueblo, Colo., November 12, 1998.

University of Northern Colorado, Greeley, Colo., November 10, 1998.
United Technology Educational Partnership, Grand Junction, Colo., November 9, 1998.

Hall-Ellis, Sylvia D. *Cataloging Multimedia, Kits, Globes and Map Materials in USMARC.* Sponsored and hosted by Region One Education Service Center, Edinburg, Tex., April 24, 1997 and December 12, 1996.

Hall-Ellis, Sylvia D. *New Standards for School Library Media Centers.* Sponsored and hosted by Region One Education Service Center, Edinburg, Tex., April 15, 1997.

Hall-Ellis, Sylvia D. *The School Library Media Specialist in the 21st Century: Visions for the Future.* Sponsored and hosted by Pharr-San Juan-Alamo Independent School District, Pharr, Tex., April 4, 1997.

Hall-Ellis, Sylvia D. *Cataloging Sound Recordings and Audio Materials in USMARC.* Sponsored and hosted by Region One Education Service Center, Edinburg, Tex., March 20, 1997 and November 21, 1996.

Hall-Ellis, Sylvia D. *Evaluating and Selecting CD-ROMS for School Library Media Collections.* Sponsored and hosted by Region One Education Service Center, Edinburg, Tex., March 18, 1997.

Hall-Ellis, Sylvia D. *Cataloging Audiovisual Materials in USMARC.* Sponsored and hosted by Region One Education Service Center, Edinburg, Tex., February 27, 1997, November 7, 1996 and October 24, 1996.

Hall-Ellis, Sylvia D. *Introduction to Dialog: Basic Searching Strategies.* Sponsored and hosted by Region One Education Service Center, Edinburg, Tex., February 14, 1997.

Hall-Ellis, Sylvia D. *Cataloging Books in USMARC.* Sponsored and hosted by Region One Education Service Center, Edinburg, Tex., January 30, 1997, October 10, 1996, September 26, 1996 and August 8, 1996.

Hall-Ellis, Sylvia D. *Advanced Internet Searching Techniques for Librarians.* Sponsored and hosted by Region One Education Service Center, Edinburg, Tex., January 21, 1997.

Hall-Ellis, Sylvia D. *Texas Library Connection Full-Text Searching.* Sponsored and hosted by Region One Education Service Center, Edinburg, Tex., December 13, 1996 and October 25, 1996.

Hall-Ellis, Sylvia D. *Developing Evaluation Strategies for Grants and Proposals.* Sponsored and hosted by Region One Education Service Center, Edinburg, Tex., December 10, 1996.

Hall-Ellis, Sylvia D. *Developing Needs Assessment for Grants and Proposals.* Sponsored and hosted by Region One Education Service Center, Edinburg, Tex., November 12, 1996.

Hall-Ellis, Sylvia D. *Texas Library Connection Union Catalog Searching.* Sponsored and hosted by Region One Education Service Center, Edinburg, Tex., November 8, 1996 and September 6, 1996.

Hall-Ellis, Sylvia D. *Grant Resources on the Internet.* Sponsored and hosted by Region One Education Service Center, Edinburg, Tex., October 23, 1996.

Hall-Ellis, Sylvia D. *Preparing a Response to the Telecommunications Infrastructure Fund Board: Needs Assessment, Professional Development Framework, and Evaluation Strategies.* Sponsored and hosted by Region One Education Service Center, Edinburg, Tex., October 16, 1996.

Hall-Ellis, Sylvia D. *Texas Library Connection: Building the Districtwide Bibliographic Database.* Sponsored and hosted by Mercedes Independent School District, Mercedes, Tex., September 13, 1996 and August 8, 1996. Sponsored and hosted by Los Fresnos Consolidated Independent School District, Los Fresnos, Tex., August 12, 1996.

Hall-Ellis, Sylvia D. *School-to-Work and Special Education: An Inclusive Partnership for Success.* Sponsored and hosted by the Office of Special Education, Region One Education Service Center, Edinburg, Tex., September 11, 1996.

Hall-Ellis, Sylvia D. *Telecommunications Infrastructure Fund Board: An Overview of Funding for Secondary Schools.* Sponsored and hosted by Region One Education Service Center, Edinburg, Tex., August 31, 1996.

Hall-Ellis, Sylvia D. *Cataloging Books, Multimedia, and Realia in USMARC.* Sponsored and hosted by Edinburg Consolidated Independent School District, Edinburg, Tex., August 6, 1996.

Hall-Ellis, Sylvia D. *Internet Resources for Grant Writers.* Sponsored and hosted by Region One Education Service Center, Edinburg, Tex., April 20, 1996.

Hall-Ellis, Sylvia D. *Enhanced Grant Writing Skills for Mathematics Educators: Writing Skills for Campus Teams.* Sponsored and hosted by the Office of General Education, Region One Education Service Center, Edinburg, Tex., March 22, 1996.

Hall-Ellis, Sylvia D. *Internet Resources for Grant Writers.* Sponsored and hosted by the College of Education and Applied Science, Sam Houston State University, Huntsville, Tex., March 9, 1996.

Hall-Ellis, Sylvia D. *Grant Writing for Mathematics Educators: A Development Process for Campus Teams.* Sponsored and hosted by the Office of General Education, Region One Education Service Center, Edinburg, Tex., March 4, 1996.

Hall-Ellis, Sylvia D. *Shaking the Money Tree: Preparing Successful Technology Grant Applications.* Sponsored and hosted by the Office of Technology and Media Services, Region One Education Service Center, Edinburg, Tex., February 29, 1996 and April 29, 1996.

Hall-Ellis, Sylvia D. *District-wide Technology Planning: Technical Assistance for the Texas Education Agency Initiative.* Sponsored and hosted by the Office of Technology and Media, Region One Education Service Center, Edinburg, Tex., February 2, 1996.

Hall-Ellis, Sylvia D. *Enhanced Grant Writing Skills.* Sponsored and hosted by Pharr-San Juan-Alamo Independent School District, Pharr, Tex., January 27, 1996.

Hall-Ellis, Sylvia D. *United States Copyright Act of 1976, Video Transmissions, Computer Software and the Internet.* Sponsored and hosted by the Office of Technology and Media, Region One Education Service Center, Edinburg, Tex., January 24, 1996.

Hall-Ellis, Sylvia D. *The Grant Writing Development Process.* Sponsored and hosted by Pharr-San Juan-Alamo Independent School District, Pharr, Tex., January 20, 1996.

Hall-Ellis, Sylvia D. *MARC Cataloging of Materials for Library Media Centers.* Sponsored and hosted by the Office of Media Services, Region One Education Service Center for the Donna Independent School District, Donna, Tex., August 17, 1995.

Hall-Ellis, Sylvia D. *Classification.* Sponsored by AJ Seminars, Rockville, Maryland; presented at University Hilton Hotel, Houston, Tex., May 10, 1995.

Hall-Ellis, Sylvia D. *Library Technical Services.* Sponsored by AJ Seminars, Rockville, Maryland; presented at University Hilton Hotel, Houston, Tex., April 26, 1995.

Hall-Ellis, Sylvia D. *Grant Writing: An Introduction for Public School Administrators.* Sponsored and hosted by the Office of Administrative Services, Region One Education Service Center, Edinburg, Tex., April 19, 1995.

Hall-Ellis, Sylvia D. *The School Library Media Specialist in the 21st Century: Visions for the Future.* Sponsored and hosted by the United Independent School District, Laredo, Tex., March 31, 1995.

Hall-Ellis, Sylvia D. *Using USMARC.* Sponsored by AJ Seminars, Rockville, Maryland; presented at University Hilton Hotel, Houston, Tex., March 29, 1995.

Hall-Ellis, Sylvia D. *Library Media Center Policies and Guidelines: How to Prepare for School Board Adoption.* Sponsored and hosted by the Office of Technology and Media Services, La Joya Independent School District, La Joya, Tex., March 10, 1995.

Hall-Ellis, Sylvia D. *Developing District-wide Policies and Guidelines for Library Media Centers.* Sponsored and hosted by the Office of Technology and Media Services, La Joya Independent School District, La Joya, Tex., January 10, 1995.

Hall-Ellis, Sylvia D. *MARC Cataloging of Audiovisual Materials for Library Media Centers.* Sponsored and hosted by the Office of Library Media and Technology Services, Cypress-Fairbanks Independent School District, Houston, Tex., December 1, 1994.

Hall-Ellis, Sylvia D. *The School Library Media Specialist in the 21st Century: Visions for the Future.* Sponsored and hosted by United Independent School District, Laredo, Tex., October 14, 1994.

Hall-Ellis, Sylvia D. *The School Library Media Specialist in the 21st Century: Visions for the Future.* Sponsored and hosted by the Laredo Independent School District, Laredo, Tex., October 7, 1994.

Hall-Ellis, Sylvia D. *MARC Cataloging for Library Media Centers.* Sponsored by the Office of Library Media and Technology Services, Cypress-Fairbanks Independent School District, Houston, Tex., October 5, 1994.

Hall-Ellis, Sylvia D. *Jump to the Head of the Class: Undergraduate Library Resources Available at Sam Houston State University.* Sponsored by the Office of the Associate Vice President for Student Services, Sam Houston State University, Huntsville, Tex., October 4, 1994.

Hall-Ellis, Sylvia D. *CD-ROMs - 1994's Newest and the Best for Secondary Level Media Centers.* Sponsored and hosted by Clear Lake Independent School District, Houston, Tex., June 3, 1994.

Hall-Ellis, Sylvia D. *Introduction to Classification.* Sponsored by AJ Seminars, Rockville, Maryland; presented at Holiday Inn, Market Center, Dallas, Tex., May 18, 1994.

Hall-Ellis, Sylvia D. *Basic Descriptive Cataloging.* Sponsored by AJ Seminars, Rockville, Maryland; presented at University Hilton Hotel, Houston, Tex., May 4, 1994.

Hall-Ellis, Sylvia D. *Shaking the Money Tree - Part II: Writing Successful Grant Applications.* Sponsored by Donna Independent School District, Donna, Texas, and Region One Education Service Center Edinburg, Texas; presented at South Texas Community College Library, McAllen, Tex., April 29, 1994.

Hall-Ellis, Sylvia D. *Using MARC.* Sponsored by AJ Seminars, Rockville, Maryland; presented at Holiday Inn, Market Center, Dallas, Tex., April 6, 1994.

Hall-Ellis, Sylvia D. *Automated Authority Control.* Sponsored by AJ Seminars, Rockville, Maryland; presented at University Hilton Hotel, Houston, Tex., March 23, 1994.

Hall-Ellis, Sylvia D. *Automating the District School Library Media Centers: Choices and Opportunities.* Sponsored and hosted by the Office of Technology and Library Media Services, Fort Bend Independent School District, Sugar Land, Tex., March 4, 1994.

Hall-Ellis, Sylvia D. *Shaking the Money Tree - Part I: Preparing Successful Grant Applications.* Sponsored and hosted by the Office of Library Media Services, Donna Independent School District, Donna, Tex., February 4, 1994.

GRADUATE COURSES TAUGHT

San José State University, School of Library and Information Science
INFO 249 – Advanced Cataloging and Classification (Fall 2015, 2016; Summer 2016)
INFO 287 – Special Topics in Cataloging and Classification (Spring 2017, 2018, 2019, 2020, 2021, 2022, 2023, 2024, 2025, 2026; Fall 2020, 2021, 2022, 2023, 2024, 2025, 2026)
LIBR 248 – Beginning Cataloging and Classification (Summer 2002, 2003, 2004, 2005, 2006)
LIBR 249 – Advanced Cataloging and Classification (Summer 2003; Fall 2014; Summer 2015)

University of Denver, University College
Grant Writing Certificate Seminar for Non-Profit Organizations (Fall 2020, 2021; Spring 2021)

University of Denver, Morgridge College of Education HED
5991 – Grant Writing in Higher Education (Spring 2011)
LIS 4010 – Organization of Information (Fall 2002-2009; Winter 2005; Spring 2004-2006)
LIS 4020 – Professional Principles and Ethics (Summer 2000)
LIS 4040 – Management of Libraries and Information Centers (Fall 2010; Spring 2003, 2009 (DS); Winter 2005)
LIS 4070 – Cataloging and Classification (Winter 2008, 2009, 2010, 2011, 2012; Fall 2009 (DS)) LIS
4321 – Collection Management (Spring 2005)
LIS 4326 – LIS Research (Winter 2009 (DS); Spring 2009 (DS))
LIS 4350 – Adult Materials and Services (Summer 2006, 2009)
LIS 4379 – Social Sciences Resources (Spring 2009)
LIS 4400 – Cataloging and Classification (Spring 2000, 2001; Winter 2002-2009; Summer 2005, 2006 – course renumbered LIS 4070, September 2007)
LIS 4401 – Descriptive Cataloging (Winter 2001; Spring 2002, 2003, 2006-2009; Summer 2005)
LIS 4402 – Subject Cataloging (Spring 2001, 2009; Summer 2005, 2006, 2007, 2008)
LIS 4403 – Classification Schemes (Fall 2007, 2008, 2009 (DS)) LIS
LIS 4405 – Authority Control (Winter 2009)
LIS 4510 – Materials and Services for Children (Winter 2004; Summer 2005)
LIS 4620 – Grant Writing and Fundraising (Summer 2000, 2002, 2004, 2010; Winter 2006; Fall 2006-2009)
LIS 4700 – Seminar in Technical Services (Fall 2001)
LIS 4700 – Seminar in Public Libraries (Summer 2002)
LIS 4804 – Management of Electronic Records (Spring 2004; Fall 2005)
LIS 4902 – Capstone Projects (Winter 2003, Spring 2008, 2009, 2011)
LIS 4910 – Independent Study (every quarter Winter 2000 through Spring 2011)
LIS 4920 – Service Learning (every quarter Summer 2004 through Spring 2011)
RMS 4954 – Grant Writing (Summer 2013, 2014)
RMS 4959 – Content Analysis Methodology (Spring 2015)
QRM 4978 – Grant Writing (Summer 2011, 2012)

Rutgers University, School of Communication and Information
SC&I 522 – Cataloging and Classification (Summer 2013)

University of Arizona, College of Behavioral and Social Sciences
LIS 602 – Cataloging and Classification (Summer 1995)
LIS 612 – Advanced Online Search and Retrieval (Summer 1995)

Sam Houston State University, College of Education & Applied Science
LIS 532 - Cataloging and Classification (Fall 1993, 1994, 1995)
LIS 563 - Advanced Cataloging and Classification (Summer 1994)
LIS 567 - Research Methods (Spring 1994, Spring 1995)
LIS 591 - Educational Technology (Spring 1994, 1995)
LIS 596 - Networking and Computer Technologies in Education (Fall 1993, Summer 1994, Fall 1995)

Dissertations at the University of Denver

Bowers, Stacey L. *Library Anxiety of Law School Students: A Study Utilizing the Multidimensional Library Anxiety Scale.* Chair, May 5, 2010.

Fattor, Melissa M. *Student Engagement Differences by Ethnicity and Scale for Ninth Grade Students.* Chair, November 1, 2010.

Fulton, Roseanne. *A Case Study of Culturally Responsive Teaching in Middle School Mathematics.* Kent Seidel, Chair, June 18, 2009, Outside Chair.

Grealy, Deborah S. *Tribes and Territories in Library and Information Studies Education.* Bruce Uhrmacher, Chair, June 10, 2008, Committee Member.

McCord, J. Michael. *Developing a Standard of Care for Educational Malpractice.* Chair, April 15, 2011.

Priebe, Sarah J. *Distinguishing Effects of Domain and General Knowledge on Passage Fluency and Comprehension.* Jan Keenan, Chair. July 21, 2011, Outside Chair.

Snyder-Mondragon, Sandra M. *Institutional Factors that Impact the Retention of Graduate Students of Color in Schools of Library and Information Science: A Metaregression of Accredited Library School Statistics on Student Retention and Graduation Rates.* Kathy Green, Chair, July 24, 2009, Committee Member.

Taylor, Karen Pickles. *Effective Teaching.* Elinor Katz, Chair, July 15, 2009, Outside Chair.

Thompson, Jennifer. *Distinguishing a Western Women's College: A History of the Curriculum and Student Experience at Colorado Women's College.* Edith W. King, Chair, July 16, 2010, Committee Member.

Walker, Emelda. *Influence of Organizational Factors on Job Satisfaction of Disability Service Providers at Postsecondary Institutions.* Chair, April 29, 2010.

Dissertation Proposals at the University of Denver

Bowers, Stacey L. *Library Anxiety of Law School Students: A Study Utilizing the Multidimensional Library Anxiety Scale.* Chair, November 5, 2009.

McCord, J. Michael. *Developing a Standard of Care for Educational Malpractice.* Edith W. King, Chair. April 23, 2010.

Thompson, Jennifer. *History of Colorado Women's College.* Edith W. King, Chair, October 30, 2008. Committee Member.

Walker, Emelda. *Influence of Organizational Factors on Job Satisfaction of Disability Service Providers at Postsecondary Institutions.* Chair, July 21, 2009.

Dissertations at Other Institutions

Rodríguez-Mori, Howard. *The Information Behavior of Puerto Rican Immigrants to Central Florida, 2003-2009: Grounded Analysis of Six Case Studies Use of Social Networks during the Migration Process.* Kathleen Burnett, Chair, April 10, 2009, Florida State University, Committee Member.

Schwartz, Brian *More than a Look-up Skill: Medical Information Literacy Education in Osteopathic Medical Schools.* D. Mirah Dow, Chair, July 18, 2017. Emporia State University, Committee Member.

Snow, Karen. *A Study of the Perception of Cataloging Quality among Catalogers.* Shawne D. Miksa, Chair, August 1, 2011. University of North Texas, Committee Member.

Dissertation Proposals at Other Institutions

Schwartz, Brian *More than a Look-up Skill: Medical Information Literacy Education in Osteopathic Medical Schools.* D. Mirah Dow, Chair, December 4, 2015. Emporia State University, Committee Member.

Snow, Karen. *A Study of the Perception of Cataloging Quality among Catalogers.* Shawne D. Miksa, Chair, May 11, 2010. University of North Texas, Committee Member.

Master's Thesis at the University of Denver

Hemingson, Jeff. *Recital Paper.* Lamont School of Music, February 2010, Outside Chair.

Capstones at the University of Denver

Anthony, Alisa. *Correlation of Library and Information Science Program outcomes and Vacant Position Qualifications Listed on the Colorado State Library Jobline by Employers During the Period September 1, 2000 through August 31, 2002.* Chair, Winter Quarter, 2003.

Borden, Donna M. *Improving Emergency Communications Systems: Is a Radio Communications Network the Answer?* Fall Quarter, 2014.

Bowden, Heather L.M. *Exploring Biological Models for Long-term Data Preservation.* Chair, Spring Quarter, 2008.

Casenada, Cassandra Y. *Challenges to the Recruitment, Education, and Retention of Librarians of Color*. Chair, Spring Quarter, 2008.

Chang, Jennifer C. *Legal Research Practice and Preference: A Law Firm Perspective.* Chair, Spring Quarter 2011.

Ellis, Megan S. Fitzgerald. *Design of a Public Library Adult Volunteer Recruitment Program and Training Curriculum.* Chair, Winter Quarter, 2003.

Kircher, Kathy. *Development of a Library Pathfinder for Exobiology and Posting it on the Internet.* Chair, Winter Quarter, 2003.

Melhado, Loretta. *Design of St. John's Episcopal Church Library.* Chair, Spring Quarter, 2008.

Radcliff, Kathy. *Original Cataloging of Archival materials in the HERS Collection in Penrose Library.* Chair, Winter Quarter, 2003.

Sass, Carol Ann. *ACT Periodical Index: Access to Catholic Thinking Periodical Index: Web Index to Select Catholic Periodicals.* Spring Quarter 2000.

Stone, Sergio D. *Conducting Community Analysis for the Bemis Public Library (Littleton, Colorado) Using 2002 U.S. Census Data and the Online Outcome-Based Evaluation Toolkit.* Chair, Winter Quarter, 2003.

Tureson, Tamara. *Design and Use of an Information Audit Tool for Use in a Law Library.* Chair, Winter Quarter, 2003.

Tweed, Beth. *Evaluation of Email Reference Service in a Consumer Health Library Environment.* Chair, Winter Quarter, 2003.

GRANTS AND CONTRACTS

Student Learning in Agriculture STEM through Teacher Professional Development. Research team: Stanton Gartin (PI) and Cyndi Hofmeister, Northeast Junior College; Jeff Cash, Cheryl Sánchez, Anne-Marie Crampton, Lamar Community College; Suzanna Spears, Morgan Community College; Jack Wiley, Kerry Gabrielson, Trinidad State Junior College; Michael J. Miller, Colorado State University; Michael Womochil (Co-PI), Casey Sacks, and Sylvia D. Hall-Ellis, Colorado Community College System. U.S. Department of Agriculture, Agriculture and Food Research Initiative, Food, Agriculture, Natural Resources and Human Sciences Education and Literacy Initiative, $404,460 (2017-2020)

Leading and Achieving: the Colorado Agriculture Regional Consortium. Research team: Jack Wiley (PI), Kerry Gabrielson, Trinidad State Junior College; Jeff Cash (PI), Cheryl Sánchez, Anne-Marie Crampton, Lamar Community College; Suzanna Spears, Morgan Community College; Cyndi Hofmeister, Northeast Junior College; Michael Womochil (Co-PI), Casey Sacks, and Sylvia D. Hall-Ellis, Colorado Community College System. U.S. Department of Agriculture, Hispanic Serving Institutions Education Grants Program, $504,414 (2017-2020)

Cyber Prep Program Planning Grant. Research team: Debbie Sagen (PI), Brenda Lauer, Pikes Peak Community College; Gretchen Martin, Koiosa Insights; and, Sylvia D. Hall-Ellis, Colorado Community College System. U.S. Department of Commerce, Regional Alliances and Multi-stakeholder Partnerships to Stimulate (RAMPS) Cybersecurity Education and Workforce Development, $199,681 (2016-2018)

Career and Technical Education in Colorado: Pathways to Education and Employment. Research team: Heather McKay (PI), Rutgers University; Sarah Heath, Casey Sacks, Sylvia D. Hall-Ellis, Colorado Community College System. U.S. Department of Education, Institute of Education Sciences, $1,400,000 (2017-2021)

Pre-Alliance Planning Grant Colorado Community College Alliance. Research team: Victor Vialpondo (PI) and Janel Highfill, Community College of Aurora; Heidi Loshbaugh (Co-PI), Community College of Denver; Rick Reeves, Bill McGreevy, Liz Cox, and Kristin Aslin, Red Rocks Community College; Cathy Pellish, Front Range Community College; Samuel DeVries, Arapahoe Community College; Sylvia D. Hall-Ellis, Colorado Community College System. National Science Foundation, Louis Stokes Alliance for Minority Participation (LSAMP), $86,817 (2016-2017)

Towards Scalable Differentiated Instruction Using Technology-enabled, Competency-based, Dynamic Scaffolding. Research team: Karen Wilcox (PI) and Vijay Kumar, Center for Computational Engineering, Massachusetts Institute of Technology; Flora McMartin, Broad-based Knowledge; Quinsigamond Community College; and, Casey Sacks, and Sylvia D. Hall-Ellis, Colorado Community College System. U.S. Department of Education, First in the World Developmental Grant, $2,891,882 (2015-2019)

Colorado Strategic Partnerships Emergency Grant. Research team: Elise Lowe-Vaughn (PI), Amy Hodson, Celia Hardin, Barbara McBride, James Newby, Christopher Dewhurst, Nina Holland, Kate Anderson, MaryAnn Roe, Chrystalynn Chrystalynn, Elaine Edon, Mona Barnes, Tom Morgan, Rob Hanni, and Marie Valenzuela, Colorado Department of Labor and Employment; Steve Anton, Joelle Brouner, and, Katie Griego, Colorado Department of Human Services; Rebecca Holmes, Judith Martinez, and Jennifer Jirous, Colorado Department of Education; Emily Templin Lesh, Colorado Workforce Development Council; Cory Everett, Colorado Department of Regulatory Agencies; and, Casey Sacks and Sylvia D. Hall-Ellis, Colorado Community College System. U.S. Department of Labor, Strategic Partnerships Emergency Grant, $5,000,000 (2015-2017)

CAEL Jump Start Program: Competency-Based Education. Research team: Jerry Migler (PI), Casey Sacks, Debra Cohn, Thomas Hartman, and Sylvia D. Hall-Ellis, Colorado Community College System; Matt Jamison, Front Range Community College; Mike Coste, Red Rocks Community College; Amanda Corum, Pueblo Community College; Janet Colvin, Pikes Peak Community College; and, MaryAnn Matheny, Community College of Denver. Council for Adult and Experiential Learning, $15,000 (2015)

Summit on the Redesign of Developmental Education. Research team: Jerry Migler (PI), Casey Sacks, and Sylvia D. Hall-Ellis, Colorado Community College System; Chip Nava, Pueblo Community College; Kim Moultney, Arapahoe Community College; Debbie Ulibarri, Trinidad State Junior College; and, Kris Bernard, Front Range Community College. American Association of Community Colleges, $15,000 (2015-2016)

Equity in Excellence at Colorado Community Colleges. Research team: Keith Howard (PI) and Sylvia D. Hall-Ellis, Colorado Community College System; Estela Mata Bensimon, Center for Urban Education, University of Southern California; and Kerry Gabrielson, Trinidad State Junior College. Colorado Department of Higher Education, Colorado Opportunity Scholarship Program, $150,000 (2015-2016)

MBA High School of Business in Colorado. Research team: Laurie Urich (PI) and Sylvia D. Hall-Ellis, Colorado Community College System; Rudolph Sumpter and Beatrice Gerrish, Boulder Valley Schools; Keith Curry Lance, RSL Research Group. Colorado Department of Higher Education, Colorado Opportunity Scholarship Program, $501,295 (2015-2016)

Fullbridge Program in Colorado. Research team: Keith Howard (PI) and Sylvia D. Hall-Ellis, Colorado Community College System; Suzanna Spears, Fort Morgan Community College; and, Cheryl Sánchez and Anne-Marie Compton, Lamar Community College. Colorado Department of Higher Education, Colorado Opportunity Scholarship Program, $300,000 (2015-2017)

Colorado Community College System Alternative Credit Program. Research team: Jerry Migler (PI), Keith Howard, and Sylvia D. Hall-Ellis, Colorado Community College System. American Council on Education, $13,000 (2015)

Internationalization in Higher Education. Researcher: Samuel D. Museus. Technical reviewer for MCE: Sylvia D. Hall-Ellis. University of Denver, Office of Internationalization, $8,000 (2014-2015)

International Perspectives on Bilingual Education. Researcher: Sharolyn Pollard-Durodola. Technical reviewer for MCE: Sylvia D. Hall-Ellis. University of Denver, Office of Internationalization, $3,700 (2014-2015)

Cultivating Culturally Relevant and Responsive Curriculum and Pedagogy in College. Researcher: Samuel Museus. Technical reviewer for MCE: Sylvia D. Hall-Ellis. University of Denver, iRise Grant, $5,000 (2014-2015)

Project EMERGE (Educational Model for Evaluation and Replicability in Gifted Environments). Research team: Norma Hafenstein (PI) and Bruce Uhrmacher. Technical reviewer for MCE: Sylvia D. Hall-Ellis. Lynde and Harry Bradley Foundation, $235,000 (2014-2015)

Collecting Asian American Refugee Stories. Researcher: Samuel Museus. Technical reviewer for MCE: Sylvia D. Hall-Ellis. American Educational Research Association, Research Grant, $5,000 (2014-2015)

Developing Expertise in Teaching K-5 Mathematics. Research team: Julie Sarama (PI) and Douglas H. Clements (Co-PI), in partnership with the School of Education at the University of Michigan. Technical reviewer for MCE: Sylvia D. Hall-Ellis. National Science Foundation, $130,344 (2013-2015)

Investigation of the Long-Term Outcomes for Special Education Students. Researcher: Antonio Olmos-Gallos. Technical reviewer for MCE: Sylvia D. Hall-Ellis. Jefferson County School District, Office of Assessment, $40,000 (2014)

Refugee Community Collaboration. Researcher: Vicki Tomlin (PI) in partnership with the African Community Center and Jewish Family Service. Technical reviewer for MCE: Sylvia D. Hall-Ellis. University of Denver, Center for Community Engagement and Service Learning, $14,854 (2014-2015)

Access to Mathematics for All. Research team: Richard S. Kitchen (PI), Nicole M. Russell (Co-PI), and Terrence Blackman (Co-PI), Curriculum Studies and Teaching Program, Morgridge College of Education; Álvaro Árias (Co-PI, Department of Mathematics); and, James Gray (Co-PI), Department of Mathematics, Community College of Aurora. Technical reviewer for MCE: Sylvia D. Hall-Ellis. National Science Foundation, The Robert Noyce Scholarship Program, Capacity Building Project, $349,926 (2014-2016)

Cognitive Test Battery for Intellectual Disabilities. Research team: Karen Riley (PI), Lyndsay Agans, Jessica Lerner, and Karin Dittrick-Nathan in partnership with David Hessl (PI), The MIND Institute at the University of California – Davis, and Elizabeth Berry-Kravis, Rush University Medical Center. Technical reviewer for MCE: Sylvia D. Hall-Ellis. National Institutes of Health, Outcome Measures for Use in Treatment Trials for Individuals with Intellectual and Developmental Disabilities (R01), $2,499,996 ($588,672 at DU) (2014- 2019)

Broadening Participation in Engineering among Women and Latino/as: A Longitudinal, Multi-Site Study. Researcher: Patton Garriott (PI) in partnership with the University of North Dakota and the University of Missouri. Technical reviewer for MCE: Sylvia D. Hall-Ellis. National Science Foundation, HER Core Research, $677,390 ($69,992 at DU) (2014-2019)

Designing a Teacher Evaluation System to Improve Teacher Effectiveness for Culturally and Linguistically Diverse Learners. Research team: María del Carmen Sálazar (PI), Jessica Lerner, and Kathy Green. Technical reviewer for MCE: Sylvia D. Hall-Ellis. University of Denver, Professional Research Opportunities for Faculty, $29,988 (2014-2016)

Developing a College-Going Culture in Latina/O Families: Exploring the Influence of Funds of Knowledge on Family Outreach Programs. Researcher: Judy Marquez Kiyama. Technical reviewer for MCE: Sylvia D. Hall-Ellis. University of Denver, Professional Research Opportunities for Faculty, $18,720 (2014-2016)

Assessment of Quality of Life in Neutral Implantation Surgery for the Treatment of Parkinson's Disease. Researcher: Cynthia McRae. Technical reviewer for MCE: Sylvia D. Hall-Ellis. University of Denver, Office of Internationalization, $3,967 (2014-2015)

Pura Vida: Cloud Forest, Curriculum and Cross-Cultural Study. Research team: Norma Hafenstein (PI) and Bruce Uhrmacher (Co-PI). Technical reviewer for MCE: Sylvia D. Hall-Ellis. University of Denver, Office of Internationalization, $8,000 (2014-2015)

Online Course Development for Curriculum and Instruction. Researcher: Ruth Chao. Technical reviewer for MCE: Sylvia D. Hall-Ellis. University of Denver, Office of Teaching and Learning, $3,000 (2014)

Online Course Development for Curriculum and Instruction. Researcher: María del Carmen Sálazar. Technical reviewer for MCE: Sylvia D. Hall-Ellis. University of Denver, Office of Teaching and Learning, $3,000 (2014)

Online Course Development for Curriculum and Instruction. Researcher: Jessica Lerner. Technical reviewer for MCE: Sylvia D. Hall-Ellis. University of Denver, Office of Teaching and Learning, $3,000 (2014)

Online Course Development for Curriculum and Instruction. Researcher: Duan Zhang. Technical reviewer for MCE: Sylvia D. Hall-Ellis. University of Denver, Office of Teaching and Learning, $3,000 (2014)

The Mathematics Education of African Americans, 1866 – 1954. Researcher: Nicole M. Russell. Technical reviewer for MCE: Sylvia D. Hall-Ellis. National Academy of Education, Spencer Foundation Postdoctoral Fellowship, $55,000 (2014-2016)

Early Childhood Care and Education Study. Research team: Carrie Germeroth (PI), Melissa Mincic, and Douglas H. Clements. Technical reviewer for MCE: Sylvia D. Hall-Ellis. State of North Dakota, Department of Public Instruction, $73,500 (2013-2014)

Graduate Level Specialty in Addiction Counselor Training with Emphasis on Integration of Native American Specific Content. Research team: Ruth Chao (PI) and Michael J. Faragher (Co-PI). Technical reviewer for MCE: Sylvia D. Hall-Ellis. The Galena Foundation, $289,732 (2013-2016)

The Collecting Asian American and Pacific Islander Refugee Stories (CARS) Project. Researcher: Samuel Museus. Technical reviewer for MCE: Sylvia D. Hall-Ellis. University of Denver, Center for Community Engagement and Service Learning, $15,000 (2014)

Parents in Transition: A Multiple Case Study of Parent and Family Orientation Programs. Researcher: Judy Marquéz Kiyama. Technical reviewer for MCE: Sylvia D. Hall-Ellis. University of Denver, Faculty Research Fund, $1,500 (2014-2015)

The Sistah Network: Black Women Graduate Students Supporting and Retaining Each Other. Researcher; Nicole M. Russell. Technical reviewer for MCE: Sylvia D. Hall-Ellis. University of Denver, Faculty Research Fund, $2,708 (2014-2015)

Evaluation of the Northeast Denver Babies Ready for College Program. Research team: Carrie Germeroth (PI), Melissa Mincic, and Douglas H. Clements. Technical reviewer for MCE: Sylvia D. Hall-Ellis. Mile High Montessori, $9,922 (2013-2014)

Developing Teaching Expertise in K-5 Mathematics. Research team: Julie Sarama (PI) and Douglas Clements (University of Denver), in partnership with Timothy Boerst (PI), Meghan Shaughnessy, Deborah Ball, Hyman Bass (School of Education at the University of Michigan). Technical reviewer for MCE: Sylvia D. Hall-Ellis. National Science Foundation, $449,827 ($130,344 at the University of Denver (2013-2015)

Early Learning Care and Education Study Program Grant for the State of North Dakota. Research team: Carrie Germeroth (PI), Melissa Mincic, and Sheridan Green. Technical reviewer for MCE: Sylvia D. Hall-Ellis. State of North Dakota Department of Public Instruction, $73,500 (2013-2014)

Local Professional Learning Community for School Leaders. Research team: Susan Korach (PI), Kristina Hesbol, and Rebecca McClure. Technical reviewer for MCE: Sylvia D. Hall-Ellis. Education Development Center, $10,950 (2013)

Healthy Eaters, Lifelong Movers 2: Implementing Evidence-Based School Environment, Policy, and Curricular Changes to Increase Opportunities for Healthy Eating and Physical Activity in Low Income, Rural Colorado. Research team: Elaine Berlansky, University of Colorado at Denver (PI), Nicholas Cutforth, University of Denver (Co-PI), and Allison Reeds. Technical reviewer for MCE: Sylvia D. Hall-Ellis. Colorado Health Foundation, $3,103,108 (2013-2017)

Hughes Rare Books Library Room Renovation in the Sturm College of Law. Project team: Patti H. Marks, Sylvia D. Hall-Ellis, and Leigh Elliott. Mabel T. Hughes Charitable Trust, $34,000 (2013-2014)

The Promise Center Partnership with the Marsico Institute for Early Learning and Literacy and the City and County of Denver. Research team: Karen Riley (PI), Douglas H. Clements (Co-PI), and Sheridan Green. Technical reviewer for MCE: Sylvia D. Hall-Ellis. The Piton Foundation, $223,468 (2013-2014)

Center of Excellence for Problem Gambling. Research team: Ruth Chao (PI) and J. Mike Faragher. Technical reviewer for MCE: Sylvia D. Hall-Ellis. Colorado Department of Behavioral Health, $68,021 (2012-2013)

United Way Implementation and Validation Review. Research team: Douglas H. Clements (PI), Amanda Moreno, and Sheridan Green. Technical reviewer for MCE: Sylvia D. Hall-Ellis. Mile High United Way, $19,737 (2013)

Math/Science Partnership in Rural Districts. Research team: Kristen Bunn (PI, Eagle County Schools), Paul Michalec (Co-PI), and Alegra Reiber. Technical reviewer for MCE: Sylvia D. Hall-Ellis. Colorado Department of Education, Colorado's Mathematics and Science Partnership Program, $750,000 (2013-2014)

Mathematics and Science Education of African Americans. Research team: Nicole Russell (PI), Sylvia D. Hall-Ellis, Steve Fisher (Penrose Library). Technical reviewer for MCE: Sylvia D. Hall-Ellis. University of Denver, Professional Research Opportunities for Faculty, $29,994 (2013-2015)

Online Course Development for Curriculum and Instruction. Researcher: Nicole Russell. Technical reviewer for MCE: Sylvia D. Hall-Ellis. University of Denver, Office of Teaching and Learning, $3,000 (2013)

Discourse and Opportunity: Undocumented Students and Higher Education Policy. Researcher: Ryan Gildersleeve. Technical reviewer for MCE: Sylvia D. Hall-Ellis. National Academy of Education, Spencer Foundation Postdoctoral Fellowship, $55,000 (2012-2014)

An Anthropological Study of the Latino Graduation Ceremony. Researcher: Ryan Gildersleeve. Technical reviewer for MCE: Sylvia D. Hall-Ellis. Spencer Foundation, $39,900 (2012-2013)

Fragile-X and Pharmaceutical Company: Clinical Trial of AFQ056. University of California – Davis Children's Hospital MIND Institute (Sacramento), Children's Hospital Denver, and Rush Children's Hospital at Rush University Medical Center (Chicago). Karen Riley, PI. Technical reviewer for MCE: Sylvia D. Hall-Ellis. Novartis Pharmaceuticals Corporation, $394,206 (2012-2014)

Project Engage, Phase 2, a DAPRA Grant in partnership with Total Immersion Systems, Inc., and Texas A&M University. Research team: Karen Riley (PI) and Lyndsay Agans (Co-PI). Technical reviewer for MCE: Sylvia D. Hall-Ellis. U.S. Department of Defense, $60,000 (2011-2013)

International School Psychology Practicum Exchange. Researcher: Gloria L. Miller. Technical reviewer for MCE: Sylvia D. Hall-Ellis. University of Denver, Center for Community Engagement and Service Learning, $14,951 (2012-2013)

Online Course Development for Curriculum and Instruction. Research team: Bruce Uhrmacher (PI) and Norma Hafenstein (Co-PI). Technical reviewer for MCE: Sylvia D. Hall-Ellis. University of Denver, Office of Teaching and Learning, $18,193 (2012-2014)

Writers in the Schools. Research team: Karen Riley (PI) and Amanda Moreno (Co-PI).Technical reviewer for MCE: Sylvia D. Hall-Ellis. Colorado Humanities, $4,965 (2012-2013)

Learning Ecosystem Validation Grant. Research team: Karen Riley (PI), Lyndsay Agans, Kent Seidel, and Shimelis Assefa. Technical reviewer for MCE: Sylvia D. Hall-Ellis. Bill & Melinda Gates Foundation, $315,000 (2012-2013)

Project Words of Oral Reading and Language Development (WORLD). Research team: Jorge E. Gonzalez (PI), Texas A&M University; Laura Saenz (Co-PI), University of Texas – Pan American; and, Sharolyn Pollard-Durodola (Co-PI), University of Denver. Technical reviewer for MCE: Sylvia D. Hall-Ellis. U.S. Department of Education, Institute of Education Sciences, $53,354 (2012-2015); award $640,718, transfer from Texas A&M University

Increasing the Efficacy of an Early Mathematics Curriculum with Scaffolding Designed to Promote Self-Regulation. Research team: Douglas H. Clements (PI) and Julie Sarama (Co-PI). Technical reviewer for MCE: Sylvia D. Hall-Ellis. U.S. Department of Education, Institute of Education Sciences, $1,445,315 (2008-2014); award $4,541,975, transfer from University at Buffalo, The State University of New York

Using Rule Space and Poset-based Adaptive Testing Methodologies to Identify Ability Patterns in Early Mathematics and Create a Comprehensive Mathematics Ability Test. Research team: Douglas H. Clements (PI) and Julie Sarama (Co-PI). Technical reviewer for MCE: Sylvia D. Hall-Ellis. National Science Foundation, $323,791 (2010-2014); award $1,194,944, transfer from University at Buffalo, The State University of New York

Comprehensive Postdoctoral Training in Scientific Education Research. Researcher: Julie Sarama (PI). Technical reviewer for MCE: Sylvia D. Hall-Ellis. U.S. Department of Education, Institute of Education Sciences, $133,458 (2010-2014); award $613,353, transfer from University at Buffalo, The State University of New York

Longitudinal Study of a Successful Scaling Up Project: Extending TRIAD. Research team: Douglas H. Clements (PI), Julie Sarama (Co-PI), and Abt Associates (Carolyn Layzer, Fatih Unlu, Laurie Bozzi, Lily Fesler, Alina Martinez, Cristofer Price, James van Orden). Technical reviewer for MCE: Sylvia D. Hall-Ellis. Institute of Education Sciences, $384,940 (2011-2015; award $1,250,286, transfer from University at Buffalo, The State University of New York

Early Childhood Education in the Context of Mathematics, Science, and Literacy. Research team: Julie Sarama (PI), Douglas H. Clements (Co-PI). Technical reviewer for MCE: Sylvia D. Hall-Ellis. National Science Foundation, $990,020 (2010-2014; award $2,285,228, transfer from University at Buffalo, The State University of New York

Early Childhood Clearinghouse Information Center Redesign. Research team: Karen Riley (PI) and Amanda Moreno (Co-PI).Technical reviewer for MCE: Sylvia D. Hall-Ellis. Office of the Lt. Governor of Colorado, $12,000 (2012-2013)

Morgridge Rural Educational Leadership Initiative. Research team: Lyndsay Agans (PI), Linda Brookhart (Co-PI), Susan Korach, and Rebecca McClure. Technical reviewer for MCE: Sylvia D. Hall-Ellis. Morgridge Family Foundation, $100,000 (2012-2014)

Center of Excellence for Problem Gambling. Research team: Patrick Sherry (PI) and J. Mike Faragher. Technical reviewer for MCE: Sylvia D. Hall-Ellis. Colorado Department of Behavioral Health, $55,000 (2012-2013)

Intermodal Transportation Institute Research Initiatives. Researcher: Patrick Sherry. Technical reviewer for MCE: Sylvia D. Hall-Ellis. University Transportation Centers Program, Research and Innovative Technology Administration, U.S. Department of Transportation. $600,000 (2012-2014)

Mile High United Way Social Innovation Fund Early Literacy Initiative. Gloria L. Miller, PI, Amanda Moreano, Kim Hartnett-Edwards, and Sheridan Green. Technical reviewer for MCE: Sylvia D. Hall-Ellis. Mile High United Way, $89,992 (2012-2013)

International School Psychology Practicum Exchange. Researcher: Gloria L. Miller. Technical reviewer for MCE: Sylvia D. Hall-Ellis. University of Denver, Center for Community Engagement and Service Learning, $1,000 (2012-2013)

Refugee Student Art Outreach. Researcher: Karin Dittrick-Nathan. Technical reviewer for MCE: Sylvia D. Hall-Ellis. University of Denver, Faculty Research Fund, $3,000 (2012-2013)

Resistance, Resilience, and Reciprocity: Centering the Voices of Black Doctoral Women with Faculty Aspirations. Researcher: Nicole M. Russell. Technical reviewer for MCE: Sylvia D. Hall-Ellis. University of Denver, Faculty Research Fund, $2,965 (2012-2013)

Assessing Learning through Student Notebooks. Research team: Keith Miller, Nancy Sasaki, and Kathy Green. Technical reviewer for MCE: Sylvia D. Hall-Ellis. University of Denver, Professional Research Opportunities for Faculty, $30,000 (2012-2014)

International School Psychology Practicum Exchange. Researcher: Gloria L. Miller. Technical reviewer for MCE: Sylvia D. Hall-Ellis. University of Denver, Office of Internationalization, $2,000 (2012-2013)

ELO in Colorado. Research team: Cynthia Hazel and Duan Zhang. Technical reviewer for MCE: Sylvia D. Hall-Ellis. Colorado Legacy Foundation, $150,000 (2012-2013)

Creating Online LIS Courses. Research team: Mary C. Stansbury (PI), Shimelis Assefa, Denise Anthony, Xiao Hu, and Krystyna Matusiak. Technical reviewer for MCE: Sylvia D. Hall-Ellis. University of Denver, Center for Teaching and Learning, $15,000 (2011-2013)

Maritime Piracy Seminar. Researcher: Ved Nanda, The Nanda Center, Sturm College of Law. Technical reviewer for Sturm College of Law: Sylvia D. Hall-Ellis. Arsenault Family Foundation, $15,000 (2012-2013).

Early Childhood Librarianship: An Interdisciplinary, Experiential Learning MLIS. Researcher: Mary C. Stansbury (PI). Technical reviewer for MCE: Sylvia D. Hall-Ellis. Laura Bush's 21st Century Librarians Program, Institute for Museums and Library Services, $249,066 (2012-2014)

Learning Ecosystem Planning Grant. Research team: Karen Riley (PI), Lyndsay Agans, Kent Seidel, and Shimelis Assefa. Technical reviewer for MCE: Sylvia D. Hall-Ellis. Bill & Melinda Gates Foundation, $281,217 (2011-2012)

Advanced Service Learning Practitioner Faculty Grant, Sylvia D. Hall-Ellis, University of Denver, Center for Community Engagement and Service Learning, $400 (2011)

Evaluating and Enhancing the EspeciallyMe Program. Research team: Lori D. Patton and Nicole Russell. Technical reviewer for MCE: Sylvia D. Hall-Ellis. University of Denver, Center for Community Engagement and Service Learning, Public Good Fellowship Grant, $24,780 (2012)

Choosing Excellence: Let Every Child Bloom. Research team: Shimelis Assefa (PI) and Mary C. Stansbury (Co-PI). Technical reviewer for MCE: Sylvia D. Hall-Ellis. University of Denver, Center for Community Engagement and Service Learning, Public Good Grant, $7,657 (2012)

K-8 STEM Content Specific Professional Development to Improve Elementary Student Achievement. Research team: Kent Seidel (PI), Nicole Russell (Co-PI), Kimberly Hartnett-Edwards, Paul Michalec, Jeff Farmer, Keith Miller, Alegra Reiber, and Nancy Sasaki. Technical reviewer for MCE: Sylvia D. Hall-Ellis. Colorado Department of Education, Improving Teacher Quality Grant, (Title II ESEA), $307,299 (2011-2012)

Building a Better Principal Pipeline to Boost Student Achievement. Researcher: Susan Korach. Technical reviewer for MCE: Sylvia D. Hall-Ellis. Denver Public Schools; a subcontract from the Wallace Foundation Grant, $170,000 (2011-2017)

Center of Excellence for Problem Gambling. Research team: J. Mike Faragher (Co-PI) and Bobbie Vollmer (PI). Technical reviewer for MCE: Sylvia D. Hall-Ellis. Colorado Department of Behavioral Health, $79,999 (2011-2012)

An Exploration of Novice Teachers' Core Competencies: Impacts on Student Achievement, and Effectiveness of Preparation. Research team: Kent Seidel (PI), Kathy Green (Co-PI), Kimberly Hartnett-Edwards, and Duan Zhang. Technical reviewer for MCE: Sylvia D. Hall-Ellis. Institute of Education Sciences, Effective Teachers and Effective Teaching, $990,987 (2012-2015)

Project Engage, a DAPRA Grant in partnership with Total Immersion Systems, Inc., and Texas A&M University. Research team: Karen Riley (PI) and Lyndsay Agans (Co-PI). Technical reviewer for MCE: Sylvia D. Hall-Ellis. U.S. Department of Defense, $49,964 (2011-2014)

User-centered Evaluation of Music Search Engines. Researcher: Xiao Hu. Technical reviewer for MCE: Sylvia D. Hall-Ellis. University of Denver, Faculty Research Fund, $2,931 (2011-2012)

Educational Practicum in Vietnam and China to Promote the Inclusion of Young Children with Disabilities. Researcher: Gloria L. Miller. Technical reviewer for MCE: Sylvia D. Hall-Ellis. University of Denver, Office of Internationalization, $5,000 (2011-2012)

Evaluation of Colorado's Enhancing Quality in Infant-Toddler (EQIT) Initiative. Research team: Virginia R. Maloney and Amanda Moreno. Technical reviewer for MCE: Sylvia D. Hall-Ellis. Buell Foundation, $395,884 (2011-2013)

Creating Engaging Environments to Teach Pre-Algebra Mathematics to Elementary Students. Research team: Álvaro Arias, Mario López, María del Carmen Salazar, and Lyndsay Agans. Technical reviewer for MCE: Sylvia D. Hall-Ellis. University of Denver Interdisciplinary Grant, $60,000 (2011-2012)

Morgridge Education Technology Accessible (META) Resource Project. Research team: Lyndsay Agans (PI) and Shimelis Assefa (Co-PI). Technical reviewer for MCE: Sylvia D. Hall-Ellis. Morgridge Family Foundation, $36,000 (2011)

MCE Connect: A 21st Century Framework for Faculty Development. Research team: Bruce Uhrmacher (PI), Shimelis Assefa (Co-PI), Lyndsay Agans (Co-PI), Kimberly Hartnett-Edwards, Norma Hafenstein, Xiao Hu, Paul Michalec (Co-PI), María del Carmen Salazar (Co-PI), and Sandra Snyder-Mondragon. Technical reviewer for MCE: Sylvia D. Hall-Ellis. University of Denver, Center for Teaching and Learning, $22,355 (2011-2012)

Parent Education and Parent Leadership and Advocacy. Research team: Virginia Maloney (PI) and Amanda Moreno, Marsico Institute for Early Learning and Literacy. Technical reviewer for MCE: Sylvia D. Hall-Ellis. Colorado Health Foundation, $27,358 (2010-2011)

Intentional School Culture. Researcher: Cynthia Hazel. Technical reviewer for MCE: Sylvia D. Hall-Ellis. Denver Public Schools, $38,040 (2010-2011)

Healthy Eaters, Lifelong Movers: Implementing Evidence-Based School Environment, Policy, and Curricular Changes to Increase Opportunities for Healthy Eating and Physical Activity in Low Income, Rural Colorado. Research team: Elaine Berlansky, University of Colorado at Denver (PI), Nicholas Cutforth, University of Denver (Co-PI), and Allison Reeds. Technical reviewer for MCE: Sylvia D. Hall-Ellis. Colorado Health Foundation, $1,683,277 (2011-2014)

Second Life Learning Community. Research team: Don McCubbrey (PI), Sylvia D. Hall-Ellis (Co-PI), Walter LaMendola, and Paul Novak. University of Denver, Center for Teaching and Learning, $13,000 (2010-2011)

Reintroducing the Value of Law Librarians to Academic and Public Librarians in Colorado through the Identification and Use of Emerging Technologies. Research team: Sylvia D. Hall-Ellis (Co-PI), Stacey L. Bowers (PI), and Christopher Hudson, in partnership with Denver Public Library, Arapahoe Library District, and the Colorado State Supreme Court Library. University of Denver, Center for Community Engagement and Service Learning, $5,773 (2010-11)

Reintroducing the Value of Law Librarians to Public Librarians through the Identification and Use of Emerging Technologies and Resources. Research team: Stacey Bowers (PI) and Sylvia D. Hall-Ellis (Co-PI). American Association of Libraries, Wolters Kluwer Law & Business Grant Program, $2,725 (2010-2011)

Faculty Service Learning Pod. Research team: María del Carmen Salazar and Nicholas Cutforth (Curriculum and Instruction Program), Frank Tuitt (Higher Education Program), Cynthia Hazel and Gloria Miller (Child, Family, and School Psychology Program), and Sylvia D. Hall-Ellis (Library and Information Science Program). University of Denver, Center for Community Engagement and Service Learning, $8,000 (2010-2011)

Lincoln Collaborative. Research team: Antonio Esquibel (Principal, Lincoln High School), María del Carmen Salazar (Curriculum and Instruction Program), and. Sylvia D. Hall-Ellis. School Improvement Grant, Denver Public Schools, $375,000 (2010-2012)

Future LEADers of America: Leaders III. Research team: Denver Public Library (Kristen Svendson, PI), the University of Denver (Sylvia D. Hall-Ellis), the Colorado Chapter of REFORMA (Orlando Archibeque), and the Colorado Association of Libraries (Martin Garnar). Laura Bush's Recruiting Librarians for the 21st Century Program, Institute for Museums and Library Services, $988,366 (2009-2012)

Teaching for Success in the Library Environment: LIS 4030 in Library 2.0. Research team: Deborah S. Grealy (PI) and Sylvia D. Hall-Ellis (Co-PI). University of Denver, Center for Teaching and Learning, $ 9,350 (2009-10)

Writing Group Faculty Grant, Sylvia D. Hall-Ellis, University of Denver, Center for Community Engagement and Service Learning, $750 (2008-2009)

Collaborative Learning Faculty Grant, Sylvia D. Hall-Ellis, University of Denver, Center for Teaching and Learning, $1,500 (2008)

Connecting Information Literacy to Learning. Research team: Lori Micho, Merrie Valliant, Amanda Samland, and Sylvia D. Hall-Ellis. Colorado State Library, LSTA Discretionary Grant Program, $19,548 (2008-2009)

Law Librarianship Fellows Program. Research team: Sylvia D. Hall-Ellis (PI), Stacey Bowers (Co-PI), and Christopher Hudson, Westminster Law Library. Laura Bush's 21st Century Librarians Program, Institute for Museums and Library Services, $999,370 (2008-2012)

Grant Writing in a Cooperative Learning Environment. Sylvia D. Hall-Ellis. University of Denver, Center for Teaching and Learning, $2,000 (2008-2009)

Project Homeless Connect 6 Event Evaluation. Research team: Sylvia D. Hall-Ellis and Duan Zhang. University of Denver Center for Community Engagement and Service Learning, $9,785 (2008)

Project Ecuador: International Learning Service Libraries – A Faculty Development Experience in Ecuador. Sylvia D. Hall-Ellis, Office of Internationalization, University of Denver, $600 (2007)

Project Ecuador: International Learning Service Libraries – A Faculty Development Experience in Ecuador. Sylvia D. Hall-Ellis, International Service Learning Office, University of Denver, $400 (2007)

Project Homeless Connect 5 Event Evaluation. Research team: Sylvia D. Hall-Ellis and Duan Zhang. University of Denver Center for Community Engagement and Service Learning, $1,000 (2007)

Project Homeless Connect 4 Event Evaluation. Research team: Sylvia D. Hall-Ellis and Duan Zhang. University of Denver Center for Community Engagement and Service Learning, $4,595 (2007)

Future LEADers of America: Leaders II. Research team: Denver Public Library (Kristen Svendson, PI), the University of Denver (Sylvia D. Hall-Ellis), and the Colorado Chapter of REFORMA (Orlando Archibeque). Laura Bush's Recruiting Librarians for the 21st Century Program, Institute for Museums and Library Services, $988,518 (2007-2010)

Strategic Planning Assistance for the Denver Medical Library. Sylvia D. Hall-Ellis. Denver Medical Library, Inc., $30,000 (2006-2007)

Destiny Software for JMAC Student Lab. Sylvia D. Hall-Ellis, gift from the Sagebrush Corporation, Minneapolis, Minnesota, $10,000 (2006)

Libraries: Tools for Education and Development Worldwide: A Faculty Development Experience in France. Sylvia D. Hall-Ellis, Office of Internationalization, University of Denver, $800 (2005)

Denver Public Library: Opportunities for Change. Sylvia D. Hall-Ellis, Colorado Community Based Research Network, $2,000 (2005)

Future LEADers of America. Research team: Denver Public Library (Letty Icolari and Steve Taylor, PIs), Emporia State University (Jim Agee), and the University of Denver (Sylvia D. Hall-Ellis). Recruiting Librarians for the 21st Century Program, Institute for Museums and Library Services, $670,315 (2005-2008)

American Association of University Professors Summer Institute Professional Development Grant. Sylvia D. Hall-Ellis, American Association of University Professors, $300 (2005)

Beta Phi Mu Alumni Tea. Sylvia D. Hall-Ellis, gift from the Office of Alumni and Parent and Relations, University of Denver, $2,000 (2005)

Spectrum Software for LIS Student Lab. Sylvia D. Hall-Ellis, gift from the Sagebrush Corporation, Minneapolis, Minnesota, $5,000 (2005)

Developing Research Capacity in Community Organizations and Residents through Training and Technical Assistance. Nicholas J. Cutforth (PI) and Sylvia D. Hall-Ellis. Piton Foundation, $25,000 (2005-2006)

Libraries: Tools for Education and Development Worldwide: A Faculty Development Experience in Argentina. Sylvia D. Hall-Ellis, Office of Internationalization, University of Denver, $500 (2004)

Developing Research Capacity in Community Organizations and Residents through Training and Technical Assistance. Research team: Nicholas J. Cutforth (PI), Gary Lichtenstein and Sylvia D. Hall-Ellis, Piton Foundation, $25,000 (2003-2004)

Increasing Spanish-Speaking and Hispanic Diversity among Library and Information Science Students at the University of Denver: Development of a Student Recruitment Model. Researcher: Sylvia D. Hall-Ellis (PI), Office of Multicultural Excellence, University of Denver, $2,750 (2003-2004)

Collection Development Enrichment to Support the Cataloging & Classification Specialization and School Librarianship within the Library & Information Science Program at the University of Denver. Research team: Sylvia D. Hall-Ellis (PI) and Deborah S. Grealy. Women's Library Association, University of Denver, $4,000 (2003)

Collection Development Enrichment to Support the Library & Information Science Program at the University of Denver. Research team: Deborah S. Grealy (PI) and Sylvia D. Hall-Ellis. Women's Library Association, University of Denver, $4,000 (2001)

Wireless LAN for Library Education. Research team: Deborah S. Grealy (PI) and Sylvia Hall-Ellis. University of Denver, Center for Teaching and Learning, $24,000 (2001-2002)

Upward Bound – A Program for South Texas Youth. Research team: Monte Churchill, Executive Director of Community Relations; Gary R. Sauceda, Outreach Coordinator; Raymond Hernandez, (PI) Associate Dean for Student Success; and Sylvia D. Hall-Ellis, South Texas Community College (McAllen, Texas). U.S. Department of Education, Office of Postsecondary Education, $2,672,003 (1999-2003)

Write Now! Improving Elementary Students' Writing Skills. Research team: Caryl G. Thomason, Assistant Superintendent (PI); Karen Tankersley, Principal; and, Hal Anderson, Director of Technology, Cheyenne Mountain School District 12 (Colorado Springs, Colorado); and Sylvia D. Hall-Ellis. Colorado Department of Education, Educational Telecommunications Unit, $189,453 (1999-2001)

Operation Quick Start -- Distance Learning in Rural Colorado. Research team: Randal Weigum, Technology Coordinator (PI); Bonnie Barns, Director of Federal Programs and Staff Development; and, Adam "Joe" Raskop, Executive Director, Southeastern Board of Cooperative Educational Services (Lamar, Colorado); and Sylvia D. Hall-Ellis. Colorado Department of Education, Educational Telecommunications Unit, $400,000 (1999-2001)

Advanced Technological Training for Information Professionals for the 21st Century. Research team: Mario Reyna, Division of Business Director (PI) and Sylvia D. Hall-Ellis, South Texas Community College (McAllen, Texas). Phi Delta Kappa and the National Science Foundation, $250,000 (1999-2001)

Working Connections – Training Information Technologies Professionals for the 21st Century. Research team: Mario Reyna, Division of Business Director (PI) and Sylvia D. Hall-Ellis, South Texas Community College (McAllen, Texas). Microsoft Corporation and the American Association of Community Colleges, $1,147,775(1999-2001)

The ROAD (Research Oriented Amplification of Development to Literacy) Program. Research team: Deborah J. Leong (PI), Metropolitan State University; Elena Bodrova, Metropolitan State University; Dmitri Semenov, Robert J. Marzano, and Sylvia D. Hall-Ellis, Mid-continent Regional Educational Laboratory (Aurora, Colorado). Hewlett-Packard Foundation, $25,000 (1998-1999)

Press to Literacy. Research team: Deborah J. Leong (PI), Metropolitan State University; Elena Bodrova, Metropolitan State University; Dmitri Semenov, Robert J. Marzano, and Sylvia D. Hall-Ellis, Mid-continent Regional Educational Laboratory (Aurora, Colorado). The Denver Post and the Robert S. McCormick Foundation, $49,818 (1998-1999)

International Telementor Center. Research team: David Neils, David B. Frost (PI), and Sylvia D. Hall-Ellis, Mid-continent Regional Educational Laboratory (Aurora, Colorado). Hewlett-Packard Philanthropy, $100,000 (1998-1999)

America Reads: Providing Tutor Training for the America Reads Challenge. Research team: Louis F. Cicchinelli (PI) and Sylvia D. Hall-Ellis, Mid-continent Regional Educational Laboratory (Aurora, Colorado). U.S. Department of Education, Office of Educational Research and Improvement, $306,000 (1998-1999)

Comprehensive School Reform. Research team: Louis F. Cicchinelli (PI), J. Timothy Waters, and Sylvia D. Hall-Ellis, Mid-continent Regional Educational Laboratory (Aurora, Colorado). U.S. Department of Education, Office of Educational Research and Improvement, $285,000 (1998-1999)

Sustainable Energy Education (SEE) Program for Grades 4-8: Preparing Today's Youth for Lifelong Learning and Responsible Actions in Energy Conservation. Research team: Mary Gromko, Colorado Department of Education; Gene McCarthy, Rocky Flats Field Office, U.S. Department of Energy; Gina Kissell, National Renewable Energy Laboratory; and Barbara L. McCombs (PI), Janet L. Bishop, and Sylvia D. Hall-Ellis, Mid-continent Regional Educational Laboratory (Aurora, Colorado). State of Colorado Governor's Office for Energy Conservation, $499,936 (1997-1999)

Review of Kansas Curriculum Standards in Mathematics and Language Arts. Research team: Robert J. Marzano (PI), John S. Kendall, David B. Frost, and Sylvia D. Hall-Ellis, Mid-continent Regional Educational Laboratory (Aurora, Colorado). Submitted to the Kansas State Department of Education, $25,903 (1998)

International Telementor Center. Research team: David Neils, John Kuglin, Chris Rapp, David B. Frost (PI), and Sylvia D. Hall-Ellis, Mid-continent Regional Educational Laboratory (Aurora, Colorado). Hewlett-Packard Company, $54,752 (1998)

Genesis Mission: Education Public Outreach. Developed in partnership by the Jet Propulsion Laboratory, California Institute of Technology, Los Alamos National Laboratory, Lockheed Martin Astronautics, and the Mid-continent Regional Educational Laboratory (Aurora, Colorado). Research team: John T. Sutton (PI), Alice Krueger, Martha Henry, Greg Rawls, Shae Isaacs, Jeff Johnson, Deb Jordan, Arlene Mitchell, David B. Frost, Jana Caldwell, J. Timothy Waters, and Sylvia D. Hall-Ellis. National Aeronautics and Space Administration, $139,700,000; subcontract award, $4,750,000 (1997-2007)

North Dakota Mathematics Assessment Project. Developed in partnership by the North Dakota Department of Education and Mid-continent Regional Educational Laboratory (Mid-continent Regional Educational Laboratory). Research team: Ann Clapper, Clarence Bina, Greg Gallagher, North Dakota Department of Education; Don Burger (PI), Hillary Michaels, and Sylvia D. Hall-Ellis, Mid-continent Regional Educational Laboratory (Aurora, Colorado). U.S. Office of Education, $1,618,214; subcontract award, $389,076 (1997-2001)

Pacific Resources for Education and Learning Distance Education: Project Evaluation. Developed in partnership by the Pacific Educational Community, the Pacific Resources for Education and Learning (PREL), and Mid-continent Regional Educational Laboratory (McREL). Research team: John W. Kofel (PI), Executive Director, PREL; J. Timothy Waters, Executive Director; Joan Buttram, Robert Keller, and Sylvia D. Hall-Ellis, Mid-continent Regional Educational Laboratory (Aurora, Colorado). U.S. Office of Education, Star Schools Program, $10,000,000; subcontract award, $500,000 (1997-2002)

Identification of Bilingual Gifted and Talented Children: A Comprehensive School Grants for Bilingual Education. Developed in partnership by Hidalgo (Texas) ISD, Los Fresnos (Texas) CISD, Progreso (Texas) ISD, University of Texas – Pan American (Edinburg, Texas), and Education Service Center, Region One (Edinburg, Texas). Research team: Hilda Medrano, Dean, College of Education, University of Texas – Pan American; Linda Phemister (PI), Janie Navarro, and Sylvia D. Hall-Ellis, Education Service Center, Region One. U.S. Department of Education, Office of Bilingual Education and Minority Languages Affairs, $1,670,633 (1997-2002)

Academics 2000: First Things First -- The Texas Goals 2000. Developed for Jim Hogg (Hebbronville, Texas) County ISD, Mirando City (Texas) ISD, and San Isidro (Texas) ISD. Research team: Hilda Medrano, Dean, College of Education, University of Texas - Pan American (Edinburg, Texas); Angie Lehmann, Amy Mares, Ellen Gonzalez (PI), and Sylvia D. Hall-Ellis, Education Service Center, Region One (Edinburg, Texas). Texas Education Agency, $339,987 (1997-2000)

Southwestern Bell's Learning Communities Initiative. Developed for Tech Prep of the Rio Grande Valley, Inc. (Harlingen, Texas); the Center for Professional Teacher Development, University of Texas – Brownsville; Teach for America – Rio Grande Valley (McAllen, Texas); and Education Service Center, Region One (Edinburg, Texas). Research team: Patricia G. Bubb, Executive Director (PI), Tech Prep of the Rio Grande Valley; Martin Winchester, Executive Director, Teach for America – Rio Grande Valley; Aileen Johnson, Director, School of Education, University of Texas – Brownsville; and Sylvia D. Hall-Ellis. Southwestern Bell Foundation, $100,000 (1997-1998)

Texas School to Work: Regional Implementation. Developed for Tech Prep of the Rio Grande Valley, Inc. (Harlingen), South Texas Community College (McAllen), Texas State Technical College (Harlingen), Texas Southmost College (Brownsville), Empowerment Zone of the Rio Grande Valley (Mercedes), Project VIDA (Weslaco), Youth Fair Chance (McAllen), and Education Service Center, Region One (Edinburg). Research team: Patricia G. Bubb (PI), Tech Prep of the Rio Grande Valley; Stephen Vassberg, Texas State Technical College; Ellen Trevino, Youth Fair Chance; Wanda Garza, Project VIDA; Leonardo Olivares, University of Texas – Pan American; Michael Bell, South Texas Community College; and Sylvia D. Hall-Ellis. Texas Workforce Commission, $4,250,000 (1997-2002).

Comprehensive Bilingual Education Grant for Hidalgo ISD and Roma ISD. Developed for Hidalgo (Texas) ISD, Roma (Texas) ISD, College of Education, University of Texas – Pan American (Edinburg, Texas), and Education Service Center, Region One (Edinburg, Texas). Research team: Tomas Thomas (PI), Director, Office of Bilingual Education and Sylvia D. Hall-Ellis. U.S. Department of Education, Office of Bilingual Education and Minority Languages Affairs, $1,531,361 (1997-2002)

Lopez High School, Porter High School, Rivera High School, Central Middle School, and Perkins Middle School, Brownsville (Texas) Independent School District. Telecommunications Infrastructure Fund Board, $1,473,611 (1997-1998)

Donna High School, Todd Middle School, and Solis Middle School, Donna (Texas) Independent School District. Telecommunications Infrastructure Fund Board, $704,052 (1997-1998)

Memorial Middle School and Nellie Schunior Middle School, La Joya Independent School District (Texas). Telecommunications Infrastructure Fund Board, $293,641 (1997-1998)

Martin High School, Christen Middle School, Cigarroa Middle School, Lamar Middle School, Laredo (Texas) Independent School District. Telecommunications Infrastructure Fund Board, $1,200,000 (1997-1998).

Lasara Middle School, Lasara (Texas) Independent School District. Telecommunications Infrastructure Fund Board, $246,210 (1997-1998)

Los Fresnos High School and Resaca Middle School, Los Fresnos (Texas) Consolidated Independent School District. Telecommunications Infrastructure Fund Board, $500,000 (1997-1998)

Lyford Junior High School, Lyford (Texas) Independent School District. Telecommunications Infrastructure Fund Board, $354,997 (1997-1998)

Travis Middle School, McAllen (Texas) Independent School District. Telecommunications Infrastructure Fund Board, $269,139 (1997-1998)

Mission High School, Mission (Texas) Independent School District. Telecommunications Infrastructure Fund Board, $297,010 (1997-1998)

Progreso High School, Progreso (Texas) Independent School District. Telecommunications Infrastructure Fund Board, $300,000 (1997-1998)

San Perlita High School, San Perlita (Texas) Independent School District. Telecommunications Infrastructure Fund Board, $293,490 (1997-1998)

Myra Green Junior High School, Raymondville (Texas) Independent School District. Telecommunications Infrastructure Fund Board, $225,000 (1997-1998)

Rio Grande City High School, Ringgold Middle School, Gruella Middle School, Rio Grande City (Texas) Independent School District. Telecommunications Infrastructure Fund Board, $809,934 (1997-1998)

Rio Hondo Junior High School, Rio Hondo (Texas) Independent School District. Telecommunications Infrastructure Fund Board, $297,024 (1997-1998)

Roma High School, Roma (Texas) Independent School District. Telecommunications Infrastructure Fund Board, $333,178 (1997-1998)

San Benito High School, Miller Jordan Junior High School, San Benito (Texas) Consolidated Independent School District. Telecommunications Infrastructure Fund Board, $547,000 (1997-1998)

Santa Maria High School and Santa Maria Middle School, Santa Maria (Texas) Independent School District. Telecommunications Infrastructure Fund Board, $400,000 (1997-1998)

Salvador High School, United Independent School District (Laredo, Texas). Telecommunications Infrastructure Fund Board, $250,879 (1997-1998)

Weslaco High School, Cabaza Middle School, Cuellar Middle School, Weslaco (Texas) Independent School District. Telecommunications Infrastructure Fund Board, $874,242 (1997-1998)

Principals' Assessment and Training Center. Developed for Education Service Center, Region One (Edinburg, Texas). Research team: Roberto Zamora, Leonel Barrera, William H. Parry, and Sylvia D. Hall-Ellis. Texas Principals' Leadership Initiative, Texas Association of Secondary School Principals, Texas Association of Elementary School Principals, and the Sid Richardson Foundation. $461,439 (1996-1998)

The Texas Library Connection -- Integrating and Sharing Resources. Developed for Hidalgo County Library System (McAllen), Cameron County Library System (Brownsville), South Texas Community College (McAllen), the University of Texas - Pan American (Edinburg), University of Texas – Brownsville, and Education Service Center, Region One (Edinburg). Research team: William R. McGee, Coordinator, Hidalgo County Library System; Joe Garcia, Director, Cameron County Library System; Michael D. Bell, Library Director, South Texas Community College; Eleanor Folger Foster, University Library, University of Texas - Pan American; Jaime Vela (PI), Director of Instructional Technology and Media Services, Ron Pontius, Instructional Technology, and Fabiola Fuentes, Media Services, Education Service Center, Region One; and Sylvia D. Hall-Ellis. Office of Library Media Services, Technology Services, Texas Education Agency. $8,000 (1996-1997)

Developing Leadership Communities for Improving Algebra I for All Students. Developed for a partnership of the Region One Statewide Systemic Initiative Team. Research team: Noel Villarreal (PI), Eduardo Cancino, and Sylvia D. Hall-Ellis, Education Service Center, Region One (Edinburg). Texas Statewide Systemic Initiative for Reform in Mathematics, Science and Technology Education to The Charles A. Dana Center for Mathematics and Science Education, The University of Texas at Austin. $25,000 (1996-1997)

Academics 2000: First Things First -- The Texas Goals 2000. Developed for Edinburg (Texas) CISD. Research team: Hilda Medrano, Dean, College of Education, University of Texas - Pan American (Edinburg); Helen Jones, Director (PI), Gifted and Talented Education, Edinburg CISD; and Sylvia D. Hall-Ellis, Education Service Center, Region One (Edinburg). Texas Education Agency, $750,000 (1996-2001)

Texas Teachers Empowered for Achievement in Mathematics (TEXTEAM) Institute for Algebra I. Developed for Hidalgo ISD, Jim Hogg (Hebbronville) County ISD, La Joya ISD, La Villa ISD, Lyford ISD, Mission CISD, Pharr-San Juan-Alamo ISD, Rio Hondo ISD, San Isidro ISD, San Perlita ISD, Santa Maria ISD, Santa Rosa, Sharyland ISD, Valley View ISD, Webb (Laredo) CISD, Weslaco ISD, and Zapata County (Zapata) ISD. Research team: Noel Villarreal (PI), Chuck McInteer, Ellen M. Gonzalez, Education Service Center, Region One (Edinburg); and Sylvia D. Hall-Ellis. Charles A. Dana Center for Mathematics and Science Education, University of Texas - Austin, $15,975 (1996)

Community Learning Center for La Villa, Texas. Developed for Edcouch-Elsa Independent School District. Research team: Noe Gonzalez (PI), Assistant Superintendent, Edcouch-Elsa Independent School District, and Sylvia D. Hall-Ellis. Delta Region Subzone, Rio Grande Valley (Texas) Rural Empowerment Zone, $325,000 (1996-1997)

Monte Alto (Texas) Community Learning Center. Developed for Monte Alto Independent School District. Research team: Homero A. Diaz (PI), Superintendent, Monte Alto Independent School District, and Sylvia D. Hall-Ellis. Delta Region Subzone, Rio Grande Valley (Texas) Rural Empowerment Zone, $300,000 (1996-1997)

Community Learning Center for La Villa, Texas. Developed for La Villa Independent School District. Research team: Sam Gonzalez (PI), Assistant Superintendent, La Villa Independent School District; and Sylvia D. Hall-Ellis. Delta Region Subzone, Rio Grande Valley (Texas) Rural Empowerment Zone, $325,000 (1996-1997)

Building Project for Taylor Elementary. Developed for Mercedes (Texas) Independent School District. Research team: Mrs. Denise Rivera, Librarian, and Eduardo Infante, Principal, Taylor Elementary School; Ismael S. Cantu (PI), Federal Programs Director, Mercedes Independent School District; and Sylvia D. Hall-Ellis. Delta Region Subzone, Rio Grande Valley (Texas) Rural Empowerment Zone, $375,000 (1996-1997)

Border Education Network (BEN) - Distance Education through Cable Television. Developed for Edinburg (Texas) Consolidated Independent School District. Research team: Noe Torres (PI), Library Media Specialist, Magdalena Rosas, Library Media and Technology Coordinator, Edinburg Consolidated Independent School District; and Sylvia D. Hall-Ellis, Education Service Center, Region One (Edinburg). Edinburg (Texas) Consolidated School District, $250,000 (1996-1997)

Multiservice One-Stop Open Enrollment Charter School. Developed for the Information Referral Resource Assistance, Inc. (McAllen, Texas). Research team: Pablo Perez and Aguie Pena (PI), Executive Director, Information Referral Resource Assistance, Inc.; Roberto Zamora and Sylvia D. Hall-Ellis, Education Service Center, Region One (Edinburg). Texas Education Agency, $3,066,000 (1996-2001)

Project OK: A Community Youth Opportunities Grant for Summer, 1996. Developed for McAllen (Texas) Independent School District, St. Joseph the Worker Catholic Church, and the Office of Adult Education, Education Service Center, Region One. Research team: Father Bart Flatt, St. Joseph the Worker Catholic Church; Noe Calvillo (PI), Office of Adult Education; Maria Louisa Garcia, McAllen Independent School District; and Sylvia D. Hall-Ellis, Education Service Center, Region One (Edinburg). Texas Protective and Regulatory Agency through the Office of the Mayor, City of McAllen, $350,000 (1996-2001).

Early Childhood: a Time of Discovery. Developed for a partnership of Lasara ISD, Rio Hondo ISD, San Perlita ISD, the School of Education, University of Texas - Brownsville, and Education Service Center, Region One (Edinburg). Research team: Hugo Rodriguez, Dean, School of Education, University of Texas - Pan American; Leonel Barrera and Jack Damron, Field Service Agents, Ellen M. Gonzalez (PI), Administrator for Student Instructional Services, Ruth Solis, Education Specialist in Special Education, and Sylvia D. Hall-Ellis, Education Service Center, Region One (Edinburg). Texas Education Agency, $722,090 (1996-2001)

Innovative Gifted and Talented Programs for Early Childhood and Elementary Education Students. Developed for a partnership of Edinburg (Texas) CISD, the School of Education, University of Texas - Pan American (Edinburg), and Education Service Center, Region One (Edinburg). Research team: Hilda Medrano, Dean, School of Education, University of Texas - Pan American; Helen de la Garza (PI), Director of Elementary Curriculum and Instruction, Edinburg CISD; and Sylvia D. Hall-Ellis. Texas Education Agency, $750,000 (1996-2001)

Reading Recovery in Early Elementary Grades. Developed for a partnership of La Villa (Texas) ISD the School of Education, University of Texas - Pan American (Edinburg), and Education Service Center, Region One (Edinburg). Research team: Hilda Medrano, Dean, School of Education, University of Texas - Pan American; Marcario Salinas (PI), Supervisor of Elementary Curriculum and Instruction, La Villa ISD; and Sylvia D. Hall-Ellis, Education Service Center, Region One. Texas Education Agency, $750,000 (1996-2001)

Connected Mathematics Project for Middle and Junior High Students. Developed for a partnership of Michigan State University, The Charles A. Dana Center for Mathematics and Science Education, The University of Texas at Austin and Region One Statewide Systemic Initiative Team. Research team: Jack Damron, Chuck McInteer, Noel Villarreal (PI), and Sylvia D. Hall-Ellis, Education Service Center, Region One (Edinburg). National Science Foundation through Michigan State University to the Charles A. Dana Center at the University of Texas - Austin, $539,610 (1996-1999)

Sharing Resources: Testing the Interlibrary Loan Potential of the Texas Library Connection -- Integrating Media Resources. Developed under the sponsorship of the Hidalgo County Library System (McAllen) and Education Service Center, Region One (Edinburg). Research team: William H. McGee, Hidalgo County System Coordinator; Fabiola Fuentes, Library Media; Ronald Pontius (PI), Instructional Technology, Education Service Center, Region One; and Sylvia D. Hall-Ellis. Library Media Services Program, Office of Technology Services, Texas Education Agency, $25,000 (1996-1997)

State and Federal Adult Education JOBS Program. Developed for Education Service Center, Region One (Edinburg). Research team: Noe Calvillo (PI), Director, Adult Education Program, and Sylvia D. Hall-Ellis. Adult Education Program, Texas Education Agency, $532,846 (1995-1996)

Creating Safe and Drug-Free Schools and Communities. Developed for a partnership of the Region One Consortium for Safe and Drug-Free Education Environments. Research team: Clara Contreras (PI), Health Specialist, and Sylvia D. Hall-Ellis, Education Service Center, Region One (Edinburg). Texas Education Agency, $150,000 (1995-1996)

Developing Leadership Communities for Improving Mathematics Performance for All Students on Title I Campuses. Developed for a partnership of the Region One Statewide Systemic Initiative Team. Research team: Jack Damron, Chuck McInteer, Noel Villarreal (PI), and Sylvia D. Hall-Ellis, Education Service Center, Region One (Edinburg). Texas Statewide Systemic Initiative for Reform in Mathematics, Science and Technology Education to The Charles A. Dana Center for Mathematics and Science Education, The University of Texas at Austin, $50,669 (1995-1996)

The Impact of Library Resource Centers on Academic Achievement in Selected Public Schools in South Texas. Sylvia D. Hall-Ellis (PI). Developed under the sponsorship of the Department of Library Science, College of Education and Applied Science, Sam Houston State University (Huntsville). Texas Association of School Librarians, Children's Services Round Table, and Young Adults Round Table (Austin, Texas), $2,500 (1995)

School Library Media Specialists Fellowship Program. Sylvia D. Hall-Ellis (PI). Developed under the sponsorship of the Department of Library Science, College of Education and Applied Science, Sam Houston State University (Huntsville, Texas). U.S. Department of Education, HEA Title II-B, Library Education and Human Resource Development Program, $44,000 (1995-1996)

Planning for Educational Technology. Research team: Ruth Ann Riggins (PI), Director of Library Media and Technology Services, Donna (Texas) Independent School District; Noe Torres, Education Service Center, Region One; Patricia G. Bubb, Tech Prep of the Rio Grande Calley, Inc; Michael D. Bell, South Texas Community College; and Sylvia D. Hall-Ellis, Sam Houston State University. Developed under the sponsorship of Donna (Texas) Independent School District, Education Service Center, Region One (Edinburg), Tech Prep of the Rio Grande Valley, Inc. (Harlingen), South Texas Community College (McAllen), and the Department of Library Science, Sam Houston State University (Huntsville). Funded through Infusion of Educational Technology Planning Grant Program (H.B. 18: Models). Texas Education Agency, $18,000 (1993-1994)

The Impact of Library Resource Centers on Academic Achievement in Selected Public Schools in South Texas. Sylvia D. Hall-Ellis (PI) and Mary Ann Berry. Developed under the sponsorship of the Department of Library Science, College of Education and Applied Science, Sam Houston State University (Huntsville). Sam Houston State University Research Enhancement Fund, $7,500 (1993-1994)

Electronic Mail Resource Sharing System: Management and Operation of the Iowa Computer-Assisted Network. State Library of Iowa, $294,000 (1986-1993)

The Iowa Locator: A CD-ROM Resource Sharing Tool. State Library of Iowa, $567,000 (1986-1992)

Statewide Database Development: An OCLC Tape Analysis To Determine Feasibility. State Library of South Dakota, $15,000 (1987)

The Iowa Locator: A Feasibility Study. State Library of Iowa, $50,000 (1986)

Electronic Mail Resource Sharing System: A Feasibility Study for Libraries in the State of Iowa. State Library of Iowa, $5,000 (1985)

Access Pennsylvania: A Feasibility Study. State Library of Pennsylvania, $50,000 (1984)

Automating Library Administrative and Management Tasks: Procurement and Distribution of Microcomputer Systems for District Library Centers in the Commonwealth of Pennsylvania. State Library of Pennsylvania, $495,000 (1982)

Sharing Serial Titles Resources: Procurement and Distribution of Microfiche Readers for 550 Libraries in the Commonwealth of Pennsylvania. State Library of Pennsylvania, $500,000 (1982)

Electronic Mail System: A Pilot Project for Libraries throughout the Commonwealth of Pennsylvania. State Library of Pennsylvania, $125,000 (1982)

Literacy Program for Adults in Rural Upstate New York State: Program Outreach and Evaluation - Phase 3. Appalachian Regional Commission, $50,000 (1981)

Database Building: A Cooperative Project of the Finger Lakes Library System (Ithaca), Four County Library System (Binghamton), and the Southern Tier Library System (Corning). New York State Library, $450,000 (1980-1985)

Faces of the Southern Tier: A Professional Photographer-in-Residence. New York State National Endowment for the Humanities, $25,000 (1980)

Literacy Program for Adults in Rural Upstate New York State: Program Implementation - Phase 2. Appalachian Regional Commission, $50,000 (1980)

Small Business Resources Center: A Pilot Project for Rural Public Libraries. New York State Library, $50,000 (1980)

Media Programming: A Professional Development Program for Public Librarians in Upstate New York: A Program in Allegheny, Chemung, Schuyler, Steuben, and Yates Counties. New York State Library, $35,000 (1979)

Information and Library Resources for Inmates and Prisoners in Selected Upstate New York Facilities: A Cooperative Program in Allegheny, Chemung, Schuyler, Steuben, and Yates Counties. New York State Library, $25,000 (1979)

Library Resources for Homebound Adults in Upstate New York: An Outreach Program in Allegheny, Chemung, Schuyler, Steuben, and Yates Counties. New York State Library, $40,000 (1979)

Literacy Program for Adults in Rural Upstate New York State: Program Initiation and Establishment - Phase 1. Funded by the Appalachian Regional Commission. Awarded to the Corning (New York) Public Library, $50,000 (1979)

Information Reference Services to Homebound Adults. New York State Library, $31,000 (1978)

Books-By-Mail Services to Homebound Adults. New York State Library, $31,000 (1978)

System Headquarters Services and Programs for Public Libraries in District 10. Funded through Library Services and Construction Act Title I. Texas State Library and Historical Commission, $880,000 (1976)

County Library Development Grant for Atascosita County. Funded through Library Services and Construction Act Title I. Texas State Library and Historical Commission, $15,000 (1976)

Spanish Language Materials Collection Development Program. Texas State Library and Historical Commission, $40,000 (1975)

Establishment of System Headquarters for Alamo Regional Library System (District 10) Headquartered at the San Antonio (Texas) Public Library. Texas State Library and Historical Commission, $800,000 (1975)

SELECTED CONSULTANTSHIPS

Project Strategic Planning & Funding Proposal Development

Walden University, 2015.
Pikes Peak Library District, 2014.
Douglas County Public Libraries, 2011-2012.
Denver School for Science and Technology, 2008-2011.
Johnson & Wales University, Denver Campus, 2007-2009.
Challenges, Choices, and Images K-12 Charter School, Denver Public Schools, 2007.
Denver Medical Library, Inc., 2006-2010.
Bemis Public Library (Littleton), Ergonomic Design and Facilities Enhancement Consultant, 2003.
Curtis Park Community Center (Denver), Community Technology Center Evaluation and Proposal Development Consultant, 2003.
Colorado Community Based Research Network (Denver), Funding Research Associate, 2002.
Our Lady of the Rosary Academy (Edgewater), Learning Resource Center Development Project Consultant, 2001-2003
University of Southern Colorado (Pueblo). Technology Integration and Curriculum Enhancement into Higher Education Learning Environment. Proposal Development Consultant, 2000.
Jefferson County Library System (Lakewood), 1999-2000.
Southeastern BOCES (Lamar, CO). Distance Learning Curriculum Content Development Project. Proposal Development Consultant, 1998-2004.
Cheyenne Mountain School District 12 (Colorado Springs, CO). Technology Integration into Elementary Writing Curriculum Project. Proposal Development Consultant, 1998.
Telecommunications Infrastructure Fund Board Round #2 Application, 1997. Technical assistance to the following: La Villa (Texas) Independent School District; Mirando City (Texas) Independent School District; Monte Alto (Texas) Independent School District; San Isidro (Texas) Independent School District.
Telecommunications Infrastructure Fund Board Round #1, 1996. Technical assistance to the following: Brownsville (Texas) Independent School District; Donna (Texas) Independent School District; Edinburg (Texas) Consolidated Independent School District; Harlingen (Texas) Consolidated Independent School District; Jim Hogg County Independent School District (Hebbronville, Texas); La Feria (Texas) Independent School District; La Joya (Texas) Independent School District; La Villa (Texas) Independent School District; Los Fresnos (Texas) Consolidated Independent School District; Progreso (Texas) Independent School District; Raymondville (Texas) Independent School District; Rio Hondo (Texas) Independent School District; San Benito (Texas) Independent School District; Sharyland Independent School District (Mission, Texas); Weslaco (Texas) Independent School District; Zapata (Texas) County Independent School District.
South Texas Community College (McAllen). Strategy Development to Meet the Technology Instructional Needs for Vocational, School-To-Work and Academic Programs, 1994-2000. Development Consultant.
Donna (Texas) Independent School District. Planning for the Infusion of Technology in Middle Schools Serving High At-Risk Students, 1994-1995. Research Associate.
Pettus (Texas) Independent School District. Planning for District-wide Automation in School Library Media Centers: Preparation of Data, and CD-ROM Hardware/Software Configuration Evaluation, 1994. Principal Investigator.
Fort Bend Independent School District (Sugar Land, TX). Planning for District-wide Automation in School Library Media Centers, Preparation of Data, and CD-ROM Hardware/Software Configuration Evaluation, 1994-1995. Principal Investigator.
Northern Waters Library Services (Ashland, WI). Professional Consulting Services to Make Recommendations on the Development of System-Wide Efforts of the Northern Waters Library Service, 1988-1989. Research Associate.
State Library of Iowa (Des Moines). The Iowa Locator Compact Disc to Support Multi-Type Libraries Resource Sharing including Database Design, Building, Production, and Distribution, 1986-1991. Project Director.
State Library of Iowa (Des Moines). Iowa Computer-Assisted Network Development, Enhancement, and Operation, 1985-1992. Technical Director.
State Library of South Dakota (Pierre). Statistical Sampling and Analysis of Multi-Institutional OCLC Archive Tape for Statewide Online Database Building, 1985-1986. Research Associate.
District of Columbia Public Library (Washington, DC). Planning Document for the Retrospective Conversion of Bibliographic Records and Automation Issues in the 1990's, 1984-1985. Research Associate.

State Library of Pennsylvania (Harrisburg). Database Development for High School Libraries, 1984-1985. Research Associate.
MINITEX (Minneapolis, MN). Workshops for Retrospective Conversion, Bar Coding, Library Statistics, and OCLC Serials Format, 1985. Presenter and Research Associate.
ABC Film Consortium (Altoona, Bellefonte, Johnstown, PA). Database Building, System Design, and Implementation of Online Film Booking System, 1983-1985. Database Manager.

Library Automation -- System Design & Implementation

Douglas County Library District (Castle Rock, CO). Library Automation Technical and System Performance Specifications, 2001.
Pharr-San Juan-Alamo Independent School District (Pharr, TX). Library Automation Technical and System Performance Specifications, 1997. Project Development Consultant.
Harlingen (Texas) Independent School District. Planning for District-wide Automation in Junior High School Library Media Centers: Preparation of Data, and CD-ROM Hardware/Software Configuration Evaluation, 1996. Principal Investigator.
Sharyland (Texas) Independent School District. Design and Construction of New Elementary School Library and Technology Resources Center, 1995-1996. Principal Investigator.
South Texas Independent School District (Mercedes, TX). Design and Construction of a New High School Library and Technology Resources Center, 1995-1996. Principal Investigator.
Citizens' Library (Washington, PA). Online Community Resources Files: Design and Implementation, 1984. Research Associate.
Altoona (Pennsylvania) Hospital. Integrated Online System Upgrade Study, 1984. Research Associate.
State Library of South Dakota (Pierre). Automation Plan and State Database Development, 1982-1983. Principal Investigator.
State Library of Pennsylvania (Harrisburg). COM Production and Preparation of the Technical Specifications Document, Procurement, and Distribution of Microcomputers in the Commonwealth of Pennsylvania, 1983-1984. Research Associate.
Altoona (Pennsylvania) Area Public Library. Integrated System (Circulation/Online Catalog) Study, 1982-1983. Principal Investigator.
COPSCAULD (Council of Pennsylvania State College and University Library Directors, Edinboro, PA). Design of Online Media Catalog, 1982. Principal Investigator.
Erie (Pennsylvania) County Library System. Operations Research and Design for Automated Circulation, Hardware Upgrade and Re-Retrospective Conversion, 1982. Research Associate.
Michigan Library Consortium (Lansing, MI). Tape Management System Design and Implementation, 1982-1984. Research Associate.
State Library of Pennsylvania (Harrisburg). Preparation of the Technical Specifications Document, Procurement and Distribution of Microfiche Readers in the Commonwealth of Pennsylvania, 1982. Research Associate.
Community College of Allegheny County, Allegheny Campus (Pittsburgh, PA). Integrated Systems Study, 1981. Principal Investigator.
Community College of Allegheny County, South Campus (West Mifflin, PA). Retrospective Conversion Training Program for Handicapped Students, 1981. Technical Director.
Southern Tier Library System (Corning, NY). OCLC Acquisitions Subsystem Evaluation, 1981. Principal Investigator.
South Central Reference and Research Council (Ithaca, NY). South Central Regional Delivery System, 1980. Principal Investigator.
Southern Tier Library System (Corning, NY). Newspapers on Microfilm in the Chemung-Southern Tier Library System, 1979-1981. Principal Investigator.

Cataloging & Bibliographic Database Building

Challenges, Choices, and Images K-12 Charter School, Denver Public Schools, 2007.
Denver Medical Library, Inc., 2006-2010.
Ricks Gifted and Talented School Library, 2005-
American Humane Society (Englewood), 2004-2006.
Fisher Early Learning Center Library, 2004-

Colorado Community Based Research Network (Denver), 2004-
Boulder Valley School District (Boulder), 2002-2003.
Douglas Public Library District (Castle Rock), 2001-2002.

Bibliographic Center for Research, Inc. (Denver). Original Cataloging, 2001-2003 & 1992-1993. Professional Cataloger. Libraries include Arapahoe Library District (Centennial); Clarke College (Clarke, IA); Kaiser Permanente Center for Health Research (Portland, KS); Douglas County Library System (Carson City, NV); Grinnell College (Grinnell, IA); Kansas State University (Manhattan, KS); Kansas State Library (Topeka, KS); McPherson College (McPherson, KS); Newman University (Wichita, KS); Montana Technical University (Helena, MT); Montana State Library (Helena, MT); University of Texas Southwest Medical Center Library (Dallas, TX); Community College of Southern Nevada (Las Vegas, NV); Pikes Peak Library District (Colorado Springs); Mesa Community College (Grand Junction); Coe College (Cedar Rapids, IA); Briar Cliff College (Sioux City, IA); Tri-Care Health Systems (Aurora); The Penrose-St. Francis Healthcare System (Colorado Springs); Westminster Public Library (Westminster); Lutheran Medical Center Medical Library (Wheat Ridge); American Heritage Center, University of Wyoming (Laramie, WY); National Wildlife Research Center Library (Lakewood); University of Colorado Health Sciences Center, Denison Memorial Library (Denver); Water Resources Library, Denver District Office, Bureau of Land Management (Lakewood); Mesa State Community College Learning Resources Center (Pueblo); Front Range Community College Learning Resources Center (Westminster).

Colorado Historical Society Library (Denver). Original Cataloging of Serials for Multi-Institutional Union Listing Project, 1993. Technical Services Associate. Institutional partners: Denver Art Museum, Denver Museum of Natural History Library, and Denver Botanical Gardens Library.

Arapahoe Library District (Centennial). Original Cataloging of Major Media, 1991.

Original Cataloging Projects: Davis and Elkins College (Elkins, WV), 1989-1990; Waldorf College (Forest City, IA), 1989-1990; Kennametal Corporation (Latrobe, PA), 1984-1985; Pennsylvania Public Libraries Film Center (Harrisburg), 1982-1985.

Retrospective Conversion Projects: North Central Regional Library Service (Mason City, IA), 1987-1988; Southeastern Library Services (Davenport, IA), 1986-1987; Virginia Theological Seminary (Alexandria), 1984-1985; California University of Pennsylvania (California, PA), 1984-1985; Kennametal Corporation (Latrobe, PA), 1984-1985; West Virginia University (Morgantown), 1983-1985; Altoona Area Public Library (Altoona, PA), 1983-1984; George Washington University (Washington, DC), 1983-1984; Indiana University of Pennsylvania (Indiana, PA), 1983-1985; Health Education Center (Pittsburgh), 1983-1984; Central Pennsylvania District Library Center (Bellefonte, PA), 1982-1985; Duquesne University Law School Library (Pittsburgh), 1982-1983; Allegheny County Law Library (Pittsburgh), 1982-1984; Calgon Technical Information Center (Pittsburgh), 1982; Dow Corning Corporation, Technical Information Center (Midland, MI), 1982-1983; Tri-System Public Library Retrospective Conversion Project (Binghamton, Corning, and Ithaca, NY), 1978-1981, Technical Project Director.

Updated July 2025

Exhibit 1005

Elsevier

May/June 2013
Volume 52, Number 3

The Journal of Foot & Ankle Surgery®

Proven leaders. Lifelong learners. Changing lives.

Official Publication of the
American College of Foot and Ankle Surgeons

The Journal of Foot & Ankle Surgery®

EDITOR
D. Scot Malay, DPM, MSCE, FACFAS

SECTION EDITORS

Adult Reconstruction — Forefoot
Luke D. Cicchinelli, DPM, FACFAS
Paul D. Dayton, DPM, MS, FACFAS
Molly Schnirring-Judge, DPM, FACFAS
John T. Marcoux, DPM, FACFAS
Vincent J. Muscarella, DPM, FACFAS

Adult Reconstruction — Rearfoot & Ankle
Lawrence A. DiDomenico, DPM, FACFAS
Michael S. Downey, DPM, FACFAS
George T. Liu, DPM, FACFAS
Laurence G. Rubin, DPM, FACFAS

Diabetes
William P. Grant, DPM, FACFAS
Paul J. Kim, DPM, FACFAS
John S. Steinberg, DPM, FACFAS

Medicine/Rheumatology
Donald Kushner, DPM, FACFAS
Thomas E. Lyons, DPM, FACFAS

Pediatrics
Patrick S. Agnew, DPM, FACFAS
Richard N. Goad, DPM, FACFAS
Edwin J. Harris, DPM, FACFAS

Research
Emily A. Cook, DPM, MPH, FACFAS
Jeremy J. Cook, DPM, MPH, FACFAS
Robert M. Joseph, DPM, PhD, FACFAS
Bradley M. Lamm, DPM, FACFAS
Naohiro Shibuya, DPM, MS, FACFAS
Paul H. Wooley, PhD

Sports Medicine
Richard T. Bouché, DPM, FACFAS
Amol Saxena, DPM, FACFAS

Trauma
Mark A. Hardy, DPM, FACFAS
Christopher F. Hyer, DPM, FACFAS
Stephen A. Mariash, DPM, FACFAS
Benjamin D. Overley, Jr., DPM, FACFAS
Narendra R. Patel, DPM, FACFAS
Shannon M. Rush, DPM, FACFAS

Tumors/Pathology
Bo Jian, MD, PhD
Lawrence Osher, DPM
Herrick J. Siegel, MD

AUDIO FILE EDITOR
Robert A. Hadfield, DPM, AACFAS

EDITORS EMERITUS

Earl G. Kaplan, DPM
Lowell Scott Weil, Sr., DPM, FACFAS
Richard P. Reinherz, DPM
John M. Schuberth, DPM

COUNCIL FOR JOURNAL MANAGEMENT
Troy J. Boffeli, DPM, FACFAS, Chairman
Lawrence M. Fallat, DPM, FACFAS
Geoffrey M. Habershaw, DPM, FACFAS
Stephen H. Silvani, DPM, FACFAS
John S. Steinberg, DPM, FACFAS
Glenn M. Weinraub, DPM, FACFAS

AMERICAN COLLEGE OF FOOT AND ANKLE SURGEONS

BOARD OF DIRECTORS

PRESIDENT
Jordan P. Grossman, DPM, FACFAS
PRESIDENT-ELECT
Thomas S. Roukis, DPM, PhD, FACFAS
SECRETARY-TREASURER
Richard Derner, DPM, FACFAS
IMMEDIATE PAST PRESIDENT
Michelle L. Butterworth, DPM, FACFAS

DIRECTORS
Kris A. DiNucci, DPM, FACFAS
Sean T. Grambart, DPM, FACFAS
Christopher F. Hyer, DPM, FACFAS
Christopher L. Reeves, DPM, FACFAS
Laurence G. Rubin, DPM, FACFAS
John S. Steinberg, DPM, FACFAS
DIVISION PRESIDENTS COUNCIL, CHAIRMAN
Randall L. Wraalstad, DPM, FACFAS

EXECUTIVE DIRECTOR
J. C. (Chris) Mahaffey, MS, CAE, FASAE
8725 West Higgins Road, Suite 555
Chicago, IL 60631-2724
PHONE: 773-693-9300
FAX: 773-693-9304
www.acfas.org

The Journal of Foot & Ankle Surgery®

VOLUME 52, NUMBER 3 MAY/JUNE 2013

Contents

EDITORIAL

Impact Factors and Other Measures of a Journal's Influence 285
D. Scot Malay, DPM, MSCE, FACFAS

ORIGINAL RESEARCH

A Retrospective Comparison of Percutaneous Plantar Fasciotomy and Open Plantar Fasciotomy with Heel Spur Resection 288
Lawrence M. Fallat, DPM, FACFAS; J. Todd Cox, DPM; Ruby Chahal, DPM; Pamela Morrison, DPM, FACFAS; John Kish, PhD

Clinical Usage and Influence of Radiographs in the Assessment of Hallux Valgus 291
John Malik, FCPodS; Ian Mathieson, PhD

Reconstruction of Lisfranc Joint Dislocations Secondary to Charcot Neuroarthropathy Using a Plantar Plate 295
Dave Garchar, DPM; Lawrence A. DiDomenico, DPM, FACFAS; Kaj Klaue, MD

Lateral Release in Hallux Valgus Deformity: From Anatomic Study to Surgical Tip 298
Rastislav Hromádka, MD, PhD; Vladislav Barták, MD, PhD; Jiří Bek, MD; Stanislav Popelka Jr., MD; Jana Bednářová; Stanislav Popelka, MD, PhD

Distal Chevron Osteotomy with Lateral Soft Tissue Release for Moderate to Severe Hallux Valgus Decided Using Intraoperative Varus Stress Radiographs 303
Hyong-Nyun Kim, MD, PhD; Yoo-Jung Park, MD; Gab-Lae Kim, MD; Yong-Wook Park, MD, PhD

Dynamic Ultrasonography: A Cadaveric Model for Evaluating Aseptic Loosening of Total Ankle Arthroplasty 311
Paul M. Ryan, MD; Michael W. Downey, DPM; David Fortenbaugh, PhD, MS; John Kirchner, MD

Fixation Orientation in Ankle Fractures with Syndesmosis Injury 315
Craig J. Nimick, DPM; David R. Collman, DPM, FACFAS; Pieter Lagaay, DPM, FACFAS

Ultrasound Assessment of Bilateral Symmetry in Dorsal Lisfranc Ligament 319
Joshua J. Marshall, BA; Nathan C. Graves, DPM; David D. Rettedal, BSc; Katherine Frush, DPM, AACFAS; Vassilios Vardaxis, PhD

Foot Deformity Correction with Hexapod External Fixator, the Ortho-SUV Frame™ 324
Munetomo Takata, MD; Victor A. Vilensky, MD, PhD; Hiroyuki Tsuchiya, MD, PhD; Leonid N. Solomin, MD, PhD

Evaluation of Joint Position Sense Measured by Inversion Angle Replication Error in Patients with an Osteochondral Lesion of the Talus 331
Tomoyuki Nakasa, MD, PhD; Nobuo Adachi, MD, PhD; Hayatoshi Shibuya, MD, PhD; Atsushi Okuhara, MD, PhD; Mitsuo Ochi, MD, PhD

Incidence of Repeat Amputation after Partial First Ray Amputation Associated with Diabetes Mellitus and Peripheral Neuropathy: An 11-Year Review 335
Sara L. Borkosky, DPM; Thomas S. Roukis, DPM, PhD, FACFAS

Biomechanical Comparison of a Locking Plate with Intraplate Compression Screw Versus Locking Plate with Plantar Interfragmentary Screw for Lapidus Arthrodesis: A Cadaveric Study . . . 339
James M. Cottom, DPM; Ryan B. Rigby, DPM, AACFAS

Sagittal Alignment of the First Metatarsophalangeal Joint after Arthrodesis for Rheumatoid Forefoot Deformity 343
Akihiko Tanabe, MD; Tokifumi Majima, MD; Tomohiro Onodera, MD; Naohiro Sawaguchi, MD; Takuya Watanabe, MD; Yasuhiko Kasahara, MD; Daisuke Takahashi, MD

Relationship of Frontal Plane Rotation of First Metatarsal to Proximal Articular Set Angle and Hallux Alignment in Patients Undergoing Tarsometatarsal Arthrodesis for Hallux Abducto Valgus: A Case Series and Critical Review of the Literature 348
Paul Dayton, DPM, MS, FACFAS; Mindi Feilmeier, DPM, FACFAS; Merrell Kauwe, BS; Jordan Hirschi, BS

Relationship of Alignment and Tibial Cortical Coverage to Hypertrophic Bone Formation in Salto Talaris® Total Ankle Arthroplasty 355
Christy M. King, DPM, AACFAS; John M. Schuberth, DPM; Jeffrey C. Christensen, DPM, FACFAS; Katie M. Swanstrom, DPM, AACFAS

CASE REPORTS AND SERIES

Intraosseous Lipoma of the Calcaneus: Report of a Case and Review of the Literature 360
Dadjo K. Aumar, MD; Yves B.A. Dadjo, MD; Belkacem Chagar, PhD

Chance Fracture of the Talus and Calcaneum 364
Sarah Lancaster, MBChB, MRCS; William Harries

Isolated Transcalcaneal Talonavicular Dislocation: A Severe Injury Related to a Low-energy Mechanism 367
Nicholas T. Ventham, MRCS (Eng), MBBS; Joideep Phadnis, MRCS (Eng); Arunan Sujenthiran, MRCS (Eng); Alex J. Trompeter, MBBS, BSc, FRCS (Tr+Orth); Palanisamy Ramesh, FRCS

***Burkholderia pseudomallei* Osteomyelitis of the Metatarsal in an Infant** 370
Deeptiman James, MS; Vrisha Madhuri, MS, MCh; Abhay Deodas Gahukamble, MS; Lisa Choudhrie, MD; Padmaja Pancharatnam, MD

Treatment of Acute Jones Fracture with Ilizarov External Minifixator: Case Series of Six Elite Athletes 374
Slavko Tomic, MD, PhD; Vuk Vucic, MD; Milan Dobric, MD; Greg Bisignani, MD

An Unusual Aberrant Muscle in Congenital Clubfoot: An Intraoperative Finding 380
Sameh Mahmoud Abo El-Fadl, MD

Transmetatarsal Amputation in the Setting of Antiphospholipid Antibody Syndrome 383
Jacob M. McLeod, DPM; Charles O. Brantigan, MD; Kristen Alix, FNP;
Dustin L. Kruse, DPM, MA, AACFAS; Paul A. Stone, DPM, FACFAS

Simultaneous Development of Dieterich Disease and Freiberg Disease 389
Xavier Conesa, MD; Xavier González, MD; Eduard Siles, MD, PhD; Fèlix Parals, MD;
Josep Novell, MD, PhD

Complete Medial Dislocation of the Tarsal Navicular without Fracture: Report of a Rare Injury 393
Adrian T. Davis, MD; Adam Dann, DO; Djoldas Kuldjanov, MD

TIPS, QUIPS, AND PEARLS

Use of Femoral Locking Plate for Salvage of Failed Ankle Arthoplasty after Trauma 397
Lawrence A. DiDomenico, DPM, FACFAS; Zachary M. Thomas, DPM

Fixation of a Posteromedial Osteochondral Lesion of the Talus Using a Three-Portal Posterior Arthroscopic Technique 402
Hyong Nyun Kim, MD, PhD; Gab Lae Kim, MD; Jae Yong Park, MD; Kyung Jei Woo, MD;
Yong Wook Park, MD, PhD

Calcaneal Z Osteotomy for Extra-articular Correction of Hindfoot Valgus 406
Ryan T. Scott, DPM, AACFAS; Gregory C. Berlet, MD

Technical Considerations for Surgical Intervention of Jones Fractures 409
Robert W. Mendicino, DPM, FACFAS; Matthew J. Hentges, DPM; Michael R. Mendicino;
Alan R. Catanzariti, DPM, FACFAS

INVESTIGATORS' CORNER

The Medium Is the Message: Thoughts on Picture Perfect Presentation 415
Daniel C. Jupiter, PhD

The Journal of Foot & Ankle Surgery®

INFORMATION FOR SUBSCRIBERS

The Journal of Foot & Ankle Surgery® (ISSN 1067-2516) is published bimonthly by Elsevier Inc., 360 Park Avenue South, New York, NY 10010-1710. For Post Office use only: Volume 52, issue 3 of 6. Months of issue are January, March, May, July, September, and November. Periodicals postage paid at New York, NY and additional mailing offices.

POSTMASTER: Send address changes to *Journal of Foot & Ankle Surgery*, Elsevier Health Sciences Division, Subscription Customer Service, 3251 Riverport Lane, Maryland Heights, MO 63043.

Website: www.jfas.org

Editorial correspondence should be addressed to D. Scot Malay, DPM, MSCE, FACFAS, Editor, *The Journal of Foot & Ankle Surgery*®, 2314 Waverly Street, Philadelphia, PA 19146; telephone/fax: 215-967-4463; e-mail: editorjfas@gmail.com

Author inquiries: For inquiries relating to the submission of articles (including electronic submission where available) please visit www.elsevier.com/authors. This site also provides the facility to track accepted articles and set up e-mail alerts to inform you of when an article's status has changed, as well as detailed artwork guidelines, copyright information, frequently asked questions, and more. Contact details for questions arising after acceptance of an article, especially those relating to proofs, are provided after registration of an article for publication.

Information regarding ACFAS membership: Contact the American College of Foot & Ankle Surgeons, 8725 West Higgins Road, Suite 555, Chicago, IL 60631-2724. Phone: (773) 693-9300. Fax: (773) 693-9304.

Correspondence regarding subscriptions or change of address should be directed to *The Journal of Foot & Ankle Surgery*®, 3251 Riverport Lane, Maryland Heights, MO 63043. E-mail: elspcs@elsevier.com **ACFAS members, please contact the College with your change.**

Change of address notices, including both the old and new addresses of the subscriber and the mailing label, should be sent at least one month in advance.

Customer Service: Elsevier Health Sciences Division, Subscription Customer Service, 3251 Riverport Lane, Maryland Heights, MO 63043. Tel: 1-800-654-2452 (U.S. and Canada); 314-447-8871 (outside U.S. and Canada). Fax: 314-447-8029. E-mail: journalscustomerservice-usa@elsevier.com (for print support); journalsonlinesupport-usa@elsevier.com (for online support).

Yearly subscription rates: *ACFAS members: Annual dues include* $35 *for* Journal *subscription. Nonmember rates:* United States and possessions: individuals, $184; institutions, $354; students and residents, $92. All other countries: individuals, $260; institutions, $446; students and residents, $129. For all areas outside the United States and possessions, there is no additional charge for surface delivery. To receive student/resident rate, orders must be accompanied by name of affiliated institution, date of term, and the *signature* of program/residency coordinator on institution letterhead. Orders will be billed at individual rate until proof of status is received.

Prices are subject to change without notice. Current prices are in effect for back volumes and back issues. Single issues, both current and back, exist in limited qualities and are offered for sale subject to availability. Back issues sold in conjunction with a subscription are on a prorated basis. Checks should be made payable to Elsevier and sent to *The Journal of Foot & Ankle Surgery*®, 3251 Riverport Lane, Maryland Heights, MO 63043.

Copyright © 2013 by the American College of Foot and Ankle Surgeons. All rights reserved. No part of this publication may be reproduced or transmitted in any form or by any means now or hereafter known, electronic or mechanical, including photocopy, recording, or any information storage and retrieval system, without permission in writing from the Publisher. Printed in the United States of America.

Correspondence regarding permission to reprint all or part of any article published in this journal may be sought directly from Elsevier's Rights Department in Philadelphia, PA, USA; phone: (215) 239-3804, fax: (215) 239-3805, e-mail: healthpermissions@elsevier.com. Requests may also be completed on-line via the Elsevier homepage (www.elsevier.com/locate/permissions).

The appearance of the code at the bottom of the first page of an article in this journal indicates the copyright owner's consent that copies of the article may be made for personal or internal use, or for the personal or internal use of specific clients, for those registered with the Copyright Clearance Center, Inc. (222 Rosewood Drive, Danvers, MA 01923; (978) 750-8400; www.copyright.com). This consent is given on the condition that the copier pay the stated per-copy fee for that article through the Copyright Clearance Center, Inc. for copying beyond that permitted by Sections 107 or 108 of the US Copyright Law. This consent does not extend to other kinds of copying, such as copying for general distribution, for advertising or promotional purposes, for creating new collective works, or for resale. Absence of the code indicates that the material may not be processed through the Copyright Clearance Center, Inc.

Reprints of single articles available online may be obtained by purchasing Pay-Per-View access for $25 per article on the journal Web site, www.jfas.org. For 100 or more copies of an article in this publication, please contact the Commercial Reprints Department, Elsevier Science Inc., 360 Park Avenue South, New York, NY 10010-1710. Telephone: (212) 633-3813, Fax: (212) 633-3820, e-mail: reprints@elsevier.com.

Advertising representative: Elsevier, 360 Park Ave South, New York, NY 10010. For Product Advertising Sales, and Recruitment & Classified Advertising Sales, contact: Danny Wang, Tel: 212-633-3158; Fax: 212-633-3820.

The ideas and opinions expressed in *The Journal of Foot & Ankle Surgery*® are those of the authors and do not necessarily reflect those of the American College of Foot and Ankle Surgeons, the Editor, or the Publisher. Publication of an advertisement or other product mention in *The Journal of Foot & Ankle Surgery*® should not be construed as an endorsement of the product or the manufacturer's claims. Readers are encouraged to contact the manufacturer with any questions about the features or limitations of the products mentioned. Neither the American College of Foot and Ankle Surgeons nor the Publisher assumes any responsibility for any injury and/or damage to persons or property arising out of or related to any use of the material contained in this periodical. The reader is advised to check the appropriate medical literature and the product information currently provided by the manufacturer of each device or of each drug to be administered to verify the dosage, the method and duration of administration, or contraindications. It is the responsibility of the treating physician or other health care professionals, relying on independent experience and knowledge of the patient, to determine drug dosages and the best treatment for the patient.

The contents of *The Journal of Foot & Ankle Surgery*® are currently included by the following services in print and/or electronic format: *Index Medicus, Excerpta Medica, Biosciences Information,* and *CINAHL.*

This material may be protected by Copyright law (Title 17 U.S. Code)

The Journal of Foot & Ankle Surgery 52 (2013) 348–354

Contents lists available at ScienceDirect

The Journal of Foot & Ankle Surgery

journal homepage: www.jfas.org

Relationship of Frontal Plane Rotation of First Metatarsal to Proximal Articular Set Angle and Hallux Alignment in Patients Undergoing Tarsometatarsal Arthrodesis for Hallux Abducto Valgus: A Case Series and Critical Review of the Literature

Paul Dayton, DPM, MS, FACFAS [1], Mindi Feilmeier, DPM, FACFAS [2], Merrell Kauwe, BS [3], Jordan Hirschi, BS [3]

[1] *Director, Podiatric Medicine and Surgery Residency, Trimark Physicians Group, Trinity Regional Medical Center; and Adjunct Professor, College of Podiatric Medicine and Surgery, Des Moines University, Fort Dodge, IA*
[2] *Assistant Professor, Des Moines University College of Podiatric Medicine and Surgery, Des Moines, IA*
[3] *Podiatric Medical Student, Des Moines University College of Podiatric Medicine and Surgery, Des Moines, IA*

ARTICLE INFO

Level of Clinical Evidence: 4
Keywords:
bunion
CORA
fixation
Lapidus arthrodesis
surgery
toe
triplane deformity

ABSTRACT

Rotation of the first metatarsal, as a component of hallux abducto valgus, is rarely discussed and is not addressed as a component of most hallux valgus corrective procedures. We believe frontal plane rotation of the first metatarsal to be an integral component of hallux abducto valgus deformity (the "third plane of deformity") and believe de-rotation is necessary for complete deformity correction. We observed the change in angular measurements commonly used in the evaluation of hallux valgus deformity in patients who underwent a modified lapidus procedure. We measured the intermetatarsal angle, hallux abductus angle, proximal articular set angle, and tibial sesamoid position on weightbearing radiographs of 25 feet in 24 patients who had undergone tarsal metatarsal corrective arthrodesis and lateral capsular release. Specific attention was given to reduction of the frontal plane rotation of the first metatarsal during correction. Our results showed a change in the angular measurements observed by 4 investigators as follows. The mean change in the intermetatarsal angle was 10.1° ($p < .0001$). The mean change in the hallux abductus angle was 17.8° ($p < .0001$). The mean change in the proximal articular set angle was 18.7° ($p < .0001$). The mean change in the tibial sesamoid position was 3.8 ($p < .0001$). Also, a consistent valgus, or everted position of the first metatarsal, was noted as a component of the hallux abducto valgus deformity in our patient population and was corrected by varus rotation or inversion of the metatarsal. We also reviewed the current literature related to anatomic changes in the first ray in the patient with hallux valgus deformity and reviewed our hypothesis regarding the reduction in the proximal articular set angle, which we believe to be related to frontal plane rotation of the first metatarsal, resulting in a radiographic artifact.

© 2013 by the American College of Foot and Ankle Surgeons. All rights reserved.

Measurement of the 2-dimensional radiographic angular relationships has become an integral part of the evaluation and management of hallux abducto valgus (HAV) deformity. The intermetatarsal angle (IMA), hallux abductus angle (HAA), proximal articular set angle (PASA), and tibial sesamoid position are all commonly measured in an attempt to define the continuum of the HAV deformity. Although these measurements are common in practice, we question whether these 2-dimensional parameters accurately describe the HAV deformity. We know from studying anatomic reports that the first ray deformity associated with HAV is actually a triplane deformity with components of the deformity in the transverse, sagittal, and the third, or frontal, plane (1,2). A review of the published data revealed a question regarding the accuracy and reproducibility of these angular measurements, especially the PASA (3,4). Chi et al (4), in 2002, questioned the accuracy and validity of the PASA. They noted in a series of patients who underwent proximal first ray procedures a consistent reduction in the PASA without distal procedures (4). We have noted in our series that this reduction in PASA was consistent and quite dramatic after tarsal–metatarsal corrective arthrodesis. We hypothesized that this reduction resulted from attention to frontal plane rotational correction in addition to transverse plane and sagittal plane correction. From our observations, we believe the PASA might be a radiographic artifact, rather than a fixed deformity of the first metatarsal head. Using this concept of frontal plane rotational correction, we have been able to obtain excellent correction of the HAA, IM, and PASA with no metatarsal head procedures. Additionally, we have questioned the necessity of the commonly used first metatarsophalangeal joint (MTPJ) release

Financial Disclosure: None reported.
Conflict of Interest: None reported.
Address correspondence to: Paul Dayton, DPM, MS, FACFAS, Director, Podiatric Medicine and Surgery Residency, Trimark Physicians Group, Trinity Regional Medical Center, 804 Kenyon Road, Suite 310, Fort Dodge, IA 50501.
E-mail address: daytonp@me.com (P. Dayton).

1067-2516/$ - see front matter © 2013 by the American College of Foot and Ankle Surgeons. All rights reserved.
http://dx.doi.org/10.1053/j.jfas.2013.01.006

and soft tissue balancing. A case series is presented, along with a literature review, to support our hypothesis.

Patients and Methods

The radiographic records of patients who had undergone a tarsal metatarsal corrective arthrodesis procedure for HAV from 2009 to 2011 by 2 of us (P.D., M.F.) were retrospectively reviewed. The Des Moines University institutional review board approved the record review. Only patients who had undergone tarsal metatarsal arthrodesis for HAV with limited soft tissue release and no other osseous procedures in the first ray were included in the present review. Limited soft tissue release was defined as lateral capsular release through a medial intracapsular approach. An additional inclusion criterion was the availability of preoperative and postoperative weightbearing anterior posterior radiographs of sufficient quality to make angular measurements. All 4 of us evaluated the IM, HAA, PASA, and tibial sesamoid position measurements independently. The measurement technique was consistent with the recommendations from Gerbert (5). The measurements were recorded, and the mean change in each measurement from preoperatively to postoperatively was calculated. The statistical analysis included calculation of the mean change in the preoperative and postoperative values after the patients were able to ambulate independently and perform full weightbearing for radiographic examination. We then used a paired *t* test to determine whether the pre- and postoperative measurements differed in each of the 4 characteristics that were measured.

The determination of outcomes such as union rate and patient satisfaction were considered to be outside the scope of the present review. We studied only the radiographic changes in position resulting from the procedure.

Surgical Procedure

All patients were evaluated and determined to be satisfactory candidates for the surgical procedure from a medical and anesthetic standpoint. Conservative care and preoperative consent were in accordance with the accepted standards of the American College of Foot and Ankle Surgeons treatment guidelines (6). The procedures were performed using general anesthesia or local anesthesia with sedation, as determined by medical appropriateness and patient preference. All procedures were performed with the patient in the supine position with standard extremity preparation and a single dose of prophylactic antibiotic given within 30 minutes of the initial incision. In general, tourniquet hemostasis was used. The first step involved a lateral sesamoid ligament release through a medial midline incision without subcutaneous separation. The plantar joint pouch was entered, and the sesamoids were retracted plantarly, allowing access to the lateral capsule. The lateral capsule was incised in the transverse plane only. No additional soft tissue release was performed, including no release or dissection of the dorsal capsule, no tendon releases or transfers, and no capsular plication. In most cases, no medial metatarsal head resection was performed.

The incision for the tarsal–metatarsal fusion was placed dorsally, directly over the joint. Again, dissection was minimal, avoiding plane separation and preserving the perforating blood supply. Most of the tissue separation was subcapsular and subperiosteal. Initially, we simply observed the frontal plane rotation needed to realign the joint. In later cases, before release of the tarsometatarsal joint (TMTJ) and resection of the articular surfaces, 2 smooth, 2-mm, pins were placed directly in the sagittal plane and parallel, 1 in the base of the metatarsal and 1 in the cuneiform. These pins were used as a reference to more easily visualize the rotation of the metatarsal in the frontal plane. The joint surfaces were next resected, including the cartilage and all subchondral bone. The cuts were oriented to correct the transverse and sagittal components, as needed, with the first metatarsal cut perpendicular to the long axis of the metatarsal. The cuneiform cut was made such that the distal medial portion of the cuneiform was left intact. This allowed reduction of the IMA without sacrificing the length of the first ray. Next, the rotation of the metatarsal was addressed by rotating the bone in a varus, or inverted, direction until congruous alignment of the first MTPJ and sesamoids was observed clinically and on the fluoroscopic examination. We found that using the reference pins allowed us to better note the direction of the rotation (Fig. 1).

The segments were next temporarily stabilized with smooth wires. The final fixation in our cases consisted of multiple methods, including 2 small, flexible, locking plates placed dorsally and medially, single- and double-screw fixation, and anatomic locking plate with compression screw. The fusion site was positioned with the dorsal and medial cortices flush in all cases. No sliding offset was performed in any plane. Thus, all correction in the sagittal and transverse planes was angular.

Results

A total of 24 patients with 25 procedures were identified as having met the inclusion criteria for the present study. All patients reviewed had undergone tarsal–metatarsal arthrodesis, with the only other first

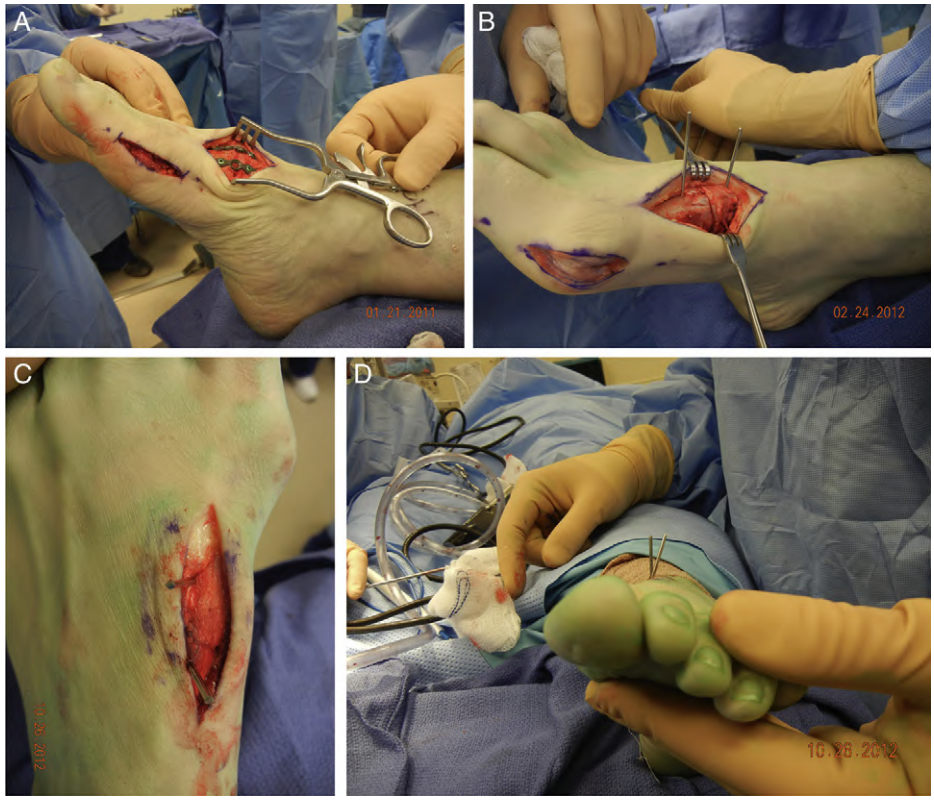

Fig. 1. (*A*) Two-incision approach with medial midline first metatarsal phalangeal incision and 2-plate fixation technique, with (*B*) positioning of reference wires to observe rotation (1 wire in metatarsal base and 1 parallel wire in first cuneiform). (*C*) Varus or inversion rotation of metatarsal indicated by reference wire position after anatomic alignment of first metatarsal and first metatarsal phalangeal joint. (*D*) Second case after correction showing smaller degree but varus or inversion rotation once correction is complete.

ray procedure a limited lateral capsular release through a medial midline incision. Of the 24 patients, 20 were female and 4 were male. The mean age at the procedure was 30.8 (range 14 to 52) years. Four of the patients also underwent lesser metatarsal procedures: 1, an isolated second metatarsal cuneiform arthrodesis; 2, a second and third metatarsal cuneiform arthrodesis; and 1, a fifth metatarsal osteotomy. The preoperative and postoperative IMAs of the 3 patients with the second metatarsal cuneiform arthrodesis procedures were not used in our IMA calculations.

Our first observation was made intraoperatively. In all cases, inversion or varus rotation of the metatarsal was noted when anatomic joint alignment was achieved. Anatomic alignment was determined by congruous reduction of the first MTPJ, anatomic alignment of the HAA, and a normal sesamoid position by both clinical examination and fluoroscopy. Only the direction of the metatarsal or reference pin offset was noted, and no attempt was made to quantify the amount of rotation needed to achieve accurate alignment.

The IMA, HAA, PASA, and tibial sesamoid position were measured on the preoperative and postoperative weightbearing radiographs. The results for each measurement of the 4 investigators were averaged, resulting in a composite mean value. The mean postoperative measurements were significantly lower than the preoperative measurements for each of the 4 traits measured ($p < .0001$, for all tests). The pre- and postoperative measurements for the 4 traits in each patient are shown in Fig. 2.

The mean preoperative IMA was 14.9° (range 10.5° to 23.5°). The mean postoperative IMA was 4.7° (range 1.3° to 7.5°). The mean change in the IMA was 10.1° ($p < .0001$). The mean preoperative HAA was 30.3° (range 18.0° to 48.3°). The mean postoperative HAA was 17.8° (range 4.3° to 21°). The mean change in the HAA was 17.8° ($p < .0001$). The mean preoperative PASA was 25.2° (range 12.8° to 39.3°). The mean postoperative PASA was 6.6° (range 1.3° to 15.0°). The mean change in the PASA was 18.7° ($p < .0001$). The mean preoperative tibial sesamoid position was 5.6 (range 3.3 to 7.0). The mean postoperative tibial sesamoid position was 1.7 (range 1.0 to 4.0). The mean change in the tibial sesamoid position was 3.8 ($p < .0001$).

No complications were noted in the observed postoperative period, including no deep infections, no wound healing issues, and no need for a return to surgery. The healing rates and healing times and postoperative function scoring were not observed and were considered outside the scope of the present review.

Discussion

The surgical approaches for HAV include a myriad of procedures with countless modifications of osteotomies and soft tissue balancing procedures. The procedures are typically classified into metatarsal head, metatarsal shaft, metatarsal base, and distal or proximal arthrodesis. A combination of these procedures is often recommended. The search for consistent and effective procedures has continued for decades, and the attempts to classify the HAV deformity are numerous. Many have attempted to define the HAV by the etiology and progression of the deformity (7–10). Although many descriptions and opinions have been published, disagreement exists regarding the elemental cause and progression of HAV deformity.

According to Kelikian (7), Carl Hueter first introduced the term "hallux valgus" in 1870. Hueter described the great toe moving away from the midline of the body with a first metatarsal that deviates toward the midline of the body (7). This deformity was termed "metatarsus primus varus" by Walter Truslow (8) in 1925. After noting a bone deformity on radiographs at the first metatarsal cuneiform joint and none at the MTPJ, Truslow concluded, "any operative procedure that does not include the correction of the deformity at its proximal focus is unscientific and inadequate." Although this association of hallux and metatarsal deviation has been widely accepted, which is the primary deformity giving rise to the other has not been.

Munuera et al (9) in 2006 studied the relationship of the HVA to the IMA of metatarsals 1 and 2. They found that a mild HVA deformity

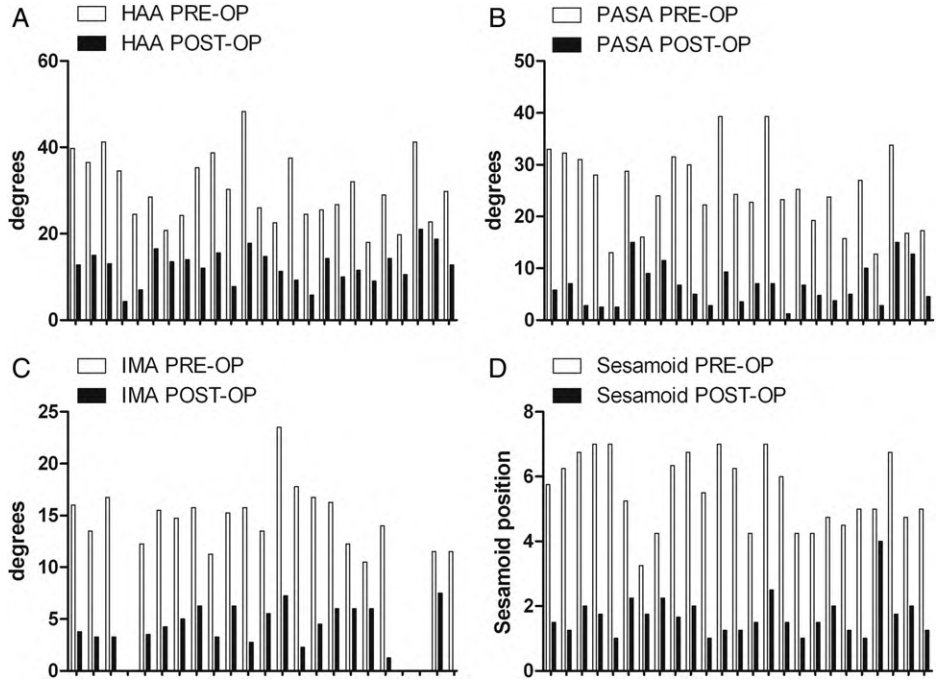

Fig. 2. Results of angular measurements of 25 procedures on preoperative (PRE-OP) and postoperative (POST-OP) weightbearing radiographs, with mean reduction of hallux abductus angle (HAA) of 17.8°, mean reduction of proximal articular set angle (PASA) of 18.7°, mean reduction of intermetatarsal angle (IMA) of 10.1°, and mean reduction of tibial sesamoid position of 3.8.

preceded a clinically meaningful increase in the IMA, leading them to conclude that hallux valgus leads to metatarsus primus varus (9).

Snjeiders et al (10) used a biomechanical study in which they used force vectors to show that walking produced force about a moment arm that deviated the hallux laterally, thereby causing the "spread foot" or medial deviation of the first metatarsal, and recommended that a first MTPJ arthrodesis should be the procedure of choice in addressing HVA deformities (10). Studies have shown that first MTPJ fusions can improve the metatarsus primus varus or IMA without any proximal procedures, possibly because of relief of retrograde buckling of the hallux on the metatarsal (11–13).

Even before Truslow, others had identified the first TMTJ as the apex of the deformity (14,15). Subsequently, other investigators, including Lapidus (16), also suggested that the tarsal metatarsal articulation is the apex and primary deformity in a bunion (17–19).

Although clear etiology and an agreed on progression of HAV deformity eludes us, we must still attempt to define the deformity clinically. Currently, it is taught that the radiographic parameters such as PASA, IMA between the first and second metatarsal, and the HAA must be used to define the deformity and to choose a specific procedure or combination of procedures to correct the HAV deformity. Using these severity-based algorithms, HAV is treated as a continuum of deformities rather than a single deformity. We consider HAV to be a singular deformity, with a consistent level of deformity or center of rotation angulation (CORA), as described by Paley (20). Additionally, we have identified the importance of 3 planar components of the CORA, with the frontal plane rotation ("third plane") playing a central role in the deformity.

Although it might not be intuitive because of generations of teaching and the use of algorithms, the level of the deformity and, therefore, the CORA, as it relates to the evaluation of the HAV deformity, must be considered. All deformities have a position or level at which the deformity originates. As taught by Paley (20), failure to respect this level of deformity prevents accurate alignment of the anatomic and mechanical axes and creates new deformities. Identification of the CORA is vital if we are to correct a deformity without introducing secondary deformities (Fig. 3). If our angulation correction axis, which dictates the level of the osteotomy we make, is located at our CORA, the deformity can be corrected without creating additional or secondary deformities. If we do not address the deformity at the CORA, we will inevitably create secondary deformities in the bone (20). We believe that because most common procedures focus osteotomy or correction at a point in the metatarsal rather than at the metatarsal cuneiform joint, which we believe is the CORA, these procedures will not completely correct the deformity. Many osteotomies create a second deformity while allowing the initial deformity to persist (Fig. 3).

Despite the universality of radiographic analysis of the HAV deformity, disagreement exists regarding the significance and reliability of even our most common measurements. Vanore et al (6), in their clinical guide, defined the PASA as the lateral adaptation of the distal first metatarsal articular surface that occurs with long-standing HAV. PASA is typically assessed on the radiograph but can also be observed qualitatively by direct intraoperative inspection. This angle has also been described as the distal metatarsal articular angle (DMAA). The normal values are 0° to 8°; however, interobserver variability exists, and the value might not correlate with the intraoperative observations (3,4,21–23).

Piggott (24) in 1960 conducted a radiographic study of adolescents and proposed that 4 types of changes occurred at the head of the metatarsal and that those changes determine the severity of the HAV deformity. He determined that these changes at the DMAA were the pre-existing condition that caused the deviation of the metatarsal and the bony prominence of the medial aspect of the foot (24). He also stated that when the DMAA is shifted laterally, it decreases the amount of correction that can be achieved (24). Piggott (24) believed the deformity would be likely to revert back to its preoperative state unless correction has been made at the DMAA.

Coughlin (25), in 1997, took the information that Piggott (24) presented in 1960 and applied it to surgical correction. Coughlin (25) agreed with Piggott (24) and concluded that the reason behind undercorrection of hallux valgus deformities, or the high rate of recurrence seen, resulted from the lack of correction of the DMAA. McInnes and Bouché (26) in 2001 agreed with that tenent and stated that the PASA is responsible for undercorrection of the hallux valgus angle, even if the IMA was completely reduced. They also advised that when performing a modified Lapidus procedure, we should consider a head procedure to correct for the PASA (26).

In 2001, Coughlin and Freund (3) concluded, "The interobserver reliability in the assessment of the DMAA is questioned." Physicians participating in the study did not consistently measure the DMAA with the precision with which they measured the IMA and HAA. Coughlin and Freund (3) further stated that the decreased reliability of this measurement between the different observers resulted from the "difficulty in consistently determining the medial and lateral

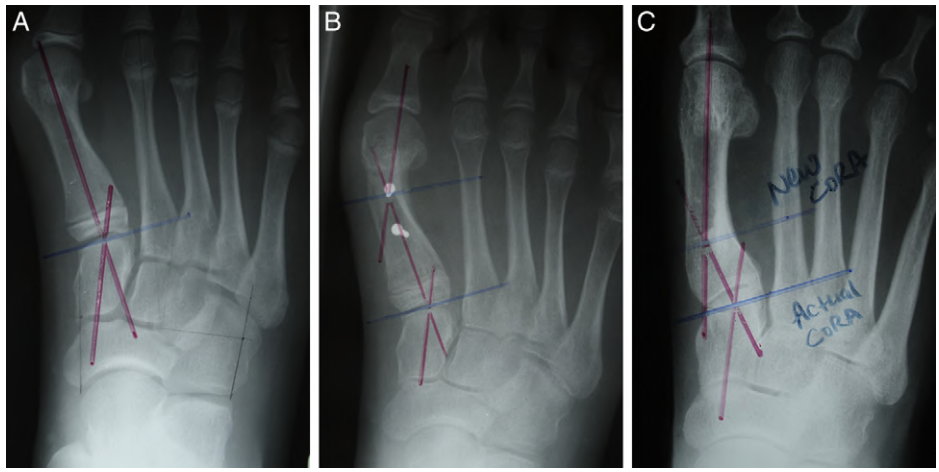

Fig. 3. Evaluation of hallux abducto valgus (HAV) using center of rotation angulation (CORA) principle. Deformity level was at metatarsal cuneiform joint, with no deformity noted in the metatarsal. (*A*) Alignment after midshaft sliding osteotomy showing persistence of original intermetatarsal angle (IMA), nonanatomic alignment of first metatarsophalangeal joint (MTPJ) and sesamoids and new deformity CORA in the metatarsal. (*B*) Alignment after basilar osteotomy using the CORA principle and showing residual CORA at original deformity, a new deformity in the metatarsal, and nonanatomic alignment of the first MTPJ.

extent of the distal metatarsal articular surface." Vittetoe et al (21) and Robinson et al (22) also confirmed that the PASA measurement was unreliable between observers. In both studies, they radiographically measured a cadaveric first metatarsal and found that with frontal plane rotation of the metatarsal, the PASA measurements changed.

Martin (23), in 1993, presented a different perspective on the changes at the head of the metatarsal in his critical analysis of the PASA. Martin (23) found that the preoperative PASA is rarely visualized intraoperatively and was often decreased postoperatively without any procedure to address the PASA or the head of the metatarsal. The study by Chi et al (4) in 2002 also showed a decreased PASA with proximal bunion repair procedures using pre- and postoperative radiographic measurements.

The results from our series agree with the observations of first metatarsal phalangeal realignment and a decreased PASA (18.7° in our series) after tarsal metatarsal corrective arthrodesis. We believe that it is the frontal plane rotation of the metatarsal ("third plane of deformity") that changes the appearance of the articular surface of the metatarsal head on radiographs. Furthermore, we have noted that rotation also allows accurate realignment of the joint and a substantial decrease in the HAA (17.8° in our series). Because the metatarsal head is an imperfect sphere, any change in rotation will have a corresponding change in the direction and profile of the articular surface, both clinically and radiographically. This could be the basis for the changes seen on the pre- and postoperative radiographs (Fig. 4).

We recognize that in some instances the distal metatarsal articular surface might appear deviated on direct inspection. Thordarson and Krewer (27) discussed the idea that the medial cartilage loss resulting from abnormal forces of the deviated hallux might be responsible for the apparent enlargement of the medial eminence. They noted that although the head was more exposed medially, it was not necessarily enlarged (27). Perera et al (28), in 2011, discussed the PASA and noted changes in the angle over time, indicating it might be a developmental, not a fixed or intrinsic, deformity. We believe that this loss of medial cartilage could also change the intraoperative appearance of the articular surface enough to give the appearance of a deviated PASA. This, however, does not, in reality, change the alignment and congruency of the first MTPJ, which is determined by the intrinsic bone shape and position of the first metatarsal in the transverse, sagittal, and frontal planes.

Because of these same observations, we question whether routine resection of the so-called medial eminence is necessary or prudent. We believe the often-described medial eminence enlargement might be accentuated on anteroposterior radiographic examination owing to the abnormal profile caused by eversion, or valgus positioning, of the metatarsal. We rarely find it necessary to resect any significant portion of the metatarsal head once the frontal plane rotation has been corrected. We believe it is prudent to wait until the abnormal frontal plane position is addressed before excising any metatarsal head. We have noted a persistent medial bump in some cases and have found this to be largely due to thickening of the medial capsule. We have found it necessary to thin the capsule to decrease the clinical appearance of medial prominence if noted on clinical inspection after deformity correction.

Reviewing again the common radiographic relationships used to assess the HAV deformity, the measurements are taken in 2 dimensions, with an emphasis on the transverse plane components of the deformity. A lower priority is typically placed on the sagittal plane component of the deformity. The least consideration is given to the frontal plane rotation in both the radiographic evaluation and the procedure choice. Although rotation of the first metatarsal as a component of the HAV deformity has been described, the definitions have been inconsistent. Some investigators have been in favor of inversion of the first ray on dorsiflexion. Hicks (29), in 1953, used 5 normal amputated feet and, after attaching pulleys and springs, isolated the motion of extension and supination in the first ray (i.e., dorsiflexion and inversion). Ebisui (30), in 1968, found that as he applied internal and external rotary forces to 15 freshly amputated legs, dorsiflexion of the first ray occurred with internal rotation of the leg. This happened about the axis Hicks had determined and carried with it concomitant inversion of the first ray. In 1982, Kelso et al (31) manually moved the first ray on an immobile hindfoot into

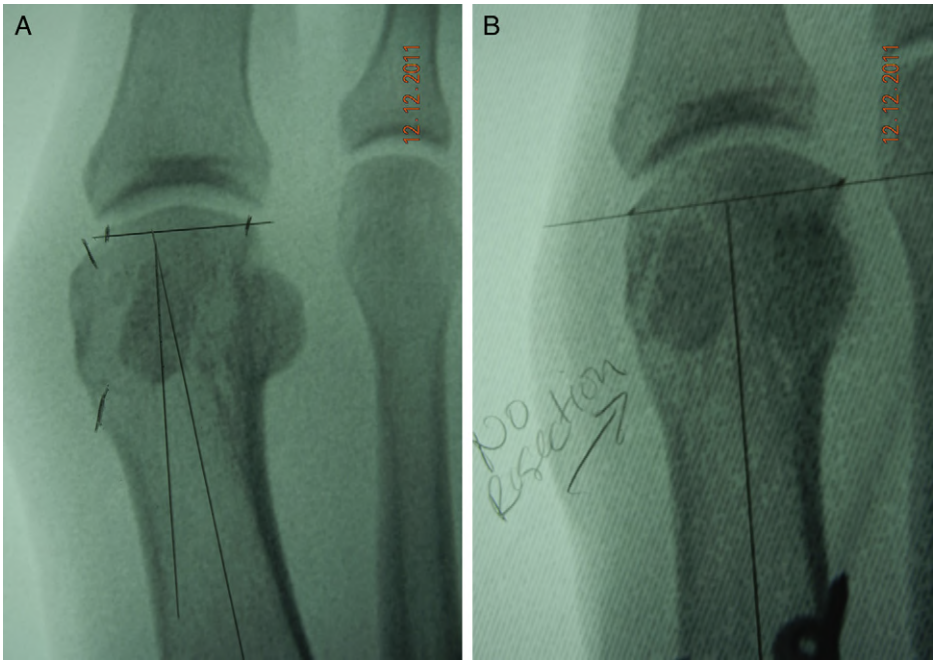

Fig. 4. (*A*) Preoperative first metatarsophalangeal joint alignment and apparent prominence of medial eminence. (*B*) Postoperative first metatarsophalangeal joint alignment showing reduction in proximal articular set angle after rotation and reduction in apparent prominence of medial eminence without bone resection.

dorsiflexion and plantarflexion. Using pins as reference points, they found that inversion occurred as the first ray was dorsiflexed (31).

These findings of dorsiflexion and inversion have been opposed in a number of studies starting in 1974 with Inman (32). Inman (32) used a pin in the hallux to show that as the leg was internally rotated, the foot pronated and the hallux everted into a valgus rotated position. He interpreted this to mean that the entire first ray everted as it dorsiflexed (32). In 1979, D'Amico and Schuster (33) used pins to visually show that as they manually moved 5 cadaver feet from a neutral to a pronated position the dorsal surface of the first metatarsal moved medially and inferiorly. Therefore, it everted as it was dorsiflexed (33). Also, in 1979, Oldenbrook and Smith (34) used accelerometers to measure first ray motion in 5 cadaveric feet. All the specimens showed dorsiflexion and eversion occurring in tandem as they internally rotated the leg (34).

Other interesting studies by Scranton and Rutkowski (1) and by Grode and McCarthy (2) investigated feet with bunion deformities. Scranton and Rutkowski (1) used 35 cadaveric and fresh feet. On anatomic inspection, they found that the hallux was in a valgus position and that pronation of the metatarsal head had occurred (1). They hypothesized that this pronation of the metatarsal was the cause of the plantar migration of the abductor hallucis muscle. Grode and McCarthy (2) took 3 cadaveric specimens and subjected them to a cryomicrotomic study. They found that the crista and orientation of the head of the metatarsal in feet with bunion deformities showed clear eversion.

Thus, it is clear that there is no final recommendation on the topic of first ray motion. In our recent experience, we have found consistent valgus rotation, or eversion, of the first metatarsal in association with HAV deformity. In our series, we directly observed varus rotation, or inversion, of the metatarsal to have occurred when the joint was corrected into congruous alignment using TMTJ corrective arthrodesis (Fig. 1). We believe this supports the hypothesis of valgus rotation or eversion of the metatarsal associated with the metatarsus primus adductus seen in hallux valgus. This has led us to our recommendation that rotational correction be considered when correcting the HAV deformity. Unlike most head, shaft, and base osteotomy procedures, TMTJ arthrodesis allows triplane correction at the deformity's CORA. Although measurement and calculation of the absolute amount of rotation were outside the scope of the present review, the direction of rotation we observed was consistent in all patients. Additional prospective studies could be designed to measure the mean amount of rotation and would help to clarify the rotational component of the deformity.

If we can accept that HAV deformity is triplane, it follows that each of these planes should be addressed in the corrective operation. Nearly all head, shaft, and basilar procedures provide measurable correction only in the transverse plane. Many others have attempted correction in the sagittal plane; however, when simple geometry is used, very little sagittal plane correction can be obtained with most angular and sliding metatarsal osteotomies. Also, the location of popular osteotomies is placed within the metatarsal. When considering the deformity correction rules, we question whether sound osteocorrective principles are being used with these procedures if the correction is attempted at a point other than at the CORA. In addition, the fact is evident from intrinsic geometry that most procedures, especially sliding procedures, cannot address frontal plane rotation.

However, tarsal metatarsal corrective arthrodesis can address all 3 planes of the HAV deformity. In our series, joint alignment, including a decrease in the PASA and HAA, was seen concurrently with minimal or no soft tissue balancing and no distal osteotomy. Our preferred lateral capsule/sesamoid ligament release was done from a medial midline incision through the plantar joint pouch. The entire dorsal joint pouch was maintained, and no additional tendon release, tendon balancing, capsulorrhaphy, or other soft tissue procedure was performed to attempt additional correction at the first MTPJ. We believe this further supports the idea of the HAV deformity as a triplane

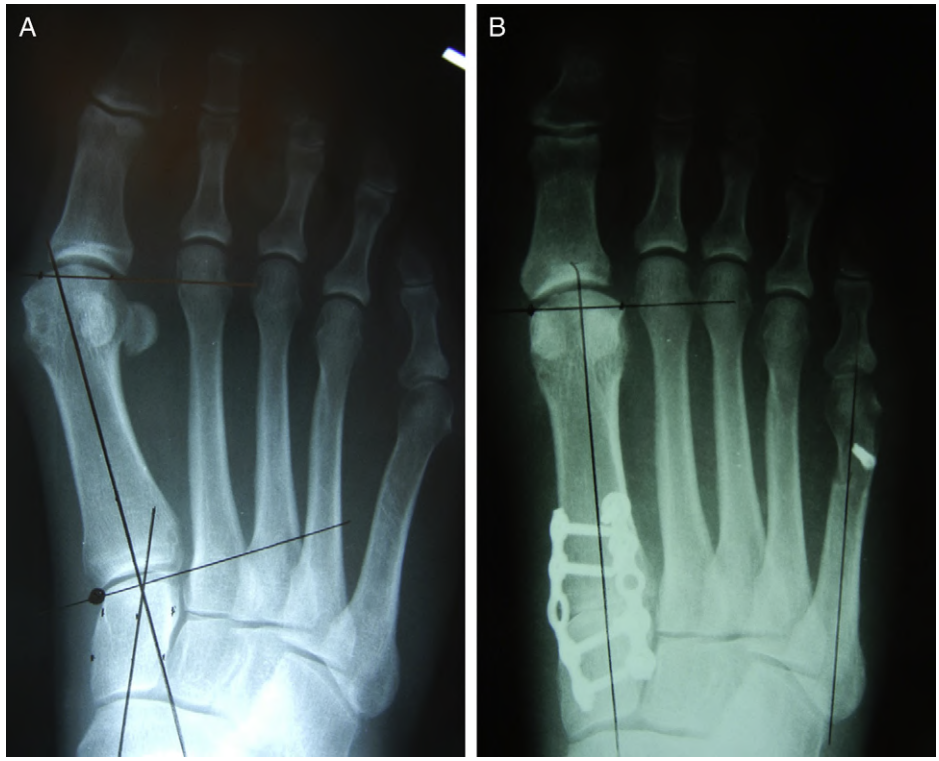

Fig. 5. Alignment of first ray and first metatarsophalangeal joint before (*A*) and after (*B*) tarsal metatarsal corrective arthrodesis. Triplane correction resulted in anatomic alignment of first metatarsophalangeal joint without distal procedures or medial eminence resection.

deformity and indicates that "third plane" or rotational correction is necessary to obtain anatomic alignment at the first metatarsal phalangeal joint and of the sesamoids (Fig. 5). We hypothesized that some de-rotation of the first ray might occur with other procedures and could be based on relieving the retrograde buckling forces that the deformed hallux and first metatarsal phalangeal joint have on the proximal first ray. This example is clear in the case of reduction of the IMA, which is seen after first MTPJ fusion.

Our series has shown a dramatic and consistent reduction in the PASA by simply inverting, or rotating, the metatarsal in a varus direction, with transverse plane and sagittal plane correction during tarsal metatarsal corrective arthrodesis. We consider this the "third" plane of deformity in HAV. As we have noted, most procedures have focused primary attention on the transverse plane of the deformity and have attempted to correct a metatarsal deformity that does not exist. We believe that 2-dimensional radiographic analysis does not accurately define the HAV deformity, because it does not address the third plane. We believe that the frontal plane component is a key component of first MTPJ misalignment in HAV deformity and must be addressed during correction to provide anatomic alignment of the first MTPJ.

Acknowledgment

The authors wish to thank John "Keoni" Kauwe, PhD, Assistant Professor, Department of Biology, Brigham Young University, for technical assistance and statistical analysis of our data.

References

1. Scranton PE, Rutkowski R. Anatomic variations in the first ray—part 1: anatomic aspects related to bunion surgery. Clin Orthop Rel Res 151:244–255, 1980.
2. Grode SE, McCarthy DJ. The anatomical implications of hallux abducto valgus: a cryomicrotomic study. J Am Podiatr Med Assoc 70:539–551, 1980.
3. Coughlin MJ, Freund E, Roger A. Mann award: the reliability of angular measurements in hallux valgus deformities. Foot Ankle Int 22:369–379, 2001.
4. Chi TD, Davitt J, Younger A, Holt S, Sangeorzan BJ. Intra- and inter-observer reliability of the distal metatarsal articular angle in adult hallux valgus. Foot Ankle Int 23:722–726, 2002.
5. Gerbert J, editor. *Textbook of Bunion Surgery*, WB Saunders, New York, 2001.
6. Vanore JV, Christensen JC, Kravitz SR, Schuberth JM, Thomas JL, Weil LS, Zlotoff HJ, Mendicino RW, Couture SD. Clinical Practice Guideline First Metatarsophalangeal Joint Disorders Panel of the American College of Foot and Ankle Surgeons. Diagnosis and treatment of first metatarsophalangeal joint disorders. Section 1: hallux valgus. J Foot Ankle Surg 42:112–123, 2003.
7. Kelikian H. *Hallux Valgus, Allied Deformities of the Forefoot and Metatarsalgia*, WB Saunders, Philadelphia, 1965.
8. Truslow W. Metatarsus primus varus or hallux valgus. J Bone Joint Surg Am 7:98–108, 1925.
9. Munuera PV, Dominquez G, Polo J, Rebollo J. Medial deviation of the first metatarsal in incipient hallux valgus deformity. Foot Ankle Int 27:1030–1035, 2006.
10. Snjeiders CJ, Snijder JG, Philippens MM. Biomechanics of hallux valgus and spread foot. Foot Ankle Int 7:26–39, 1986.
11. Cronin JJ, Limbers JP, Kutty S, Stephens MM. Intermetatarsal angle after first metatarsophalangeal joint arthrodesis for hallux valgus. Foot Ankle Int 27:104–109, 2006.
12. Mann RA, Katcherian DA. Relationship of metatarsophalangeal joint fusion on the intermetatarsal angle. Foot Ankle Int 10:8–11, 1989.
13. Dayton P, LoPiccolo J, Kiley J. Reduction of the intermetatarsal angle after first metatarsophalangeal joint arthrodesis in patients with moderate and severe metatarsus primus adductus. J Foot Ankle Surg 41:316–319, 2002.
14. LeBoucq H. Le développement du premier merararsien et de son articulation arsienne chez l'homme. Arch Biol 3:335, 1882.
15. Picque L. Note sur une cas d'hallux valgus. Bull Mem Soc Chir 28:518–525, 1902.
16. Lapidus P. A quarter century experience with the operation. Bull Hosp Joint Dis 17:404–421, 1956.
17. Tanaka Y, Takakura Y, Kumai T, Samoto N, Tamai S. Radiographic analysis of hallux valgus: a two dimensional coordinate system. J Bone Joint Surg Am 77:205–213, 1995.
18. Morton DJ. Metatarsus atavicus: the identification of a distinctive type of foot disorder. J Bone Joint Surg 9:531–544, 1927.
19. Mashima N, Yamamoto H, Tsuboi I, Tsuchiya H, Tanaka Y, Watanabe S. Correction of hallux valgus deformity using the center of rotation of angulation method. J Orth Sci 14:377–384, 2009.
20. Paley D, Herzenber JE, editors. *Principles of Deformity Correction*, Springer-Velag, Berlin, 2005.
21. Vittetoe DA, Saltzman CL, Krieg JC, Brown TD. Validity and reliability of the first distal metatarsal articular angle. Foot Ankle Int 15:541–547, 1994.
22. Robinson AH, Cullen NP, Chhaya NC, Sri-Ram K, Lynch A. Variation of the distal metatarsal articular angle with axial rotation and inclination of the first metatarsal. Foot Ankle Int Am 27:1036–1040, 2006.
23. Martin DE. Preoperative radiographic evaluation in HAV surgery: a critical analysis of PASA and other soft tissue adaptation. In: *Reconstructive Surgery of the Foot and Leg*, edited by CA Camasta, NS Vickers, JA Ruch, Podiatry Institute, Tucker, GA, 1993.
24. Piggott H. The natural history of hallux valgus in adolescence and early adult life. J Bone Joint Surg Br 42:749–760, 1960.
25. Coughlin MJ. Hallux valgus in men: effect of the distal metatarsal articular angle on hallux valgus correction. Foot Ankle Int 18:463–470, 1997.
26. McInnes BD, Bouché RT. Critical evaluation of the modified Lapidus procedure. J Foot Ankle Surg 40:71–90, 2001.
27. Thordarson DB, Krewer P. Medial eminence thickness with and without hallux valgus. Foot Ankle Int 23:48–50, 2002.
28. Perera AM, Mason L, Stephens MM. Current concepts review: the pathogenesis of hallux valgus. J Bone Joint Surg 93:1650–1661, 2011.
29. Hicks JH. The mechanics of the foot. Part I: the joints. J Anat 87:345–357, 1953.
30. Ebisui JM. The first ray axis and the first metatarsal phalangeal joint: an anatomical and pathomechanical study. J Am Podiatr Med Assoc 58:160–168, 1968.
31. Kelso SF, Richie DH Jr, Cohen IR, Weed JH, Root ML. Direction and range of motion of the first ray. J Am Podiatr Med Assoc 72:600–605, 1982.
32. Inman VT. Hallux valgus: a review of etiologic factors. Orthop Clin North Am 5:59–66, 1974.
33. D'Amico JC, Schuster RO. Motion of the first ray: clarification through investigation. J Am Podiatr Med Assoc 69:17–23, 1979.
34. Oldenbrook LL, Smith CE. Metatarsal head motion secondary to rearfoot pronation and supination: an anatomical investigation. J Am Podiatr Med Assoc 69:24–28, 1979.

Exhibit 1011

1

VOLUME

McGLAMRY'S COMPREHENSIVE TEXTBOOK OF FOOT AND ANKLE SURGERY

FOURTH EDITION

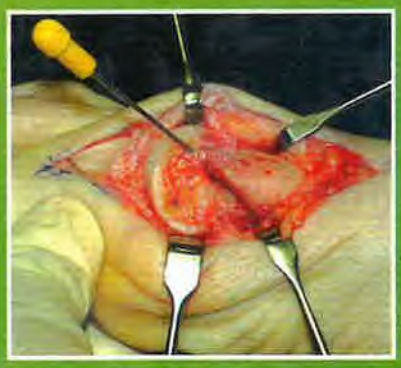

Joe T. Southerland
Jeffrey S. Boberg • Michael S. Downey
Aprajita Nakra • Linnie V. Rabjohn

INCLUDES FULLY SEARCHABLE TEXT ONLINE

Wolters Kluwer Health | Lippincott Williams & Wilkins

VOLUME ONE

McGLAMRY'S

Comprehensive Textbook of Foot and Ankle Surgery

Fourth Edition

EDITOR

JOE T. SOUTHERLAND, DPM, FACFAS
Faculty
The Podiatry Institute
Decatur, Georgia
Private Practice
Arlington/Mansfield Foot and Ankle Centers
Arlington, Texas

AUTHORS' EDITOR

DANIEL F. VICKERS, CAE
Executive Director
The Podiatry Institute
Decatur, Georgia

SECTION EDITORS

JEFFREY S. BOBERG, DPM, FACFAS
Faculty
The Podiatry Institute
Decatur, Georgia
Private Practice
St. Louis, Missouri

MICHAEL S. DOWNEY, DPM, FACFAS
Faculty
The Podiatry Institute
Decatur, Georgia
Clinical Professor and Former Chairman, Department of Surgery
Temple University School of Podiatric Medicine
Chief, Division of Podiatric Surgery
Penn Presbyterian Medical Center
Private Practice
Ankle and Foot Medical Centers of the Delaware Valley
Philadelphia, Pennsylvania

APRAJITA NAKRA, DPM, FACFAS
Faculty
The Podiatry Institute
Decatur, Georgia
Private Practice
Phoenix and Gilbert, Arizona

LINNIE V. RABJOHN, DPM, FACFAS
Private Practice
Arlington/Mansfield Foot and Ankle Centers
Arlington, Texas

Wolters Kluwer | Lippincott Williams & Wilkins
Health

Philadelphia • Baltimore • New York • London
Buenos Aires • Hong Kong • Sydney • Tokyo

Acquisitions Editor: Brian Brown
Product Manager: Dave Murphy
Marketing Manager: Lisa Lawrence
Design Manager: Doug Smock
Manufacturing Manager: Benjamin Rivera
Prepress Vendor: SPi Global

4th edition

Copyright © 2013 Wolters Kluwer Health | Lippincott Williams & Wilkins.

All rights reserved. This book is protected by copyright. No part of this book may be reproduced or transmitted in any form or by any means, including as photocopies or scanned-in or other electronic copies, or utilized by any information storage and retrieval system without written permission from the copyright owner, except for brief quotations embodied in critical articles and reviews. Materials appearing in this book prepared by individuals as part of their official duties as U.S. government employees are not covered by the above-mentioned copyright. To request permission, please contact Lippincott Williams & Wilkins at Two Commerce Square, 2001 Market St., Philadelphia, PA 19103, via email at permissions@lww.com, or via our website at lww.com (products and services).

Printed in China

Library of Congress Cataloging-in-Publication Data
McGlamry's comprehensive textbook of foot and ankle surgery. — 4th ed. / editor, Joe T. Southerland ; section editors, Jeffrey S. Boberg, Michael S. Downey, Aprajita Nakra, Linnie V. Rabjohn.
p. ; cm.
Comprehensive textbook of foot and ankle surgery
Includes bibliographical references and index.
ISBN 978-0-7817-6580-0
I. McGlamry, E. Dalton. II. Southerland, Joe T. III. Title: Comprehensive textbook of foot and ankle surgery.
[DNLM: 1. Foot—surgery. 2. Ankle—surgery. 3. Foot Deformities—surgery. 4. Foot Injuries—surgery. WE 880]
617.5'85059—dc23

2012006861

DISCLAIMER
Care has been taken to confirm the accuracy of the information present and to describe generally accepted practices. However, the authors, editors, and publisher are not responsible for errors or omissions or for any consequences from application of the information in this book and make no warranty, expressed or implied, with respect to the currency, completeness, or accuracy of the contents of the publication. Application of this information in a particular situation remains the professional responsibility of the practitioner; the clinical treatments described and recommended may not be considered absolute and universal recommendations.

The authors, editors, and publisher have exerted every effort to ensure that drug selection and dosage set forth in this text are in accordance with the current recommendations and practice at the time of publication. However, in view of ongoing research, changes in government regulations, and the constant flow of information relating to drug therapy and drug reactions, the reader is urged to check the package insert for each drug for any change in indications and dosage and for added warnings and precautions. This is particularly important when the recommended agent is a new or infrequently employed drug.

Some drugs and medical devices presented in this publication have Food and Drug Administration (FDA) clearance for limited use in restricted research settings. It is the responsibility of the health care provider to ascertain the FDA status of each drug or device planned for use in their clinical practice. The publishers have made every effort to trace the copyright holders for borrowed material.

To purchase additional copies of this book, call our customer service department at (800) 638-3030 or fax orders to (301) 223-2320. International customers should call (301) 223-2300.

Visit Lippincott Williams & Wilkins on the Internet: http://www.lww.com. Lippincott Williams & Wilkins customer service representatives are available from 8:30 am to 6:00 pm, EST.

9 8 7 6 5 4 3 2 1

CCS0912

Contents

Contributing Authors x
Foreword xvii
Preface xviii
Introduction xix

VOLUME ONE

PART I: BASICS

SECTION I: Technical Principles

1 Instrumentation 3
D. SCOT MALAY AND ROBYN WINNER

2 Biomaterials: Metals and Other Nonabsorbables 15
SEAN T. GRAMBART AND JEFFREY C. CHRISTENSEN

3 Absorbable Biomaterials 24
ADAM S. LANDSMAN

4 Suture Materials and Needles 37
DANNY R. FIJALKOWSKI

SECTION II: Perioperative Management

5 Perioperative Evaluation 54
LOPA DALMIA AND ANDREA D. CASS

6 Local Anesthetics 63
MITZI L. WILLIAMS AND DONALD R. GREEN

7 General and Regional Anesthesia . . . 73
CONSTANTINE S. KOKENES, JAY D. RYAN, ALLISON J.A. MENKE, AND DONALD R. POWELL

8 Perioperative Pain Management 83
ANDREW J. MEYR AND JOHN S. STEINBERG

9 Perioperative Prophylaxis for Deep Vein Thrombosis 97
JAMES H. MORGAN, JR

10 Perioperative Antibiotics 101
AMANDA MESZAROS

PART II: FOREFOOT SURGERY

SECTION I: Nail Surgery

11 Nail Surgery 109
TIMOTHY W. CRISLIP AND JEFFREY S. BOBERG

SECTION II: Morton Neuroma

12 Interdigital Neuroma (Morton Neuroma) 117
JEFFREY S. BOBERG AND CAMERON L. EILTS

SECTION III: Digital Deformity

13 Lesser Digital Deformities: Etiology, Procedural Selection, and Arthroplasty 124
JEFFREY S. BOBERG AND JASON J. WILLIS

14 Digital Surgery: Metatarsophalangeal Joint Release and Proximal Interphalangeal Joint Arthrodesis . . 129
ANDREA D. CASS AND JOHN A. RUCH

15 Flail Toe with Bone Graft 140
KIERAN T. MAHAN

16 Flexor Digitorum Longus Tendon Transfer 145
ANNETTE D. FILIATRAULT, JOHN A. RUCH, AND STEVEN A. WEISKOPF

17 Congenital Overlapping Fifth Toe Deformity 154
MICHAEL S. DOWNEY AND JON M. WILSON, JR

18 Surgical Repair of Fifth Digit Deformities 165
THOMAS F. SMITH, CARL A. KIHM, AND KEITH D. PFEIFER

SECTION IV: Lesser Metatarsophalangeal Joint Deformities

19 Plantar Plate Repair of the Second Metatarsophalangeal Joint 187
CRAIG A. CAMASTA

20 Transverse Plane Digital Deformities 202
MICHAEL S. DOWNEY, MICHAEL C. McGLAMRY, AND SARAH A. SPIZZIRRI

21 The Weil Lesser Metatarsal Osteotomy 224
RICHARD J. ZIRM

22 Central Rays: V Osteotomy, DFWO, Condylectomy 229
WILLIAM D. FISHCO AND JEFFREY S. BOBERG

23 Tailor's Bunion Deformity 235
SEAN PATRICK DUNN AND JANE PONTIOUS

PART III: FIRST RAY, HALLUX ABDUCTO VALGUS, AND RELATED DEFORMITIES

24 Evaluation and Procedural Selection in Hallux Valgus Surgery 245
JEFFREY S. BOBERG

25 Anatomic Dissection of the First Metatarsophalangeal Joint for Hallux Valgus Surgery 250
JOHN A. RUCH, CHARLES F. PEEBLES, AND CLAIRE A. HOLLSTROM

26 Hallux Osteotomies 260
THOMAS F. SMITH AND JARED L. MOON

27 Distal Metaphyseal Osteotomies in Hallux Abducto Valgus Surgery . . . 279
THOMAS A. BROSKY II AND PATRICK B. HALL

28 Proximal Osteotomies of the First Metatarsal 290
ROBB A. MOTHERSHED

29 Offset-V Osteotomy of the First Metatarsal Shaft in Hallux Abducto Valgus 302
GARY R. BAUER AND HAROLD W. VOGLER

30 Z-Scarf Osteotomy 314
CHARLES J. GUDAS

31 Lapidus Bunionectomy: First Metatarsal–Cuneiform Arthrodesis 322
LAWRENCE A. DiDOMENICO AND MARI WARGO-DORSEY

32 Juvenile Hallux Abducto Valgus Deformity 331
DONALD R. GREEN, KIERAN T. MAHAN, AND TRACY L. KLIMAZ

33 Joint Salvage and Preservation Surgical Techniques for Hallux Limitus. 343
ANNALISA Y. CO, THOMAS J. CHANG, AND CRAIG A. CAMASTA

34 First Metatarsophalangeal Joint Arthroplasty 362
JOHN V. VANORE, WILLIAM G. MONTROSS, A. LOUIS JIMENEZ, AND JONNICA S. DOZIER

35 First Metatarsophalangeal Joint Arthrodesis 400
THOMAS F. SMITH AND ALLISON J.A. MENKE

36 Complications in Hallux Abducto Valgus Surgery (Excluding Hallux Varus) 417
MOLLY A. JUDGE

37 Hallux Varus 461
MOLLY A. JUDGE

PART IV: REARFOOT

SECTION I: Midfoot and Heel Surgery

38 Common Pedal Prominences 471
THOMAS F. SMITH AND LESLIE B. DOWLING

39 Plantar Heel. 494
JEFFREY S. BOBERG, DAMIEN M. DAUPHINÉE, D. SCOT MALAY, AND WILLIAM HARRIS IV

40 The Distal Tarsal Tunnel: First Branch of the Lateral Plantar Nerve Release. 505
ROBERT M. GOECKER

41 Plantar Foot Surgery 513
J. MICHAEL MILLER AND SUHAIL B. MASADEH

42 Pes Cavus Surgery 525
CRAIG A. CAMASTA AND ANDREA D. CASS

SECTION II: Valgus Foot Deformity

43 Ankle Equinus 541
MICHAEL S. DOWNEY AND JACLYN M. SCHWARTZ

44 Flexible Valgus Deformity 585
KIERAN T. MAHAN AND K. PAUL FLANIGAN

45 Tarsal Coalition 598
MICHAEL S. DOWNEY AND ALISON M. DEWATERS

46 Posterior Tibial Tendon Dysfunction 636
ALAN R. CATANZARITI, ROBERT W. MENDICINO, AND MICHAEL P. MASKILL

47 Medial Column Fusion. 670
THOMAS J. CHANG

48 Arthroereisis 675
DONALD R. GREEN AND MITZI L. WILLIAMS

PART V: ANKLE

49 Os Trigonum Surgery 691
MOLLY A. JUDGE

50 Acute Ankle Conditions 702
MARK A. HARDY AND GINA A. HILD

51 Old Syndesmotic Injuries 710
BRIAN B. CARPENTER AND TRAVIS A. MOTLEY

52 Ankle Replacement Arthroplasty . . 717
JOHN M. SCHUBERTH, JEROME K. STECK, AND JEFFREY C. CHRISTENSEN

53 Arthroscopy of the Ankle and Foot 757
JEFFREY C. CHRISTENSEN, MEAGAN M. JENNINGS, AND JOHN J. STIENSTRA

54 Osteochondroses of the Foot and Ankle 780
LAWRENCE M. FALLAT, JEFFREY C. CHRISTENSEN, AND JACOB A. HORD

PART VI: MIDFOOT JOINT ARTHRODESIS

55 Principles of Arthrodesis 803
SEAN PATRICK DUNN, JUSTIN T. MEYER, AND JOHN A. RUCH

56 Tarsometatarsal Arthrodesis 810
SHINE JOHN, ALAN R. CATANZARITI, AND ROBERT W. MENDICINO

57 Trephine Arthrodesis at the Midfoot 820
ANNETTE D. FILIATRAULT

58 Triple Arthrodesis 824
JOHN A. RUCH, LOPA DALMIA, AND PATRICK B. HALL

59 Subtalar Joint Arthrodesis 843
MARK A. HARDY

60 Talonavicular Fusions. 851
WILLIAM D. FISHCO

61 Pantalar Arthrodesis 855
TRAVIS A. MOTLEY AND BRIAN B. CARPENTER

VOLUME TWO

PART VII: SPECIAL SURGERY: CONDITIONS

SECTION I: Rheumatoid Foot and Ankle

62 Rheumatoid Rearfoot. 863
LINNIE V. RABJOHN AND DANIEL J. YARMEL

63 Pan Metatarsal Head Resection . . . 876
DENNIS E. MARTIN

SECTION II: Neurologic Disorders

64 Spasticity and Paralytic Disorders 884
R. DAVID WARREN

65 Charcot-Marie-Tooth Disease. 892
ROBERT M. GOECKER, ALAN S. BANKS, MICHAEL S. DOWNEY, AND RICHARD J. ZIRM

SECTION III: Peripheral Nerve Surgery

66 General Entrapment Syndromes . . . 912
D. SCOT MALAY, E. DALTON McGLAMRY, AND MARIJA UGRINICH

67 Tarsal Tunnel Syndrome 934
MICHAEL S. DOWNEY AND DANIEL J. YARMEL

68 Complex Regional Pain Syndromes and Related Disorders 950
JEFFREY C. CHRISTENSEN

SECTION IV: Diabetic Foot

69 Evaluation and Management of the Diabetic Foot Wound 986
JOHN S. STEINBERG AND PAUL J. KIM

70 Charcot Foot and Ankle Deformity 1008
THOMAS M. ZGONIS, JOHN J. STAPLETON, AND THOMAS S. ROUKIS

71 Amputations 1022
ROBERT P. TAYLOR, JAMES L. BOUCHARD, AND LINNIE V. RABJOHN

SECTION V: Congenital Deformities

72 Brachymetatarsia 1036
MICHELLE L. BUTTERWORTH AND DENNIS E. MARTIN

73 Metatarsus Adductus and Allied Disorders 1056
PATRICK S. AGNEW

74 Clubfoot 1079
LUKE D. CICCHINELLI, DAVID J. GRANGER, TODD R. GUNZY, TODD B. HADDON, AND JORGE G. PENAGOS VASQUEZ

75 Congenital Digital Deformities. . . 1097
75.1 Polydactyly 1097
ANNETTE D. FILIATRAULT
75.2 Macrodactyly 1106
THOMAS A. BROSKY II
75.3 Ectrodactyly 1109
CORNELIUS M. DONOHUE
75.4 Syndactyly 1117
CARL R. WAGREICH, RENATO J. GIORGINI, TARA L. GIORGINI

PART VIII: SPECIAL SURGERY: SOFT TISSUE

76 Principles of Muscle–Tendon Surgery and Tendon Transfers . . . 1127
STEPHEN J. MILLER AND MACK JAY GROVES IV

77 Peroneal Tendon Disorders 1165
LAWRENCE A. DIDOMENICO AND MICHELLE C. ANANIA

78 Achilles Tendon Disorders 1181
JAMES L. THOMAS

79 Plastic and Reconstructive Surgery 1193
TOD R. STORM AND MICHAEL S. LEE

80 Bone Anchors 1222
THOMAS A. BROSKY II, MICHAEL C. McGLAMRY, AND MITZI L. WILLIAMS

81 Interpositional Arthroplasty of the First Metatarsophalangeal Joint 1231
CHRISTOPHER F. HYER AND JAYMES D. GRANATA

82 Lateral Column Arthroplasty 1234
THOMAS J. CHANG

PART IX: SPECIAL SURGERY: MISCELLANEOUS TOPICS

83 External Fixation of Rearfoot and Ankle Arthrodeses. 1241
BRADLEY M. LAMM

84 Puncture Wounds. 1254
STEPHEN V. COREY AND MICHELLE L. BUTTERWORTH

85 Lower Extremity Infections 1267
MARK A. KOSINSKI AND WARREN S. JOSEPH

86 Osteomyelitis 1287
LAWRENCE M. OLOFF AND GEOFFREY S. HEARD

87 Nonunions. 1309
STEPHAN J. LAPOINTE

88 Orthobiologics. 1322
D. SCOT MALAY AND WILLIAM HARRIS IV

89 Electrical and Mechanical Bone Growth Stimulation 1333
MICHAEL S. DOWNEY AND WEN-YIN CHOI WANG

90 Nonosseous Injuries. 1350
KEITH D. COOK

PART X: TUMORS

91 Skin Lesions. 1363
D. SCOT MALAY AND MARIJA UGRINICH

92 Soft Tissue Masses 1387
MICHAEL S. DOWNEY AND CHRISTA M. GREDLEIN

93 Bone Tumors of the Foot and Ankle 1413
LAWRENCE S. OSHER, BRYAN D. CALDWELL, AND HILAREE B. MILLIRON

94 Surgical Management of Bone Tumors in the Foot and Ankle . . 1474
HILAREE B. MILLIRON, JOSEPH A. FAVAZZO, AND B. HUDSON BERREY

95 Plantar Fibromatosis 1486
MICHAEL S. DOWNEY AND RANDALL J. CONTENTO

PART XI: TRAUMA

SECTION I: Acute Trauma

96 Open Fractures 1499
MARK A. HARDY AND JORDAN P. GROSSMAN

97 Complex Soft Tissue Injuries: Degloving and Soft Tissue Loss Injuries 1508
RYAN H. FITZGERALD AND JOHN S. STEINBERG

98 Complications of Internal Fixation 1523
JOHN V. VANORE AND WILLIAM G. MONTROSS

99 Trauma to the Nail and Associated Structures 1535
D. SCOT MALAY AND ROBYN WINNER

100 Management of Acute and Chronic Tendon Injury 1549
RYAN H. FITZGERALD

101 Achilles Tendon Trauma 1580
ALAN NG AND KEITH L. JACOBSON

102 Dislocations of the Foot and Ankle 1600
GRAHAM A. HAMILTON, LAWRENCE A. FORD, AND JOHANNA-MARIE RICHEY

103 Digital and Sesamoid Fractures 1629
MICHAEL S. DOWNEY AND GRETCHEN A. LAWRENCE

104 Metatarsal Fractures. 1646
MICHAEL S. LEE AND LINDA HO

105 Midfoot Fractures 1662
TRAVIS A. MOTLEY AND BRIAN B. CARPENTER

106 Tarsometatarsal (Lisfranc) Joint Dislocation 1677
LAWRENCE A. DiDOMENICO AND DAWN Y. STEIN

107 Calcaneal Fractures 1685
MEAGAN M. JENNINGS AND JOHN M. SCHUBERTH

108 Talar Fractures. 1707
JOHN M. SCHUBERTH, SHANNON M. RUSH, AND MEAGAN M. JENNINGS

109 Ankle Fractures 1739
LAWRENCE M. FALLAT, THOMAS J. MERRILL, ZEESHAN S. HUSAIN, AND KITTRA T. OWENS

110 Pilon Fractures 1765
GEORGE S. GUMANN AND JUSTIN J. FLEMING

111 Pediatric Foot and Ankle Fractures 1786
EDWIN J. HARRIS

SECTION II: Repair of Posttraumatic Injuries

112 Neglected Calcaneal Fractures . . 1835
GEORGE T. LIU

113 Ankle Malunions 1849
BRADLEY M. LAMM AND JOHN E. HERZENBERG

114 Supramalleolar Osteotomy. 1874
SHANNON M. RUSH, AND JOHN M. SCHUBERTH

115 Talar Avascular Necrosis 1890
CHRISTOPHER F. HYER AND WILLIAM T. DeCARBO

116 Lisfranc Injuries. 1914
GEORGE F. WALLACE

117 Fibular Lengthening 1924
BYRON L. HUTCHINSON

Index I-1

Contributing Authors

Patrick S. Agnew, DPM, FACFAS, FACFAP
Founder, Coastal Podiatry Group
Virginia Beach, Virginia
Past President, American College of Foot and Ankle Pediatrics
Director, Podiatric Education
Eastern Virginia Medical School
Norfolk, Virginia

Michelle C. Anania, DPM, FACFAS
Private Practice
Ankle and Foot Care Centers
Youngstown, Ohio

Alan S. Banks, DPM, FACFAS
Faculty
The Podiatry Institute
Decatur, Georgia
Private Practice
Village Podiatry Centers
Tucker, Georgia

Gary R. Bauer, DPM
Associate Professor Emeritus
Department of Surgery
Temple University School of Podiatric Medicine
Philadelphia, Pennsylvania

B. Hudson Berrey, MD, FACS
Professor, Department of Orthopedic Surgery
Chief, Sarcoma and Musculoskeletal Oncology
University of Florida Health Science Center
Jacksonville, Florida

Jeffrey S. Boberg, DPM, FACFAS
Faculty
The Podiatry Institute
Decatur, Georgia
Private Practice
St. Louis, Missouri

James L. Bouchard, DPM, FACFAS
Faculty
The Podiatry Institute
Decatur, Georgia
Private Practice
Lawrenceville, Georgia

Thomas A. Brosky II, DPM, FACFAS
Faculty
The Podiatry Institute
Attending Surgeon
DeKalb Medical Center
Decatur, Georgia
Private Practice
Oakwood, Georgia

Michelle L. Butterworth, DPM, FACFAS
Affiliate Member
The Podiatry Institute
Decatur, Georgia
Private Practice
Pee Dee Foot Clinic
Kingstree, South Carolina

Bryan D. Caldwell, DPM, MS
Professor and Dean
Clinical Education and Operations
Kent State University College of Podiatric Medicine
Independence, Ohio

Craig A. Camasta, DPM, FACFAS, FACPS
Faculty
The Podiatry Institute
Decatur, Georgia
St. Joseph's Hospital
Atlanta, Georgia

Brian B. Carpenter, DPM, FACFAS
Associate Professor
Department of Orthopedics
University of North Texas Health Science Center
Fort Worth, Texas

Andrea D. Cass, DPM, AACFAS
Faculty
The Podiatry Institute
Decatur, Georgia
Private Practice
Smyrna, Georgia

Alan R. Catanzariti, DPM, FACFAS
Affiliate Member
The Podiatry Institute
Decatur, Georgia
The Western Pennsylvania Hospital
Philadelphia, Pennsylvania

Thomas J. Chang, DPM, FACFAS
Faculty
The Podiatry Institute
Decatur, Georgia
Clinical Professor and Past Chairman
Department of Podiatric Surgery
Samuel Merritt School of Podiatric Medicine
Redwood Orthopedic Surgery Associates
Santa Rosa, California

Wen-Yin Choi Wang, DPM, AACFAS
East Bay Physicians Medical Group
Department of Podiatry
Advanced Wound Care Center
Sutter Delta Medical Center
Antioch, California

Jeffrey C. Christensen, DPM, FACFAS
President and Founder
Ankle and Foot Clinics Northwest
Past Section Chairman and Attending Surgeon
Department of Orthopedics, Podiatric Section
Swedish Medical Center
Seattle, Washington

Luke D. Cicchinelli, DPM, FACFAS
Faculty
The Podiatry Institute
Decatur, Georgia
Private Practice
East Valley Foot and Ankle Specialists
Mesa, Arizona

Annalisa Y. Co, DPM
Faculty
The Podiatry Institute
Decatur, Georgia
Private Practice
Sacramento, California

Randall J. Contento, DPM, AACFAS
Private Practice
Central Ohio Podiatry Group
Westerville, Ohio

Keith D. Cook, DPM, FACFAS
Director, Podiatric Medical Education
University Hospital
University of Medicine and Dentistry of New Jersey
Newark, New Jersey

Stephen V. Corey, DPM, FACFAS
Faculty
The Podiatry Institute
Decatur, Georgia
Private Practice
Pee Dee Foot Clinic
Kingstree, South Carolina

Timothy W. Crislip, DPM
Private Practice
Columbia Orthopaedic Group
Columbia, Missouri

Lopa Dalmia, DPM
Faculty
The Podiatry Institute
Decatur, Georgia
Associate Physician, Podiatric Surgery
University of California Davis Health System
Citrus Heights, California

Damien M. Dauphinée, DPM, FACFAS, FAENS, FACCWS, CWS-P
Medical Director
Center for Wound Healing and Hyperbaric Medicine
North Texas Hospital
Denton, Texas

William T. DeCarbo, DPM, AACFAS
Fellowship Trained Foot and Ankle Surgeon
Faculty
Mountain Valley Foot and Ankle Reconstruction Fellowship
The Orthopedic Group
Pittsburgh, Pennsylvania

Alison M. DeWaters, DPM
Private Practice
Affiliated Foot and Ankle Center
Howell, New Jersey

Lawrence A. DiDomenico, DPM, FACFAS
Adjunct Professor
Ohio College of Podiatric Medicine
Visiting Professor
Northeast Ohio Medical University
Section Chief, Podiatric Medicine and Surgery
St. Elizabeth's Hospital
Director, Reconstructive Rearfoot and Ankle Surgical Fellowship
Ankle and Foot Care Centers
Youngstown, Ohio

Cornelius M. Donohue, DPM
Medical Director, Comprehensive Wound Healing Center
Roxborough Memorial Hospital
Philadelphia, Pennsylvania

Leslie B. Dowling, DPM
Faculty
The Podiatry Institute
Decatur, Georgia
Private Practice
Waycross, Georgia

Michael S. Downey, DPM, FACFAS
Faculty
The Podiatry Institute
Decatur, Georgia
Clinical Professor and Former Chairman, Department of Surgery
Temple University School of Podiatric Medicine
Chief, Division of Podiatric Surgery
Penn Presbyterian Medical Center
Private Practice
Ankle and Foot Medical Centers of the Delaware Valley
Philadelphia, Pennsylvania

Jonnica S. Dozier, DPM
Staff Podiatrist
Carl Vinson Veterans Administration Medical Center
Dublin, Georgia

Sean Patrick Dunn, DPM
Faculty
The Podiatry Institute
Attending Surgeon
DeKalb Medical Center
Decatur, Georgia
Staff Physician
Northwest Georgia Medical Center
Gainesville, Georgia
Private Practice
Oakwood, Georgia

Cameron L. Eilts, DPM
Faculty
The Podiatry Institute
Decatur, Georgia
Private Practice
Sports Medicine Atlantic Orthopedics
Portsmouth, New Hampshire

Lawrence M. Fallat, DPM, FACFAS
Clinical Assistant Professor
Department of Family Practice
Wayne State School of Medicine
Director, Podiatric Surgical Residency
Section Leader, Podiatry
Department of Surgery
Oakwood Hospital
Taylor, Michigan

Joseph A. Favazzo, DPM
Assistant Professor
Department of Surgery
Ohio College of Podiatric Medicine
Private Practice
Twinsburg, Ohio

Danny R. Fijalkowski, DPM
Center for Podiatric Medicine and Surgery
Belmont Community Hospital, a Division of Wheeling Hospital
Bellaire, Ohio

Annette D. Filiatrault, DPM, MS, FACFAS
Faculty
The Podiatry Institute
Decatur, Georgia
Private Practice
Atlanta, Georgia

William D. Fishco, DPM, MS, FACFAS
Faculty
The Podiatry Institute
Decatur, Georgia
Teaching Faculty
Maricopa Medical Center
Private Practice
Anthem, Arizona

Ryan H. Fitzgerald, DPM, AACFAS
Private Practice
Hess Orthopaedics and Sports Medicine
Harrisonburg, Pennsylvania

K. Paul Flanigan, DPM, FACFAS
Private Practice
Portland Foot and Ankle
Portland, Maine

Justin J. Fleming, DPM, FACFAS
Faculty
The Podiatry Institute
Decatur, Georgia
Chief, Foot and Ankle Service
Muscle, Bone and Joint Center
Director, Foot and Ankle Training
Aria Health System
Northwest Orthopedic Specialists
Philadelphia, Pennsylvania

Lawrence A. Ford, DPM, FACFAS
Assistant Sub-Chief, Department of Orthopedics and Podiatric Surgery
Kaiser Permanente
Program Director
Kaiser San Francisco Bay Area Foot and Ankle Residency
Oakland, California

Renato J. Giorgini, DPM, FACFAS, FASPS, DABPS, DABPO
Section Chief, Podiatric Surgery
Director, Podiatric Medical Education
Good Samaritan Medical Center
Professor, Division Surgical Sciences
New York College of Podiatric Medicine
Lindenhurst, New York

Tara L. Giorgini, DPM, MD
Faculty
The Podiatry Institute
Decatur, Georgia
Casa di Cura Quisisana
Rome, Italy

Robert M. Goecker, DPM, FACFAS
Faculty
The Podiatry Institute
Decatur, Georgia
Chief, Podiatric Foot and Ankle Surgery
Sarasota Memorial Hospital
Private Practice
Sarasota, Florida

Sean T. Grambart, DPM, FACFAS
Carle Physician Group
Carle Foundation Hospital
Clinical Instructor University of Illinois
School of Medicine
Champaign, Illinois

Jaymes D. Granata, MD
Private Practice
Lewis Center, Ohio

David J. Granger, DPM, FACFAS
Orthopaedic and Spine Specialists
York, Pennsylvania

Christa M. Gredlein, DPM, FACFAS
Private Practice
Baltimore, Maryland

Donald R. Green, DPM, FACFAS
Faculty
The Podiatry Institute
Decatur, Georgia
Residency Director
Scripps Mercy Kaiser Podiatric
Residency Program
San Diego, California
Clinical Professor
California School of Podiatric Medicine
Oakland, California

Jordan P. Grossman, DPM, FACFAS
Affiliate Member
The Podiatry Institute
Decatur, Georgia
Private Practice
Akron, Ohio

Mack Jay Groves IV, DPM, FACFAS
Faculty
The Podiatry Institute
Decatur, Georgia
St. Tammany Parish Hospital
Covington, Louisiana

Charles J. Gudas, DPM, FACFAS
Private Practice
Charleston, South Carolina

George S. Gumann, DPM, FACFAS
Faculty
The Podiatry Institute
Decatur, Georgia
Orthopedic Clinic
Martin Army Hospital
Fort Benning, Georgia

Todd R. Gunzy, DPM, FACFAS
Affiliate Member
The Podiatry Institute
Decatur, Georgia
Director, Pediatric Foot and Ankle Medical
Mission Program
Private Practice
Mesa, Arizona

Todd B. Haddon, DPM, FACFAS
Faculty
The Podiatry Institute
Decatur, Georgia
Private Practice
Mesa, Arizona

Patrick B. Hall, DPM
Faculty
The Podiatry Institute
Decatur, Georgia
Bone and Joint Clinic of Baton Rouge
Baton Rouge, Louisiana

Graham A. Hamilton, DPM, FACFAS
Attending Surgeon
Department of Orthopedics and
Podiatric Surgery
Kaiser San Francisco Bay Area Foot and
Ankle Residency Program
Antioch, California

Mark A. Hardy, DPM, FACFAS
Staff
Ohio Permanente Medical Group, Inc.
Director, Cleveland Clinic Kaiser
Permanente Foot and Ankle Residency
Cleveland, Ohio

Edwin J. Harris, DPM, FACFAS
Clinical Professor, Orthopaedics and
Rehabilitation
Loyola University Chicago, Stritch School
of Medicine
Chicago, Illinois

William Harris IV, DPM, AACFAS
Private Practice
Lancaster, South Carolina

Geoffrey S. Heard, DPM
Chairman, Podiatry Department
Sequoia Hospital
Redwood City, California
Private Practice
Belmont, California

John E. Herzenberg, MD, FRCSC
Director, Pediatric Orthopedics
Director, International Center for
Limb Lengthening
Director, Limb Reconstruction Fellowship
Program
Rubin Institute for Advanced Orthopedics
Sinai Hospital of Baltimore
Clinical Professor, Department of
Orthopaedics
University of Maryland School of Medicine
Baltimore, Maryland

Gina A. Hild, DPM
PGY III
Kaiser Permanente, Cleveland Clinic
Foundation
Cleveland, Ohio

Linda Ho, DPM
Private Practice
Loma Linda, California

Claire A. Hollstrom, DPM
Diplomate, American Board of
Podiatric Surgery
Private Practice
Ankle and Foot Center of Georgia
LaGrange, Georgia

Jacob A. Hord, DPM, AACFAS
Faculty
Jewish Hospital Podiatry Residency
Program
Louisville, Kentucky
Private Practice
Shelbyville, Kentucky

Zeeshan S. Husain, DPM, FACFAS
Assistant Residency Director
Podiatric Medicine and Surgery
Residency
Detroit Medical Center
Detroit, Michigan

Byron L. Hutchinson, DPM, FACFAS
Program Director, Foot and
Ankle Institute
St. Francis Hospital
Federal Way, Washington
Private Practice
Burien, Washington

Christopher F. Hyer, DPM, MS, FACFAS
Fellowship Co-Director
Advanced Foot and Ankle Surgical Fellowship
Orthopedic Foot and Ankle Center
Westerville, Ohio

Keith L. Jacobson, DPM, FACFAS
Committee Member
Highlands-Presbyterian St. Luke's Residency Program
Advanced Orthopedic and Sports Medicine Specialists
Denver, Colorado

Meagan M. Jennings, DPM, FACFAS
Department of Orthopedics and Podiatry
Palo Alto Medical Foundation
Chief of Podiatry
El Camino Hospital
Mountain View, California

A. Louis Jimenez, DPM, FACFAS
Faculty
The Podiatry Institute
Decatur, Georgia
Program Director, Atlanta VAMC Podiatric Residency Program
Past President, American College Foot and Ankle Surgeons
Private Practice
Gwinnett Foot, Ankle Leg Centers
Snellville, Georgia

Shine John, DPM, AACFAS
Foot Specialists
Cedar Park, Texas

Warren S. Joseph, DPM, FIDSA
Consultant
Lower Extremity Infectious Diseases
Roxborough Memorial Hospital
Philadelphia, Pennsylvania

Molly A. Judge, DPM, FACFAS
Director, Publications and Research
Podiatric Residency Program
Cleveland Clinic Foundation–Kaiser Permanente Foundation
Cleveland, Ohio
Adjunct Faculty
Ohio University and Colleges of Podiatric Medicine
Faculty
Graduate Medical Education
Mercy Health Partners
Private Practice
Toledo, Ohio

Carl A. Kihm, DPM
Faculty
The Podiatry Institute
Decatur, Georgia
Private Practice
Douglasville, Georgia

Paul J. Kim, DPM, FACFAS
Associate Professor, Department of Plastic Surgery
Division of Wound Healing and Hyperbaric Medicine
Georgetown University Hospital
Washington, District of Columbia

Tracy L. Klimaz, DPM, AACFAS
Private Practice
Virginia Beach, Virginia

Constantine S. Kokenes, MD
Department of Anesthesiology
DeKalb Medical Center
Decatur, Georgia

Mark A. Kosinski, DPM, FIDSA
Professor, Department of Medical Sciences
New York College of Podiatric Medicine
New York, New York
Instructor, Department of Surgery
New York Medical College
Valhallah, New York

Bradley M. Lamm, DPM, FACFAS
Head of Foot and Ankle Surgery
International Center for Limb Lengthening
Director, Foot and Ankle Deformity Correction Fellowship
Rubin Institute for Advanced Orthopedics
Sinai Hospital
Baltimore, Maryland

Adam S. Landsman, DPM, PhD, FACFAS
Assistant Professor of Surgery
Harvard Medical School
Chief, Division of Podiatric Surgery
Cambridge Health Alliance
Cambridge, Massachusetts

Stephan J. LaPointe, DPM, PhD, FACFAS
Faculty
The Podiatry Institute
Decatur, Georgia
Private Practice
Rome, Georgia

Gretchen A. Lawrence, DPM, AACFAS
Private Practice
Waynesville, North Carolina

Michael S. Lee, DPM, FACFAS
Adjunct Clinical Professor
Des Moines University
Past President
American College of Foot and Ankle Surgeons
Private Practice
Capital Orthopaedics and Sports Medicine, PC
Clive, Iowa

George T. Liu, DPM, FACFAS
Assistant Professor
Department of Orthopaedic Surgery
University of Texas Southwestern Medical Center
Parkland Memorial Hospital Level I Trauma Center
Dallas, Texas

Kieran T. Mahan, DPM, FACFAS
Faculty
The Podiatry Institute
Decatur, Georgia
Associate Dean for Academic Affairs
Chair and Professor, Department of Podiatric Surgery
Temple University School of Podiatric Medicine
Philadelphia, Pennsylvania

D. Scot Malay, DPM, MSCE, FACFAS
Faculty
The Podiatry Institute
Decatur, Georgia
Director of Podiatric Research and Staff Surgeon
Penn Presbyterian Medical Center
Private Practice
Ankle and Foot Medical Centers of the Delaware Valley
Philadelphia, Pennsylvania

Dennis E. Martin, DPM, FACFAS
Faculty
The Podiatry Institute
Decatur, Georgia
Private Practice
North Charleston, South Carolina

Suhail B. Masadeh, DPM, FACFAS
Faculty
American Health Network Fellowship
Advanced Reconstructive Foot and Ankle Surgery
Private Practice
Muncie, Indiana

Michael P. Maskill, DPM
Orthopaedic Associates of Kalamazoo
Department of Foot and Ankle Surgery
Kalamazoo, Michigan

E. Dalton McGlamry, DPM, DSc (Hon), DHL
Founding Member
The Podiatry Institute
Decatur, Georgia

Michael C. McGlamry, DPM, FACFAS
Faculty
The Podiatry Institute
Decatur, Georgia
Private Practice
Cumming, Georgia

Robert W. Mendicino, DPM, FACFAS
Foot and Ankle Surgery
Pinnacle Orthopedic Associates
Salisbury, North Carolina

Allison J.A. Menke, DPM, AACFAS
Faculty
The Podiatry Institute
Decatur, Georgia
Attending Surgeon
DeKalb Medical Center
Decatur, Georgia

Thomas J. Merrill, DPM, FACFAS
Faculty
The Podiatry Institute
Decatur, Georgia
Professor of Surgery
Barry University School of Podiatric Medicine
Miami Shores, Florida
Residency Director
Mercy Hospital
Miami, Florida

Amanda Meszaros, DPM, FACFAS
Co-Chair, Department of Surgery
Mercy Allen Hospital
Private Practice
Oberlin, Ohio

Justin T. Meyer, DPM
Faculty
The Podiatry Institute
Decatur, Georgia
Private Practice
Santa Barbara, California

Andrew J. Meyr, DPM, AACFAS
Assistant Professor, Department of Podiatric Surgery
Temple University School of Podiatric Medicine
Philadelphia, Pennsylvania

J. Michael Miller, DPM, FACFAS
Director of Fellowship Training
Foot and Ankle Reconstructive Surgical Service
American Health Network
Indianapolis, Indiana

Stephen J. Miller, DPM
Faculty
The Podiatry Institute
Decatur, Georgia
Anacortes, Washington

Hilaree B. Milliron, DPM
Private Practice
Jacksonville Beach, Florida

William G. Montross, DPM, FACFAS
Attending Physician
Denver Veterans Administration Hospital Podiatric Residency
Denver, Colorado
Assistant Clinical Professor
Rocky Vista Osteopathic College
Parker, Colorado

Jared L. Moon, DPM
Faculty
The Podiatry Institute
Decatur, Georgia
Private Practice
Chicago, Illinois

James H. Morgan Jr, DPM, FACFAS, FAAPSM
Faculty
The Podiatry Institute
Decatur, Georgia
Private Practice
Mobile, Alabama

Robb A. Mothershed, DPM, FACFAS
Faculty
The Podiatry Institute
Decatur, Georgia
AO Alumnus
Department of Orthopedics
University of Washington
Seattle, Washington
Private Practice
Winston-Salem, North Carolina

Travis A. Motley, DPM, MS, FACFAS
Associate Professor
Department of Orthopaedic Surgery
Bone and Joint Institute
University of North Texas Health Science Center
Fort Worth, Texas

Aprajita Nakra, DPM, FACFAS
Faculty
The Podiatry Institute
Decatur, Georgia
Private Practice
Phoenix and Gilbert, Arizona

Alan Ng, DPM, FACFAS
Advanced Orthopedic and Sports Medicine Specialists
Residency Committee Highlands/Presbyterian St. Luke's Medical Center
Denver, Colorado

Lawrence M. Oloff, DPM
Diplomate, American Board of Podiatric Surgery
Sports Orthopedic and Rehabilitation (SOAR) Medical Group
Redwood City, California

Lawrence S. Osher, DPM
Professor, Department of Podiatric Medicine
Ohio College of Podiatric Medicine
Independence, Ohio

Kittra T. Owens, DPM
Division Officer, Department of Orthopedics
Naval Hospital
Camp Lejeune, North Carolina

Charles F. Peebles, DPM, FACFAS
Faculty
The Podiatry Institute
Decatur, Georgia
Private Practice
Atlanta, Georgia

Jorge G. Penagos Vasquez, MD
Chief, Department of Orthopaedic Surgery and Foot and Ankle
Pediatric Foundation of Guatemala City
Guatemala City, Guatemala

Keith D. Pfeifer, DPM
Assistant Residency Director
Eisenhower Army Medical Center
Fort Gordon, Georgia

Jane Pontious, DPM, FACFAS
Faculty
The Podiatry Institute
Decatur, Georgia
Chair, Department of Surgery
Assistant Dean of Clinical Education
Temple University School of Podiatric Medicine
Philadelphia, Pennsylvania

Donald R. Powell, DPM
Faculty
The Podiatry Institute
Attending Surgeon
DeKalb Medical Center
Decatur, Georgia

Linnie V. Rabjohn, DPM, FACFAS
Private Practice
Arlington/Mansfield Foot and Ankle Centers
Arlington, Texas

Johanna-Marie Richey, DPM, BBS
Chief Resident
Kaiser San Francisco Bay Area Foot and Ankle
San Francisco, California

Thomas S. Roukis, DPM, PhD, FACFAS
Department of Orthopaedics
Podiatry and Sports Medicine
Gundersen Lutheran Medical Center
La Crosse, Wisconsin

John A. Ruch, DPM, FACFAS
Director of Medical Education
The Podiatry Institute
Attending Surgeon
DeKalb Medical Center
Decatur, Georgia
Private Practice
Village Podiatry Centers
Tucker, Georgia

Shannon M. Rush, DPM, FACFAS
Director, Silicon Valley Foot and Ankle Fellowship
Palo Alto Medical Foundation
Mountain View, California

Jay D. Ryan, DPM, AACFAS
Faculty
The Podiatry Institute
Decatur, Georgia
Staff Physician
Inova Fairfax Hospital
Fairfax, Virginia

John M. Schuberth, DPM
Faculty
The Podiatry Institute
Decatur, Georgia
Chief, Foot and Ankle Surgery
Department of Orthopedic Surgery
Kaiser Foundation Hospital
San Francisco, California

Jaclyn M. Schwartz, DPM
Senior Resident
DeKalb Medical Center
Decatur, Georgia

Thomas F. Smith, DPM, FACFAS
Faculty
The Podiatry Institute
Decatur, Georgia
Chairman, Podiatry Section
University Hospital
Podiatry Staff
Charlie Norwood VAMC
Augusta, Georgia
Consultant
Eisenhower Army Medical Center
Fort Gordon, Georgia

Joe T. Southerland, DPM, FACFAS
Faculty
The Podiatry Institute
Decatur, Georgia
Private Practice
Arlington/Mansfield Foot and Ankle Centers
Arlington, Texas

Sarah A. Spizzirri, DPM, AACFAS
Private Practice
Christie Clinic
Champaign, Illinois

John J. Stapleton, DPM, FACFAS
Foot and Ankle Surgery
VSAS Orthopaedics
Chief of Podiatric Surgery
Leigh Valley Hospital
Allentown, Pennsylvania
Clinical Assistant Professor of Surgery
Penn State College of Medicine
Hershey, Pennsylvania

Jerome K. Steck, DPM, FACFAS
Private Practice
Southern Arizona Orthopedics
Tucson, Arizona

Dawn Y. Stein, DPM, CWS
Department of Podiatry
Grove City Medical Center
Grove City, Pennsylvania

John S. Steinberg, DPM, FACFAS
Associate Professor
Department of Plastic Surgery
Georgetown University School of Medicine
Program Director
MedStar Washington Hospital Center
Podiatric Residency
Co-Director, Center for Wound Healing
MedStar Georgetown University Hospital
Washington, District of Columbia

John J. Stienstra, DPM, FACFAS
Department of Orthopedics
The Permanente Medical Group
Union City, California

Tod R. Storm, DPM, FACFAS
Active Staff
Bozeman Deaconess Hospital
Bozeman, Montana

Robert P. Taylor, DPM, FACFAS
Faculty
The Podiatry Institute
Decatur, Georgia
Adjunct Faculty
Department of Medicine
Baylor Medical Center
Garland, Texas
Private Practice
Frisco, Texas

James L. Thomas, DPM, FACFAS
Chief, Division of Foot and Ankle
Department of Orthopaedic Surgery
University of Florida
Jacksonville, Florida

Marija Ugrinich, DPM, AACFAS
Staff Surgeon
Penn Presbyterian Medical Center
Private Practice
Ankle and Foot Medical Centers of the Delaware Valley
Philadelphia, Pennsylvania

John V. Vanore, DPM, FACFAS
Faculty
The Podiatry Institute
Decatur, Georgia
Private Practice
Gadsden, Alabama

Harold W. Vogler, DPM, FACFAS
Past Chairman, Department of Surgery
Pennsylvania College of Podiatric Medicine
Philadelphia, Pennsylvania
Past Chairman, Section of Foot and Ankle Surgery
Sarasota Memorial Hospital
Partner and Fellowship Director
Sarasota Orthopedic Associates
Sarasota, Florida

Carl R. Wagreich, DPM
Associate Clinical Professor
University of Southern California
Los Angeles, California
Residency Director
HealthSouth Surgery Center of South Bay/Baja Project Surgical Residency Program
Torrance, California
Co-Director, Baja Project for Crippled Children
Mexicali, Mexico

George F. Wallace, DPM, FACFAS
Director, Podiatry Service
Medical Director, Ambulatory Care Services
University Hospital
University of Medicine and Dentistry of New Jersey
Newark, New Jersey

Mari Wargo-Dorsey, DPM, AACFAS
Private Practice
The Ankle and Foot Care Centers
Boardman, Ohio

R. David Warren, DPM, FACFAS
Private Practice
Arlington, Texas

Steven A. Weiskopf, DPM, FACFAS
Faculty
The Podiatry Institute
Decatur, Georgia
Private Practice
Woodstock, Georgia

Mitzi L. Williams, DPM, FACFAS
Young Affiliate Member
The Podiatry Institute
Decatur, Georgia
Attending Surgeon
San Francisco Bay Area Foot and Ankle Residency Program
Department of Orthopedics and Podiatric Surgery
Kaiser Permanente Hospital
Oakland, California

Jason J. Willis, DPM, AACFAS
Attending Podiatrist
Foot Centers of Texas
Methodist Sugar Land Hospital
Sugar Land, Texas

Jon M. Wilson Jr, DPM, AACFAS
Department of Surgery
St. Tammany Parish Hospital
Lakeview Regional Medical Center
Covington, Louisiana

Robyn Winner, DPM
Private Practice
Seattle, Washington

Daniel J. Yarmel, DPM, AACFAS, AAPWCA
Private Practice and Attending Faculty
Pinnacle Health Hospitals
Harrisburg, Pennsylvania

Thomas M. Zgonis, DPM, FACFAS
Associate Professor, Department of Orthopaedics
Division Chief, Externship
Fellowship Program Director
University of Texas Health Science Center
San Antonio, Texas

Richard J. Zirm, DPM
Faculty
The Podiatry Institute
Decatur, Georgia
Department of Surgery
Southwest General Health Center
Private Practice
Cleveland, Ohio

Foreword

The fourth edition of *McGlamry's Comprehensive Textbook of Foot and Ankle Surgery* has been written to meet the current need for a comprehensive work on foot and ankle surgery, not only for podiatric surgeons but also for orthopaedic foot and ankle surgeons, who are making valuable contributions to this field.

Foot and ankle surgery has evolved at a rapid pace over the past 30 years. Not until an understanding of foot and ankle biomechanics and the principles of AO-ASIF were materially refined was this surgery practiced with precision. Prior to that time, functional arthroplasty and fusion dominated the field. Orthopaedic companies assisted in that revolution with the development of unique designs of internal and external fixation that brought the surgical results into a functional cure rather than a palliative "fix."

In concert with this revolution, E. Dalton McGlamry, DPM, founded the Podiatry Institute in Atlanta and soon thereafter edited the text *Fundamentals of Foot Surgery* and the first edition of *The Comprehensive Textbook of Foot Surgery*. Dr. McGlamry was a great inspiration to all podiatric surgeons, and his legacy has been carried on by many of his residents and colleagues.

This two-volume edition of *McGlamry's Comprehensive Textbook of Foot and Ankle Surgery*, edited by Joe T. Southerland, DPM, and assisted by 151 authors, consists of 117 chapters and more than 1,900 pages and is worthy of comparison with *Campbell's Operative Orthopedics*. Virtually every aspect of foot and ankle surgery has been covered, from ingrown nails to total ankle arthroplasty and hybrid external fixation.

To overcome the widespread conception of foot and ankle surgery as a purely mechanical equation, an effort is made in the first section of this text to correlate the technical principles used in this subspecialty. This is followed by a section on perioperative management, which includes the various aspects that one encounters in foot and ankle surgery. The next 50 chapters follow guidelines of anatomical sites where foot and ankle surgery is performed, beginning with nail surgery and concluding with midfoot and hindfoot arthrodesis. The section on first ray, hallux abducto valgus, and related deformities is especially noteworthy, with 14 chapters on the subject covering virtually every aspect of contemporary correction of bunion deformities and their complications. This is true as well for the section on trauma, with 18 comprehensive chapters on the subject.

This book is designed to be a user-friendly and clinically relevant text on common foot and ankle surgery procedures. As the discipline becomes more and more sophisticated, it is obvious that the technical component of operative intervention is critical to clinical success or failure. Therefore, there continues to be an important need to understand the technical aspects of foot and ankle surgery. Many pearls of wisdom are detailed by the authors in order to deal with the multiple potential pitfalls seen in patients with complex foot and ankle deformities.

I have often said that "surgery is both a science and an art, but foot and ankle surgery may be more art than science." This text should prove to be the resource of choice for modern foot and ankle surgery care over the next several years. It will serve those who are novices in the field who wish to concentrate on principles, those experienced surgeons who wish to fine-tune their approach, and everyone in between.

Lowell Scott Weil, Sr, DPM
Weil Foot and Ankle Institute
Des Plaines, Illinois

Preface

It is with great pleasure that we present the fourth edition of *McGlamry's Comprehensive Textbook of Foot and Ankle Surgery*. The goal of this text, as always, is to help students build a good foundation, to help residents develop their skills, and to help surgeons hone their technique.

Like the three previous editions, this book encompasses all facets of foot and ankle surgery. This edition, however, places greater emphasis on an instructional approach so as to better help the surgeon, resident, or student *see* how the procedures are done. It has been completely reorganized to present content in a more logical fashion. Divided into 12 parts across 2 volumes, it begins with basics such as biomaterials and pain management and moves through anatomic locations, physiologic conditions, special surgery, tumors, and trauma. This fourth edition has dozens more chapters and contributors than earlier volumes, making it the most truly comprehensive *Comprehensive Textbook* so far. In addition, for the first time, the textbook has been printed in full color throughout, greatly clarifying the appearance of disorders, diagnostic signs, and surgical landmarks and bringing the operative steps to life.

As the lead editor, I extend my gratitude to the section editors for their work in helping make this a reality. However, most appreciated are the authors, without whom a book of this sort cannot exist. Amid the responsibilities of practice, teaching, and family lives, they were able to find the time needed to write these chapters. Unfortunately, this edition is missing one esteemed author, Gerard V. Yu, who passed away unexpectedly in 2005.

It has been a several-year journey since we started work on this book, and I am very proud to be a part of it. It is my hope that it delivers what we set out to do.

Joe T. Southerland, DPM, FACFAS

Introduction

As the director of Medical Education of the Podiatry Institute, I am proud to provide the Introduction for the fourth edition of *McGlamry's Comprehensive Textbook of Foot and Ankle Surgery.*

This textbook is the ongoing testament to the life passion of E. Dalton McGlamry, DPM. This ambitious project was conceived 30 years ago under the direction of Dr. McGlamry. The supporting staff included graduates of the original Doctor's Hospital Podiatric Residency and many other highly talented and dedicated educators in the podiatric profession.

The first edition, called simply *Comprehensive Textbook of Foot Surgery,* took several years to compile and edit and was published in 1987. It could not have been completed without the tireless support of Dalton's wife, Becky, who served the unenviable roll as authors' editor. The second edition was produced in 1992 under the guidance of editors Dalton McGlamry, Alan Banks, and Michael Downey. The third edition was released in 2001 with Alan Banks, Michael Downey, Dennis Martin, and Steve Miller serving as editors. You now hold the fourth edition. Our many thanks are owed to editors Joe Southerland, Jeffrey Boberg, Michael Downey, Aprajita Nakra, and Linnie Rabjohn for their countless hours of work.

Anyone who has attempted to produce a scientific paper knows the many hours of commitment and effort that are necessary to complete even a single article. That the dedicated faculty of the Podiatry Institute have stuck together for over 40 years and overseen the publication of a major textbook on foot and ankle surgery through four editions is a remarkable feat. One of our dearest members, the late Gerard Vincent Yu, deserves special mention. His many contributions to podiatric education, his drive and energy, his integrity, his love of the profession, and his commitment to colleagues and friends have inspired and always will inspire us.

The contributing authors for this textbook throughout its lifespan so far are too many to mention individually, but without each and every one of them those editions could not have been completed. I would like to recognize and salute each of the individuals who once again have sacrificed their personal time and energy to perpetuate this information.

The completion of this edition of *McGlamry's Comprehensive Textbook of Foot and Ankle Surgery* could not have been possible without the tireless efforts of Mr. Dan Vickers, the executive director of the Podiatry Institute. It has been Dan's commitment and support to the project, to the institute, and to each of us that has kept us on track to reach our goal once again.

John A. Ruch, DPM

PART I

Basics

CHAPTER 1

D. Scot Malay
Robyn Winner

Instrumentation

Surgical instrumentation is highly specialized, and it has been said that there is a tool for every maneuver. In many instances, multiple instruments serve the same function, and each surgeon develops his or her own preferences. All foot and ankle surgeons should familiarize themselves with the basic set of podiatric surgical instruments. A thorough understanding of the design and proper use of the basic tools enable the surgeon to operate with comfort and proficiency.

METALLURGY AND MANUFACTURING

High-quality surgical instruments are typically made of austenitic (300 series) or martensitic (400 series) stainless steel. These iron-based alloys contain carbon, chromium, nickel, and molybdenum as essential elements in their production. The presence of carbon makes the steel extremely hard, whereas chromium primarily allows resistance to corrosion. The formation of a passive layer of chromium oxide on the surface of the alloy imparts corrosion resistance. Corrosion-resistant alloys, when properly manufactured, are capable of replenishing the inert chromium oxide layer after mechanical disruption. Repassivation spontaneously occurs when exposed chromium within the alloy covalently bonds with oxygen from the aqueous environment of the tissue fluids. The presence of the other elements in the molecular configuration of the stainless steel allows the manufacturer to manipulate the alloy's ductility, malleability, toughness, and corrosion resistance further. When extreme hardness is required for a specific component of the surgical instrument, such as the grasping surface of a needle holder, a tungsten-carbide insert is often used (Fig. 1.1).

The most useful implantable alloy, austenitic stainless steel, is designated in manufacturing terms as 300 series alloy or, more specifically, 316LVM. Austenitic stainless steel offers superior corrosion resistance, malleability, and ductility in comparison with the harder martensitic (400 series) steel alloys. Austenitic stainless steel is ideal for the production of metallic implants, such as screws, plates, pins, and other fixation devices, because of the alloy's ability to resist corrosion. Austenitic alloys are also used to manufacture forceps and retractors in which resilience is a necessary property of the instrument. Martensitic alloys are used to manufacture cutting instruments that must maintain sharp edges and accurate jaw alignment, such as osteotomes, scissors, curettes, and rongeurs. The combination of austenitic and martensitic alloys for specific component parts of high-quality surgical instruments is also beneficial with respect to instrument performance and durability. High-quality surgical scissors, for instance, have finger rings and handles made of 300 series alloy, blades made of 400 series alloy, and tungsten-carbide blade edge inserts.

SURGICAL BLADES

The scalpel is the instrument of choice for precise, atraumatic division of tissue. The scalpel consists of a handle portion and a blade portion. Blades may be detachable and thereby replaceable, or the scalpel may consist of a solid piece of steel that requires periodic sharpening of the blade. The handle portion of the scalpel may differ in size. The no. 3 handle is most commonly used for foot and ankle surgery (Fig. 1.2). The handle should have an engraved metric scale on one side. The scalpel can be held between the thumb and third finger, with the index finger placed along the back of the blade. This is referred to as the pencil grip and is used in foot and ankle surgery because it provides excellent control for making precise incisions (Fig. 1.3). When it is held in the reverse fashion, the scalpel handle may also be used to assist in separating the subcutaneous tissue from the deeper layers. This is commonly performed in the reflection of the subcutaneous tissue from the medial aspect of the first metatarsophalangeal joint in hallux abducto valgus surgery (Fig. 1.4).

Scalpel blades are also available in various sizes and shapes (Fig. 1.5). Blades are constructed of high-quality surgical steel, with the cutting edge honed to a width of approximately 0.015 inch. The scalpel blade is designed strictly for incising tissues, and the belly of the blade should be used as the primary cutting edge. Scalpel blades should not be used for prying because they may easily break within the wound. Reversing the instrument and prying or bluntly separating with the handle portion of the scalpel may be useful. Separate blades are usually used for incising the skin and deeper tissues. The broad no. 10 blade functions well as the skin knife in most cases, although the smaller no. 15 blade may be desirable for making precise skin incisions on the digits. The no. 15 blade is also most commonly used as the deep knife. The no. 11, or bayonet, blade is useful for performing open Z-plasty tenotomy, as well as incising superficial abscesses for drainage. Some surgeons find the smaller Beaver blades (nos. 64, 67, and 81) and matching handle useful for digital arthroplasty as well as for nail plate and bed incisions.

Figure 1.1 Needle driver with a tungsten-carbide insert.

Figure 1.2 A no. 3 scalpel handle with an engraved metric scale.

Figure 1.3 The pencil grip may be used to hold the scalpel handle.

Figure 1.4 The reverse end of the scalpel may be used to help separate the subcutaneous tissue from deeper layers.



Figure 1.5 Surgical blades **(top to bottom)**: no. 10, no. 11, no. 15, and no. 62 on a minihandle.

SCISSORS

Besides the scalpel, scissors are the instruments most commonly used for tissue dissection (Figs. 1.6 and 1.7). Scissors also serve as the general-purpose instrument for cutting sutures, bandages, and other materials. Tissue scissors are finely constructed of surgical steel and are of lighter weight compared with the heavier suture cutting and utility scissors. Dissecting scissors are designed to cut soft tissues only and should not be used to cut other materials. These instruments are best grasped with the thumb and ring fingers in the finger rings, with the index finger stabilizing the hinge region of the scissors and the middle and little fingers on either side of the lesser digital finger ring (Fig. 1.8).

The blunt tips of dissecting scissors are best used for spreading and cutting tissues, and thumb forceps are usually held in the contralateral hand to manipulate tissues. The blades of the scissors should not be closed without first visualizing the tips.

Tungsten-carbide blade inserts prolong the maintenance of a sharp cutting edge. Straight blades are used near the wound surface, whereas curved blades aid in deeper dissection. The curved design of dissecting scissors enhances visualization of the cutting field, improves directional mobility, and readily allows tissue separation along smooth curves. Heavier blunt-tipped Mayo scissors are used for cutting thick bands of fascia and ligament; they are available with either straight or curved blades. The lighter Metzenbaum scissors have narrow, slightly curved, blunt-tipped blades that are ideal for subcutaneous

Figure 1.6 Metzenbaum scissors.

dissection and cutting lighter fascial and capsular structures. The fine cutting blades of the lightweight iris scissors are suited only for delicate tissue dissection, and careful manipulation of the sharp tips of this instrument is necessary. The short, broad-blade, collar-and-crown, or Sistrunk, scissors are occasionally used for accurate dissection of osseous structures such as sesamoid bones.

Suture scissors usually have straight blades with blunt tips that reduce the chance of inadvertent injury to nearby tissues. When deep sutures are cut, the tips of the scissors are placed about the suture and the blades are slid down to the level of the knot; they are turned approximately 25 degrees, and, with the tips in full view, the scissors are closed. In cutting deep sutures that are under a large amount of tension, a small tag of suture should be left above the knot. A larger tag is left when one is cutting skin sutures that will be removed later. Often, general utility scissors, which come in various sizes, are used for cutting sutures. Stainless steel monofilament wire sutures are cut with wire-cutting scissors.

Bandage scissors are designed with a flat, plow-like lower blade tip that protects the patient from inadvertent injury during bandage removal. Ideally, a wound should be undressed without cutting the deep layers of the bandage. All house staff members and medical students should carry, and have readily available, a clean, sharp pair of bandage scissors.

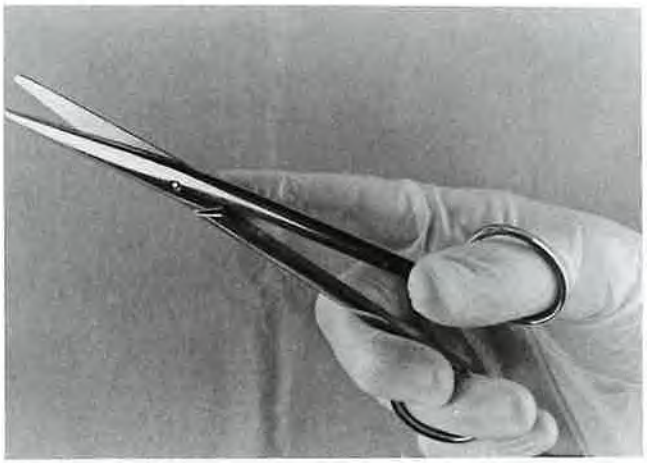

Figure 1.8 Grasping the scissors.

HEMOSTATIC FORCEPS

Hemostats are hinged instruments composed of a set of jaws, finger rings, and a locking mechanism (Fig. 1.9). They are the primary means of acquiring hemostasis during anatomic dissection and are also useful for bluntly spreading tissues. Many types of hemostatic forceps are available, and those most commonly used in foot surgery include the mosquito (Halsted), Crile, and Kelly designs. Hemostatic jaws are straight or curved, with serrations that run either perpendicular or parallel to the long axis of the jaws. The forceps close with force about the vessel and lock and thereby crush the contained tissue that will be ligated. If the clamped portion of vessel is to remain functional, such as in vascular reconstruction, a noncrushing or controlled-closure hemostat must be used. Hemostatic metal clips may also be used to obtain secure ligation of vessels in sites that are poorly accessible with hand ties.

Figure 1.7 Scissors (**left, top to bottom, then right, top to bottom**): bandage, wire-cutting, Metzenbaum, crown-and-collar or Sistrunk, iris, and Mayo.

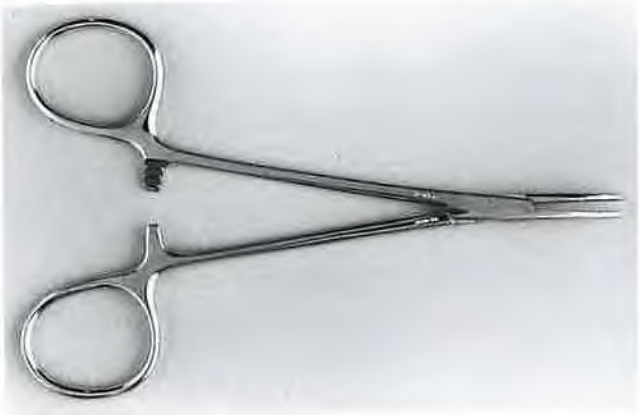

Figure 1.9 Halsted (mosquito) hemostatic forceps.

THUMB FORCEPS

Thumb forceps consist of two pieces of surgical steel attached at one end, and they are used to pick up or grasp tissues (Fig. 1.10). The forceps are held among the thumb, middle finger, and index finger of either hand. The tips may be flat or have teeth or fine serrations, and they vary in width. Forceps with teeth (Brown-Adson, rat-tooth or one-two) are usually narrow and allow the surgeon to hold structures securely while a minimum of tension is applied. Flat-tipped or finely serrated narrow forceps (atraumatic forceps) are used to delicately grasp vital structures, to pull sutures and needles, and, with great care, to manipulate skin during closure. The one-two (rat-tooth) pickup is frequently used for skin closure, depending on the surgeon's preference. The wide-tipped Russian forceps are excellent for delicate manipulation of deep tissues in the hindfoot and ankle. Wide-tipped atraumatic forceps (Potts-Smith) may also be useful for the application and removal of surgical dressings.

TRACTION FORCEPS

Traction forceps are of heavier construction than hemostats and consist of a locking mechanism and finger rings, as well as jaws for grasping tissues (Fig. 1.11). The grasping portion of each jaw typically has teeth, or a single sharp point, that provides traction without undue pressure or crushing force.

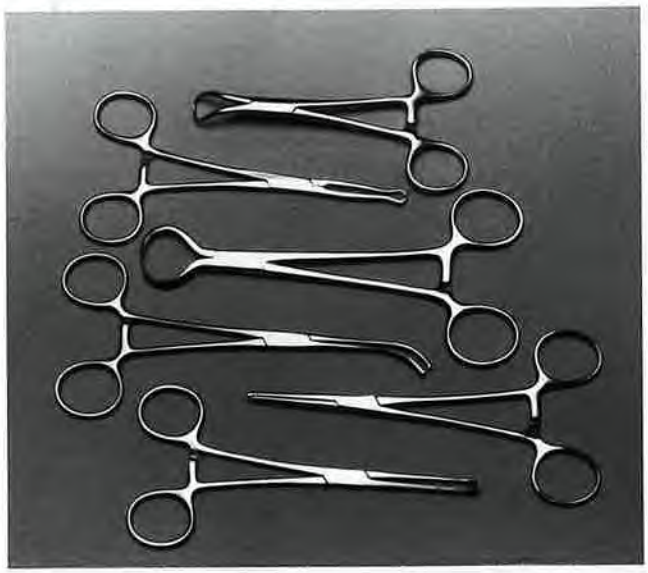

Figure 1.11 Assorted traction forceps **(top to bottom)**: Backhaus towel clamp, phalangeal forceps, Lewin, sesamoid clamp, Kocher, and Allis clamp.

The Backhaus towel clamp provides a double-sharp set of jaws and is used for draping the operative field and, occasionally, for grasping bone. The Allis clamp is available with narrow or wide jaws, each jaw composed of opposing serrated edges or short teeth. These are effective for grasping and retracting fascia and the subcutaneous layer, and they are occasionally used for clamping towels while draping. Kocher forceps have two long-blade jaws displaying transverse serrations with opposing sharp, interlocking teeth at the tips. These are useful for placing traction on heavy fascia, although care must be taken to avoid crushing the contained tissues. Uterine packing forceps have gently curved, long jaws that make them ideal for transferring tendons along tendon sheaths during myoplastic reconstruction. The sesamoid clamp and phalangeal forceps are specifically designed for grasping small ossicles and bony fragments. The sponge clamp has two opposing circular jaws with transverse serrations used to hold a folded gauze sponge during preparation or blotting of the surgical area (Fig. 1.12).

Figure 1.10 Assorted thumb forceps **(top to bottom)**: one-two or rat-tooth, Brown-Adson, and atraumatic.



Figure 1.12 **Top to bottom**: uterine packing forceps, tendon-passing forceps, and sponge clamp.

RETRACTORS

Retractors are used to hold tissues aside, thereby increasing exposure and protecting vital structures. The blade portion of the retractor may be fixed or malleable, and the retractor itself may be handheld or self-retaining. Handheld retractors enable the assistant to control the force with which tissues are held and to release tension intermittently as necessary (Figs. 1.13 and 1.14). Conversely, self-retaining retractors free the assistant to perform duties that may expedite the procedure (Figs. 1.15 to 1.17).

Figure 1.13 Handheld retractors (**top to bottom**): double-prong skin hooks, Senn, and Ragnell.

Figure 1.14 The Senn retractor (seen dorsally) works well when tissue needs to be pulled apart to provide visualization of deeper structures. The Seeburger malleable retractor (seen plantarly) is helpful in reflecting and holding tissue around a corner or exposed region of bone.

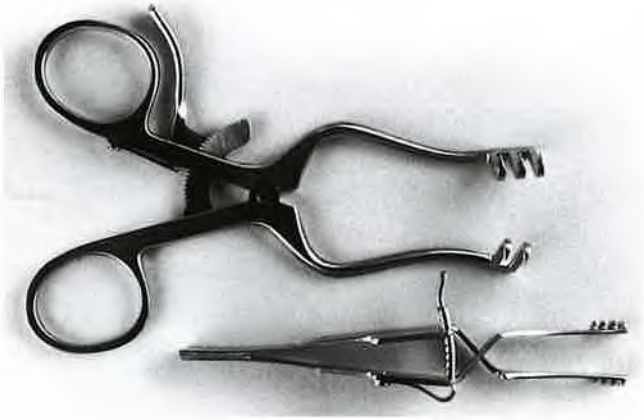

Figure 1.15 The three-two Weitlaner self-retaining retractor (**top**) and the digital self-retaining or Holzheimer retractor.

Figure 1.16 The Weitlaner retractor is particularly helpful in dissection of the first intermetatarsal space for the repair of hallux abducto valgus deformity.

Figure 1.17 The small lamina spreader.

Self-retaining retractors should be gently set and intermittently released during long procedures in an effort to avoid tissue necrosis or excessive retraction trauma. Large handheld retractors such as the Army-Navy devices are helpful in providing full exposure when dissection is performed in the rearfoot and ankle area (Fig. 1.18).

A self-retaining retractor with many applications in reconstructive foot and ankle surgery, the Weinraub Joint and Calcaneal Spreader (Innomed, Savannah, GA) (Fig. 1.19) employs two pins that are affixed to the selected osseous segments to be separated (or compressed) via cylindrical sleeves on either side of the retractor's hinged arms, thereby stabilizing the instrument and preventing descent into the surgical site (Fig. 1.20). This particular retractor, or one with a similar design, can be used to enhance exposure and to facilitate access to many joints, particularly those deep in the hindfoot, for resection and preparation for fusion.



Figure 1.18 **Top to bottom**: Large malleable ribbon retractor, Army-Navy or right-angle, and Volkmann rake.

Figure 1.19 The Weinraub retractor.

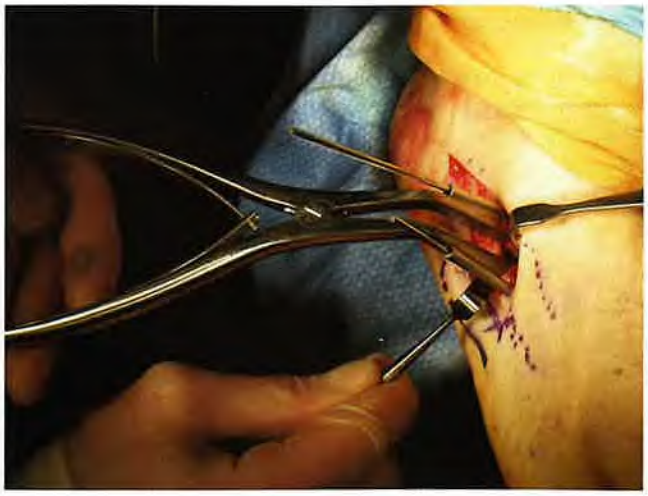

Figure 1.20 The Weinraub retractor affixed to joint margins via 0.045-inch K-wires and used to distract the osseous segments.

PERIOSTEAL ELEVATORS

Periosteal elevators are used to separate periosteum from underlying bone and, occasionally, to provide leverage for retracting deep fascia, ligaments, and periosteum (Fig. 1.21). These instruments have smooth, broad blades that vary in sharpness. The Freer elevator is ideal for reflecting periosteum from the shaft of a metatarsal. One end of the Freer elevator is semisharp, whereas the other is blunt. The Sayre elevator has a short, heavy, rounded blade frequently used to distract the sesamoid apparatus from the first metatarsal head. In other circumstances, it works well to pry apart and separate osseous segments. Key elevators are excellent for rapidly reflecting periosteum from glabrous bony surfaces, as are the narrow-blade and broad-blade Langenbeck elevators. Crego elevators expedite periosteal reflection around curved surfaces such as the talar neck and posterior aspect of the calcaneus and are essential in performing triple arthrodesis and other hindfoot procedures (Fig. 1.22).

OSTEOTOMES, CHISELS, GOUGES, AND MALLETS

Osteotomes (Lambotte) and chisels are used to resect prominent portions of bone, and the cutting edge of these instruments must be periodically sharpened to ensure proper function. Osteotomes differ from chisels in that both surfaces of an osteotome taper to form a fine cutting edge, whereas one surface of a chisel tapers to meet the opposite flat surface at the cutting edge (1) (Fig. 1.23).

Figure 1.21 Periosteal elevators (**top to bottom**): Freer, Sayre, and Key.

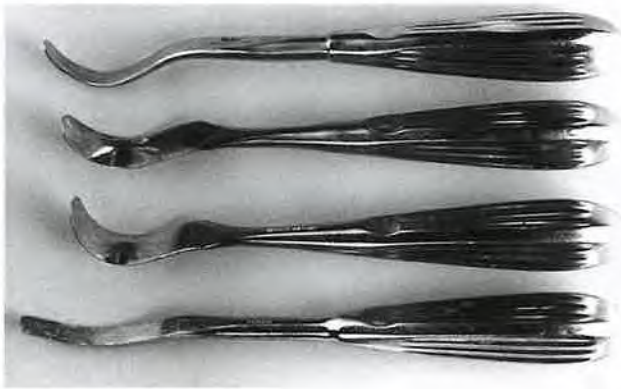

Figure 1.22 Crego periosteal elevators.



Figure 1.23 Chisel (**top**) and osteotome (**bottom**).



Figure 1.24 Mallet (**top**) and straight osteotome (**bottom**).

Figure 1.25 McGlamry metatarsal elevator.

Osteotomes and chisels are held firmly in one hand and are driven with deliberate, repetitive blows from the surgical mallet. Mallets are available with stainless steel heads, as well as heads capped with synthetic polymers for quieting the blow and enhancing control. The small and medium-sized mallets are best suited for podiatric surgery (Fig. 1.24).

Gouges are similar to chisels; however, the cutting edge is curved. These instruments come in various widths and are useful in smoothing curved surfaces and rounding flat surfaces of bone. Gouges may also be used to free metatarsal heads from surrounding soft tissue structures. The McGlamry metatarsal elevator is a specialized gouge with a broad, curved, scoop-like blade set on a curved handle (Fig. 1.25). This instrument is ideal for freeing metatarsal heads from adherent soft tissues, for exposing the plantar surface of the head for observation, and for releasing an adherent flexor plate.

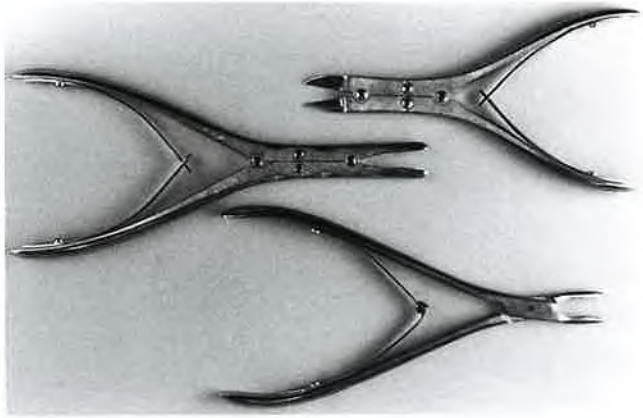

Figure 1.26 **Top to bottom**: Bone-cutting forceps (double-action), straight rongeur (double-action), and curved rongeur (single-hinge).

BONE-CUTTING FORCEPS AND RONGEURS

Bone-cutting forceps and rongeurs are used to incise through and reduce bone or to resect cartilaginous surfaces. Instruments used for osseous work (Fig. 1.26) are frequently of the multihinge design and function on the so-called double-action principle. This increases mechanical advantage, reduces operator strain, and provides increased accuracy. Double-action bone-cutting forceps have straight or slightly curved jaws that are ideal for transecting phalanges and other small-diameter portions of bone. Rongeurs have strong, heavily constructed opposing jaws, each of which is scooped out like the tip of a curette. Rongeur jaw designs include broad or narrow (needle-nose rongeurs) and straight or curved. The sharp cutting edges of the rongeur are ideal for reducing bony prominences, such as spurs and spicules, as well as sharp edges.

TREPHINES AND CURETTES

Trephines display a circular cutting edge at the tip of a hollow tube that enables the operator to remove plugs of bone neatly for biopsy, graft procurement, or osseous reduction (Figs. 1.27 and 1.28). Assorted trephines and corresponding obturators should be available. A small modified trephine, known as a plug cutter, may also be used to remove



Figure 1.27 Obturator (**top**) and trephine (**bottom**).

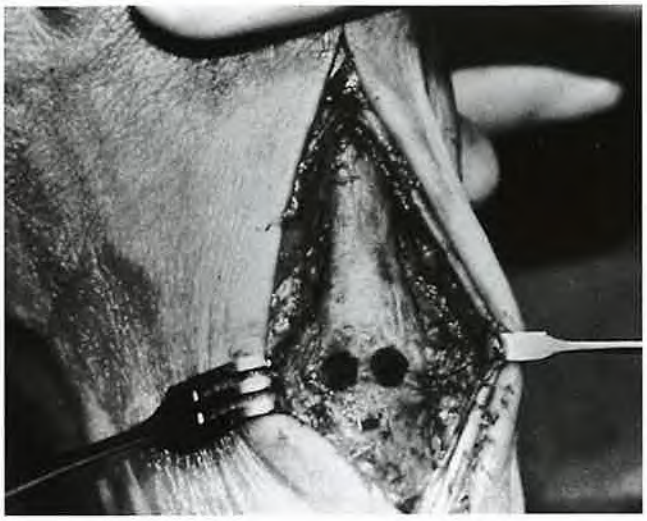

Figure 1.28 The trephine may be used in joint fusion. Bone has been removed in the first metatarsocuneiform joint. The defects will be replaced with bone graft to effect fusion.

Figure 1.29 Curettes: dermal (**top**) and Cobb (**bottom**).

Figure 1.30 Ringed (uterine) curette.

surrounding bone from the tip of a buried fixation wire or pin and thereby to expedite removal of the wire or pin whenever retrieval is necessary.

Curettes consist of a curved, scoop-like blade on a handle (Fig. 1.29). Heavy curettes are used for reducing rough bony surfaces and for gouging into broad areas of bone. They are also useful for débriding infected or necrotic bone. Dermal curettes, conversely, are of lighter construction and are used for débridement of soft tissues as well as nail beds and grooves. Ringed (uterine) curettes are unique in that the shaft of the instrument is malleable, so the cutting portion of the instrument can be placed in areas that are difficult to reach such as the lateral portion of the talonavicular joint when arthrodesis is performed (Fig. 1.30).

BONE-HOLDING CLAMPS AND REDUCTION FORCEPS

Clamps used to grasp bone or to hold bony fragments together are of heavy construction and are capable of applying large amounts of pressure. Some bone clamps and reduction forceps have a hinge with a locking ratchet, whereas others close on tightening of a locking nut. Small fragments of bone and small ossicles such as sesamoids or phalanges may be grasped and manipulated with sesamoid and phalangeal clamps (Fig. 1.31). The double-sharp and alligator bone reduction forceps are ideally suited for reducing and maintaining small and medium-sized fragments (Fig. 1.32). Larger fragments encountered in hindfoot and ankle fractures require heavier reduction forceps such as the Lewin, "baby" Lane, Lowman, and Verbrugge (Fig. 1.33).

RASPS

Rasps are used to reduce and smooth bony surfaces (Fig. 1.34); they are usually employed after a bony prominence has been grossly reduced by means of an osteotome and mallet, rongeur, or power saw. The cutting surface of a rasp presents serrations of fine teeth running in a parallel or crosscut pattern (Fig. 1.35). The Bell rasp is double-ended with two small elliptic rasping surfaces. The Joseph nasal rasp, also known as the beaver-tail rasp, has a single, long, elliptic cutting surface with a double crosscut pattern for fine smoothing of broad surfaces. The Maltz and Parkes rasps each present a single, coarse cutting surface ideal for rapid reduction of large osseous prominences. Rasping surfaces are also available for reciprocating power instrumentation. A stainless steel wire brush should be available for periodic intraoperative cleansing of the rasp surface.

NEEDLE HOLDERS

Needle holders consist of finger rings, a locking mechanism, and jaws and come in a wide variety of sizes and shapes (Fig. 1.36). The individual surgeon picks the design that he or

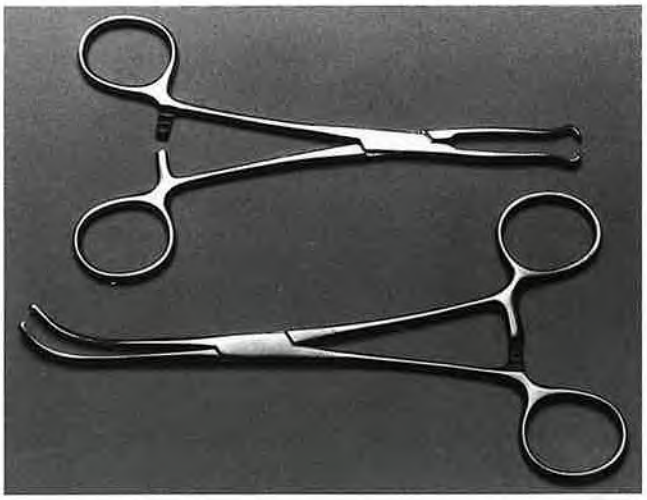

Figure 1.31 Phalangeal (**top**) and sesamoid (**bottom**) clamps.

Figure 1.32 Bone reduction forceps (**left to right**): Lewin, ASIF double-sharp, ASIF "alligator" small fragment, ASIF small plate forceps, and ASIF small fragment self-centering clamp.

Figure 1.33 Large fragment reduction forceps (**top to bottom**): Verbrugge, Lowman, and "baby" Lane.

Figure 1.34 Rasping instruments (**top to bottom**): Joseph nasal rasp (beaver-tail), Maltz rasp, Podiatry Institute rasp, and Bell rasp.

she prefers for each specific task. Long-handled needle holders are used for closing deeper layers, whereas shorter designs are used superficially. Jaw designs vary from smooth, to crosscut or parallel serrations, to channeled jaws for holding specific needles and those modified for twisting wires. Needle holders with heavy jaws are used to hold large needles, and *vice versa*. Tungsten-carbide jaw inserts greatly enhance instrument function and durability. Examples of commonly used needle holders include Mayo-Hegar, Sarot, Ryder, and Halsey devices.

POWER INSTRUMENTATION

Practically any aspect of osseous surgery may be performed with power instrumentation. Power saws, both oscillating and reciprocating, drills, burs, rasps, wire drivers, osteotomes, and screwdrivers are commercially available. Power sources may be pneumatic or electrical (alternating or direct current). Power instrumentation varies with respect to size, strength, maneuverability, precision, durability, method of sterilization, and care. The decision regarding which set to use varies with the surgical site and the



Figure 1.35 Comparison of crosscut (**left**) and parallel-cut (**right**) rasping surfaces.

Figure 1.36 Assorted needle holders.

surgeon's preference. The electrosurgical cleaning ("scratch") pad can also be used to refine the cutting edges of some instruments, as suggested by Kubiak et al (2). Its coarse surface, synthesized from aluminum oxide and rooted in epoxy, may be used to refinish coarse irregularities on instruments made of soft metals, some stainless steel instruments, and even titanium. The authors have used this intraoperatively to restore the rims of drill sleeves damaged and deformed from repeated use.

INSTRUMENTS FOR FIXATION OF BONE AND OTHER TISSUES

Fixation of bony fragments may be obtained in many ways. Osseous fixation is best obtained by following standard techniques of osteosynthesis. Fixation devices include stainless steel wire sutures (20, 22, 24, 26, 28, and 30 gauge), Kirschner wires (K-wires), and Steinmann pins in a variety of sizes, both threaded and smooth, with tips varying from tapered to trocar or bayonet for easy penetration of hard cortical bone. These may be used to fixate bony fragments by direct pinning or intramedullary nailing, as well as providing anchoring for skeletal traction. Various specialized wire twisters are available. A handheld wire bender, a standard wire cutter or a flush wire cutter, a pair of needle-nose pliers (single- or double-action), and a small plug cutter are also recommended (Fig. 1.37).

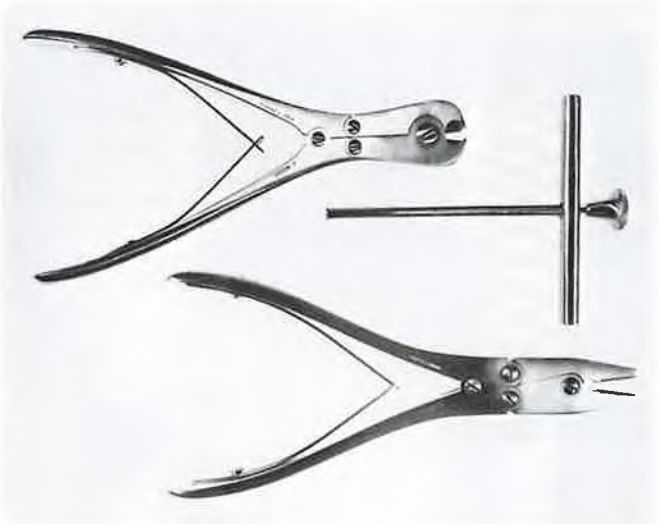

Figure 1.37 Flush pin set consists of a double-action flush pin cutter **(top)** designed to cut K-wires flush with bone to facilitate burying of wires. It also contains a small plug cutter **(middle)** and double-action needle-nose pliers **(bottom)** for retrieval of buried wires.

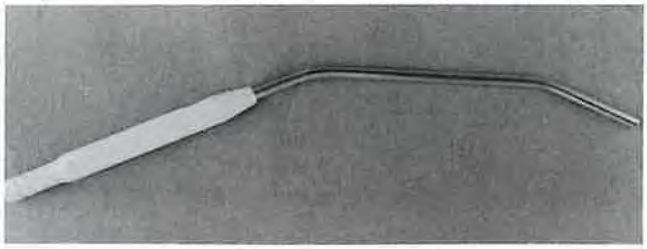

Figure 1.38 Malleable Frazier-tip suction catheter.

SUCTION APPARATUS

A continuous suction source is helpful in some podiatric surgical cases. The amount of suction should be variable and controlled by the assistant operating the suction catheter. The malleable Frazier-tip suction catheter (Fig. 1.38) is ideal for use in foot and ankle surgery, whereas suction catheters of a larger size may be necessary in the leg.

CONCLUSION

Obviously, the wide variety of surgical needs mandates the availability of a large array of instrumentation (3). Not every instrument is needed for every case, and for this reason the basic instruments are divided into a forefoot pack and a rearfoot or ankle pack. The forefoot pack supplies instrumentation for a typical bilateral forefoot case. For hindfoot surgery, the rearfoot or ankle pack is opened along with the forefoot pack. Division of instrumentation into reduced sets also allows more efficient sterilization and storage. Instruments that may be needed at any time, regardless of surgical site, are packed separately. Basic instrument packs for specific surgical application include the following:

I. Forefoot pack
   A. Blade handles
      1. No. 3 scalpel handle (six)
      2. Long and short Beaver handles (one each)
   B. Scissors
      1. Iris, small (one)
      2. Crown and collar (one)
      3. Curved and straight Mayo (one each)
      4. Metzenbaum (two)
      5. Large utility (two)
      6. Lister bandage (two)
      7. Monofilament wire cutter (one)

C. Hemostatic forceps
   1. Curved and straight mosquito (12 and four, respectively)
   2. Curved and straight Crile (two each)
   3. Curved and straight Kelly (two each)
D. Thumb forceps
   1. Brown-Adson (four)
   2. Rat-tooth (one-two pickup) (two)
   3. Atraumatic (two)
   4. Large toothed (two)
   5. Large atraumatic (two)
E. Traction forceps
   1. Backhaus towel clamp (six)
   2. Allis clamp, large and small (two each)
   3. Kocher (two)
   4. Sesamoid clamp (one)
   5. Phalangeal forceps (one)
   6. Sponge clamp (one)
F. Retractors
   1. Digital self-retaining (one)
   2. Weitlaner three-two and four-three (two and one, respectively)
   3. Skin hooks, single- and double-prong (two and four, respectively)
   4. Ragnell (four)
   5. Senn (four)
   6. Seeburger (two)
   7. Mini-Hohmann (four)
   8. Rakes (four-prong, sharp) (two)
   9. Army-Navy (two)
   10. Malleable ribbon (two)
G. Periosteal elevators
   1. Freer (four)
   2. Langenbeck, narrow and broad (one each)
   3. Sayre (one)
H. Osteotomes, chisels, mallets
   1. Lambotte osteotomes (2 to 22 mm) (one each)
   2. Curved osteotome (8 mm) (one)
   3. US Army no. 18 chisel (one)
   4. Medium-sized surgical mallet (one)
I. Bone-cutting forceps, rongeurs
   1. Double-action bone-cutting forceps (one)
   2. Large and small curved double-action rongeurs (one each)
   3. Needle-nose rongeur (one)
J. Bone-holding clamps: Lewin (one)
K. Rasps and wire brush
   1. Bell rasp (two)
   2. Joseph nasal (beaver-tail) (two)
   3. Maltz and Parkes (one each)
   4. Wire brush (one)
L. Needle holders: assorted sizes and jaw configurations depending on surgeon's preference
M. Miscellaneous
   1. Ruler (stainless steel)
   2. Flush wire cutter (one)
   3. Wire bender (one)
   4. Double-action needle-nose pliers (two)
   5. Small plug cutter (one)

II. Rearfoot or ankle pack
A. Retractors
   1. Large ribbon (two)
   2. Large rakes (two)
   3. Lamina spreader (one)
B. Periosteal elevators
   1. Key (one set)
   2. Crego (one set)
C. Osteotomes, gouges, mallets
   1. Large osteotomes (one set)
   2. Gouges (one set)
   3. Large surgical mallet (one)
D. Bone-cutting forceps and rongeurs
   1. Large double-action bone-cutting forceps (one)
   2. Large double-action rongeur (one)
   3. Kerrison rongeur (two)
E. Curettes and trephines
   1. Bone curettes (one set)
   2. Trephines (one set)
F. Miscellaneous
   1. Blount staple holder, driver, puller (one set)
   2. Large pin cutter (one)

III. Minor surgical pack
A. Blade handles: no. 3 scalpel handle (two)
B. Scissors
   1. Iris (one)
   2. Crown and collar (one)
   3. Curved and straight Mayo (one each)
   4. Metzenbaum (one)
   5. Utility scissors (one)
C. Hemostatic forceps
   1. Curved and straight mosquito (four and two, respectively)
   2. Curved and straight Crile (one each)
   3. Curved and straight Kelly (one each)
D. Thumb forceps
   1. Brown-Adson (one)
   2. Rat-tooth (one-two pickup) (one)
   3. Atraumatic (one)
E. Traction forceps
   1. Backhaus towel clamps (two)
   2. Allis clamp (two)
F. Retractors
   1. Digital self-retaining (one)
   2. Weitlaner three-two (one)
   3. Skin hooks, double-prong (two)
   4. Senn (two)
   5. Seeburger (two)
G. Periosteal elevators: Freer (two)
H. Rasps
   1. Bell (one)
   2. Joseph nasal (one)
I. Needle holders: large and small (one each)
J. Miscellaneous
   1. Large bone curette (one)
   2. Straight nail nipper (one)
   3. Curved tissue nipper (one)
   4. Glass medicine cup (one)
   5. Stainless steel bowl (3-inch diameter) (one)
   6. Bandages
      a. 4 × 4 inch gauze (10)
      b. 2- and 3-inch Kling (one each)

IV. Nail surgical pack
A. Blade handles
   1. No. 3 scalpel blade (one)
   2. Beaver blade handle (one)

B. Scissors and nippers
   1. Iris (one)
   2. Utility (one)
   3. Large and small nail nippers (one)
   4. English anvil nail nipper (one)
C. Hemostatic forceps
   1. Straight mosquito (two)
   2. Straight Kelly (one)
D. Thumb forceps: Brown-Adson (one)
E. Elevators and curettes
   1. Freer (two)
   2. Nail-plate elevator, large and small (one each)
   3. Medium-sized dermal and bone curette (one each)
F. Needle holder: small (Mayo-Hegar jaw) (one)
G. Miscellaneous
   1. Glass medicine cup (one)
   2. Cotton-tip applicators (10)
   3. Bandages
      a. 2 × 2 inch and 4 × 4 inch gauze (10 and six, respectively)
      b. 2-inch Kling (one)

V. Ulcer or wound débridement pack
   A. Blade handles: no. 3 scalpel handle (two)
   B. Scissors and nippers
      1. Iris (one)
      2. Utility (one)
      3. Nail nipper (one)
      4. Tissue nipper (one)
   C. Hemostatic forceps: curved and straight mosquito (one each)
   D. Thumb forceps
      1. Brown-Adson (one)
      2. Atraumatic (one)
   E. Elevators and curettes
      1. Freer (one)
      2. Medium sized dermal and bone curette (one each)
   F. Miscellaneous bandages
      1. 4 × 4 inch gauze (10)
      2. 2-inch Kling (one)

VI. Podiatry dressing pack
   A. 4 × 4 inch gauze (10)
   B. Kling
      1. 2-inch (one)
      2. 3-inch (one)
   C. Tube gauze (2 5/8 × 36 inch) (one)

REFERENCES

1. Edmonson AS, Crenshaw AH, eds. *Campbell's operative orthopedics*, 6th ed. St. Louis, MO: CV Mosby, 1980:1–20.
2. Kubiak EN, Hildebrandt R, Egol KA, et al. Intraoperative instrument repair using an electrocautery pad. *J Orthop Trauma* 2004;18:236–237.
3. Nealon TF. *Fundamental skills in surgery*, 3rd ed. Philadelphia, PA: WB Saunders, 1979:12–24.

CHAPTER

31

Lawrence A. DiDomenico
Mari Wargo-Dorsey

Lapidus Bunionectomy: First Metatarsal–Cuneiform Arthrodesis

Metatarsus primus varus and hallux abducto valgus (HAV) have been used to correct HAV since originally described by Albrecht (1) in 1911. Truslow (2) followed with a version of the procedure in 1925 that involved a wedged resection of bone from the first metatarsocuneiform joint. The procedure was later popularized by and named after Paul Lapidus. In 1930, he proposed a first metatarsal–cuneiform arthrodesis paired with arthrodesis of the second metatarsal as well as resection of the dorsomedial eminence of the first metatarsal head and distal soft tissue repositioning for metatarsus primus varus. He believed that metatarsus primus varus was the result of an underdeveloped atavistic foot type. He hypothesized that hypermobility of the first metatarsal–cuneiform joint combined with an increased first to second intermetatarsal (IM) angle caused by an oblique joint axis predisposes the foot to HAV and metatarsus primus varus. Lapidus concluded that the apex of the deformity, the first metatarsal–cuneiform joint, needed to be addressed or a "bayonet-shaped" deformity would result (3).

While many techniques have been described modifying the original Lapidus procedure, all use arthrodesis of the metatarsal–cuneiform joint (4–11). The procedure allows for triplanar correction of first metatarsal pathology, increases the biomechanical advantage of the peroneus longus, and has the ability to stabilize the medial column. The first metatarsal–cuneiform arthrodesis, while controversial, is a versatile procedure that can correct numerous pathologies.

EVALUATION/DIAGNOSIS/ FUNCTIONAL ANATOMY

Traditionally, the first metatarsal–cuneiform arthrodesis has been used to correct for a hypermobile first ray. When the first metatarsal possesses increased motion of the first metatarsal–cuneiform joint, the metatarsal elevates during gait, making the first ray unstable and unable to maintain its position against ground reaction forces throughout the gait cycle (12). Numerous attempts have been made to define hypermobility in both the sagittal and transverse planes although no standardized values exist. Clinical assessment of the first ray range of motion is still currently the most accepted method to diagnose hypermobility of the first ray. Root described normal first ray motion as equal dorsal and plantar range of motion and hypermobility as anything beyond equal motion in the sagittal plane. He placed the ankle joint and subtalar joints in neutral position and then stabilized metatarsal heads 2 to 5 with one hand and the first metatarsal head with the other hand, while taking the first metatarsal through its range of motion (13,14). Later, one thumb's breadth of dorsal motion was described as hypermobile when using Root's technique (15). Roukis et al have promoted the "dynamic Hicks test," in which the foot is tested with the hands positioned in the same manner as Root described. The hallux is then fully dorsiflexed at the first metatarsophalangeal joint, and dorsal and plantar pressures are then applied to the metatarsal head. The results of the "dynamic Hicks test" are then compared with those of Root's; they believe that true hypermobility of the first ray exists when both tests show a positive result of hypermobility (16). Radiographically, hypermobility is frequently distinguished on anteroposterior radiograph as an increased first to second IM angle with medial cortical thickening of the second metatarsal, which is believed to be due to second metatarsal overload (17). Clinically, this can be accompanied with a hyperkeratotic lesion plantar to the second metatarsal head (18). Some advocate the test for evaluation of transverse plane hypermobility, which entails wrapping an ACE wrap across the forefoot while applying moderate tightness (19,20). Radiographs with the ACE wrap applied are compared with normal weight-bearing radiographs to assess if hypermobility of the joint occurs in the transverse plane, which can be seen with a decreased IM angle with the apex of deformity at the first metatarsal–cuneiform joint. Hypermobility is frequently concomitant with a large HAV deformity, although mild to moderate cases of HAV have been treated successfully when first ray hypermobility is present (5,12,21–23). The procedure is also indicated when generalized ligamentous laxity is seen with HAV.

Juvenile HAV frequently is accompanied by hypermobility at the first metatarsal–cuneiform joint. Adolescent HAV differs from adult HAV in that a smaller dorsomedial eminence is present and less valgus rotation of the hallux occurs (24,25). If hypermobility is present and not addressed, recurrence of the deformity may result, as juvenile HAV frequently is a structural problem that can persist throughout adulthood and progress (12,22). It has been demonstrated that the angle created by the axis of the first metatarsal and the distal surface of the medial cuneiform is increased with statistical significance in Juvenile HAV, supporting that varus angulation occurs proximal to the metatarsal at the level of the first metatarsal–cuneiform joint. A positive correlation also exists between the angle created by the distal surface of the medial cuneiform and the axis of the second metatarsal and an increased IM angle (26). Lower recurrence rates have been achieved with this procedure as it addresses the deformity at its apex and eliminates first ray hypermobility (17,22,27). Juvenile HAV corrected with other procedures has been noted to have recurrence rates as high as 35% (27,28). The procedure is an excellent option for correction of Juvenile HAV as it can be performed successfully without resection of the medial eminence and distal soft tissue release (17).

Moderate to severe HAV can be treated effectively with this procedure without the presence of hypermobility. IM angles ranging from 14 to 30 degrees on anteroposterior radiograph have been used as a baseline for the procedure (24,29). Etiology of an increased IM angle may be due to the shape of the first MC joint itself, as a positive correlation exists between the obliqueness of the joint and increased first to second IM angle (30). Surgical correction of large IM angles needs to be addressed with proximal procedures, as the long lever arm allows for a higher level degree of correction as opposed to distal procedures. The procedure has the ability to restore first metatarsophalangeal joint congruency and realign the sesamoid apparatus in addition to correction of the IM angle. The closing base wedge osteotomy (CBWO) and the modified Lapidus were compared and both procedures demonstrated significant first to second IM correction, with the Lapidus maintaining a greater degree of correction postoperatively, the CBWO losing an average of 2.55 degrees of correction and the Lapidus losing only an average of 1.08 degrees (31).

More recently, the procedure has been used in conjunction with other procedures as a practical option for treatment of medial column insufficiency and flatfoot deformity. Addressing the medial column for these pathologies is vital as the first metatarsal can accommodate up to 50% of the stress experienced through gait and provides a paramount role in stabilizing the medial longitudinal arch (32). It is important to note that the procedure is not advocated for primary correction of these pathologies. Morton described what has become known as a "Morton's foot" in which the first metatarsal is anatomically or functionally short, leading to rotation about the axis of the forefoot causing pronation (33–37). The goal of surgical correction of a "Morton's foot" is to stabilize the medial column and realign the parabola of the metatarsal heads to distribute weight-bearing evenly. The peroneus longus muscle gains mechanical advantage following a Lapidus procedure contributing to functional stability of the medial column, which is lost with pronation of the foot (38,39). In 2008, Avino et al performed radiographic analysis on 39 feet in which an isolated Lapidus was performed to review the effects of the arthrodesis to the medial column in the sagittal plane. Postoperatively, the mean cuneiform increase in height was 3.44 mm and Meary's angle decreased by a mean of 2.97 degrees (40). Logel et al examined the effects of calcaneocuboid arthrodesis and first metatarsal–cuneiform arthrodesis on lateral column pressure as well as radiographic correction of flatfoot deformity on 10 fresh frozen cadaver limbs. They found that with the lateral column lengthening procedure alone there was improved radiographic measurements when evaluating lateral talus–first metatarsocuneiform angle, talonavicular coverage angle, medial column height, lateral talus–calcaneal angle, and calcaneal pitch; however, increased lateral column pressures were noted. They subsequently performed a first metatarsal–cuneiform arthrodesis on the same limbs, which decreased pressure of the lateral column and the radiographic values demonstrated additional increased correction (41). This procedure has been successfully used when medial column insufficiency is present in conditions such as Charcot-Marie-Tooth and postpolio when restoration and stability of the medial column is essential to restore function of the foot (4,42).

Degenerative joint disease (DJD) of the first metatarsal–cuneiform joint can be successfully treated with arthrodesis of the joint. DJD can be the result of arthritides, trauma, and long-standing biomechanical abnormalities (11,17,43). The pain experienced with the DJD is corrected with arthrodesis of the joint.

Failed HAV procedures may also elicit the need of arthrodesis of the Lapidus procedure as it can maintain good functional results (44). If the deformity returns following initial surgical correction, hypermobility of the first metatarsal–cuneiform joint needs to be assessed as well as generalized ligamentous laxity to determine if excessive movement of the joint was etiology of recurrence. A bone graft may need to be incorporated into the joint to maintain length and restore function as the prior procedure may have shortened the first metatarsal.

Hallux limitus and metatarsal primus elevatus may also be corrected with this procedure (21,45). With intraoperative plantarflexion of the first metatarsal, decompression of the first metatarsophalangeal joint occurs, allowing for increased motion of the joint.

CRITERIA/SELECTION OF PROCEDURE/CONTRAINDICATIONS

Inclusion criteria for the Lapidus procedure for HAV and metatarsus primus varus include a pathologic hypermobile first ray, moderate to severe HAV with or without the presence of hypermobility with a first to second IM angle greater than 15 degrees, HAV with concurrent generalized ligamentous laxity, adolescent HAV (Fig. 31.1), or instability at the tarsal–metatarsal joint in the sagittal, transverse, and/or frontal plane. The procedure can be used as an adjunctive procedure for correction of pes planovalgus deformity and hallux rigidus deformity, in patients who present with a sub–second metatarsal callous/lesion, or in conditions where tarsal–metatarsal instability exists (Fig. 31.2). Arthrodesis of the first metatarsal–cuneiform joint can be performed in the presence of painful degenerative joint and for decompression of the first metatarsophalangeal joint seen with hallux limitus and metatarsus primus elevatus.

Figure 31.1 Preoperative HAV deformity. Note the valgus rotation of the great toe

Figure 31.2 Preoperative HAV deformity in a patient who experiences pain from the callous sub–second metatarsal lesion. The lesion is a direct result of the HAV deformity and the associated instability of the tarsal–metatarsal joint.

The main contraindication of the Lapidus procedure is an exceedingly short first ray due to the shortening that is inevitable with resection of the joint. When this does occur, techniques have been described that use grafts in order to facilitate and lengthen the metatarsal–tarsal complex. A relative contraindication is juveniles with HAV when the epiphyses are open; however, the procedure can be performed with open epiphyses if fixation is performed with smooth Kirschner wires (K-wires) (46). Another relative contraindication is a young, athletic person where postoperative stiffness could follow and add morbidity to their active lifestyle (47). A foot with underlying hind foot biomechanical abnormalities should not primarily be treated with a Lapidus procedure (48,49).

TECHNIQUE

An incision is made over the metatarsal–cuneiform joint approximately 4 to 6 cm in length. There is no incision at the level of the first metatarsophalangeal joint or in the IM joint space. The tarsal–metatarsal incision is deepened in the same plane using sharp and blunt dissection. All bleeders are identified and ligated as necessary. The incision is carried down exposing the metatarsal–cuneiform joint. The tarsal–metatarsal ligaments are resected using a rongeur exposing the joint. Two mini Hohman retractors are used for the soft tissue retraction and the articular cartilage of the metatarsal–cuneiform joint are resected. The initial joint resection is performed on the first metatarsal articular surface. The first metatarsal articular surface is denuded first as this is the most distal and the most unstable segment. This resection is made perpendicular to the long axis of the first metatarsal and parallel to the existing metatarsal base. There is no correction made within the first metatarsal segment, as there is no deformity in the first metatarsal of an untreated hallux valgus/metatarsal primus varus deformity: Thus, the articular joint resection needs to be kept consistent and parallel with the natural occurring anatomy. The base of the first metatarsal is concave; therefore, the amount of cartilaginous resection on the base of the first metatarsal will need to be slightly greater than the amount on the convexity of the natural occurring articular surface of the cuneiform. The corrective articular resection is made at the distal aspect of the convex-shaped cuneiform. The correction is made in the transverse plane and the frontal and sagittal planes are later corrected via reduction and appropriate positioning of the tarsal–metatarsal joint.

Prior to reducing the joint into the appropriate desired position, a significant amount of time should be spent with joint preparation. The metatarsal base and distal cuneiform as well as the medial aspect of the second metatarsal base are prepared. It is imperative that the surgeon is diligent to ensure that the subchondral plate is penetrated demonstrating good bleeding at both the metatarsal and cuneiform. The medial cortex of the base of the second metatarsal is débrided with a pituitary rongeur (Fig. 31.3A). The joint preparation is extremely important in efforts to obtain a bony union and to avoid a delayed and nonunion. The recommended joint preparation techniques consist of the use of an osteotome and mallet, a 2-mm drill bit, and a bone pic (Fig. 31.3B). A substantial period of time is spent preparing this joint as this is a vital portion of the procedure to ensure good bony healing.

Next, the frontal plane is addressed. The surgeon derotates the hallux out of valgus in order to get the nail plate to be parallel with the ground. This derotation, allows for the entire hallux, sesamoid, and first metatarsal complex to be rotated from a position of valgus and into a neutral position as one unit. This rotation will be clinically evident at the tarsal–metatarsal joint as well as under fluoroscopy (Fig. 31.4). Because there is no dissection at the first metatarsophalangeal joint (medial eminence resection or sesamoidal dissection), the maintenance of the soft tissues allows the hallux, sesamoids, and metatarsal to function as one unit. The sesamoid correction can be observed under fluoroscopy at this time.

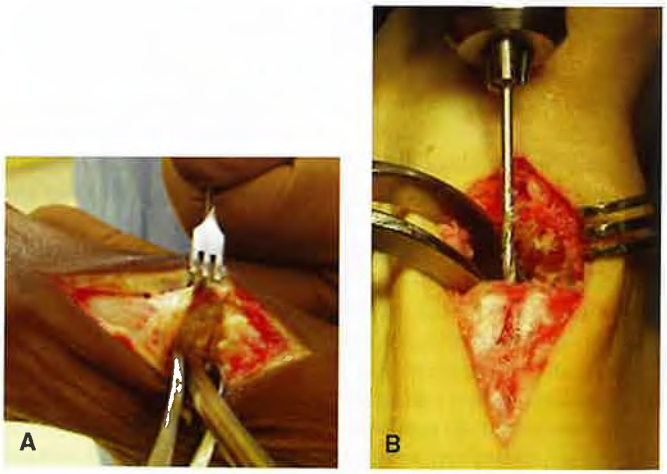

Figure 31.3 **A:** Intraoperative view demonstrating an incision that does not involve the first metatarsal phalangeal joint. This view also demonstrates the use of a pituitary rongeur to débride the medial aspect of the base of the second metatarsal. This area is used for additional attempt of stabilization between first and second metatarsal. **B:** Intraoperative clinical view demonstrating the use of a 2-mm drill preparing the tarsal–metatarsal joint prior to fixation.

Figure 31.4 **A:** Preoperative AP radiograph demonstrating a large IM angle with notable valgus deformity of the great toe and a significant sesamoid position with a valgus rotation. **B:** Intraoperative radiograph demonstrating the ability to correct the frontal plane pathology of the HAV deformity, following joint preparation of the tarsal–metatarsal. Please note the rotation of the hallux and that there is no soft tissue release performed at the metatarsophalangeal joint. **C:** Preoperative AP radiograph of a significant HAV deformity. Please note the valgus rotation of the hallux. **D:** Intraoperative AP radiograph reducing the frontal plane deformity, aligning the metatarsal phalangeal joint and the sesamoids without any distal soft tissue dissection.

The sagittal plane reduction technique is performed by stabilizing the hind foot, while the surgeon dorsiflexes the first metatarsophalangeal joint initiating the windless mechanism. This hind foot stability allows the surgeon to apply retrograde forces to the plantar tarsal–metatarsal joint and allows for the first metatarsal to plantarflex to a natural occurring level, parallel with the lesser metatarsals. Once the surgeon has the hallux, sesamoid, and metatarsal rotated to a neutral desirable position (frontal plane reduction), and the first metatarsal sagittal plane corrected, the surgeon can use his or her thumb against the first metatarsal to manually reduce the first intermetatarsal angle in the transverse plane. The primary surgeon must ensure that the first metatarsal is in the desired position, which is essentially rotated out of valgus, and parallel with the second metatarsal in both the transverse and sagittal planes. In many cases, a large Weber clamp may be used to assist, increase, or maintain the reduction (Fig. 31.5). When using the large Weber clamp, the surgeon must be sure not to change the sagittal plane

Figure 31.5 Intraoperative radiograph in a case in which a large Weber clamp was used for reduction of a large IM angle.

relationship between the first and lesser metatarsals. Next a 1.6- or 2-inch smooth K-wire is used to stabilize the reduction and position. The first K-wire is positioned from the central proximal one-third of the first metatarsal into the cuneiform. Because of appropriate positioning of the tarsal–metatarsal joint, it is not unusual to see dorsal gapping at the tarsal–metatarsal joint. Subsequently, while maintaining position in all three planes a second K-wire is inserted into the medial first metatarsal head and into the lesser metatarsals; this serves to prevent derotation in the frontal plane and maintains reduction in the transverse plane. If the surgeon feels a need to obtain more correction in the frontal plane, the K-wire can be inserted into the first metatarsal medial and lateral cortex with the K-wire in the direction of inferior medial to superior lateral. Once the K-wire penetrates the far cortex of the first metatarsal, the K-wire can be used as a rotation device and rotate the metatarsal into more of a neutral position and insert the K-wire into the lesser metatarsal to stabilize the position. The position is checked both clinically as well as under fluoroscopy to confirm acceptable alignment.

The recommended fixation techniques consist of interfragmentary compression of three solid cortical screws or an interfragmentary compression of solid cortical screw along with a medial based locking plate. Regardless of the construct, the first screw is the most important screw; this is often referred to as the "homerun screw" (50) (Fig. 31.6). This screw should be a solid long cortical screw with preference size of a 3.5 or 4 mm. A trough is created into the middorsal side of the first metatarsal approximately in the proximal one-third of the metatarsal (51). The first drill is either 4 mm for a 4-mm cortical screw or 3.5 mm for a 3.5-mm cortical screw and is drilled into the first metatarsal and stopped at the cuneiform. The next drill is either 2.9 mm for the 4-mm cortical screw or 2.5 mm for the 3.5-mm cortical screw and drilled into the cuneiform. The drill is aimed for the inferior, medial aspect of the cuneiform (based on the shape of the cuneiform, the largest cross section of bone is in the medial cuneiform). This screw should have a bicortical purchase; this screw provides interfragmentary compression and leverage. The interfragmentary compression will create an excellent reduction at the base of the tarsal–metatarsal joint most often leaving some dorsal gapping of the tarsal–metatarsal joint.

When a three-screw construct is desired, the next screw is inserted from the medial proximal one-third of the first metatarsal under the first screw with the respective drill sizes for a 3.5-mm or a 4-mm cortical screw. The initial drill is the oversized drill through the first metatarsal, and the second drill is the undersized drill into the second and or possibly the lesser metatarsals in order to obtain an excellent screw purchase. Often times a washer will be applied with this screw, which provides greater reduction of the IM angle. The third screw is placed from the most proximal dorsal position of the cuneiform aiming into the medial proximal first metatarsal. This screw also should be as long as possible for obtaining leverage (52). The construct should be checked under fluoroscopy to confirm adequate reduction (Fig. 31.7).

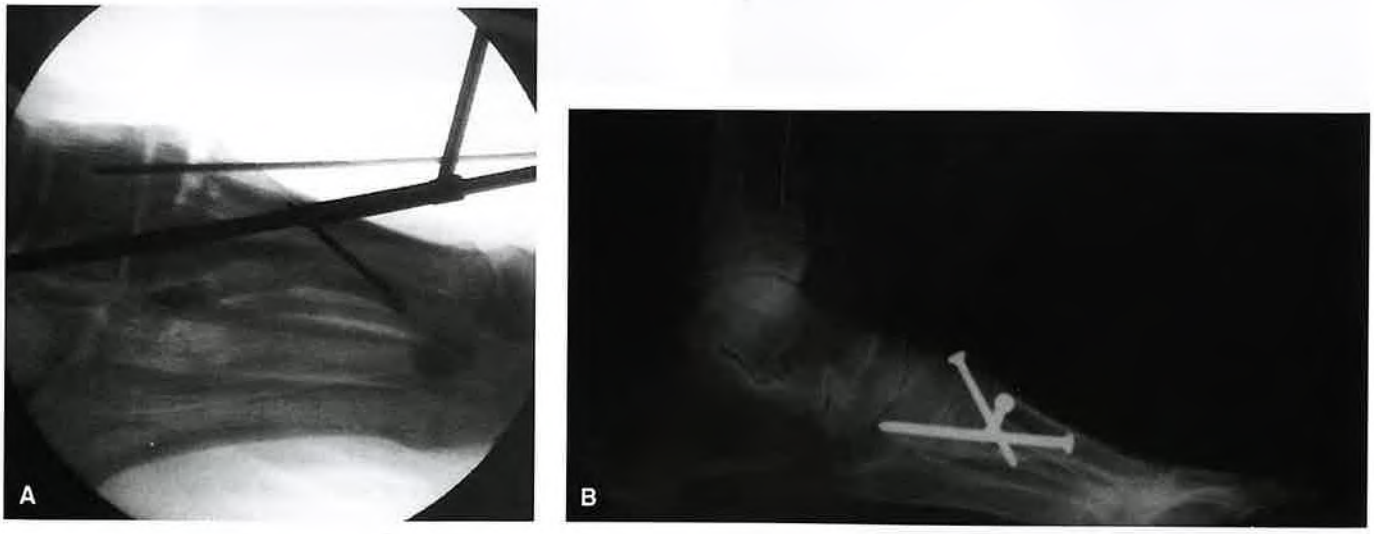

Figure 31.6 **A:** An intraoperative view demonstrating the drilling of the "homerun screw" from proximal one-third to one-half the metatarsal into and exiting the most medial, inferior cortex of the medial cuneiform. **B:** The homerun screw is long with a bicortical purchase and is almost parallel to the ground providing a "beam effect."

Figure 31.7 Postoperative AP radiograph demonstrating the "three solid cortical screw technique" with restoration of anatomical alignment.

When a locking plate is used in conjunction with an interfragmentary compression screw the plate is applied to the medial first metatarsal–cuneiform joint. Following the insertion of the homerun screw, the initial screws are placed proximal in the medial cuneiform of the plate in combination of locking and nonlocking screws. The distal screws are placed into the metatarsal with a combination of locking and nonlocking screws (Figs. 31.8 and 31.9). Similar to the three-screw technique, an interfragmentary compression screw can be applied in the plate from medial to lateral into the second and/or lesser metatarsals. This interfragmentary compression allows the surgeon to reduce the IM angle well as the plate essentially becomes an excellent reduction tool acting similar to a large washer. The construct should be checked under fluoroscopy to confirm adequate reduction.

Attention is directed to the lateral aspect of the calcaneus where a small stab incision is made in the resting skin line that is posteroinferior to the sural nerve and the peroneal nerves. A Freer elevator is inserted in the incision, freeing the periosteum medially and laterally, exposing the lateral wall of the calcaneus. A 3.5-mm drill was used to penetrate the lateral cortex. With this done, a curette is inserted into the calcaneus, allowing for harvesting of cancellous bone from the lateral aspect of the calcaneus (53).

The dorsal gap of the tarsal–metatarsal is packed tightly with autogenous bone graft and serves as a shear strain–relieved bone graft (52,54). The construct is checked under fluoroscopy and the wound is closed with typical deep and skin wound sutures.

The postoperative course is dictated by the construct. It has been the experience of the authors to keep patients with the three solid cortical screw technique non-weight-bearing in a below the knee cast for 2 weeks, followed by 4 to 6 weeks of full weight-bearing in a protective fracture boot with a sound AO construct (55). The authors are encouraged with the results and believe that in the future it may be possible to allow for immediate full weight-bearing in a protective fracture boot. When utilizing a interfragmentary compression screw along with a medial locking plate, it has been the experience of the authors to allow immediate and full weight-bearing in a protective fracture boot.

PEARLS, TIPS, PITFALLS

During clinical assessment, it is important to assess mobility of the first metatarsocuneiform joint in the sagittal, frontal, and transverse planes. While sagittal plane range of motion

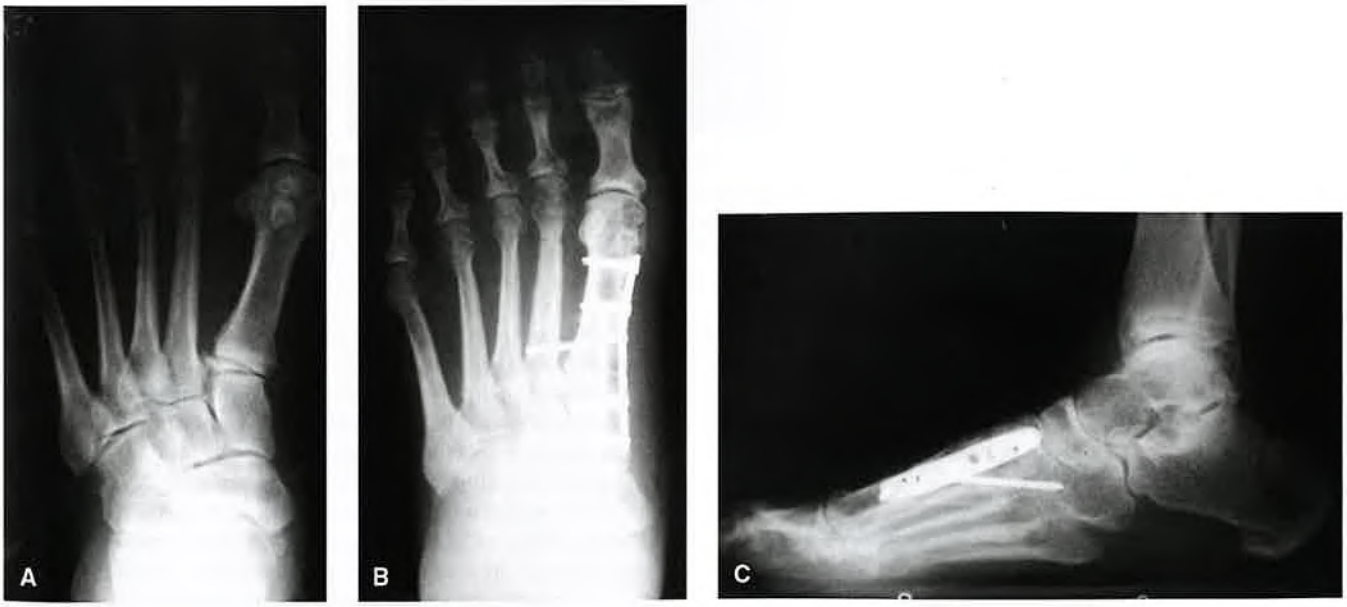

Figure 31.8 **A:** Preoperative radiograph with a HAV deformity. **B,C:** Postoperative radiographs demonstrating the use of an interfragmentary screw with a locking plate. Please note the restoration of anatomical alignment.

Figure 31.9 **A,B:** Preoperative radiograph and clinical photo of a patient with HAV deformity. **C,D:** Postoperative radiograph and clinical photo of the patient with the use of an interfragmental compression screw and a medial based locking plate. The correction can be seen in all three planes.

is typically tested, transverse and frontal plane motion is often overlooked. The use of the first ray splay test is a relevant method to determine if transverse plane hypermobility needs to be addressed. The foot is positioned with the subtalar joint and midtarsal joint in neutral, and direct transverse plane pressure is applied with the thumb and index finger to the first and second metatarsal heads. If hypermobility is demonstrated, with the addition of fixation between the first and second metatarsals, a first metatarsal base–second metatarsal base arthrodesis may be advocated (56). Unfortunately, to the best of the author's knowledge, there is no known preoperative frontal plane motion stress test. Intraoperatively, the authors have been able to demonstrate the dynamic changes in the frontal plane of the first metatarsophalangeal joint. Once the ligamentous structures of the tarsal–metatarsal joint is free of soft tissue attachments, rotation of the first metatarsal from a valgus position in the direction of varus and into a neutral position can demonstrate the frontal plane motion associated with the pathological hallux valgus deformity.

While performing the procedure, it is vital that the entire plantar ledge of the metatarsal base and medial cuneiform are removed in entirety. If a plantar ledge remains following the osteotomy, correction will be impeded as proper placement and compression across the arthrodesis site will not be achieved. A transverse capsulotomy has also been advocated at the joint to decrease periosteal stripping (45).

Bone grafting has been heavily used in this procedure both for maintenance of length of the first ray as well as to aid in arthrodesis to prevent delayed and nonunions. Historically, cancellous bone harvested percutaneously from the calcaneus, tricortical grafts from the iliac crest as well as the medial eminence from the first metatarsal head have been successfully used as grafting material (6,7,57,58). If grafting is not performed, the surgeon should consider plantarflexing the metatarsal to accommodate for the shortening; however, caution is advised as it has been reported that a 3-mm wedge resection results in approximately 1 cm of plantarflexion (4,59).

Concomitant deformities and biomechanical abnormalities need to be addressed when performing this procedure, such as equinus (48). If other deformities are not corrected biomechanical compensations may occur that hinder the primary surgical correction (60). Early protective weight-bearing status starting at 2 weeks postoperatively has been successful when 3 points of fixation or locking plates are used (55,61,62). The authors advocate the use of a homerun screw, a fully threaded cortical screw inserted with AO standard lag technique oriented from dorsal distal to proximal plantar from the first metatarsal base to the medial cuneiform (52). The second screw, a fully threaded 4-mm cortical screw, is then inserted with AO standard lag technique perpendicular to the homerun screw, which is driven into the base of the second metatarsal to increase reduction of the first to second IM angle. The third screw, another 4-mm fully threaded cortical screw, is inserted with standard AO lag technique oriented across the first metatarsal–cuneiform joint from proximal dorsal lateral to distal plantar lateral and should cross with the homerun screw. The authors allow for early postoperative weight-bearing at 2 weeks when using this technique. This early weight-bearing may decrease incidence of deep venous thrombosis, decrease morbidity to the patient, and improve function following the surgical procedure.

In order to achieve a favorable outcome, the surgeon must spend most of his or her time obtaining good anatomical alignment, joint preparation as well as creating a rigid construct with good fixation.

COMPLICATIONS

Significant shortening of the first metatarsal can be a complication of the Lapidus procedure. Shortening of the first metatarsal can lead to transfer lesions plantar to the second metatarsal head as well as decreased hallux purchase. Current grafting techniques and proper positioning of the metatarsal during arthrodesis have made this a less common encountered complication.

Delayed unions and nonunions should be noted as complications, with delayed unions occurring more frequently in literature (63). Nonunions have had a reported incidence of up to 12% following first metatarsal–cuneiform arthrodesis (29). Grafting of the prepared joint surface and advanced internal fixation techniques of 3-point fixation and locking plates have significantly decreased the rate of delayed unions and nonunions. Nonunions have been reduced to reports of 0% (7).

Malunions associated with the procedure can be avoided with intraoperative radiographs to establish correct positioning in all three planes of motion. A malunion in an elevatus position of the first ray may give rise to a dorsal bunion, decreased range of motion, and decreased purchase of the first ray, which could lead to transfer metatarsalgia (17). Likewise, care must be taken to not plantarflex the first ray as sesamoiditis could result. Overcorrection and undercorrection are also encountered.

Although the authors do not advocate it for this procedure, if a traditional lateral first metatarsal interspace release is performed, hallux varus is a possible complication. This is a complication that can accompany any procedure that uses the lateral release.

Hardware failure can result from improper placement and/or unsuitable techniques. In cases of hardware failure, subsequent surgery to remove the hardware is performed.

Neuritis, while uncommon, can be encountered with the close proximity of the medial dorsal cutaneous nerve to the surgical site. Depending upon dissection techniques and incision planning, the saphenous nerve may be involved as well as the deep peroneal nerve of the first interspace (17,27,46). Cases of complex regional pain syndrome status past surgery have been reported (63).

REFERENCES

1. Albrecht GH. The pathology and treatment of hallux valgus (Russian). *Russk Vrach* 1911;10:14–19.
2. Truslow W. Metatarsus primus varus or hallux valgus. *J Bone Joint Surg* 1925;7:98–108.
3. Lapidus PW. Operative correction of the metatarsus varus primus in hallux valgus. *J Surg Gynecol Obstet* 1930;58:183–191.
4. Chang T, Ruch J. Lapidus arthrodesis A different perspective. *J Am Podiatr Med Assoc* 1994;6:281–288.
5. Hofbauer M, Grossman J. The Lapidus procedure. Clin Podiatr Med Surg 1996;3:485–496.
6. Sangeorzan B, Hansen S. Modified Lapidus procedure for hallux valgus. *Foot Ankle* 1989;6:262–266.
7. Butson ARC. A modification of the Lapidus operation for hallux valgus. *J Bone Joint Surg* 1980;62B:350–352.
8. Bacardi BE, Boysen TJ. Considerations for the Lapidus operation. *J Foot Surg* 1986;25:138.
9. Hernandez A, Hernandez PA. Lapidus: when and why?. *Clin Podiatr Med Surg* 1989;6:197.
10. Mauldin DM, Sanders M, Whitmer WW. Correction of hallux valgus with metatarsocuneiform stabilization. *Foot Ankle* 1990;11:57
11. Myerson M. Metatarsocuneiform arthrodesis for treatment of hallux valgus and metatarsus primus varus. *Orthopedics* 1990;13:1050.
12. Neylon T, Johnson B, Laroche R. Use of the Lapidus bunionectomy in first ray insufficiency. *Clin Podiatr Med Surg* 2001;2:365–375.
13. Root ML, Orien WP, Weed JH. Muscle function of the foot during locomotion. In: Root ML, O'Rien WOP, Weed JH, eds. *Clinical biomechanics*, vol 2. Los Angeles, CA: Clinical Biomechanics Corporation, 1977.
14. Root ML, Orien WP, Weed JH, et al. Technique for the examination of the first ray. In: Root SA, ed. *Biomechanical examination of the foot*, vol 1. Los Angeles, CA: Clinical Biomechanics, 1971:80–87.
15. Bednarz PA, Manoli A. Modified Lapidus procedure for the treatment of hypermobile hallux valgus. *Foot Ankle* Int 2000;10:816–821.
16. Roukis TS, Landsman AS. Hypermobility of the first ray: a critical review of the literature. *J Foot Ankle Surg* 2003;6:377–390.
17. Myerson M, Allon S, McGarvey W. Metatarsocuneiform arthrodesis for management of hallux valgus and metatarsus primus varus. *Foot Ankle* 1992;13:107–115.
18. Klaue K, Hansen ST, Masquelet AC. Clinical, quantitative assessment of first tarsometatarsal mobility in the sagittal plane and its relation to hallux valgus deformity. *Foot Ankle Int* 1994;15:9–13.
19. Lapidus PW. The author's bunion operation from 1931 to 1959. *Clin Orthop* 1960;16:119–135.
20. Romash MM, Fugate D, Yanklowit B. Passive motion of the first metatarsal cuneiform joint: Preoperative assessment. *Foot Ankle* 1990;10:293–299.
21. Catanzariti AR, Mendecino RW, Lee MS, et al. The modified Lapidus arthrodesis: a retrospective analysis. *J Foot Ankle Surg* 1999;38:322–332.
22. Grace D, Delmonte R, Catanzariti AR, et al. Modified Lapidus arthrodesis for adolescent hallux abducto valgus. *J Foot Ankle Surg* 1999;38:8–13.
23. Rutherford RL. The misuse of the Lapidus procedure [letter]. *J Foot Ankle Surg* 1997;36:74–76.
24. Goldner JL, Gaines R. Adult and juvenile hallux valgus: analysis and treatment. *Orthop Clin* 1976;7:863–887.
25. Piggot H. The natural history of hallux valgus in adolescent and early adult life. *J Bone Joint Surg Br* 1960;42-B:749–760.
26. Vyas S, Conduah A, Vyas N, et al. The role of the first metatarsocuneiform joint in juvenile hallux valgus. *J Pediatr Orthop* B 2010;5:399–402.
27. Clarke HR, Veith RG, Hansen ST. Adolescent bunions treated by the modified Lapidus procedure. *Bull Hosp Jt Dis Orthop Inst* 1987;47:109–122.
28. Scranton PE, Zuckerman JD. Bunion surgery in adolescents: results of surgical treatment. *J Pediatr Orthop* 1984;4:39–43.
29. Saffo G, Desnoyers R, Wooster M, et al. First metatarsocuneiform joint arthrodesis: a five year retrospective analysis. *J Foot Surg* 1989;5:459–465.
30. McCrea J, Lichty T. The first metatarsocuneiform articulation and its relationship to metatarsus primus adductus. *J Am Podiatr Assoc* 1979;12:700–706.

31. Haas Z. Maintenance of correction of first metatarsal closing base wedge osteotomies versus modified Lapidus arthrodesis for moderate to severe hallux valgus deformity. *J Foot Ankle* Surg 2007;5:358–365.
32. Cooper A, Clifford P, Parikh V, et al. Instability of the first metatarsal-cuneiform joint: diagnosis and discussion of an independent pain generator in the foot. *Foot Ankle Int* 2009;10:928–932.
33. Morton DJ. Evolution of the longitudinal arch of the human foot. *J Bone Joint Surg* 1924;6:56–90.
34. Morton DJ. Hypermobility of the first metatarsal bone. Bone Joint Surg 1928;10:187–196.
35. Morton DJ. Structural factors in static disorders of the foot. *Am Surg* 1930;9:315–328.
36. Morton DJ. *The human foot: Its evolution, physiology and functional disorders.* New York, NY: Columbia University Press, 1935.
37. Morton DJ. Metatarsus atavicus, the identification of a distinctive type of foot disorder. *J Bone Joint Surg* 1927;9:531–544.
38. Catanzariti AR. First metatarsocuneiform joint arthrodesis. In: Marcinko DE, ed. *Comprehensive textbook of hallux abducto valgus reconstruction.* St. Louis, MO: Mosby-Yearbook, 1992
39. Bierman RA, Christensen JC, Johnson CH. Biomechanics of the first ray. Part III. Consequences of Lapidus arthrodesis on peroneus longus function: a three-dimensional kinematic analysis in a cadaver model. *J Foot Ankle Surg* 2001;3:125–131.
40. Avino A, Patel S, Hamilton G, et al. The effect of the Lapidus arthrodesis on the medial longitudinal arch: A radiographic review. *J Foot Ankle Surg* 2008;6:510–514.
41. Logel KJ, Parks BG, Schon L. Calcaneocuboid distraction arthrodesis and first metatarsocuneiform arthrodesis for correction of acquired flatfoot deformity in a cadaver model. *Foot Ankle Int* 2007;4:435–440.
42. Frankel J, Larsen D. The misuse of the Lapidus procedure: re-evaluation of the preoperative criteria. *J Foot Ankle Surg* 1996;4:355–361.
43. Catanzariti AR. Modified medial column arthrodesis. *J Foot Anhle Surg* 1993;2:180–188.
44. Coetzee JC, Resig SG, Kuskowski M, et al. The Lapidus procedure as salvage after failed surgical treatment of hallux valgus. Surgical technique. *J Bone Joint Surg Am* 2004;86-A:30–36.
45. Mote GA, Yarmel D, Treaster A. First metatarsal-cuneiform arthrodesis for the treatment of first ray pathology: a technical guide. *J Foot Ankle Surg* 2009;5:593–601.
46. Catanzariti AR, Blitch EL. Metatarsal cuneiform procedures. In: Banks AS, Downey MS, Martin DE, et al., eds. *McGlamry's comprehensive textbook of foot and ankle surgery,* 3rd ed. Philadelphia, PA: Lippincott Williams & Wilkins, 2001:544–556.
47. Coughlin MJ, Mann RA. Hallux valgus. In: Coughlin MJ, Mann RA, Saltzman CL, eds. *Surgery of the foot and ankle,* 8th ed. Philadelphia, PA: Mosby Elsevier, 2007:183–362.
48. Barvarian B, Briskin GB, Burns P. Lapidus bunionectomy: arthrodesis of the first metatarsocuneiform joint. *Clin Podiatr Med Surg* 2004;21:97–111.
49. Fuhrmann RA. Arthrodesis of the first tarsometatarsal joint for correction of the advanced splayfoot accompanied by a hallux valgus. *Oper Orthop Traumat* 2005;2:195–210.
50. Hansen ST, MD, oral communication.
51. Manoli A, Hansen ST. Screw hole preparation in foot surgery. *Foot Ankle Int* 1990;11:105–106.
52. Hansen ST, ed. *Functional reconstruction of the foot and ankle,* 1st ed. Philadelphia, PA: Lippincott Williams & Wilkins, 2000.
53. DiDomenico LA, Haro AA. Percutaneous harvest of calcaneal bone graft. *J Foot Ankle Surg* 2006;2:131–133.
54. Perren SM. Physical and biological aspects of fracture healing with special reference to internal fixation. *Clin Orthop Relat Res* 1979;(138):175–196.
55. Blitz NM, Lee T, Williams K, et al. Early weight bearing after modified Lapidus arthrodesis: a multicenter review of 80 cases. *J Foot Ankle Surg* 2010;49:357–362.
56. Weber AK, Hatch DJ, Jensen JL. Use of the first ray splay test to assess transverse plane instability before first metatarsocuneiform fusion. *J Foot Ankle Surg* 2004;4:278–282.
57. Giannestras N. In: Giannestras N, ed. *Foot disorders: medical and surgical management.* Philadelphia, PA: Lea & Febiger, 1973.
58. Ruch JA, Chang TJ. Relative strengths and efficacy of fixation techniques in osteotomies and arthrodesis of the first metatarsal. In: Ruch JA, Vickers NS, eds. *Reconstructive surgery of the foot and leg-update 1992.* Tucker, GA: Podiatry Institute, Inc, 1992:233–235.
59. Thompson IM, Bohay DR, Anderson JG. Fusion rate of first tarsometatarsal arthrodesis in the modified Lapidus procedure and flatfoot reconstruction. *Foot Ankle Int* 2005;698–703.
60. DiDomenico LA, Adams HB, Garchar D. Gastrocnemius recession for the treatment of gastrocnemius recession. *J Am Podiatr Med Assoc* 2005;95(4):410–413.
61. Basile P, Cook EA, Cook JJ. Immediate weight bearing following modified Lapidus arthrodesis. *J Foot Ankle Surg* 2010;49:459–464.
62. Sorensen MD, Hyer CF, Berler GC. Results of Lapidus and locked plating with early weight bearing. *Foot Ankle Spec* 2009;2:227–233.
63. Rink-Brune O. Lapidus arthrodesis for management of hallux valgus—a retrospective review of 106 cases. *J Foot Ankle Surg* 2004;43(5):290–295.

CHAPTER

34

John V. Vanore
William G. Montross
A. Louis Jimenez
Jonnica S. Dozier

First Metatarsophalangeal Joint Arthroplasty

First metatarsophalangeal joint (MTPJ) arthroplasty is primarily performed today as a resectional arthroplasty with or without use of a joint implant. Resection arthroplasty without an implant usually involves remodeling of the first metatarsal head with resection of the base the proximal phalanx, that is, the Keller arthroplasty (1–3). Implant arthroplasty predominantly with the use of silicone-type interpositional devices became very popular in the 1970s (4–9) but suffered a decline in usage in the 1980s with reports of complications associated with silicone detritus (10–21). Hinge silicone implants and two-component metallic/polymer joint implants followed (6,22–30). Silicone was still a politically incorrect material mainly due to the breast implant crisis of the 1990s, and two-component total joint systems never really achieved widespread clinical usage (31). As a result, there were surgeons who favored simple resection arthroplasty or arthrodesis versus implant arthroplasty (32–36).

Implant arthroplasty may involve relatively simple interpositional devices such as the metallic hemi- or double-stem silicone hinge implants or multicomponent total joint replacement (TJR) systems. In past editions, the history and evolution of implant systems have been discussed extensively. The reader is referred to earlier editions for further information in this regard (37–39). One relative newcomer to implant arthroplasty is the attempt to address the first metatarsal independently. Hemiarthroplasty of the first metatarsal was initially attempted by Swanson and Joplin among others, but long-term implant instability limited continued use. This has also been somewhat problematic with two-component arthroplasty with loosening leading to implant instability, migration, bone resorption, and pain. In 2005, a metallic cap was introduced to address first MTPJ arthrosis with resurfacing of the first metatarsal head, the Toe HemiCAP (ArthroSurface Inc., Franklin, MA). This concept has been utilized in larger joints such as the shoulder, hip, and knee and subsequently applied to the first metatarsal. Several literature reports show the procedure to be of value in patients with hallux rigidus (40–42). More recently, several metatarsal implants has been introduced, the MOVEMENT system (Ascension Orthopedics Inc., Austin, TX) and EnCompass (OsteoMed Inc., Dallas, TX) metatarsal resurfacing implant. These implants attempt to address surgical observations that most degenerative changes at the first MTPJ involve the metatarsal head.

INDICATIONS AND CONTRAINDICATIONS

Indications for implant arthroplasty are painful arthritic joints that are deemed to be nonsalvageable with joint preservation techniques (31,34,43). This may be subdivided:

- Degenerative arthrosis of first MTPJ
  - Hallux rigidus
  - Hallux valgus
  - Postsurgical arthrosis and/or chronic joint pain
- Arthrosis of first MTPJ secondary to arthritides, for example, rheumatoid arthritis
- Posttraumatic arthrosis

Patients should be evaluated regarding pathologic indications for implant arthroplasty as well as for alternative surgical procedures including cheilectomy with or without joint preservation–type osteotomy, resection arthroplasty, and first MTPJ arthrodesis. Cartilage replacement or osteochondral autologous transplantation (OATS)-type procedure for repair of excoriated articular surfaces is also an alternative utilizing synthetic, autogenous, or allograft (44). Contraindications to implant arthroplasty would include poor bone stock, poor soft tissue coverage, and joint infection or osteomyelitis. This is of particular importance in the patient with rheumatoid arthritis or gout who may possess poor bone stock that will not retain the implant very well. Patients should be informed that any implant arthroplasty may require revision including removal of the implant.

The general indications for usage of implant arthroplasty (Table 34.1) have changed little over the past three decades, but patient selection has become more stringent. (8,31,37,45) Implant arthroplasty, be it interpositional or a joint replacement procedure, is a joint destructive procedure. As such, surgeons must carefully assess each patient for alternatives (Table 34.2), not only for implant arthroplasty but also for joint preservation whenever possible, particularly in younger, more active patients. It has been suggested that TJR may be appropriate for younger patients requiring a joint destructive procedure (45,46). This is a recommendation not based on studies as the present literature does not document the superiority of any particular procedure over another particularly in the younger patient except for maybe joint fusion.

PREOPERATIVE CONSIDERATIONS

The main indication for implant arthroplasty is hallux rigidus in patients, maybe more so in females, who wish to retain a range of motion (ROM). Generally, first MTPJ fusion is preferable in younger male individuals, where durability is a main consideration. First MTPJ fusion may also be preferred to implant arthroplasty in patients with large degrees of deformity, which may occur in severe or end-stage hallux valgus. At one point, double-stem implant arthroplasty was the preferred technique

TABLE 34.1 Indications for Implant Arthroplasty

Hallux rigidus—late stage III, stage IV
Hallux valgus with degenerative arthritis
Rheumatoid arthritis
Revisionary first MPJ surgery with joint arthrosis or osseous deficit
Traumatic arthritis

TABLE 34.2 Joint Destructive Alternatives

Resection arthroplasty
Interpositional implant arthroplasty
Hemimetal
Hinged silicone
Total joint replacement
Arthrodesis

in patients undergoing rheumatoid reconstruction or forefoot arthroplasty (47–49). This has largely been supplanted by first MTPJ fusion due to the stability and long term maintenance of correction that this imparts.

Several types of implant arthroplasty may be chosen, including hemimetallic implant arthroplasty, double-stem hinge silicone arthroplasty, or multicomponent TJR. Each of these implants systems will be discussed. Finally, resection arthroplasty will be revisited as an alternative to arthrodesis or implant arthroplasty. Resection arthroplasty is probably best limited to older individuals with a stable hallux interphalangeal joint (IPJ).

RESECTIONAL ARTHROPLASTY

Resectional or excisional arthroplasty has been a traditional surgical treatment for first MTPJ pathology (50–58). Earlier methods involved first metatarsal head resection with or without excision of the sesamoid apparatus; however, these methods, over time, proved to yield suboptimal results (50,54,59). In 1886, Riedel described the resection of the base of the proximal phalanx and exostectomy of the head of the first metatarsal for the treatment of hallux valgus as an alternative procedure to avoid the deleterious sequelae of first metatarsal head resection (57,60). In 1887, the article "Contraction of the Metatarsophalangeal joint of the Great Toe," by Davies-Colley (56) followed the same technique employed for the treatment of "hallux flexus." In 1904, United States Army Captain William L. Keller popularized the surgical technique initially described by Riedel (50,60,61). Keller's name has since become synonymous with the procedure (57,60).

In Keller's (3) 1904 article, the surgical technique was employed as treatment for painful bunions and hallux valgus, regardless of the patient's age or activity. Keller observed the alleviation of pain about the first MTPJ without disrupting the "tripod" structure of the foot during locomotion. Long-term follow-up demonstrated that the Keller procedure created biomechanical impairment of first MTPJ, which resulted in unfavorable outcomes in the younger and/or active population (54,55,59,62,63). As improvements in surgical techniques evolved and the use of rigid internal fixation became a mainstay in foot and ankle surgery, the Keller lost popularity (57,59,-64–67). As a result, guidelines have been established to specify which metatarsal osteotomy is appropriate for the patient based on age, activity, bone density, and radiographic findings. The Keller procedure is advocated in elderly patients with increased first intermetatarsal (IM) angles and poor bone stock, limited gait requirements, circulatory compromise, severe first MTPJ degenerative joint disease, infection, or osteomyelitis of the first MTPJ, metabolic diseases such as gout, and reconstruction of the first MTPJ status postsurgical and traumatic intervention (59,63,64). Ideally, the Keller procedure will decrease pain, improve ROM, decrease first IM angle, decrease hallux abductus angle and/or valgus rotation, decrease heloma molle formation between the hallux and second digit, increase the gait pattern, and allow for a greater variety of shoe gear. The ultimate goal is to improve the patient's lifestyle without subjecting him to an extended and restrictive postoperative course.

Historically, morbidities associated with the Keller bunionectomy included hallux extensus, degenerative joint disease of the first MTPJ, lesser metatarsalgia, apropulsive gait, dorsal hallux irritation, hallux frontal plane rotation pathologies, a shortened hallux, and cosmetic problems (Fig. 34.1) (54,58,59,61,63,68). The above-mentioned complications are most often a result of too little or too much osseous resection, inadequate muscle-tendon balancing, and/or insufficient soft tissue interposition (54,60,61,69).

Improvements in techniques and indications have led to the metamorphosis of the Keller, which include EHL tendon lengthening when indicated, capsular interposition, Kirschner wire (K-wire) stabilization, decreasing the amount of osseous resection from the proximal phalanx, stabilization of flexor hallucis brevis and/or longus to the base of the proximal phalanx, and angling the osseous resection of the proximal phalanx (57,58,63,65,67,68,70–72). These improvements have led to more favorable results.

In a retrospective study, conducted by Henry and Waugh (73), Harris-Beath foot printing pads were utilized to assess the

Figure 34.1 Hallux extensus of the first MTPJ. Patient had discomfort over the IPJ dorsally and the hallux impinged the second digit.

weight-bearing ability of the hallux in 47 feet with a minimum 3-year follow-up. The study reported 18% of the feet demonstrating weight-bearing ability of the hallux when less than two-thirds of the proximal phalanx remained and 74% when approximately two-thirds of the proximal phalanx remained. The authors conclude that toe purchase was proportional to osseous resection of the proximal phalanx. The results from the study clarified Bonney et al's (59) speculation that one-third to one-half was the optimal amount of bone resection from the proximal phalanx. Henry and Waugh also noted satisfactory results when the preoperative hallux abductus angle was less than 30 degrees, suggesting the Keller procedure would not innocuously correct the deformity without taking a substantial amount of bone (>33%) (73).

During late stance and toe-off phase of gait the flexor hallucis brevis and longus stabilize the hallux against the first metatarsal head in preparation for propulsion (74). Should one of these tendons lose their function, stabilization of the hallux and its ability to resist ground reactive forces will be altered (74). When the base of the proximal phalanx is resected, the insertions of the flexor hallucis brevis may be attenuated or sacrificed (60). Failure to preserve or reattach the flexor hallucis brevis may result in hallux malleus or "floating hallux" (74–76). Mroczek and Miller (77) rectified this potential complication by advocating an oblique resection of the base of the proximal phalanx, which preserves the insertions of the flexor hallucis brevis. The authors noted no occurrence of a "cocked-up" deformity in their patients. The flexor hallucis brevis tendons can also be reattached to the remaining proximal phalanx to achieve the same results as Mroczek and Miller's modification. In the situation where the flexor hallucis brevis cannot be reattached, due to nonmobile sesamoids or friable residual flexor hallucis brevis tendons, flexor hallucis longus can be utilized to maintain plantarflexion strength (60).

In 1962, Thomas (78) presented a study that compared arthroplasty of the first MTPJ via standard operation versus a modified arthroplasty with distractions of first MTPJ. Thomas noted with joint distraction, via intramedullary K-wire or external staple fixation, that normal tension was restored to the soft tissues, toe length was maintained, and less bone resection was required. This study concluded that patients were pleased and/or satisfied in 96% of the cases and dissatisfied in 4% of the cases, using either technique. Thomas summarizes his study as "the use of a distractor can be expected to produce an improved end result and aid postoperative wound healing."

Sherman et al (79), in 1984, reviewed 51 Keller procedures in 35 patients with a follow-up of a minimum of 1 year. The average age of the patients was 53 and all were females. They compared two groups: Group A, in which no K-wire was used nor purse stringing of the capsule was performed, and Group B, in which K-wires were inserted for 3 weeks in addition to capsular purse-stringing techniques. Subjective results were slightly better in Group A and the satisfaction rate between the two groups was not significant. They also measured the gap created after each surgical procedure and found that in Group A, the distance was 3 mm and in Group B it was 2.6 mm. Patients in Group B, which had the K-wire retrograded back through the IPJ and into the metatarsal head, were found to have more pain of the IPJ.

In a 2007 retrospective study with an average of 9.1 years, Reize et al (65) evaluated 118 feet with hallux valgus and hallux rigidus following Keller bunionectomies. Improvement in the postoperative ROM was observed when the aftertreatment consisted of K-wire distraction instead of an axial K-wire transfixation. The patients who underwent Keller-Brandes surgery for hallux valgus had less pain when the aftertreatment was carried out using an axial K-wire, while those operated on for hallux rigidus had less pain when the aftertreatment consisted of distraction.

Soft tissue interposition serves as a spacer between the proximal phalanx base and first metatarsal creating a nonpainful fibrous eschar (50,53,55,67,70). There are various forms and techniques for soft tissue interposition of the first MTPJ. These include capsular imbrication, purse-string/hour glass capsulorrhaphy, U, V flaps, etc. (Fig. 34.2) (50,53,67). Others include portions of rolled up tendon called an "anchovy" which can be fabricated from the

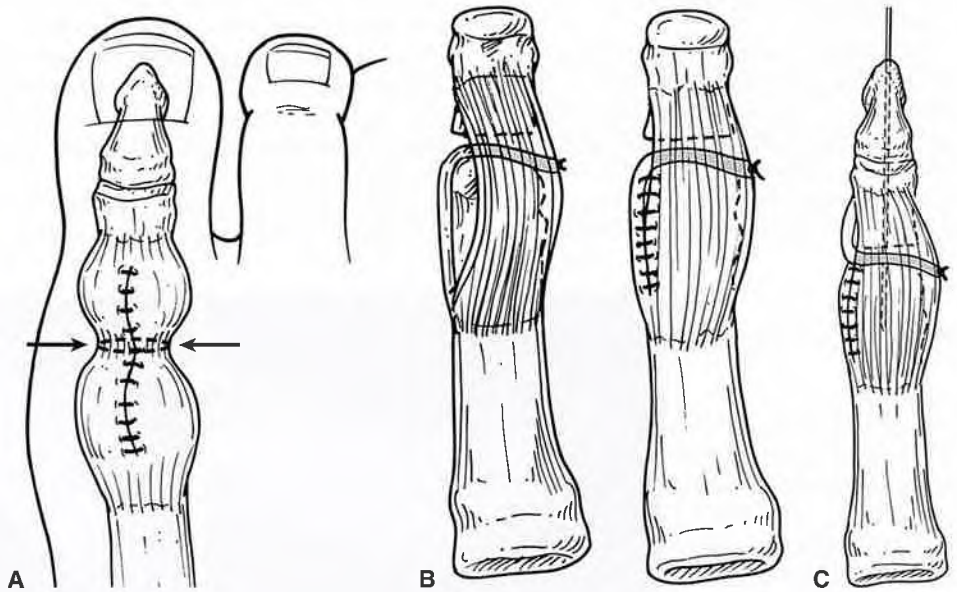

Figure 34.2 Diagrams demonstrating the hourglass (**A**), the proximally based U-flap (**B**), and distally placed U-flaps (**C**).

posterior tibial tendon, Achilles tendon, extensor hallucis brevis, extensor hallucis longus, etc. (55,71). More current techniques include the use of a dermal allograft to act as a spacer at the proximal phalanx—first metatarsal interface (50,71).

Technically, the U-shaped flap is the more simplistic to create. The surgeon has the option to maintain the base proximally on the metatarsal neck or distally at the metaphyseal–diaphyseal junction of the proximal phalanx. Fashioning a proximal flap is the technique most often employed by the authors since the capsular and periosteal attachments are thicker and less likely to tear on the metatarsal side. Conversely, Roukis et al (80) reported the use of a distally based flap, suggesting this would denervate the first metatarsal, thereby producing an analgesic effect about the first MTPJ. The rationale for this theory is based on a study by Cavalcante et al, which evaluated the innervation of mammalian joints demonstrating that joint capsules and their ligamentous supports are vastly supplied by free nerve endings (80,81). The study suggested that the areas of a joint, subject to the most compression, are the areas that are heavily innervated (80,81).

Kolker et al (71) reported on the use of acellular cadaver dermal matrix (ACDM) as a biologic spacer for soft tissue interposition. ACDM has been utilized in basal joint resection arthroplasty in monkeys to fill bony voids. Histologic evaluation demonstrated revascularization and fibroblastic proliferation filling the void with dense collagenous tissue. The authors hypothesized that using the ACDM as an anchovy and suturing it to the inner side of the capsule could attain similar results. In the presence of an atrophic or iatrogenically compromised capsule and/or periosteum, this alternative soft tissue interposition would be most beneficial.

SURGICAL TECHNIQUE

HEMIMETALLIC IMPLANT ARTHROPLASTY

Implants

Several implants are now available with a variance of features (Fig. 34.3), most are for the proximal phalanx. Today, the implants are generally a cobalt chrome or titanium metallic device with much thinner base dimensions versus their silicone predecessors. It is incumbent upon the surgeon to be thoroughly familiar with the implant system that is being used, including the instrumentation and sequential steps involved with insertion. This following discussion focuses on the Biopro hemi-implant (Biopro, Grand Rapids, MI) and its imitators (Fig. 34.4). They are manufactured of cobalt chromium with a thin, oval base and spade-like stem (31,82). More recently, a hemimetatarsal as well as phalangeal implant with an insertion technique more akin to a two-component arthroplasty has been introduced. The reader is referred to the total joint technique later in the chapter as these implants utilize an intramedullary guide wire with subsequent stepwise instrumentation. One of the unique features of this new implant is that dissection must provide generous exposure to allow for instrumentation as no bone resection is performed prior to reaming of the articular surface and subchondral bone.

Exposure

A dorsal medial approach to the first MTPJ medial to the tendon of extensor hallucis longus is generally preferred (Fig. 34.5). The incision extends from the midpoint of the first metatarsal over the MTPJ onto the great toe. In cases of hallux rigidus, limited subcutaneous dissection is necessary as the toe is generally straight and a subsequent capsulorraphy is limited. A lineal capsulotomy in line with initial skin incision medial to extensor hallucis longus is performed with initial subperiosteal dissection on the dorsal aspect of the first metatarsal but complete exposure of the base the proximal phalanx including its dorsal, medial, and lateral aspects. Generally, additional first metatarsal exposure may be delayed until after resection of the base the proximal phalanx, which greatly assists in soft tissue laxity.

Bone Resection

Retractors provide soft tissue protection, and the articular surface of the base of the proximal phalanx may be resected with



Figure 34.3 **A:** Four metallic implants. The Swanson great toe implant (Wright Medial, Arlington, TN) was similar in design to his silicone hemi-implant with a thick base and large intramedullary stem. The Biopro implant (Biopro, Grand Rapids, MI) possesses a thin base with a simple spade-like stem, which requires no reaming. The KMI (Integra LifeSciences, Plainsboro, NJ) is a hybrid of the two previous implants with a thin base but a stem that requires intramedullary reaming. The Wright Medical LPT (Wright Medial, Arlington, TN) design possesses a thin ovoid base with a suture hole for optional reattachment of the flexor apparatus and a tri-fin stem. Each implant is accompanied by a complete set of instrumentation utilized for proper insertion. **B:** Instrumentation for the KMI hemi-phalanx implant.



Figure 34.4 **A:** The Biopro implant (Biopro, Grand Rapids, MI) comes in four sizes with or without a plasma sprayed titanium coating on the stem and back of the implant, **B:** The instrumentation provides a sizer, trial implants, spade broach, and tamp to impact the implant.

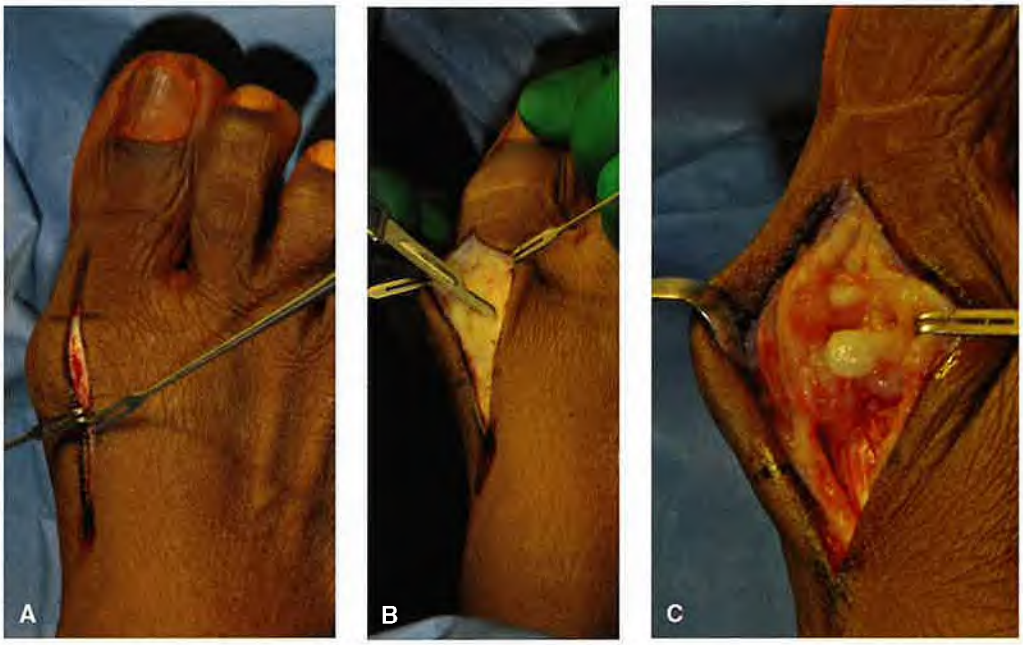

Figure 34.5 Dorsomedial skin incision (**A**) is tented with skin hooks and dissection proceeds with reflection of skin and subcutaneous tissues medial and lateral (**B**). A lineal capsulotomy (**C**) allows for subperiosteal exposure that is continued on the distal first metatarsal and proximal proximal phalanx (**D**).

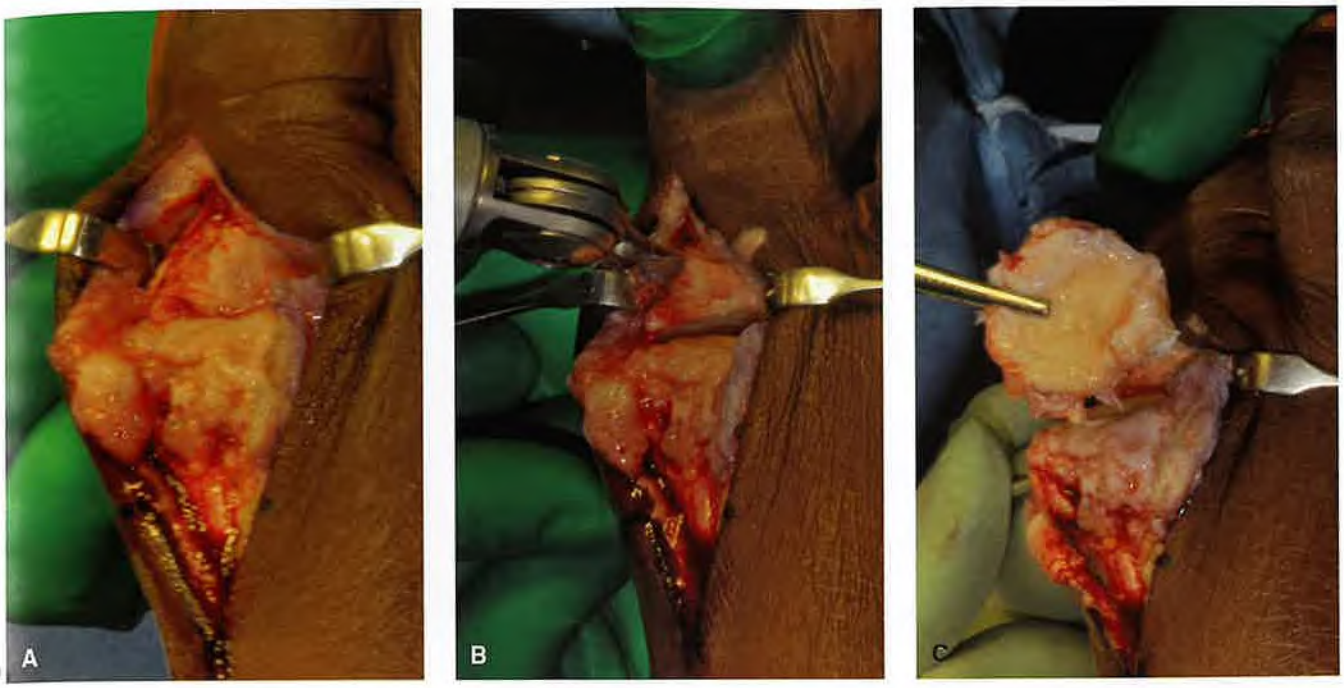

Figure 34.6 Ragnall retractors protect the skin, periosteal, and capsular tissues (**A**), while the articular surface is resected (**B**) using a sagittal saw parallel to the eponychial nail fold, which will allow rectus position of the hallux following insertion of the implant. **C:** Careful dissection of the resected base generally provides integrity of the plantar aponeurotic tissues.

a sagittal saw (Fig. 34.6). Enough bone needs to be resected to allow for good joint mobility postoperatively. This requires that bone resection is somewhat greater than the thickness of the phalangeal hemi-implant utilized. The Biopro hemi-implant is relatively thin and requires limited bone resection versus the older Swanson (Wright Medical, Arlington, TN) designs, which were very thick. Caution is also recommended regarding remodeling of the resected margins of proximal phalanx. As less bone is removed, the phalangeal stump may seem sharp but the surgeon is cautioned not to remodel the phalanx any further until after sizing is accomplished and the trial implant inserted. Much of this is obviated with the MOVEMENT System, wherein implantation does not require osteotomy. Resection of the articular surface and shortening if desired is accomplished by use of reamers.

Cheilectomy

Following resection of the base of the proximal phalanx, continued exposure of the distal first metatarsal may be accomplished (Fig. 34.7). This includes exposure of all periarticular proliferative osteophytosis, which must subsequently be resected. The author has found it helpful to create a slope or radius along the dorsal margin of the first metatarsal head, regardless of the hemiphalangeal implant utilized, to allow for good range of dorsiflexion following insertion of the implant. This bone is generally very dense and sclerotic due to the underlying degenerative joint disease and easily contoured with a saw and/or rotary bur.

Trial Implant

Each implant system provides for templates to assess the appropriate size of implant to be used (Fig. 34.8). Generally, this is accomplished with subsequent steps per the individual product guide. For the simplest implants, the sizer possesses a central hole through which a pick or guide pin may be inserted into the resected surface of the phalangeal base. Usually, a little more is required, and the appropriated-sized trial implant or sizer is inserted. The implant sizer is press-fit and adequacy of motion and bony resection assessed. If limitation of motion is observed, inspection of the MTPJ sesamoids is recommended and release performed as necessary. Assess the remodeling of the first metatarsal head. A broad flat first metatarsal head will not provide for good dorsiflexion and should be remodeled. At times, cheilectomy of the sesamoids may be performed. Caution, must be taken to prevent the margins of the implant extending beyond that of the bone as the implant may be palpable postoperatively and create symptoms wearing shoes.

Implant Insertion

Once the appropriate size implant has been selected, the implant is opened and made available to the surgeon. The trial implant is removed and copious irrigation is performed so as to remove all bone debris. It is often convenient at this time also to resect any excessive joint capsule or granulomatous synovium, which is often present in degenerative joint disease as well as rheumatoid situations. Prior to insertion of the implant, a spade-type instrument is included so that the surgeon may create a canal in the proximal phalanx for insertion of the implant stem (Fig. 34.9). It is very important that the instrument is inserted with the toe held in neutral axial rotation. It may be helpful to hold the base of the proximal phalanx steady with a bone forceps around the proximal portion of the proximal phalanx. The implant is then taken in hand and

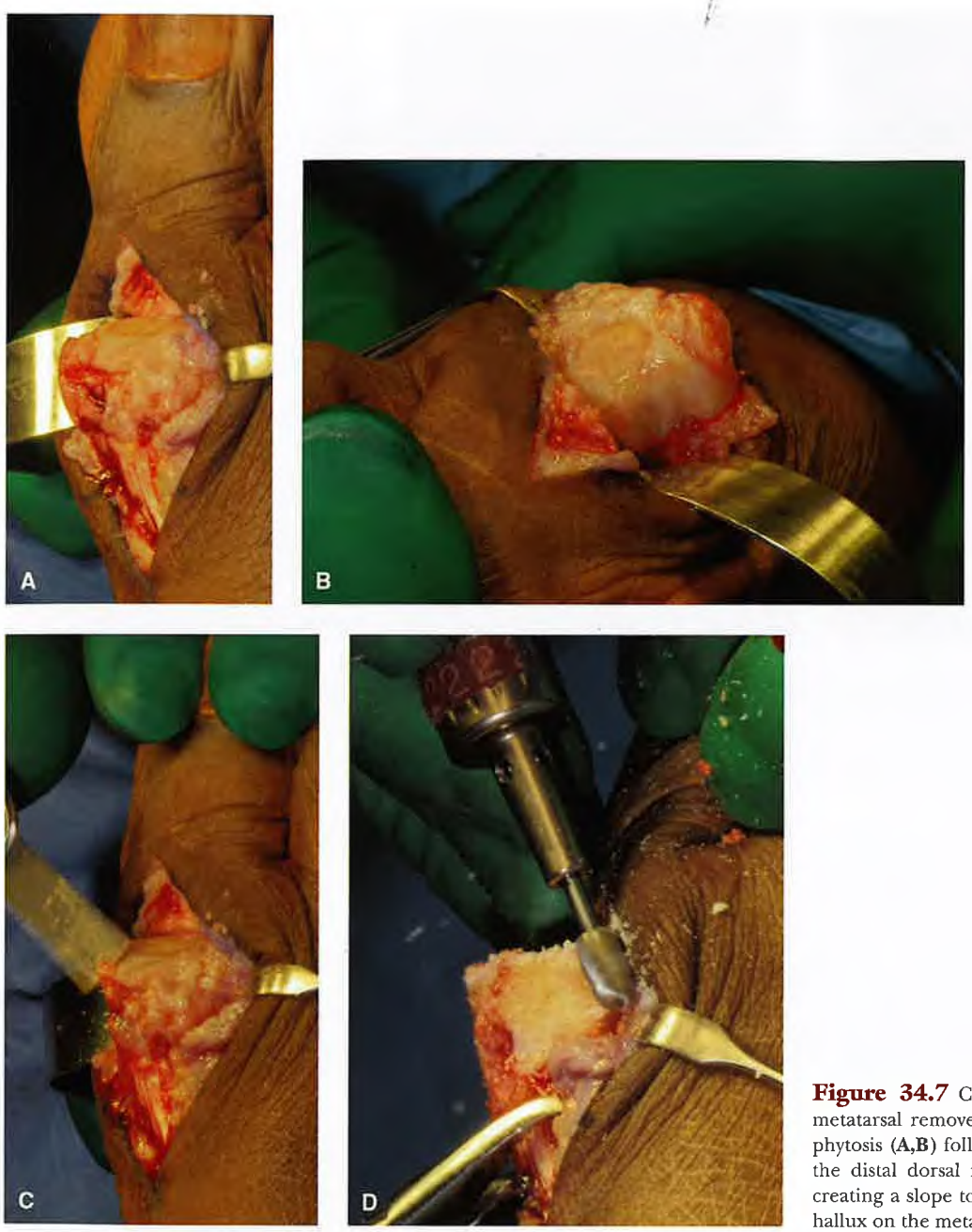

Figure 34.7 Cheilectomy of the first metatarsal removes the peripheral osteophytosis **(A,B)** followed by remodeling of the distal dorsal metatarsal head **(C,D)**, creating a slope to allow extension of the hallux on the metatarsal.

inserted within the cavity created for the stem in the proximal phalanx. A tamp is utilized with a mallet to completely oppose the implant with the resected portion of the proximal phalanx. Good solid bone impaction and stability of the implant should be achieved. Once again, irrigate the wound and place the toe through a ROM. The toe should sit in a straight and neutral position with little capsular influence. Generally, limited surgical dissection of the base of proximal phalanx will preserve the attachments of the flexor apparatus. If there are concerns of the surgeon, tethering of the long and short flexors may increase stability at the hallux IPJ. Several of the metallic great toe implants available today possess small holes within the implant that allow for repair and reattachment of the flexor apparatus.

Wound Closure

Once the implant has been inserted and a good ROM observed, closure of the wound may begin (Fig. 34.10). With a simple lineal capsulotomy and good subperiosteal dissection prior, wound closure is generally straightforward. The first MTPJ capsule is identified and reapproximated. Any excessive capsule may be excised. Generally, closure is performed with 2-0 Vicryl in the thickest portion of the capsule and 3-0 Vicryl in the remaining proximal and distal most portions. The author has not found any need for bone anchors or intraosseous soft tissue reattachments. Skin closure is generally performed with suture of surgeon's choice.

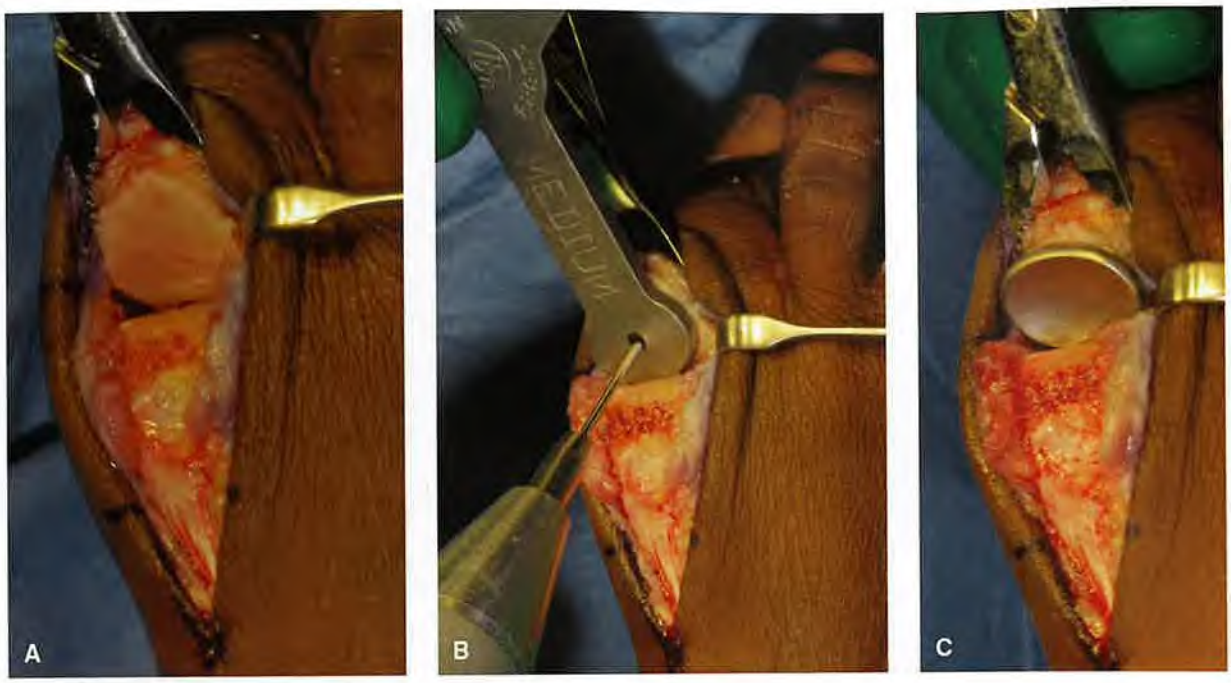

Figure 34.8 **A:** Visualize the resected surface of the proximal phalanx and compare the implant sizer to determine the appropriate size implant. **B:** The trial implant is a simple pointed 2-mm stem that may be press-fit into a central drill hole created with a 0.062-inch K-wire. **C:** Following placement of the trial implant, assess ROM and any bony prominences or excessive overhang of the implant surface itself (**D**).

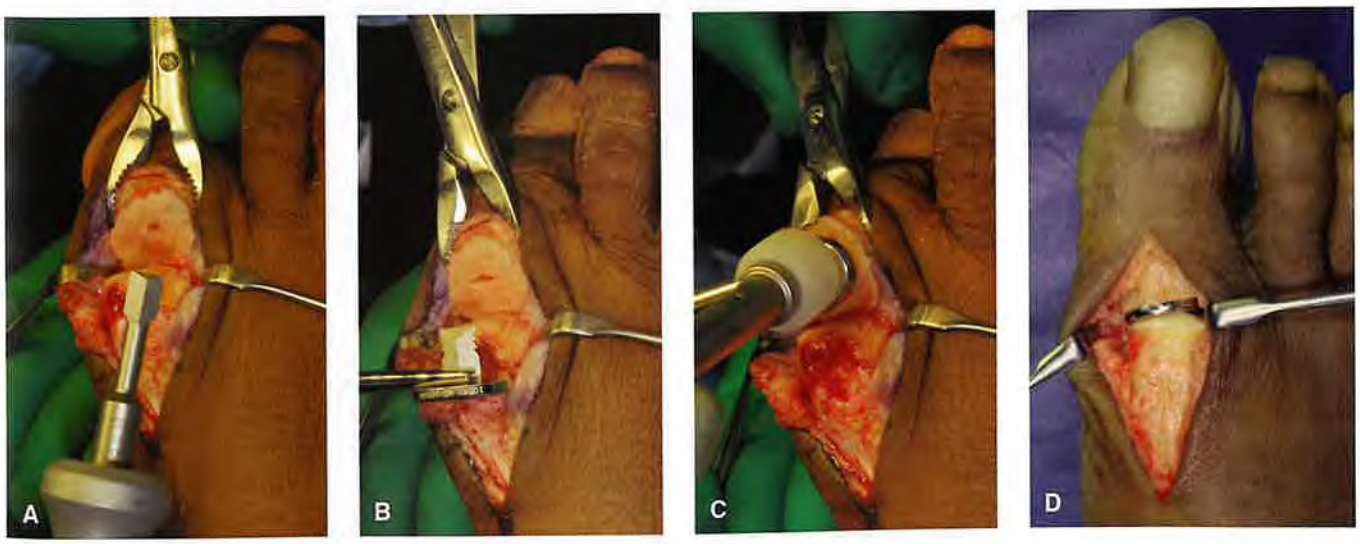

Figure 34.9 **A:** A spade-like hand instrument is used to impale and create the canal for the implant stem. The stem hole must be neutral to the frontal plane to avoid axial malalignment. The implant is then inserted (**B**) and tamped into place (**C**) flush with the underlying phalangeal bone surface (**D**).

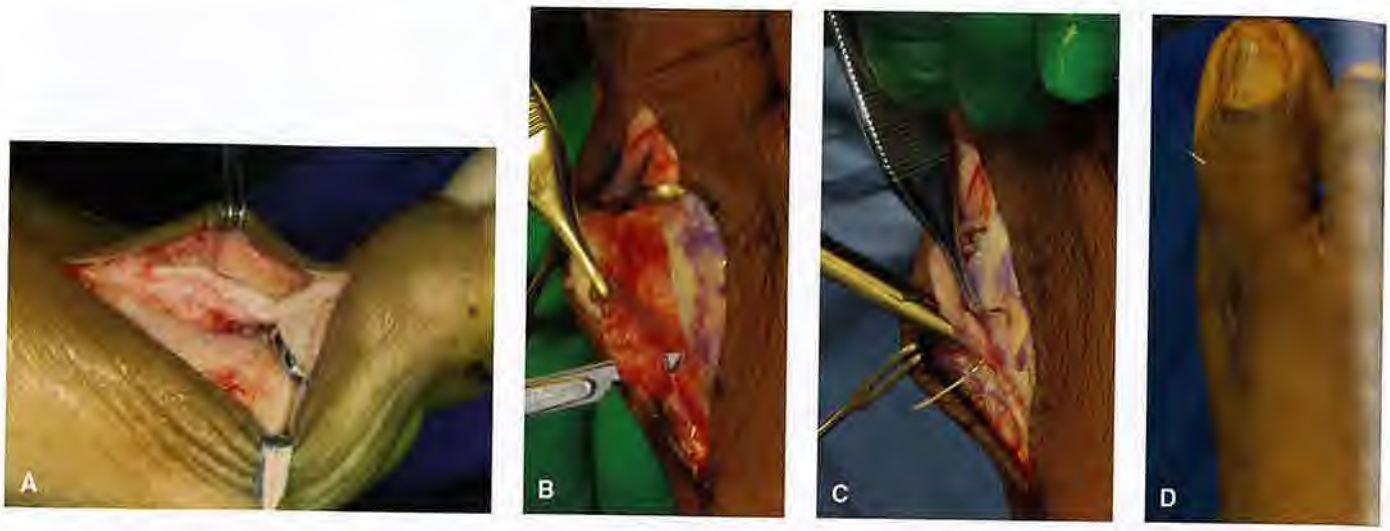

Figure 34.10 **A:** Check ROM prior to closure. **B:** Any synovitis or excessive capsular tissue may be excised. **C:** The wound is again irrigated and closure performed. **D:** Meticulous capsular closure with absorbable suture is followed by skin closure of the surgeon's choice.

HEMIMETATARSAL IMPLANT ARTHROPLASTY

Implants

Several metatarsal head implants are now available, the ArthroSurface HemiCap and the Ascension Orthopedics MOVEMENT metatarsal implants (Fig. 34.11) and the OsteoMed EnCompass. These designs recognize the intraoperative observations that the metatarsal head usually suffers the greater extent of the degenerative arthrosis in cases of hallux rigidus. These designs are more an attempt of resurfacing with limited resection of the metatarsal head.

Exposure Hemimetatarsal implant arthroplasty requires an exposure that is initially the same as any of the described arthroplasties, but attention now will be directed to the metatarsal head. Adequate exposure allows for visualization of the pathology and release of the MTP joint, which is generally necessary.

Cheilectomy

Once the joint is exposed, cheilectomy of the base of the proximal phalanx may be performed. Most surgeons typically employ a rongeur followed by a rotary bur to "clean up" the peripheral osteophytosis.

Implantation

Attention is now directed to the head of the metatarsal. The sizing guide is used to determine the size of the implant as well as acts as a guide for the guide pin. Pin placement should be confirmed via C-arm at this time. Extreme care should be taken so the implant is not placed too low to interfere with the sesamoids function and not too dorsal to contribute to continued jamming of the joint. The guide pin is inserted and sizing guide removed. A power reamer is placed over the guide pin and the articular surface is resected prior to any cheilectomy of the metatarsal. Once this is accomplished, a large drill is placed over the initial guide pin to enlarge the guide hole for proper press-fitting of the final metatarsal component. The guide pin is then removed and a saw guide for dorsal metatarsal resection then inserted. A chamfer cut of the dorsal metatarsal head is performed. The saw guide is removed and the appropriate-sized trial implant inserted. The surgeon must assess size and alignment. Now, any further cheilectomy of the metatarsal may now be performed as well as assessment of the sesamoids.

Implant Insertion

The trial implant is removed and copious irrigation is performed so as to remove all bone debris. Once the appropriate size implant has been selected, the implant is opened and made available to the surgeon. Tamps are provided for impacting the implant once partially inserted by hand. Good apposition of the dorsal angular portion as well as the undersurface of the perpendicular articular surface should be visualized. The joint is flushed and ROM is assessed. Note, that the actual implant is slightly larger than the trial to ensure a tight press fit.

Wound Closure

Closure of the wound is performed in layers per surgeon's preference with attention to capsular repair performed while holding the toe in a straight and neutral position.

Surgical Tips

- Readers are directed to the individual implant technique guides for a fuller and more exact surgical technique for the particular implant chosen. Another implant design, the ArthroSurface HemiCap, requires a variant of the described technique as this implant requires a screw-in taper post as a tray to hold an articular component.
- At times, metatarsus primus elevates is a distinct component hallux rigidus and may require osteotomy or first metatarsal–cuneiform arthrodesis. Combination of phalangeal implant arthroplasty with a proximal procedure to may be

Figure 34.11 This 58-year-old woman presented with a painful right foot with symptomatic hallux rigidus. **A,B:** Periarticular lipping with joint space narrowing is apparent on preoperative radiographs. **C,D:** Postoperatively, the implant shows good alignment in all planes; note the appearance of the stem placed centrally within medullary canal without any rotation.

an option. Hallux rigidus usually involves an equinus position of the first MTPJ. This may appear radiographically as a positional elevatus of the first metatarsal. A positional elevatus will reduce following decompression of the first MTPJ and restoration of normal first MTPJ extension.

POSTOPERATIVE MANAGEMENT

Postoperative management in most cases of hemi-implant arthroplasty, whether of the phalangeal or metatarsal surface, is generally very straightforward. Surgical dressings with the toe held in straight and neutral position are continued for approximately 3 weeks postoperatively while the patient ambulates in their surgical shoe. Full-weight-bearing is allowed although surgical dressings must be kept clean and dry. Radiographs should be obtained postoperatively to ensure proper alignment of implant arthroplasty and correction of deformity (Figs. 34.12 and 34.13).

Later, transition from surgical shoes to a casual or gym-type shoe is allowed if no wound healing complications have been encountered. Coban wraps of the forefoot during the day help to reduce swelling and maintain toe position while also helping promote a fine cicatrix. Some surgeons may also prefer a bunion night splint, although this may not be typically necessary.

Figure 34.12 Preoperative (**A**) and postoperative (**B,D**) radiographs of patient with hallux rigidus with insertion of KMI hemimetallic implant. (**C;** Integra LifeSciences, Plainsboro, NJ.)

Gradual increase in activities and regular shoe gear can be progressed per patient tolerance. ROM exercises should commence from immediately postoperatively throughout the first 3 to 6 months after surgery. Occasionally, it may be observed that ROM is limited at 2 to 3 months postoperative but will gradually increase over the subsequent 3 to 6 months. Prescription physical therapy is usually not necessary but may be considered in the patient with a limited ROM postoperatively or one reluctant to perform joint exercise themselves.

DOUBLE-STEM HINGED SILICONE IMPLANT ARTHROPLASTY

Implants

Multiple designs of the silicone hinge implant is available, most notably the Swanson original design with standard and short-stem variations, each packaged with titanium grommets and the Futura (Futura/Tornier, Edina, MN), Primus, and classic flexible great toe implants. These implants are generally utilized with the metallic grommets as a protective interface between the resected bone and soft silicone polymer. Once again, the surgeon must be thoroughly familiar with the implant system that is being utilized including the instrumentation and sequential steps involved with insertion. Generally, implantation of the silicone hinge implants requires a few less steps and possesses much simpler instrumentation than the two-component total joint systems that will be discussed in the next section. The following discussion will focus on the Swanson design silicone hinge implant (Fig. 34.14), with its tapered rectangular stems at 180 degrees in both the sagittal and transverse planes.

Exposure

Generally, a lineal dorsal medial approach to the first MTPJ is preferred with the incision medial to the tendon of extensor

Figure 34.13 Preoperative AP (**A**) and lateral (**B**) radiographs of patient with hallux rigidus and degenerative changes at first MTPJ. **C:** Patient underwent metatarsal head surface replacement arthroplasty. Postoperative AP (**D**) and lateral (**E**) radiographs show maintenance of great toe alignment and good alignment of first MTPJ position.

hallucis longus (Fig. 34.15). The incision extends from the midpoint of the first metatarsal over the MTPJ onto the great toe. In cases of hallux rigidus, limited subcutaneous dissection is necessary as the toe is generally straight. When the double-stem implant arthroplasty is used in arthritic hallux valgus deformities, somewhat more extensive medial subcutaneous dissection of the first MTPJ capsule from the overlying skin and subcutaneous tissues is performed so as to be utilized during closure to aid in reduction of deformity and stabilization of the reconstruction.

Initial subperiosteal dissection begins at the first MTPJ and extends distally onto the proximal phalanx and then progresses to the first metatarsal (Fig. 34.16). Complete exposure of the base of the proximal phalanx including the dorsal, medial, and lateral aspects is accomplished.

Enough of the first MTPJ must be resected to allow for insertion of the implant and a good ROM. Bony resection aids reduction of deformity, and excessive stress on the implant hinge must be avoided. Bone resection generally begins at the

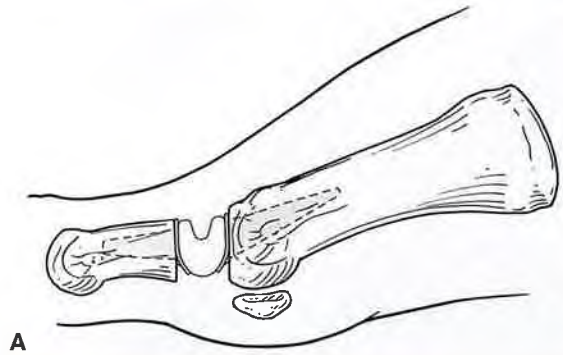

Figure 34.14 **A:** Several variants of the hinge interpositional implant are available, including the Swanson (Wright Medial, Arlington, TN) design illustrated above. **B:** This design possesses a tapered rectangular stem both proximal (long end) and distal (short end) with a central hinge to allow sagittal plane motion. Titanium grommets are packaged with the implant as an interface to protect the hinge area from opposing bone. **C:** The instrument set for the Swanson short stem implant. For each implant and corresponding stems, an intramedullary rasp allows fashioning the medullary canals in the exact negative image of the implant stem.

level of the proximal phalanx and following resection of the proximal phalangeal base, attention may be directed to the first metatarsal head (Fig. 34.17).

Any further subperiosteal exposure of the distal first metatarsal may now be accomplished. This includes exposure of all periarticular proliferative osteophytosis or enlargement medial eminence in cases of hallux valgus. In cases of severe hallux valgus, complete degloving of the distal portion of the first metatarsal may aid in reduction of deformity (Fig. 34.18).

Large dorsal osteophytes and any joint mice are resected. Initial bone resection should generally begin at the phalanx. The angle of resection and amount of bone resected will vary depending upon which implant system that is chosen. Many of the joint implants provide templates for both the amount

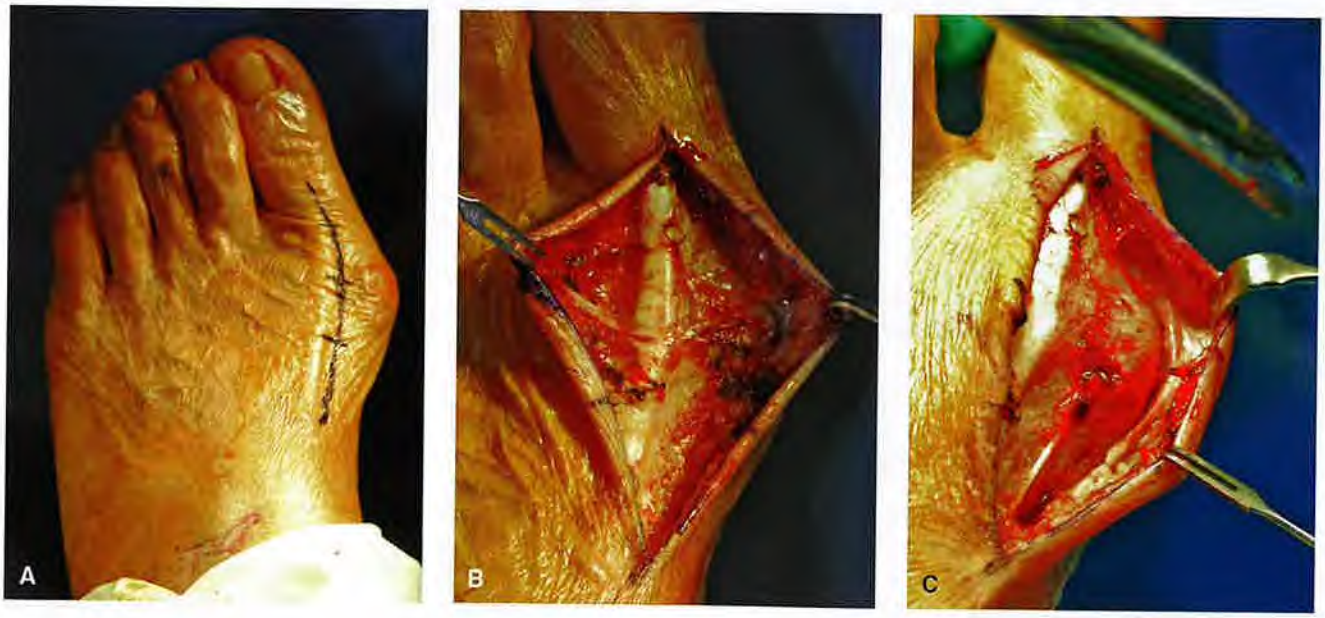

Figure 34.15 **A:** The dorsomedial skin incision is most commonly utilized, extending from the midpoint of the first metatarsal to the midpoint of the hallucal proximal phalanx. The extent of subcutaneous dissection (**B**) is generally dictated by the degree of hallux valgus deformity and requirements for capsulopasty (**C**).

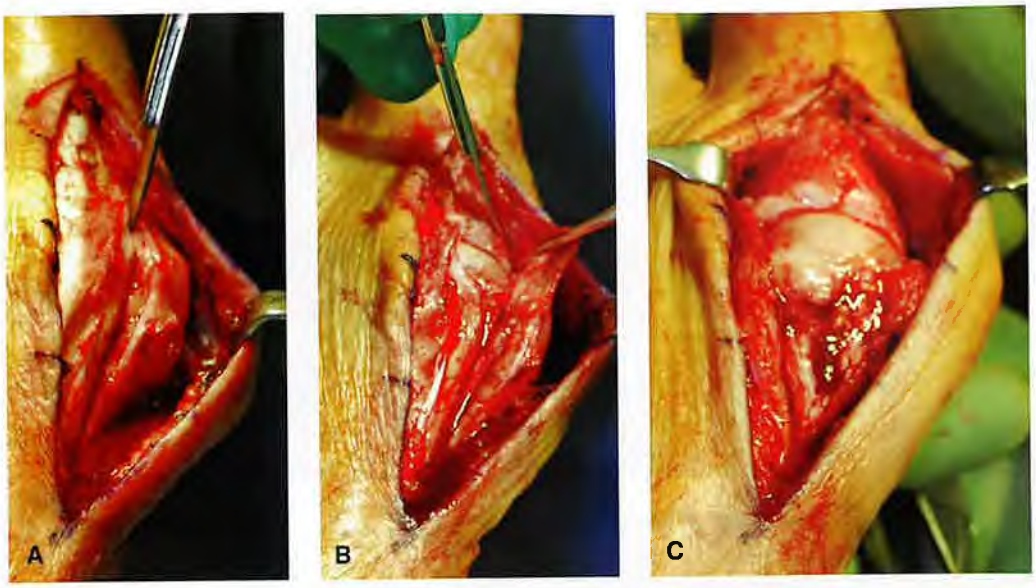

Figure 34.16 A linear capsulotomy medial to the tendon of EHL (**A**) will be followed by subperiosteal dissection (**B**) of the first metatarsal and proximal phalangeal base (**C**).

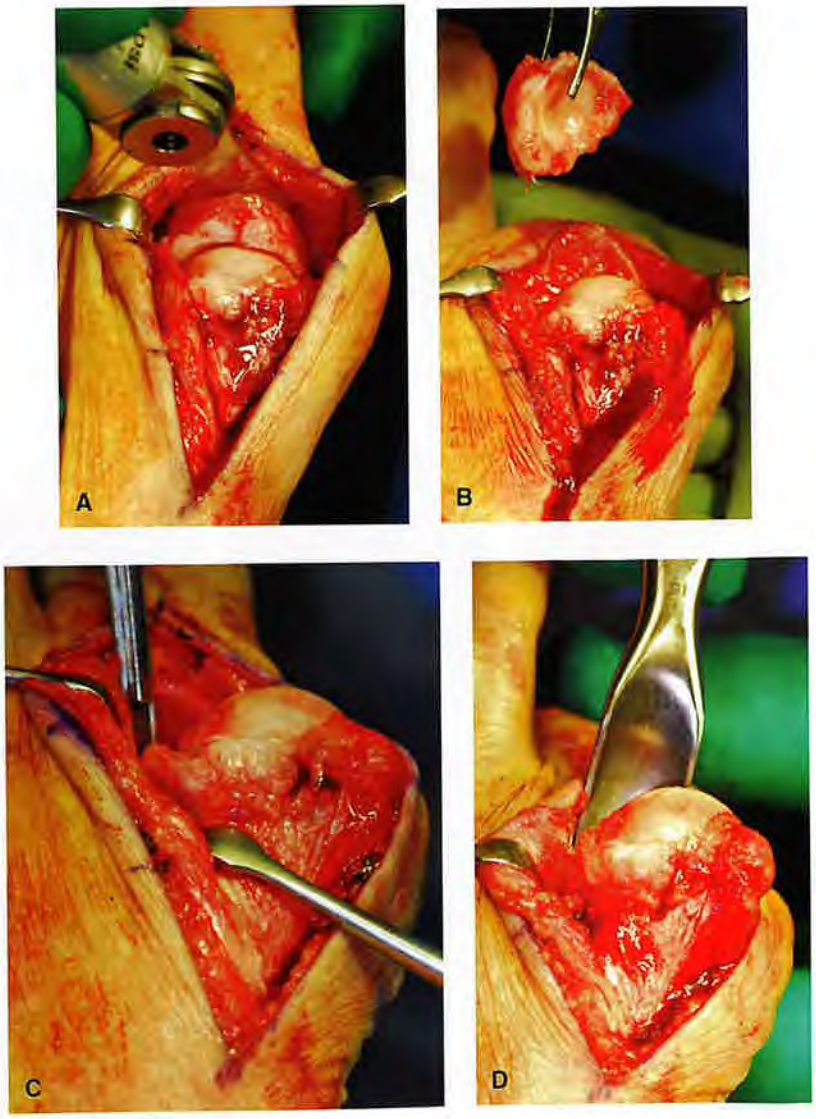

Figure 34.17 Following exposure of the proximal phalanx, transverse osteotomy (**A**) of the phalangeal base at the proximal metaphysis allows subsequent resection of phalangeal base (**B**). Further dissection of the first metatarsal is performed (**C**) as needed to allow cheilectomy and mobilization of the joint (**D**).

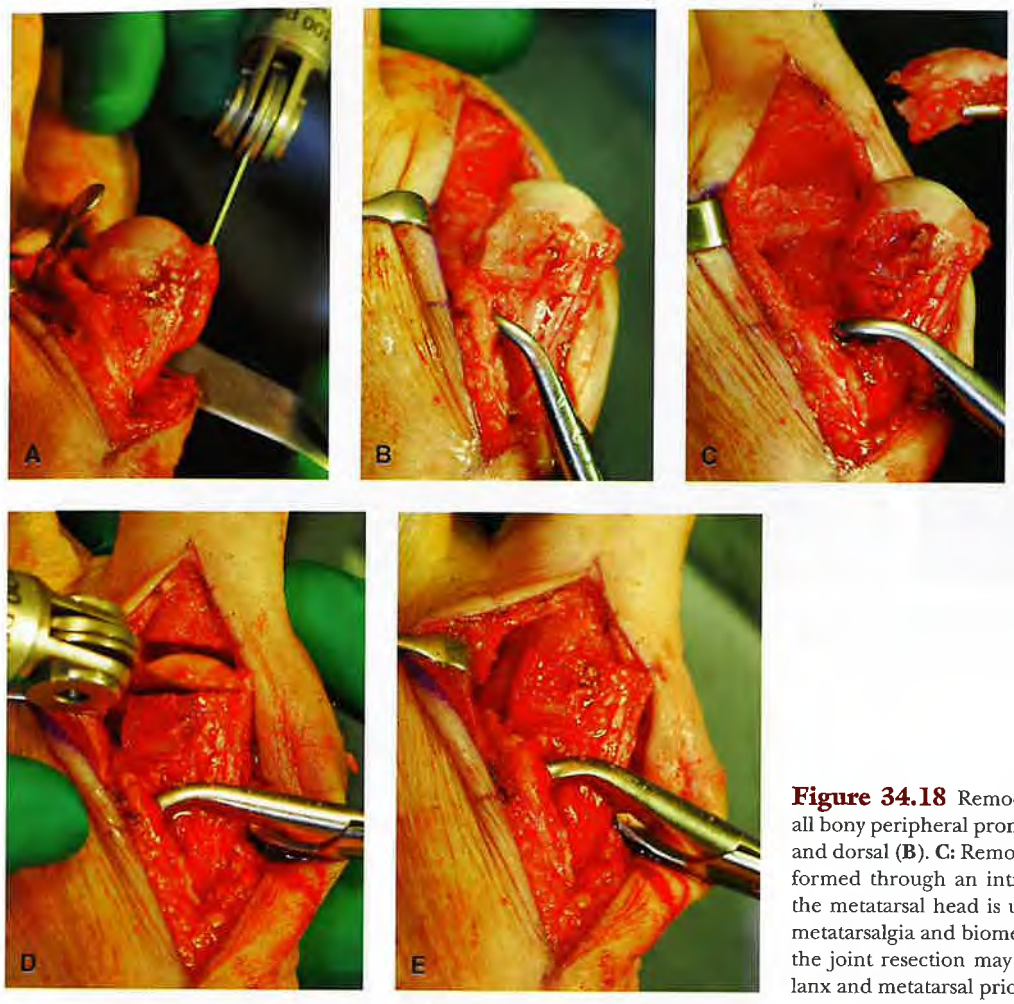

Figure 34.18 Remodeling of the first metatarsal removes all bony peripheral prominences including medial (**A**), lateral, and dorsal (**B**). **C:** Removal of the fibular sesamoid may be performed through an intracapsular approach. **D:** Resection of the metatarsal head is usually minimal to limit postoperative metatarsalgia and biomechanical imbalances. **E:** Alignment of the joint resection may be evaluated with opposing the phalanx and metatarsal prior to reaming of the medullary canals.

and direction of bone resection, for example, the Primus implant. Approximately one-quarter to one-third of the proximal phalanx is resected through an osteotomy perpendicular to desired final long axis of the hallux. This must include an assessment of the degree of interphalangeus present. The transverse plane orientation of the osteotomy usually parallels the eponychial nail fold.

The phalangeal osteotomy should just perforate the plantar cortex to avoid laceration of the long flexor tendon. From this point, careful dissection of the soft tissues from bone will help maintain the integrity of the plantar capsule and the aponeurotic insertions of the flexor tendons. Actually after removal of the base, there should be no violation of the plantar tissues, that is, the long flexor should not be exposed. The first MTPJ sesamoids generally also may be addressed. In cases of severe hallux valgus the fibular sesamoid is often released on its distal, lateral, and proximal extents through an intracapsular approach. At times, the surgeon may find it convenient to perform fibular sesamoidectomy as an aid to reducing severe deformity.

The degree of degenerative osteophytosis and size of the medial eminence will help determine the need for peripheral metatarsal head resection. This becomes extremely important in cases of double-stem hinge arthroplasty in osteoporotic bone. The first metatarsal head cortical margins should be maintained so as to give the greatest amount of support to the metaphyseal trabeculae.

Although the medullary canal may be reamed directly through the metatarsal articular surface in cases of hinged silicone implant arthroplasty, it is recommended that the articular surface be resected. Templates should be used, if available for the implant system. With the use of Futura implants (Futura/Tornier, Edina, MN), flat surfaces opposing the hinge portion of the implant are encouraged because of the design of the implant hinge.

The articular surface of the first metatarsal should be resected closer to a perpendicular to the ground rather than a perpendicular to the long axis or declination of the first metatarsal. This aids in placement of the implant high in the metatarsal and will maintain the plantar condyles for their articulation with the sesamoids. This will also allow for distal excursion of the sesamoids on the metatarsal head with dorsiflexion or extension of the joint.

With implant arthroplasty, maintenance of the weight-bearing potential of the medial column is often diminished. A surgical dilemma arises as limited bone resection is felt to minimize the biomechanical faults of the procedure yet inadequate bone resection is probably the single most cause of postoperative malalignment and recurrence of deformity. The bone resection may occur on either the metatarsal or phalangeal side of

the joint. Excessive resection of the phalangeal base releases the intrinsics and may make fitting and secure placement of the phalangeal implant tenuous.

The exception to minimizing first metatarsal head resection with a hinged silicone implant is with forefoot arthroplasty, that is, the Hoffmann-Clayton–type operation. Forefoot reconstruction of the rheumatoid foot involves total head resection of the lateral metatarsal heads achieving a somewhat normalized bony parabola. As a result, some degree of resection of the first metatarsal is also necessary; this usually involves at least one-half of the first metatarsal head.

Canal Preparation

Canal preparation will vary depending upon the implant chosen. Most implant systems today have reamers or rasps that allow the surgeon to prepare the canal as a reflection of the implant stem. The angle of the canal may also vary, and the surgeon is referred to the surgical technique guide provided by the manufacturer. Generally, implant sizers are utilized to determine the extent of canal preparation necessary. The intramedullary canals are generally begun with a 4-mm oval side cutting bar and then gradually enlarged to the appropriate size using incremental larger hand rasps until the desired size is achieved (Figs. 34.19 and 34.20).

Trial Implant

Each implant system provides for trial implant sizers, which must be matched to the size of the patient and bone stock currently being addressed. Generally, the implant sizer is inserted across the first MTPJ into both the metatarsal and proximal phalanx. The surgeon will access the reconstruction for adequacy of bone resection and correction of deformity. If the implant stem is overstressed, typically the toe will deviate lateral and may rotate yielding frontal plane instability, then additional bone resection is necessary.

Implant Grommets

Titanium grommets were introduced for the Swanson double-stem hinged implant and since adapted by Futura for their Primus implant. These are recommended as the grommet provides a protective interface between the soft silicone rubber and the opposing bone surface. Each size Swanson implant has a corresponding pair of grommets that is packaged with the implant. These are press-fit into the medullary canals of the metatarsal and proximal phalanx (Fig. 34.21). It is not usually necessary to enlarge the medullary canals for fit of the grommet. In most patients with hallux valgus undergoing implant arthroplasty, the bone density is soft and the grommet can easily be press-fit with the grommet inserter. In cases of hallux rigidus and degenerative joint disease in which the bone is dense and sclerotic, it may

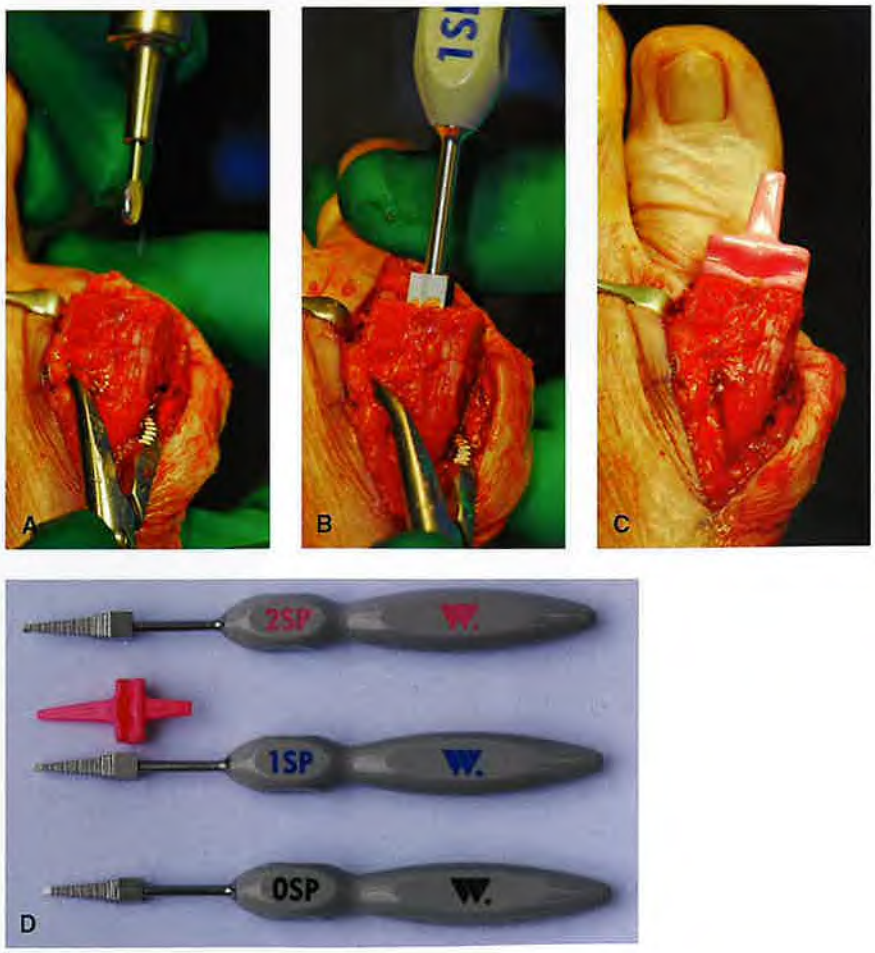

Figure 34.19 Reaming of the medullary canals is generally begun with the first metatarsal. The canal is initially drilled with a small oval side-cutting burr **(A)** followed by gradually enlarging with a series of hand rasps **(B)** of sequentially larger size **(C)**. **D:** Periodically, the implant sizer is inserted assess fit.

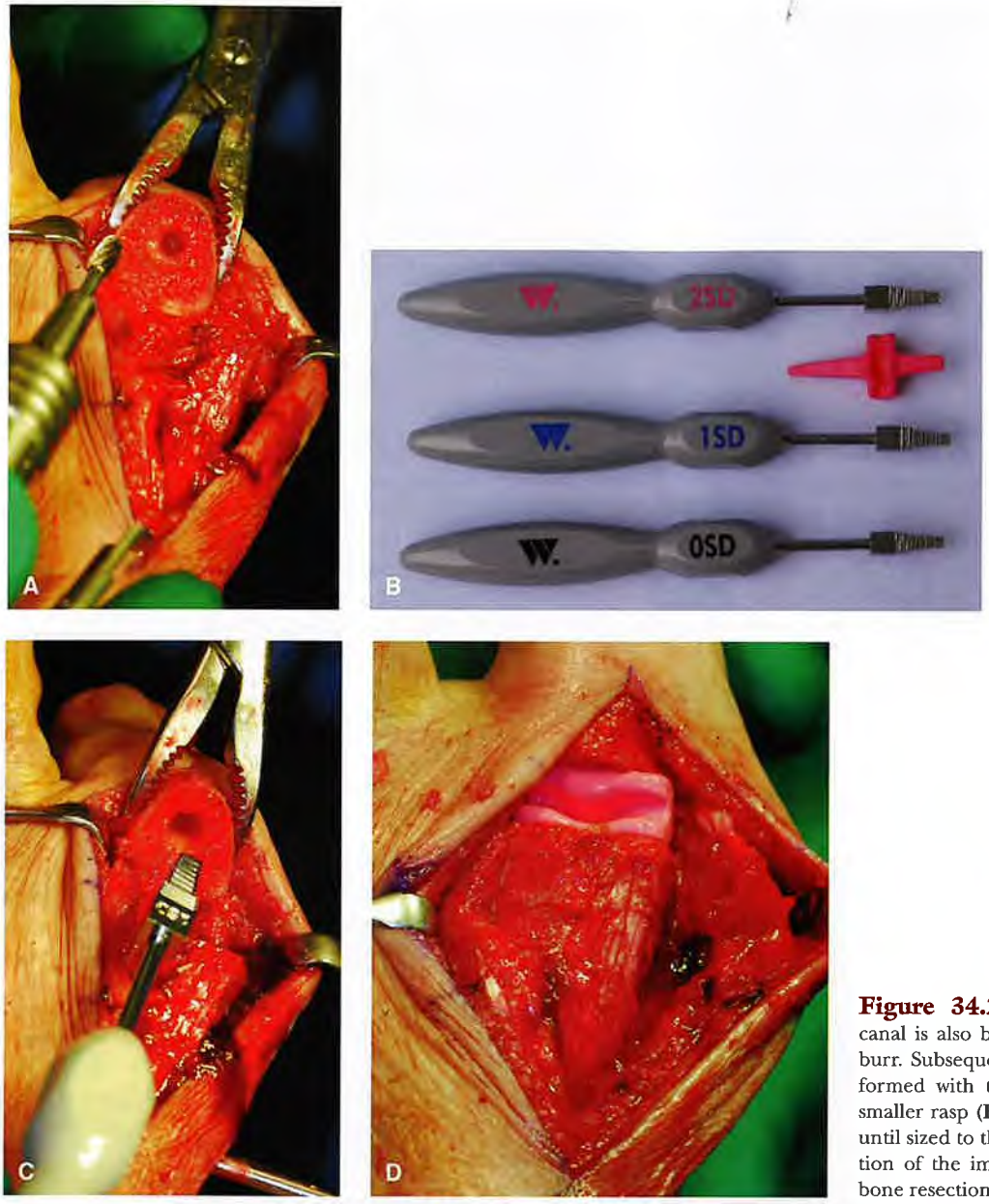

Figure 34.20 **A:** Reaming of the phalangeal canal is also begun with a broach or small rotary burr. Subsequent enlargement of the canal is performed with the hand rasps beginning with the smaller rasp (**B**) and gradually enlarging the canal until sized to the appropriate implant (**C**). **D:** Insertion of the implant sizer allows assessment of fit, bone resection, and alignment.

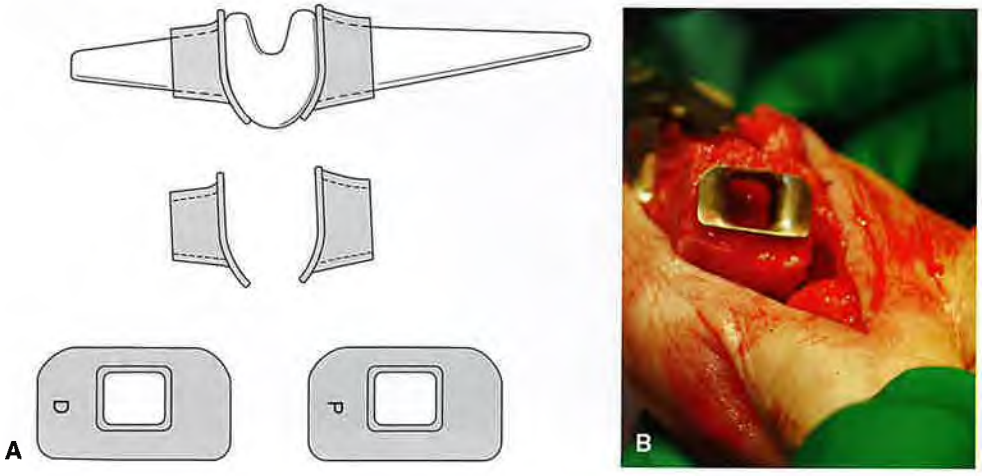

Figure 34.21 Prior to insertion of the silicone implant (**A**), the proximal grommet for the first metatarsal is press-fit into the fashioned hole in the metatarsal (**B**). The grommet for the proximal phalanx may also be press-fit but may not fit tight, and alternatively, the grommet is simply placed on the distal stem of the silicone implant

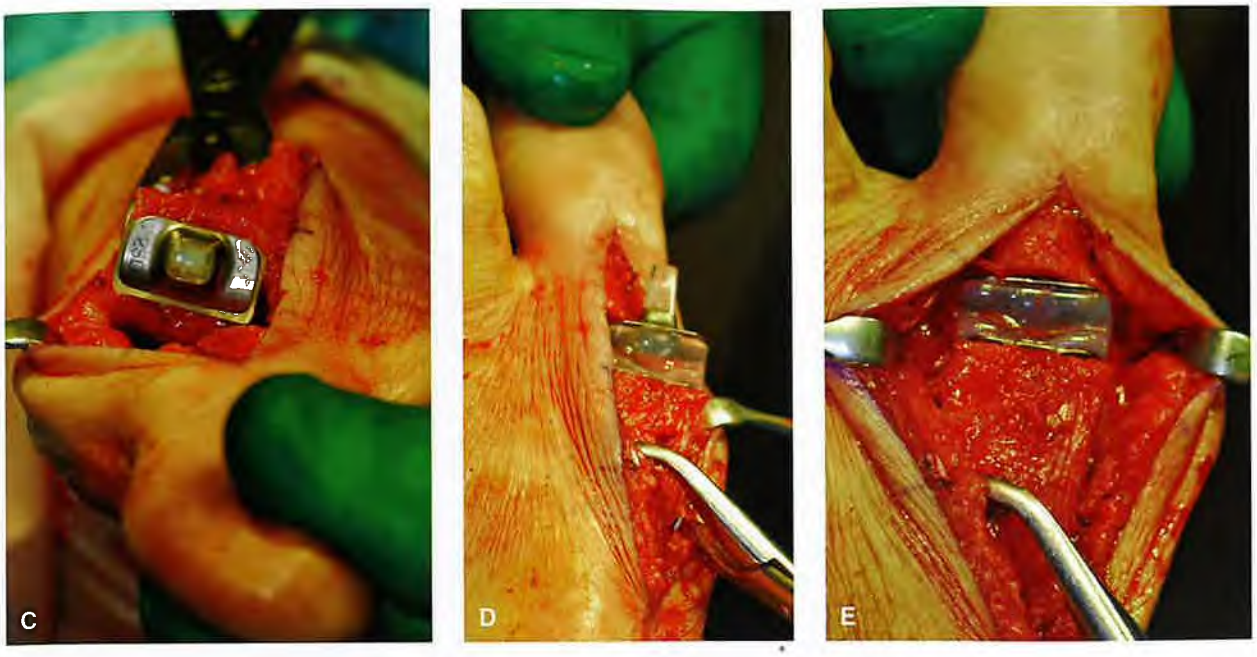

Figure 34.21 *(Continued)* **(C,D)** just prior to its insertion into the proximal phalanx **(E)**.

be necessary to round the margins of the medullary canals similar to the contour of the grommet prior to insertion.

Implant Insertion

Once the canals are prepared to their exact size, copious irrigation is performed to remove all bone debris. With insertion of the double-stem silicone implant, the proximal stem for the first metatarsal is inserted first. Plantarflexion of the hallux then allows insertion of the distal stem into the proximal phalanx. Insertion of the implant should be performed without the implant touching the skin and possible contamination, a potential cause of latent foreign body–centered infections (83,84). Assessment of position of the implant and soft tissue laxity as well as ROM should be performed at this time. If the implant is tight and the hinge stressed, additional bone resection is likely necessary.

Capsular Repair

Capsular closure is performed with the surgeon's preference of absorbable materials. The senior author's (J.V.) usual choice is 2-0 and 3-0 absorbable suture with the medial margin of the extensor hood is also incorporated into the capsular closure. This accomplishes a very important function of medializing or maintaining the vector of pull of the tendon of extensor hallucis longus. Bow-stringing of this tendon laterally may destroy the stability of the joint reconstruction yielding transverse and frontal plane deformities postoperatively.

Soft tissue repair may begin prior to insertion of the implant system. In cases of significant bone resection, the author has found that tethering the long and short flexors to each other with an intracapsular suture helps to stabilize the hallux. Other surgeons have also found it useful to reattach the short flexor tendons to the phalangeal base as initially described by Kalish and McGlamry (7) in 1974 with reattachment of the intrinsic musculature with suture through drill holes in the proximal phalanx.

In cases of significant hallux abductus, additional medial capsular repair is recommended (Fig. 34.22). A capsuloplasty may also be accomplished with a medial flap that is extended distally to give additional transverse plane stability. This involves modification of the original linear or lenticular capsulotomy just prior to insertion of the implant usually with the implant sizer in place. A vertical incision is made in the distal extent of the medial capsule. A transverse capsulotomy is then performed just above the tibial sesamoid extending proximally at least to the metatarsal neck. This capsular flap may then be advanced anteriorly or distal. Suture is first performed dorsally from distal to proximal and then the plantar portion repaired.

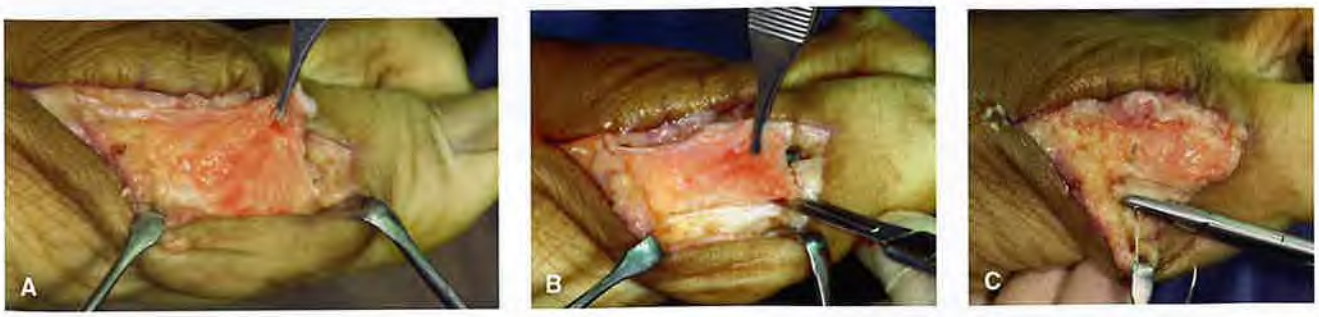

Figure 34.22 **A:** Capsular and wound closure is of surgeon's choice. **B,C:** Medial plication or use of a medial capsular flap is desirable in large degrees of hallux valgus.

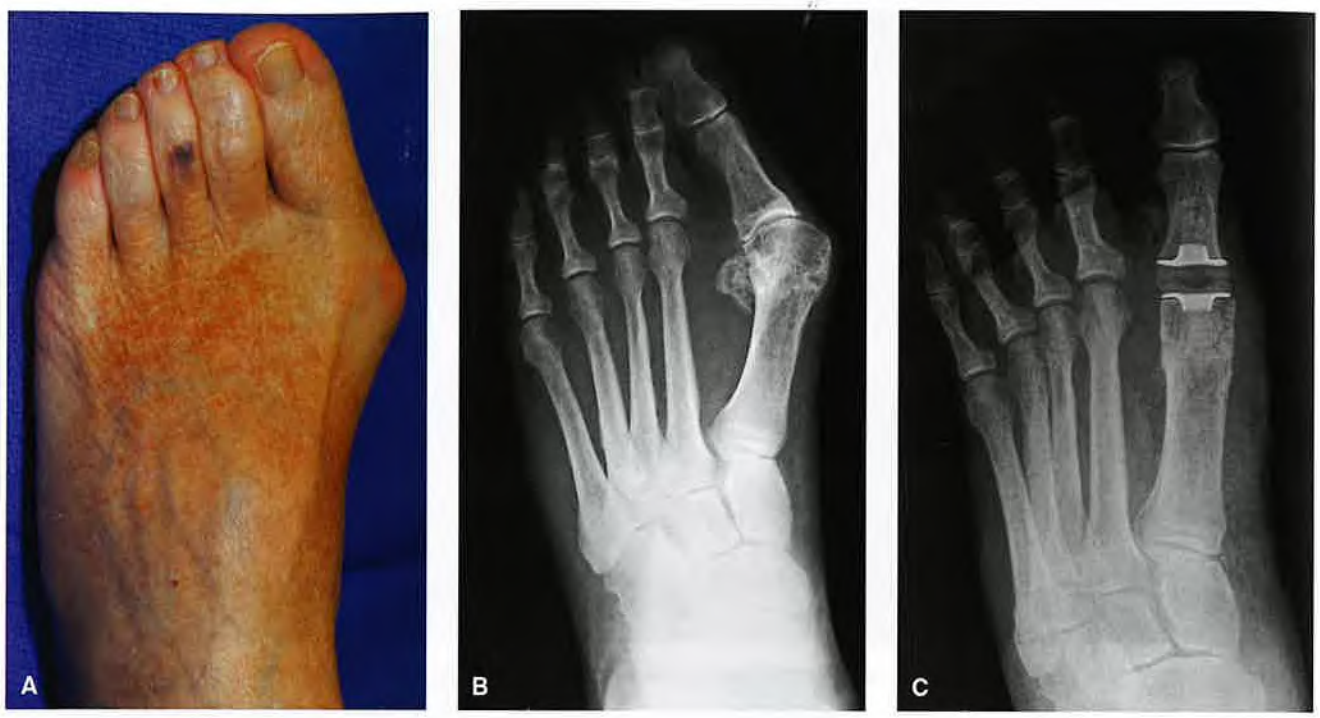

Figure 34.23 **A,B:** This 74-year-old woman possessed a large hallux abductus and IM angle, but both components of the deformity were corrected with the silicone hinge implant arthroplasty. **C:** The fibular sesamoid was excised to aid in soft tissue reduction of the IM angle.

Subcutaneous and skin closure is left to the surgeon's preference. A fluff compression dressing is utilized postoperatively splinting the toe in a rectus position and maintaining it in a somewhat plantarflexed position to aid in postoperative toe purchase.

Postoperative Course

Ambulation is allowed immediately postoperatively with a surgical shoe. In cases of isolated interpositional implant arthroplasty, ambulation in a flexible soled causal shoe may be allowed as early as 3 weeks postoperatively without any other form of toe splinting. Severe and long-standing preoperative deformities should be splinted in a rectus position for a somewhat longer length of time. A hallux valgus night splint or Coban wraps of the forefoot and hallux are often useful adjuncts.

Moderation in activity is emphasized early on, and the patient is followed with serial postoperative visits and radiographic examinations. Radiographs allow assessment of correction and alignment (Figs. 34.23 and 34.24).

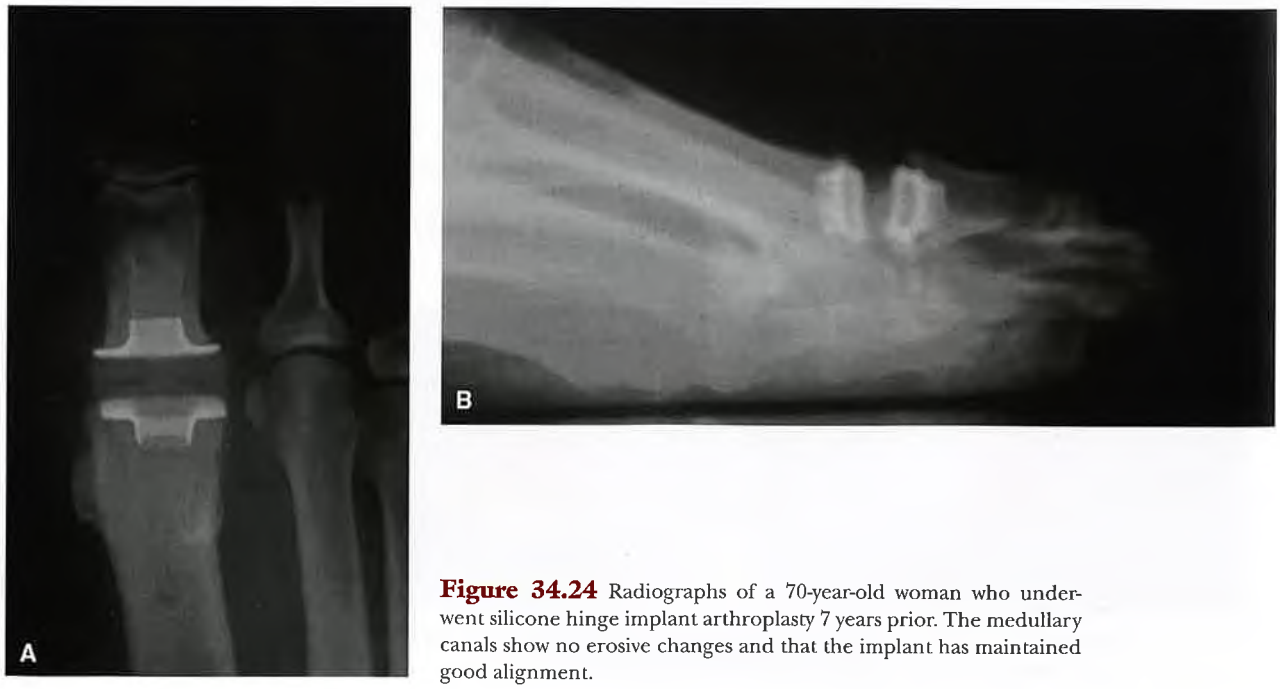

Figure 34.24 Radiographs of a 70-year-old woman who underwent silicone hinge implant arthroplasty 7 years prior. The medullary canals show no erosive changes and that the implant has maintained good alignment.

TOTAL JOINT REPLACEMENT ARTHROPLASTY

Total replacement arthroplasty involves resurfacing on both sides of the joint. Typically, the bearing surfaces involve a cobalt chromium metatarsal component and UHMW polyethylene phalangeal component. Several ceramic two-component implant systems have been introduced in Europe, and preliminary reports have been equivocal (85–87). Most surgeons will agree that degenerative changes at the first MTPJ are usually more striking on the metatarsal side of the joint. Attempts to replace or resurface the first metatarsal have not met with much success. Resurfacing of the phalangeal base has been more successful, and we continue to investigate and develop new implant systems. It is imperative that bone resection allows joint mobility and the implant system is securely held within the respective bones. These implant systems are required by the FDA to be labeled as cemented devices, although most clinical usage does not usually involve use of bone cement.

Implants

Multiple variations of the total joint concept have been introduced over the years, and a few will be mentioned (Fig. 34.25). The KGTI Kinetik Great Toe Implant (Integra LifeScience Corporation, Plainsboro, NJ) has a cobalt chromium metatarsal component with a tapered rectangular stem and dorsal flange to impart an adequate range of dorsiflexion. The phalangeal component is a titanium implant with a UHMW polyethylene articular inset. Several two-component systems are available including the Ascension MOVEMENT system (see Fig. 34.22), and whatever implant system that is chosen, the surgeon must be thoroughly familiar with the implant system that is being utilized including the instrumentation and sequential steps involved with insertion.

Exposure

The authors generally prefer a dorsal approach to the first MTPJ medial to the tendon of extensor hallucis longus (Fig. 34.26). The incision extends from the midpoint of the first metatarsal over the MTPJ onto the great toe. In cases of hallux rigidus, limited subcutaneous dissection is necessary as the toe is generally straight and subsequent capsulorraphy limited. A lineal capsulotomy in line with initial skin incision medial to extensor hallucis longus is performed with subperiosteal exposure of the head of the first metatarsal and the base the proximal phalanx. The surgeon needs to be thoroughly familiar with the technique recommended for the implant that is being inserted, and this discussion will center upon the KGTI.

Bone Resection

The implant tray has an instrument guide to help the surgeon resect the proper amount of bone and at the proper angles (Fig. 34.27). It is imperative to follow the proper application of the guide for the osteotomy particularly for the KGTI. Two guides are available: one that allows for bone resection equal to that required for implant insertion and a second guide that allows for an additional 5 mm of bone resection from the phalanx in cases of tight joints to provide joint laxity. Careful use of this initial guide is important, and inattention to details may with result in angular errors of 5 degrees or more, and the implant may not seat or move properly. The guide is inserted into the first MTPJ with the concave surface placed against that of the metatarsal head while the flat surface is opposing the phalanx. Transverse osteotomy of the metatarsal head and then the phalanx is performed partially through the respective bones. The resection is finished following removal of the guide. The guide should allow resection of the phalangeal base perpendicular to the long axis of the proximal phalanx while

Figure 34.25 Several total joint replacement systems are available, including the KGTI Kinetik Great Toe Implant (Integra LifeScience Corporation, Plainsboro, NJ) **(A)**, the Acumed Great Toe System (Acumed, Hillsboro, OR) **(B)**, and the MOVEMENT Great Toe System (Asension Orthopedics, Austin, TX) **(C)**.

Figure 34.26 Dorsomedial skin incision (**A**) medial to tendon of EHL (**B**) allows for exposure to first MTPJ. **C:** A lineal capsulotomy with subperiosteal dissection provides joint exposure.

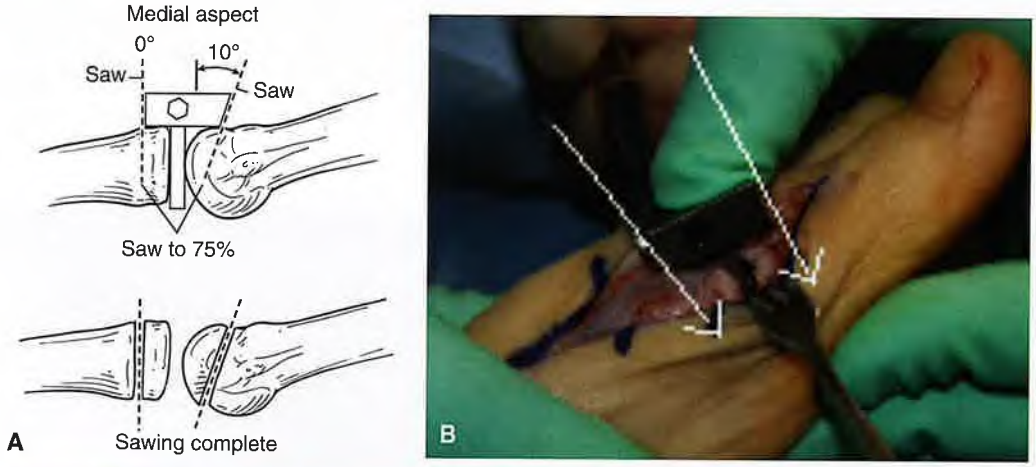

Figure 34.27 **A,B:** Insertion of primary resection guide provides for a cutting guide for resection of the articular surfaces. The cuts are begun, the guide removed, and the osteotomies completed. **C:** Resected bone surfaces are extripated.

the metatarsal surface is resected with a 10-degree dorsal angulation. The resection guide does not allow for high degrees of distal articular set angles or interphalangeus, and the surgeon must be attentive to the individual patient anatomy. The phalangeal osteotomy must be perpendicular to the long axis of the proximal phalanx to allow proper seating of the phalangeal component. Following osteotomies, the surfaces are completely dissected from the surrounding soft tissue and excised.

Implant Sizing and Canal Preparation

Following joint resection, the metatarsal sizer/drill guide is placed over the resected surface, paying attention to neutral coronal rotation. Choose the most appropriate size for your patient's anatomy. The sizer must not be placed too plantar and block the sesamoidal grooves; otherwise final implant insertion will impinge range of motion of the sesamoids (Fig. 34.28).

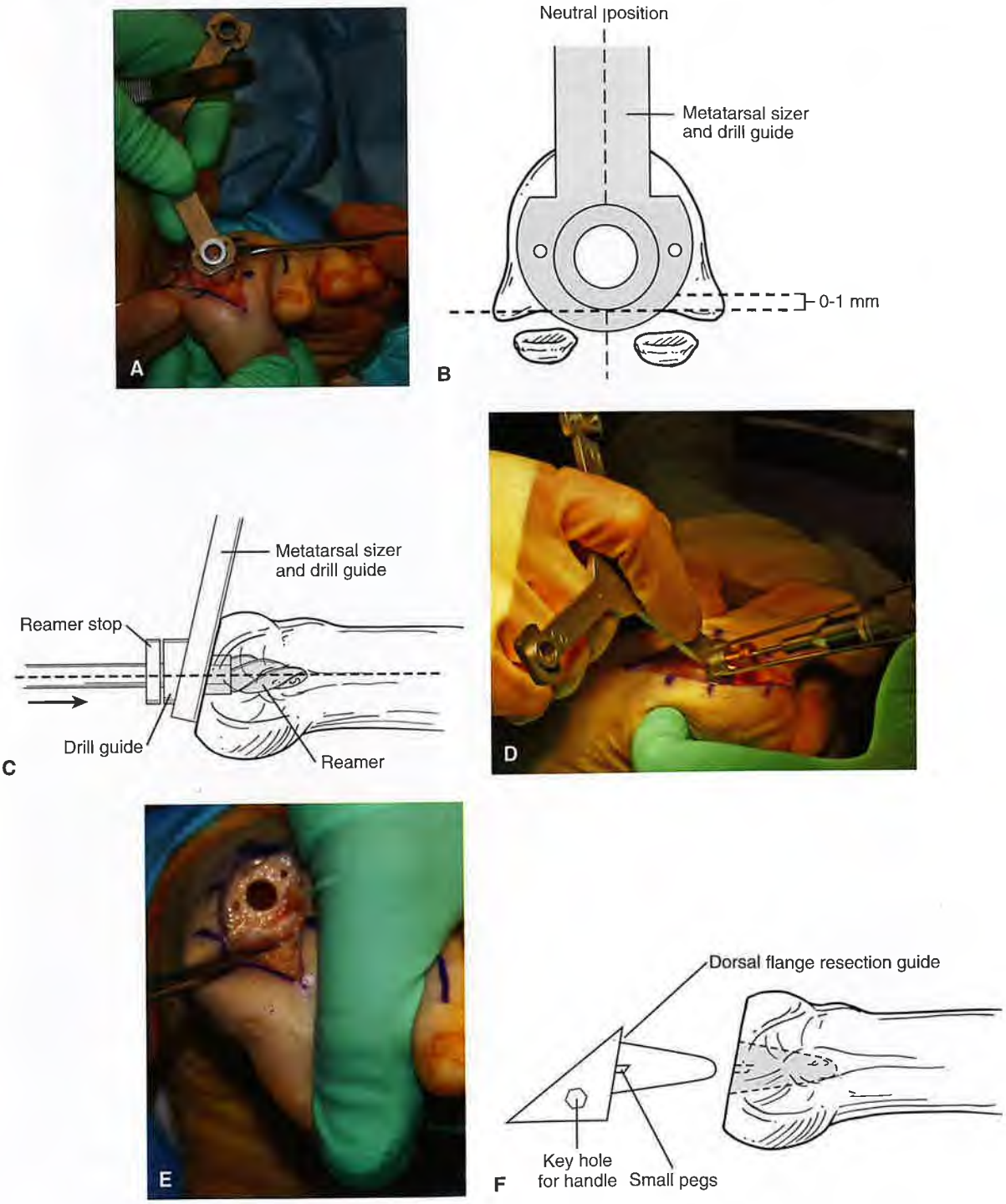

Figure 34.28 **A,B:** The metatarsal sizer is placed on the resected surface and held in place with two K-wires. The canal is reamed (**C–E**), and dorsal flange resection guide (**F**) is used to resect dorsal articular margin and osteophytes.

The sizer is held in place with insertion of two 0.045-inch K-wires and on either side of the central aperture. The metatarsal is subsequently reamed with the metatarsal reamer on a power drill and performed through the sizer/guide. Following reaming, the K-wires and metatarsal guide are removed and replaced with the dorsal flange resection guide and angular resection of the metatarsal head dorsal surface is resected.

The metatarsal is now ready for further remodeling of the medullary canal with a broach to create a negative image of the implant stem (Fig. 34.29). The metatarsal broach guide is placed onto the resected distal metatarsal surface. Pins in the broach guide are inserted into the peripheral holes made from the prior medial and lateral K-wire holes. The medullary broach is used manually and tapped with a mallet until the stop of the broach abuts the outer most edge of the broach guide stop. Following irrigation of the wound and canal, the selected sized trial implant is used to check for proper size and position of the head component.

Attention is then directed to the hallucal proximal phalanx in which the phalangeal sizer/drill guide is held in place and size determined for the phalangeal component. The phalangeal reamer on a power drill is utilized to fashion a canal in the proximal phalanx (Fig. 34.30). The wound is flushed and the trial phalangeal and metatarsal components are inserted to ascertain to fit and need for any additional bone resection (Fig. 34.31). With the KGTI, the surgeon debulks excess bone after the implant is finally sized.

It is also up to the surgeon to remove adequate amount of bone to avoid jamming of the joint and poor motion. Excess removal of bone must also be avoided to prevent an unstable reconstruction or transfer metatarsalgia.



Figure 34.29 **A:** The metatarsal broach guide is placed on the metatarsal surface and tapped into place. **B–D:** Broaching of the first metatarsal may be done by hand, or a broach is supplied that may be placed in a power reciprocating saw.

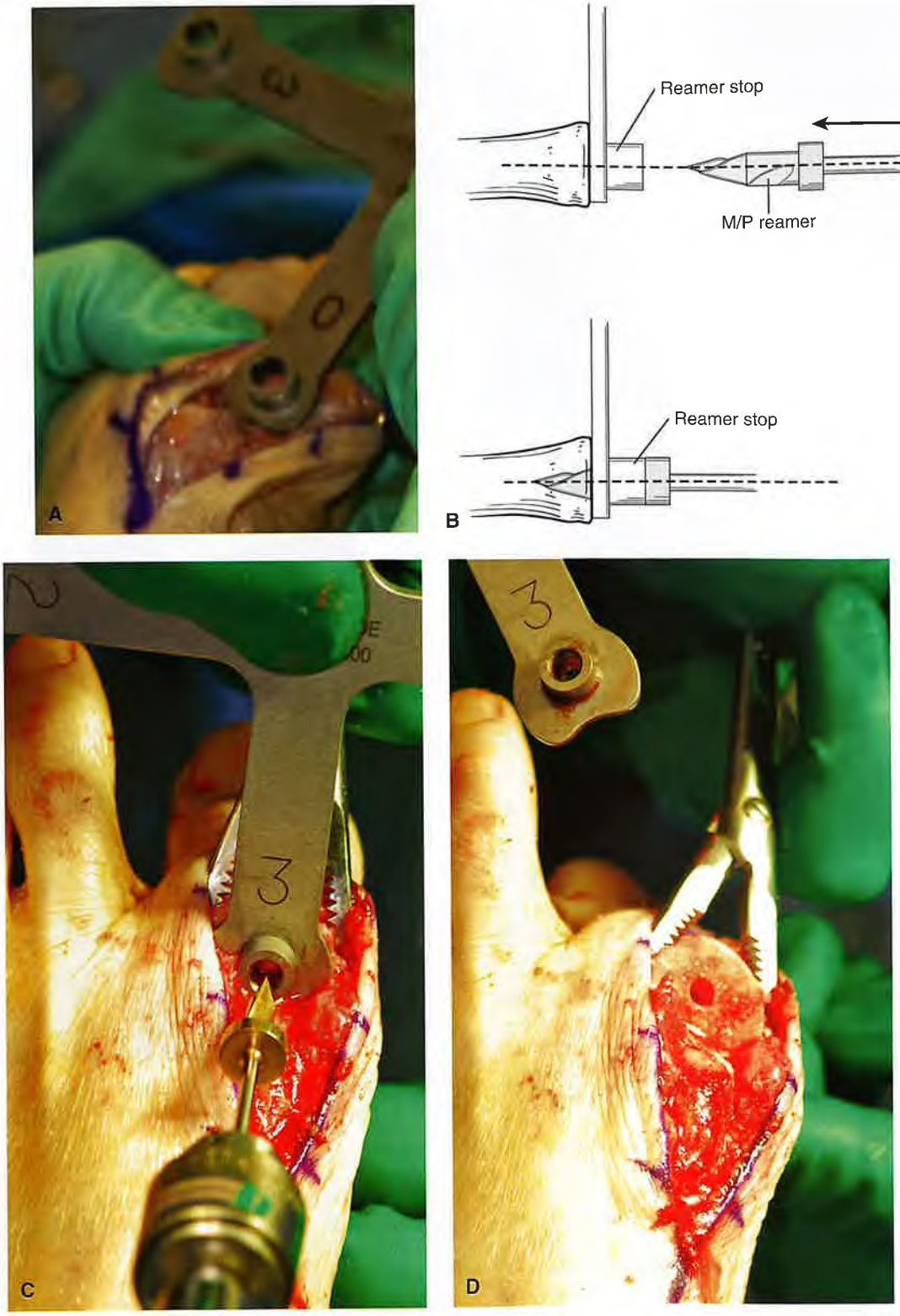

Figure 34.30 The phalangeal sizer and drill guide are placed on the resected surface of proximal phalanx (**A,B**), and then reaming of the canal, performed with an M/P reamer placed in a power instrument (**C,D**).

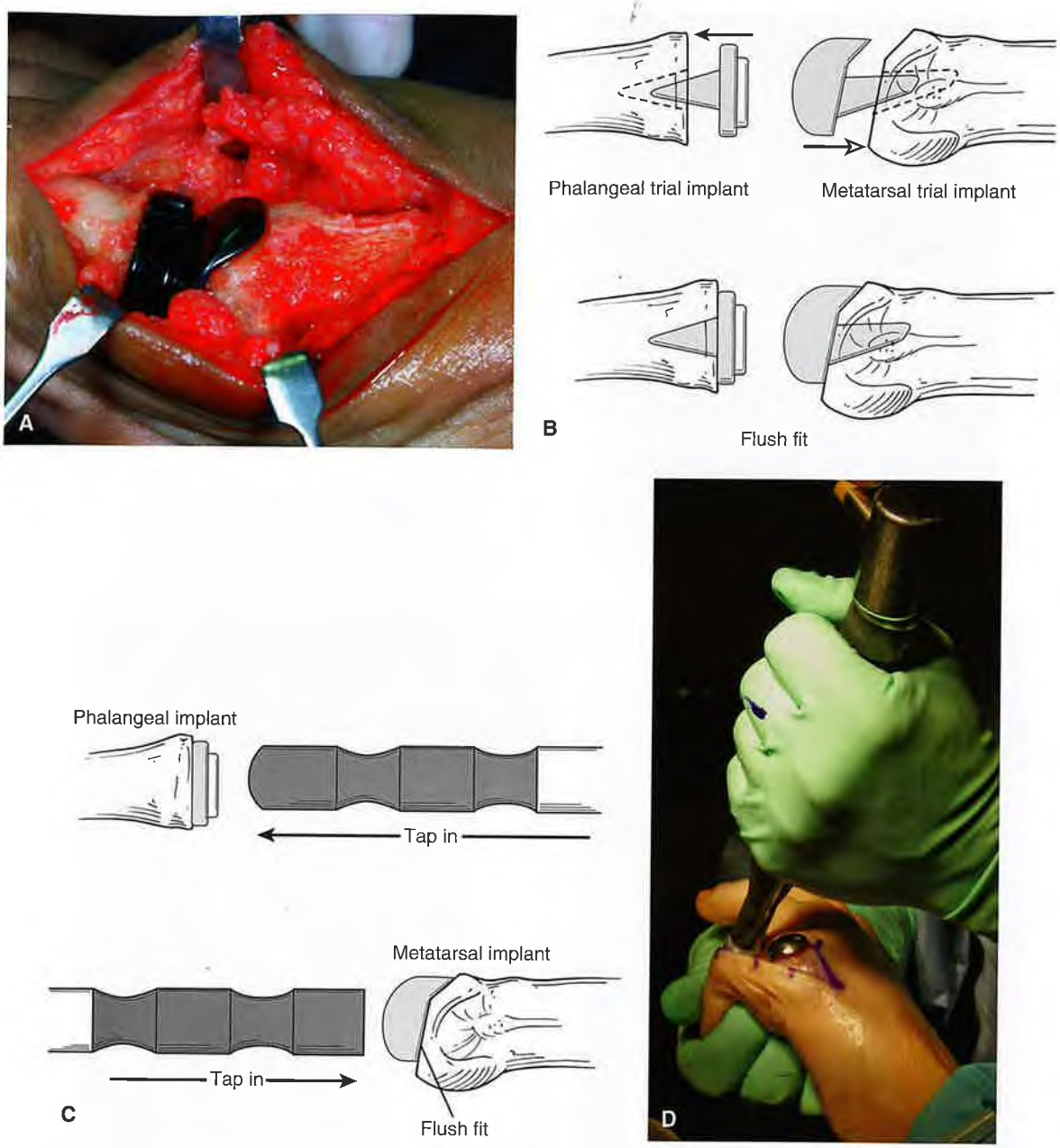

Figure 34.31 **A–C:** Trial implant is inserted and the ROM evaluated. **D:** If the joint is tight, additional bone is resected from the proximal phalanx. (**B,C** courtesy of KGTI Surgical Technique, Part No. 81-0053 Rev D, 10/06.)

Implant Insertion

The metatarsal and phalangeal components are inserted into their respective bone and tapped into place utilizing tamps and a mallet until good flush fit is achieved.

Wound Closure

Once the implant has been inserted and a good ROM observed, closure of the wound can begin (Fig. 34.32). With a simple lineal capsulotomy and good subperiosteal dissection prior, wound closure is generally straightforward. The first MTPJ capsule is identified and reapproximated. Any excessive capsule may be excised but exercise caution so not to over tighten the joint and restrict motion.

Generally, closure is performed in standard fashion with suture of the surgeon's choice.

Surgical Tips

- Do not perform overzealous resection of the peripheral osteophytosis. The KGTI guides and technique take into account much of the surrounding excess bone during the insertion technique.

Figure 34.32 Before closure, assess the implant for alignment (**A**) and adequacy of joint motion (**B**).

- If the surgeon readily sees the flexor hallucis longus tendon, the flexor brevis needs to be reattached to the base of the proximal phalanx. Alternatively, the flexor hallucis longus may be reattached to the base of the proximal phalanx or simply tether the medial and lateral heads of the brevis tendon to the flexor longus tendon.
- The implant should only be used with an IM angle of 0 to 8 degrees. If the IM angle exceeds this, it must be addressed. Once the surgeon has prepared the metatarsal and proximal phalanx for the implant, then correct the IM angle.
- Following insertion of the trial components, place the toe and first MTPJ through a ROM and access any potential abutment or malalignment. This must be corrected prior to final implantation.

Postoperative Management

Postoperative management in most cases of total joint arthroplasty without proximal osteotomy is generally straightforward. Surgical dressings with the toe held in straight and neutral position are continued for approximately 3 weeks postoperatively while the patient ambulates in a surgical shoe. Full weight-bearing is allowed, although surgical dressings must be kept clean and dry. Radiographs should be obtained postoperatively to ensure proper alignment of the reconstruction and correction of deformity (Fig. 34.33).

Later, transition from surgical shoes to a casual or gym-type shoe is allowed if no wound healing complications have been encountered. Gradual increase in activities and regular shoe gear may progress per patient tolerance. ROM exercises should commence from immediately postoperatively (the day of surgery) throughout the first 3 to 6 months after surgery. Occasionally, it may be observed that ROM is limited at 2 to 3 months postoperative but will gradually increase over the subsequent 3 to 6 months. Rarely, professional physical therapy will be needed.

RESECTION ARTHROPLASTY (KELLER ARTHROPLASTY)

The following technique employed by Jimenez and Dozier incorporates modifications of the Keller procedure. These include adequate osseous resection from the proximal phalanx, exostectomy of the metatarsal head, reattachment of the flexor hallucis brevis, and/or flexor hallucis longus to the base of the proximal phalanx, use of appropriate soft tissue interposition, use of K-wire fixation, and appropriate closure and bandaging to maintain position. The following surgical technique presents the patient with radiographs and clinical pictures shown in Figs. 34.34 and 34.35.

A dorsal medial incision is placed over the first MTPJ extending from middiaphysis of the first metatarsal just short of the IPJ of the hallux. The incision is deepened through subcutaneous tissue to the level of the capsule. The subcutaneous tissues are mobilized from the medial first MTPJ allowing for a capsular flap incision. The capsule is marked to identify the incision that will be placed into it (Fig. 34.36). The capsule is then mobilized off the metatarsal head and base of the proximal phalanx. The base of the proximal phalanx is freed from soft tissue attachments (Fig. 34.37). Resection

Figure 34.33 This 56-year-old man presented with painful right foot with symptomatic hallux rigidus. **A,B:** Periarticular lipping with joint space narrowing is apparent on preoperative radiographs. **C,D:** Postoperative radiographs show good alignment in all planes; note appearance of stem placed centrally within medullary canals.

Figure 34.34 Preoperative views of hallux valgus with severe increase in the first IM angle and lateral deviation of the hallux.

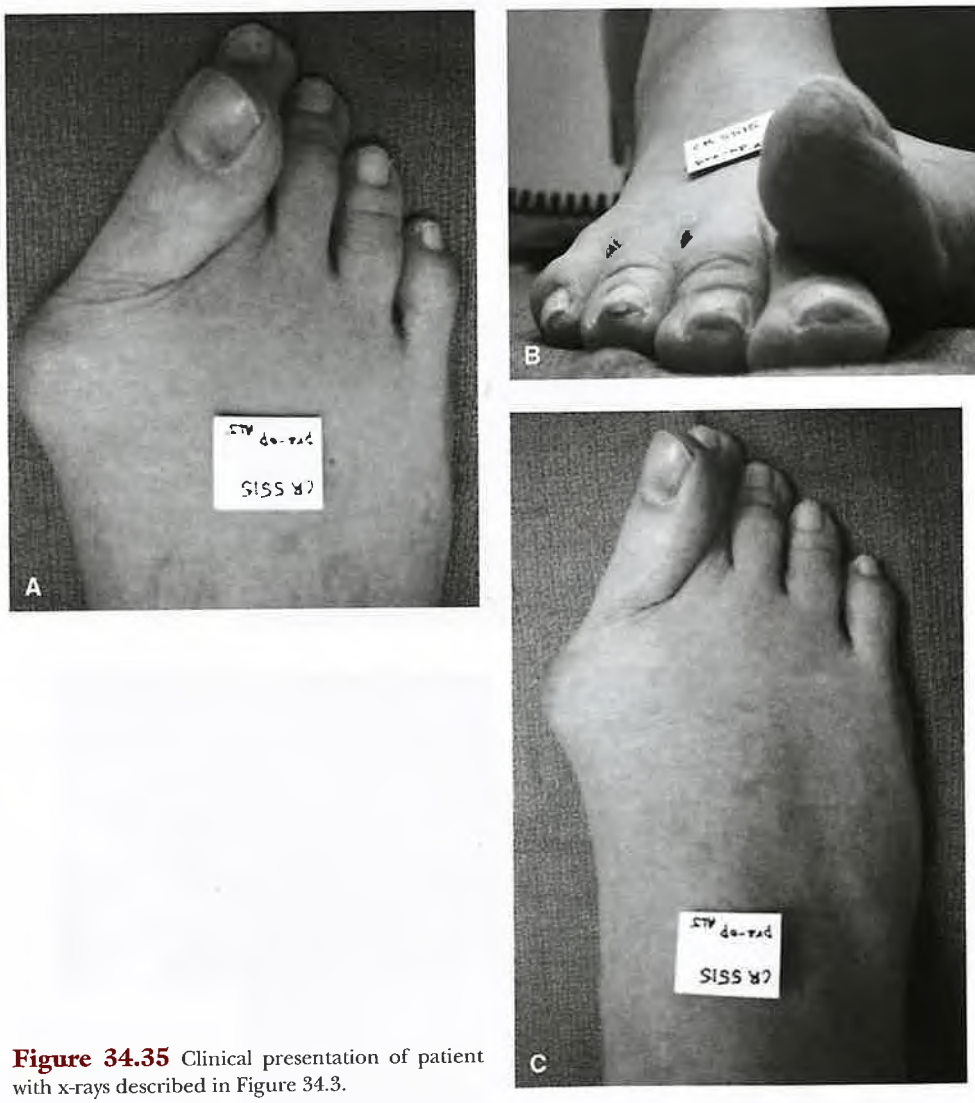

Figure 34.35 Clinical presentation of patient with x-rays described in Figure 34.3.

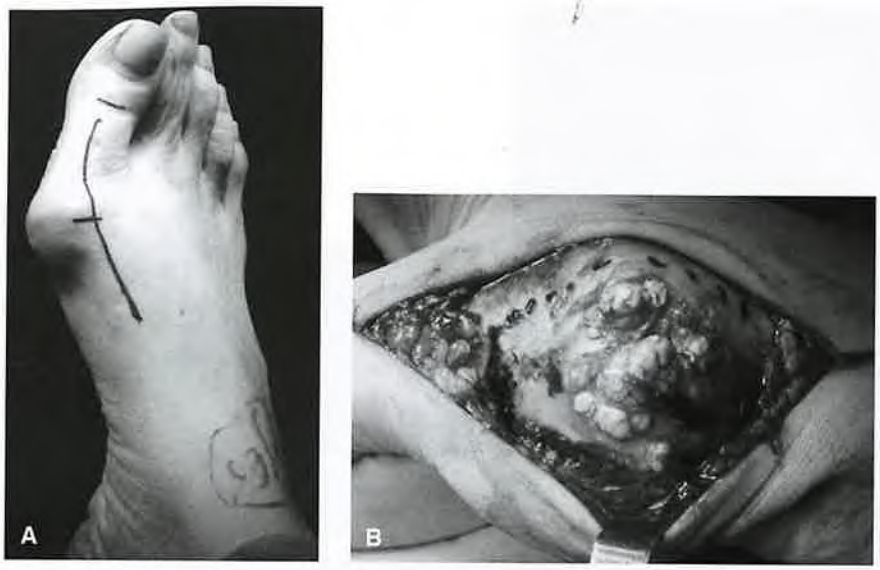

Figure 34.36 **A:** Planned dorsal medial incision. **B:** Planned capsulotomy is marked.

of the osteophytes from the metatarsal head is accomplished followed by resection of approximately 25% to 30% of the proximal phalanx perpendicular to the longitudinal axis. This is ordinarily enough to allow excellent mobility of the remaining base against the metatarsal head (Fig. 34.38). In long-term hallux valgus/rigidus, the sesamoids may be severely arthritic, fibrosed, and nonmobile. If the sesamoids are mobile, the flexor hallucis brevis tendon can be reattached to the remaining proximal phalanx. A 0.062-inch K-wire or 1.6-mm drill bit can be used to create a drill hole into proximal inferior aspect of the remaining proximal phalanx (Fig. 34.39). A 2-0 nonabsorbable suture is placed within the flexor hallucis brevis tendon and/or the flexor hallucis longus tendon and secured in place allowing for flexor stability during gait (Fig. 34.40). A K-wire is then driven through the base of the proximal phalanx exiting the toe and stopped when the proximal end of the K-wire is even with remaining body of the proximal phalanx (Fig. 34.41). A second K-wire is introduced antegrade through the proximal phalanx exiting distal medial to the proximal phalanx. The distal aspect of the capsule is then placed over the head of the metatarsal using a horizontal mattress suture, which incorporates the lateral capsule and is secured in place (Figs. 34.42 and 34.43). Once the capsule is interposed between the osseous segments, the hallux is distracted slightly, keeping space between the proximal phalanx and the metatarsal head, and the K-wire is driven within the body of the metatarsal head, exiting the inferior distal third of the first metatarsal (Fig. 34.44). When the K-wire purchases this cortex, less pistoning is created of the K-wire with the first metatarsal maintaining longer stability. It is important to maintain the position of the hallux approximately 10 degrees extended to the long axis of the first metatarsal head. If the K-wire is in line with the long axis of the first metatarsal, it may be difficult for the patient to ambulate and, in fact, may bend the wires during gait. This is more of a problem in a cavus-type foot as with a cavus foot the angle of declination of the first metatarsal is higher. The position of the hallux therefore will have to be more extended at the MTPJ. Two K-wires are used to maintain position, one to hold length and the second wire to reduce the possibility of frontal plane rotation and shortening of the proximal phalanx–metatarsal head interface (Fig. 34.45). The wound is then closed in layers.

Figure 34.37 Capsule mobilized off the metatarsal head and base of the proximal phalanx. Note gouty tophi within the capsule and joint.

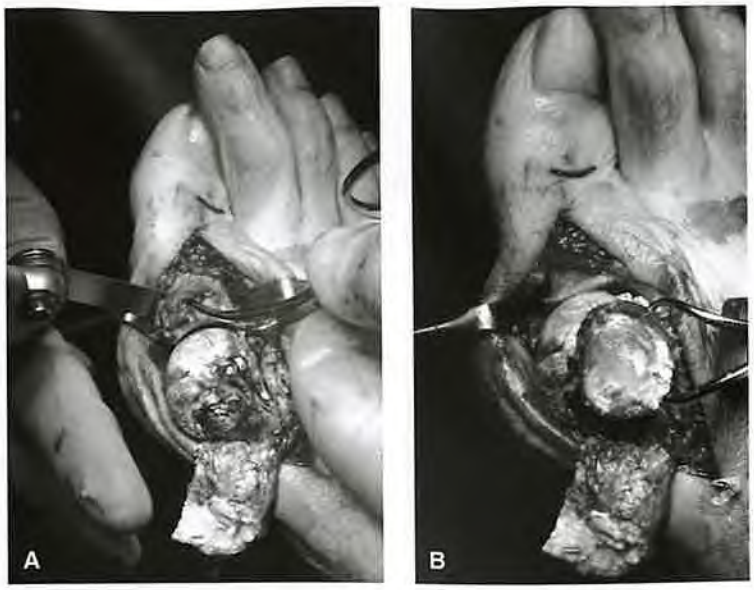

Figure 34.38 Resection of base of the proximal phalanx.

Figure 34.39 Drill hole placed on inferior proximal aspect of the remaining proximal phalanx for reattachment of the flexor hallucis brevis tendons.

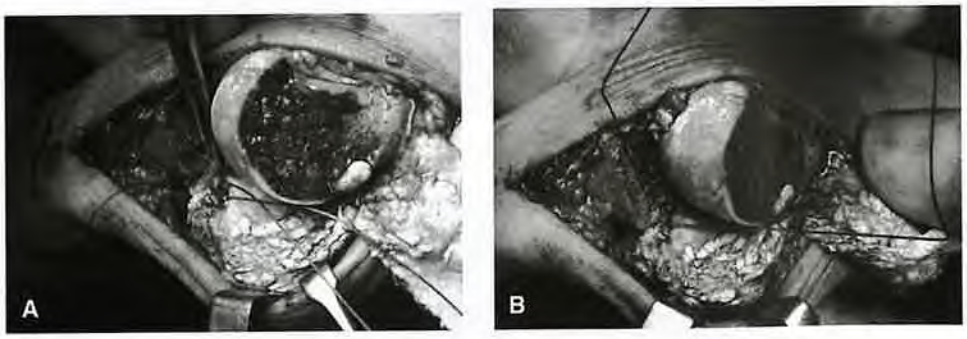

Figure 34.40 Suturing of short flexor tendon to base of the proximal phalanx using 2-0 nonabsorbable suture.

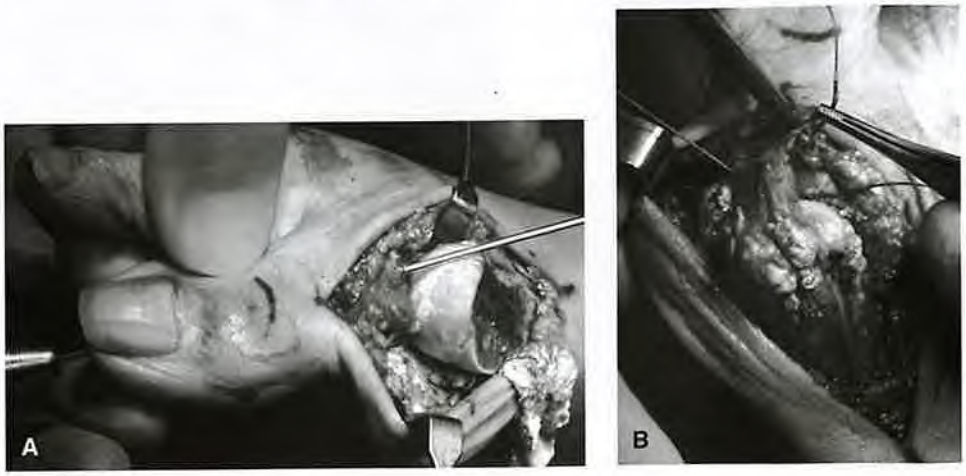

Figure 34.41 K-wire is antegraded from proximal to distal through the hallux.

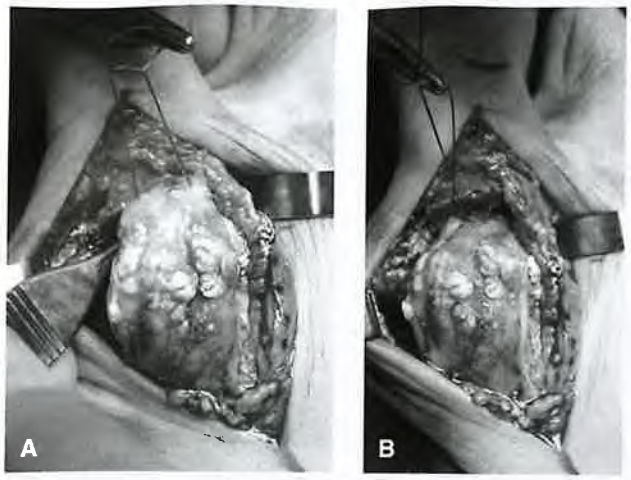

Figure 34.42 Capsule is then used to cover the metatarsal head and held in place using a horizontal mattress suture.

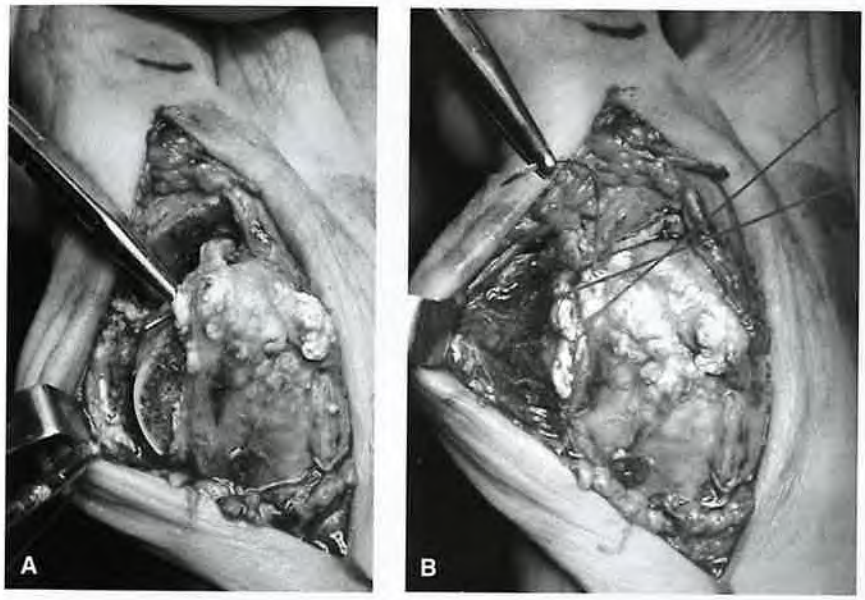

Figure 34.43 Inferior portion of capsule is repaired.

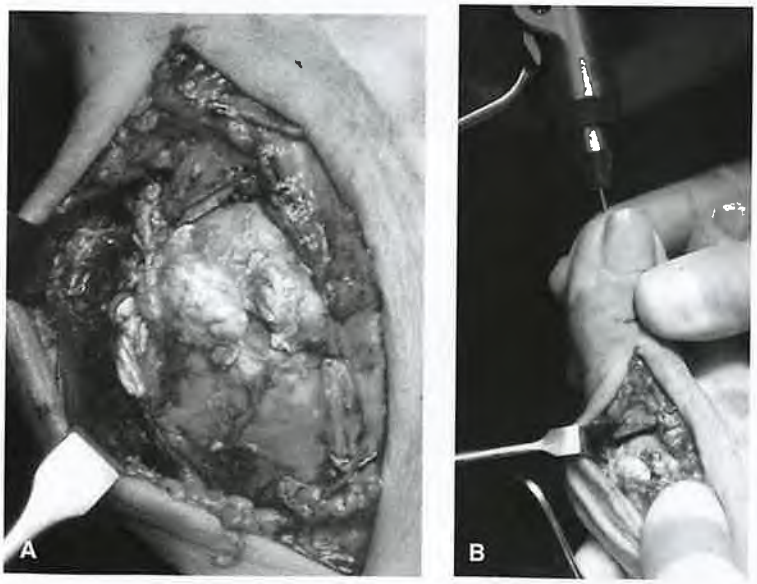

Figure 34.44 While the hallux is distracted to maintain distance between proximal phalanx and metatarsal head, the K-wire is then retrograded into the first metatarsal head.

Figure 34.45 **A,B:** K-wires are placed in two planes to avoid telescoping and frontal plane deviation during the healing process. **C,D:** X-rays reveal K-wires in position.

The patient is allowed weight-bearing to tolerance with a stiff sole postoperative shoe. Patients who have K-wires holding alignment may bathe after complete epithelialization of the incision site. The K-wires are left in place for approximately 6 weeks, at which time they are removed and the patient is encouraged to return to more standard shoe gear (Fig. 34.46). Should the K-wires lose position or need to be removed prior to 6 weeks, a splint can be utilized to maintain position (Fig. 34.47).

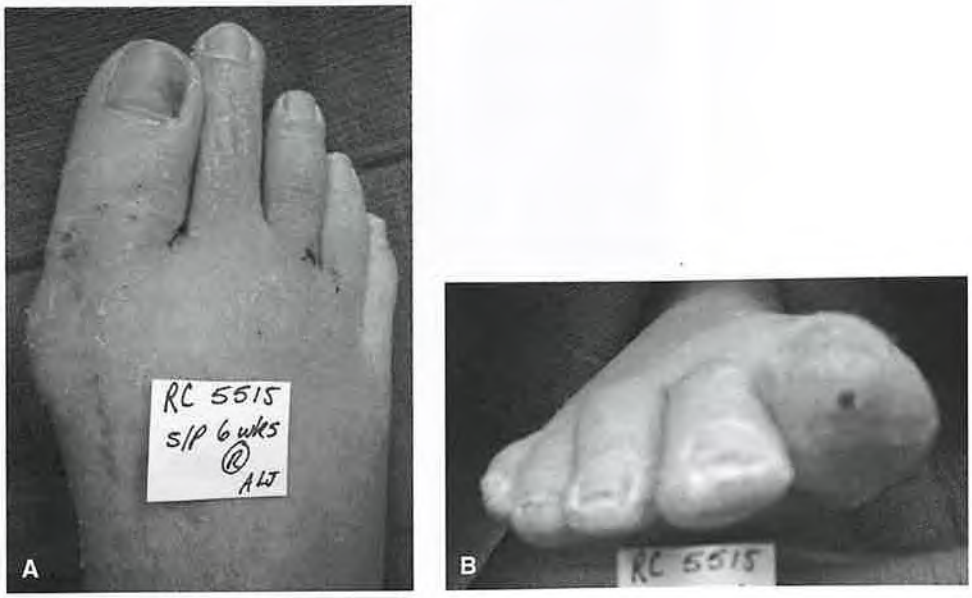

Figure 34.46 Clinical pictures 6 weeks after surgery following K-wire removal.

Figure 34.47 Toe alignment splint.

Complications

Complications of implant arthroplasty generally include acute or latent infection, malalignment of the arthroplasty with or without loosening of the implant, and generation of wear debris with soft tissue or osseous reaction (11,13,16,18–21,88–104).

Postoperative wound infections occur with a statistical frequency whether or not an implant is used. Generally, immediate postoperative wound infections are not a diagnostic dilemma, but foreign bodies are associated with latent or foreign body–centered infections that may be difficult to identify and treat (84). Problems persist as bacteria adhere to the surface of the foreign material hidden in a biofilm layer. Generally, removal of the implant is curative (Fig. 34.48).

Arthroplasty malalignment does occur and generally associated with more severe postoperative deformities. High IM angles must be addressed. Postoperative malalignments typically occur with recurrent hallux abductus with or without actual rotation of the implant or sagittal plane instability of the great toe, which is the resulting deformity at both the hallux IPJ as well as the first MTPJ. Joint malalignments, particularly with component implants, may lead to generation of wear particles, osteolysis, and deformity.

Implant pathology also includes deformation, fatigue fracture, and microfragmentation or wear debris (20). Osteolysis may also be a considerable problem and is associated with metallic as well as polymer implants. Biomechanical derangements

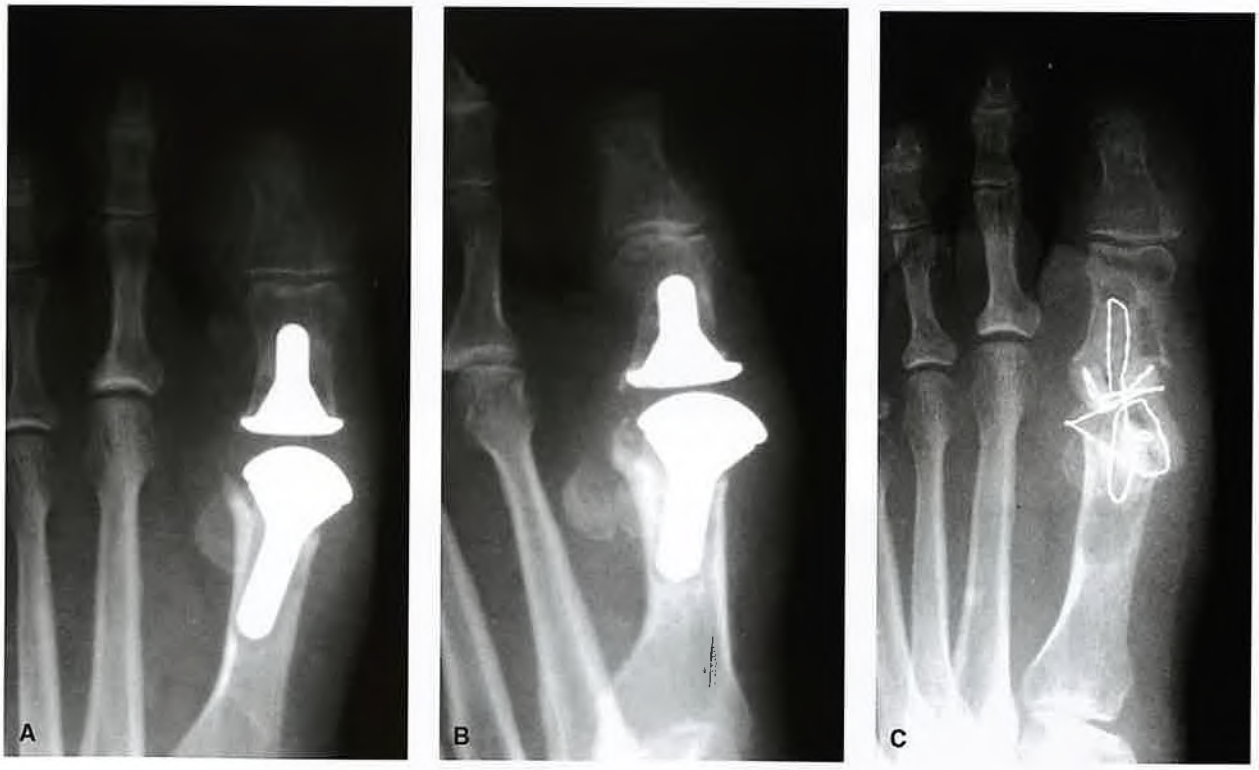

Figure 34.48 Implant arthroplasty is subject to complications usually requiring removal as illustrated by this case of a foreign body–centered infection undiagnosed until revision for chronic pain with unstable joint. **A,B:** Preoperative radiographs show resorptive changes around the implant. Intraoperatively, purulence was noted in tissues, MRSE was cultured. **C:** Antibiotic beads were inserted, and the patient underwent 6 weeks of IV antibiotics.

Figure 34.48 *(Continued)* **D–F:** She was later brought back to surgery for salvage fusion with an autogenous bone graft and plate fixation. **G,H:** Radiographs taken more than a year postoperatively following removal of the plate.

Figure 34.49 **A,B:** Preoperative radiographs of a 68-year-old man with late-stage hallux rigidus who underwent TJR with the Acumed implant. **C,D:** Postoperative radiographs show good alignment, but postoperative ROM was limited likely due to unstable medial column as verified by elevatus on postoperative lateral.

are not uncommon and may be seen in almost any of the reconstructions (Fig. 34.49). TJR was advocated to provide a more biomechanically sound repair but arthralgias and biomechanical difficulties are encountered with similar frequencies as with the other implant arthroplasties. Limited or painful joint motion may occur, or lateral metatarsalgia with medial column insufficiency may occur. This surgeon has seen a perfectly functioning and positioned implant that provides a constant nagging pain to a patient who was treated with removal of the implant and fusion.

Revision of implant arthroplasty must be a consideration as there will always exist a situation when removal and revisionary procedure is necessary (105). A simple rule of thumb is that implant arthroplasties that require more initial bone resections will be more difficult to revise.

CONCLUSION

Long-standing joint deformity and/or arthropathy of the first MTPJ, specifically end-stage hallux valgus or degenerative arthrosis, often requires some type of joint arthroplasty. These procedures are joint destructive in nature, meaning that either one or both sides of the joint are sacrificed (43). This may involve resection arthroplasty with or without an implant or arthrodesis.

Our focus is, of course, implant arthroplasty, which is an adjunct to resection arthroplasty. Resection arthroplasty by itself usually is performed as a Keller-type procedure with resection of the base of the proximal phalanx. This type of procedure is associated with instability of the great toe and or first metatarsal that contribute to a lack of toe purchase and lateral weight transfer. Swanson proposed implant arthroplasty to improve cosmesis, improve joint stability, and increase the likelihood of a reliable degree of joint motion (4,5). And much as with a resection arthroplasty, implant arthroplasty was expected to relieve the pain of joint disease.

Silicone implantation, whether with hemi-implant or a double-stem device, is an interpositional arthroplasty. It is not a joint replacement procedure. Reference to the double-stem hinge as a total implant is inaccurate and confusing but does appear in the literature (106,107). In the late 80s, a revival of the concept of TJR of the first MTPJ began with Richard Koenig (26). Interestingly, at a time of the decline of implant arthroplasty, there followed the development of five total joint implant systems. Several inventors and numerous surgeons then began renewed attempts of TJR (26,108–110). Some good results were reported and there are some among us who experienced difficulties. TJR may have its place in arthrosis of the first metatarsophalangeal joint, but it is yet to be fully defined. TJR as well as interpositional arthroplasty has a place in our surgical armamentarium. We recommend caution and selection of patients that meet criteria. They should be patients wherein other alternatives are more likely to yield a less successful reconstruction.

Obviously, there are better and worse places to implement first MTPJ implants. Either the patient's functional demands are such that the durability of an implant procedure might be questioned or biomechanical faults might likely ensue. Implant arthroplasty as commonly performed today is not perfect, but there have been good results as well as some occasional difficulties encountered. Proper indications must be delineated and above all agreed upon by surgeons. Both the surgeon and patient should have a clear understanding of the goals and objectives of the procedure (111).

Joint arthroplasty, performed either as a resection arthroplasty with or without a joint implant, is still a viable surgical alternative in the patient with long-standing deformity and/or arthrosis of the first MTPJ. Implant arthroplasty, whether interpositional or TJR, is a joint destructive procedure that should be reserved for cases of end-stage arthrosis or nonfunctional and painful first MTPJs.

REFERENCES

1. Ganley JV Lynch FR, Darrigan RD. Keller bunionectomy with fascia and tendon graft. *J Am Podiatr Med Assoc* 1986;76:602–610.
2. Keller W The surgical treatment of bunions and hallux valgus. *N Y Med J* 1904;80:741.
3. Keller W. Further observations of the surgical treatment of hallux valgus and bunions. *N Y Med J* 1912;95:696.
4. Swanson A. Implant arthroplasty for the great toe. *Clin Orthop* 1972;85:75.
5. Swanson A. Implant arthroplasty in disabilities of the great toe. In: *The American academy of orthopaedic surgeons instructional course lectures.* St Louis, MO: CV Mosby, 1972.
6. Weil LS, Pollak RA, Goller WL. Total first metatarsophalangeal joint in hallux valgus and hallux rigidus. *Clin Orthop* 1984;1:103.
7. Kalish SR, McGlamry, ED. The modified Keller hallux valgus repair utilizing Silastic implants. *J Am Podiatry Assoc* 1974;64:761–773.
8. LaPorta GA, Pilla P, Richter KP. Keller implant procedure: A report of 536 procedures using a silastic intramedullary stemmed implant. *J Am Podiatry Assoc* 1976;66:126.
9. Albin RL, Weil LS. Flexible implant arthroplasty of the great toe: an evaluation. *J Am Podiatry Assoc* 1974;64:967–975.
10. Aptekar RG, Davie JM, Cattell HS. Foreign body reaction to silicone rubber: complication of a finger joint implant. *Clin Orthop* 1974;98:231.
11. Bass SJ, et al. Phagocytosis of Silastic material following Silastic great toe implant. *J Foot Surg* 1978;17:70.
12. Caneva R. Postoperative degenerative changes of the metatarsal head following use of the Swanson implant: four case reports. *J Foot Sur.* 1977;16:34.
13. Christie AJ, Weinberger KA, Dietrich M. Silicone lymphadenopathy and synovitis: complications of silicone elastomer prostheses. *JAMA* 1977;237:1463.
14. Coleman DL, King RN, Andrade JD. The foreign body reaction: A chronic inflammatory response. *J Biomed Mater Res* 1974;8:199.
15. Ferlic DC, Clayton ML, Holloway M. Complications of silicone implant surgery in the metacarpophalangeal joint. *J Bone Joint Surg Am* 1975;57:991.
16. Glod D, Frykberg RG. Foreign body reaction in a Dacron-meshed hemi-implant. *J Foot Surg* 1990;29(3):250–252.
17. Kaufman RL, Tong I, Beardmore TD. Prosthetic synovitis: clinical and histologic characteristics. *J Rheumatol* 1985;12:1066.
18. Lemon RA, Engber WD, McBeath AA. A complication of Silastic hemiarthroplasty in bunion surgery. *Foot Ankle* 1984;4(5):262–266.
19. McCarthy DC, Kershisnik W,O'Donnell E. The histopathology of silicone elastomer implant failure in podiatric surgery. *J Am Podiatr Med Assoc* 1986;76:247–265.
20. Vanore J, O'Keefe R, Pikscher I. Complications of silicone implants in foot surgery. *Clin Podiatry* 1984;1(1):175–198.
21. Worsing R, Engber WD, Lange TA. Reactive synovitis from particulate silastic. *J Bone Joint Surg Am* 1982;64:581.
22. Cracchiolo A 3rd, Swanson A, Swanson GD. The arthritic great toe metatarsophalangeal joint: a review of flexible silicone implant arthroplasty from two medical centers. *Clin Orthop Relat Res* 1981;157:64–69.
23. Dobbs B, et al. LaPorta great toe implant. *J Am Podiatr Med Assoc* 1990;80:370–373.
24. Gerbert J, Chang TJ. Clinical experience with two-component first metatarsal phalangeal joint implants. *Clin Podiatr Med Surg* 1995;12:403–413.
25. Johnson KA, Buck PG. Total joint arthroplasty of the first metatarsophalageal joint. *Foot Ankle* 1981;1:307.
26. Koenig RD. Koenig total great toe implant. Preliminary report. *J Am Podiatr Med Assoc* 1990;80(9):462–468.
27. Merkle PF Sculco TP. Prosthetic replacement of the first metatarsophalangeal joint. *Foot Anhle* 1989;9:267–271.
28. Reinherz R, Kent M. Total reconstruction of the first metatarsophalangeal joint by utilizing the Cutter hinged prosthesis: a case study. *J Foot Surg* 1977;16:121.

29. Swanson AB, Lumsden RM, Swanson GD. Silicone implant arthroplasty of the great toe. A review of single stem and flexible hinge implants. *Clin Orthop Relat Res* 1979;142:30–43.
30. Swanson AB, et al. The use of a grommet bone liner for flexible hinge implant arthroplasty of the great toe. *Foot Ankle* 1991;12:149–155.
31. Vanore JV, O'Keefe RG, Pikscher I. Current status of first metatarsophalangeal joint implants. *Foot Ankle Quart* 1995;8(3):121–134.
32. McKeever D, Arthrodesis of the first metatarsophalangeal joint for halux valgus, hallux rigidus and metatarsus primus varus. *J Bone Joint Surg Am* 1952;34:129.
33. Coughlin M. Arthrodesis of the first metatarsophalangeal joint with mini-fixation plate fixation. *Orthopedics* 1990;13:1037–1044.
34. Vanore JV. First metatarsophalangeal joint arthrodesis. In: Oloff LM, ed. *Musculoskeletal disorders of the lower extremities.* Philadelphia, PA: WB Saunders Co., 1994:545–558.
35. Yu GV, Gorby PO. First metatarsophalangeal joint arthrodesis. *Clin Podiatr Med Surg* 2004;21(1):65–96.
36. Brage ME, Ball ST. Surgical options for salvage of end-stage hallux rigidus. *Foot Ankle Clin* 2002;7(1):49–73.
37. Vanore JV. Implants. In: Alan MSD, Banks S, Martin DE, Miller SJ, eds. *McGlamry's comprehensive textbook of foot and ankle surgery.* Philadelphia, PA: Lippincott Williams and Wilkins Co., 2001:373–417.
38. Vanore JV, et al. First metatarsophalangeal joint implant arthroplasty. In: Banks AS, McGlamry ED, Downey MS, eds. *Comprehensive textbook of foot surgery.* Baltimore, MD: Williams & Wilkins, 1992:617–684.
39. Vanore JV, O'Keefe RG, Pikscher I. First metatarsophalangeal joint implant arthroplasty. In: McGlamry ED, ed. *Comprehensive textbook of foot surgery.* Baltimore, MD: Williams and Wilkins Co., 1987.
40. Giza E, Sullivan MR. First metatarsophalangeal hemiarthroplasty for grade 3 and 4 hallux rigidus. *Tech Foot Ankle Surg* 2005;4:2–9.
41. Carpenter B, Smith J, Motley T, et al. Surgical treatment of hallux rigidus using a metatarsal head resurfacing implant: mid-term Follow-up. *J Foot Ankle Surg* 2010:321–325.
42. Sullivan MR. Hallux rigidus: MTP joint arthroplasty. *Foot Ankle Clin North Am* 2009;14:33–42.
43. Vanore JV, Corey sv. Hallux limitus, rigidus, and metatarsophalangeal joint arthrosis. In: Marcinko DE, ed. *Comprehensive textbook of hallux abducto valgus reconstruction.* St. Louis, MO: Mosby-Year Book Inc, 1992:209–241.
44. Title CI, et al. First metatarsal head OATS technique: an approach to cartilage damage. *Foot Ankle Int* 2006;27(11):1000–1002.
45. Fenton CF, Gilman RD, Yu GV. Criteria for joint replacement surgery in the foot. *J Am Podiatry Assoc* 1982;72:535.
46. Brodsky JW, Ptaszek AJ, Morris SG. Salvage first MTP arthrodesis utilizing ICBG: clinical evaluation and outcome. *Foot Ankle Int* 2000;21(4):290–296.
47. Cracchiolo A, et al. Arthroplasty of the first metatarsophalangeal joint with a double-stem silicone implant. *J Bone Joint Surg Am* 1992;74-A:552–563.
48. Moeckel BH, et al. The double-stemmed silicone-rubber implant for rheumatoid arthritis of the first metatarsophalangeal joint. *J Bone Joint Surg Am* 1992;74-A(4):564–570.
49. Pfeiffer WH, Cracchiolo A, Grace DL, et al. Double-stem silicone implant arthoplasty of all metatarsophalangeal joints in patients with rheumatoid arthritis. *Semin Arthroplasty* 1992;3(1):1–24.
50. Berlet GC, Hyer CF, Thomas HL, et al. A soft-tissue interpositional arthroplasty technique of the first metatarsophalangeal joint for the treatment of advanced hallux rigidus using a human acellular dermal regenerative tissue matrix. *Tech Foot Ankle Surg* 2006;5(4):257–265.
51. Berner A, Sage R, Niemela J. Keller procedure for the treatment of resistant plantar ulceration of the hallux. *J Foot Ankle Surg* 2005;44(2):133–136
52. Cleveland M, Winant EM. An end-result study of the Keller operation. *J Bone Joint Surg Am* 1950;32A(1):163–175.
53. Cook KD. Capsular interposition for the Keller bunionectomy with the use of soft-tissue anchors. *J Am Podiatr Med Assoc* 2005;95(2):180–182.
54. Coughlin MJ, Mann RA. Arthrodesis of the first metatarsophalangeal joint as salvage for the failed Keller procedure. *J Bone Joint Surg Am* 1987;69A(1):68–75.
55. Coughlin MJ, Shurnas PJ. Soft-tissue arthroplasty for hallux rigidus. *Foot Ankle Int* 2003; 24(9):661–672.
56. Davies-Colley M. Contraction of the metatarsophalangeal joint of the great toe. *Br Med J* 1887;1:728.
57. Donley BG, Vaughn RA, Stephenson KA, et al. Keller resection arthroplasty for treatment of hallux valgus deformity: increased correction with fibular sesamoidectomy. *Foot Ankle Int* 2002;22(8):699–703.
58. Ioia JV and Jacobs RL. The decompression principle of joint surgery and its application to the Keller bunionectomy. *Iowa Ortho J* 1(1): 13–14
59. Bonney G, MacNab I. Hallux valgus and hallux rigidus. *J Bone Joint Surg Br* 1952;34B(3):366–385.
60. Steinbock G. Joint destructive procedures. In: *Hallux valgus and forefoot surgery.* New York. Churchill Livingstone, 1994:295–306
61. Jordan HH, Brodsky AE. Keller operation for hallux valgus and hallux rigidus: An end result study. *AMA Arch Surg* 586–596
62. Derner R, Goss K, Postowski NH, et al. A plantarflexory-shortening osteotomy for hallux rigidus: a retrospective analysis. *J Foot Ankle Surg* 2005;44(5):377–389.
63. Prasad MG, Shankar NS. Clinical results of Keller's arthroplasty. *Foot* 1998;8:223–225.
64. Blewitt N, Greiss ME. Long-term outcome following Keller's excision arthroplasty of the great toe. *Foot* 1993;3:144–147.
65. Reize P, Schanbacher J, Wulker N. K-wire transfixation or distraction following the Keller-Brandes arthroplasty in hallux rigidus and hallux valgus? *Int Orthop* 2007;31: 325–331.
66. Schneider W, Knahr K. Keller procedure and Chevron osteotomy in hallux valgus: five-year results of different surgical philosophies in comparable collectives. *Foot Anke Int* 2002;23(4):321–329.
67. Vallejo RB, Iglesias MEL, Tirado FV, et al. Use of a Kirschner wire for distraction and capsular flaps in the Keller interpositional arthroplasty. *J Am Podiatr Med Assoc* 2008;98(4):326–329.
68. Rankin ME, Rankin EA. Experience with the Keller bunionectomy. *J Natl Med Assoc* 1996;88(1):33–35.
69. O'Doherty DP, Lowrie IG, Magnussen PA, et al. The management of the painful first metatarsophalangeal joint in the older patient: arthrodesis or Keller's arthroplasty. *J Bone Joint Surg Br* 1990;72B(5):839–842.
70. Hamilton WG, O'Malley MJ, Thompson FM, et al. Capsular interposition arthroplasty for severe hallux rigidus. *Foot Ankle Int* 1997;18(2):68–70.
71. Kolker D, Weinfeld S. Technique tip: a modification to the Keller arthroplasty using interposition allograft. *Foot Ankle Int* 2007;28(2):266–268.
72. Schenk S, Meizer R, Kramer R, et al. Resection arthroplasty with and without capsular interposition for treatment of severe hallux rigidus. *Int Orthop* 2009;33:145–150.
73. Henry APJ, Waugh W. The use of footprints in assessing the results of operations for hallux valgus. *J Bone Joint Surg Br* 1975;57B(4):478–481.
74. Valmassy RL. *Clinical biomechanics of the lower extremities.* St. Louis, MO: Mosby Inc., 1996
75. Shereef MJ, Bejjani FJ, Kummer FJ. Kinematics of the first metatarsophalangeal joint. *J Bone Joint Surg Am* 1986;68A(3):392–398.
76. Vallier GT, Petersen SA, LaGrone MO. The Keller resection arthroplasty: a 13-year experience. *Foot Ankle* 1991;11(4):187–194.
77. Mroczek KJ, Miller SD. The modified oblique Keller procedure: a technique for dorsal approach interposition arthroplasty sparing the flexor tendons. *Foot Ankle Int* 2003;24(7): 521–522.
78. Thomas FB. Keller's arthroplasty modified. In: Hetherington VJ, ed. *J Bone Joint Surg Br* 1962;44B(2):356–365.
79. Sherman KP, Douglas DL, Benson MKD. Keller's arthroplasty: Is distraction useful? *J Bone Joint Surg Br* 1984;66B(5):765–769.
80. Roukis TS, Landsman AS, Ringstrom JB, et al. Distally based capsule-periosteum interpositional arthroplasty for hallux rigidus. *J Am Podiatr Med Assoc* 2003;93(5):349–366.
81. Cavalcante ML, Rodrigues JC, Mattar R. Mechanorecptors and nerve endings of the triangular fibrocartilage in the human wrist. *J Hand Surg Am* 2004;29(3):432–435.
82. Townley CO, Taranow WS. A metallic hemiarthroplasty resurfacing prosthesis for the hallux metatarsophalangeal joint. *Foot Ankle* 1994;15:575–580.
83. Gristina AG, Jennings RA, Naylor PT, et al. Comparative in vitro antibiotic resistance of surface-colonizing coagulase-negative staphylococci. *Antimicrob Agents Chemother* 1989.
84. Gristina AG. Biomaterial-centered infection: microbial adhesion versus tissue integration. *Science* 1987;237:1588–1595.
85. Gupta S, Mallya N. TOEFIT-PLUS(TM)-replacement-of-the-first-metatarsophalangeal-joint-of-the-first-toe: a-short-term-follow-up-study. *Foot* 2008;18:20–24.
86. Barwick TW, Talkhani IS. The MOJE total joint arthroplasty for 1st metatarso-phalangeal osteoarthritis: a short-term retrospective outcome study. *Foot* 2008;18:150–155.
87. Chee YH, Clement N, Ahmed I, et al. Functional-outcomes-following-ceramic-total-joint-replacement-for-hallux-rigidus. *J Foot Ankle Surg* 2009.
88. Arenson DJ, Weil LS, Aseptic necrosis: an unusual cause of silastic (Swanson) implant failure: a case report. *J Am Podiatry Assoc* 1979;69:616.
89. Cook SD, Beckenbaugh RD, Redondo J, Popich LS, et al. Long-term follow-up of pyrolytic carbon metacarpophalangeal implants. *J Bone Joint Surg* 1999;81(5):635–648.
90. Deheer DH, et al. Particulate synovitis: a complication of total joint arthroplasty. *Foot Ankle Quart* 1995;8(3):109–120.
91. Feith R. Side-effects of acrylic cement implanted into bone. *Acta Orthop Scand* 1975;161(Suppl):315.
92. Ferdini R, Schoppe K, Wolbert E. Silicone implants of the basal joint of the big toe. A critical 10 year study. *Z Orthop Ihre Grenzgeb* 1988;126(6):606–608.
93. Galante JO, et al. The biologic effects of implant materials. *J Orthop Res* 1991;9:760–775.
94. Gordon M, Bullough PG. Synovial and osseous inflammation in failed silicone-rubber prostheses: a report of six cases. *J Bone Joint Surg Am* 1982;64:574.
95. Jay RM, Schoenhaus HD. Complications in implant arthroplasties for the osteoarthritic joint. *J Am Podiatry Assoc* 1982;72:248.
96. Kossovsky N, et al. Delayed hypersensitivity to silicone products. In: Kossovsky RKaN, ed. *Materials sciences and implant orthopedic surgery.* Dordrecht, Netherlands: Martinus Nijhoff Publishers, 1986:285–305.
97. Lim WT, Landrum K, Weinberger G, Silicone lymphadenitis secondary to implant degeneration. *J Foot Surg*, 1983;22:243.
98. McKellop, HA, Campbell P, Park SH. The origin of submicron polyethylene wear debris in total hip arthroplasty. *Clin Orthop* 1995;311:3–20.
99. Nenad D. Postoperative osteophytic activity: a case report. *J Foot Surg* 1978;17:31.
100. Poss K, KE, Kaplan G. Osteomyelitis associated with joint implant rejection: a case history. *J Foot Surg* 1979;18:112.
101. Sethu, A, D'Netto DC, Ramakrishna B. Swanson's silastic implants in great toes. *J Bone Joint Surg Br* 1980;62-B(1):83–85.
102. Shereff MJ, Jahass MH. Complications of silastic implant arthroplasty in the hallux. *Foot Ankle* 1980;1:95.
103. Verhaar J, et al. Bone reaction to silicone metatarsophalangeal joint-1 hemiprosthesis. *Clin Orthop* 1989;245:228.
104. Vanore JV, O'Keefe RG, Pikscher I. Silastic implant arthroplasty: Complications and their classification. *J Am Podiatry Assoc* 1984;74:423.

105. Vanore JV. *Revision of the problematic 1st mpj implant. in update 2000.* Atlanta, GA: The Podiatry Institute Publishing, Inc., 2000.
106. Mondul M, Jacobs PM, Caneva RG, et al. Implant arthroplasty of the first metatarsophalageal joint: a 12 year retrospective study. *J Foot Surg* 1985;24(4):275–279.
107. Arenson DJ, Proner SC. A clinical evaluation of the total first metatarsophalangeal joint prosthesis: the use of footprints in assessing foot contact. *J Foot Surg* 1981;20:117.
108. Zang K, Askari S, Fuller A, Seuferling C. First metatarsal pathology: can an Implant provide a long-term solution? *Pod Today* 2006:35-43.
109. Borovoy M, Gray W, Rinker A. Total replacement of the first metatarsophalangeal joint. *J Foot Surg* 1983;22:159.
110. Wenger R, Whalley R. Total replacement of the first metatarsophalangeal joint. *J Bone Joint Surg Br* 1978;60:88.
111. Turnbull T, Grange W. A comparison of Keller's arthroplasty and distal metataral osteotomy in the treatment of adult hallux valgus. *J Bone Joint Surg Br* 1986;68B(1): 132–137.

CHAPTER

36

Molly A. Judge

Complications in Hallux Abducto Valgus Surgery (Excluding Hallux Varus)

Recurrence of deformity can occur in the face of any procedure performed for the correction of the hallux abducto valgus (HAV) deformity (1–6). In general, these procedures are selected based upon their ability to address either structural or dynamic components of the deformity depending upon the presumptive etiology. It is common to perform both an osseous correction (structural rearrangement) and a soft tissue balancing procedure (dynamic rebalancing) in an attempt to address combination deformities. The recurrence rate after the most common of HAV procedures, the distal metaphyseal osteotomy (DMO), has been reported between 1.85% and 10% (2,3,6). Revision surgery pursued after a combination of procedures has been performed can be challenging since the normal anatomy of both soft tissue and bone has been altered. A second dissection in the same location may well increase the risk of nerve entrapment, the development of a painful or unsightly scar, vascular compromise, and wound and bone healing complications as well as the risk of chronic edema, nerve irritation or entrapment, and the development of chronic pain. In addition, as in any surgical procedure, revision surgery necessarily includes the risk of infection, overcorrection and undercorrection of the deformity.

EVALUATION

THE SUBJECTIVE COMPLAINT

While conservative measures should always be exhausted, many patients suffering from complications of HAV surgery fail at this effort when major structural complications such as hallux varus or painful sagittal plane deformities of the first ray exist. To ensure that the patient's goals and expectations are understood, it is prudent to begin with a cursory exercise in which patients are asked to point to the target of their most important discomfort and to describe their pain in that area thoroughly. Is the target of tenderness at the first metatarsophalangeal joint (MTPJ), at the hallux interphalangeal joint (HIPJ), beneath the metatarsal head, or in a combination of areas? Often, the target of tenderness is actually beneath the second MTPJ due to the inability of the first MTPJ to bare weight. Once the location of the chief complaint is determined, the type or quality of the pain is elucidated. Certain descriptions of pain are suggestive of the etiology. Descriptors such as tingling, numbness, burning, and pins and needles sensations are often associated with entrapment neuritis or sensory neuropathy indicating that a nerve decompression may be required as a sole procedure or as an adjunctive portion of the surgical plan. When the complaint includes pain about the inferior aspect of the first MTPJ, this may indicate an abnormal articulation with a sesamoid bone or fibrous adhesions between the plantar plate and the sesamoids and therefore may require a release of the capsular and sesamoidal structures about the periphery of the MTPJ. This can result from an overaggressive medial eminence resection leaving a painful articulation between the tibial sesamoid and the inferior medial aspect of the metatarsal head (Fig. 36.1). When the patient describes a painful grinding with motion of the joint, loose bodies or intra-articular damage is likely and suggests degenerative changes of one or both chondral surfaces of the MTPJ. Such crepitation and dysfunction may indicate the need for an arthroplasty if not a joint destructive procedure depending upon the nature and extent of the chondral defects present. Tightness, cramping, and spasm of the extensor hallucis longus (EHL) tendon are often associated with lateral bow stringing of the structure and a hallux over- or underriding the second digit. These structural aberrations suggest persistent transverse plane (abduction) deformity with or without frontal plane (valgus) rotation of the hallux.

CLINICAL EVALUATION

Evaluation of recurrent or residual HAV should be performed in a stepwise fashion to most consistently identify the full extent of deformity and dysfunction. Clinical evaluation includes both weight-bearing and non-weight-bearing examinations of the foot and ankle, identical to that performed prior to first-time elective bunion surgery. The stance evaluation is the key to determining the first ray position and alignment under normal weight-bearing conditions. Weight-bearing assessment will reveal the true nature of the deformity be it structural, dynamic, or a combination of both. Hallux varus and other planar deformities of the first ray may be unmasked in the weight-bearing condition (Fig. 36.2).

So too the presence of compensatory digital deformities, such as flexor or extensor substitution and flexor stabilization, can shed light onto additional components of the functional problem. When thoroughly conducted, this portion of the clinical evaluation will demonstrate the true nature of the deformity and muscle–tendon imbalances, which will have a weighty impact on procedure selection. When the weight-bearing condition reveals shifting of load to the lesser MTPJs, it becomes obvious that the first MTPJ is dysfunctional (Fig. 36.3). The gait examination can be done strictly by visual observation or with the assistance of force plates or other computer-assisted modalities. From a practical perspective, the emphasis here will be on clinical evaluation without the benefit of additional technical support. When watching patients, it is best to be methodical and review the patients from head to toe as they walk away and walk toward their starting point. Noting posture, position, and alignment of the axial and appendicular skeleton will provide

Figure 36.1 Radiographic evaluation after an overly aggressive medial eminence resection: Here the hallux is subluxed medially and that the medial metatarsal head impinges within the central aspect of the articular cup of the hallux. With the absence of the fibular sesamoid, this complex is extremely unstable and the medial hallux base articulates with the tibial sesamoid. This complication often results in a painful articulation between the tibial sesamoid and the inferior medial aspect of the metatarsal head. The second digit is subluxed medially as well, as this will not reduce with correction of the hallux position alone.

the most comprehensive assessment. This exam should reveal a predictable heel to toe gait pattern with stride length and cadence that falls into normal parameters given the patients habitus. Taking note of shoulder, hip, and knee alignment should prompt adjunctive orthopaedic consultations as necessary. Propulsion off the first MTPJ should be easily discernable if the first ray is functioning properly. Dysfunction is obviated when propulsion is interrupted, as is the case when an abductory twist is present or if antalgia, vaulting, or splinting away from the first MTPJ is seen during the gait examination. A completely apropulsive gait will be evident when the first MTPJ is significantly subluxed, dislocated, or impinged. In addition, the weight-bearing exam reveals the extent of first metatarsal head prominence whether it is dorsal, medial, plantar, or a combination, and this helps to clarify the structural deformity present such as first metatarsal elevatus and hallux limitus, sesamoid apparatus dysfunction, or end-stage first MTPJ subluxation.

The non-weight-bearing evaluation is an equally important component of the physical examination. When assessing the motion of the first MTPJ transverse, frontal and sagittal planes are considered since the deformity is typically multiplanar. Whether or not the deformity is reducible is an important clue to whether the condition is flexible enough to be corrected with revision of the original procedure (assuming a DMO and soft tissue balancing) or if an alternate procedure is warranted. The examination of the first MTPJ begins with stabilizing the first ray at the metatarsal neck and manipulating the hallux at the MTPJ level. With the foot at 90 degrees to the ankle and the subtalar joint in neutral position, the hallux is manipulated into a rectus position on the metatarsal head and sagittal plane motion is assessed in both dorsiflexion and plantarflexion. It is important to load the foot prior to evaluation to eliminate the effects of hypermobility and masking of structural deformities such as metatarsus primus elevatus. When motion is absent, limited in dorsiflexion, or restricted to solely plantarflexion, it is suspected that there is a metatarsus primus elevatus present and further study is required. If the first MTPJ motion is limited with a bone-on-bone end range of motion or when crepitation is present, a degenerative condition is suspected and significant articular defects are likely. If there is limitation with the joint held in a congruous position and a spongy end range of motion is evident, then the soft tissue structures remain suspect and revision of the lateral release and/or adductor tendon transfer may be required. If the medial column exhibits hypermobility and the first metatarsocuneiform joint (MCJ) is excessively mobile, then the peroneus longus muscle becomes ineffective at both plantarflexing the first ray and abducting the forefoot, allowing the first ray to deviate medially and rotate into varus (4,5).

To determine the transverse plane deformity, again, the first metatarsal is stabilized at the metatarsal neck. With the hallux placed into neutral position on the metatarsal head, the range of motion of the first MTPJ is then assessed. If the motion at the first MTPJ remains unrestricted with the joint in a congruous position, then the deformity is considered fully reducible and soft tissue rebalancing may be considered alone or in combination with an osseous procedure. If the joint is irreducible, then structural deformity or malposition of the first metatarsal is likely (e.g., meaningful metatarsus primus varus, adductus or a fixed sagittal plane deviation of the metatarsal bone) and an osseous procedure is probably required. If the motion at the first MTPJ is restricted due to a plantarflexed or dorsiflexed first ray segment, then structural realignment including a sagittal plane osseous procedure will be required. This can be achieved via osteotomy or a joint destructive procedure depending on the severity of the metatarsal angulation and the integrity of the articular surfaces. The decision to perform a proximal or distal procedure in this instance is determined by the degree of sagittal plane correction needed to achieve adequate first ray mobility, and radiographic evaluations will assist in making that determination.

When sagittal plane motion is restricted in the direction of dorsiflexion and point tenderness exists beneath the inferior aspect of the hallux base and/or the first metatarsal head, the sesamoid apparatus may be adhered warranting an aggressive release of both the capsular and ligamentous structures about the first MTPJ. Dorsal impingement occurs when the metatarsal head has been shifted into an elevated position and restricts sagittal plane motion. With impingement, osteophytic degeneration may prompt crepitation due to the formation of loose bodies.

Close inspection of the local anatomy will reveal whether or not an exaggerated length or angulation of the proximal phalanx

Figure 36.2 **A:** The stance evaluation often reveals more significant deformity than that noted in the off-weight-bearing exam in the study of hallux varus deformity. While the adduction deformity of the hallux is appreciable in the non-weight-bearing condition, loading the foot and ankle reveals a significant flexion deformity at the HIPJ with tension and medial drift of the EHL tendon. The second digit has developed a similar deformity in this long-standing case of hallux varus. **B:** Dorsoplantar radiograph reveals the plantar-medial subluxation of the hallux in addition to the dislocation of the right hallux base and a valgus tilt of the left hallux. Notice the lateralward bowing of the metatarsal bones and the cystic degeneration at the MCJ indicative of the retrograde force and degenerative bone change throughout the first ray segment. There is a loss of normal trabeculations within the metatarsal head and the phalangeal base suggesting at least the presence of a generalized osteopenia. This low bone mineralization is important to consider when planning for osseous procedures, and a modified fixation strategy may be required to adequately stabilize the bone.

Figure 36.3 **A:** Clinical evaluation of a failed silicone implant in a 30-year-old physical therapist. Only during the weight-bearing examination is the crossover position of the hallux realized. The non-weight-bearing posture of the hallux is exaggerated by contractures of the EHL tendon and lateral joint capsule. The adduction deformity of the lesser digits is reflective of the non-weight-bearing condition of the first MTPJ and the compensatory flexor stabilization that takes place as the long flexors and quadratus plantae gain mechanical advantage. **B:** The stance evaluation of the same patient reveals the lateral overloading as the first MTPJ is unable to bear weight and spontaneously shifts the forefoot into varus splinting away from the painful joint. Notice that the varus attitude of the forefoot is so powerful that it further the shifts the rear foot into varus inverting the calcaneus.

is contributing to the residual hallux abduction significantly. The influence of the HIPJ deformity may have been underestimated previously and may contribute to residual or recurrent deformity. If excessive length and abduction of the proximal phalanx are a deforming factor, a basilar phalangeal osteotomy such as an Akin procedure should be considered as this angular deviation creates a retrograde force that exacerbates the HAV deformity (6).

Mobility or laxity at the level of the first metatarsal cuneiform joint (MCJ) and the medial aspect of the naviculocuneiform joint should be assessed to determine if in fact there is a more proximal joint contributing to the recurrence of the hallux abductus deformity (7–9). If the MCJ is semirigid or immobile, then it may be impossible to reduce the transverse plane deformity of the metatarsal, leaving the sesamoid apparatus rotated in a lateral position as compared with the metatarsal head. Should excessive laxity exist at this joint level, the incidence of recurrent HAV deformity is predictable (10). Plain radiographs may reveal an abnormal angulation of the articular facets at the first MCJ, which is felt to be contributory to hypermobility in the proximal first ray (11,12). While it is generally understood that the primary source of motion within the first ray during propulsion occurs at the medial naviculocuneiform joint, the precise clinical measurement of this joint motion remains difficult to perform and even more difficult to reproduce in everyday practice (13,14). Normal parameters of motion within the medial column have been defined as 12.3 degrees at the medial naviculocuneiform joint and 5 degrees at the first metatarsocuneiform joint (13). Should the clinical exam reveal increased mobility at these joint levels in the face of a recurrent HAV deformity, strong consideration for selecting a proximal medial column arthrodesis is suggested. This may include arthrodesis of one or both of the most proximal medial column joints: the metatarsocuneiform joint and/or the naviculocuneiform joint.

RADIOGRAPHIC EVALUATION

Weight-bearing radiographs obtained in multiple orthogonal planes, in addition to oblique and axial views of the forefoot, will elucidate the degree of intra-articular derangement. The intermetatarsal angle (IMA) and associated length patterns of the first metatarsal and proximal phalanx are important radiographic parameters in determining the need for structural correction. Should the length of the first metatarsal bone be insufficient to maintain adequate weight-bearing function, sub two transfer lesions may be present.

A lateral view of the first MTPJ often reveals derangement such as joint space narrowing, periarticular osteophytes, or an elevated metatarsal (or elevated metatarsal head after a DMO procedure) position that may not be appreciated in the clinical exam. It should be noted that poor technique when positioning the x-ray tube head for the lateral radiograph can create a virtual metatarsal elevatus; for example, when the tube head is positioned 10 degrees caudal to the lateral foot, the first ray will appear to be elevated (Fig. 36.4). The tube head must be positioned parallel to the weight-bearing surface and perpendicular to the lateral foot to reveal the true angular relationship between the first and second rays. When there is a divergence between the first and second dorsal cortices of the metatarsal bones, the question becomes whether the deformity is positional, as in a forefoot varus, or if it is structural and due to deformity of the bone itself (15). Both intrinsic and extrinsic deformities have the potential to be nonreducible and so either may require an osseous procedure for correction. Often as a complication of HAV surgery, the first metatarsal may be elevated due to an intrinsic change in bone structure. This iatrogenic deformity will mandate an osseous procedure when the degree of elevatus disrupts joint function (15,16) (Fig. 36.5). Once the presence of a first metatarsal elevatus has been identified, a stress lateral radiograph can be used to evaluate whether

Figure 36.4 Lateral weight-bearing radiograph with the tube head directed upward 10 degrees (dorsally). Note the amount of separation of the first and second metatarsals, while the angular relationship between these two bones remains constant. (Reprinted from Camasta C. Radiographic evaluation and classification of metatarsus primus elevates. In: *The Podiatry Institute's update '94.* Tucker, GA: The Podiatry Institute, 1994:122–127, with permission.)

the deformity is reducible allowing adequate joint function. This weight-bearing view will help to determine the extent to which the first MTPJ can be reduced and the degree of plantarflexion, if any, that will be required to restore joint function (Fig. 36.6).

Determining whether the first MTPJ is deviated, subluxed, or congruent or if an abnormality of the proximal articular set angle (PASA) is present is an integral exercise in determining the contributory features of joint malalignment (17). With close inspection of the dorsoplantar (DP) film, the morphology of the articular surface and condition of the subchondral plate can be estimated considering the presence of sclerotic changes and irregularities about the metatarsal head and phalangeal base. When the distal-most aspect of the metatarsal head appears skewed, the cartilage is suspected to be deviated. While cartilage itself is not visible on plain radiographs, the position and alignment of the subchondral bone lend insight as to whether there is an angular deformity of this surface. Often, the appearance of an abnormal PASA is overestimated by plain radiographs, but when intraoperative findings conclude that cartilage malalignment exists, a cartilage realignment procedure will be necessary to achieve a congruous joint (Fig. 36.7). Should there be significant evidence of subchondral cystic degeneration, sclerosis, unusual derangement in morphology, or literal collapse of the metatarsal head, a dysvascular condition is suspected and further study may be required.

Figure 36.5 Outline of the first and second metatarsal, defining the dorsal cortex of each bone. (Reprinted with permission from Camasta C. Radiographic evaluation and classification of metatarsus primus elevates. In: *The Podiatry Institute's update '94.* Tucker, GA: The Podiatry Institute, 1994:122–127, with permission.)

If there is serious concern regarding perfusion to the forefoot, then noninvasive vascular studies such as pulse volume recordings, photoplethysmography, ankle–brachial index, arterial Doppler and transcutaneous oxygen pressure ($TCPO_2$) measurements, and vascular consultation are warranted. Ancillary imaging via magnetic resonance imaging (MRI) or nuclear medicine imaging (NMI) will demonstrate whether healthy perfusion is evident or if a dysvascular condition exists. Of added benefit is the fact that both modalities can be used to rule out the coincidence of an infectious process. Should an infection be identified, a staged procedure is required to eradicate infection before definitive structural correction is pursued. In this instance, the emphasis is on expertly obtained bone and soft tissue cultures to confirm the presence of infection and antibiotic sensitivity when it exists. Ascertaining this information is critical prior to procedure selection. When chronic edema, discoloration, unusual coolness, or cyanosis exist, it is prudent to pursue vascular consultation with the benefit of noninvasive vascular testing including $TCPO_2$ measurements to assess healing potential for the forefoot and digits. Vasospastic conditions can impair the ability of bone to heal, and prophylactic vasodilatory medications can be used during the perioperative period to override this condition. Cold water immersion stress studies can be completed to determine the significance of this condition when it exists (18–20). Identification of decreased perfusion and reduced healing potential will increase the risk of developing a chronic nonhealing wound and may prompt serious postoperative complications threatening more proximal amputation.

Cortical hypertrophy of adjacent metatarsal shafts 2 and 3 may also reflect the lateral transfer of weight-bearing away from the first MTPJ indicating stress fractures or at least stress deformation of the metatarsal(s). This finding suggests that a reconstructive procedure to restore weight-bearing function of the first ray is in order. This is often the case when the first ray is shortened and/or elevated resulting in first MTPJ dysfunction and compensatory weight transfer to the lesser metatarsal phalangeal joints. Understanding the extent to which the length pattern of the first ray contributes to dysfunction is critical to procedure selection. The metatarsal parabola can be readily evaluated on the dorsal plantar radiograph, and the presence of a shortened first ray segment is often a harbinger for the need of a modified distal osteotomy technique or in more severe cases of shortening other lengthening procedures, which may require bone graft material (autogenous or allergenic) or the callus distraction (bone transport) technique for restoring weight-bearing potential to the great toe joint. Each of these special techniques will shift the risk:benefit ratio into a negative direction since these procedures are more complex and their outcomes are less predictable than other more traditional HAV correction techniques.

The radiographic position of the sesamoid apparatus as we have come to learn is most reflective of a malposition or residual deviation of the metatarsal head medially (21) and is often accompanied by significant lateral contractures due to

Figure 36.6 Radiographic evaluation in the DP (**A**) and stress lateral (**B**) views reveal a mildly elevated position of the first metatarsal head after a DMO; however, this does not interfere with weight-bearing function.

insufficient capsular and ligamentous release or from adhesion and fibrosis due to previous surgery. Performing a sesamoid axial radiograph will reveal whether or not the sesamoid position is actually associated with incongruence at the level of the cristae within the sesamoid apparatus (22). This view is particularly helpful when considering the need for revisional lateral release and mobilization of the intrinsic musculature (Fig. 36.8). When there is congruency of the sesamoids and the cristae as seen on the forefoot axial (aka sesamoid axial), a revisional lateral dissection may be avoided.

PROCEDURE SELECTION

Complications occurring during the index procedure in correcting the HAV deformity are addressed immediately during surgery. While there are a host of potential complications that can occur, misadventures in distal metaphyseal osteotomies are often due to poor planning and placement of the osteotomy itself. The nuances of creating the V osteotomy have been detailed to include proper positioning of the osteotomy within the metatarsal head to avoid placing in the cuts too far proximal or distal within the metatarsal head as each extreme in positioning carries with it different potential complications (23). When placed too far proximally, a large amount of the osteotomy rests in diaphyseal bone and so has a higher potential for nonunion or malunion of bone. Should the osteotomy be made too far distal, the potential for splitting the metatarsal head and creating an intra-articular fracture is a reality (Fig. 36.9).

Procedure selection is based upon the nature of the residual deformity and dysfunction. If an appropriate procedure was selected initially, then revision surgery may be a matter of simply performing the same in a more aggressive manner. Revision surgery for overcorrection may be a matter of reversing the

Figure 36.7 **A:** Dorsoplantar view reveals cartilage malalignment of the metatarsal head associated with residual/recurrent hallux abductus after soft tissue rebalancing. Often, this radiographic parameter does not correlate well with intraoperative findings, and so it is prudent to perform the intraoperative evaluation prior to selecting a cartilage realignment procedure. Notice the short first metatarsal, the long proximal hallux phalanx, and residual metatarsus adductus as concomitant deforming forces in this recurrence of HAV. **B:** This intraoperative photo reveals a high angulation PASA that deviates laterally away from the hypertrophic medial eminence. **C:** Intraoperative photo. When recurrent juvenile HAV deformity develops after a failed proximal metatarsal osteotomy, it becomes apparent that culprits for recurrence are the failure to perform a lateral interspace release and tendon balancing as well as failure to address a significantly increased PASA. Here the axis guide for a medially based wedge osteotomy is created within the sagittal plane of the distal metaphyseal region of the metatarsal head. With the osteotomy scored, the design uses a proximal horizontal line perpendicular to the metatarsal shaft and a short oblique to create approximately 10-degree wedge to reduce the lateral deviation of the cartilage. **D:** With provisional fixation in place using 2.0 Ethilon, reduction of the deformity is realized creating a congruous alignment at the first MTPJ. Fixation can be completed using simple techniques such as suture, cerclage wire, staples, or K-wires. The use of two points of fixation oriented at 90 degrees is preferred.

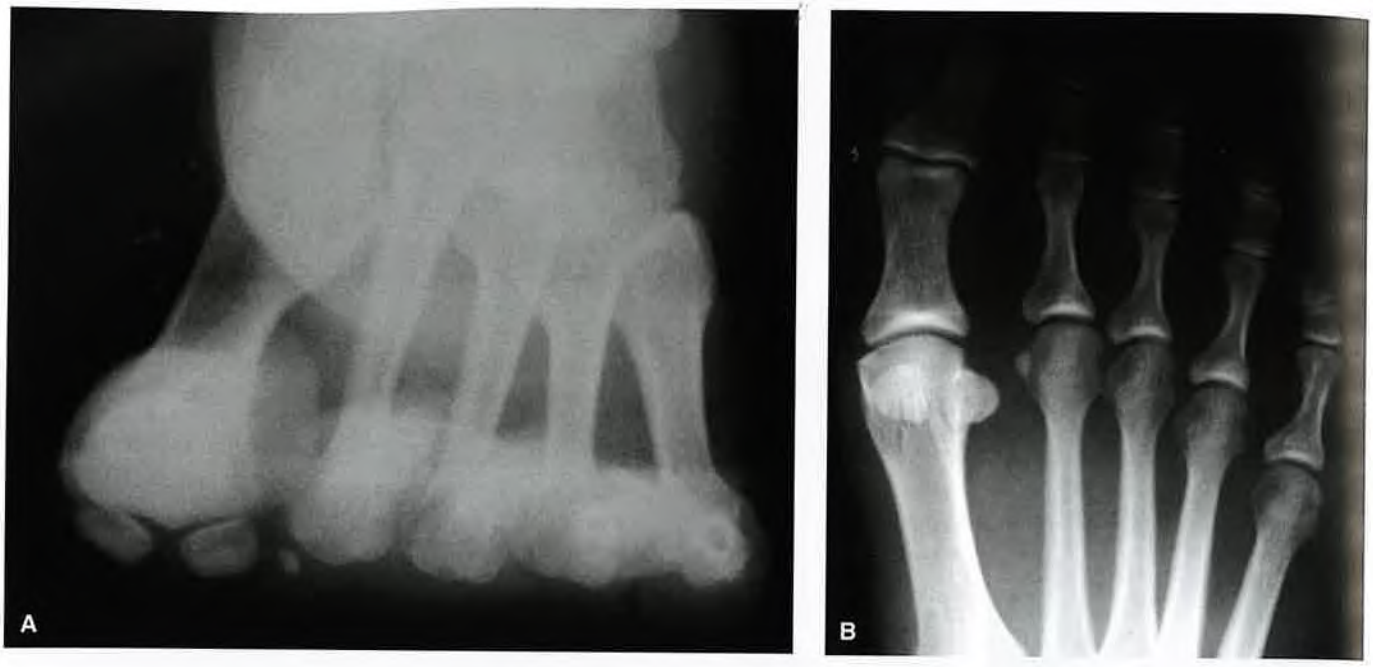

Figure 36.8 **A:** Sesamoid axial view reveals congruency of the cristae and the lateral sesamoid. **B:** Contrast that with the deviated sesamoid position noted on the DP view, in which the fibular sesamoid appears to be significantly rotated into the first interspace. Metatarsus primus varus rotation contributes to this radiographic discrepancy.

original procedure to affect a more appropriate structural or dynamic correction of deformity whichever the case may be. The original procedure may have compromised the condition of bone, intrinsic musculature, ligaments, neurovascular elements, or a combination of these, and for that reason, revision surgery always carries a worse risk:benefit ratio than the initial procedure. Should there be evidence of significant neurovascular compromise, alternate medical consultations should be pursued in advance of conducting revision surgery. Any history or overt evidence of complex conditions such as reflex sympathetic dystrophy or chronic regional pain syndrome should be considered a contraindication to further surgery and merits referral to a neurovascular specialist or pain management expert. When these conditions exist, it is wise to refer the patient for a second opinion as a precursor to any further consultations for revisional surgery.

The types of surgical procedures available in addressing complications of HAV surgery are no different than those available for the initial surgery, and they fall into a number of categories including reconstructive and joint destructive procedures. Procedures designed to salvage function of the first ray segment include the following. Joint destructive procedures such as implant arthroplasty of the first MTPJ are reserved for discussion in an alternate section of this text.

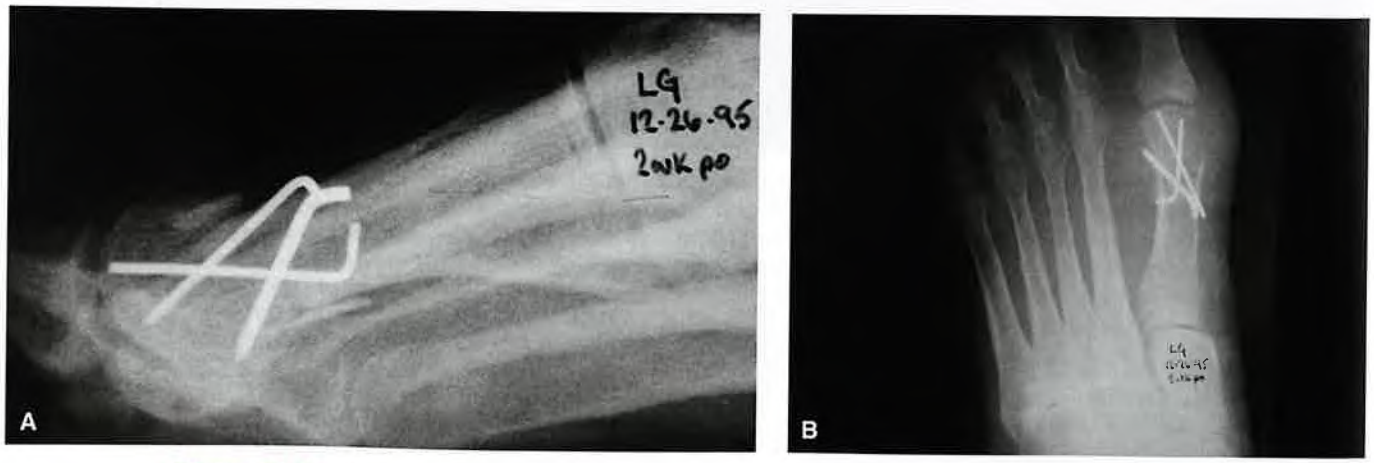

Figure 36.9 **A:** Lateral radiograph reveals three points of fixation to stabilize the split metatarsal head that resulted from an extremely distal placement of the V osteotomy. When the apex of the V is placed too far distal, there is a risk for fracture through the distal metatarsal head. The resulting intra-articular fracture is associated with a high incidence of degenerative joint disease. **B:** Dorsoplantar radiograph demonstrates the excessive shortening that can result when the metatarsal head is inadvertently split as a complication in HAV surgery.

Reconstructive procedures for residual HAV deformity

- Soft tissue and tendon balancing procedures
- Phalangeal osteotomy of the hallux
- Distal first metatarsal osteotomies
- Proximal first metatarsal osteotomies

*Joint destructive procedures for residual HAV deformity**

- Metatarsal phalangeal joint arthroplasty
- Metatarsal phalangeal joint arthrodesis
- MCJ arthrodesis

EARLY COMPLICATIONS

In the early postoperative period, within the first 21 days, soft tissue adhesion and fibrosis do not significantly interfere with reduction of the deformity. In this early period, bone healing consists of blood clot formation that is gradually replaced by highly vascular connective tissue. This connective tissue becomes infiltrated by fibrocartilage over time and develops into a provisional bone callus. At this early stage, the callus serves as a flexible bone bridge not yet ossified and is relatively malleable. Complications that occur during the first few weeks after surgery are often due to overt trauma or patient noncompliance. This situation is met when the patient experiences either unexpected trauma or is grossly negligence in self-care (e.g., another person accidently stepping on the patients' foot after recent HAV surgery) or when unusual weight-bearing activities (e.g., aggressive walking, running, deep squatting, ladder climbing, or prolonged kneeling) cause disruption of the osteotomy or disturb soft tissue balance. In these circumstances, there are three principal goals to be achieved to salvage the function of the first ray: (a) evacuation of hematoma, eradication of infection, and resolving incision dehiscence; (b) open reduction and internal fixation (ORIF) of the disrupted bone with or without bone graft; and (c) revision of soft tissue rebalancing such as revising the medial capsulorrhaphy or adductor tendon transfer depending on the original procedure performed. Each may be a necessary adjunctive procedure in circumstances that arise unexpectedly resulting in early recurrence of deformity (Fig. 36.10).

Figure 36.10 Twenty-four hours after HAV surgery, a 180-pound person deliberately stepped on the patient's foot. A compartment syndrome developed as a result from the crush injury requiring immediate decompression of the interosseous compartments of the foot.

CORRECTION OF DELAYED RECURRENCE

SOFT TISSUE IMBALANCE AND RESIDUAL SESAMOID DISPLACEMENT

Whenever possible, an extension of the original incision line is used to access the first MTPJ and the intermetatarsal space. The revisional incision should begin approximately 1 cm more proximal than the original incision and extends a similar distance beyond the most distal extent. This will allow the surgeon to identify, both proximally and distally, the zones of transition between normal anatomy and that violated by previous dissection. Starting the dissection proximally in healthy tissue will make it easier to become oriented in the soft tissue planes before pursuing the remainder of the exploration. In particular, identifying predictable dorsal cutaneous nerves at this level will help to identify evidence of nerve entrapment due to adhesions and fibrotic changes resulting from prior manipulation or violation. Dissection is likely to be difficult due to the presence of this aberrant soft tissue layer. Care should be taken to explore for the presence of entrapped cutaneous nerves and when present nerve decompression should be completed with exploration along the full length of the affected nerve until reconstitution of normal nerve tissue is identified. Often, a two-layer dissection is prepared with the dermis and superficial subcutaneous structures being prepared as a single layer. The deep fascia is dissected as the second layer and is meticulously prepared to preserve a solid plane of tissue for closure over the affected bone and joint. In cases in which adhesions and fibrotic changes are profound, it may be necessary to create one sharp incision to the deep fascia.

When residual sesamoid displacement exists after a modified McBride-type bunionectomy, the culprit for recurrence is likely an insufficient lateral release. The enthesis of the common adductor tendon is through attachments at the phalangeal base, the plantar plate, and sesamoid apparatus. Depending on the severity of the underlying deformity, the sesamoid apparatus may have retained fibrosis or adhesions to the plantar and lateral intrinsics preventing long-term realignment of the plantar plate. To ensure adequate lateral release, dissection of the first intermetatarsal space and exploration of the lateral MTPJ are required. The fibular sesamoid is a complex region of intrinsic

*The joint destructive procedure of implant arthroplasty is covered elsewhere in this text.

attachments and includes the lateral head of flexor hallucis brevis (FHB) tendon, the deep transverse intermetatarsal ligament (DTIL), the common tendon (oblique and transverse) of the adductor hallucis and fibrous bands that extend from the sesamoid apparatus into the flexor digitorum longus tendon, and the superficial plantar aponeurosis (24). Since the sesamoids and plantar plate are intra-articular structures with many intrinsic attachments, identification and isolation of the lateral joint capsule in the region of the enthesis is a critical first step in this process. The region of the first MTPJ is exposed, and the lateral aspect of the joint space is identified by placing distal traction on the hallux to cause a puckering of the joint capsule. This maneuver facilitates identification of the lateral joint space where the intrinsic structures can be found as they attach to the base of the proximal phalanx, sesamoid apparatus, and plantar plate. Delineating this joint level allows for proper placement of a capsulotomy via a stab incision. Once performed, any residual intrinsic attachments can be undermined and transected from their entheses liberating the hallux and sesamoid apparatus. Manual manipulation of the hallux into extreme varus will break through any remaining fibrous banding that may exist deep within the lateral joint. Modifications of the capsulotomy include making a larger more vertically oriented capsular incision or simply fenestrating the lateral joint capsule and then allowing manual manipulation of the hallux to break through residual lateral ligamentous structures (25). If there is evidence that the adductor tendon remains attached at the proximal phalanx base, this structure should be grasped, undermined, and transected or dissected out proximally and prepared for later transfer. The use of an adductor transfer to the medial capsule for supplementation of the medial capsule repair may be an important adjunctive procedure in the face of recurrent HAV. Whether this structure is transferred dorsally to the medial capsule or run through the neck of the first metatarsal, the end result is supplementation of the medial capsulorrhaphy while creating a change in muscle balance countering adductus or varus shift of the first metatarsal. This technique has been called into question by some as the benefits of the adductor have never been scientifically born out in the literature, and in fact, one series concluded that this maneuver provided no added benefit when performed with a DMO (26).

The condition of the sesamoid apparatus should be inspected to ensure that there is adequate mobility of the sesamoids. It is understood that relocation of the first metatarsal is impeded by fibrosis and adhesion of the sesamoid apparatus, and so this is an important portion of the procedure. If the fibular sesamoid appears to be grossly hypertrophic and abnormally fixed in position, then the need for a fibular sesamoidectomy should be entertained. Once the fibular sesamoid is mobilized or excised, the first MTPJ may be manipulated to check for reducibility in the transverse plane. If it is impossible to reduce the hallux valgus deformity due to a residual or nonreducible metatarsus adductus or metatarsus varus, the MCJ should be reassessed to rule out residual contractures or degenerative joint changes interfering with joint mobility. Weight-bearing may be simulated on the operating table to evaluate the degree of reduction achieved from the soft tissue release alone. Any residual contractures of the EHL tendon or first MTPJ capsule will be evident and should be addressed via lengthening techniques in lieu of capsulotomy or tenotomy. By performing a controlled tissue lengthening, physiologic tension can be achieved and is preferred to simple release. To address residual EHL contracture, a Z lengthening will allow sufficient relaxation for neutral position and alignment of the great toe. It is important to perform the MTPJ capsulotomy in the plane of the contracture to correct the deformity at its apex. Although numerous techniques have been suggested, a simple V to Y capsulotomy will release contracture, and the capsule closure can be performed under physiologic tension with the hallux in neutral alignment on the metatarsal head.

At this point, the residual deformity is assessed and whether or not to perform a metatarsal osteotomy or a more proximal procedure is considered. It is generally understood that performing a metatarsal osteotomy in the face of a fibular sesamoidectomy increases the risk of developing a hallux varus deformity (see Chap. 37), and so caution is advised and judicious use of this combination of procedures is recommended. The detailed execution of specific osteotomies and their modifications in performing the distal or proximal metaphyseal osteotomy, midshaft metatarsal osteotomy, first MCJ arthrodesis, and their modifications can be found in alternate chapters of this text.

PHALANGEAL OSTEOTOMY OF THE HALLUX

When the apex of deformity is within the hallux itself, an Akin osteotomy may be effective in correcting the condition. An unusually long hallux or high angulation hallux interphalangeus are typical criteria for use of this adjunctive technique. The original procedure described by Akin included resection of the medial eminence of the first metatarsal head, resection of the medial phalangeal base, and wedge osteotomy of the proximal hallux (27). While the original procedure was extensive, current modifications include simply creating an oblique base wedge osteotomy (short or long) or a transverse osteotomy within the proximal phalanx of the hallux. This technique should not be used as a primary procedure to correct an increased IMA or deformity due to an abnormal PASA deformity. When used inappropriately, the Akin procedure may create enough retrograde pressure on the metatarsal head to exaggerate the lateral deviation of the first metatarsal perpetuating deformity (28–32).

The use of this osteotomy is usually an intraoperative consideration when there is residual lateral deviation of the hallux noted after a primary bunion procedure has been performed, that is, first metatarsal osteotomy with muscle tendon balancing.

A high angulation hallux abductus interphalangeus, a long medial border of the proximal phalanx of the hallux, or an increased distal articular set angle may be responsible for this residual deformity (Fig. 36.11). By derotating the hallux medialward using the Akin osteotomy, the long tendons of the flexor and extensor tendons will be relocated more centrally about the HIPJ and the metatarsal phalangeal joint reducing the retrograde force that aggravates recurrence of HAV deformity.

Technique

The skin incision should provide ample exposure for preparation of the osteotomy and allow for ease of application of fixation. A linear incision along the dorsomedial aspect of the hallux or one that divides the dorsal and plantar skin is often sufficient for execution of the procedure. An optimal incision plan incorporates the original incision allowing for exposure of the first MTPJ and the distal 1/3 of the proximal

Figure 36.11 **A:** The stance evaluation of this juvenile football player reveals extreme hallux valgus that underlaps the lesser digits. Here an anterior cavus deformity prompts flexor substitution aggravating sagittal plane deformity within the lesser digits. Here the interossei muscles become overpowered by the flexors, and a combination deformity develops at the MTPJs and PIPJs of the lesser digits. Friction against the PIPJs causes local irritation when in shoes and is equal in importance to the bunion pain complaint. The overcrowding of the lesser digits is noticeable only when in the weight-bearing condition. Notice that there is abduction deformity at both the MTPJ and HIPJ level in this case. **B,C:** Stance evaluation just 2 months after HAV and lesser digit correction reveals early evidence of persistent or recurrent deformity. While non-weight-bearing in a short leg cast, this residual was not appreciated. Notice the PIPJ arthrodesis eliminated the flexion deformity; however, elevation of the toe at the MTPJ results from lateral hallux abutment. Radiographic evaluation in this DP view reveals recurrence of the hallux abductus deformity and lateral subluxation of the MTPJ despite performing a CBWO and first intermetatarsal space release. Notice the unusual length of the proximal hallux phalanx. In this case, the role of the anterior cavus, metatarsus adductus, and long proximal phalanx each contribute to recurrence of deformity. A metal shard is present between the fixation devices and reflects collision of instrumentation during the procedure.

phalanx. Sharp and blunt dissection is used to get through the subcutaneous tissue envelope, which is naturally asthenic in this region. Due to the thin dermal and subcutaneous layers, meticulous handling is important to avoid necrosis of the wound margins from overaggressive retraction. Using the blunt end of Regnauld retractors is effective for this dissection. All four of the very delicate digital neurovascular elements within this region are invariably manipulated since the most medial and lateral borders of the phalanx must be exposed throughout the procedure. Once the first MTPJ and body of the proximal phalanx have been exposed, a linear incision is made extending from the dorsum of the first MTPJ onto the distal 1/3 of the phalangeal body. It is best to begin this incision proximally along the medial border of the EHL tendon. The periosteum is reflected sharply about the proximal phalanx base, while blunt reflection over the central and distal aspects of the phalanx can be managed with a freer elevator. Preparation of this soft tissue layer is an important portion of the procedure as it will allow for thorough coverage of the osteotomy site and fixation devices during closure. This coverage will prevent adhesion formation between the osteotomy site and the long extensor tendon. The metaphyseal–diaphyseal junction of the phalangeal base is identified, isolated, and scored with marking pen to provide two important landmarks. The first landmark is a horizontal line that parallels the base of the proximal phalanx approximately 0.5 to 1.0 cm from the first MTPJ. This is the most proximal area for screw or pin placement without risking violation of the articular surface. The second landmark is drawn to create a transverse or oblique arm for a closing base wedge osteotomy (CBWO). The length and angulation of this osteotomy will depend upon the degree of reduction needed to realign the hallux. One method to determine the size of the wedge resection is to measure the difference between the medial and lateral cortical margins. This difference should provide adequate reduction of hallux deviation while creating a more parallel relationship between the distal and proximal articular surfaces of the hallux (Fig. 36.12A). This medially based wedge can be expected to heal promptly when placed within the metaphyseal region of bone. The longer and more oblique the cut, the more diaphyseal bone involved, and rigid internal fixation is integral to facilitate primary bone healing in this region. An axis guide is placed in the proximal lateral corner of the metaphyseal diaphyseal junction and is drilled from dorsal to plantar using a 0.045-inch Kirschner wire (K-wire) (Fig. 36.12B) Just

Figure 36.12 **A:** Intraoperative view of the proximal hallux with the axis guide for a medially based wedge intact. The axis guide is run purely in the sagittal plane to avoid mal rotation of the osteotomy. The hallux is scored horizontally to parallel the articular surface of the hallux. The oblique arm of the osteotomy is scored at a 45-degree angle to provide a maximum of derotation. The 4-mm wedge osteotomy is cut and then is planed to provide definitive derotation of the hallux. It is best to resect a small wedge first and assess the correction when performing most wedge osteotomy procedures. Notice the overcorrected position of the hallux after scoring the intended osteotomy. **B:** Resection of a 4-mm wedge from the proximal hallux base is completed before planning of the osteotomy to complete correction of the deformity. **C:** Notice overreduction of the phalangeal abduction as the medial border is now shorter than the lateral border. This position reduces the retrograde force on the hallux reducing the IMA and is easily secured with a single cortical screw in this dense bone. It is important to note that the bone is mature as there is no evidence of open epiphysis. **D:** Weight-bearing clinical photo in juvenile HAV 3 years after CBWO and 2 years after Akin osteotomy demonstrates good maintenance of position and alignment long term. All digits purchase the ground and weight-bearing is tolerated well. A full functional recovery includes unrestricted participation first string in football.

as in a CBWO for the first metatarsal, the guide wire can be angulated to provide sagittal plane correction; however, since this is a medially based wedge, the orientations to achieve plantarflexion or dorsiflexion of the part are opposite. Tilting the axis guide lateralward will effect elevation of the distal segment and may be efficacious when hallux limitus is coincident. An axis guide tilted medially will affect plantarflexion while tilting the axis distally will reduce valgus deviation of the hallux. Once proper placement of the axis guide is determined, the osteotomy is scored using a no. 10 osteotome and a mallet. Once satisfied with the orientation of the proposed osteotomy, power instrumentation is used to cut the osteotomy. An oscillating saw

held parallel to the axis guide will allow for a well-controlled cut. The maximum depth of the proximal phalanx is approximately 1.0 cm, and so a fine-tooth blade that is 1.0 cm wide and at least 1.0 cm long will facilitate this maneuver. Constant irrigation during the osteotomy will minimize thermal necrosis and improve the setting for bone healing. The lateral hinge of the osteotomy provides a second point of fixation, and so care is taken to preserve this structure during provisional fixation. Final assessment of correction should be completed prior to applying definitive fixation devices. While the fixation of an Akin osteotomy is a matter of surgeon's preference, the long oblique modification allows for rigid internal fixation with the benefit of a 2.7-mm cortical screw. Numerous alternate types of fixation have been used for this procedure such as staples, K-wires, cannulated screws, and absorbable screws and pins. Since full visualization of the entrance and exit of the screw is easily achieved, standard screws are the mainstay for this procedure. In the face of a transverse osteotomy, bone coaptation and rigid fixation can be achieved with the benefit of the two-point cerclage technique, parallel staples, or K-wires. Once satisfied with correction of the deformity and stabilization of the osteotomy, a layered closure can be completed after copious irrigation. A meticulous layered closure will reduce the risk of wound dehiscence. Immediate weight-bearing in a rigid-soled or orthowedge surgical shoe for 6 weeks or until adequate bone consolidation is appreciated both clinically and radiographically (Fig. 36.12C and D). Potential complications of the procedure include fracturing of the lateral hinge or failure of fixation devices in either transverse or oblique osteotomies. If failure of fixation occurs, then the addition of supplemental fixation devices can be done percutaneously. Some would argue that simply splinting the hallux or providing a more aggressive off loading of the hallux will allow bone union to complete in a primary or secondary fashion.

Pearls/Pitfalls

The oblique osteotomy is less stable than its transverse counterpart. Therefore, when the lateral hinge is lost, the entire construct becomes markedly less stable. This would change the degree of protected weight-bearing or digital splinting required to achieve bone union.

CONSIDERATIONS IN SALVAGE AFTER AN OVERLY AGGRESSIVE OSTECTOMY

When HAV surgery is complicated by an overly aggressive medial exostectomy, one of two conditions may develop: undercorrection or overcorrection of the transverse plane deformity or residual hallux valgus or hallux varus. Hallux varus as a complication of HAV surgery is discussed specifically in Chapter 36. When undercorrection is the result, it is likely that the original deformity was underestimated and an insufficient procedure was selected. Stretching the indications for the use of conservative bunion surgery is doomed to failure in the face of a high IMA or excessive hallux abductus angle or when significant metatarsus primus adductus, metatarsus adductus, increased proximal articulation set angle, or a combination of these exists. An overly aggressive exostectomy is often an attempt to further reduce medial metatarsal prominence when the index osteotomy/ostectomy failed to provide this correction. This medial scalloping of the metatarsal rarely achieves the desired effect of eliminating the structural deformity and so results in persistent or recurrent hallux valgus with a significant loss of bone volume from the metatarsal head.

The conservative bunion surgery aka exostectomy is intended to remove the excess medial eminence without violating the articulation of the tibial sesamoid. Salvage of this condition requires a combination of procedures: one to restore the articular surface of the metatarsal head and the other to achieve definitive correction of the first ray alignment. Determining the procedure for correcting first ray alignment is dependent upon function of the first MTPJ, degree of residual MTPJ incongruity, degree of first metatarsal malalignment, and medial column stability not unlike selecting a primary bunion procedure.

Technique

Metatarsal head grafting. One viable technique for salvage of the first MTPJ function after an overaggressive exostectomy is to graft the metatarsal head and restore a more normal cubic content for articulation with the phalanx. When reinforcing the region with bone graft, the convex surface of the metatarsal head is supplemented and a foundation for the phalangeal base articulation is restored (33). The purpose of this technique is to create a more normal morphology to the first metatarsal head allowing for congruous articulation with the hallux base and was originally described to reverse the ill effects of hallux varus resulting from HAV surgery. Once the surface area of the metatarsal head has been restored, the metatarsal segment can be realigned with a combination of osseous and soft tissue procedures as necessary. This may require the benefit of a proximal metatarsal osteotomy and release of contractures within the first intermetatarsal space depending on the severity of the residual deformity.

Resectional arthroplasty of phalanx. After an overaggressive exostectomy, a joint salvage procedure may not be possible. In bedridden, wheelchair-bound, or low-demand, sedentary patients, an arthroplasty to remove the phalangeal base, the Keller procedure, may be enough to reduce the deformity, eliminate painful bone prominence, and reduce risk of ulceration (34). In select patients, the Keller procedure can provide an apropulsive gait that allows for effective weight transfers and pivoting necessary for basic low-weight-bearing daily activities. Care should be taken to perform a meticulous capsulorrhaphy and include reattachment of the long flexor tendon for optimal stabilization of the hallux. This tendon transfer will provide enhanced stability reducing the risk of hallux contracture after surgery. Performing a combination of purse stringing the joint capsule and reattaching either the short or long flexor tendon to the residual phalanx will prevent hallux extensus deformity (35,36).

With reattachment of the short flexor tendon, the sesamoid apparatus is firmly supported, and it is felt that this serves to prevent joint subluxations that contribute to lesser metatarsalgia (Fig. 36.13). Although there are no strict contraindications for the Keller procedure, the relative contraindication is the presence of chronic lesser metatarsalgia in the absence of hammertoe contractures and instability of the first ray segment. When excessive bone loss results in instability of the MTPJ, it may not be possible to re-create a supporting surface for the hallux base. In higher-demand patients, the Keller arthroplasty is not a functional option.

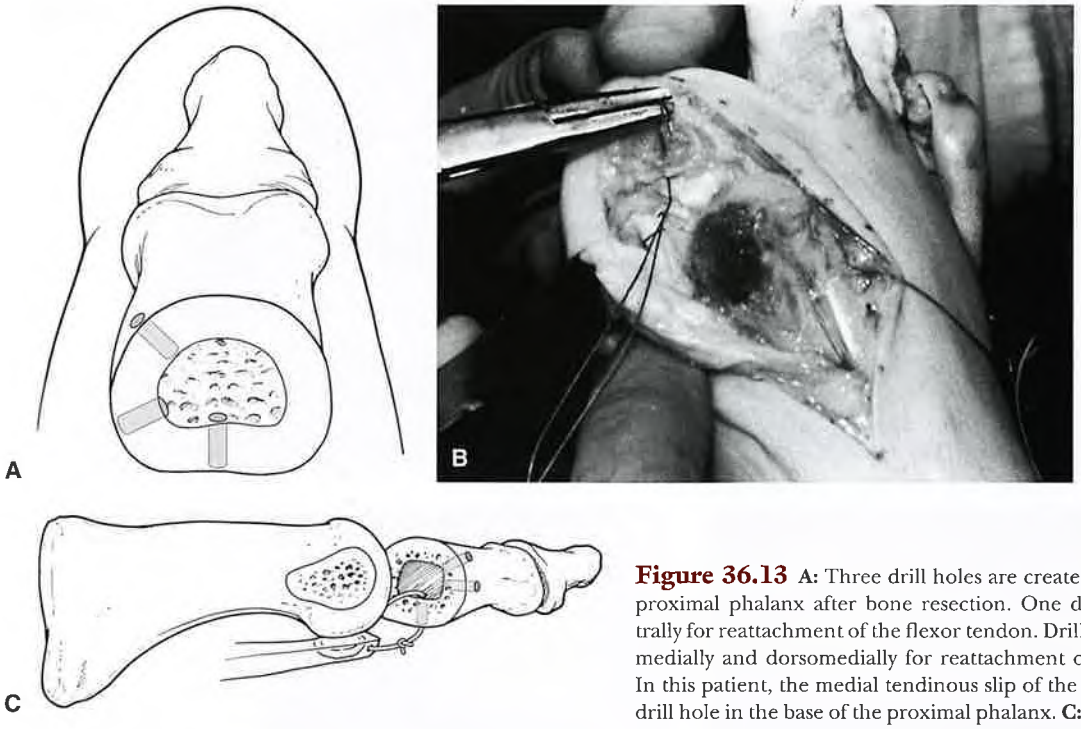

Figure 36.13 **A:** Three drill holes are created in the remaining base of the proximal phalanx after bone resection. One drill hole is made plantar centrally for reattachment of the flexor tendon. Drill holes are then created plantar medially and dorsomedially for reattachment of the medial capsular flap. **B:** In this patient, the medial tendinous slip of the FHB is tagged into the central drill hole in the base of the proximal phalanx. **C:** Diagrammatic representation.

REVISIONAL DISTAL METAPHYSEAL OSTEOTOMY

Clinical Considerations

When revision of a distal osteotomy is necessary and the quality of the residual bone is in question, ancillary imaging is warranted. The benefit of three-dimensional imaging, MRI, or computed axial tomography (CAT) will identify voids and other structural defects that may not be evident on plain x-ray aiding in procedure selection. If the metatarsal head is in relatively good condition and there is little shortening of the metatarsal segment, then a revisional osteotomy may be curative. The primary risks of the procedure are increased when performing revisional surgery; infection, nerve entrapment, painful or unsightly cicatrix, chronic edema, over- or undercorrection, and delayed nonunion or malunion of bone are all possible if not even more likely in this surgery. Due to the repeated neurovascular insult, the hallux is at particular risk for compromise. Hence, meticulous dissection and bone handling are critical to success in these cases. In revisional surgery, it is prudent to discuss and reserve the right to perform a joint destructive procedure should intraoperative findings warrant it. This would dramatically change the postoperative care plan likely including a considerable period of non-weight-bearing when performed. If that non-weight-bearing plan evolves in a patient with risk factors for the development of deep vein thrombosis (DVT), then a plan for DVT prophylaxis should be pursued and communications with the primary care physician should be completed well in advance of the surgery. On a similar note, if the patient is on anticoagulant therapy, then reversal of the agent and perioperative prophylaxis becomes a major component of the surgical plan.

Technique

The incision takes into consideration the clinical appearance of the deformity and the most recent radiographs to ensure that exposure is optimal to execute débridement, osteotomy, and fixation (Fig. 36.14A and B). For this reason, the incision plan often includes the original cicatrix line plus extensions both proximally and distally to enhance exposure and allow for the identification of tissue planes that have not been disrupted by previous surgery. Gentle manipulation of the skin is required to prepare the skin in a single layer for retraction and exposure of the subcutaneous layers; however, when dermal atrophy is profound and the basement layer of skin is adhered to the subcutaneous layer, this may not be possible. The dorsal cutaneous nerves and vessels should be identified, isolated, and retracted whenever possible. The integrity of the EHL tendon should be assessed and may be found fibrosed to the underlying joint capsule when tendinopathy is a contributing factor (Fig. 36.14C). A layered dissection is always preferred however is not always possible in revision surgery. Often, when the surgical site is matted down due to dermal atrophy and deep adhesions or when extensive fibrosis exists, the dissection is performed using sharp incision through a single layer down to the periosteum. A dorsolinear periosteal incision is made to expose the joint, and the capsulotomy may be linear or modified into an inverted L or T configuration for best joint exposure. When the joint capsule contributes to contracture of the joint, the capsular incision should be placed strategically to facilitate relaxation of that tissue. The original osteotomy site is often easy to identify intraoperatively. It is common to find a well-defined line of sclerosis defining the margins of the capital fragment with or without exuberant osteophytic degeneration (Fig. 36.14D). Before incising the osteotomy site, it is important to inspect the articular surfaces of the metatarsal head and phalanx base to identify unusual articular defects or obvious joint incongruity. If the degenerative changes about the articular surfaces are more significant than predicted or if the bone quality is not sufficient to maintain an osteotomy (overly sclerotic or grossly osteoporotic), then consideration for an alternate procedure such as a

Figure 36.14 The preoperative clinical photo **(A)** and DP radiograph **(B)** demonstrate the ill effects of undercorrection in using the transverse plane V osteotomy. The continued lateral drift of the hallux has resulted in such severe destabilization of the second digit that a crossover toe has resulted. This combination of deformities is perhaps one of the most challenging of forefoot deformities. **C:** Intraoperative photo reveals chronic tendonopathy of the EHL tendon. Notice the undulation of the distal tendon fibers indicating laxity due to an overstretched Z lengthening of the EHL tendon, which had been performed as an adjunctive procedure. The thickened central portion of the tendon is associated with capsular adhesions and MTPJ restriction. **D:** Osteophytic degeneration and sclerosis are easily appreciated about the failed V osteotomy in this intraoperative sagittal view. Notice that the thickened zones of sclerotic change and fibrosis occurs at the level of capsular attachment giving the appearance of a reverse V orientation of the degenerative bone. These mixed fibrotic and sclerotic changes about the metatarsal head develop as secondary changes due to previous surgical insult. *(Continues on next page)*

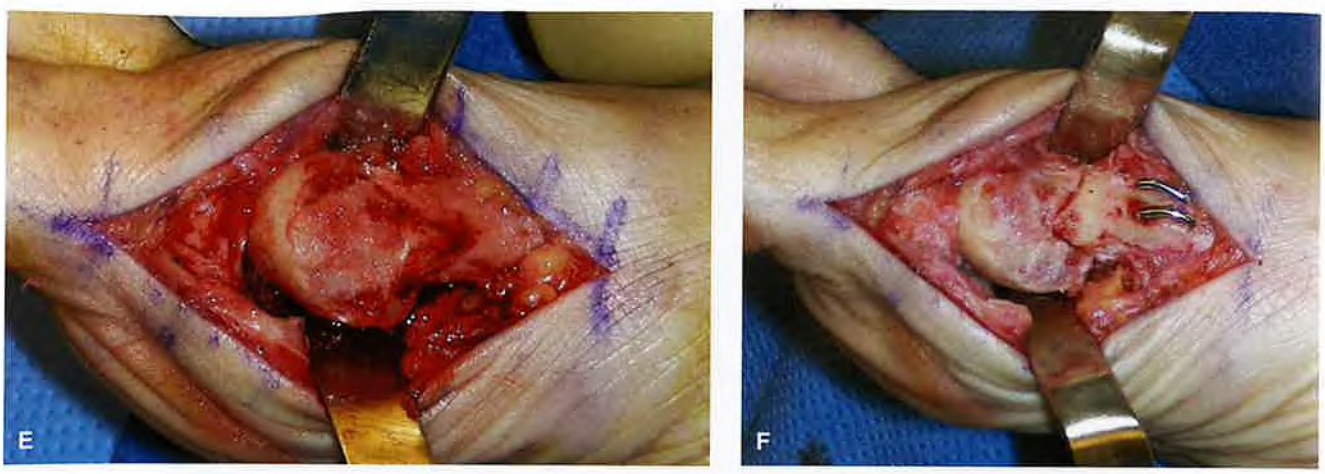

Figure 36.14 *(Continued)* **E:** Once débrided, the metatarsal head bleeds revealing the location shape and orientation of the degenerative bone resection. In this case, 4-year status post V osteotomy, the bone has been well healed and so the original V cuts are no longer visualized. **F:** After a generous débridement of degenerative changes, the osteotomy is replicated using the landmarks of the most dorsal and plantar extents of the cartilage to identify the apex for the V cut. The metatarsal head is then more aggressively lateralized, and this osteoporotic metatarsal head is stabilized using two points of fixation. Notice that aggressive removal of the dorsal osteophytes gives the appearance of a plantarflexed osteotomy. Look closely at the plantar extent of the articular cartilage, the congruency of the articulation with the hallux base, and the location of the apex of the V cut in comparison to that noted in **E** to best visualize the position and alignment of the osteotomy. A line drawn from the most dorsal extent of the articular cartilage to the most plantar is used as a reference for the osteotomy. The apex of the V osteotomy should rest at the midpoint of this line as seen here.

more proximal osteotomy should be entertained. Modification of the osteotomy, when necessary, is much easier to prepare before the original osteotomy is recut. Critical evaluation of the articular surfaces to assess the condition of the cartilage and reducibility of the MTPJ is performed prior to recutting the osteotomy. When angular deformity of metatarsal bone exists, such as sagittal plane malalignment, modifications of the osteotomy can be employed avoiding the need for a combination of osteotomies to reduce deformity (37,38).

When significant angular deformity of the articular surface of the metatarsal head is evident, modification of the original osteotomy cut is warranted and a cartilage realignment procedure is necessary. When there is significant sclerosis or avascular changes present, a DMO procedure is not prudent and so close scrutiny of the bone quality is required to avoid further devitalization of the metatarsal head. There are some that would suggest performing a hallucal osteotomy in this case to realign the pull of the long flexor and extensor tendons to create a more effective tendon function across the MTPJ and reduce the angular retrograde pull that aggravates the recurrence of the HAV deformity. This avoids further violation of the metatarsal head while correcting abnormal biomechanics that perpetuate the deformity.

When a DMO is appropriate, an axis guide is prepared for the revision and sharp resection of the osteotomy will require power instrumentation to minimize shortening. Copious irrigation should be performed throughout the resection to prevent thermal necrosis and reduce the risk of devascularizing the metatarsal head. Depending on the quality of bone, the intramedullary segment of the metatarsal head may be manipulated into an improved position with the benefit of a freer elevator. It is important to gently manipulate this segment of bone to avoid devitalization or fragmentation of the part. When the bone quality is compromised, débridement and supplemental bone should be pursued to improve bone quality and enhance bone healing. Using graft material to pack voids within the metatarsal head, shaft, or both will often require two points of fixation to afford optimal stability of the parts and provide ample immobilization of bone to ensure bone healing. When grafting is required simply to pack voids, the fixation technique can be completed simply by using two points of fixation, for example, two parallel or crossing K-wires where the goal is to achieve a stable construct for propulsion by way of primary bone healing (Fig. 36.15A and B). This supplemental bone grafting is a very different procedure than when an interpositional bone graft technique is used for the benefit of restoring length to the first ray, and so the rationale in fixation is dramatically different between the two. See the Pearls/Pitfalls section for further discussion on this subject.

When using power instrumentation to re-create an osteotomy, especially in unusually dense and sclerotic bone, continuous irrigation is important to prevent thermal necrosis. Fenestration of the parts will facilitate vascular ingrowth and encourage enhanced perfusion to the metatarsal segments (Fig. 36.15C and D). Once the fragment has been well coapted, the articulation of the joint should be assessed. Ultimately, positioning of the revisional osteotomy should produce a congruous articulation with the hallux. If this new position is not optimal, modification of the osteotomy may be required. If excessive elevation of the metatarsal head is evident while manipulating the V-type osteotomy, enhanced plantarflexion can be achieved simply by planning the dorsal arm of the osteotomy and allowing the entire metatarsal head to drop down. The reverse maneuver will be effective when faced with extreme plantarflexion of the part. The sagittal saw blade is 1 mm thick and so removes approximately 1 mm of bone when planing the site. It is important to reevaluate the position of the osteotomy closely after each pass of the blade to prevent excessive bone

Figure 36.15 Postoperative DP (**A**) and lateral (**B**) radiographs reveal the revision of a DMO stabilized using two-point 0.062-inch K-wire fixation in osteopenic bone. Notice the improved alignment and congruity of the first MTPJ as compared with Figure 36.14B. **C:** Intraoperative photo showing the dorsolateral aspect of the metatarsal head is reflective of the joint impingement resulting from an iatrogenic metatarsal elevatus and subsequent hallux limitus as a complication of a proximal metatarsal osteotomy malunion. The bald chondral zone of the metatarsal head is fenestrated using a 2.0-mm wire pass drill bit (in lieu of a K-wire) to excavate bone and decompress the region to encourage vascular ingrowths. **D:** Distraction of the osteotomy in revision HAV surgery reveals densely sclerotic bone that has been fenestrated to encourage vascular ingrowths.

loss. Once optimal position has been achieved, the capital fragment should be manually impacted onto the shaft compressing the parts prior to preparing the fixation device(s). Fixation of the osteotomy can be completed with the benefit of a single 0.062-inch K-wire in many cases. Which fixation device and how many points of fixation are used are dependent on the overall stability of the osteotomy in the corrected position. It is prudent to challenge the osteotomy by grasping the hallux and distracting at the MTPJ while observing for evidence of insufficiency about the osteotomy site. If there is evidence of motion across the osteotomy or frontal plane instability about the capital fragment, then a second point of fixation should be employed. A final assessment of the alignment of the articular surfaces, joint motion, and hallux position should be completed after rigid fixation has been achieved to confirm optimal position and function prior to closure.

Pearls/Pitfalls

When considerable angular deformity of the metatarsal articular surface is evident, modification of the original osteotomy cut is warranted. While it may seem intuitive to perform a Reverdin-type wedge within the distal metatarsal head to realign the cartilage, this may not be prudent when there is significant sclerosis or avascular changes. There are some that would suggest attempting a hallucal osteotomy, such as a proximal Akin, in this case to attempt to realign the pull of the long flexor and extensor tendons to create a more effective muscle tendon function across the MTPJ. This realignment of the hallux will reduce the angular retrograde pull of these extrinsic tendons that aggravates recurrence of the HAV deformity. The Akin osteotomy cannot be expected to reduce an elevated PASA or reduce an increased first–second IMA.

If the recurrent HAV deformity is the result of subsidence of bone, then grafting may be required to repair the osteotomy defect. When this is the case, supplemental bone graft materials can be interposed in small amounts preventing excessive impaction of the part. Removing excess bone from the medial metatarsal head, milling it, and replacing it within regions of bone subsidence may prove sufficient. In other cases in which larger defects are evident, bone graft morsels of autogenous or allogenic material may be used to fill defects of the metatarsal shaft when revision of an osteotomy is an appropriate procedure. It is understood that autogenous graft materials provide a more physiologic environment since it is enhanced with osteoinductive and osteoconductive agents such as bone morphogenic protein and growth factors from host thrombocytes. Others have demonstrated that allogenic bone graft material can be used in these small areas of bone deficit with good outcome. Regardless of the source of the graft material, ultimately, it is the position and stability of the fixation that will bring the construct to final union.

When grafting is required simply to pack voids, the fixation technique can be as simple as a crossing K-wire technique in which the goal is to achieve a stable construct for propulsion whether that is from primary bone healing or the development of a fibrous union (Fig. 36.16). This supplemental bone grafting is a distinctly different procedure than the interpositional bone graft technique used to restore length to the first ray. Generally, bone grafting to simply fill voids after failed DMO or silicone implant will require two points of fixation and protected weight-bearing to achieve union. The interpositional bone graft procedure requires more technical considerations regarding the type of grafts used and the methods of fixation for them. This grafting procedure requires the use of low-profile plates and screws and the need for absolute non-weight-bearing to achieve union. When using this technique, there is an increased risk of complication since two discrete areas will have the potential for developing a nonunion (Fig. 36.17).

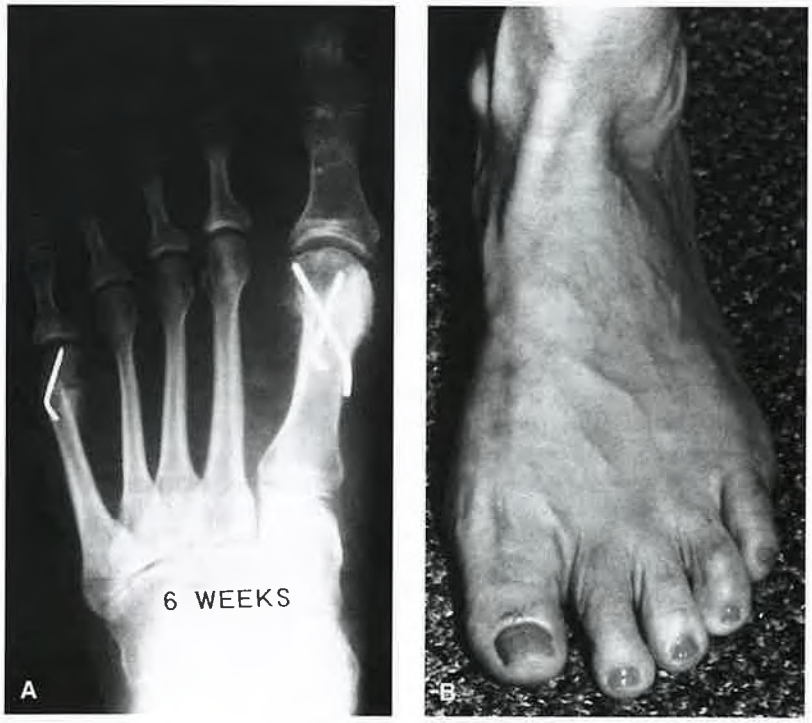

Figure 36.16 **A:** Radiograph 6 weeks postoperatively. **B:** Clinical appearance 4 months postoperatively.

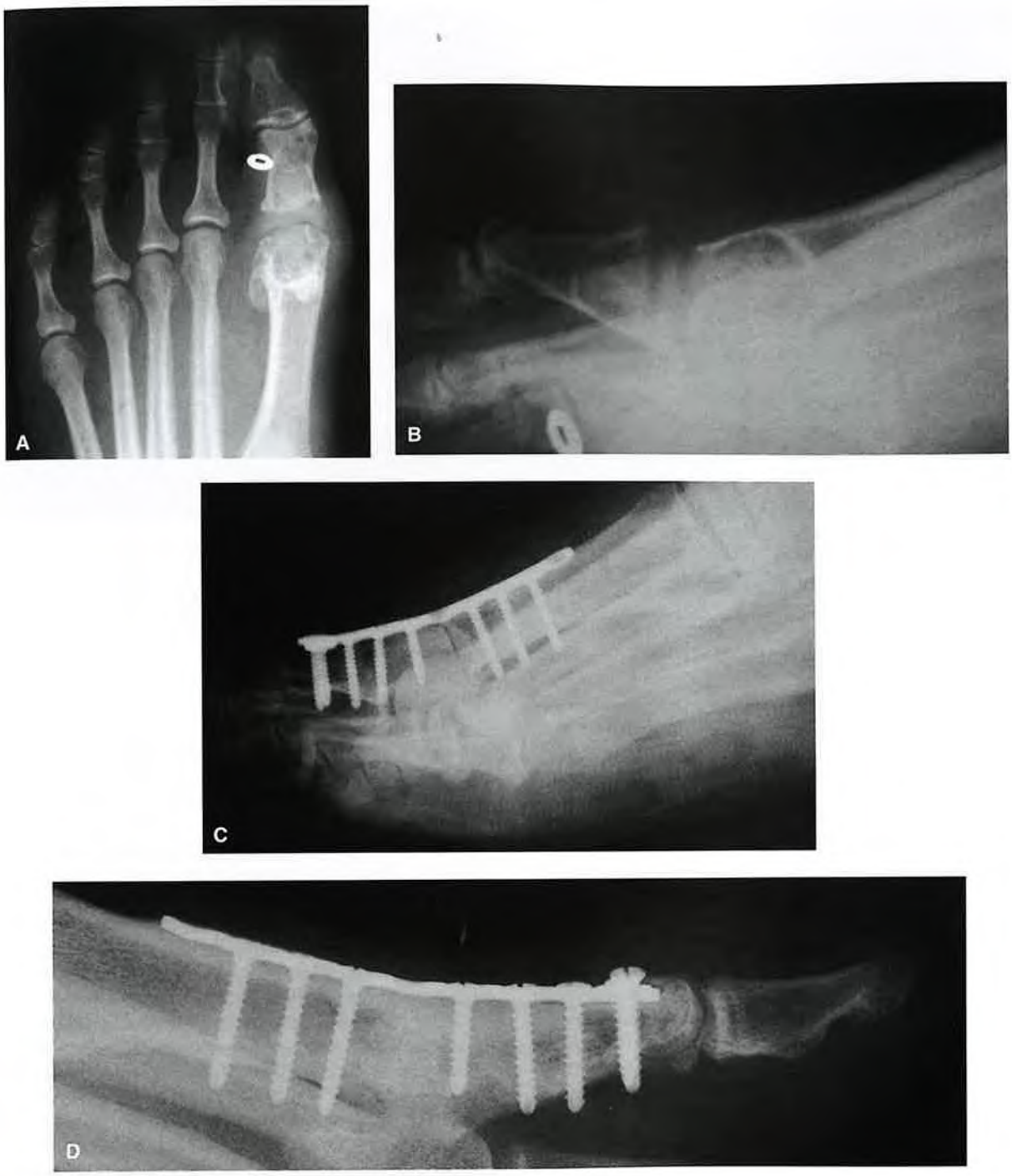

Figure 36.17 **A:** Preoperative DP radiograph reveals the profound cystic degeneration resultant of a total first MTPJ silicone implant. The metallic marker indicates the region of osseous insufficiency as the silicone began to erode through the phalanx in this region. The sclerotic margins about the implant and increased soft tissue density about the joint are easily appreciated. Preoperative lateral radiograph showing that the distal portion of the silicone implant is subluxed dorsally and the implant has eroded against the inferior margin of the phalanx. The metallic marker indicates the target of irritation upon weight-bearing. The flexion deformity of the hallux is easily appreciated as the dorsal subluxation of the implant has given the FHL a mechanical advantage. **C:** Early postoperative lateral radiograph reveals the interpositional bone graft required to restore length due to a complication of HAV surgery. Here the low-profile titanium plate stabilizes the graft–arthrodesis interfaces. In this procedure, each interface is at risk for bone healing complications such as nonunion as compared with an end-to-end arthrodesis in which there is only one site at risk. The proximal aspect of the graft–metatarsal interface is easily appreciated as a vertical lucency in this view. **D:** Lateral radiograph at 4 years postoperatively showing complete incorporation of the graft is easily appreciated. Notice that there is approximately 20 degrees of dorsiflexion in the hallux position to allow for athletic activity of this younger physical therapist. Notice there is an increased prominence of the distal most screws. *(Continues on next page)*

Figure 36.17 *(Continued)* **E:** Dorsoplantar radiograph at 4 years postoperatively, the graft is indistinguishable from natural bone beneath this low-profile titanium plate. The minimal profile of this modular hand plate makes it well tolerated even after 4 years of heavy athletic activity. **F:** The remnants of the total joint silicone implant and thickened rings of fibrinous ingrowths are excised prior to curettement of the medullary contents of bone.

PROXIMAL METATARSAL OSTEOTOMY

When the quality of bone residual from DMO is suspect, a more proximal procedure may be required for revision. In such instances, a CBWO can be performed to achieve multiplanar correction while sparing the length pattern of the first ray. This technique mandates strict attention in preparing the osteotomy axis guide to ensure optimal correction of the deformity while preventing the ill effects of a misaligned osteotomy. While this procedure is straightforward in its essence, the literature reflects that complications often arise when the standard technique is poorly understood and executed. The oblique base wedge osteotomy is an inherently unstable configuration and so requires rigid internal fixation in concert with a course of non-weight-bearing to achieve primary bone healing in the intended position. Should the fixation of a base wedge procedure fail, untoward outcomes such as first ray elevation and shortening of the metatarsal are predictable (37).

Other proximal metatarsal shaft procedures are further options; however, from the standpoint of bone healing, procedures performed on diaphyseal bone require heartier internal fixation and are naturally more challenging in regard to achieving bone healing as compared with procedures performed within metaphysis. In the right hands, a CBWO can provide significant derotation of the first metatarsal and requires the benefit of relatively simplistic internal fixation techniques. Close scrutiny of articular cartilage alignment is needed to determine if an adjunctive procedure is needed to achieve total joint congruity. Cartilage realignment procedures such as the Reverdin, a closing wedge performed in the distal aspect of the metatarsal head, can accomplish this task adding a modicum of time and additional fixation to the procedure (see Fig. 36.8).

Technique

The skin incision is place about the dorsomedial aspect of the first MCJ. If there is a need for concomitant first intermetatarsal space dissection, as is often the case, this incision will extend distally across the first MTPJ. Proximally, the subcutaneous dissection will reveal the dorsomedial cutaneous nerve as it crosses the base of the first metatarsal. The subcutaneous layer and superficial neurovascular structures should be gently retracted to reveal the deep fascial layer including the EHL tendon and the proximal aspect of the first MCJ. The soft tissue balancing procedure of the first intermetatarsal space is performed as described earlier in this text.

The deep fascia is incised in a single layer beginning 1 cm proximal to the first MCJ and extending distally along the medial aspect of the EHL tendon just past the first MTPJ. This will provide exposure for the lateral interspace release as well as the proximal osteotomy. With the periosteum exposed, the incision plan for the osteotomy can be prepared. The configuration of the periosteal incision will vary depending on the shape of the intended osteotomy; usually a short or long oblique orientation is used. The long oblique osteotomy has the benefit of facilitating two points of fixation, and its longer radius arm allows greater lateral rotation as the wedge is closed. Before preparing the osteotomy, it is prudent to place an 18-gauge needle in the first MCJ to serve as a landmark for the articular surface of the first metatarsal base. This will help prevent inadvertent violation of the joint. Here the periosteal incision begins approximately 1 cm distal to the proximal medial corner of the first metatarsal base. This placement preserves the periosteum about the proximal medial border of the metatarsal base and will serve to support the lateral hinge of the osteotomy. The periosteal incision is made at a 40-degree angle to the shaft of the metatarsal, and when the lateral border of the metatarsal is

encountered, the incision is directed along this border to facilitate wide exposure of the metatarsal. A freer elevator is used to reflect the periosteum, and the metatarsal is prepared for osteotomy. A 0.062-inch K-wire is run oriented from dorsal to plantar through the medial base of the metatarsal, 1 cm distal to the MCJ. This K-wire is oriented perpendicular to the weight-bearing surface to serve as an axis guide for the osteotomy. This orientation will allow transverse plane translocation of the segment without untoward deviation in the frontal or sagittal plane (see the Chapter on Closing Base Wedge Osteotomy). A skin marker can be used to design and preview the length and width of the intended osteotomy. An osteotome or saw blade can be used to score the dorsal cortex of the metatarsal and create a 40- to 45-degree angle for the proximal cut of the osteotomy. The angulation of the distal cut will depend on the degree of correction required (see the Chapter on Closing Base Wedge Osteotomy). An oscillating saw can be used to begin the osteotomy at the lateral most cortex and should propagate toward the K-wire maintaining the blade parallel to the pin throughout the procedure. It is best to create a smaller wedge and later gently plane the osteotomy than to cut an excessively large wedge and be unable to close the osteotomy without fracturing the hinge. Constant irrigation while performing the osteotomy will reduce the risk of thermal necrosis of bone and will provide optimal physiology for bone healing. Once satisfied with the wedge resection, the bone wedge is inspected along with the deepest region of the osteotomy cut to ensure that the wedge was removed in its entirety. Any inadvertent bone remnant will impede closure of the wedge and create a stress riser about the hinge when attempting to close the wedge. The bone clamp is used to maintain closure of the wedge while intraoperative radiographs are taken to ensure adequate reduction of the deformity. Two points of fixation are employed: an anchor screw and a compression screw. Precise placement of the screws is important to prevent collision of the devices. When viewing the lateral base of the metatarsal in the sagittal plane, the area can be divided into four quadrants. By placing the anchor screw in the dorsal and proximal quadrant and placing the compression screw in the plantar and distal quadrant, collision of the screws is unlikely. The most proximal screw is run transversely through the base of the first metatarsal bone and serves as the anchor screw, protecting against telescoping and shortening of bone and fracture of the medial hinge. This anchor screw is tightened to two-finger tightness as overtightening prior to application of the second screw will prompt a distal shift of the medial fragment and fracture the hinge. Prior to inserting the second screw, the bone clamp is released. The second (distal) screw is oriented as close to perpendicular to the osteotomy as possible.

Final radiographs or fluoroscopy is obtained to ensure adequate position and alignment of bone and fixation devices. The range of motion about the first MTPJ is reassessed, and joint congruence is confirmed. Copious irrigation is then completed, and a layered closure is performed with the benefit of 3-0 absorbable suture running from proximal to distal to reapproximate the periosteum and capsule in an interlocking running fashion to completely cover the fixation devices. The subcutaneous structures are closed with the benefit of 4-0 absorbable suture in a simple running fashion, and the dermal edges are reapproximated with the benefit of 5-0 absorbable suture in a subcuticular running fashion. A Jones compression dressing with a fiberglass egg shell or posterior splint is maintained for the first 5 to 7 days. Absolute non-weight-bearing is integral to success as early weight-bearing will deform if not fracture the proximal metatarsal segment. The duration of non-weight-bearing will vary based upon the quality of the bone stock and evidence of radiographic bone consolidation confirmed in multiple views. It is difficult to assess the degree of bone consolidation of the proximal metatarsal from a clinical perspective, and no physical exam for this has ever been described. After 6 weeks of non-weight-bearing with satisfactory radiographic evidence of bone consolidation, the patient is allowed to return to protected weight-bearing in a firm-soled shoe and is advanced as tolerated thereafter. Serial radiographs are taken in 2- to 3-week intervals for the first 2 months and monthly thereafter until full functional recovery has been achieved. More frequent radiographs are taken when symptoms or clinical change dictates further examination.

Pearls/Pitfalls

The technical consideration regarding proper placement of the hinge axis concept and placement of the axis guide for the CBWO is discussed in detail in an alternate section of this text.

It is prudent to place an 18-gauge needle in the first MCJ to serve as a landmark for the articular surface of the first metatarsal base in an attempt to prevent inadvertent violation of the joint. To further protect the articular surface, the periosteal incision begins approximately 1 cm distal to the proximal medial corner of the first metatarsal base. This placement preserves the periosteum about the proximal medial border of the metatarsal base and will serve to support the lateral hinge of the osteotomy.

Precise placement of the screws is important to prevent collision of fixation devices. When viewing the lateral base of the metatarsal in the sagittal plane, the area can be divided into four quadrants. By placing the anchor screw in the dorsal and proximal quadrant and placing the compression screw in the plantar and distal quadrant, collision of the screws is unlikely.

ARTHRODESIS IN FAILED HALLUX ABDUCTO VALGUS SURGERY

Clinical Considerations

When the first MTPJ is placed in the corrected position and there is a considerable loss of first MTJ motion, a joint preservation procedure may not be feasible. In the face of irreducible MTPJ incongruity or instability of the first MTPJ, an arthrodesis may provide the most predictable and arguably the most definitive correction of the deformity, especially in patients with higher functional demands. Over time, numerous modifications in performing arthrodesis of the first MTPJ have been described (39–55). The first MTPJ fusion, traditional or modified techniques, can correct transverse plane deformity while simultaneously achieving optimal sagittal plane joint position for propulsion when properly executed. This will stabilize the distal aspect of the first ray and with optimal positioning will improve weight-bearing function of the first MTPJ.

If there is any question regarding the perfusion to bone in this region, the benefit of ancillary imaging is warranted. The nuclear medicine triphasic bone scan can shed light on the presence of perfusion deficits as well as the incidence of atrophic or hypertrophic bone subsequent to prior surgery (56). MRI can shed insight as to the presence of dysvascular changes in bone however cannot provide dynamic information regarding active perfusion in the region.

In considering this procedure, the bone quality and length is scrutinized to determine the potential benefit of incorporating an intercalary bone graft as needed to restore length. This technique involves procurement of a stout autogenous graft when the recipient bed is considered compromised. Alternately, allogenic bone can be used when bone quality is not an issue. In light of the fact that some have found that patients failing their revisional surgery using allogenic bone would opt for autogenous bone if they had to do it over again, it is the patients right to choose between the graft type used after detailed education regarding the risks and benefits of each. The morbidity associated with autogenous tricortical iliac bone grafts has been well established in the literature (55).

Whether to use an autograft or allograft implant has been a matter of debate over recent years, and so there has been a fair amount of research to investigate the question. Traditionally, when a large tricortical-type graft was desired, an autograft from the iliac crest is preferred (55,57–59).What we have learned over time is that allogenic bone performs well in foot and ankle surgery and can provide excellent functional long-term outcomes. The current literature suggests that arthrodesing procedures in foot and ankle surgery can be done safely and effectively with the benefit of allogenic bone graft materials sparing the patient a second operative site and avoiding the natural complications attributed to bone graft procurement and host site morbidity (57,60–62). Others have made it clear that arthrodesing procedures can be successful without the benefit of any bone graft whatsoever (63). If in fact bone supplementation is being considered to enhance perfusion to existing bone, then an autogenous graft is perhaps the most physiologic technique.

Whether the fusion is end to end or if a bone graft is used, the *hallmark to successful bone healing* is rigid internal fixation and immobilization of the part (57,60). The *hallmark to functional success* is proper positioning of the parts for fusion and function. Based upon published reports in large series reviews of first MTPJ arthrodesis procedures, the union rate ranges from 68% to 100%. Many of these procedures have been performed for failed HAV surgery. When a bone graft is used, it is intuitive that the complication rate in bone healing may be increased; however, this was not born out in the above-mentioned review as only one study reported the use of the inlay bone graft technique and touted a union rate of 97%. A review of strictly first MTPJ fusion using interpositional bone graft would be the most valuable here.

Technique

When it is possible to perform a primary end-to-end arthrodesis, the dissection and bone preparation are not unlike those performed for a primary first MTPJ arthrodesis. In light of a prior HAV surgery, it must be determined if the original surgical cicatrix location is suitable to provide exposure for this procedure. If the cicatrix lies dorsal or dorsomedial along the first ray segment, then it is probably useful to prepare this exposure incorporating that cicatrix to minimize the risk of further skin compromise. Often, it is necessary to extend the incision both proximally and distally by an additional 1.0 cm to identify normal soft tissue planes and prepare the most meticulous dissection as possible for a revision procedure. An incision along the dorsal or dorsomedial aspect of the first metatarsal measuring approximately 6 to 8 cm in length will allow for adequate exposure of the first MTPJ region depending on the size of the foot. Sharp and blunt dissection is performed to expose the deep fascia over the joint. The periosteal and capsular incisions are prepared in a linear fashion immediately in line with the skin incision. Once the intra-articular segments are exposed, thorough denuding of the cartilage surfaces and preparation of the parts for fusion are paramount to establishing a sound foundation for fixation. If a primary arthrodesis is feasible and the metatarsal length is sufficient, then an end-to-end procedure should be completed. Denuding the cartilage from the articular surfaces should be done in a fashion that minimizes bone loss and preserves length. This can be done using rongeurs, curettes, or power instrumentation. A crescentic blade can be used to resect the cartilage with a minimum of bone loss. An alternate technique uses a cone reamer and contours the surfaces to preserve the ball and socket configuration. The technique used should be one that is most comfortable and expeditious for the surgeon. The desired morphology of the fusion site is reliant upon the resection technique. That is to say, if the ball and socket configuration is to be maintained, then curettage, conical reamer, or crescentic saw blade resection will facilitate that goal (Fig. 36.18). These techniques tend to result in the least amount of bone loss and therefore aid in preserving the final length of the first ray. If a flush cut, flat, end-to-end arthrodesis is desired, then resection using a fine-tooth sagittal saw is preferred to minimize bone loss. This will create a ginglymus joint that will allow for two points of fixation using pins, screws, staples, or cerclage techniques. While rongeurs can be used for this purpose, they are difficult to use on the concave surface of the hallux base, especially in dense or sclerotic bone. Copious irrigation is completed before realignment of the parts to remove any bone debris that may interfere with bone apposition. Additional fenestration of the subchondral region of bone using a 0.54-inch K-wire may be desired if this layer is very thick or sclerotic. This encourages immediate perfusion and may facilitate vascular ingrowths over time.

Once the bone has been prepared for arthrodesis, the position of fusion must be determined, and this is the most important functional decision to be made during the procedure. Intraoperatively, it is possible to simulate weight-bearing by flexing the patient's knee and placing the foot at 90 degrees to the leg with the foot flat atop a solid surface, for example, an instrument tray lid. With the ankle at 90 degrees and the foot in neutral weight-bearing position, the hallux can be elevated just until it is possible to pass an index finger freely between the hallux and the tray. This subtle dorsiflexion of the hallux will allow enough motion to load and propulse off of the HIPJ. With the hallux rectus or slightly abducted to parallel the adjacent digit, the position should prove to be comfortable in sensible shoe gear. This exercise also serves to prevent an equinus position of the hallux. Although a wide range of positions have been suggested as the optimal position for a first MTPJ arthrodesis, generally, the desired position of fusion is considered 15 degrees to 25 degrees dorsiflexion with a similar degree of abduction, often 15 degrees to 20 degrees (64). This position of fusion takes into account that the first MTPJ must dorsiflex approximately 20 degrees to accommodate a 1-inch heel height (6,65,66). While these parameters are a general guideline, it is understood that position of the fusion site becomes a function of the surgeons experience and preference. This in mind some would recommend creating a congruous first MTPJ with only slight elevation and abduction. Once adequate joint position and alignment has been achieved, provisional fixation should

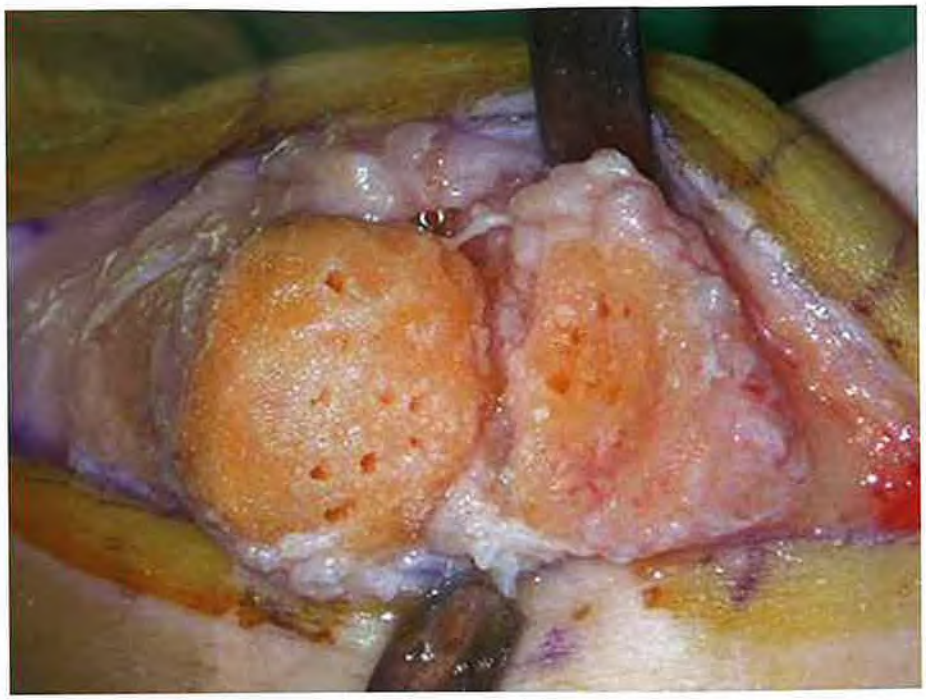

Figure 36.18 Intraoperative photograph showing that the articular surfaces of the first MTPJ have been denuded while preserving the subchondral surface. Once fenestrated using a 1.5-mm wire pass drill bit, the parts can be juxtaposed for arthrodesis. Several techniques can be utilized to denude cartilage from these surfaces such as curettage, the use of crescentic saw blades and curettement, or the use of conical reamers. These techniques facilitate denuding of the articular surfaces with minimum bone loss. (Courtesy of Jordan Grossman, DPM).

be applied. Temporary fixation of the parts using two 0.062-inch K-wires should be placed to firmly capture the desired position, and intraoperative radiographs should confirm final position, alignment, and adequate coaptation of the parts. Multiple orthogonal planes should be reviewed to ensure that a maximum of bone to bone contact has been achieved. Once satisfied with position and alignment, the decision to use crossing K-wire fixation or alternate techniques to provide rigid internal fixation can be made. Fixation should be critically assessed to ensure there are no devices interfering with HIPJ joint function and that no device is protruding plantarly to impede weight-bearing.

Internal fixation for an end-to-end arthrodesis is strictly a matter of surgeon preference in good-quality bone. Crossing K-wires work well in the face of osteoporosis, while other K-wire configurations have proven equally effective. Parallel 0.062-inch K-wires or small Steinman pins can be used as external devices running out the hallux base and retrograded into the first metatarsal and can be removed after solid bone union has been achieved (Fig. 36.19). The crossing screw technique and the use of a low-profile plate are perhaps the most commonly used in more dense bone. The plate may be placed either dorsal or medial across the joint, and this should vary depending upon available soft tissue coverage. When the dorsal skin has suffered from atrophy and considerable adhesion exists, the vascularity of the region may not support a dorsal plate, and the medial application is a viable alternative. The use of plates and screws, threaded Steinman pins, K-wire and cerclage, single oblique screw, and double crossing screw techniques as well as the peg and hole technique have all been described with successful outcome over time (44,45,48,50,51,53,67–92).

Once satisfied with the position and alignment of the fusion and internal fixation device(s), copious irrigation is completed and a layered closure is performed. Care is taken to cover the periosteum over fixation devices to prevent irritation due to prominent devices or interference with the function of the extensor tendons. A sterile bandaging of the foot and ankle is completed with the benefit of a Jones compression dressing incorporating a cryotherapy unit as desired. A posterior splint or a fiberglass egg shell can be applied to encourage compliance with the non-weight-bearing. The postoperative course is a matter of debate to some. Traditionally, a non-weight-bearing course for 4 to 6 weeks has been exercised, while others suggest modified protected weight-bearing in a firm-soled or orthowedge shoe. Regardless of the technique used, the site of fusion should be protected and monitored clinically and radiographically over 6 to 8 weeks time to ensure adequate bone consolidation and maintenance of position. The physical rehabilitation plan includes a short leg compression stocking beginning once the surgical wound has completely healed. This will prevent prolonged edema and the development of subsequent neuritic symptoms. Gradual advancement into firm-soled athletic shoe gear is pursued to tolerance as early as 6 weeks postoperatively if radiographic consolidation is evident on multiple views.

Pearls/Pitfalls

Interestingly, the technique of creating a peg and hole arthrodesis construct has proven efficacious even as a primary surgery to correct the HAV deformity. When an overaggressive exostectomy has been performed and the residual metatarsal head has been reduced to a fraction of its original morphology, this technique may prove curative (92). The authors of this technique article declare an 85% success rate with the caveat that it is suggested for elderly patients. Further, it is touted that the peg and hole technique does not require internal fixation and that protected weight-bearing is allowed to tolerance as opposed to traditional protocols associated with first MTPJ arthrodesis. Of the 31 patients undergoing this technique for severe HAV deformity, none experienced hallux varus even when significant metatarsus primus varus was evident preoperatively. In the original article, the technique was described using a beef bone

Figure 36.19 Multiple K-wires or Steinmann pins are useful for fusion of the first MTPJ and is commonly used with or without concomitant fusion of the HIPJ. Three parallel pin **(A)** and two parallel pin **(B)** techniques. Whether to use two or three points of fixation is a matter of the size of the parts. When the bone is sufficiently large, it may take multiple points of fixation to gain stability in both the transverse and frontal planes.

peg and manual impaction of the parts without fixation and was performed in 33 cases resulting in a 90% fusion rate (92). Of the 10% that experienced nonunion, it was found that they broke the peg at the fusion site when resuming unprotected weight-bearing at 6 to 8 weeks after surgery. It is interesting to note that the original author suggested prolonged plaster cast immobilization for 8 to 10 weeks contrary to more contemporary recommendations by Humbert 20 years later (91).

A similar technique, using specially designed reamers, fashions a cone at the metatarsal head for a peg and socket articulation. After reviewing 85 such first MTPJ fusions over a 20-year period, the authors tout a 97.6% fusion rate while maintaining the corrected position in long-term follow-up (93).

Using preoperative radiographs is the best way to predict the extent of bone deficits due to devitalized bone and to prepare for the size of bone graft required for harvest. The size of the graft must be sufficient to fill the defect and restore optimal length to the first ray segment. Once the size of the graft is determined, selection of the size and shape of the plate can be completed. This preoperative assessment will allow precise measures of both the length of the plate and allows estimation of the length of the screws required along each segment of the ray. To interpose an intercalary bone graft, it is beneficial to first measure the plate against the entire length of the metatarsal bone graft phalangeal base segment to determine where the center of the plate should lie. It is desirable to have at least 2 or 3 points of fixation proximal and distal to the graft to create the most stable construct whenever possible. When using the small low-profile devices designed for the small bones of the foot, this may require the use of a 10-hole plate or larger. On the back table, the graft can be prepared by running a single screw through the plate and graft to create a preliminary strut for mounting the plate to the site of fusion. Now with the plate and graft secured, this solid unit can be interposed between the metatarsal and the phalangeal base. Compression of the plate along the first ray is achieved with the benefit of plate clamps while the remaining screws are placed using standard AO technique. To provide axial compression across the fusion site, eccentric drilling of the screws placed just proximal and distal to the graft should be performed (Fig. 36.20).

Whether to use an autograft or allograft implant has been a matter of debate over recent years, and so there has been a fair amount of research to investigate the question. Traditionally, when a large tricortical-type graft was desired, an autograft from the iliac crest is preferred (59,94,95).

What we have learned over time is that allogenic bone performs well in foot and ankle surgery and can provide excellent functional long-term outcomes. The current literature suggests that arthrodesing procedures in foot and ankle surgery can be done safely and effectively with the benefit of allogenic bone graft materials sparing the patient a second operative site and avoiding the natural complications attributed to bone graft procurement (57,60–62).

Others have made it clear that arthrodesing procedures can be successful without the benefit of any bone graft whatsoever (63,96,97). If in fact bone supplementation is being considered strictly to enhance perfusion at the site of fusion, then an autogenous graft is the most physiologic technique.

Figure 36.20 Fusion with a smaller-profile titanium plate and an interfragmentary screw. These materials are more compatible with the size of the bones at the first MTPJ and from a biologic perspective.

When considering bone grafting in the small bones of the forefoot, the discussion differs dramatically from that in rearfoot arthrodesing procedures. In the face of large bone reconstruction, the use of autogenous bone remains the graft material of choice in arthrodesing procedures (57). However, despite its inherent lack of bone morphogenic protein, allogenic bone graft has been shown to perform well in numerous procedures in foot and ankle surgery (60). When given a healthy perigraft environment, these bone bank specimens provide ample structural support and a porous surface area to allow for creeping substitution in secondary bone healing (98). In contrast to this, it has been demonstrated that autogenous bone graft is preferred in salvage reconstruction of the very small bones of the forefoot in which vascular compromise in the adjacent tissue beds is an issue (99). Most authors would agree that if there is any question of the vascular competence of the recipient bed or the peripheral graft sites, then the benefits of using autogenous grafting to enhance bone healing outweigh the risks associated with donor site morbidity (60,98,100–103).

Techniques in autogenous bone grafting of the first MTPJ have been suggested specifically when length has been lost after metatarsal osteotomy procedures (104). Further, single-stage lengthening techniques using autogenous bone graft have been compared with the callus distraction technique. Ultimately, it is reported that the one-stage approach yields bone healing at a faster rate (6 weeks vs. 10.8 weeks, respectively, in one study). Neither technique resulted in neurovascular compromise with similar outcomes in length achieved from both (105). The use of intercalary bone grafting in revisional bunion surgery to restore length has been documented with good success even in cases in which bone quality was suspect (58,59).

Whether the fusion is end to end or if a bone graft is used, the hallmark to successful bone healing is rigid internal fixation and immobilization of the parts. The hallmark to functional success is proper positioning of the parts for fusion and function. Based upon published reports in large series reviews of first MTPJ arthrodesis procedures, the union rate ranges from 68% to 100%. Many of these procedures have been performed for failed HAV surgery. When a bone graft is used, it is intuitive that the complication rate in bone healing may be increased; however, this was not born out in the above-mentioned review as only one study reported the use of the inlay bone graft technique and touted a union rate of 97%. A review of strictly first MTPJ fusion using interpositional bone graft would be the most valuable here.

Even when an overly aggressive exostectomy has been performed, it does not usually affect the length pattern of the first ray and commonly leaves the foundation for a relatively straightforward arthrodesis. Stabilization of the construct can then be prepared definitively using a variety of techniques depending upon the quality of bone present. In the event of osteoporosis, modifications in the fixation plan may include the crossing K-wire technique (with or without the prebending),dual or triple parallel external K-wire technique (see Fig. 36.19), staples (two-staple technique using 90-degree staple orientations), or an interlocking plate. In the face of unusually porous bone, the use of at least two points of fixation is advised to prevent motion about the fusion site.

When normal bone quality exists, aside from the eminence deficit, more traditional devices can be used to provide an end-to-end arthrodesis, and these include single- or double-screw techniques, staples, or the combination of cerclage and 0.062-inch K-wire. The nuances for each of these internal fixation techniques are found in alternate sections of the text.

REVISIONAL HAV SURGERY IN THE JUVENILE PATIENT

When juvenile forms of HAV have met failure from bunion surgery, it is typically the result of having failed to appreciate the influence of residual metatarsus adductus, an increased PASA, equinus, peritalar subluxations, flexible flatfoot deformity, or some combination thereof (106). Most forefoot surgery performed in the face of midfoot and rearfoot pronation should be supplemented with the benefit of an aggressive prescription (University of California Biomechanics Laboratory) to enhance long support and control of these added deforming forces. Optimal revision of the juvenile bunion may require addressing the residual metatarsus adductus to avoid more important deformity and dysfunction in adult years. In the face of osseous immaturity, this can be accomplished with the benefit of an epiphysiodesis (106–109). Alternately, waiting to achieve osseous maturity may be the better part of valor prior to attempting revisional surgery as this will allow complete closure of the proximal growth plate of the first ray and facilitate the use of proximal arthrodesing techniques when indicated. Gastrocnemial or gastrocsoleus equinus has a noted contribution to the development or exacerbation of an HAV deformity. Indentifying the influence of such a powerful dynamic and destructive force is paramount to success in revision. Conservative therapies to address this component of the problem may be pursued; however, when a severe or recalcitrant condition exists, a gastrocnemius recession or Achilles tendon lengthening may be a vital adjunct.

Pearls/Pitfalls

It is important to avoid an overly aggressive capsulotomy and lateral release. When addressing recurrent HAV deformity, an overly aggressive capsulotomy will increase the risk of developing a hallux varus deformity. Should the lateral capsulotomy

be too extensive, the defect will not completely fill with fibrous tissue leaving the lateral capsule insufficient to counter the retrograde pressure of the hallux on the metatarsal head. With lateral capsule weakness, the hallux may tend to drift unopposed into a varus alignment.

Understanding the structures involved in the lateral release will provide a better understanding of why HAV surgery may fail. The functional unit of this region is referred to as the sesamophalangeal apparatus as coined by Gillette (110) and is composed of the two sesamoids invested within the fibrous plantar plate and takes attachment from the base of the hallux proximal phalanx. While the metatarsal head remains fixed with normal motion of the MTPJ, the sesamophalangeal apparatus moves forward and backward about the stationary metatarsal head with manipulation of the joint. In hallux valgus deformity, the sesamoids, which are embedded in the plantar plate, may appear to be displaced as the phalanx rotates lateralward. The retrograde pressure of the hallux on the metatarsal head can force a medial translation of the first metatarsal further exaggerating the appearance of sesamoid displacement. The sesamoid ligaments each attach to the collateral aspects of the first metatarsal head proximally and to the base of the proximal phalanx with distal extensions into the plantar plate. These ligamentous investments make the distal and collateral portions of the plantar plate much stronger than the central portion (24). This weaker central portion of the plantar plate apparatus is subject to wear and frank injury under certain circumstances. With this in mind, it is important to respect the plantar plate when a lateral release is performed as iatrogenic defects can result in insufficiency of the sesamoid apparatus and dysfunction of the MTPJ resulting in subluxation or even dislocation of the joint (Fig. 36.21). Such is the case in a first MTPJ hyperextension injury in which the metatarsal head ruptures the weaker intersesamoidal segment and creates a "button hole" through the plantar plate allowing the sesamoids to dorsally dislocate with the base of the phalanx.

Figure 36.21 Postoperative DP radiograph reveals the hallux subluxation and sesamoid dislocation as a result of violation of the plantar plate and lateral head of the FHB of the first MTPJ. The resultant hallux varus is chronically painful and disruptive in any form of shoe gear. This requires soft tissue rebalancing and repair to reduce the medial contractures.

When subsidence has resulted in a loss of cubic content of bone, it is prudent to critically evaluate the metatarsal parabola radiographically and compare the length pattern of the first ray to that of the contralateral limb both clinically and on weight-bearing plain x-rays. This will help in determining the graft size necessary and may allow for graft harvest from a local source rather than from a larger more proximal site such as the iliac crest. If it is determined that a local autograft will suffice, then the risks of the procedure and subsequent postoperative morbidity may be markedly reduced. Whether to use allograft or autograft in such foot surgery has been discussed in the literature with the consensus that allograft can be used safely and effectively in these cases (57,60–62).

When complications of bunion surgery have resulted in a loss of cubic content of bone, it is prudent to critically evaluate the metatarsal parabola radiographically and compare the length pattern of the first ray to that of the contralateral limb both clinically and on weight-bearing plain x-rays. This will help in determining the graft size necessary and may allow for graft harvest from a local source rather than from a larger more proximal site such as the iliac crest. If it is determined that a local autograft will suffice, then the risks of the procedure and subsequent postoperative morbidity will be markedly reduced.

When supplementing a revision osteotomy with bone graft or when converting an osteotomy procedure into an arthrodesis, there is a need for provisional fixation and stabilization of the construct prior to the application of a low-profile plate. This can be achieved using a long K-wire, which can be later removed or retained as a supplemental point of fixation. Application of a provisional device can be accomplished using a K-wire applied axially out through the hallux and retrograded into the metatarsal segment securing the entire length of the construct. When bone healing complications require a joint fusion or supplementation with bone graft, use of a locking plate system can be entertained with predictable results.

Whether to use allograft or autograft in revisional forefoot surgery has been discussed in the literature with the consensus that allograft can be used safely and effectively in these cases (57,60–62). It stands to reason that the survival of the graft is dependant, at least in part, on the integrity of the adjacent soft tissues and bone. If in fact the recipient bone site is dysvascular, that is an ominous sign when considering the use of allogenic bone material since that graft will be more reliant upon the recipient bone and soft tissues for nutrition and support (111). Autogenous bone graft is less reliant on the surrounding tissues and so is more likely to survive in what is already considered a compromised situation.

BONE HEALING COMPLICATIONS

The bone healing complications associated with the HAV surgery include delayed union, nonunion, and malunion of bone. In fact, these three conditions may constitute a spectrum of bone healing abnormalities and in HAV surgery can result in a malunited and malpositioned osteotomy. These three conditions are closely related; however, they are defined individually and so will be treated as distinct entities for the

purpose of discussing complications in HAV surgery. Only clinically significant or symptomatic conditions will be discussed herein.

MALUNION

A malunion, for practical purposes, is described as any angular, axial, or rotary deviation of an osteotomy other than that intended from the original procedure. From a functional standpoint, only those cases that are symptomatic are of clinical significance. Dorsal tilting of the osteotomy segment is perhaps the most common of bone healing complications and has been reported as occurring from 1.6% to 14% of cases although in the largest study less than 2% incidence was reported and no clinical significance was reported (125,130).

Regarding proximal metaphyseal osteotomies, a malunion resulting in an elevatus will undoubtedly become symptomatic and functionally important. In this event, the condition requires serious consideration for revisional surgery should prescription orthosing and shoe gear modification fail to alleviate symptoms. The malunion can largely be avoided by assuring rigid internal fixation and strict adherence to a postoperative course of non-weight-bearing during the primary bone healing process.

Evaluation and Procedure Selection

Radiographic evaluation is the mainstay in the assessment of a malunion. Should perfusion or mineral deficits be suspected, ancillary imaging such as NMI, MRI, or CAT will be of value. In most cases, plain radiographic evaluation performed in standard orthogonal planes will elucidate the nature, location, and extent of the malunion. The lateral view is most helpful in determining the extent of sagittal plane elevation of the part while shedding light on the condition of the residual joint space. The DP and forefoot axial views will help to identify any degree of combination (transverse or frontal plane) deformity that may complicate the potential for orthotic management.

In reviewing 109 feet after proximal metatarsal osteotomy and interspace release, a 28% incidence of radiographic elevatus was reported without associated clinical symptomatology or new transfer lesion (131). It is believed that up to 10 degrees of dorsal elevatus of the capital fragment can be tolerated without clinical ramification as long as joint congruency has been maintained (132).

The functional significance of subtle dorsal malalignment of the metatarsal head may be of no clinical significance as long as a functional position and alignment of the joint has been achieved and maintained. While transverse and frontal plane deviations do occur, their sequela falls into the category of overcorrection or undercorrection of the original deformity, and those conditions are discussed earlier in this chapter.

Radiographic assessment of the osteotomy site can help elucidate the reason for malunion. If a sclerotic line is apparent in the region of the malunion, then it is likely that motion prevented bone healing and instability resulted in deviation of the bone segment. When a significant loss of normal bone trabeculations is apparent, it can be presumed that an underlying osteopenia or osteoporosis is contributory. When there is evidence of proliferative bone callus formation, it is suspected that a delayed bone healing process has contributed to instability of the part and eventual malalignment developed with progressive weight-bearing.

When clinically significant, a dorsal elevatus of the first metatarsal head will yield joint dysfunction and limitation of motion that prompts biomechanical compensations and transfer metatarsalgia. When present, these mechanical compensations can result in imbalance and proprioceptive deficits that increase the risk of falling. As a consequence, when symptomatic, first metatarsal elevatus is clinically important and should be addressed as soon as it is identified. This condition is not one that the patient will "get used to" or adapt to and places the patient at an increased risk for injury. In essence, this patient has traded a bunion deformity for hallux limitus. As time goes on, less weight is accepted by the medial column of the foot and transfer lesions will develop in association with lesser digital deformities. Porokeratomas, nucleated and even neuritic hyperkeratotic lesions, may develop as a result of this important imbalance. When hypertrophic or heterotopic bone develops about the periphery of the joint, most commonly the dorsal first MTPJ, shoe gear irritation becomes prevalent. To best understand the impact of the metatarsus elevatus, determining whether an intrinsic (structural) or extrinsic (positional) elevatus is present is important (15).

An intrinsic metatarsus elevatus can occur as a complication from a malunion of a proximal metatarsal osteotomy resulting in an elevated position of the part. First MTPJ malalignment due to an intrinsic deformity results in joint impingement and an abnormal wearing of the articular surfaces. While a functionally important intrinsic elevatus can occur from a distal metatarsal osteotomy, the literature discusses the ramifications of this as a complication of proximal metatarsal surgery much more frequently.

Conservative Treatment

When a clinically important intrinsic metatarsal elevatus is the result of HAV surgery, the resulting condition is hallux limitus. Conservative management for this joint malalignment and dysfunction can be achieved with the benefit of a prescription orthotic device that provides a Morton extension to off-load the joint and balance the lesser metatarsal segments. The use of a polylaminate material can provide enhanced shock absorption and support that allows pain-free ambulation. When a semiflexible orthotic device with a semirigid extension along the distal first ray segment is enhanced with these shock-absorbing materials, an orthotic device can be curative. Of course, the orthotic device will be required for a lifetime, and barefoot activities are unlikely to be tolerated. Often, continued limitation of activities despite modified orthoses is not satisfactory for many patients, and in younger more active individuals, it is predictably futile. Definitive surgical procedures can be divided into three categories: (a) salvage via revisional procedure or surgical reconstruction, (b) lesser metatarsal osteotomy to address discrete transfer lesions, or (c) joint destructive procedures. Salvage procedures may include either distal or proximal metatarsal procedures, while joint destructive procedures may require arthrodesing procedures or in the most severe cases pan metatarsal head resection.

Surgical Management of Intrinsic Metatarsal Elevatus

Revisional DMO to correct clinically significant capital fragment elevation. When the malunion is the result of a DMO, revision of the index procedure (DMO) can be

entertained as long as the underlying bone quality permits and no significant shortening is apparent. When significant shortening is present, simple revision of the DMO will likely be met with failure. Complicating conditions such as osteopenia and osteoporosis (or systemic disease resulting in the same) add to the difficulty of revisional surgery. Enhanced fixation techniques can be employed to prevent recurrence of the deformity.

The technique of revising a distal metatarsal osteotomy has been described earlier in this chapter. Modifications of the revisional DMO to achieve plantarflexion of the metatarsal head include a dorsally based opening base wedge osteotomy with placement of a small allogenic or autogenic graft wedge cut to fit for derotating the capital fragment. This osteotomy is created by scoring a dorsally based wedge in the medial aspect of the distal metaphyseal region of the metatarsal. A 0.045-inch K-wire is used as an axis guide using the same principles discussed earlier in the section on the CBWO. The size of the wedge is dependent on the degree of plantarflexion required to create a congruous joint. A similar procedure can be performed using the closing wedge technique. A dorsal apex and a plantarly based wedge osteotomy will derotate the metatarsal head in a similar fashion. The closing wedge technique avoids the need for bone graft and may be technically easier to perform. Standard 0.062-inch K-wires or cancellous screws are used for definitive fixation. Absorbable devices will work in these procedures; however, in revisional surgery, the additional risks of geode formation compromising the repair or more important foreign body response tilt the risk to benefit ratio in a negative direction and so are discouraged. Regardless of the distal procedure selected, the intraoperative goals that must be achieved for successful joint function are plantar rotation of the capital fragment and congruency of the first MTPJ allowing for unrestricted motion.

Revisional proximal metatarsal osteotomy to correct intrinsic metatarsal elevatus. When the index procedure was a proximal metatarsal osteotomy, revisional surgery is a matter of surgeon preference. The most common surgical options include a proximal metatarsal shaft procedure, a modified closing base wedge, or a first metatarsal cuneiform arthrodesis. Each of these procedures has been discussed in detail earlier in this text. When considering correction of this deformity, surgical goals can be divided into two categories: (a) correction focused upon the apex of deformity and (b) chief complaint surgery. From a purist perspective, elective foot surgery should be geared to correct the apex of structural deformity to provide optimal function in a pain-free manner. However, as a matter of principle, surgeons may choose to perform elective surgery for one goal or the other depending on certain variables such as the surgeon's preference and ability, the circumstance leading to the deformity (injury, congenital or iatrogenic deformity), and the patient type (age and desired activity of daily living).

When the index procedure was an oblique base wedge osteotomy, the original osteotomy line will be readily apparent once the initial dissection has been completed down to the deep fascial layer. The periosteum is minimally dissected whenever possible to provide exposure of the part and provide later coverage of the fixation device(s). After close scrutiny of the original osteotomy line, manual instrumentation is used to rescore the line of the osteotomy. This will provide a track for the oscillating blade to follow during resection of the part. Care is taken to gently remove existing internal fixation devices to best preserve the cubic content of bone. The MCJ is identified, and a 25-gauge needle is placed within the joint as a proximal joint landmark. Once fixation has been removed, an axis guide is driven through the metatarsal base in the transverse plane from medial to lateral and the osteotomy is scored to create a long oblique plantarly based wedge. This configuration will allow for plantarflexion of the metatarsal as the wedge is slowly closed with reduction forceps. The osteotomy is cut keeping the blade parallel to the axis guide, taking care to create and maintain the proximal dorsal hinge (Fig. 36.22). It is important to perform this maneuver under continuous saline lavage to avoid thermal necrosis and helps to avoid subsequent bone healing complications. Once the wedge of bone is completely resected, the proximal osteotomy is inspected to ensure that there are no retained bone fragments deep within the osteotomy. A bone reduction forceps is used to slowly close the osteotomy and to stabilize the parts while provisional fixation is applied. Intraoperative fluoroscopy or plain films should then be obtained to confirm adequate position and alignment of the first ray. The foot should be loaded to simulate weight-bearing, and the position of the first ray and range of motion about the first MTPJ should be critically evaluated to ensure that excessive plantarflexion has been avoided. The long oblique osteotomy often facilitates fixation with two small parallel cancellous screws when oriented from dorsal distal to plantar proximal within the metatarsal base. Once satisfied with the position and alignment, copious irrigation is followed by a layered closure ensuring complete deep fascial coverage of the fixation devices. A sterile compression dressing is applied beneath a modified Jones compression dressing fortified with a cryotherapy unit.

The geometry and concepts surrounding the hinge axis guide and radius arm of closure have been discussed in a comprehensive fashion earlier in this text. The nuances regarding modifying that procedure to achieve plantarflexion in a closing wedge fashion are important. Here the axis guide is prepared approximately 1 cm distal to the first MCJ to provide a dorsal cortical hinge. The MCJ should be identified and marked with the benefit of an 18-gauge needle to serve as a landmark to prevent violation of this proximal joint. Exposure of the base can be difficult due to the natural morphology depth of the first metatarsal base. Complete periosteal stripping about the proximal metaphysis is required to facilitate application of the axis guide and the plantarflexory osteotomy. Using a 0.062-inch K-wire, the axis guide is run through the proximal metatarsal base from medial to lateral purely in the transverse plane. When this distally based plantar wedge is resected appropriately, the axis will allow motion strictly in the sagittal plane. The osteotomy may be modified to create an osteotomy perpendicular (rather than oblique) to the axis. This will create a smaller osteotomy that rests primarily within the diaphyseal metaphyseal junction of bone. The more proximal the hinge axis, the more effective the radius arm for reversing the elevatus deformity. If the shorter, perpendicular osteotomy is performed, then closure can be secured with the benefit of crossing 0.062-inch K-wires or screws, small Steinman pins, horizontal cerclage wire, or staples. Absorbable devices will work in these procedures; however, in revisional surgery, the additional risks of geode formation compromising the repair or more important foreign body response tilt the risk:benefit ratio in a negative direction and so are discouraged.

Copious irrigation is followed by a layered closure ensuring complete deep fascial coverage of the fixation devices. A sterile

Figure 36.22 **A:** Preoperative radiograph reveals residual metatarsus primus elevatus and hallux flexion deformity resulting in chronic shoe gear irritation and pain within the first MTPJ. Additionally, this forefoot dysfunction will prompt rearfoot supination due to biomechanical compensations and a functional hindfoot varus may coexist. **B:** Intraoperative photo reveals the axis guide approximately 1 cm distal to the MCJ. The osteotomy cut for a plantarflexory CBWO is prepared in a long oblique fashion to adequately reduce the iatrogenic metatarsus primus elevatus. Notice the blue needle hub marking the landmark of the first MCJ. **C:** Postoperative weight-bearing lateral radiograph demonstrating complete reduction of the first metatarsal deformity. Two points of fixation are required to secure the long oblique osteotomy used to reduce the elevation of the distal metatarsal segment.

compression dressing is applied beneath a modified Jones compression dressing fortified with a cryotherapy unit.

The opening wedge osteotomy can be performed to achieve plantarflexion of the first ray. The level of the MCJ is marked using an 18-gauge needle. An axis guide is driven from medial to lateral through the transverse plane of the inferior quadrant of the first metatarsal base. The wedge osteotomy is scored to create an oblique dorsally based wedge. When the osteotomy plan is satisfactory, a sagittal saw is used to cut the segment and the wedge of bone is removed. The osteotomy is planed gradually as each pass of the saw resects 1 mm at a time. The metatarsal segment is manipulated into plantarflexion, further opening the wedge until adequate reduction of the elevatus has been achieved. A cortical graft must be incorporated into the construct to maintain position and alignment. Cortical bone is desired as it will provide durable support and resists subsidence and loss of correction as the graft incorporates. The size of the graft is dependent on the degree of correction required to reduce the metatarsal elevatus. Autogenous graft has numerous benefits over its allogenic counterpart, and graft materials are discussed in detail in a prior chapter. Autogenous bone can be procured safely from the body of the calcaneus as this affords a large surface area for graft procurement even a large graft can be obtained from this region (60). Some authors would

subscribe that the calcaneal defect residual from this graft does not need to be refilled as the healthy cancellous nature of the calcaneal body heals predictably. Others feel it is best not to leave any osseous deficiency prior to closure of the wound and so use allogenic bone to fill the harvest site void. Fixation of the graft within the metatarsal osteotomy can be achieved with the benefit of standard or cannulated screws. With a bone clamp in place, the osteotomy is closed compressing the graft dorsally. Provisional fixation is applied with the benefit of K-wires, and intraoperative fluoroscopy or plain films will confirm reduction of the deformity. Definitive fixation is completed with interfragmentary fixation complimented with a combination of plate and screws. Copious irrigation is followed by a layered closure ensuring complete deep fascial coverage of the fixation devices. A sterile compression dressing is applied beneath a modified Jones compression dressing fortified with a cryotherapy unit.

Regardless of the proximal osteotomy performed, the postoperative course is generally the same. The compression dressing is changed after 3 to 7 days, and a short leg fiberglass cast is applied. Non-weight-bearing is to continue from 6 to 8 weeks, depending upon radiographic evidence of bone consolidation. Protected weight-bearing is initiated only after evidence of bone consolidation has been confirmed. The hazards of an overzealous return to weight-bearing may well compromise the reconstruction and prompt another malunion or nonunion of bone. Weight-bearing is titrated slowly to tolerance in a controlled ankle motion (CAM) walker, and serial radiographs are obtained every 2 weeks unless otherwise indicated by a change in clinical symptoms. The development of pain, unusual edema, or warmth in the region of the osteotomy is a harbinger of instability. In the face of these outward changes non-weight-bearing should be reinstituted until stability of the construct can be confirmed both clinically and radiographically. Once the patient is converted into a firm-soled walking shoe, activities can be further advanced and radiographs may be taken monthly as needed. It is prudent to follow these cases out until athletic activities have been advanced and tolerated for months. The 6- and 12-month postoperative radiographs are generally representative of the long-term result of the procedure.

DELAYED UNION AND NONUNION

Delayed union is defined by the Arbeitsgemeinschaft für Osteosynthesefragen/Association for the Study of Internal Fixation as a fracture that is not united by 4 to 5 months (133). Others have suggested that the delayed union is the absence of healing in 2 to 6 months (134). Still others propose that the delayed union is a failure to demonstrate evidence of healing at an average rate for a specific location and type of fracture (135). Each of these definitions takes into consideration both radiographic and clinical signs of fracture healing. Radiographically, when gaps within a fracture site persist, it is suggested that granulation tissue (not scar) is present. When this correlates with continued outward signs of clinical change such as mild inflammation commensurate with fracture healing, the condition is said to be in a state of delayed union. During this time, protection and immobilization of the part is hallmark in therapy. The addition of external bone stimulation devices at this juncture is a matter of individual philosophy in fracture management.

Regarding the first metatarsal, specifically, the definition is not so well established, and delayed bone healing has been defined as a range from 4 to 8 months after the initial insult whether it be trauma or elective surgery. In one large study of first metatarsal osteotomies, 500 procedures were performed with K-wire fixation, and only one delayed union and no nonunions were reported. The working definition of a delayed union here was a lack of clinical or radiographic consolidation by 8 weeks after surgery but achieving bone union by 8 months (130). Watson Jones felt it best to discuss concepts of bone healing by virtue of the appearance of bone radiographically and described a "slow union" as separate and distinct from a delayed union or nonunion. The term slow or indolent bone union was used to describe a fracture that had the appearance of an early fracture despite more than a few weeks of healing. Here the fracture lines remain visible without evidence of fracture gap or callus formation. This fracture is not a form of nonunion and will heal with appropriate immobilization (136,137). In the delayed union, fracture repair is not complete and the fracture gap is filled with granulation rather than scar tissue in contrast to the sclerotic change noted in nonunion of bone. The sclerotic zones develop in a nonunion as the medullary canal actually seals off both ends of the fracture and prohibits closure of the fracture gap. If the local physiology is sufficient, a bursal projection may be interposed at the fracture site and a pseudarthrosis manifests radiographically.

Over time, the definition of the spectrum of healing from delayed union to nonunion of bone has varied considerably among physicians and even from region to region. This became clinically relevant with the advent of internal and external bone stimulation devices. In the early 1980s, when a physician chose to use a bone stimulator, it became a matter of added expense in fracture management and health care and its use was not without controversy (138).

For that reason, the definition of a nonunion, a condition in which the prognosis was that bone would not heal, became clinically important. The clinical criteria declaring the difference between a delayed union and a nonunion became a bone of contention between the physicians and the insurance companies. Use of the latest technology in bone stimulation devices required preauthorization and approval, which was and continues to be tightly controlled by the insurance companies and was most often denied. Due to controversy in determining what was a delayed union, a condition in which it was suggested bone healing may ensue, versus a nonunion, the need for a strict definition was declared. Thus, the U.S. Food and Drug Administration developed a definition of nonunion for the purpose of testing bone healing devices. Since this time, the diagnosis of nonunion could only be established after a period of 9 months had elapsed from the time of injury without radiographic evidence of healing over a 3-month period of time (133,137). Clinically speaking, it may be most appropriate to discuss delayed union of bone by virtue of outward signs and/or symptoms of continued bone healing such as persistent swelling, erythema, or calor in the region of fracture. Radiographically, the continued inflammation of a delayed union results in resorptive changes and widening of the fracture gap with obliteration of the fracture margins. The fracture margins of the delayed union are obscured as opposed to having very well-defined margins as in a slow or indolent union of bone. In some cases, the clinical symptoms are significant yet radiographic findings may be unimpressive, and so both should be taken into consideration. The documentation of clinical symptomatology and serial radiographic findings are important in any event and will support the diagnosis. The mainstay in therapy for the delayed union is conservative and includes

immobilization and the benefit of external bone stimulation as desired. Generally speaking, the delayed union has a good prognosis with conservative therapies.

Nonunions have been classified based upon perfusion about the fracture site in conservative fracture management and are categorized as either *hypertrophic* or *atrophic*. This clarification is made based upon plain radiographic findings and can be further elucidated by NMI. Classification schemes for nonunions are largely based upon nonunions occurring in the long bones of the lower extremity (135). A *hypertrophic* nonunion exists when there is a proliferative, well-vascularized bone reaction at the fracture site. Usually, this proliferative fibrous tissue will progress by calcifying and ultimately ossifies as it matures. The hypertrophic nonunion is considered a viable bone healing condition most commonly associated with fractures that have been closed reduced and have the potential to respond to bone stimulation. Hypertrophic nonunions can be further subdivided based upon their morphology and the amount of bone callus present: The *elephant foot* has a large amount of bone callus with an expanded rounded periphery of the parts, the *horse hoof* has a moderate amount of bone callus with relatively flat flush segments, and the *oligotrophic* nonunion in which the parts are not hypertrophic and there is no evidence of bone callus. An *atrophic nonunion* is distinct in that there is no evidence of local bone reaction and the site is not well vascularized. Typically, the avascular condition is associated with ORIF of fracture. It is intuitive that this condition may develop after severe trauma such as open, comminuted fractures and degloving injuries in which vascular structures may have been damaged or stripped from the fracture site. Atrophic nonunions can be subdivided into *torsion wedge, comminuted, defect,* and *atrophic* nonunions and are described based upon the appearance of the nonunion site. Classification of the type of the nonunion is directly related to treatment strategies as they define the viability, that is, vascularity of the nonunited fragments and their morphology. Generally speaking, hypervascular nonunions can be expected to heal with débridement, compression, and rigid fixation of the parts. Atrophic nonunions in contrast require resection of the degenerate bone ends and supplementation with bone graft prior to coaptation of the parts and rigid internal fixation. The repair of nonunions on the whole requires the same basic principles in fracture management such as anatomic alignment, compression, and rigid internal fixation of the parts complimented by non-weight-bearing immobilization.

A lack of radiographic evidence of bone union 6 months after the index procedure without signs of healing on serial radiographs suggests the diagnosis of nonunion and becomes a diagnosis of exclusion by 8 to 12 months. Today, the diagnosis of a nonunion has become more a matter of clinical impression and the diagnosis is made when there are no progressive radiographic signs of bone healing on plain x-rays.

The incidence of nonunion has changed over time as the study of fracture management has evolved, and the concepts of anatomic reduction and rigid internal fixation have been emphasized. Historically, the tibia has been touted as the long bone with the greatest propensity for bone healing complications, specifically nonunion (139). In Boyd and Lipinski's study of 741 patients with delayed union and nonunion of bone, the femur had the highest incidence of nonunion followed by the tibia, humerus, radius, ulna, and clavicle (140). Here the diagnosis of nonunion was confirmed with the presence of one or more radiographic findings such as obliteration of the medullary cavity, evidence of a pseudarthrosis with or without false motion, and sclerosis about the fracture ends. The time to diagnosis of nonunion averaged 8 months and 13 days, which is consistent with the definition of a nonunion by current standards some 40 years later. Another large series of fractures described the high incidence of nonunion in the long bones of the lower extremity in which out of 100 fracture nonunions, the vast majority (63 nonunions) occurred in the tibia (138). Regarding the first metatarsal, the literature is less replete, and interestingly, it has been suggested that 50% of nonunions here are asymptomatic (141). Clinical signs of nonunion may include induration, pain, localized warmth, and erythema. Often, motion about the fracture site can be confirmed by manipulation under fluoroscopy when a nonunion is present. When pain is present with and without weight-bearing, the presence of infection should be considered and promptly ruled out. Baseline serology such as the complete blood count and C-reactive protein are important portions of the workup and medical documentation. While bone biopsy remains the gold standard for the diagnosis of osteomyelitis, ancillary imaging via NMI can be used to delineate the location and extent of the infectious process (56). Radiographically, there may be malalignment of the osteotomy, bone callus, resorptive changes about fixation devices, migration of fixation devices, or radiolucency. Fixation devices may cause fatigue and evidence of stress fracture may be apparent in only one view, which underlines the importance of obtaining multiple orthogonal radiographs.

Treatment Considerations in Nonunion

Treatment is reliant upon the significance of the bone healing complication. The clinical and radiographic significance of a nonunion is naturally a matter of physician perception. Bhandari demonstrated this after surveying 444 surgeons in whom there was no clear consensus on matters such as the definition of nonunion or the parameters defining a clinically important malunion in tibial fractures. From this survey, the definition of nonunion variedly widely from 2 to 12 months. Furthermore, there was a lack of consensus regarding acceptable degrees of malunion such as shortening (ranging from <5 to >15 mm) and rotational or frontal plane deviations (ranging from 5- to 20-degree malalignment) (142). This supports the notion that despite all that we understand about bone healing and physiology, the diagnosis of nonunion and clinically important malunion remains controversial and is highly subjective. Treatment should be guided by clinical symptomatology and any apparent compromise of bone and joint function. Conservative management can be reasonably entertained when the position and alignment of bone are suitable for function. When significant malposition is evident and a poor functional prognosis exists, it is prudent to discuss definitive correction. In some cases, closed reduction of the part may allow for percutaneous fixation. When poor bone stock is a factor, external stabilization after manipulation may be prudent. More often, an open reduction with standard internal fixation is required to achieve definitive stabilization. When faced with a bone healing complication, less is not more and there should be due diligence in achieving anatomic reduction and rigid fixation of the part. When bone deficits and angular deformity exist, multiplane correction with bone graft material will be required. Additional planning is required in these instances as interpositional grafts need to be tailored for the size, shape, and angular

configuration required to realign the part. Absolute immobilization of the part is essential to expedite bone union in these complex cases. Treatment options for nonunion after a distal metatarsal osteotomy include (a) callus distraction and first MTPJ arthrodesis; (b) resection of the nonunion with revision of internal fixation with or without interpositional bone graft; (c) excision of the nonunited bone fragment, with or without lesser metatarsal head resections; or (d) first MTPJ arthrodesis. The procedures for metatarsal head resection (isolated or pan metatarsal head resection) and first MTPJ arthrodesis have been detailed earlier within this chapter.

Two-Stage First MTPJ Arthrodesis Procedure, Callus Distraction Osteogenesis, and End-to-End First MTPJ Arthrodesis

When a nonunion is apparent after a DMO with significant shortening of the metatarsal segment, the joint may not be salvageable. If progressive joint space narrowing and degenerative changes of the first MTPJ have developed, then chronic instability, pain, and compensatory gait disturbances are predictable. Conservative measures in this instance may be met with failure and warrant serious considerations regarding the salvage option. The keys to salvage in this condition are to restore length to the metatarsal and to realign and definitively stabilize the joint. This is one of the most challenging scenarios among complications in HAV surgery. Here a staged approach can be entertained for restoration of the length of the first ray segment followed by stabilization of the first MTPJ via arthrodesis.

While it is possible to use intercalary bone graft to increase the length in a congenitally short first metatarsal, the soft tissue contractures and scarring that results from complications in HAV surgery may prohibit elongation of the soft tissues and neurovascular elements. When this iatrogenic shortening is significant, greater than 15mm, the single-stage procedure is less predictable and may result in complications such as joint jamming or neurovascular compromise. The ill effect of an abrupt lengthening of bone has been demonstrated both in the laboratory and in clinical practice, and as little as 6-mm acute lengthening is believed to cause considerable tension within the soft tissue envelope of the first ray (143). In this case, the gradual lengthening of the callus distraction procedure may be tolerated better and provides a more physiologic approach to reducing the bone deficit. This technique will effectively provide restoration of the first ray length while creating a viable substrate for a first MTPJ fusion. A principal indication for callus distraction osteogenesis is a bone defect measuring greater than 15 mm resulting in shortening and dysfunction of the ray (144). It is believed that attempting a single-stage lengthening via intercalary bone graft in these instances will insult vital neurovascular elements and will compromise the health of the entire segment. To avoid that potential complication, a gradual lengthening using the callus distraction technique may be better tolerated (145). While an acceptable cosmetic result is frequently reported, this technique is suggested for the purpose of addressing pain and dysfunction resulting from failed HAV surgery in this instance, not for cosmetic appeal alone.

Success using this technique is predictable when the basic principles of callus distraction and enhanced fixation for arthrodesis are fully appreciated. Proper application of the external fixator will be facilitated by first establishing orthogonal alignment of the fixator to the first ray and the nonunion fragment. In this scenario, a small external fixator may be used to create a strut to stabilize the parts by first aligning the distal fragment to the metatarsal shaft, conducting a callus distraction to the desired length and finally conducting an end-to-end arthrodesis at the first MTPJ.

While this technique is straightforward from an academic perspective, the technical execution of the procedure is rather intensive and requires strict attention to detail in surgical technique and very deliberate considerations in management throughout the entire perioperative period. Successful management of this complex case requires thorough patient education regarding each step of the process and a detailed description of patient instructions for each. Proper patient selection and reasonable patient expectations are to be established prior to proceeding with this procedure.

Technique

Stage I: Callus distraction osteogenesis for restoration of length. A calf tourniquet may be applied to provide hemostasis although is not mandatory for this procedure. The first stage of the technique is completed in two parts: one static and the other dynamic. The *static* portion of the procedure includes anatomic dissection to determine viability of the nonunited fragment and application of the external fixator. When the bone quality of the metatarsal head is sufficient, it can be included in the arthrodesis. When the part is avascular and sclerotic, the degenerative condition is considered end stage and the fragment should be excised in toto. The *dynamic* portion of the procedure is the distraction osteogenesis, which will restore length and ultimately provides a solid foundation for stabilization and arthrodesis (Fig 36.23).

Anatomic dissection is begun from a dorsolinear incision to gain access to the first MTPJ and the site of nonunion. The subcutaneous structures are handled meticulously to avoid wound complications and provide a quality layer for later closure. In revision for this complication, there is no need for violation of the first intermetatarsal space and so there is no soft tissue balancing per se using this technique. The EHL tendon is identified, isolated, and retracted laterally. The deep fascial structures are exposed and an extensile dorsal linear incision is made along the periosteum from the midshaft of the metatarsal segment across the capsule of the first MTPJ ending at the midshaft of the proximal phalanx of the hallux. Maintaining this soft tissue envelop in continuity better prepares the periosteal envelope to enhance the quality of regenerate bone (146,147).

Reflection of the joint capsule can be facilitated by incising a vertical arm into the capsule at the medial joint level when fibrous adhesions or heterotopic calcifications complicate joint exposure and preparation of this tissue layer. Soft tissue contractures and fibrosis of the sesamoid apparatus may restrict mobility at the MTPJ and subsequent lengthening after failed HAV surgery. This restriction will prompt plantar angulation of the metatarsal, and this sagittal plane deviation may cause flexion deformity of the hallux, sesamoiditis, or joint jamming, and so a thorough soft tissue and plantar plate release should be pursued prior to distraction osteogenesis. Once the joint has been exposed, fibrous adhesions released the articular surfaces of the metatarsal head, and phalangeal base can be evaluated. If there is evidence of chondral thinning or balding within these surfaces, careful fenestration of the parts can be completed in an attempt to improve perfusion in this region, preparing for the second stage of the procedure—first MTPJ

arthrodesis. Avoid the use of K-wires for fenestration as a solid wire actively packs and compresses bone, which impedes capillary ingrowths. When using a 1.5-mm wire pass drill bit to generously fenestrate these surfaces, the bone will be excavated while creating recesses for neovascularization and capillary ingrowths. The site of nonunion is addressed by first removing any existing fixation devices. Once removed, the margins of the nonunion are delineated exposing the most dorsal and the most plantar aspects of the site. With adequate exposure, the quality of the bone is assessed and any heterotopic calcifications or hypertrophic or sclerotic margins of the nonunion can be removed using manual instrumentation. If the distal fragment of the nonunion is vascular, then it will be incorporated into the procedure. Next, the parts are prepared to create optimal alignment of the metatarsal head and the metatarsal shaft using the pins for a monorail, uniplanar, mini external fixator device. For accurate execution of this technique, it is best to apply and stabilize the fixator to the ray first as this will provide a stable segment for performing the corticotomy.

Application of the mini external fixator begins with manipulation of the foot and ankle to create a neutral position of the foot to the leg while loading the foot on the operating table. Simulated weight-bearing can be achieved by simply flexing the knee and placing the foot on the operating table with the subtalar and midtarsal joints in neutral position. Attention to the alignment of the first ray is critical throughout the balance of the procedure as deviation in the frontal or sagittal plane will result in creating a malunion that may result in pain that

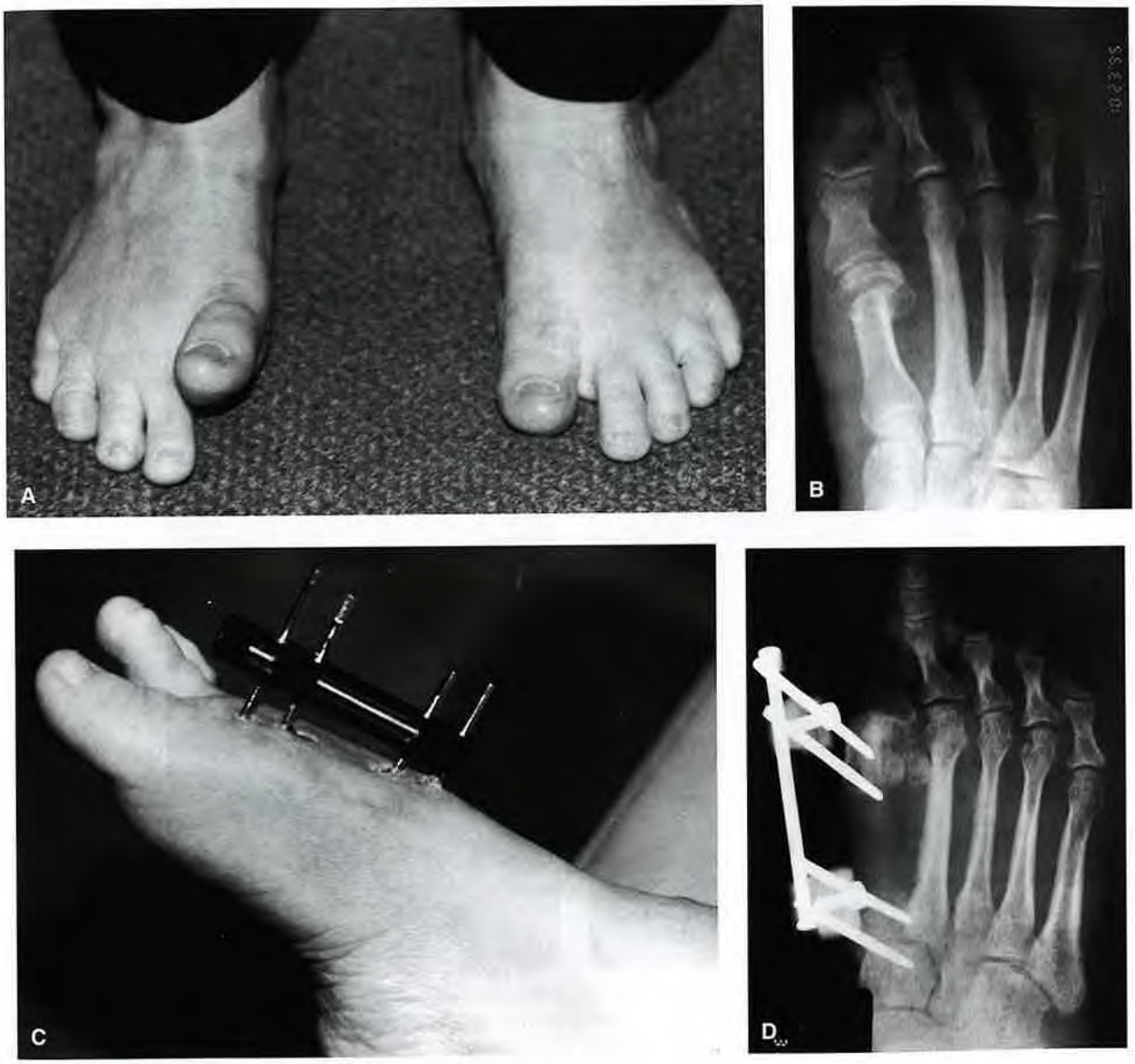

Figure 36.23 **A:** Clinical appearance after surgical procedures of the first ray and both feet. The patient's right foot developed a severe nonunion with a severely dorsiflexed hallux resulting from proximal retraction. **B:** Dorsoplantar radiograph of the same patient. Note the obvious frank nonunion of a previous DMO 1½ years later. **C:** Clinical photograph showing the miniature external fixator that was used for distraction osteogenesis for the first stage of surgery. **D:** Oblique radiograph of same after successful lengthening. Note the early callus formation. *(Continues on next page)*

Figure 36.23 *(Continued)* **E:** Dorsoplantar radiograph of the same patient after removal of the internal fixator. **F:** Dorsoplantar radiograph showing angular deformity of the first metatarsal resulting from weakness of the medial cortex after successful distraction osteogenesis. **G:** Stage II surgery consisting of first MTPJ arthrodesis and stabilization of the first metatarsal using a one-third tubular plate. The deformity of the first metatarsal is readily corrected by simply passing a surgical blade through the soft bone area and applying a plate. Note restoration of length compared with the preoperative radiograph. **H:** Final clinical appearance of the same patient 1½ years postoperatively.

is equal to or worse than the nonunion condition. With the benefit of fluoroscopy, the first ray should be visualized from a dorsal to plantar projection. Purely orthogonal alignment should be established with the tube head at 90 degrees to the first MTPJ and first ray to ensure precise manipulation of the part. The plan for application of the fixator should be established to provide at least two or three points of stability along the metatarsal shaft. It is acceptable and often is necessary to have pins placed within the medial cuneiform, depending on the location of the nonunion, taking care to avoid violation of the MCJ. It has been postulated that lengthening with the pins along the sagittal plane of the long axis of the metatarsal can produce an increased metatarsal declination resulting in untoward rearfoot compensation and a resultant varus deformity. Therefore, placing the fixator pins within the transverse plane of the metatarsal may reduce the incidence of plantar angulation of the distal metatarsal and subsequent compensatory mechanics (148). These pins should be placed through the central aspect of the medial metatarsal shaft and are run purely through the transverse plane creating a parallel arrangement of the wires leaving sufficient length of the pin external to allow for placement of the rail and providing excess room to allow for swelling. They should be spaced generously apart from one another to enhance stability of the construct. It is prudent to run 0.062-inch K-wires and confirming their placement radiographically prior to running the 3-mm half pins for the fixator. Next, the distal portion of the ray can be prepared by spearheading the distal fragment through the transverse plane in a manner identical to when placing an osteotomy axis guide for a V osteotomy. Since there is full exposure of the parts in this open technique, precise application is made easy as opposed to the closed technique in which application may be more challenging. Estimation of the central aspect of the fragment will allow placement of a stab incision in the skin over the medial aspect of the first MTPJ. A fixator pin is first run to spear the distal fragment of the nonunion site and then another to align the distal portion of the metatarsal so that these parts can be manipulated and gently compressed with fixator manipulation. These distal pins should be oriented parallel to the pins within the proximal metatarsal shaft to prevent angular deviation during the dynamic or distraction phase of the procedure. If the pins within the distal segment are placed slightly plantar in the metatarsal head, it will allow a slight plantarflexion as the distraction proceeds (145). An alternate configuration establishes a dorsally placed fixator with pins set within the sagittal plane of the metatarsal bone. Intraoperative radiography should be taken to confirm position and alignment of the parts in three planes to ensure that there is no untoward deviation of the parts.

A corticotomy should be prepared in the proximal metatarsal shaft preferably within the metaphyseal–diaphyseal region of bone. While callus distraction can be performed within purely diaphyseal bone, the vascularity of the metaphysis is optimal from a physiologic standpoint. Metaphyseal bone not only supports the callus distraction by providing a more vascular substrate but is believed to facilitate final consolidation more predictably due to the increased vascularity and porosity of cancellous bone (149–155).

Considering mechanical principles, metaphyseal bone offers a wider segment of bone and therefore a larger surface area for the distraction. The increased cubic content of bone here will tend to be more stable throughout the distraction and ultimately may produce a stronger segment of bone.

There is no need for a periosteal dissection as it is best to preserve the inherent vascularity of this segment. The corticotomy is prepared by fenestrating the site using a 0.062-inch K-wire about the dorsal, medial, and lateral circumference of the metatarsal. The corticotomy should be made at least 1.0 cm distal to the most distal pin within the proximal aspect of the first ray to ensure that the pin rests within solid bone stabilizing this segment for the duration of the distraction. Once the fenestration is complete, the segment can be gently cut superficially along the fenestrations using a small oscillating blade taking care not to completely penetrate the medullary canal. Preparation in this manner is felt to be more physiologic than a through and through transection of bone since it maintains the integrity of the intramedullary substance providing a more vascular substrate for the callus distraction. This simulates a "greenstick"-type fracture in that it does not violate the medullary canal and provides an incontinuity substrate for distraction osteogenesis and ultimately the ossification process. Under real-time fluoroscopy, the site should be distracted to ensure complete mobility between the ends of the corticotomy.

Once satisfied with placement and alignment of the pins and the corticotomy, the wound is irrigated and layered closure is completed. Once the wounds have been closed, the monorail, as seen in Fig. 36.23C, an EBI mini fixator (Electro Biology, Inc., Parsippany, New Jersey), can be applied to the pins and the device can be prepared for the dynamic portion of the procedure.

The *dynamic* portion of stage I occurs at two points in time: during axial compression of both the nonunion site and at the corticotomy as well as during the distraction osteogenesis technique. Once the *dynamic compression* phase is complete, the latency period begins and lasts a variable period of time, anywhere from 4 to 14 days after the corticotomy and compression. The *dynamic distraction* phase is initiated after the latency period and will continue until the desired length is achieved often in increments of 0.5 mm to 1.0 mm/day.

Compression of the distal fragment onto the metatarsal shaft is completed with the benefit of the fixator. The device should be manipulated until there is gentle coaptation and compression across the nonunion site. Taking care to perform this manipulation without causing deviation in the transverse, sagittal, or frontal planes is integral to a successful procedure. Under fluoroscopy axial compression is applied stabilizing the distal free fragment onto the stable more proximal segment. The parts are then compressed to a gentle two-finger tightness, and once stabilized, the remainder of the fixator is rechecked to ensure that each pin is definitively secured to the rail. Once satisfied with the orientation of the distal segment of the construct, the metatarsal head and neck, attention is directed to the proximal metatarsal metaphyseal–diaphyseal junction under fluoroscopy. Now the fixator will be used to compress the site of the corticotomy to initiate the process of bone callus formation. In compressing this proximal segment, great care is taken to avoid excessive compression and undue compaction of the cortical margins. This gentle compression is maintained until the latency period is completed after approximately 10 days and can range from 4 to 14 days depending on the individual's potential for mineralization (149,156–159). There are a number of factors that enter into an individual's propensity for bone mineralization and among them is overall health, tobacco history, associated systemic conditions that may result in generalized osteopenia or osteoporosis such as diabetes or rheumatoid arthritis, age, and the location of the osteotomy. Additionally,

the latency period may be shorter in younger individuals and longer in adults, and this is due to differences in respective rates of bone mineralization. It is wise to avoid a prolonged latency period as premature consolidation can complicate this process, especially in younger individuals.

While there is no well-defined system to determine the rate for distraction osteogenesis, it is suggested that smaller more frequent intervals of lengthening will be tolerated well and with frequent adjustment then will prevent premature mineralization. This concept was discussed by Ilizarov and is believed to provide a more efficient osteogenic process (146,147). Using a mini external fixator, each ¼ turn of the pin produces a ¼-mm of distraction (or compression depending on the direction of the turn). The process of distraction is performed in ¼-turn increments every 6 to 8 h/day as tolerated, and this will provide a very gradual 0.75- to 1-mm distraction per day. The patient is expected to follow this instruction daily until the desired length is achieved. Should the patient experience increased difficulty in turning the device, this may be a sign of premature bone consolidation, and the frequency of the distraction should be increased. Radiographic evidence of bone callus may not manifest until 2 weeks or more has past. When a fracture gap is persistent for a prolonged period of time, it is possible to use the distractor to recompress the part and initiate the distraction once again. Price and Mann suggested that distraction could be slowed or even reversed if poor-quality bone callus or a prolonged fracture gap developed. In this event, recompression at the same rate as the distraction would proceed until the fracture gap is closed. In their work in lengthening the tibia, this compression would be maintained for 1 to 2 weeks before initiating distraction again (150). No literature has been found suggesting a specific time to initiate such recompression when performing this technique in the metatarsal bones.

The total length of distraction is determined using weight-bearing DP and lateral view radiographs. It is generally recommended not to exceed lengthening beyond 40% to 50% of the entire length of the metatarsal (160–162).

When addressing larger defects, it is prudent to perform ancillary procedures such as Z lengthening of the long extensor tendon and pinning of the HIPJ and/or MTPJ to prevent the development of joint subluxation and stiffening (162). It is preferred to create a metatarsal parabola in which the first metatarsal head is commensurate with that of the second depending on the foot type. In instances in which there is significant metatarsus adductus or brachymetatarsia, a modified parabola may be prepared. In these circumstances, it will be necessary to critically evaluate the forefoot axial view to ensure that the final metatarsal parabola has the first and second metatarsals resting at a similar level. The goal is to create similar load-bearing potential between the first and the second metatarsal heads avoiding elevation of the first metatarsal head. While a slightly plantarflexed position of the first metatarsal may be tolerated, elevatus is likely to result in transfer lesions and metatarsalgia.

An forefoot axial view is taken in addition to the DP and lateral views to confirm final position and alignment of the parts. With the mini external fixator along the medial aspect of the first ray, the pin sites can be prepared with antibiotic ointment and a loose sterile gauze dressing can be applied about the pin sites. There are prefabricated sterile foam squares to pad and protect the pin sites. Alternately, sterile gauze squares can be layered and cut to provide protection at the pin sites. Non-weight-bearing immobilization is maintained, and serial radiographs are begun immediately after surgery and are repeated every 1 or 2 weeks thereafter. Close clinical follow-up is advised in these complex cases to identify early evidence of major complication such as pin tract infection, the development of an unusually large fracture gap, subluxation of the MTPJ, dislocation of the metatarsal head, angular deformation, stress fracture of the callus or lesser metatarsal, or failure of fixation devices. Daily first MTPJ passive range of motion should be encouraged and assessed with each clinical follow-up to reduce the incidence of postoperative joint stiffness.

Routine pin care is required until the device is removed. This includes applying antibiotic ointment to the pin sites three times per day while monitoring for early signs of unusual erythema, drainage, or proximal streaking. Timing of the distraction and subsequent consolidation periods are generally a matter of conjecture. It has been suggested that the total time of distraction (by number of days) should be followed by continued non-weight-bearing for that same number of days or more to allow for the ossification and consolidation period to complete, for example, 3 weeks of distraction are followed by 3 weeks of non-weight-bearing immobilization. An alternate suggestion is to maintain the fixator and non-weight-bearing for a 6- to 8-week period in keeping with typical fracture management principles for the first metatarsal bone. In truth, the total duration of external fixation is a combination of radiographic and clinical findings plus a degree of clinical intuition. Once bone consolidation has been confirmed clinically and radiographically, the fixator can be removed with or without anesthesia depending on patient anxiety. Confirming continuity along three bone cortices when viewing radiographs in the DP and lateral views supports radiographic consolidation of the regenerate segment (145,163) (Fig. 36.23E).

It is important to benchmark bone consolidation with serial radiographs while advancing weight-bearing activity for the early identification of stress risers, cortical hypertrophy, or subtle deformation of the new bone segment, all indicators of osseous insufficiency and the need for further off loading of the segment. Beginning protected weight-bearing with the fixator in place is an option that is protective of the new bone segment during the early phases of weight-bearing. A compression stocking and protected weight-bearing should be slowly titrated using a firm-soled shoe as tolerated. In the event that considerable disuse osteopenia is persistent beyond the early protected weight-bearing period, deformation of the newly formed bone segment may occur. Similarly, noncompliance and overaggressive early weight-bearing activity can result in the same (Fig. 36.23F). For this reason, the use of external bone stimulation may be considered as an adjunctive therapy once the callus distraction has been completed. After callus distraction lengthening has been completed, it is typical to complete a period of non-weight-bearing to allow for consolidation of the segment prior to removal of the fixator. This period is variable and may range from 6 to 16 weeks, depending on radiographic evidence of bone consolidation and physician intuition regarding the clinical condition. It is not uncommon to have a fixator in place for 100 days or more (145,163–165).

A healing index of 75 days/cm was reported by Oh in the study of callus distraction of the first metatarsal segment in adults (162). In another study of thirteen first metatarsal distraction osteogenesis, a healing index of 72.4 days/cm and an average of 100 days in the mini fixator was reported (163).

Others have reported healing indexes ranging from 60 to 82 days/cm (161,162,164,166).

Stage II: End-to-End First MTPJ Arthrodesis with Stabilization Plate. The technique of an end-to-end arthrodesis of the first MTPJ has been described earlier in this section. After consolidation of the zone of osteogenesis and distraction, the final procedure of first MTPJ arthrodesis can be completed. The method used to definitively stabilize the site of arthrodesis in conjunction to a newly modeled metatarsal segment is a matter of surgeon preference and experience. Given the degree of osteopenia that may exist in these cases, simple cross K-wire fixation of the first MTPJ can be definitive after curettement of the ball and socket joint. It is prudent in this case to consider rigid internal fixation that provides enhanced stabilization of the proximal ray to prevent the development of angular deformity in this last stage of the procedure. The use of low-profile plates and screws can be considered; however, standard plates and screws continue to be the mainstay in fixation. The postoperative period will require further non-weight-bearing. Some would argue that the index procedure here is the first MTPJ arthrodesis and protected weight-bearing is sufficient to maintain stability of that construct. Due to the fact that the region of distraction osteogenesis is still not mature, there is continued risk for plastic deformation of that segment. Any excessive early weight-bearing may prompt angular deformity and will thwart the surgical outcome. The intraoperative assessment of bone quality along the metatarsal segment contributes to the rationale for the postoperative non-weight-bearing plan. Ultimately, radiographic parameters will determine the duration of non-weight-bearing. The combination of radiographic and clinical assessments will carry the greatest weight in determining when to advance to protected weight-bearing. The ill effects of prolonged non-weight-bearing in the small bones of the foot have been well documented, and so it becomes a fine balance between stressing bone to encourage consolidation and resting the part to allow mineralization with immobilization. Radiographic consolidation at the site of fusion is confirmed by the presence of trabeculations crossing the site. Once confirmed, the patient may be advanced to a compression stocking and a firm-soled shoe for approximately 3 weeks if absolute weight-bearing had been maintained. If the patient was allowed protected weight-bearing prior to consolidation, then the advancement of activities is titrated to patient tolerance. Clinical follow-up will continue with serial radiographs being staggered based upon clinical acumen (Fig. 36.24).

It is prudent to continue to benchmark progress radiographically at defined intervals such as 3, 6, 9, and 12 months after managing such a complex case to ensure the earliest evidence of complications such as stress fracture or the development of angular deformity.

COMPLICATIONS OF FIRST METATARSAL DISTRACTION OSTEOGENESIS

Some case reports discuss first metatarsal lengthening in conjunction with lesser metatarsal procedures performed for congenitally shortened rays, and these cases have a greater risk for complication and resultant transfer lesions or stress fracture (167). When addressing lengthening in patients of osseous immaturity, there is the added inherent risk of disrupting the growth plate and causing more important metatarsal length and/or angular discrepancies (168). In a review of the current literature from 2000 to 2008, only two articles report the use of callus distraction osteogenesis for lengthening the first metatarsal iatrogenically shortened from HAV surgery. In one report, five callus distraction procedures were performed in the first metatarsal bone for five patients without complication (165). The most recent report of procedures performed for iatrogenic shortening of the first metatarsal ultimately touts good success in six patients; however, several complications were discussed such as stress fracture of lesser metatarsals, fracture of new bone segment with return to weight-bearing, displacement of the distal metatarsal requiring open reduction and fixation of the fragment, plantar displacement of the first metatarsal yielding sesamoiditis, delayed evidence of consolidation requiring prolonged non-weight-bearing immobilization (6 months in total), inadvertent trauma fracturing the proximal pins, and spontaneous fusion of the first MTPJ (169). Should plantar subluxations develop, tenotomy may be required to reduce the contracture. When applying this technique to correct deformity residual from failed HAV surgery, soft tissue contractures and fibrosis of the sesamoid apparatus may restrict lengthening and prompt plantar angulation of the metatarsal. This sagittal plane deviation may cause flexion deformity of the hallux, sesamoiditis, or joint jamming, and so a thorough soft tissue release should be pursued prior to distraction osteogenesis.

Speaking from the host of the literature reporting on callus distraction in brachymetatarsia of the lesser metatarsals, the occurrence of pin site infection is perhaps the most common complication. This is typically treated with oral antibiotics such as a first-generation cephalosporin barring no reported allergy to the drug. This complication may be avoided by practicing meticulous pin care during the period of external fixation. Other complications associated with callus distraction are most commonly due to overlengthening and include decreased range of motion and stiffness at the MTPJ and flexion deformity of the digit (170,171).

The incidence of complications using the callus distraction technique has been reported as high as 48% in adults when reviewing procedures of the fourth metatarsal bone (162). It is interesting to note that there are devices that can be used internally to produce callus distraction, and these low-profile devices may reduce the incidence of pin tract infection while avoiding the need for removal (172).

PEARLS/PITFALLS

The corticotomy is prepared by fenestrating the site using a 0.062-inch K-wire about the dorsal, medial, and lateral circumference of the metatarsal. The corticotomy should be at least 1.0 cm distal to the most distal pin within the proximal aspect of the first ray to ensure that the pin rests within solid bone stabilizing this segment throughout the distraction. Once the fenestration is complete, the segment can be gently cut superficially along the fenestrations using a small oscillating blade taking care not to completely penetrate the medullary canal. Preparation in this manner is felt to be more physiologic than a through-and-through transection of bone since it maintains the integrity of the intramedullary substance providing a more vascular substrate for callus distraction. This simulates a

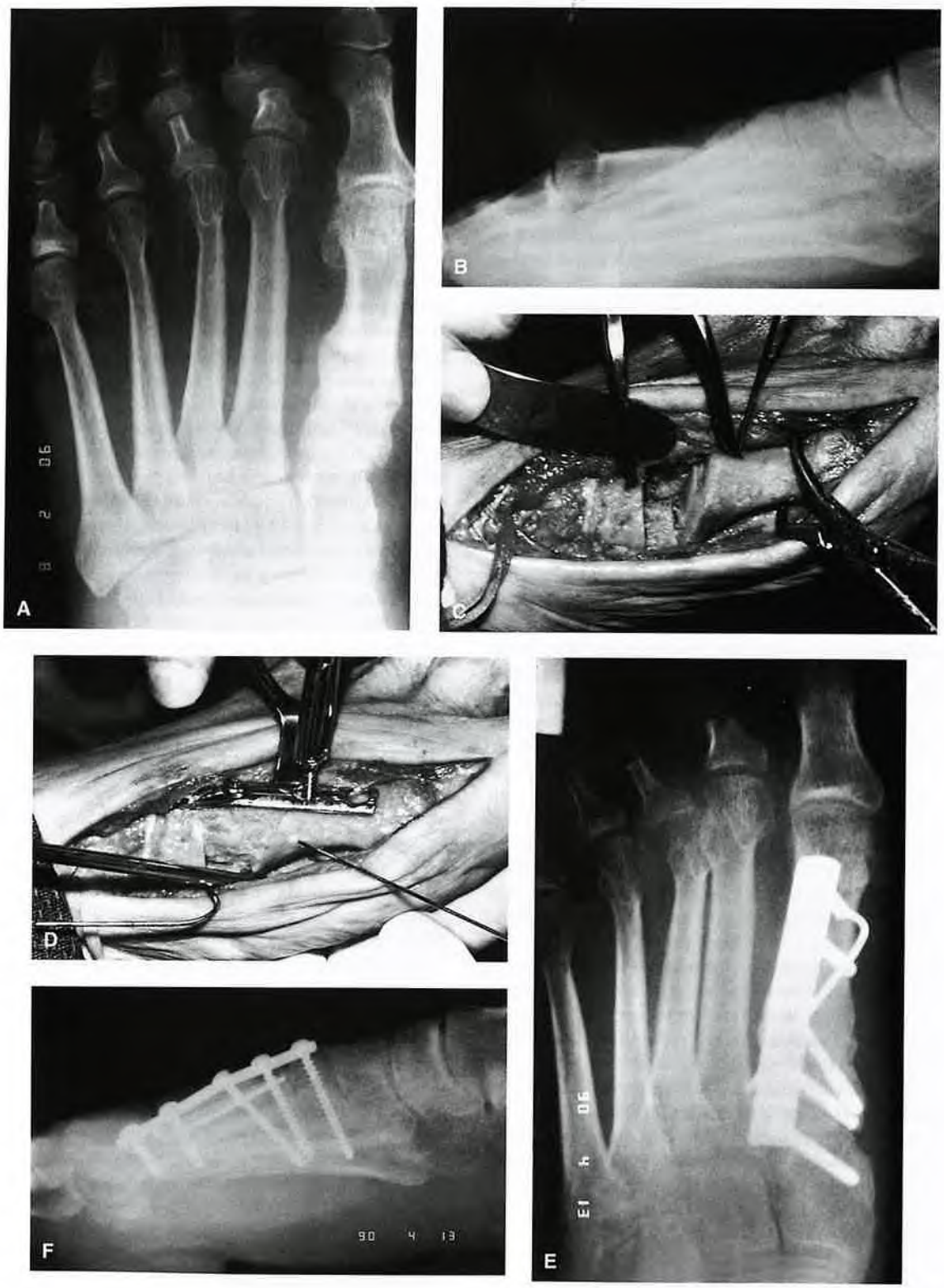

Figure 36.24 **A:** Dorsoplantar radiograph of a patient with nonunion of the first metatarsal osteotomy. Note the callus formation and radiolucency. Significant clinical symptoms were also present. **B:** Lateral radiograph of the same patient. Note the severe metatarsus primus elevatus, as well as the malalignment of the first MTPJ. The distal osteotomy of the first metatarsal healed. **C:** Intraoperative appearance after resection of the nonunion site. Note the presence of sclerotic bone. Aggressive drilling was performed. The plantar cortex was preserved to provide some inherent stability and to serve as a hinge for correction of the sagittal plane malalignment. The laminar spreader is maintaining in plantarflexed position of the first metatarsal before insertion of the bone graft. **D:** Insertion of autogenous tricortical iliac crest graft with fixation by K-wire and one-third tubular plate with multiple screws. Postoperative DP **(E)** and lateral **(F)** radiographs after excellent healing and incorporation of bone graft. Correction of the metatarsus primus elevatus was achieved as well as restoration of length.

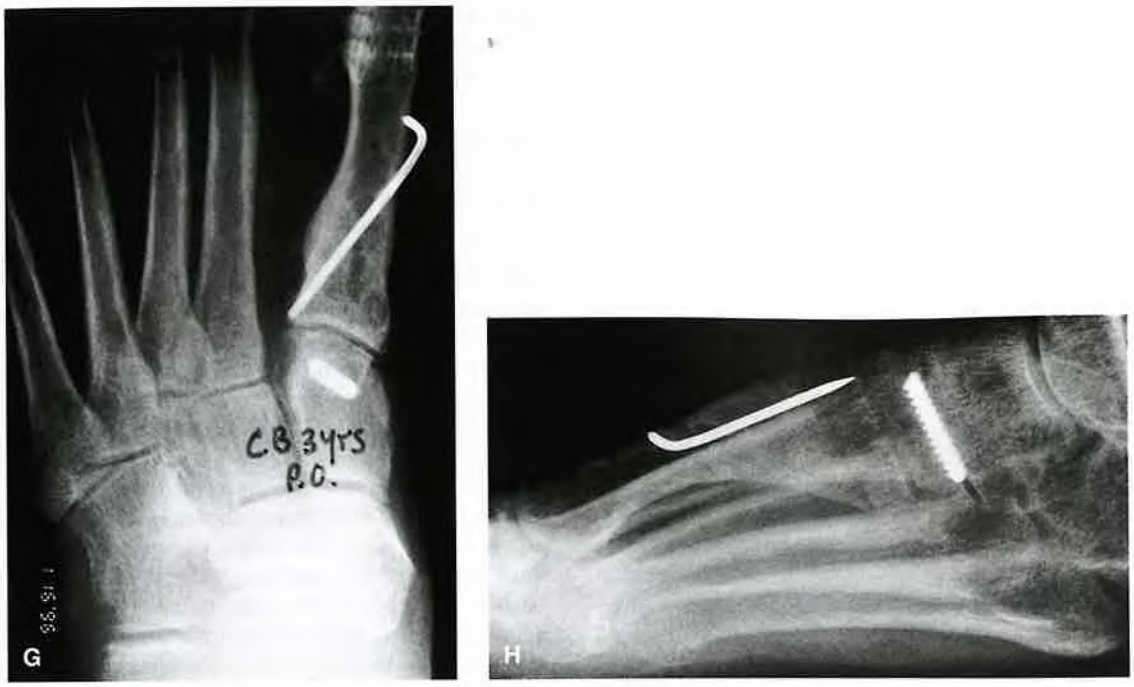

Figure 36.24 *(Continued)* Dorsoplantar **(G)** and lateral **(H)** radiographs 3 years postoperatively. Because of stress across the MCJ, the plate failed and was subsequently removed. The retained portion of the screw within the medial cuneiform remained asymptomatic.

"greenstick"-type fracture in that it does not completely violate the medullary canal and provides an incontinuity substrate for distraction osteogenesis and ultimately the ossification process.

The total length of distraction is determined using weight-bearing DP and lateral view radiographs. It is preferred to create a metatarsal parabola in which the length of the first metatarsal is commensurate with that of the second depending on the foot type. In instances in which there is significant metatarsus adductus or brachymetatarsia of the second metatarsal, a modified parabola may be prepared. In these circumstances, it will be necessary to critically evaluate plain radiographs including the forefoot axial view to ensure that the final metatarsal parabola has the first and second metatarsals resting at a similar level. The goal is to create similar load-bearing potential between the first and the second metatarsal heads. While a slightly plantarflexed position of the first metatarsal may be tolerated, elevatus is likely to result in transfer lesions and metatarsalgia. Generally, it has been suggested to limit the total lengthening to 40% (164,166) or 50% (160–162) as overlengthening will increase the risk of MTPJ subluxation, joint stiffness, plantar deviation of the metatarsal, angular deformity of the new bone segment, and clawing of the hallux.

It has been postulated that first metatarsal lengthening with the pins aligned in the center of the sagittal plane of the metatarsal can produce an increased first metatarsal declination. A rigidly plantarflexed first ray is known to produce rearfoot compensation and a resultant varus deformity. Dorsal soft tissue contractures from previous surgery, contracture of the EDL tendon, and distraction greater than 40% to 50% of the length of the metatarsal are likely contributory factors that would aggravate and increase the metatarsal declination. With that in mind, placing the fixator pins within the transverse plane of the metatarsal may reduce the incidence of plantar angulation of the distal metatarsal and avoid compensatory mechanics (148). These pins should be placed through the central aspect of the medial metatarsal shaft and are run purely through the transverse plane creating a parallel arrangement of the wires leaving sufficient length of the pin external to allow for placement of the rail and providing excess room to allow for swelling. They should be spaced generously apart from one another to enhance stability of the construct. It is prudent to run 0.062-inch K-wires and confirming their placement radiographically prior to running the 3-mm half pins for the fixator.

In callus distraction osteogenesis, the need for a latency period prior to distraction is understood. The duration of that period is subjective and typically ranges from 4 to 14 days for foot and ankle procedures. When the corticotomy/osteotomy is within metaphyseal bone, distraction can begin in 7 to 10 days, whereas a latency of 2 weeks is suggested for the procedure in diaphyseal bone. Although there is no strict consensus on the duration of the latency period, there are a number of factors that enter into an individual's propensity for bone mineralization and among them is overall health, tobacco history, systemic conditions associated with generalized osteopenia or osteoporosis such as diabetes or rheumatoid arthritis, age, and the location of the osteotomy (149,156–159).

Additionally, the latency period may be shorter in younger individuals (10 days) given that their periosteum is thicker, and prompt revascularization allows for earlier callus distraction. In adults, revascularization may be slower, and so a longer latency is required (14 to 21 days). Longer latency periods are suggested for osteotomies within dense cortical bone and when lengthening after correction of angular deformity or

significant displacement (156,173,174). These latencies are further supported due to respective differences in bone mineralization rates.

It is generally suggested to avoid prolonged latency periods as premature consolidation can complicate this process, especially in younger individuals.

Radiographic evidence of callus formation should be evident anywhere from 2 to 5 weeks after initiation of lengthening. When a fracture gap is persistent for a prolonged period of time, it is possible to use the distractor to recompress the part and initiate the distraction once again. Price and Mann suggested that distraction could be slowed or even reversed if poor-quality bone callus or a prolonged fracture gap developed. In this event, recompression at the same rate as the distraction would proceed until the fracture gap is closed. In their work in lengthening the tibia, this compression would be maintained for 1 to 2 weeks before initiating distraction again (150). No literature has been found suggesting specific time to initiate such recompression when performing this technique in the metatarsal bones.

After callus distraction lengthening has been completed, it is typical to complete a period of non-weight-bearing to allow for consolidation of the segment prior to removal of the fixator. This period is variable and may range from 6 to 16 weeks depending on radiographic evidence of bone consolidation and physician intuition regarding the clinical condition. It is not uncommon to leave the fixator in place for 100 days or more (145,148,163–165). In the two-stage procedure of distraction osteogenesis and first MTPJ arthrodesis, further non-weight-bearing will be required once definitive fixation of the first MTPJ fusion and stabilization of the new bone segment has been completed. In this case, it is shortsighted to prepare the internal fixation plan strictly for the index procedure, the end-to-end first MTPJ arthrodesis. Given the fact that the new bone segment requires a prolonged period of time to mature and that time is variable with each patient, it must be stabilized throughout the attempted first MTPJ and non-weight-bearing is required to facilitate primary bone healing while the arthrodesis site is consolidating. Due to the fact that the region of distraction osteogenesis has not yet matured, there is continued risk for plastic deformation of that segment. Any excessive early weight-bearing may prompt angular deformity thwarting the surgical outcome. The intraoperative assessment of the regenerate bone quality is an important factor in determining the duration of the non-weight-bearing plan. Ultimately, radiographic parameters will determine the duration of non-weight-bearing, and anywhere from 6 to 10 weeks of non-weight-bearing would be typical depending on bone quality. The combination of radiographic and clinical assessments will carry the greatest weight in determining when to advance to protected weight-bearing. The ill effects of prolonged non-weight-bearing in the small bones of the foot have been well documented, and so it becomes a fine balance between stressing bone to encourage consolidation and resting the part to allow mineralization with immobilization. Radiographic consolidation at the site of fusion is confirmed by the presence of trabeculations crossing the site. Once confirmed, the patient may be advanced into a compression stocking and a firm-soled shoe for approximately 3 weeks of protected weight-bearing. Thereafter, advancement of activities is titrated to patient tolerance. Clinical follow-up will continue with serial radiographs being staggered based upon clinical acumen. It is prudent to benchmark progress radiographically at defined intervals such as 3, 6, 9, and 12 months after managing such a complex case to ensure the earliest evidence of late complications such as the development of stress fractures or the development of angular deformity.

RESECTION OF PROXIMAL METATARSAL NONUNION WITH REVISION OF INTERNAL FIXATION (WITH OR WITHOUT BONE GRAFT)

Application of multiple layers of elasticized cast padding is applied beneath a calf tourniquet to provide hemostasis if desired. Dissection to gently prepare the deep fascia and maintain optimal perfusion to the first ray is completed. Next, the level of the nonunion is identified and isolated in preparation for the deep fascial incision. The incision begins at the base of the first metatarsal and extends distally across the MTPJ. The site of nonunion is addressed by first removing any existing fixation devices. Once removed, the margins of the nonunion are delineated exposing the most dorsal and most plantar aspects of the site. With adequate exposure, the quality of the bone is assessed and the margins of the nonunion are circumscribed with manual instrumentation. Often, the parts can be gently separated with manual instrumentation such as a freer elevator or a small osteotome. In attempting to separate the parts, care is taken not to "bottle cap" the segment as this may result in fracture. When the segment is resistant, power instrumentation is used to incise the nonunion. Irrigation of both segments of the nonunion is completed, and the free ends of bone are inspected. Any evidence of sclerotic change or fibrotic ingrowths should be removed at this time. After débridement, the bone deficit is inspected and the need for an intercalary bone graft versus an autogenous reverse on lay graft is determined. When there is a well-localized segment of sclerotic bone at the site, consideration for a reverse onlay graft can be entertained. When there is a large volume of sclerotic bone at the site of nonunion, the onlay technique may not provide an adequate volume of healthy bone, and in this event, an en bloc resection repaired with an intercalary graft is preferred.

Resection of sclerotic or otherwise degenerative bone is performed using a sagittal saw under continuous irrigation. Supplementation of the medullary segments with cancellous bone chips should be completed if necessary. Once satisfied that the free segments of bone are healthy appearing, the size of the intercalary graft can be determined. With the distal metatarsal segment placed into neutral alignment with the hallux, the deficit in metatarsal length can be estimated and the appropriate size and shape of the graft can be measured. The length of the first ray can be compared to that of the contralateral limb via plain radiographs for best assessment. It is important to remember that the graft should be prepared slightly larger than the defect to begin this process as there is usually further sculpting required to achieve a press fit for the graft. Autogenous graft is preferred in revision of a nonunion segment, and the author prefers the benefit of a tricortical iliac crest graft for this purpose. In resecting the nonunion residual from an oblique base wedge osteotomy, a rhomboid-shaped defect may result (Fig. 36.24C). The bone defect should be measured in height, length, and width, and the dimensions should be drawn to serve as a blueprint when the defect is sufficiently large. From a technical standpoint, the goal is to fashion an anatomic match for the site and to create a press fit for that site. It is best to begin with a graft that is slightly large in length and to then plane the bone under continuous saline irrigation

to preserve healthy bone quality while trimming the graft. With the graft in place, the construct can be compressed in an axial direction by manually loading the distal metatarsal. With the segment compressed against the graft, temporary fixation may be applied using a 0.062-inch K-wire. After provisional fixation is established, the first MTPJ range of motion should be assessed to ensure that smooth and unrestricted motion is available in this corrected position. A standard 1/3 tubular plate with 2.7- or 3.5-mm screws are then applied depending on the size of the bone. These devices are applied using strict AO technique to stabilize the construct. A modification of this technique is to first prebend and apply the plate to the graft using a single screw. Once secured, the entire plate-graft unit can be placed within the defect. When securing the plate to the metatarsal, the holes just proximal and distal to the graft are eccentrically drilled to create compression upon the graft (Fig. 36.24D). The rest of the screws are applied centrally within the plate for neutralization, and finally, all screws are tightened to two-finger tightness. Final intraoperative radiographs should be obtained to confirm appropriate position and alignment of the first ray and internal fixation devices. Final exploration of the first MTPJ and range of motion is performed to ensure proper function in this corrected position prior to closure. If there are regions of chondral lifting or deep chondral defects, débridement should be completed. Regions of worn and unusually thin or degenerative cartilage can be fenestrated. Avoid the use of K-wires for fenestration as a solid wire packs and compresses bone, which impedes capillary ingrowths. Using a 1.5-mm wire pass drill bit, the bone will be excavated while creating recesses for neovascularization and capillary ingrowths. Copious irrigation is then completed followed by a layered closure taking care to generously cover fixation devices to reduce superficial irritation. With the foot and ankle in neutral position, a modified Jones compression dressing is applied using multiple layers of elasticized cast padding alternating with 6-inch elastic wrap compression. A cryotherapy bladder is employed after the first layer and a three-layer dressing is prepared.

The postoperative course includes absolute non-weight-bearing until there is radiographic evidence of bone consolidation. Typically, 8 to 12 weeks may be required. Once bone consolidation has been confirmed along three cortices of the metatarsal in multiple radiographic views, protected weight-bearing can begin with the benefit of a CAM walker. A compression stocking is applied as soon as the layered dressing is discontinued, typically once sutures are removed. Passive range of motion of the first MTPJ should begin as soon as tolerated after the procedure to prevent stiffness and loss of motion. This passive motion should be painless, and this is generally reassuring to the patient. Titration into a firm-soled shoe surgical shoe is completed as tolerated. Serial radiographs are obtained every 2 to 4 weeks, and once full-weight-bearing has been tolerated well, the frequency of radiographs can be reduced. It is prudent to follow these complex cases monthly until the patients have returned to their usual shoe gear and are tolerating full-weight-bearing activity well. Thereafter the patient can be reassessed quarterly until functional goals and subjective satisfaction have been achieved.

Pearls/Pitfalls

After débridement, the bone deficit is inspected and the need for an intercalary bone graft versus an autogenous reverse onlay graft is determined. When there is a well-localized segment of sclerotic bone at the site, consideration for a reverse onlay graft can be entertained. When there is a large volume of sclerotic bone at the site of nonunion, the onlay technique may not provide an adequate volume of healthy bone, and in this event, an en bloc resection repaired with an intercalary graft is required.

The reverse onlay graft technique has been described for use in long bones with good success. There is a learning curve to using this technique. The graft can be prepared in a customized fashion depending on the nature and location of the nonunion. The reverse onlay graft is prepared by cutting a rectangle of bone through the site of nonunion that extends approximately 50% deep into the largest girth of the nonunion site. Once excised, this rectangular segment is then rotated 180 degrees to bring healthy autogenous bone into the site of nonunion repair and shifts the sclerotic zone out into the healthy distal bone segment. This provides all of the benefits of autogenous bone morphogenic protein to the nonunion and provides a near-perfect match of bone quality to the site of repair. This reverse onlay can be stabilized using standard devices or low-profile plate and screws. When excising a long segment of bone, it is beneficial to bevel the cuts along the long axis of the segment as this will allow a very snug press fit after reversing the autogenous graft segment. This rectangular segment can be taken from the dorsal or medial aspect of the metatarsal base depending on the location and depth of the nonunion. It is important to resect this segment sufficiently deep but not greater than 50% into the widest girth of the bone to ensure a stout segment of bone to secure and stabilize the graft. Once adequate fixation is applied, radiographs are taken to confirm position and alignment of the autograft and fixation devices.

ACKNOWLEDGMENTS

Special thanks to the Medical Library Staff at St. Vincent Mercy Medical Center in Toledo, Ohio, for their exhaustive work with literature searches and acquisition of publications to complete this project.

REFERENCES

1. Meier PJ, Kenzora JE. The risks and benefits of distal first metatarsal osteotomies. *Foot Ankle* 1985;6(1):7–17.
2. Lagaay PM, Hamilton GA, Ford LA, et al. Rates of revision surgery using Chevron-Austin osteotomy, Lapidus arthrodesis and closing base wedge osteotomy for correction of hallux valgus deformity. *J Foot Ankle Surg* 2008;47:267–272.
3. Coughlin MJ, Mann RA, Saltzman CL. Adult hallux valgus. In: Coughlin MJ, Mann RA, Saltzman CL, eds. *Surgery of the foot and ankle*, vol 1, 8th ed. St. Louis, MO: CV Mosby, 2007.
4. Thordarson DB, Schmotzer H, Chon J, et al. Dynamic support of the human longitudinal arch: a biomechanical evaluation. *Clin Orthop* 1995;316:165–172.
5. Bohne WHO, Lee KT, Peterson MGE. Action of the peroneus longus tendon on the first metatarsal against metatarsus primus varus force. *Foot Ankle* 1997;18:510–512.
6. Yu GV, Schinirring-Judge MA, Shook JE. Complications of hallux abducto valgus surgery. In: Banks AS, Downey M, Martin DE, et al, eds. *McGlamry's comprehensive textbook of foot and ankle surgery*, 3rd ed, vol 1. Philadelphia, PA: Lippincott Williams & Wilkins, 2001:655–677.
7. Lapidus PW. Operative correction of metatarsus varus primus in hallux valgus. *J Surg Gynecol Obstet* 1930;58:183–191.
8. Catanzariti AR, Edwin L. Blitch IV. Metatarsal cuneiform procedures. In: Banks AS, Downey M, Martin DE, eds. *Chapter 16 part 2: metatarsal cuneiform procedures in the comprehensive textbook of foot surgery*, 3rd ed., Baltimore, MD: Williams and Wilkins, 2001.
9. Catanzariti AR. First metatarsocuneiform joint arthrodesis. In: Marcinko DE, ed. *Comprehensive textbook of hallux abducto valgus reconstruction*. St. Louis, MO: Mosby-Yearbook, 1992.
10. Roling BA, Christensen JC, Johnson CH. Biomechanics of the first ray. Part IV. The effect of selected medial column arthrodeses: a three-dimensional kinematic analysis in a Cadaver Model. *J Foot Ankle Surg* 2002;41(5):278–285.

11. Hirsch BE. Structural biomechanics of the foot. *J Am Podiatr Med Assoc* 1991;81:338–343.
12. Fritz GR, Prieskorn D. First metatarsocuneiform motion: a radiographic and statistical analysis. *Foot Ankle Int* 1995;16:117–123.
13. Phillips RD, Law EA, Ward ED. Functional motion of the medial column joints of the foot during propulsion. *J Am Podiatr Med Assoc* 1996;86:474–486.
14. Ouzounian TJ, Shereeff MJ. In vitro determination of mid foot motion. *Foot Ankle* 1989;10:140–146.
15. Camasta CA. Radiographic evaluation and classification of metatarsus primus elevatus. In: *The Podiatry Institute update '94*. Tucker, GA: The Podiatry Institute, 1994:122–127.
16. Davies GF. Plantarflexory base wedge osteotomy in the treatment of functional and structural metatarsus primus elevates. *Clin Podiatr Med Surg* 1989;6:93–102.
17. Martin DE, Pontius J. Introduction and evaluation of hallux abducto valgus. In: Banks AS, Downey M, Martin DE, eds. *Introduction and evaluation of hallux abducto valgus in the comprehensive textbook of foot surgery*, 3rd ed. Baltimore, MD: Williams and Wilkins, 2001:486–487.
18. Yamamoto H, Zheng KC, Arilizumi M. A study of the hand-arm vibration syndrome in Okinawa, a subtropical area of Japan. *Ind Health* 2002;40:59–62.
19. Takahashi S, Iwamoto M, Yoshimura Laskar MS, et al. *Int Arch Occup Environ Health* 2003;76: 249–252.
20. Laskar Md S, Harada N. Different condition of cold water immersion Test for diagnosing hand—arm vibration syndrome. *Environ Health Prevent Med* 2005;10:351–359.
21. Judge MS, LaPointe S, Yu GV, et al. Hallux valgus surgery and the effect of the sesamoid apparatus in HAV surgery. *J Am Podiatr Med Assoc* 1999;89(11/12):551–559.
22. Boberg JS, Judge MS. Follow-up of the isolated medial approach to hallux abducto valgus correction without interspace release. *J Am Podiatr Med Assoc* 2002;92(10):555–562.
23. Chang TJ. Distal metaphyseal osteotomies in hallux abducto valgus surgery. In: Banks AS, Downey MS, Martin DE, et al, eds. *McGlamry's comprehensive textbook of foot and ankle surgery*, 3rd ed, vol 1. Philadelphia, PA: Lippincott Williams & Wilkins, 2001:506–507.
24. Sarrafian SK. *Anatomy of the foot and ankle, descriptive, tomographic, functional*. 2nd ed. Philadelphia, PA: J.B. Lippincott Company, 1993:207–217.
25. Coughlin MJ, Mann RA, Saltzman CL, eds. *Surgery of the foot and ankle*, 8th ed., vol I, Part II Fore foot. Philadelphia, PA: Mosby, 1993:340.
26. Resch S, et al. Chevron osteotomy for hallux valgus not improved by additional adductor tenotomy; a prospective randomized study of 84 patients. *Acta Orthop Scand* 1994;65:541.
27. Akin OF. The treatment of hallux valgus: a new operative procedure and its results. *Med Sentinel* 1925;33:678–679.
28. Boberg J. Surgical procedures of the hallux. In: McGlamry ED, Banks AS, Downey M, eds. *The comprehensive textbook of foot and ankle surgery*, 2nd ed, vol 1. Philadelphia, PA: JB Lippincott, 1992:533–534.
29. McDonald KC, Drake R, Durrant MN et al. Retrospective analysis of the Akin-Austin bunionectomies on patients over fifty years of age. *J Foot Surg* 1988;6:545–555.
30. Plattner PF, VanManen JW. Etiology and treatment of hallux valgus: results of Akin type proximal phalangeal osteotomy for the correction of hallux abducto valgus deformity. *Orthopedics* 1990;13:989–996.
31. Goldberg I, Bahar A, Yosipovitch Z. Late results after correction of hallux abducto valgus deformity by basilar phalangeal osteotomy. *J Bone Joint Surg Am* 1987; 69:64–67.
32. Springer KR. The role of the Akin osteotomy in the surgical management of hallux abducto valgus. *Clin Podiatr Med Surg* 1989;6:115–130.
33. Rochwerger A, Curvale G et al. Application of bone graft to the medial side of the metatarsal head in treatment of hallux varus. *J Bone Joint Surg Am* 1999;81;1730–1735.
34. Rosenblum BI, Giurini JM, Chrzan JS, et al. Preventing loss of the great toe with the hallux interphalangeal joint arthroplasty. *J Foot and Ankle Surg* 1994;33(6):557–560.
35. McGlamry ED, Kitting RW, Butlin WE. Keller bunionectomy and hallux valgus correction: further modifications. *J Am Podiatr Med Assoc* 1973; 63:237–246.
36. McGlamry ED. Arthroplasty technique for repair of the first metatarsophalangeal joint. *J Am Podiatr Med Assoc* 1974;64:611–616.
37. Ruch JA, Banks AS. Base wedge osteotomies of the first metatarsal. In: McGlamry ED, Banks AS, Downey M, eds. *The comprehensive textbook of foot and ankle surgery*, 2nd ed, vol 1. Philadelphia, PA: JB Lippincott, 1992:504–522.
38. Selner AJ, Selner MD, Cyr RP, et al. Revisional hallux abducto valgus surgery using tricorrectional bunionectomy. *J Am Podiatr Med Assoc* 2004;94(4):341–346.
39. Flavin R, Stephens MM. Arthrodesis of the first metatarsophalangeal joint using a dorsal titanium contoured plate. *Foot Ankle Int* 2004:25(11):783–787.
40. Calderone DR, Wertheimer SJ. First metatarsophalangeal joint arthrodesis using a mini-Hoffman external fixator. *J Foot Ankle Surg* 1993;32:517–525.
41. Shim GS, Pikscher I, Frankel N. First metatarsophalangeal joint arthrodesis with a truncated cone reamer system. *J Foot Surg* 1992;31:342–349.
42. Bouche RT, Adad JR. Arthrodesis of the first metatarsophalangeal joint in active people. *Clin Podiatr Med Surg* 1996;13:461–484.
43. Yu GV, Shook JE. Arthrodesis of the first metatarsophalangeal joint: current recommendations. *J Am Podiatr Med Assoc* 1994;84:266–280.
44. Chana GS, Andrew TA, Cotteril CP. A simple method of arthrodesis of the first metatarsophalangeal joint. *J Bone Joint Surg Br* 1984;66:703–705.
45. Coughlin MJ. Arthrodesis of the first metatarsophalangeal joint with mini fragment plate fixation. *Orthopedics* 1990:13:1037–1044.
46. Holmes GB Jr. Arthrodesis of the first metatarsophalangeal joint using inter fragmentary screw and plate. *Foot Ankle* 1992;13:333–335.
47. Marin GA. Arthrodesis of the first metatarsophalangeal joint of the big toe for hallux valgus and hallux rigidus; a new method. *Int Surg* 1968;50:175–180.
48. Phillips J, Hooper G. A simple technique for arthrodesis of the first metatarsophalangeal joint. *J Bone Joint Surg Br* 1986;68:774–775.
49. Smith RW, Joanis TL, Maxwell PD. Great toe metatarsophalangeal joint arthrodesis: a user friendly technique. *Foot Ankle* 1992;13:367–377.
50. Turan I, Lindgren U. Compression screw arthrodesis of the first metatarsophalangeal joint of the foot. *Clin Orthop* 1987;221:292–295.
51. Wilson JN. Cone arthrodesis of the first metatarsophalangeal joint. *J Bone Joint Surg Br* 1967;49:98–101.
52. Wilson CL. A method of fusion of the metatarsophalangeal joint of the great toe. *J Bone Joint Surg Am* 1958;40:384–385.
53. Wu KK. Arthrodesis of the first metatarsophalangeal joint of the great toe with Herbert screws: a clinical analysis of 27 cases. *J Foot Ankle Surg* 1993;32:47–52.
54. Kupcha PC, Fitzpatrick MJ. Application of the tension band technique for arthrodesis of the fore foot and mid foot. *Foot Ankle Int* 1996;17:784.
55. DeOrio JK, Farber DC. Morbidity associated with anterior iliac crest bone grafting in foot and ankle surgery. *Foot Ankle Int* 2005;26(2):147–151.
56. Jacobs AM, Klein S, Oloff L, et al. Radionuclide evaluation of complications after metatarsal osteotomy and implant arthroplasty of the foot. *J Foot Surg* 1984:23:86–96.
57. McGarvey WC, Braly WG. Bone graft in hindfoot arthrodesis: allograft versus autograft. *Orthopedics* 1996;19(5):389–394.
58. Brodsky JW, Ptaszek AJ, Morris SC. Salvage first MTP arthrodesis utilizing ICBG: clinical evaluation and outcome. *Foot Ankle Int* 2000;21(4): 290–296.
59. Myerson MS, Schon LC, McGuigan FX, et al. Result of arthrodesis of the hallux metatarsophalangeal joint using bone graft for restoration of length. *Foot Ankle Int* 2000;21(4):297–306.
60. Mahan KT, Hillstrom HJ. Bone grafting in foot and ankle surgery. A review of 300 cases. *J Am Podiatr Med Assoc* 1998;88(3):109–118.
61. Pietrzak WS, Perins SV, Keyes J, et al. Demineralized bone matrix graft: a scientific and clinical case study assessment. *J Foot Ankle Surg* 2005;44(5):345–353.
62. Chou LB, Halligan BW. Treatment of severe, painful pes planovalgus deformity with hind foot arthrodesis and wedge-shaped tricortical allograft. *Foot Ankle Int* 2007;28(5): 569–574.
63. Rosenfeld PF, Budgen SA, Saxby TS. Triple arthrodesis: is bone grafting necessary? The results in 100 consecutive cases. *J Bone and Joint Surg Br* 2005;87(2):175–178.
64. Yu GV, Schnirring-Judge M, Shook JE. Complications of hallux abducto valgus surgery. In: Banks AS, Downey MS, Martin DE, et al, eds. *McGlamry's comprehensive textbook of foot and ankle surgery*, 3rd ed, vol 1. Philadelphia, PA: Lippincott Williams & Wilkins, 2001:655–677.
65. Sussman RE, et al. Arthrodesis of the first metatarsophalangeal joint. *J Am Podiatr Med Assoc* 1986;76:631–635.
66. Sussman RE, D'Amico JC. The influence of the height of the heel on the fist metatarsophalangeal joint. *J Am Podiatry Assoc* 1984;74;504.
67. Harrison MHM, Harvey FJ. Arthrodesis of the first metatarsophalangeal joint for hallux valgus and rigidus. *J Bone Joint Surg Am* 1963;45:471–480.
68. Moynihan F. Arthrodesis of the first metatarsophalangeal joint of the great toe. *J Bone Joint Surg Br* 1967;49:544–551.
69. Marin GA. Arthrodesis of the first metatarsophalangeal joint of the hallux for hallux valgus and hallux rigidus: a new method. *Int Surg* 1968;50:175–180.
70. Fitzgerald JAW. A review of results of arthrodesis of the first metatarsophalangeal joint *J Bone Joint Surg Br* 1969;51:488–493.
71. Raymakers R, Waugh W. The treatment of metatarsalgia with hallux valgus. *J Bone Joint Surg Br* 1971;53:684.
72. Wilkinson J. Cone arthrodesis of the first metatarsophalangeal joint. *Acta Orthop Scand* 1978:49,267.
73. McKeever D. Arthrodesis of the fist metatarsophalangeal joint for hallux valgus, hallux rigidus and metatarsus primus varus. *J Bone Joint Surg Am* 1952;34:129–134.
74. Humbert JL, Bourbonniere C, Laurin CA. Metatarsophalangeal joint fusion for hallux valgus: indications and effect on the first metatarsal ray. *Can Med Assoc J* 1979;120:937–941.
75. Von Salis-Soglio G, Thoners W. Arthrodesis of the first metatarsophalangeal joint of the great toe. *Arch OrthopTrauma Surg* 1979;95:7.
76. Mann RA, Oates JC. Arthrodesis of the first metatarsophalangeal joint. *Foot Ankle* 1980:1;159–166.
77. Riggs SA, Johnson EW, McKeever arthrodesis for the painful hallux. *Foot Ankle* 1983:3;248–253.
78. Johannson JE, Barrington TW. Cone arthrodesis of the first metatarsophalangeal joint. *Foot Ankle* 1984:4:244–248.
79. Beauchamp CG, Kirby T, Rudge SR, et al. Fusion of the first metatarsophalangeal joint in fore foot arthroplasty. *Clin Orthop* 1984:190;249–253.
80. Mann RA, Thompson FM. Arthrodesis of the first metatarsophalangeal joint for hallux valgus in rheumatoid arthritis. *J Bone Joint Surg Am* 1984;66:687–692.
81. Sussman RE, Russo CL, Marquit H, et al. Arthrodesis of the first metatarsophalangeal joint. *J Am Podiatr Med Assoc* 1986;76;631–635.
82. Coughlin MJ, Mann RA. Arthrodesis of the first metatarsophalangeal joint as a salvage for the failed Keller procedure. *J Bone Joint Surg Am* 1987;69:68–74.
83. Mann RA, Katcherian DA. Relationship of metatarsophalangeal joint fusion on the intermetatarsal angle. *Foot Ankle* 1989;10:8–11.
84. Gregory JL, Childers R, Higgins KR, et al. Arthrodesis of the first metatarsophalangeal joint: a review of the literature and long term retrospective analysis. *J Foot Surg* 1990;29:369–374.
85. O'Doherty DP, Lowrey LG, Magnussen PA, et al. The management of the painful first metatarsophalangeal joint in the older patient. *J Bone Joint Surg Br* 1990;72:839.
86. Lampe HIH, Fonteije P, van Linje B. Weight bearing after arthrodesis of the first metatarsophalangeal joint: a randomized study of 61 cases. *Acta Orthop Scand* 1991;62:544–545.
87. Hughes J, Grace D, Clark P, et al. Metatatarsal head excision for rheumatoid arthritis: 4-year follow up of 68 feet with and without hallux fusion. *Acta Orthop Scand* 1991;62:63.
88. Niskanen RO, Lehtimaki MY, Hamalainen MM, et al. Arthrodesis of the first metatarsophalangeal joint in rheumatoid arthritis. *Acta Orthop Scand* 1993;64:100–102.
89. Wu KK. First metatarsophalangeal joint fusion in the salvage of failed hallux abducto valgus operations. *J Foot Ankle Surg* 1994;33:383–395.
90. Hecht PJ, Gibbons MJ, Wapner KL, et al. Arthrodesis of the first metatarsophalangeal joint to salvage failed silicone implant arthroplasty. *Foot Ankle Int* 1997;18:383–390.
91. Humbert JL, Bourbonniere C, Laurin CA. Metatarsophalangeal fusion for hallux valgus: indications and effect on the first metatarsal ray. *Can Med Assoc J* 1979;120:937–956.

92. Tupman GS. Bone peg arthrodesis of the first metatarso-phalangeal joint. *Postgrad Med J* 1959;35:583–586.
93. Wilkinson J. Cone arthrodesis of the first metatarsophalangeal joint. *Acta Orthop Scand* 1978;49:627–630.
94. Raikin SM, Brislin K. Local bone graft harvested from the distal tibia or calcaneus for surgery of the foot and ankle. *Foot Ankle Int* 2005;26(6):449–453.
95. Brown CH. A technique for distal tibial bone graft for arthrodesis of the foot and ankle. *Foot Ankle Int* 2000;21(9):780–781.
96. Weinraub GM, Cheung C. Efficacy of allogenic bone implants in a series of consecutive elective foot procedures. *J Foot Ankle Surg* 2003;42(2):86–89.
97. Myerson MS, Neufeld SK, Uribe J. Fresh-frozen structural allografts in the foot and ankle. *J Bone Joint Surg Am* 2005;87(1):113–120.
98. Catanzariti A, Karlock L. Application of allograft bone in foot and ankle surgery *J Foot Ankle Surg* 1996;35:440–451.
99. Mahan KT. Bone graft reconstruction of a flail digit. *J Am Podiatr Med Assoc* 1992; 82(5):264–268.
100. Mann RA. Calcaneal donor bone grafts. *J Am Podiatr Med Assoc* 1994;84:1–9.
101. Philip AJ. Bone grafts: autogenous vs. allogenic/cortical vs. cancellous. In: Dinapoli DR, ed. *Reconstructive surgery of the foot and leg: update 1990.* Tucker, GA: The Podiatry Institute, 1990:120–123.
102. Mahan KT. Bone grafts materials and perioperative management. In: Camasta CA, ed. *Reconstructive surgery of the foot and leg: update 1995.* Tucker, GA: The Podiatry Institute, 1995:69–75.
103. Mahan KT, Downey MS, Weinfield GD. Autogenous bone graft interpositional arthrodesis for the correction of flail toe. A retrospective analysis of 22 cases. *J Am Podiatr Med Assoc* 2003;93(3):167–173.
104. Kaplan EG, Kaplan GS. Metatarsal lengthening by use of autogenous bone graft and internal wire compression fixation: a preliminary report. *J Foot Surg* 1978;17(2):60–66.
105. Choi IH, Chung MS, Baek GH, et al. Metatarsal lengthening in congenital brachymetatarsia: one-stage lengthening versus lengthening by callotasis. *J Pediatr Orthop* 1999;19(5):660–664.
106. Kalen V, Brecher A. Relationship between adolescent bunions and flatfoot. *Foot Ankle* 1988;8:331.
107. Lynch FR, et al. Juvenile hallux abducto valgus. In: McGlamry ED, Banks AS, Downey MD, eds. *The comprehensive textbook of foot and ankle surgery*, 2nd ed, vol 1. Philadelphia, PA: JB Lippincott, 1992:573–577.
108. Fox IM, Smith SC. Juvenile bunion correction by epiphysiodesis of the first metatarsal. *J Am Podiatr Med Assoc* 1983;73:440–455.
109. Nelson JP. Mechanical arrest of bone growth in pedal deformities. *J Foot Surg* 1981;20:14–16.
110. Gillette. Des sesamoides. *J Anat Physiol Normal Path* 1872;8:506.
111. Blitch EL IV, Pachuda NM, Karlock LG, Mahan KT. Bone grafts. In: Banks AS, Downey MS, Martin DE, Miller SJ, eds. *McGlamry's comprehensive textbook of foot and ankle surgery*, 3rd ed. Philadelphia, PA: Lippincott Williams & Wilkins, 2001:1465–1486.
112. Zinsmeister BJ. A biomechanical approach to hallux varus *J Am Podiatr Med Assoc* 1985;75:613–615.
113. Hawkins FB. Acquired hallux varus: cause, prevention and correction. *Clin Orthop Relat Res* 1971;76:169–176.
114. Miller JW. Acquired hallux varus: a correctible and preventable disorder *J Bone Joint Surg Am* 1975;57:183–187.
115. Feinstein MH, Brown HN. Hallux adductus as a surgical complication. *J Foot Surg* 1980;19:207–211.
116. McBride ED. Hallux valgus. *J Int Coll Surg* 1954;21:99–105.
117. Hansen C. Hallux valgus treated by the McBride operation. A follow up. *Acta Orthop Scand* 1974;45:778–792.
118. Joplin RJ. Sling procedure for correction of splay foot, metatarsus primus varus and hallux valgus. *J Bone Joint Surg Am* 1964;46:690–693.
119. Trnka HJ. Acquired hallux varus and clinical tolerability. *Foot Ankle Int* 1997;18:593–597.
120. Banks AS, Ruch JA, Kalish SR. Surgical repair of hallux varus. *J Am Podiatr Med Assoc* 1988;78(7):339–347.
121. Thomson SA. Hallux varus and metatarsus varus: a five year study (1954–1958). *Clin Orthop* 1960;16:109–118.
122. Faraj A. A modified Jones procedure for post-polio claw hallux deformity. *J Foot Ankle Surg* 1997;36(5):356–359.
123. Ahmed S, Kaji S, Samesima K, et al. Osteoarthropathy in hereditary sensory radicular neuropathy. A case report. *Acta Orthop Scand* 1990;61(1):92–94.
124. Jahss MH. Spontaneous hallux varus: relation to poliomyelitis and congenital absence of the fibular sesamoid. *Foot Ankle* 1983;3(4):224–226.
125. Storm TR, Lee MS. Complications of hallux abducto valgus surgery. In: Banks AS, Downey M, Martin DE, et al, eds. *McGlamry's comprehensive textbook of foot and ankle surgery*, 3rd ed, vol 2. Philadelphia, PA: Lippincott Williams & Wilkins, 2001:1500–1503.
126. Berlet GC, Hyer CF, Lee TH, et al. Interpositional arthroplasty of the first MTP joint using a regenerative tissue matrix for the treatment of advanced hallux rigidus. *Foot Ankle Int* 2008;29(1):10–21.
127. Berlet GC, Hyer CF, Lee TH, et al. A soft tissue interpositional arthroplasty technique of the first metatarsophalangeal joint for the treatment of advanced hallux rigidus using a human acellular dermal regenerative tissue matrix. *Techniq Foot Ankle Surg* 2006;5(4):257–265.
128. Clark WD. Abductor hallucis tendon transfer for hallux varus. *J Foot Surg* 1984;23:146–148.
129. Wood WA. Acquired hallux varus: a new corrective procedure. *J Foot Surg* 1981;20:194–197.
130. Mancuso JE, Abramow SP, Bloom WB, et al. Smooth Kirschner (K) wire fixation of distal metaphyseal osteotomy bunionectomies: a 10- year retrospective survey. *J Foot Surg* 1992;31:276–284.
131. Mann RA, Rudicel S, Graves SC. Repair of hallux valgus with repair of a distal soft tissue procedure and proximal metatarsal osteotomy. *J Bone Joint Surg Am* 1992;74:124–129.
132. Brought NS, Winson IG. Keller's arthroplasty and Mitchell's osteotomy: a comparison with first metatarsal osteotomy of the long-term results for hallux valgus deformity in the younger female. *Foot Ankle Int* 1990;10:201–205.
133. Muller ME, Allgower M, Willenegger H. *Manual of internal fixation.* New York, NY, Springer-Verlag, 1970.
134. Rosen H. Nonunion and mal union. In: Browner BD, Jupiter JB, Levine A, et al., eds. *Skeletal trauma.* Philadelphia, PA: WB Saunders, 1992.
135. Taylor JC. Delayed union and nonunion in fractures. In: Crenshaw A, ed. *Campbell's operative orthopedics*, vol 2, 8th ed. St. Louis, MO: CV Mosby, 1992.
136. Watson Jones R. *The principles of fracture treatment*, 4th ed. Baltimore, MD: Williams & Wilkins, 1957.
137. Mayer PJ, Evarts CM. Nonunion, delayed union, mal union, and avascular necrosis. In: Epps CH Jr, ed. *Complications in orthopedic surgery*, vol 1, 2nd ed. Philadelphia, PA: JB Lippincott, 1986.
138. Connolly SF. Electrical treatment of non unions-its use and abuse in 100 consecutive fractures. *Orthop Clin North Am* 1984;15:89.
139. Nicoll EA. Fractures of the tibial shaft: a survey of 705 cases. *J Bone Joint Surg Br* 1964;46:373.
140. Boyd HB, Lipinski S. Causes and treatment of nonunion of the long bones, with a review of 741 patients. *AAOS Instr Course Lect* 1960:27.
141. Jhass MH. Disorders of the hallux and first ray. In: Jhass MH, ed. *Disorders of the foot and ankle: medical and surgical management*, 2nd ed, vol 2. Philadelphia, PA: WB Saunders, 1991.
142. Bhandari M, Guyatt GH, Swiontkowski MF, et al. A lack of consensus in the assessment of fracture healing among orthopedic surgeons. *J Orthop Trauma* 2002;16(8):562–566.
143. Gabbay NM. The sagittal "Z" osteotomy and its effects on the first metatarsophalangeal joint range of motion when used to lengthen the first metatarsal. In: *Proceedings of the annual meeting of the Podiatry Institute: update 2003*, Tucker, GA: The Podiatry Institute, 2003:66.
144. Schimizzi A, Brage M. Brachymetatarsia. *Foot Ankle Clin* 2004;9(3):555–570.
145. Hurst JM, Nunley JA. Distraction osteogenesis for the shortened metatarsal after hallux valgus surgery. *Foot Ankle Int* 2007;28(2):194–198.
146. Shevtsov VI. Professor G.A. Ilizarov's contribution to the method of transosseous osteosynthesis. *Bull Hosp Jt Dis* 1997;56:11–15.
147. Ilizarov GA, Frankel VH. The Ilizarov external fixator, a physiologic method of orthopaedic reconstruction and skeletal correction: a conversation with Professor G.A. Ilizarov and Victor H. Frankel. *Ortho Rev* 1988;17:1142-1154.
148. Shim JS, Park SJ. Treatment of brachymetatarsia by distraction osteogenesis. *J Pediatr Orthop* 2006;26:250–254.
149. Price CT, Cole JD. Limb lengthening by callotasis for children and adolescents; early experience. *Clin Orthop Relat Res* 1990;250:105–111.
150. Price CT, Mann JW. Experience with the orthofix device for limb lengthening. *Orthop Clin North Am* 1991;22:651–661.
151. Aldegheri R. Lengthening of the lower limbs in achondroplastic patients. *J Bone Joint Surg Br* 1988;70:69.
152. Moseley C. Leg lengthening: a 30 year review. Clin Orthop, 1989;247:38.
153. Pelionen J, Karaharju E, Aalto K et al. Leg lengthening by osteotomy and gradual distraction: an experimental study. *J Pediatr Orthop*, 1988;8:509.
154. Martin D. Callus distraction in brachymetatarsia: a clinical update and pearls in operative technique., In: *Reconstructive surgery for the foot and leg, update'94.* Tucker, GA: The Podiatry Institute, 1994:251.
155. Martin DE. Callus distraction. In: Banks AS, Downey M, Martin DE, et al, eds. *McGlamry's comprehensive textbook of foot and ankle surgery*, 3rd ed, vol 2. Philadelphia, PA: Lippincott Williams & Wilkins, 2001:2097.
156. Aldegheri R, Renzie-Brivio L, Agostini S. The callotasis of limb lengthening. Clin Orthop Relat Res, 1989;241:137.
157. Dahl MT, Fischer DA. Lower extremity lengthening by Wagner's method and by callus distraction. *Orthop Clin North Am* 1991;22:643.
158. Fischgrund J, Paley D, Suter C: Variables affecting time to bone healing during limb lengthening. *Clin Orthop Relat Res* 1994;301:31.
159. Ilizarov GA. The tension-stress effect on the genesis and growth of tissues: part II. The influence of the rate and frequency of distraction. *Clin Orthop Relat Res* 1989, 239:263.
160. Wada A, Bensabel H, Takamura K, et al. Metatarsal lengthening by callus distraction for brachymetatarsia. *J Pediatr Ortho* 2004;13(3):206–210.
161. Kim, H T; Lee, S H; Yoo, C I; Kang, J H; Suh, J T:The management of brachymetatarsia. J Bone Joint Surgery Br, 2003;85(5): 683–90.
162. Oh CW, Sharma R, Song H-R, et al. Complications of distraction osteogenesis in short fourth metatarsals. J Ped Orthop, 2003; 23(4):484–487.
163. Oh CW, Satish BR, Lee ST Song HR. Complications in distraction osteogenesis in short metatarsals. J Pediatr Orthop, 2004; 24:711–715.
164. Masada K, Fujita S, Fuji T Ohno H. Complications following metatarsal lengthening by callus distraction for brachymetatarsia. *J Pediatr Orthop* 1999;19:394–397.
165. Robinson JF Ouzounian TJ. Brachymetatarsia: Congenitally short third and fourth metatarsals treated by distraction lengthening- A case report and literature summary. *Foot Ankle Int* 1998; 19(10):713–718.
166. Song H-R, Oh C-W, Kyung H-S, et al. Fourth brachymetatarsia treated with distraction osteogenesis. *Foot Ankle Int* 2003;24(9):706–711.
167. Hosokawa K Suski T. Treatment of multiple brachymetatarsia: a case report. *Br J Plast Surg* 1987;40:423–426.
168. Magnan B, Bragantini A, Regis D Bartolozzi P. Metatarsal lengthening by callotasis during growth phase. *J Bone Joint Surg* 1995;77:602–607.
169. Benson J Christopher; Banks, Alan S: First metatarsal callus distraction. *J Am Podiatr Med Assoc* 2008;98(1):51–60.
170. Wilusz PM, Van P, Pupp GR. Complications associated with distraction osteogenesis for the correction of brachymetatarsia: a review of five procedures. *J Am Podiatr Med Assoc* 2007;97(3):189–194.
171. Davidson RS. Metatarsal lengthening. *Foot Ankle Clin* 2001;6(3):499–518.

172. Yamada N, Yasuda Y, Hashimoto N, et al. Use of internal callus distraction in the treatment of congenital brachymetatarsia. *Br J Plastic Surg* 2005;58:1014–1019.
173. Debastiani G, Aldegheri R, Renzi-Brivio L, et al. Limb lengthening by callus distraction (callotasis). *J Pediatr Orthop* 1987;7:129–134.
174. Price CT, Bright R, Sproul JT, et al. Limb lengthening after immediate correction of deformity using the Orthofix unilateral fixator. Presentation at American Academy of Orthopaedic Surgeons, Anaheim, CA, March 1991.

SUGGESTED ADDITIONAL READING

Allen TR, Gross M, Miller J, et al. Reassessment of adolescent hallux valgus before and after first metatarsal osteotomy. *Int Orthop* 1981;5:111–115.
Cicchinelli LD, Camasta CA, McGlamry ED. Iatrogenic metatarsus primus elevatus: etiology, evaluation and surgical management. *J Am Podiatr Med Assoc* 1997,87:165–177.
Grabe RP, deJongh AGV, Van Papaendorp D. The chevron osteotomy in the treatment of hallux valgus. *J Bone Joint Surg Br* 1990;72:744.
Johnson KA, Spiegl PV. Extensor hallucis longus transfer for hallux varus deformity. *J Bone Joint Surg Am* 1984;66:681–686.
Jones KJ, Feiwell LA, et al. The effects of first metatarsal osteotomy and lateral release on the blood supply to the first metatarsal head. *J Bone Joint Surg* 1995;77:197–204.
Lincoln CR, Wood KE, et al. Metatarsus varus corrected by opening wedge osteotomy of the first cuneiform *Orthop Clin North Am* 1976;7:795–798.
Peterson DA, Ziberafrb JL, et al. Avascular necrosis of the first metatarsal head: incidence in distal osteotomy combined with lateral soft tissue release. *Foot Ankle Int* 1994;15:59–63.
Poehling GG, DeTorre J. Hallux varus and hammertoe deformity. *Ortho Trans* 1982;6:186.
Richardson EG. Complications after hallux valgus surgery. *Instr Course Lect* 1999;48:331–342.
Talbot KD, Salzman CL. Assessing sesamoid subluxation: how good is the AP radiograph? *Foot Ankle Int* 1998;19:547–554.

CHAPTER

55

Sean Patrick Dunn
Justin T. Meyer
John A. Ruch

Principles of Arthrodesis

HISTORY

The use of arthrodesis for the correction of deformities is a cornerstone of podiatric surgery. From the proximal interphalangeal joint (PIPJ) for the correction of a digital contracture to a pantalar arthrodesis for the unstable Charcot foot and ankle, all podiatric surgeons need to be well versed in the principles for the fusion of joints. The modern general principles behind performing an arthrodesis were originally described by Glissan for the ankle arthrodesis. Since then, several organizations have added to the core principles in an attempt to provide a more predicable fusion.

In 1949, Glissan published his procedure for the performance of ankle arthrodesis, which has been notorious for delayed and nonunion of the fusion surfaces. He postulated that strict adherence to four basic principles would lead to a higher fusion rate (Table 55.1). First, the surgeon must completely remove all cartilage, fibrous tissue, and any other material that would prevent the close approximation of the raw bone surfaces that will comprise the fusion mass. Second, the surgeon must provide an accurate and close-fitting construct for fusion. Third, optimal position of the joint to be fused must be ensured. Finally, the surgeon must maintain the bone apposition in an undisturbed fashion until the fusion is complete (1). These principles revolutionized the steps that were undertaken to perform ankle arthrodesis and have been adopted, modified, and expanded by the AO for use in fracture repair.

In 1958, the AO was founded by world-renowned trauma surgeons in Switzerland who were unhappy with the lack of standardization in the treatment of orthopaedic injuries. Through their pioneering research into the basic science of bone healing, they modified Glissan's principles for use in fracture healing/repair (Table 55.2). The AO principles include preserving the blood supply to the fracture or fusion, obtaining anatomic reduction, providing stable fixation, and beginning early, active range of motion of the involved body part (2). These principles have been integrated into common surgical practice and greatly enhance surgical visualization and stability in arthrodesis.

SURGICAL STRATEGY

The integration of the above-mentioned principles into common surgical practice begin with proper surgical planning. The surgeon's thorough knowledge of the indications for the procedure to be performed, the surgical anatomy, proper patient positioning, and proper anesthesia is of paramount importance. Additionally, the proper implants (screws, plates, wires, etc.) and instrumentation to insert the implants should be planned before surgery.

Proper incision placement is of the utmost importance when performing any surgical procedure. If an incision is improperly planned, inadequate visualization, excessive retraction on skin and soft tissue, and violation of vital anatomic structures will result. Additionally, improper incision placement may preclude the use of the most stable form of fixation for the desired procedure and may impede proper positioning. When planning the surgical incision, the desired joint exposure for resection and the proper exposure to insert fixation should be taken into consideration (Fig. 55.1).

Once the incision is planned, strict adherence to proper surgical technique is vital. This includes the use of anatomic dissection (tissue plane dissection) (Fig. 55.2). This is explained in further detail in the sections on specific surgical procedures. One point of emphasis will be in the periosteal dissection.

The periosteum provides approximately 80% of the blood supply to the bone (3). Because of its importance in the healing of the fusion site, it should be treated delicately. The preferred method to periosteal dissection involves making a linear incision in the periosteum to provide the exposure needed to perform the arthrodesis. Following incision, a Freer elevator is utilized to begin the subperiosteal dissection in a blunt manner over the diaphyseal area of the bone. This provides a known target layer on the proximal and distal aspect of the joint surface to be fused. In the periarticular area, the periosteum is continuous with the joint capsule and is firmly attached to the bone by Sharpey fibers. These fibers must be sectioned sharply in the same plane as the subperiosteal dissection (Fig. 55.3). However, care must be taken not to shred or lacerate the periosteum and capsule. By maintaining the periosteum as a single layer, the disruption of the periosteal blood supply is minimized.

JOINT RESECTION

After proper incision placement and utilization of anatomic dissection technique, the proposed joint for arthrodesis should be visualized within the surgical wound. The next vital step to successfully prepare a joint for arthrodesis is joint exposure. Without proper exposure, the surgeon will not be able to adequately resect the joint for arthrodesis. The two most efficient ways to gain exposure to a joint is either through joint disarticulation or joint distraction. The best way to gain exposure to a metatarsal phalangeal joint or an interphalangeal joint is through disarticulation (Fig. 55.4), whereas exposure to an intertarsal or ankle joint is most amenable to joint distraction.

It may be difficult to delineate or gain access to a joint secondary to severe degenerative changes. In these instances, a Sayer, Key, or Freer elevator may be useful to pry the joint apart (Fig. 55.5A). To maintain or obtain joint distraction, many surgical instruments are available. These instruments include lamina spreader, AO "mini distractor," femoral distractor, tarsal distractor, and Weinraub distractor (Fig. 55.5B and C). After full visualization of the joint has been obtained, the joint is now ready for resection. Care should be taken to place the distractor

TABLE 55.1 Glissan's Principles of Arthrodesis
Remove all interposing soft tissue
Accurate and close fitting of the fusion surfaces
Optimal position of (ankle) joint
Maintenance of bone apposition in an undisturbed fashion until complete fusion

TABLE 55.2 AO Principles
Preserve blood supply to the fracture
Anatomic reduction
Stable internal fixation
Early and active range of motion

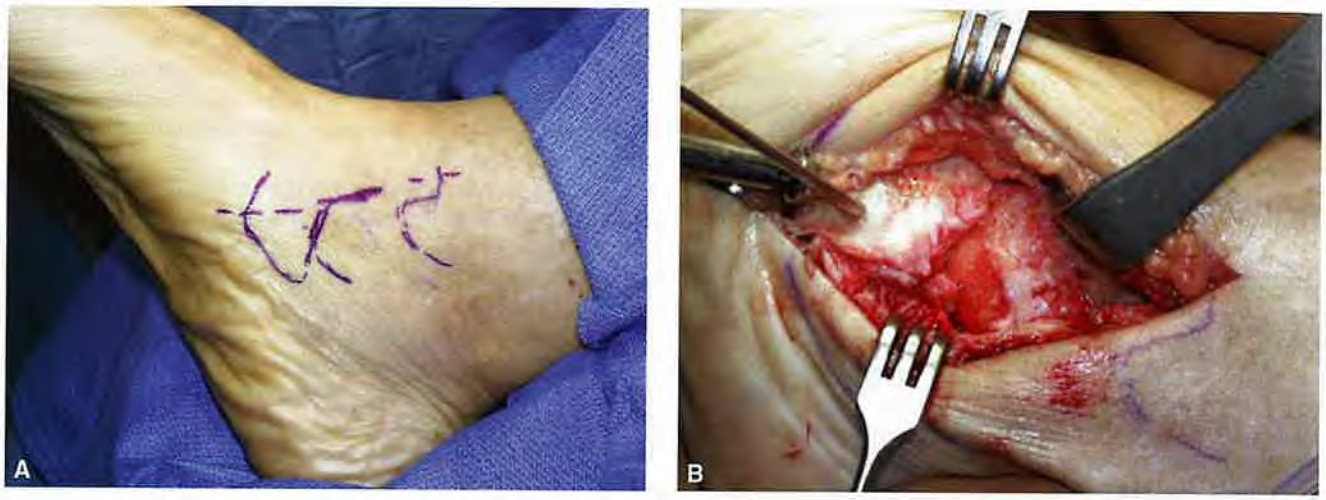

Figure 55.1 **A:** Proposed incision placement for the medial dissection for a triple arthrodesis. Note the bias of the incision to provide access for joint preparation and fixation placement. **B:** The same incision with joints prepared and fixation being applied.

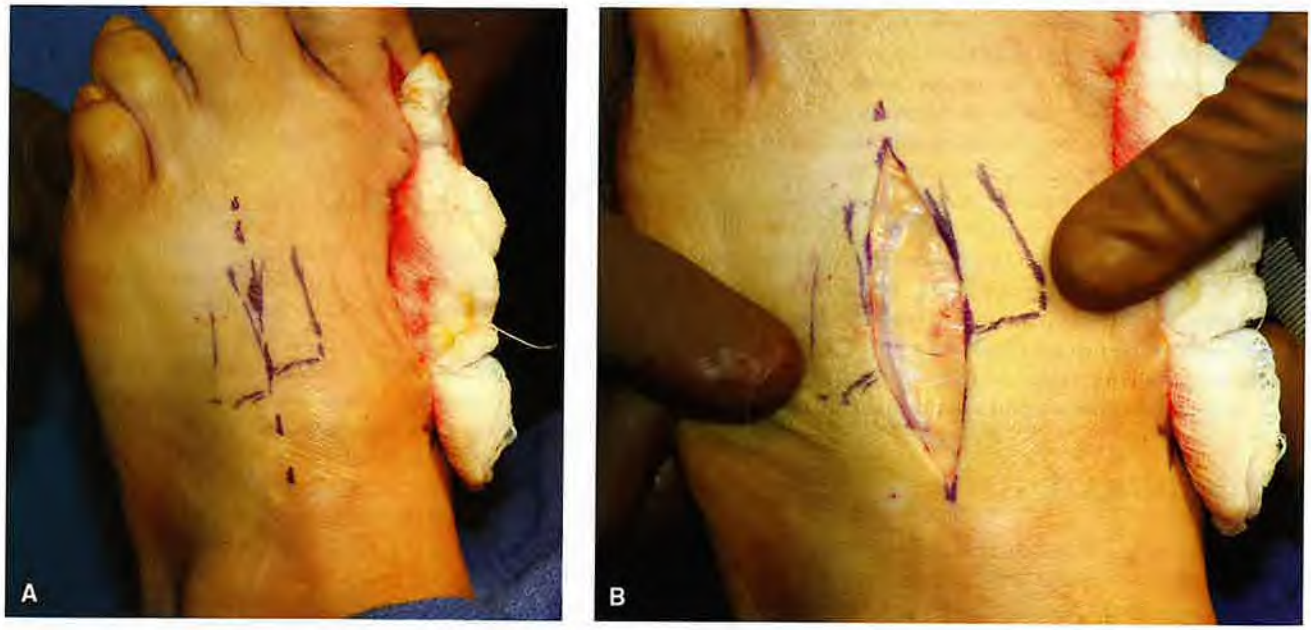

Figure 55.2 **A:** Incisional landmarks with proposed incision for metatarsal–cuneiform fusion. **B:** Controlled depth incision through epidermis and dermis.

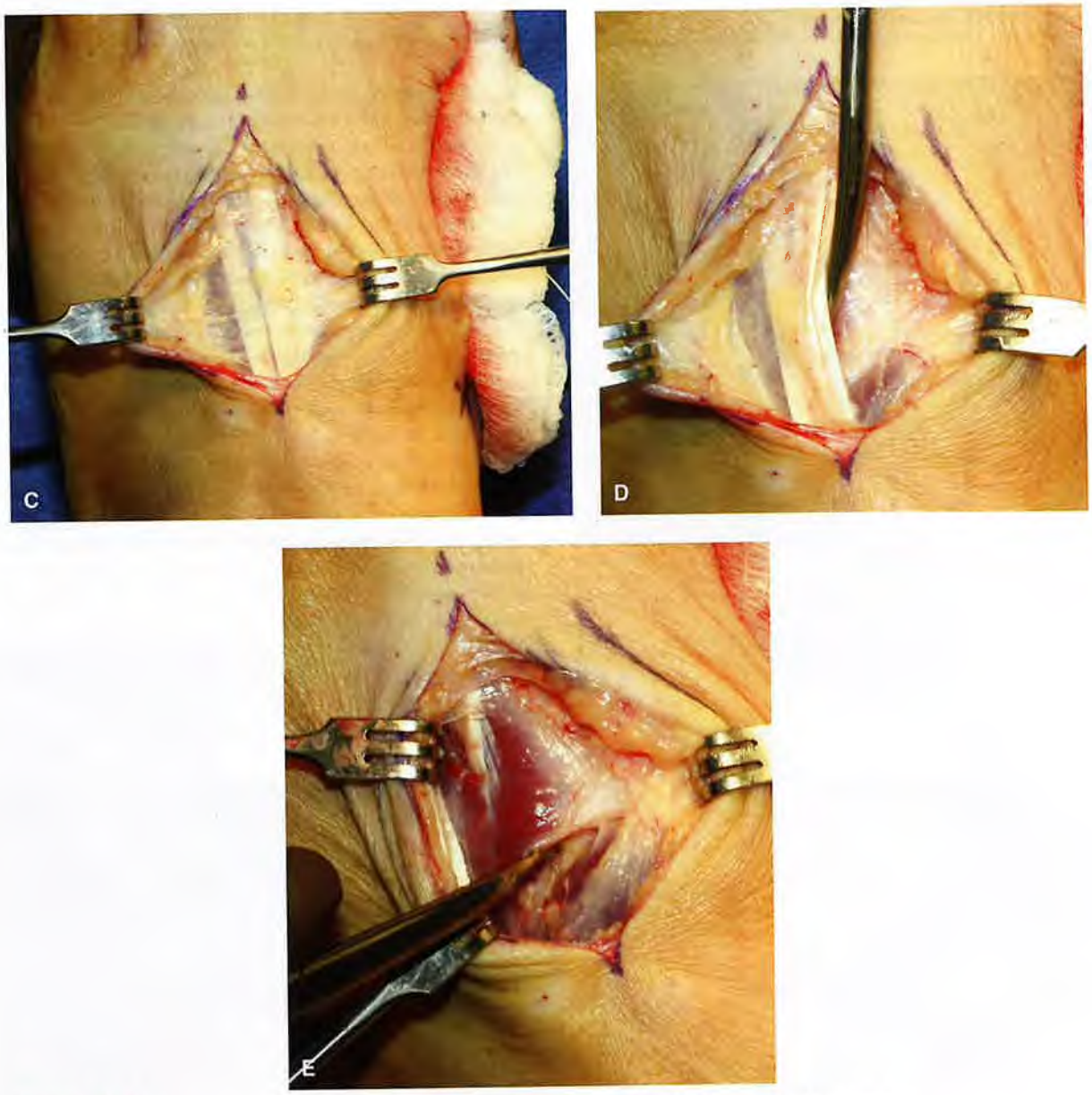

Figure 55.2 *(Continued)* **C:** The subcutaneous tissue has been dissected to the level of the deep fascia and the first dissection interval has been developed via "sponge" technique. **D:** Deep fascial incision has been performed to allow for retraction and protection of the extensor tendons. **E:** The metatarsal cuneiform joint has been exposed.

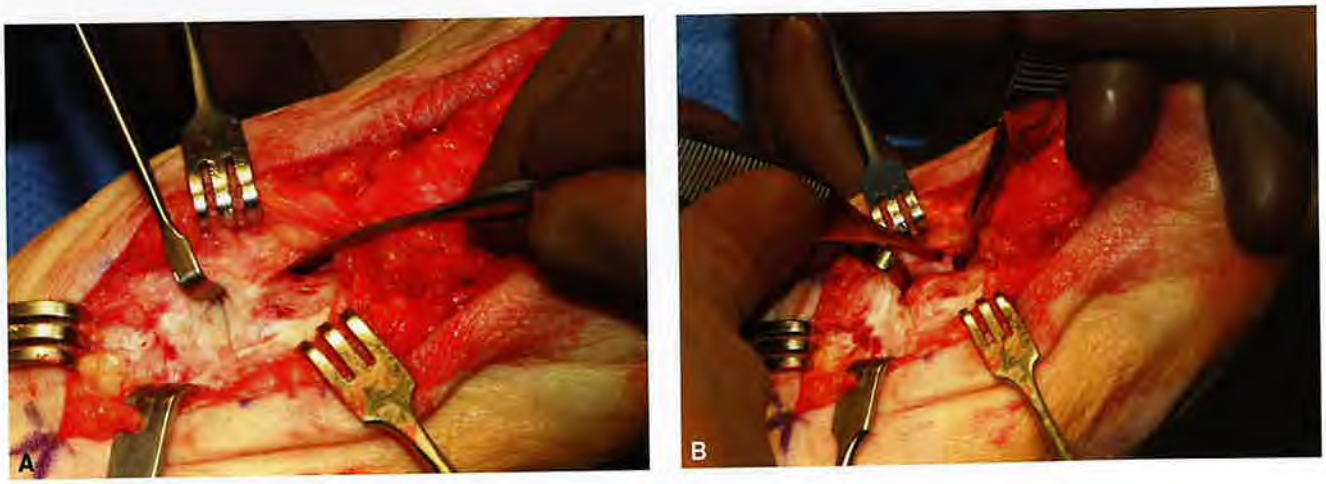

Figure 55.3 **A:** The Freer is used to develop a subperiosteal plane of dissection over the shaft of the metatarsal. The firmly attached capsule must be released sharply. **B:** Release of the capsular structures with a 15 blade.

Figure 55.4 Disarticulation of a PIPJ. Note the collateral ligaments are still attached to the head of the proximal phalanx.

in a location in which it may provide optimal distraction but remain distant from the surgeon's field.

When resecting a joint and preparing the bone for arthrodesis, Glissan's first principle of arthrodesis is employed: complete removal of all cartilage, fibrous tissue, and any other material that may prevent contact of raw bony surfaces. The anatomy of an articular joint consists of articular cartilage and a subchondral bone plate. Superficial articular cartilage is uncalcified, relatively malleable, and avascular. The subchondral bone plate is composed of two layers. The first and most superficial layer is calcified cartilage, which is hard and avascular. The second layer is subchondral bone. Subchondral bone is thin, relatively avascular compared with cancellous bone, and constructed mainly of appositional layers of bone with trabeculae. Subchondral bone differs from cortical bone due to the fact that haversian canals are seldom seen histologically (4,5). Beneath the subchondral bone plate is vascular cancellous bone. The cancellous bone just beneath the subchondral bone plate is the layer sought when preparing the bone for arthrodesis. Once cancellous substrate is exposed, it is recognized by capillary bleeding within the resected boney surface, also called "Paparika sign" (6–8).

There have been numerous techniques described for resection of every joint within the lower extremity. Most all techniques follow the principle of either contoured or wedged

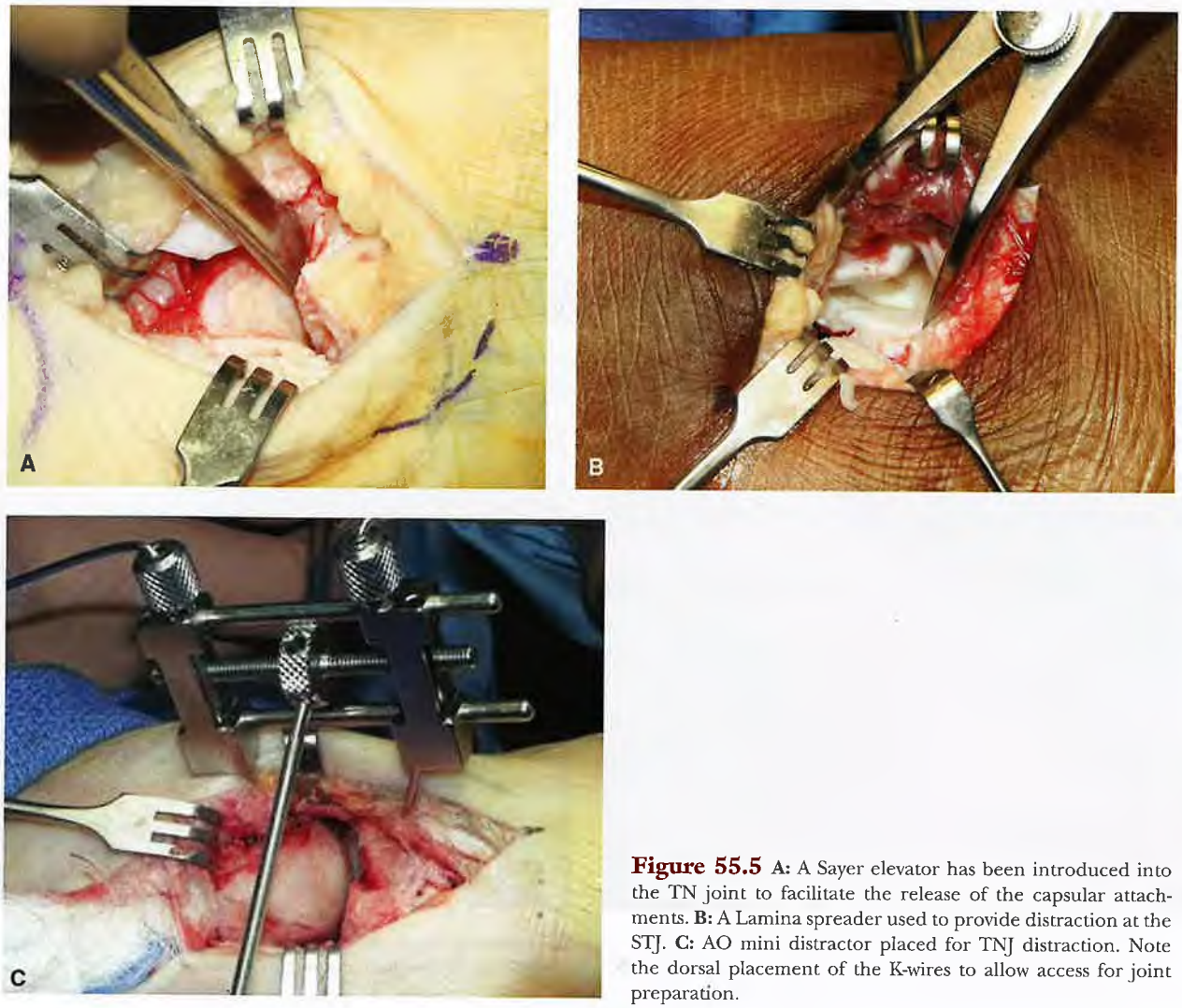

Figure 55.5 **A:** A Sayer elevator has been introduced into the TN joint to facilitate the release of the capsular attachments. **B:** A Lamina spreader used to provide distraction at the STJ. **C:** AO mini distractor placed for TNJ distraction. Note the dorsal placement of the K-wires to allow access for joint preparation.

joint resection. Contoured joint resection allows the surgeon to maintain the anatomic concave/convex relationship of the joint. Advantages of contoured resection are that it helps to minimize shortening and allows for manual reduction of the deformity without having to remove more bone to achieve position. Joints in the lower extremity that amend themselves to this type of resection are ellipsoid (condylar), saddle, hinge, and even some planar joints. Wedge joint resection is generally employed for reduction of rigid deformities. The principle of wedge resection is to resect the joint in a planar or linear surface fashion. Each side the arthrodesis site is a planar surface so as to achieve maximum boney surface apposition. To adjust the position of the arthrodesis site, a wedge of bone from either surface must be taken. Care must be exercised when adjusting position with this resection technique because every adjustment is subjected to some degree of shortening. This type of resection as mentioned above is preferred for reduction of a rigid deformity or resection of some planar joints. The physical act of joint resection can be accomplished with various surgical instruments. When a contoured resection technique is employed, the goal is to maintain an anatomic concave/convex relationship of the joint and minimize shortening. The articular cartilage of a joint can be resected utilizing a curette, although a curette is not effective at resecting the subchondral bone plate (5) (Fig. 55.6A). The use of rongeur or an osteotome with mallet can be utilized for a controlled depth resection of the subchondral bone plate (Fig. 55.6B–E).

In instances in which the articular cartilage has been resected and the subchondral plate has been partially resected with use of a curette, a power burr, or fenestration with a Kirschner wire (K-wire), or an osteotome/mallet can be used to break through the subchondral plate and expose cancellous bone (Fig. 55.7A and B). Reaming systems have also been designed for joint resection to maintain an anatomic concave/convex relationship of the joint. Care must be taken to control the depth of resection as to minimize shortening with use of these reaming systems. When a wedge resection technique is employed, the goal is to create a planar or linear surface when resecting the subchondral

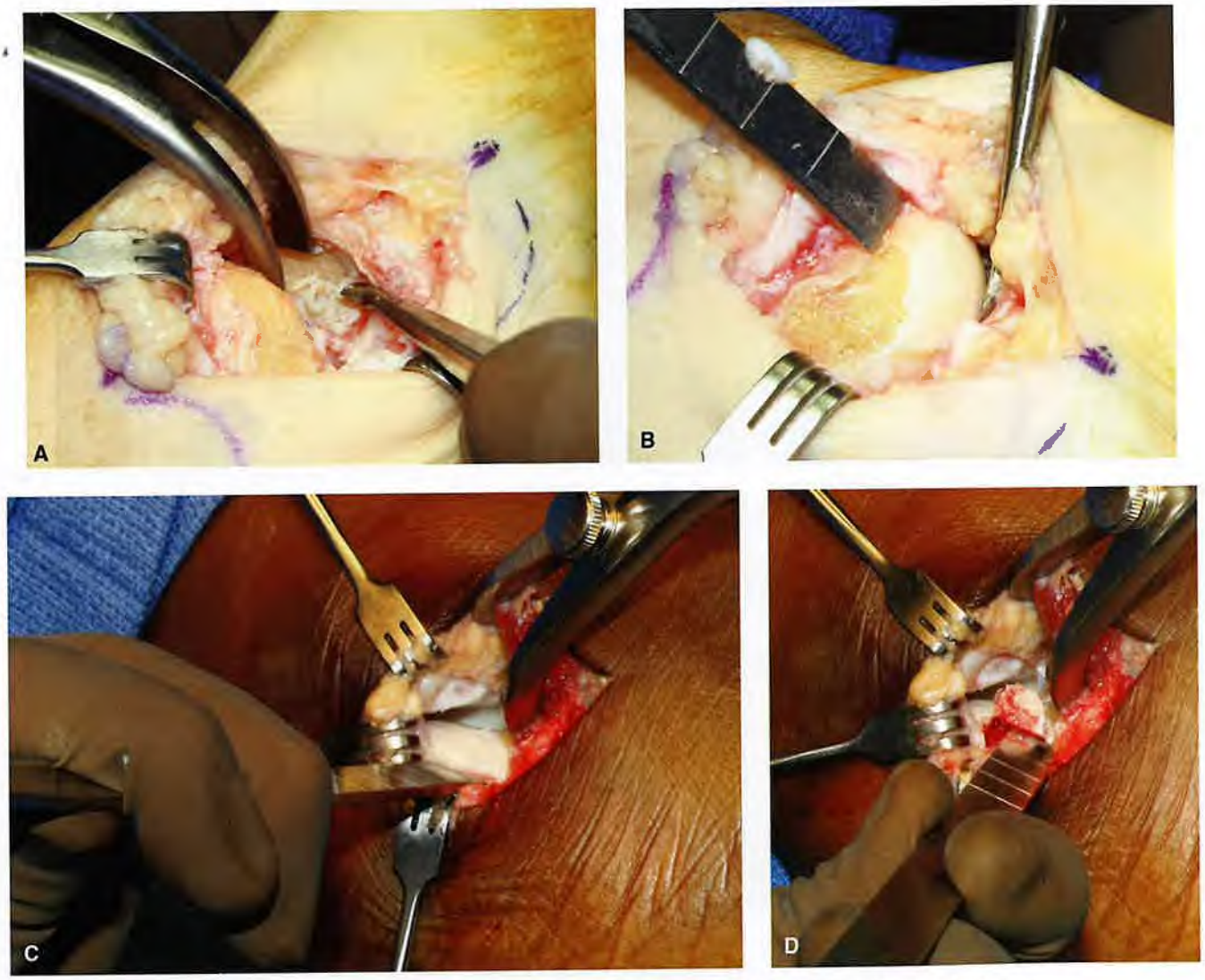

Figure 55.6 **A:** Utilizing a curette for débridement of cartilage. Note that the subchondral plate is still intact. **B:** Use of an osteotome and mallet to remove cartilage and subchondral plate from the head of the talus. Note the exposed cancellous bone along the resected surface. **C:** Use of an osteotome and mallet for preparation of the STJ. Initial placement of the osteotome to establish depth. **D:** Subchondral bone and cartilage are resected a few mm at a time to maintain optimal depth. *(Continues on next page)*

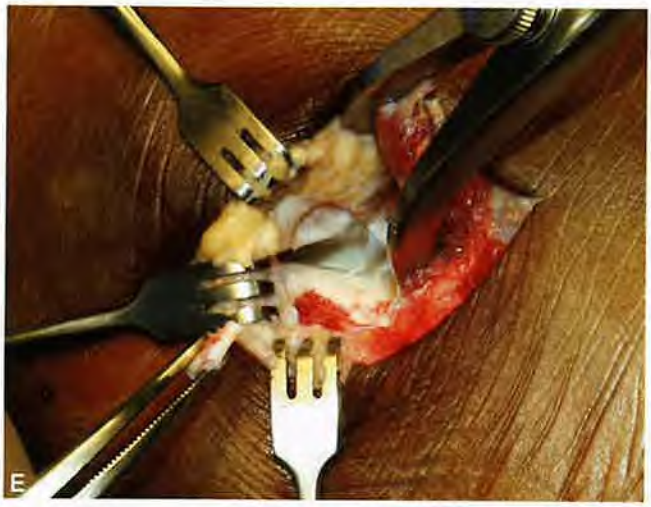

Figure 55.6 *(Continued)* **E:** Bleeding cancellous bone surface on the posterior facet of the STJ. You can see the thickness of resection with the fragment being held in the hemostat.

bone plate. This is best achieved with the use of a sagittal saw, so a uniform planar surface can be created (Fig. 55.7C–G).

FIXATION

After positioning the joint in the desired location, fixation may be applied. While there are many different types of fixation that may be applied to the arthodesis site (wires, screws, plates, etc.), it must be emphasized that the fixation is only utilized to stabilize the arthrodesis site while the bone heals. One of the founders of AO (Stephan Perren, MD) is credited with the statement: "The healing of a fusion/fracture site is a race between bone healing and fixation failure." Despite significant improvements in internal fixation over the past several decades, this statement is as true today as it was in 1978. The use of stable, internal fixation to stabilize the fusion site is one of the tenets of the AO philosophy (2). Whatever method of fixation is utilized, the arthrodesis site must be held in close, stable apposition until full healing across the fusion site has occurred.

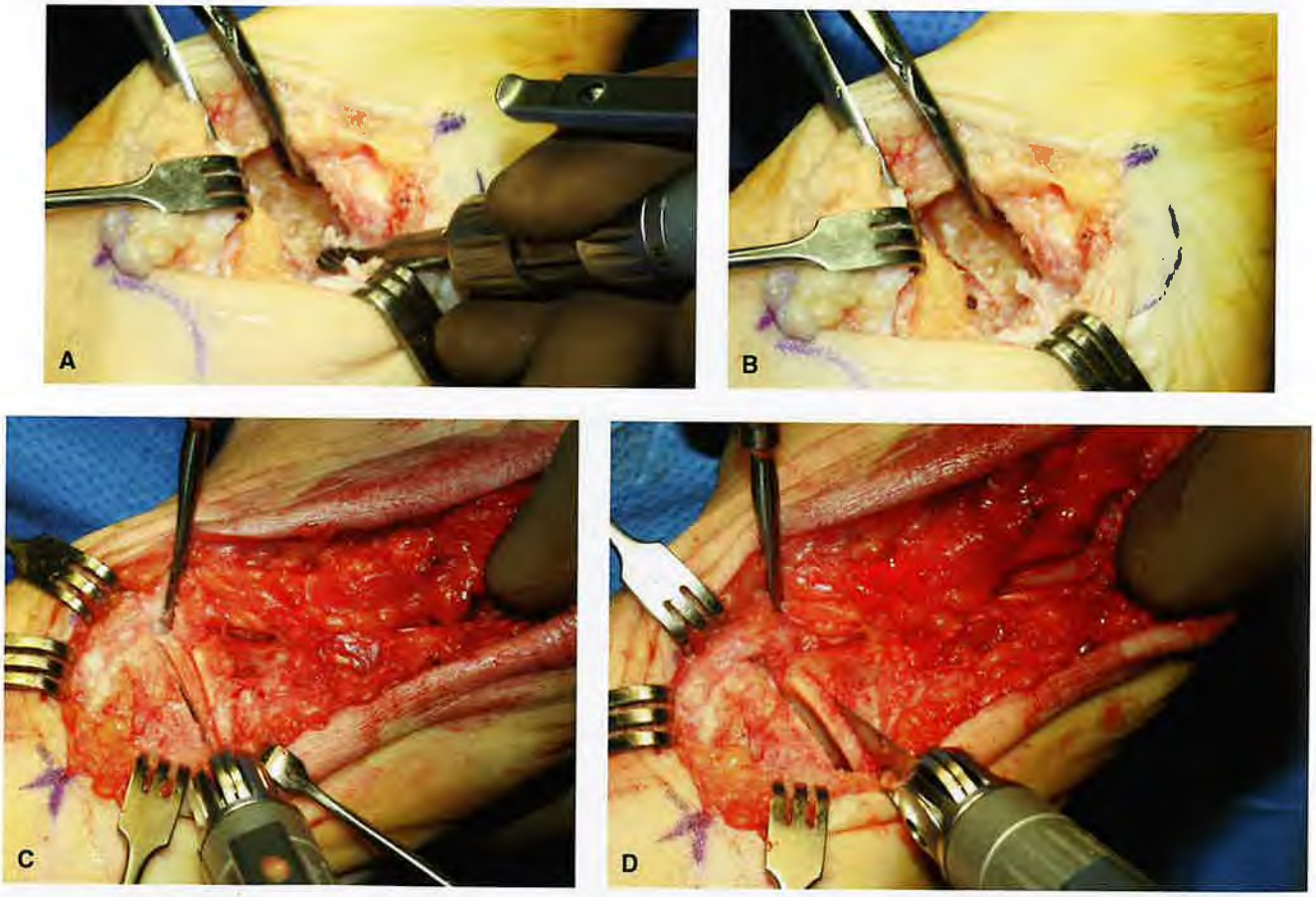

Figure 55.7 **A:** A burr is used to place "divots" into the subchondral plate of the navicular following resection of the cartilage with a curette. **B:** Final preparation of the navicular after the burr has been used. Note the "golf-ball" appearance. **C:** Resection of the articular surface of the medial cuneiform with the sagittal saw. **D:** Removal of the articular surface of the base of the first metatarsal.