Congenital adrenal hyperplasia

Diala El-Maouche, Wiebke Arlt, Deborah P Merke

Lancet 2017; 390: 2194–210
Published Online May 30, 2017 http://dx.doi.org/10.1016/S0140-6736(17)31431-9
This online publication has been corrected. The corrected version first appeared at thelancet.com on Nov 11, 2017

National Institutes of Health Clinical Center, Bethesda, MD 20892, USA (D El-Maouche MD, Prof D P Merke MD); Institute of Metabolism and Systems Research (IMSR), University of Birmingham & Centre for Endocrinology, Diabetes and Metabolism (CEDAM), Birmingham Health Partners, Birmingham, UK (Prof W Arlt MD); and The Eunice Kennedy Shriver National Institute of Child Health and Human Development, Bethesda, MD, USA (Prof D P Merke)
Correspondence to: Dr Deborah P Merke, National Institutes of Health Clinical Center, Bethesda, MD 20892–1932, USA dmerke@nih.gov

Congenital adrenal hyperplasia is a group of autosomal recessive disorders encompassing enzyme deficiencies in the adrenal steroidogenesis pathway that lead to impaired cortisol biosynthesis. Depending on the type and severity of steroid block, patients can have various alterations in glucocorticoid, mineralocorticoid, and sex steroid production that require hormone replacement therapy. Presentations vary from neonatal salt wasting and atypical genitalia, to adult presentation of hirsutism and irregular menses. Screening of neonates with elevated 17-hydroxyprogesterone concentrations for classic (severe) 21-hydroxylase deficiency, the most common type of congenital adrenal hyperplasia, is in place in many countries, however cosyntropin stimulation testing might be needed to confirm the diagnosis or establish non-classic (milder) subtypes. Challenges in the treatment of congenital adrenal hyperplasia include avoidance of glucocorticoid overtreatment and control of sex hormone imbalances. Long-term complications include abnormal growth and development, adverse effects on bone and the cardiovascular system, and infertility. Novel treatments aim to reduce glucocorticoid exposure, improve excess hormone control, and mimic physiological hormone patterns.

Introduction

In 1865, Luigi De Crecchio, an Italian pathologist, described the case of a man who, at autopsy, was found to have female internal anatomy and large adrenal glands, representing the first known case of presumed congenital adrenal hyperplasia (figure 1).[1] However, treatment for congenital adrenal hyperplasia was not introduced for almost another century when cortisone was given for what was then known as adrenogenital syndrome.[18–22]

Congenital adrenal hyperplasia is a group of seven autosomal recessive diseases caused by mutations in genes encoding enzymes in pathways involved in cortisol biosynthesis: 21-hydroxylase (21OH), 11β-hydroxylase (11βOH), 17α-hydroxylase (17OH; also known as 17,20-lyase), 3β-hydroxysteroid dehydrogenase type 2 (3βHSD2), steroidogenic acute regulatory protein (StAR), P450 cholesterol side-chain cleavage enzyme (SCC), and P450 oxidoreductase (POR). Multiple hormonal imbalances occur and congenital adrenal hyperplasia manifests with a range of clinical and biochemical phenotypes, with or without alterations in glucocorticoid, mineralocorticoid, and sex steroid production. Both severe (classic) and mild (non-classic) forms of congenital adrenal hyperplasia have been described.

More than 95% of congenital adrenal hyperplasia cases are due to 21OH deficiency,[23] characterised by impaired cortisol and aldosterone production and androgen excess. Life-saving neonatal screening for classic congenital adrenal hyperplasia due to 21OH deficiency was first done in Alaska in 1977,[7] and is currently used worldwide in more than 40 countries, including all 50 US states since 2009, although it is yet to be implemented in the UK.[7,23–25] Although all types of classic congenital adrenal hyperplasia are rare orphan diseases, the non-classic form due to 21OH deficiency is estimated to be one of the most common autosomal recessive disorders.[26,27]

Congenital adrenal hyperplasia remains one of the most challenging endocrine disorders to diagnose, manage, and treat because of the disorders' direct and indirect effects on steroidogenic pathways and the rarity of these conditions. Advances in genetics, metabolomics, and treatment strategies continue to improve understanding of these complex diseases and aim to improve patient outcomes.

Search strategy

We searched the Cochrane Library, MEDLINE, and Embase between Jan 1, 2010, and Sept 30, 2016. Keywords and controlled vocabulary and their synonyms were used when appropriate. We used variations of the search term "congenital adrenal hyperplasia" in combination with the terms "diagnosis/diagnostics", "genetics", "genomics", "adrenal crisis", "glucocorticoid", "mineralocorticoid", "gene therapy", "quality of life", "well-being", "screening", "metabolomics", "prenatal", "antenatal", "bone mineral density", "tumor", "pregnancy", "treatment/therapy/ therapeutic", "fertility/fecundity", "surgery", "management", "metabolic", and "complications". We largely selected publications in the past 5 years, but did not exclude commonly referenced and highly regarded older publications. We also searched the reference lists of articles identified by this search strategy and selected those we judged relevant. Review articles and book chapters are cited to provide readers with more details and more references than this Seminar has room for. The search was restricted to English publications.

Genetics and pathophysiology

Overview

All types of congenital adrenal hyperplasia are monogenetic and autosomal recessive. Most patients are compound heterozygotes, meaning that they have different mutations in two alleles for a particular gene. The clinical manifestation follows the allele that results in a more functional enzyme, and generally genotype–phenotype correlation is good.[28,29]

Adrenal steroidogenesis occurs by a series of steps facilitated by adrenal zone-specific enzyme expression, and in different types of congenital adrenal hyperplasia this process is interrupted at distinct points. In addition to the classic well established steroidogenesis pathway, an alternative pathway to active androgen biosynthesis exists (termed the backdoor pathway),[30,31] which might play a role in the pathophysiology of congenital adrenal hyperplasia (figure 2). The clinical manifestation of congenital adrenal hyperplasia is closely related to the type and severity of impairment.

Neurocrine EX1015
Page 1 of 17

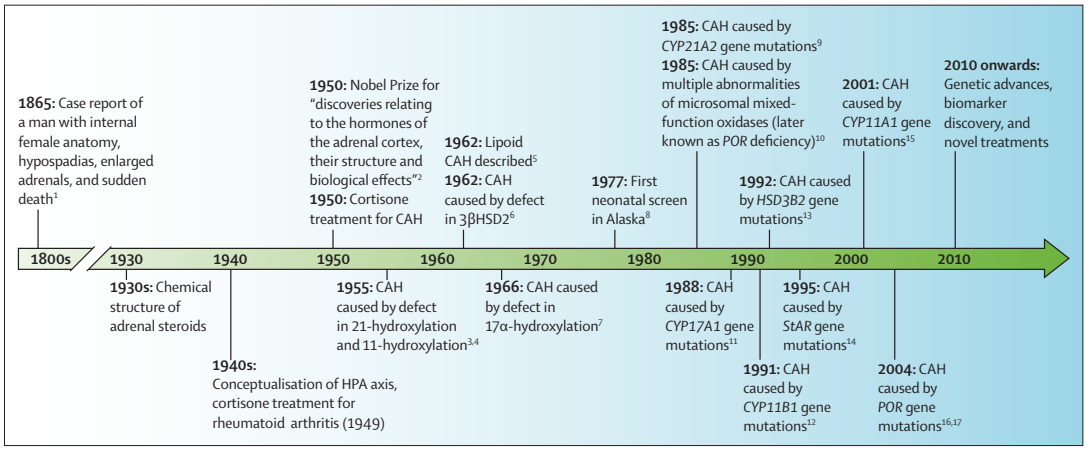

Figure 1: **Timeline of important discoveries in adrenal steroidogenesis, treatment landmarks, and gene discovery of congenital adrenal hyperplasia**
HPA=hypothalamic-pituitary-adrenal. CAH=congenital adrenal hyperplasia. 3βHSD2=3β-hydroxysteroid dehydrogenase type 2 deficiency. POR=P450 oxidoreductase.

21OH deficiency

The gene for 21OH, *CYP21A2*, is located within the human leucocyte antigen class III region of chromosome 6 (table 1). *CYP21A2* and a homologous pseudogene, *CYP21A1P*, lie about 30 kb apart. Meiotic recombination events are common in this genomic region because of the high degree of sequence homology between duplicated genes. Approximately 95% of *CYP21A2* disease causing mutations are *CYP21A1P*-derived variants or deletions due to recombination events.[28,39]

Defective 21OH-hydroxylation results in decreased glucocorticoid and mineralocorticoid synthesis and elevated precursors, most notably 17-hydroxyprogesterone (17OHP), which is used for congenital adrenal hyperplasia diagnosis (figure 2). Adrenocorticotropic hormone (ACTH)-stimulated androgen production occurs because no block exists in the pathway synthesising adrenal androgens.

Conventionally, classic 21OH deficiency is subclassified into salt wasting and simple virilising forms, which reflect the severity of aldosterone deficiency. Mutations that completely inactivate *CYP21A2* result in the salt-wasting phenotype, which, without neonatal screening, presents in the first 2 weeks of life with a life-threatening adrenal crisis (table 2).[23] Patients with classic simple virilising congenital adrenal hyperplasia have mutations that retain 1–2% of 21OH activity and minimal aldosterone production prevents a neonatal crisis.[40] Excess fetal adrenal androgen exposure results in virilisation of external genitalia of 46,XX patients with classic 21OH deficiency (salt wasting and simple virilising; figure 3A). Without neonatal screening, male toddlers with the simple virilising form of the disorder are diagnosed with signs and symptoms of androgen excess. Postnatal excess androgen presence leads to premature growth of pubic hair and rapid skeletal growth in children. Patients with the non-classic form retain up to 50% of enzyme activity and mostly do not have adrenal insufficiency, but might have partial glucocorticoid deficiency, and female patients have normal genitalia.[41] Patients might present with mild androgen excess or have few or no symptoms. In fact, the term cryptic congenital adrenal hyperplasia was created to define patients with non-classic congenital adrenal hyperplasia who are identified by family genetic studies, but are otherwise asymptomatic.[42]

11βOH deficiency

Congenital adrenal hyperplasia caused by 11βOH deficiency is due to *CYP11B1* mutations (table 1). The enzyme encoded by *CYP11B1* functions in the adrenal zona fasciculata to convert 11-deoxycortisol to cortisol and deoxycorticosterone to corticosterone under the regulation of ACTH (figure 2). Most *CYP11B1* mutations correspond to minimal or absent enzyme activity, resulting in a classic congenital adrenal hyperplasia phenotype.[43]

Impaired 11-hydroxylation results in decreased corticosterone and cortisol synthesis, with subsequent increase in ACTH and excess androgens, caused by shunting of the pathway towards androgen production. Normally corticosterone and deoxycorticosterone production by *CYP11B1* transcription in the adrenal zona fasciculata is minimal, but deoxycorticosterone concentrations can rise substantially under the influence of ACTH.[44] Deoxycorticosterone is a weak mineralocorticoid, but elevated concentrations of deoxycorticosterone suppress the renin–angiotensin system, resulting in extracellular fluid volume expansion, hypertension, low plasma renin activity, and low aldosterone concentrations, although the ability to produce aldosterone remains.[32] The effects of

Neurocrine EX1015
Page 2 of 17

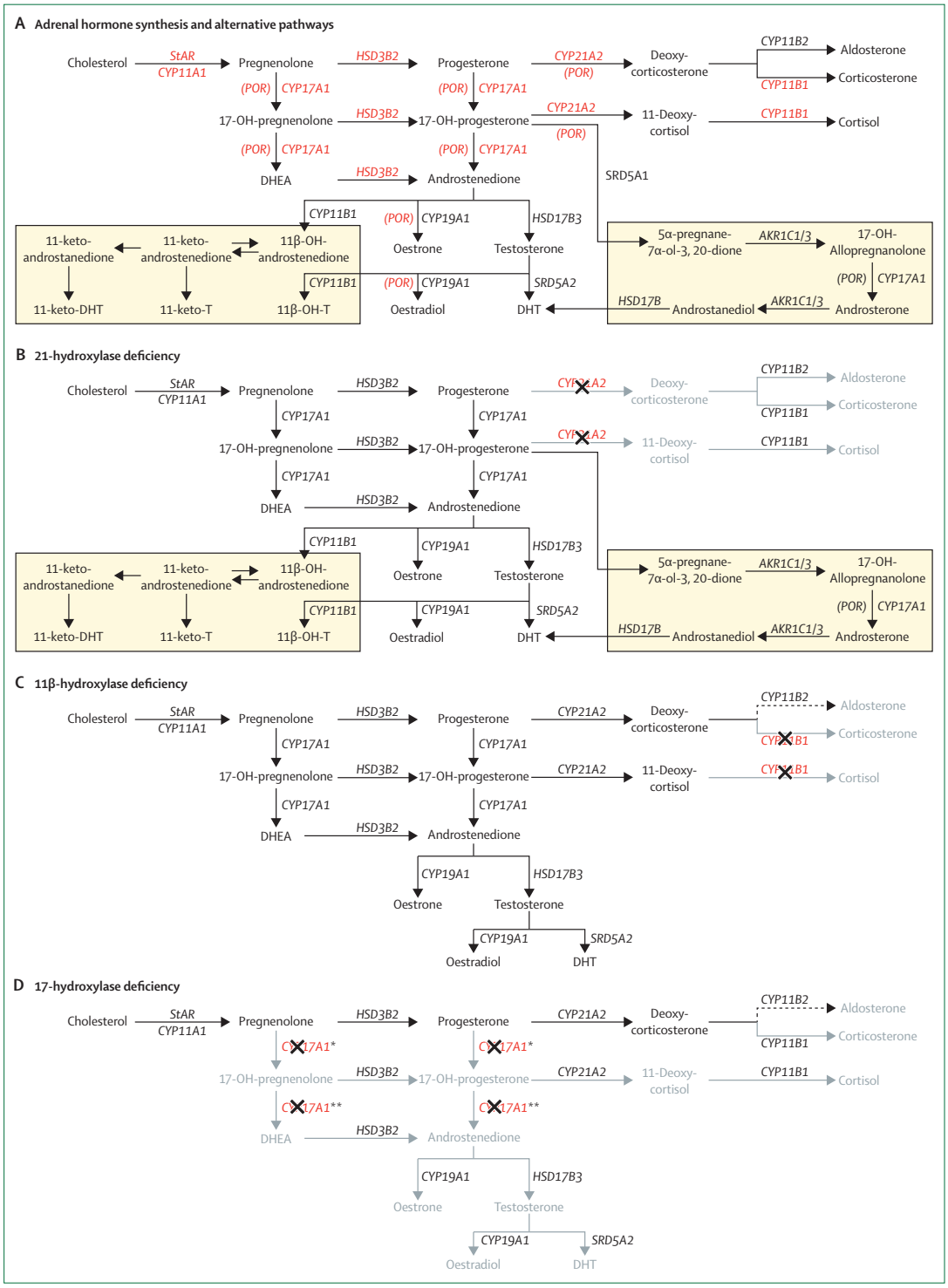

(Figure 2 continues on next page)

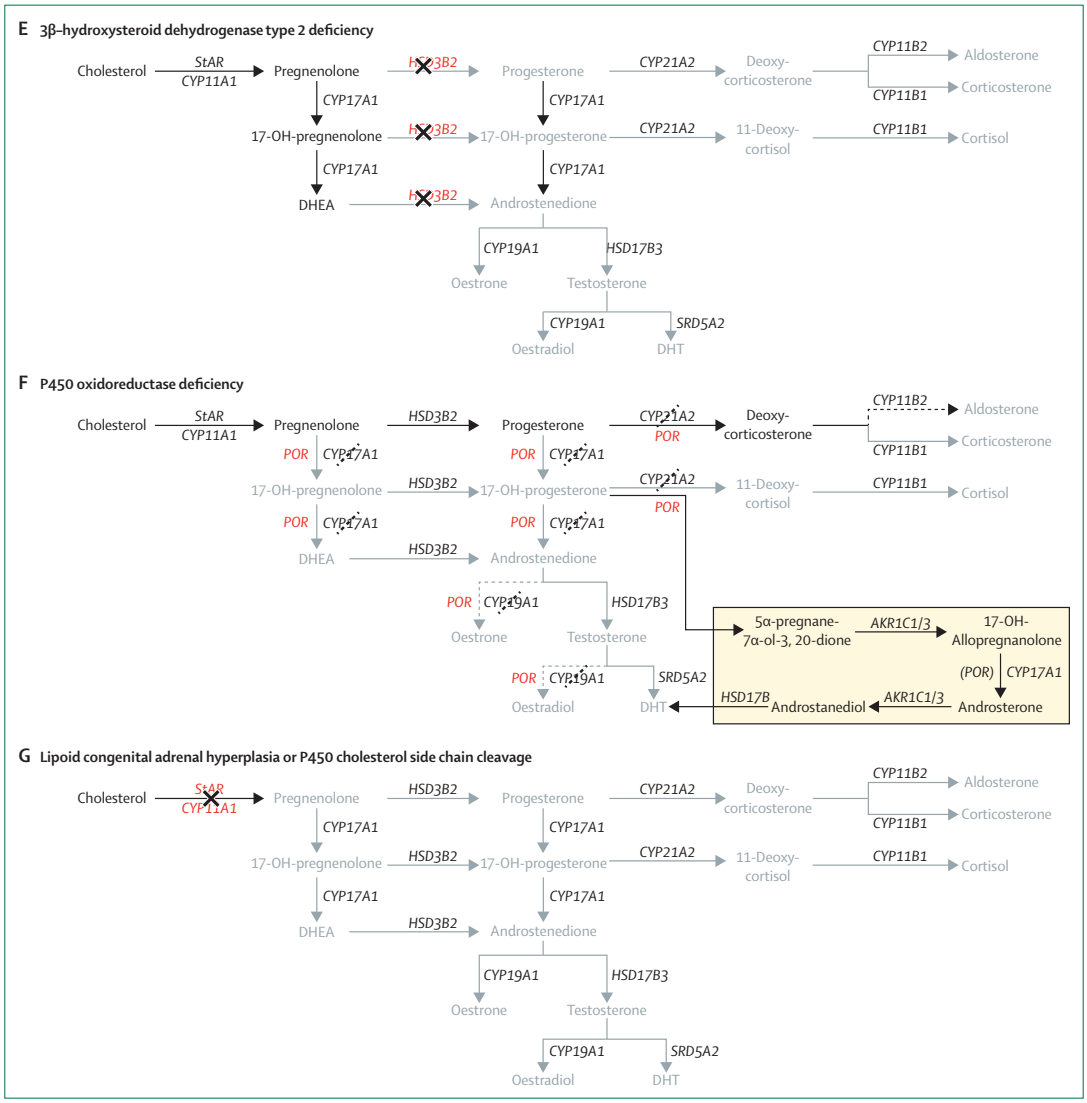

Figure 2: **Adrenal steroidogenesis pathways**

(A) Classic steroidogenesis pathway and alternative pathways leading to androgen production in the light yellow boxes. (B) 21-hydroxylase deficiency, (C) 11β-hydroxylase deficiency, (D) 17-hydroxylase deficiency, (E) 3β-hydroxysteroid dehydrogenase type 2 deficiency, (F) P450 oxidoreductase deficiency, and (G) lipoid congenital adrenal hyperplasia and P450 cholesterol side chain cleavage deficiency, with impact of specific impairments on the adrenal steroidogenic pathway. Genes in which mutations cause congenital adrenal hyperplasia are shown in red. Light grey denotes deficient hormones at low concentrations due to the preceding block in steroid production. Dashed arrows denote indirect suppression of the subsequent hormone. Dashed lines across enzymes denote apparent enzyme deficiency. DHEA=dehydroepiandrosterone. DHT=5α-dihydrotestosterone. T=testosterone. POR=P450 oxidoreductase.

renin–angiotensin system suppression might not occur in the neonatal period because of renal mineralocorticoid resistance that is present in the first few months of life. Clinically, patients with 11βOH deficiency present similarly to patients with 21OH deficiency with signs of androgen excess, but patients with 11βOH also have hypertension rather than salt loss (table 2).[32] A non-classic form of enzyme deficiency caused by *CYP11B1* mutations exists but is very rare.[45]

17OH deficiency

The *CYP17A1* gene encodes an enzyme that expresses both 17α-hydroxylase and 17,20-lyase activities (table 1). Because of the location of the enzyme in the steroidogenic pathway, severe mutations in the gene impair adrenal and gonadal sex steroid production (figure 2), which causes sexual infantilism and puberty failure (table 2).[35] Production of dehydroepiandrosterone is blocked, which prevents adrenarche and development of pubic and axillary hair.

Neurocrine EX1015
Page 4 of 17

	21-hydroxylase deficiency	11β-hydroxylase deficiency	17α-hydroxylase/ 17,20-lyase deficiency	3β-hydroxy-steroid dehydrogenase type 2 deficiency	P450 oxidoreductase deficiency	Lipoid adrenal hyperplasia	Cholesterol side chain cleavage enzyme deficiency
Affected gene (OMIM number)	*CYP21A2* (201910)	*CYP11B1* (202010)	*CYP17A1* (202110)	*HSD3B2* (201810)	*POR* (201750)	*StAR* (600617)	*CYP11A1* (118485)
Incidence	Classic: 1:10 000 to 1:20 000[25] Non-classic: 1:200[27] to 1:1000[26]	1:100 000[32] in Caucasians, 1:6000[33] in Moroccan Jews* Non-classic: unknown	1:50 000[34] Increased frequency in Brazil*[34,35]	Rare	Rare, 130 cases from 11 countries reported[36]	Rare, mostly Japanese, Korean, and Palestinian populations [37]	Rare, <30 patients, mostly from eastern Turkey[38]
Affected organs	Adrenal glands	Adrenal glands	Adrenal glands and gonads	Adrenal glands and gonads	Adrenal glands, gonads, liver, and skeletal	Adrenal glands and gonads	Adrenal glands and gonads
Disorder of sex development	Classic: 46,XX Non-classic: No	Classic: 46,XX Non-classic: No	46,XY	Classic: 46,XY, 46,XX (rare) Non-classic: No	46,XX, 46,XY (variable)	46,XY Non-classic: 46,XY (variable)	46,XY Non-classic: 46,XY (variable)
Salt wasting	Classic: Yes Non-classic: No	No	No	Yes	No	Classic: yes Non-classic: minimal to none	Classic: Yes Non-classic: minimal to none
Hypertension	No	Yes Non-classic: variable	Yes	No	Yes	No	No
Postnatal virilisation	Classic: yes Non-classic: yes	Classic: Yes Non-classic: Yes	No	Classic: 46,XX Non-classic: 46,XX	No	No	No
Sex steroid deficiency	No	No	Yes	Classic: Yes Non-classic: No	Yes	Yes Non-classic: variable	Yes Non-classic: variable
Other	..	..	..	..	With or without skeletal malformations With or without maternal virilisation	..	..

OMIM=Online Mendelian Inheritance in Man. POR=P450 oxidoreductase. StAR= steroidogenic acute regulatory protein. *Due to presence of a founder mutation.

Table 1: **Genetic causes and clinical features of the various forms of congenital adrenal hyperplasia**

CYP17A1 is expressed in the adrenal zona fasciculata and zona reticularis but not in the zona glomerulosa. Therefore, ACTH-mediated steroidogenesis results in elevated concentrations of deoxycorticosterone and corticosterone. High concentrations of deoxycorticosterone cause sodium retention, hypertension, and hypokalaemia, with suppression of aldosterone production. The presence of corticosterone, which has glucocorticoid activity, prevents patients from having an adrenal crisis, even though cortisol production is low or absent. Both 46,XX and 46,XY patients with 17OH deficiency have female external genitalia and usually present during puberty as girls without secondary sexual characteristics, with hypergonadotropic hypogonadism, and low-renin hypertension (table 2). Isolated 17,20-lyase-deficiency has been reported[46] but is extremely rare and in truly isolated forms is caused by mutations in cytochrome b5, the co-factor needed by CYP17A1 to exert 17,20 lyase activity.[47] Although phenotype variability occurs, a non-classic form with subtle clinical manifestations has not been defined.

3βHSD2 deficiency

3β-hydroxysteroid dehydrogenase exists in two isoforms, type 1 (3βHSD1) and type 2 (3βHSD2), which are encoded by *HSD3B1* and *HSD3B2* genes, respectively (table 1). The *HSD3B2* gene is highly expressed in the adrenals and gonads, while *HSD3B1* is expressed in the placenta and peripheral tissues.

Impaired 3βHSD2 functionality results in decreased concentrations of aldosterone, cortisol, and androstenedione, with a subsequent increase in the concentrations of renin, ACTH, and dehydroepiandrosterone (figure 2). Dehydroepiandrosterone can be converted to testosterone by extra-adrenal 3βHSD1. Patients present in infancy with a salt-wasting adrenal crisis, underdeveloped 46,XY genitalia, and rarely 46,XX virilisation (table 2).[48]

The hormonal criteria for diagnosis of 3βHSD2 deficiency have changed over the past three decades because the initial studies identifying a possible non-classic form were not based on genetic findings and subsequent genetic studies failed to confirm the diagnosis.[49–51] Non-classic 3βHSD2 deficiency exists, but is extremely rare.

POR deficiency

POR plays a key role in electron transport in the endoplasmic reticulum, and several enzymes including 17OH, 21OH, and aromatase depend on POR for their catalytic activity (figure 2). The discovery of POR deficiency, in 2004,[16,17] provided an explanation for multiple hormonal deficiency, initially known as apparent combined 17OH and 21OH deficiency. Insufficient placental aromatisation of fetal androgens could contribute to the virilisation seen in some mothers carrying babies affected by POR deficiency. However, the

Neurocrine EX1015
Page 5 of 17

	Clinical presentation	Hormonal profile	Cosyntropin stimulation testing*	Other testing
21-hydroxylase deficiency	Classic: atypical genitalia (46,XX), neonatal salt wasting (75%), and virilisation <4 year old (46,XY) Non-classic: precocious pubarche, hirsutism, oligomenorrhea/amenorrhea, and female infertility	↑ 17OHP, 21-deoxycortisol, androstenedione, and renin ↓ Cortisol and aldosterone	17OHP >30 nmol/L (>1000 ng/dL) (several times higher for classic)	Non-classic: early morning follicular phase 17OHP<6 nmol/L (<200 ng/dL) usually excludes non-classic congenital adrenal hyperplasia
11β-hydroxylase deficiency	Classic: atypical genitalia (46,XX), virilisation <4 years old (46,XY), hypertension, and hypokalaemia Non-classic: precocious pubarche, hirsutism, oligomenorrhea/amenorrhea, female infertility, and with or without hypertension	↑ DOC, 11-deoxycortisol, androstenedione and 17OHP (mild) ↓ Cortisol, aldosterone, corticosterone, and renin	11-deoxycortisol >3 times the upper limit of normal (several times higher for classic)	..
17α-hydroxylase/ 17,20-lyase deficiency	Adolescent female with absence of secondary sexual characteristics, hypertension, and hypokalaemia	↑ DOC, corticosterone (>115 nmol/L, 4000 ng/dL), and progesterone ↓ Cortisol, aldosterone, 17-hydroxypregnenolone, 17OHP, renin, DHEA, and androstenedione	Poor response of 17-hydroxypregnenolone and 17OHP Elevated ratios of DOC to cortisol and corticosterone to sex steroids	..
3β-hydroxysteroid dehydrogenase type 2 deficiency	Atypical genitalia (46,XX: rare, mild; 46,XY), neonatal salt wasting Non-classic: precocious pubarche, hirsutism, and oligomenorrhea/ amenorrhea (46,XX); atypical genitalia (46,XY; mild)	↑ 17-hydroxypregnenolone, DHEA, and renin ↓ Cortisol, aldosterone, progesterone, 17OHP, androstenedione, DOC, and 11-deoxycortisol	17-hydroxypregnenolone >150 nmol/L (5000 ng/dL) Elevated ratios pregnenolone to progesterone and 17-hydroxypregnenolone to 17OHP	Poor testosterone response hCG stimulation in infancy
P450 oxidoreductase deficiency	Atypical genitalia, with or without skeletal manifestation (Antley-Bixler), and with or without maternal virilisation	↑ Pregnenolone, progesterone, 17OHP, DOC, and corticosterone ↓ DHEA and androstenedione Variable (normal or low): cortisol, aldosterone	Variable 17OHP response, variable cortisol response (often inadequate)	Urine steroid metabolite profile shows characteristic diagnostic profile
Lipoid adrenal hyperplasia or SCC enzyme deficiency	Classic: female genitalia, neonatal salt wasting Non-classic: adrenal insufficiency (2 years to adulthood), variable gonadal function, variable genitalia (46,XY: mild)	↑ Renin ↓ All steroids Non-classic: variable	Minimal to no response Non-classic: variable response, ↓cortisol common	Classic: minimal response hCG stimulation Genetic testing needed to differentiate lipoid congenital adrenal hyperplasia and SCC deficiency

17OHP=17-hydroxyprogesterone. DHEA=dehydroepiandrosterone. DOC=deoxycorticosterone. hCG=human chorionic gonadotropin. SCC=side chain cleavage. *Administration of standard dose of 250 μg cosyntropin (in very low birthweight infants the dose may be reduced to 0·125 μg), concomitant measurement of 17OHP, cortisol, DOC, 11-DOC, 17-hydroxypregnenelone, DHEA, and androstenedione at baseline and 60 min to distinguish 21-hydroxylase deficiency from other rarer forms of congenital adrenal hyperplasia.

Table 2: **Clinical presentation and biochemical findings**

production of androgens via an alternative pathway to the one that produces the most potent androgen, non-aromatisable 5α-dihydrotestosterone, might also explain the prenatal virilisation of female patients affected by POR deficiency, while affected individuals have postnatal sex steroid deficiency.[17] POR also acts as an electron donor to cytochrome P450 (CYP) enzymes other than steroidogenic CYP enzymes, which explains POR deficiency-associated changes in drug metabolism[52] and the pathogenesis of skeletal dysplasia, which is often seen in patients.[53]

Most *POR* mutations retain some enzymatic function; homozygous mutations with complete loss of function might not be viable, as seen in rodent models.[54] Presentation of patients with *POR* mutations varies from mildly affected women with amenorrhea and polycystic ovaries or men with androgen deficiency, to severe hormone disturbances causing atypical genitalia in both 46,XX and 46,XY patients (table 1, 2). 46,XX virilisation does not progress, and patients postnatally have sex steroid deficiency. Craniosynostosis, radioulnar or radiohumeral synostosis, midface hypoplasia, and other skeletal manifestations that resemble the Antley-Bixler syndrome can occur.[16]

Generally, patients with POR deficiency do not have mineralocorticoid deficiency as impairment of 17α-hydroxylase increases production of mineralocorticoid intermediates, and affected adults can develop hypertension.[16,36] Patients have variable cortisol responses to cosyntropin testing, with most patients requiring either permanent or stress dose glucocorticoid coverage.[36]

Lipoid congenital adrenal hyperplasia

Classic lipoid congenital adrenal hyperplasia is characterised by deficiency of all steroid hormones and is due to *StAR* mutations (table 1, figure 2). StAR regulates the transfer of cholesterol from the outer to inner mitochondrial membrane, a key step in the initiation of steroidogenesis. When cholesterol cannot be mobilised, adrenal lipid droplets accumulate and are seen on autopsy, hence the name lipoid congenital

Neurocrine EX1015
Page 6 of 17

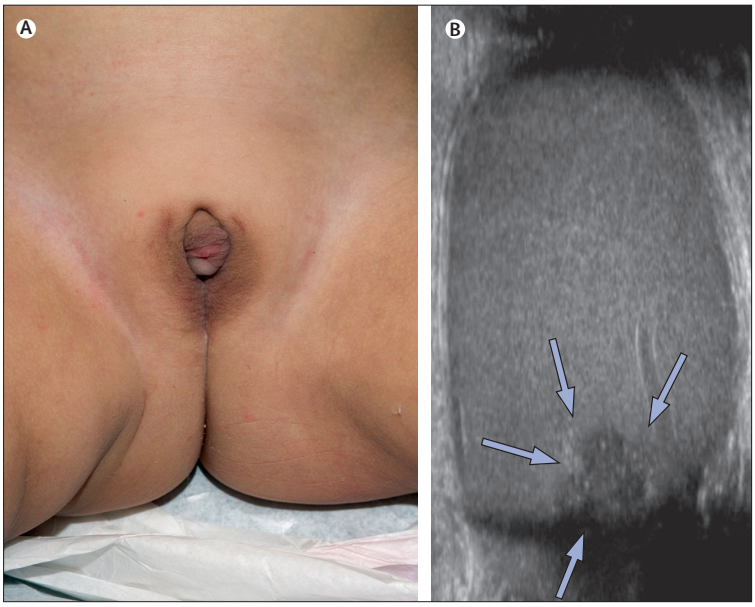

Figure 3: **Adverse outcomes in congenital adrenal hyperplasia**
(A) Atypical genitalia with clitoromegaly and posterior labial fusion of a 46,XX infant with 21-hydroxylase deficiency. (B) A right sided, lobulated echopenic focus measuring 2·7 × 1·0 x 1·1 cm, consistent with testicular adrenal rest tissue.

adrenal hyperplasia. The lipoid form is one of rarest forms of congenital adrenal hyperplasia and results in neonatal crisis and female external genitalia in both 46,XX and 46,XY infants (table 2).[55] Later presentation of lipoid congenital adrenal hyperplasia up to 1 year of age has been described.[56]

The pathogenesis of lipoid congenital adrenal hyperplasia is explained by a two-hit model: the first hit arises from the loss of StAR production, which leads to accumulation of intracellular cholesterol and cholesterol esters, and the second hit arises from destruction of cellular function by accumulated products.[55,57,58] This two-hit mechanism explains some unusual phenotypes. Spontaneous puberty has been described in 46,XX patients, caused by minimal ovarian *StAR* expression.[55] The ovaries are quiescent during fetal life and childhood and therefore toxic accumulation of cholesterol can be delayed until adolescence.

A non-classic form of lipoid congenital adrenal hyperplasia was first described in 2006,[59] and was associated with mutations that retain approximately 20–30% of StAR activity. Most of these cases were initially misdiagnosed as Addison's disease or isolated familial glucocorticoid deficiency.[60] Patients with non-classic lipoid congenital adrenal hyperplasia can present early as toddlers or later up to adulthood, with insidious onset of glucocorticoid deficiency, hyperpigmentation, and high ACTH concentrations (but mostly intact mineralocorticoid function). Wide variation in gonadal function has been reported, ranging from hypergonadotropic hypogonadism to normal gonadal function.[55] Similarly, 46,XY patients with non-classic lipoid congenital adrenal hyperplasia might have normal male genitalia and undergo normal puberty, or be born with atypical genitalia.[61]

SCC deficiency

SCC is involved in the first and rate-limiting step in the steroidogenic pathway (figure 2), encoded by *CYP11A1* (table 1), and is clinically and biochemically identical to lipoid congenital adrenal hyperplasia (table 2); however, patients typically have atrophic adrenals and gonads.[55] Less than 40 cases of SCC deficiency have been reported.

Similar to non-classic lipoid congenital adrenal hyperplasia, non-classic SCC deficiency has been described with delayed adrenal insufficiency onset and variable gonadal effect, caused by mutations that correspond to 7–30% of retained enzyme activity.[62–65]

Since StAR and SCC deficiency are similar clinically and biochemically, DNA testing is the only definitive method to distinguish between the two, with StAR deficiency being more common.

Diagnosis

Neonatal screening for 21OH deficiency is done via measurement of 17OHP concentration in dried blood spots on filter paper. Second-tier screening with liquid chromatography-mass spectrometry/mass spectrometry (LC-MS/MS) can efficiently measure a panel of steroids. LC-MS/MS has been used to successfully diagnose 11βOH deficiency,[66] but the focus of neonatal screening remains detection of 21OH deficiency. Premature, stressed, or ill infants could have falsely elevated 17OHP concentrations; the specificity of diagnosis is improved with gestational age stratification.[67] Tests that make use of 21-deoxycortisol, which is elevated in 21OH deficiency, might increase neonatal screening specificity.[68]

If an infant tests positive for 21OH deficiency in a neonatal screen or is clinically suspected of having congenital adrenal hyperplasia (ie, ambiguous genitalia), confirmatory testing is indicated. Although a baseline panel of LC-MS/MS steroids can be diagnostic for 21OH deficiency, its diagnosis often requires cosyntropin testing[23,69] and is based on a characteristic rise in adrenal hormones preceding the enzymatic blockage (table 2). The fact that 17OHP concentration might be elevated in other types of congenital adrenal hyperplasia, such as 11βOH or POR deficiency, should also be considered. An alternative approach to serum steroid analysis is urinary steroid profiling, which captures the entire steroid metabolome.[70] Additional tests and genotyping might be needed to confirm the diagnosis.

21OH deficiency screening after infancy relies on the measurement of early morning (before 0800 h) 17OHP concentration. A 17OHP concentration above 30 nmol/L (1000 ng/dL) is diagnostic for 21OH deficiency, although a random concentration of 303 nmol/L

Neurocrine EX1015
Page 7 of 17

(10 000 ng/dL) or greater is commonly observed in the classic form (table 2).[23] A 17OHP concentration of less than 6 nmol/L (200 ng/dL) usually excludes non-classic congenital adrenal hyperplasia if 17OHP is measured during the follicular phase of a reproductive-age woman.[71] Cosyntropin stimulation testing is often needed for diagnosis of the non-classic form.

The diagnosis of POR deficiency can be best made with a urinary steroid profile which reveals characteristic precursor accumulation that can be captured by steroid ratios,[36] whereas serum steroid analysis often yields confusing results because of the overlapping effects of combined 17OH and 21OH deficiency. Further criteria for urinary and serum metabolites have been suggested to diagnose POR deficiency prenatally or differentiate POR deficiency from 21OH deficiency.[72,73]

Management of congenital adrenal hyperplasia

Medical treatment

Glucocorticoid therapy

The mainstay of treatment in the classic forms of congenital adrenal hyperplasia is chronic glucocorticoid therapy (panel). Because of their growth-suppressing effect, long-acting glucocorticoid treatment is avoided in children, but is sometimes used in adults.[75] The goal of glucocorticoid therapy is to optimise control of excess hormones, replace deficient hormones, and avoid potential Cushingoid side-effects. Laboratory results should guide but not define management; clinical evaluation should always be considered.

In general, higher doses of glucocorticoids are needed to achieve adequate suppression of hormone excess (ie, androgens in the virilising forms of congenital

Panel: Management of congenital adrenal hyperplasia

Glucocorticoid replacement

- Needed in classic forms of congenital adrenal hyperplasia, variable use in non-classic forms and P450 oxidoreductase deficiency
- Children: hydrocortisone (8–15 mg/m² per day) divided into three doses where the lowest dose is used to allow normal growth while controlling adrenal steroids[23,74]
- Adolescents and adults: hydrocortisone 2–3 times daily or longer-acting[23,74] glucocorticoids, such as prednisone (5·0–7·5 mg per day; one or two times daily), prednisolone (3–7 mg per day; one or two times daily), or dexamethasone (0·25–0·5 mg per day; once daily)
- Monitor for over-replacement: weight gain, central obesity, striae, stunted growth (children), decline in bone mineral density
- Monitor for under-replacement: weight loss, fatigue, hyperandrogenism (21-hydroxylase [21OH] and 11β-hydroxylase [11βOH] deficiency), hypertension (11βOH, 17-hydroxylase [17OH] deficiency, and in adult patients with P450 oxidoreductase [POR] deficiency)
- In women, monitor for cycle regulation and, if appropriate, anovulation
- In males, monitor for testicular adrenal rest tissue (TART) using testicular ultrasound from adolescence onward; if positive, then offer sperm count and motility assessment and counsel regarding the possibility of cryopreservation of semen

Stress dosing

- Needed if patient receiving glucocorticoid therapy or cortisol response to cosyntropin stimulation <500 nmol/L (18 mg/dL)[23,74]
- Double or triple glucocorticoid dose during intercurrent illness (fever, gastrointestinal illness), surgery, or trauma
- Intramuscular or subcutaneous hydrocortisone if unable to take oral glucocorticoid (home regimen). Children 50 mg/m²; adults 100 mg intravenous bolus followed by 200 mg over 24 h (hospital regimen)[74]

Mineralocorticoid replacement

- Needed in salt-wasting forms of congenital adrenal hyperplasia
- Fludrocortisone 50–200 μg daily to achieve a plasma renin activity in the mid–normal range[23,74]
- First 6–12 months of life: sodium chloride 1–2 g (17–34 mmol/L) daily, divided and given with feeds[23]
- Monitor for over-replacement: hypertension, oedema, and suppressed plasma renin activity
- Monitor for under-replacement: salt-craving, orthostatic hypotension, and elevated plasma renin activity
- Encourage salt intake during hot weather and conditions that promote excessive sweating. Consider seasonal adjustment of fludrocortisone dose in countries with very hot summers

Sex steroid replacement

- Needed in forms of congenital adrenal hyperplasia that result in sex steroid deficiency
- For pubertal females, oral oestradiol (0·5 mg per day advanced to 1–2 mg per day); or transdermal (25 μg per day advanced to 75–100 μg per day) over 2–3 years; progesterone added following 2 years of oestrogen monotherapy or when breakthrough bleeding occurs, 100–200 mg per day, or medroxyprogesterone acetate 5–10 mg per day, or norethindrone acetate 2·5–5 mg per day, for 5–10 days, in women with intact uterus[35]
- For pubertal males, intramuscular testosterone (50 mg per month titrated to about 200 every 2 weeks) or transdermal testosterone (titrated to 25–100 g per day)[35] is indicated

Anti-hypertensive treatment

- Needed if glucocorticoid unsuccessful in treatment of hypertension in 11βOH and 17OH deficiency
- Spironolactone 50–200 mg per day in one or two divided doses or eplerenone 50–100 mg per day

(Panel continues on next page)

Neurocrine EX1015
Page 8 of 17

(Panel continued from previous page)

- Calcium-channel blockers, such as amlodipine, 2·5–10 mg per day, can be used

Anti-androgen treatment

- Oral contraceptives with or without spironolactone to control hirsutism, and amenorrhea in non-classic 21OH and 11βOH deficiency

Infertility

- Initiate glucocorticoid for non-classic forms 21OH and 11βOH deficiency
- Optimise glucocorticoid therapy with suppression of follicular phase progesterone (females) and shrinkage of TART (males) for 21OH and 11βOH deficiency
- Clomiphene citrate stimulation with progesterone supplementation for hypogonadal forms of congenital adrenal hyperplasia
- Consider in-vitro fertilisation (females) or intra-cytoplasmic sperm injection (males)

Pregnancy

- If patients are on glucocorticoid therapy, hydrocortisone, prednisone, or prednisolone can be used— dexamethasone should be avoided
- Increase glucocorticoid dose by 20–40%, particularly during third trimester[74]
- Stress dosing for labour and delivery

Additional monitoring requirements

- Clinical evaluation frequently in first year of life, every 4–6 months for growing child and yearly for adults
- Patients on glucocorticoid replacement should wear an emergency bracelet or card, receive sick day rule education, and carry an emergency hydrocortisone kit
- Screening for psychological and sexual health issues and late-onset complications of genital surgery, if indicated
- Age-appropriate vitamin D and calcium intake and bone mineral density screening during early adulthood
- Orthopaedic management may be needed for POR deficiency

adrenal hyperplasia, classic 21OH and 11βOH, or deoxycorticosterone in 17OH deficiency), than doses of glucocorticoids given for replacement purposes when all all steroids are deficient. Low glucocorticoid doses can also be used in the non-classic forms of congenital adrenal hyperplasia, if treatment is indicated.[76]

For women planning to conceive, a glucocorticoid that does not reach the fetus and is inactivated by placental 11βHSD2, such as prednisone, prednisolone, or hydrocortisone, is typically used and continued throughout pregnancy.[23]

Patients with non-classic congenital adrenal hyperplasia are treated according to their symptoms. Children with non-classic 21OH deficiency should be treated if they have progressive signs and symptoms of virilisation with advanced skeletal maturation. Women with non-classic congenital adrenal hyperplasia with signs of androgen excess can often be successfully treated with oral contraceptives, and if needed, in combination with spironolactone. Glucocorticoid therapy is used for female infertility in non-classic 21OH deficiency. Furthermore, a reduction in miscarriage rate has been reported when glucocorticoids are taken throughout pregnancy.[77,78]

Mineralocorticoid replacement

Mineralocorticoid, in the form of fludrocortisone, is given to achieve a plasma renin activity in the healthy range in salt-wasting forms of congenital adrenal hyperplasia (panel).[23] Mineralocorticoid dose is independent of body surface area, although higher doses are usually needed during the first 6 months of life because of neonatal physiological mineralocorticoid resistance.[79] Infants during the first year of life also require salt supplementation. Although patients with simple virilising 21OH deficiency have some aldosterone production, relative aldosterone insufficiency exists and fludrocortisone is recommended because it allows for glucocorticoid reduction, which leads to improved height outcomes.[80]

Glucocorticoid stress dosing

Patients receiving glucocorticoid treatment, including those with non-classic congenital adrenal hyperplasia, need to be educated on adrenal crisis prevention and the necessity of increasing glucocorticoid dose during intercurrent illness (panel). Intramuscular, subcutaneous, or intravenous hydrocortisone should be given to patients when oral intake is not possible, and stress dose management is identical to that recommended in primary adrenal insufficiency.[74] Patients with classic 21OH deficiency also have epinephrine deficiency, due to abnormal adrenomedullary formation;[81] this places patients at risk for hypoglycaemia, especially when fasting, or during acute illness. Adrenomedullary function has not been studied in the rarer forms of congenital adrenal hyperplasia.

Patients with non-classic congenital adrenal hyperplasia can have suboptimal cortisol response on cosyntropin stimulation testing (<18 μg/dL of cortisol). If patients are

Neurocrine EX1015
Page 9 of 17

asymptomatic, daily glucocorticoid use is not indicated, but glucocorticoid stress coverage should be used during serious illness or major surgery.[74]

Sex steroids

Sex steroid replacement is initiated around the time of physiological puberty in patients with 17OH deficiency,[35] 3βHSD2 deficiency,[48] lipoid congenital adrenal hyperplasia, SCC deficiency,[55] or POR deficiency[82] (as needed). Replacement of androgen (in men) and oestrogen (in women), with progestin to induce cyclical bleeding (if uterus is present), are advanced slowly to adult regimens (panel).

Anti-hypertensives

In both 11βOH and 17OH deficiency, glucocorticoid therapy is often sufficient to control hypertension by suppressing deoxycorticosterone. However, because high dose glucocorticoid therapy and complete suppression of the hypothalamic-pituitary-adrenal axis should be avoided, deoxycorticosterone is not fully suppressed and many patients eventually become hypertensive. In such cases, a mineralocorticoid receptor antagonist or calcium channel blocker can be used to treat hypertension (panel).[35,83]

Controversial therapies

Genital surgery

Genital surgery for patients with disorders of sex development is a complex issue that has generated much controversy. Historically, surgeons have recommended surgery on the basis of genital appearance and fertility potential. In the past two decades, some advocacy groups and physicians have recommended delaying surgery so that patients can participate in the decision regarding surgical intervention. Conversely, others have expressed concern about the puacity of outcome data and psychosocial stress resulting from not doing early surgery.[84] Most importantly, the patient's family should always be educated on the advantages and disadvantages of having and not having surgery. An interdisciplinary team of specialists is often required to navigate the decision-making process.[85]

An international group of experts, appointed by the Endocrine Society to develop clinical practice guidelines for congenital adrenal hyperplasia due to 21OH deficiency, concluded that surgery should be considered for considerably virilised 46,XX patients.[23] The timing of surgery is beyond the scope of this Seminar but options include a one-stage approach—ie, simultaneous neurovascular-sparing clitoroplasty, labioplasty, and vaginoplasty—done in infancy (the standard option in many countries including the USA and UK)[23,86,87] or delayed until puberty, or a two-stage approach with labioplasty and clitoroplasty done in infancy and vaginoplasty delayed until puberty.[86,87] Most patients with congenital adrenal hyperplasia caused by 21OH deficiency prefer early surgery.[88] Although in-utero exposure to androgens has been shown to affect behaviour, with male typical behaviour patterns commonly seen in 46,XX patients with classic congenital adrenal hyperplasia, gender dysphoria is extremely rare and the recommended sex assignment of 46,XX patients with disorders of sex development due to congenital adrenal hyperplasia is female.[85]

The main challenge of surgery for the 46,XX virilised patient with congenital adrenal hyperplasia is the imperfect functional and cosmetic outcomes, including urinary incontinence, vaginal stenosis, and clitoral pain, all of which can affect psychosocial and sexual wellbeing.[86] Many of the new surgical approaches have not existed for long enough to assess outcomes. Patients should be referred to a specialist surgeon with experience managing disorders of sex development.

Surgical reconstruction of 46,XY atypical genitals is complex. Chordee repair and surgery for distal hypospadias have high success rates,[87] but proximal hypospadias repair is more challenging, with higher complication and reoperation rates than distal hypospadias repair. The main complications are urethral stricture, meatal stenosis, urethrocutaneous fistula, and glans wings separation.[87]

Early gonadal neoplastic changes were observed histologically as early as 1 year of age in a 46,XY patient with classic lipoid congenital adrenal hyperplasia.[89] Gonadectomy is recommended in 46,XY patients raised as female who are severely affected, although the risk of gonadal malignancy is unknown.

Prenatal treatment

For over 30 years dexamethasone was offered to pregnant women at risk of having a child with classic virilising congenital adrenal hyperplasia, which aimed to suppress fetal androgen production and reduce virilisation of females affected by congenital adrenal hyperplasia.[90] Dexamethasone, unlike hydrocortisone and prednisolone, crosses the placental barrier to the fetus without inactivation. Prenatal therapy is controversial because only one in eight fetuses will be female with congenital adrenal hyperplasia when both parents are carriers. Long-term effects of in-utero dexamethasone exposure are unknown, and potential effects on the brain, behaviour, and cognition of fetuses have been described.[91–94]

Testing of fetal cells present in maternal circulation for congenital adrenal hyperplasia is being studied to avoid 46,XY treatment and initiate early treatment in affected 46,XX patients.[95] Cell-free fetal DNA obtained from mother's plasma as early as 5 weeks gestation has correctly identified fetal congenital adrenal hyperplasia status in 14 families.[96] Multiple international groups, including medical societies in the USA and Europe, have stated that prenatal therapy should only be considered in a research setting with full disclosure of potential risks and benefits.[23,97] Long-term effects of prenatal dexamethasone

Neurocrine EX1015
Page 10 of 17

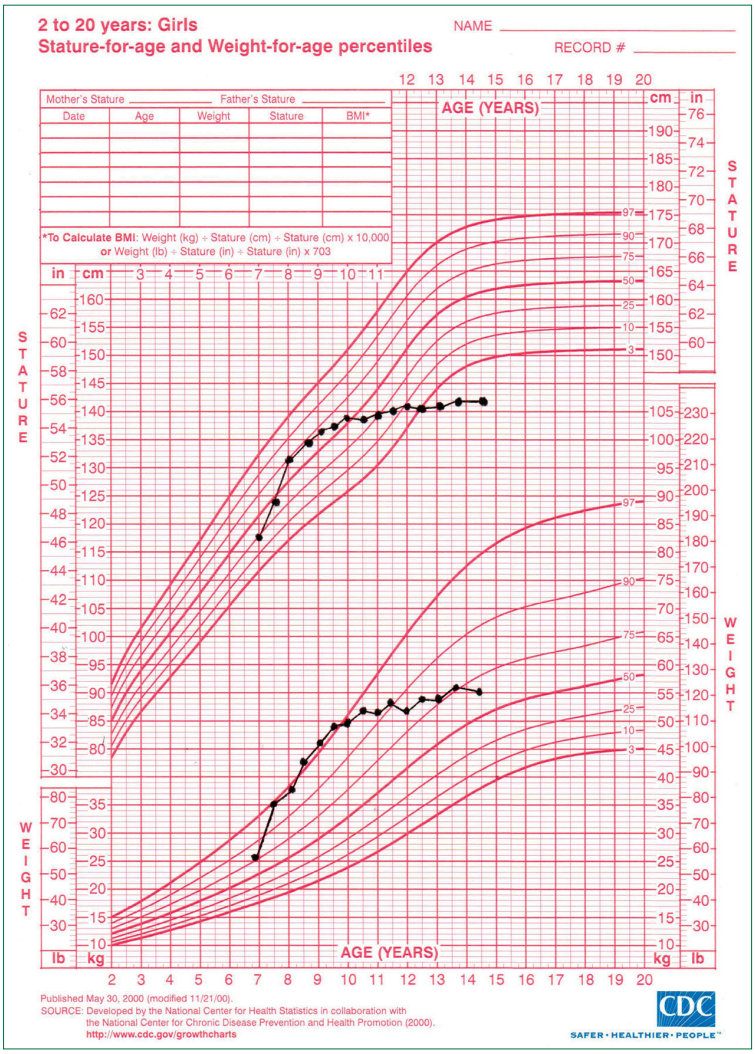

Figure 4: **Growth chart of a female patient with classic 21-hydroxylase deficiency**
The patient experienced early puberty and epiphyseal fusion of her bones due to excess adrenal sex steroids, and obesity due to excess glucocorticoid therapy. Both probably contributed to her adult short stature.

exposure requires further study but early non-invasive fetal DNA testing would potentially restrict exposure to female fetuses affected by congenital adrenal hyperplasia.

Bilateral adrenalectomy

Bilateral adrenalectomy has been used successfully to treat female infertility with uncontrolled hyperandrogenism in patients with 21OH deficiency[98] and uncontrolled hypertension in patients with 11βOH deficiency.[99] Although follow-up of patients who have undergone an adrenalectomy is positive overall, these patients appear to be at increased risk of adrenal crisis and about a third develop adrenal rest tissue if their glucocorticoid dose is too low.[100] Adrenalectomy should only be considered in patients in whom all available medical interventions have failed.

Long-term complications

Glucocorticoid deficiency is characteristic of the severe forms of congenital adrenal hyperplasia and is potentially life threatening. In a study[101] in Sweden, 588 patients with congenital adrenal hyperplasia were compared with a national population-based registry, which revealed excess mortality in patients with congenital adrenal hyperplasia due to adrenal crises, highlighting the importance of this aspect of the disease. Results from a cross-sectional questionnaire-based study[102] of 122 patients with congenital adrenal hyperplasia showed that most adrenal crises occurred during infancy, with a second peak in crises occurring around late adolescence, and were precipitated mainly by respiratory and gastrointestinal infections.

All children with congenital adrenal hyperplasia who are receiving glucocorticoid therapy are at risk of growth impairment and short stature. The effect of glucocorticoids on growth is dose-dependent,[103] thus management always should aim to treat children with the lowest possible effective dose of glucocorticoids. Alterations in sex steroid exposure can also influence height. Late puberty can occur in patients with the rare types of congenital adrenal hyperplasia associated with sex steroid deficiency and can enhance adult height; conversely, exposure to excess androgens and oestrogens in the virilising types of congenital adrenal hyperplasia can result in early puberty and epiphyseal fusion (figure 4).[80] In a meta-analysis[80] of 35 studies of patients with classic 21OH deficiency, these patients had an average final height 1·38 standard deviations below the normal population range. Whereas studies[104,105] reveal an association between higher doses of hydrocortisone and shorter final patient height, earlier rather than later diagnosis and treatment of classic 21OH deficiency has been associated with improved height outcomes,[106] emphasising the importance of hyperandrogenism prevention.

Cardiovascular disease risk factors commonly coexist with congenital adrenal hyperplasia. In a cross-sectional study[107] of patients in the UK with classic 21OH deficiency, more than half of female patients were obese and a third had insulin resistance. In a cohort of 588 patients in Sweden with congenital adrenal hyperplasia, prevalence of hypertension, hyperlipidaemia, diabetes, and venous thromboembolism were higher than in controls.[108]

Long-term glucocorticoid exposure, particularly at the higher doses used to achieve tight control, is one of the main risk factors for compromised bone health. Data from studies over the past two decades show lower bone mass density in patients with 21OH deficiency than in control populations, with the prevalence of low bone mass density (osteoporosis or osteopenia) ranging from 37% to 81%,[107,109–111] and some studies[109,112] reporting an increased fracture rate.

Neurocrine EX1015
Page 11 of 17

Both male and female patients with the hypogonadal forms of congenital adrenal hyperplasia have infertility. However, one woman with classic lipoid congenital adrenal hyperplasia had a successful pregnancy with clomiphene citrate stimulation followed by progesterone supplementation.[113] In-vitro fertilisation and transfer of cryopreserved embryos has successfully resulted in a live birth in a patient with lipoid congenital adrenal hyperplasia and 17OH deficiency.[114,115] Patients with *POR*, *StAR*, and *CYP17A1* mutations might also have ovarian cysts and cyst torsion.[116–118]

In the virilising forms of congenital adrenal hyperplasia, excess adrenal sex steroids can lead to hypogonadotropic hypogonadism[119,120] and increased progesterone can interfere with endometrial implantation.[121,122] Optimising glucocorticoid management might resolve hypogonadotropic hypogonadism and endometrial implantation interference and suppression of follicular phase progesterone enhances the likelihood of ovulation and subsequent conception.[123,124]

A main cause of male infertility in patients with classic 21OH and 11βOH deficiency is presence of adrenal rest tissue. Adrenal rest tissue is thought to arise from aberrant cells of adrenocortical origin that migrate during fetal development along with the gonads after the adrenal and gonadal cells separate from the urogenital ridge.[125] Adrenal rest tissue is most commonly found in the rete testis (figure 3B) and has been described in the ovaries and broad ligament.[126,127] Testicular adrenal rest tissue (TART) causes obstructive azoospermia and deficient spermatogenesis.[125] Low inhibin B concentrations reflect the decline of Sertoli cell function and can be used to monitor it.[119] 44–94% of men[111,120,128,129] and 21–33% of boys[111,130] with classic 21OH deficiency have TART; which has also been reported in male patients with 11βOH and HSD3B2 deficiency,[131–133] and rarely in non-classic congenital adrenal hyperplasia.[128] TART shrinkage and reversal of infertility in patients is possible with glucocorticoid therapy;[134] however, therapy effectiveness is variable because non-reversible fibrotic changes can occur over time.[125]

When infertility reversal and TART shrinkage are unsuccessful, other treatment methods such as intracytoplasmic sperm injection could be considered.[135] Testis-preserving surgery with TART resection has not restored fertility in male patients with congenital adrenal hyperplasia,[136] but has been successful in patients with orchialgia where simultaneous intraoperative sperm retrieval was reported.[137]

Future directions

Alternative androgen synthesis pathways

The quest for new and improved biomarkers of disease severity or treatment response in congenital adrenal hyperplasia has included exploration of alternative androgen synthesis pathways. The so-called backdoor pathway leads to synthesis of 5α-dihydrotestosterone, without dehydroepiandrosterone, androstenedione, and testosterone as intermediates, originating directly from 17OHP (figure 2). This pathway has been implicated in the normal development of male genitalia[61] and the prenatal virilisation of female patients with congenital adrenal hyperplasia.[17] Accumulation of 17OHP, as observed in 21OH and POR deficiency, increases the substrate flow to the backdoor pathway and results from subsequent studies have shown increased alternative pathway metabolite excretion in patients with congenital adrenal hyperplasia due to POR[138] and 21OH deficiency.[139]

Another androgen synthesis pathway involves the generation of 11-oxygenated C19 steroids in the adrenal cortex via CYP11B1 activity (figure 2),[140] including 11-ketotestosterone and 11-keto-5α-dihydrotestosterone, which are androgens that bind and activate the androgen receptor.[141,142] 11-oxygenated C19 steroids are increased in congenital adrenal hyperplasia due to 21OH deficiency [143,144] and exaggerated activity of both backdoor and 11-oxygenated C19 pathways persists in treated patients, even if the activity of the classic androgen pathway activity is downregulated.[143] Insights into these novel steroid markers will help to improve monitoring tools and define treatment targets.

Genetic advances

Genetic studies of congenital adrenal hyperplasia have provided insight into the pathophysiology and subtle clinical aspects of the disease. Initially described in 1989,[145] the *TNXB* gene, which encodes tenascin-X—a glycoprotein expressed in connective tissue—and its highly homologous pseudogene *TNXA*, flank *CYP21A2* and its pseudogene *CYP21A1P*, respectively. The identification of chimeric genes that impair both the *CYP21A2* and *TNXB* genes, explained an unusual observed phenotype of connective tissue dysplasia, consistent with hypermobility-type Ehlers Danlos syndrome, in patients with 21OH deficiency.[146,147] This novel syndrome, congenital adrenal hyperplasia-X, was prevalent in 8·5 % of a cohort of 246 unrelated patients with 21OH deficiency.[148]

Apart from mutations in genes that cause congenital adrenal hyperplasia, other genes can modify steroid action, salt balance, or androgen sensitivity and affect phenotype.[149–151]

Genotyping is essential for confirming carrier state, and is useful for genetic counselling or establishing the diagnosis of a patient who cannot undergo accurate hormonal testing due to glucocorticoid therapy. Genotyping might one day help to predict future outcomes and be efficacious in screening programmes.[152]

Novel therapies

Most adverse outcomes in patients with congenital adrenal hyperplasia are attributable to hormonal imbalances or treatment-related comorbidities. Development of new and improved therapies that target different aspects of the pathophysiology of congenital adrenal hyperplasia is

Neurocrine EX1015
Page 12 of 17

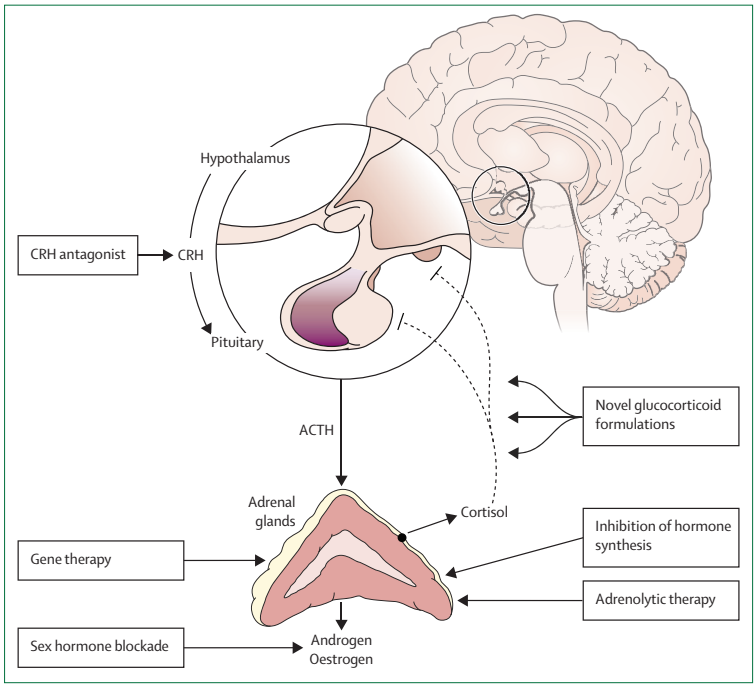

Figure 5: **Novel and emerging treatments for the management of congenital adrenal hyperplasia**
These approaches target various aspects of the hypothalamic-pituitary-adrenal axis and steroid production. CRH=corticotropin-releasing hormone. ACTH=adrenocorticotropic hormone.

ongoing (figure 5) and their efficacies for the treatment of classic 21OH deficiency are being studied.

One therapeutic approach is to replace cortisol in a physiological manner. Circadian cortisol replacement might achieve improved ACTH control and thus adrenal steroid secretion. A modified-release oral hydrocortisone preparation successfully lowered androgen levels in patients and decreased the hydrocortisone equivalent dose by use of a twice-daily regimen in a phase 2 study of 16 patients with classic 21OH deficiency.[153] A phase 3 study is currently underway (NCT02716818). Continuous subcutaneous hydrocortisone infusion via an insulin pump mimicking cortisol circadian rhythm, has similarly shown adequate ACTH suppression in patients with lower total hydrocortisone doses compared with conventional treatment,[152–155] and improved quality-of-life and decreased fatigue in eight patients with classic 21OH deficiency.[155] Long-standing comorbidities, such as insulin resistance and TART, remained mostly unchanged after 6 months, suggesting that early intervention is key and other approaches might be needed to treat well established comorbidities.

Because ACTH is the primary driver for excess steroid accumulation, strategies for reducing ACTH are being investigated. A phase 1 proof-of-principle study[156] with a corticotropin-releasing factor type 1 receptor antagonist, lowered morning ACTH or 17OHP concentrations in six of eight female participants with classic 21OH deficiency after a single dose. Future multidose trials are needed.

Pharmacological blockade or inhibition of sex steroid synthesis in prepubertal children or women receiving sex hormone replacement therapy would allow for lower dose glucocorticoid replacement in the virilising forms of congenital adrenal hyperplasia. This approach was studied in 28 prepubertal children with classic 21OH deficiency by use of an anti-androgen and aromatase inhibitor in combination with lower dose hydrocortisone and fludrocortisone, and was successful in normalising growth over 2 years.[157] Pharmacological inhibition of sex steroid synthesis was also tested in adult women with congenital adrenal hyperplasia receiving gonadal hormone replacement in a 6 day phase 1 dose-escalation study of abiraterone, a potent CYP17A1 inhibitor.[158] Promising results were reported when androstenedione concentrations normalised in five of six women after abiraterone was added to physiological doses of glucocorticoid and fludrocortisone.[158] Pharmacological inhibition of sex steroid synthesis is also being studied with an inhibitor of acyl-coenzyme A:cholesterol-O-acyltransferase 1 (NCT02804178) in a phase 2 study of classic 21OH deficiency.[159]

Adrenal enzyme inhibitors with adrenolytic properties might be useful in the treatment of congenital adrenal hyperplasia. Mitotane inhibits CYP11B1 and CYP11A1, and is adrenolytic with longer term use. Mitotane was successfully used to shrink TART and restore fertility in a 29-year-old man with classic 21OH deficiency.[160] However, due to the multiple toxic effects of mitotane, the development of alternative adrenolytic therapies is needed.

Congenital adrenal hyperplasia is a monogenic disease, so gene therapy with cell-based and gene-editing technologies might be able to restore defective steroidogenesis.[161] Adrenal transplantation with novel technology that uses bovine adrenocortical cells has been successful in animal models of adrenal insufficiency.[162] Future technological and genetic advances might enable a cure to congenital adrenal hyperplasia.

Conclusion

Congenital adrenal hyperplasia is a group of rare diseases that can result in high morbidity and mortality if left undiagnosed and untreated. The identification of alternative adrenal biomarkers has provided insight into the origin and synthesis of steroid production and has the potential to alter disease management. Decades of progress in understanding the genetics and pathophysiology of the various forms of congenital adrenal hyperplasia have led to a recent explosion in the investigation of new and improved therapies that promise to improve patient outcomes.

Contributors
DPM conceived the framework for the Seminar, wrote the Controversial therapies and Future directions sections, contributed to the writing and editing of all sections and figures, and coordinated oversight of the final manuscript. DE-M wrote the first versions of the manuscript, created the figures, and did most of the scientific literature searches. WA wrote the

Neurocrine EX1015
Page 13 of 17

Alternative androgen synthesis pathways section and contributed to the writing and editing of all sections and figures. All authors did several rounds of amendments and have seen and approved the final text.

Declaration of interests

WA reports licensing of a patent by Alta Biosciences, research grants from Diurnal and Millendo, scientific consultancy fees from Bayer AG, and a patent pending for a computational algorithm for rapid interpretation of steroid data pending. DPM received research funds from Diurnal and Millendo Therapeutics through the National Institutes of Health Cooperative Research and Development Agreement. DE-M declares no competing interests.

References

1 Delle Piane L, Rinaudo PF, Miller WL. 150 years of congenital adrenal hyperplasia: translation and commentary of De Crecchio's classic paper from 1865. *Endocrinology* 2015; **156:** 1210–17.

2 Raju TN. The Nobel chronicles. 1950: Edward Calvin Kendall (1886–1972); Philip Showalter Hench (1896–1965); and Tadeus Reichstein (1897–1996). *Lancet* 1999; **353:** 1370.

3 Eberlein WR, Bongiovanni AM. Partial characterization of urinary adrenocortical steroids in adrenal hyperplasia. *J Clin Invest* 1955; **34:** 1337–43.

4 Eberlein WR, Bongiovanni AM. Congenital adrenal hyperplasia with hypertension: unusual steroid pattern in blood and urine. *J Clin Endocrinol Metab* 1955; **15:** 1531–34.

5 Prader A, Anders GJ. On the genitics of congenital lipoid hyperplasia of the adrenals. *Helv Paediatr Acta* 1962; **17:** 285–89 (in German).

6 Bongiovanni AM. The adrenogenital syndrome with deficiency of 3β-hydroxysteroid dehydrogenase. *J Clin Invest* 1962; **41:** 2086–92.

7 Biglieri EG, Herron MA, Brust N. 17-hydroxylation deficiency in man. *J Clin Invest* 1966; **45:** 1946–54.

8 Pang S, Murphey W, Levine LS, et al. A pilot newborn screening for congenital adrenal hyperplasia in Alaska. *J Clin Endocrinol Metab* 1982; **55:** 413–20.

9 Peterson RE, Imperato-McGinley J, Gautier T, Shackleton C. Male pseudohermaphroditism due to multiple defects in steroid-biosynthetic microsomal mixed-function oxidases. A new variant of congenital adrenal hyperplasia. *N Eng J Med* 1985; **313:** 1182–91.

10 White PC, Grossberger D, Onufer BJ, et al. Two genes encoding steroid 21-hydroxylase are located near the genes encoding the fourth component of complement in man. *Proc Natl Acad Sci USA* 1985; **82:** 1089–93.

11 Kagimoto M, Winter JS, Kagimoto K, Simpson ER, Waterman MR. Structural characterization of normal and mutant human steroid 17 alpha-hydroxylase genes: molecular basis of one example of combined 17 alpha-hydroxylase/17,20 lyase deficiency. *Mol Endocrinol* 1988; **2:** 564–70.

12 White PC, Dupont J, New MI, Leiberman E, Hochberg Z, Rosler A. A mutation in CYP11B1 (Arg-448----His) associated with steroid 11 beta-hydroxylase deficiency in Jews of Moroccan origin. *J Clin Invest* 1991; **87:** 1664–67.

13 Rheaume E, Simard J, Morel Y, et al. Congenital adrenal hyperplasia due to point mutations in the type II 3 beta-hydroxysteroid dehydrogenase gene. *Nat Genet* 1992; **1:** 239–45.

14 Lin D, Sugawara T, Strauss JF 3rd, et al. Role of steroidogenic acute regulatory protein in adrenal and gonadal steroidogenesis. *Science* 1995; **267:** 1828–31.

15 Tajima T, Fujieda K, Kouda N, Nakae J, Miller WL. Heterozygous mutation in the cholesterol side chain cleavage enzyme (p450scc) gene in a patient with 46,XY sex reversal and adrenal insufficiency. *J Clin Endocrinol Metab* 2001; **86:** 3820–25.

16 Fluck CE, Tajima T, Pandey AV, et al. Mutant P450 oxidoreductase causes disordered steroidogenesis with and without Antley-Bixler syndrome. *Nat Genet* 2004; **36:** 228–30.

17 Arlt W, Walker EA, Draper N, et al. Congenital adrenal hyperplasia caused by mutant P450 oxidoreductase and human androgen synthesis: analytical study. *Lancet* 2004; **363:** 2128–35.

18 Bartter FC, Albright F, Forbes AP, Leaf A, Dempsey E, Carroll E. The effects of adrenocorticotropic hormone and cortisone in the adrenogenital syndrome associated with congenital adrenal hyperplasia: an attempt to explain and correct its disordered hormonal pattern. *J Clin Invest* 1951; **30:** 237–51.

19 Bongiovanni AM, Root AW. The adrenogenital syndrome. *N Eng J Med* 1963; **268:** 1283–89.

20 Bongiovanni AM, Root AW. The adrenogenital syndrome. *N Eng J Med* 1963; **268:** 1342–51.

21 Bongiovanni AM, Root AW. The adrenogenital syndrome. *N Eng J Med* 1963; **268:** 1391–99.

22 Wilkins L, Lewis RA, Klein R, et al. Treatment of congenital adrenal hyperplasia with cortisone. *J Clin Endocrinol Metab* 1951; **11:** 1–25.

23 Speiser PW, Azziz R, Baskin LS, et al. Congenital adrenal hyperplasia due to steroid 21-hydroxylase deficiency: an Endocrine Society clinical practice guideline. *J Clin Endocrinol Metab* 2010; **95:** 4133–60.

24 Coulm B, Coste J, Tardy V, et al. Efficiency of neonatal screening for congenital adrenal hyperplasia due to 21-hydroxylase deficiency in children born in mainland France between 1996 and 2003. *Arch Pediatr Adolesc Med* 2012; **166:** 113–20.

25 Therrell BL. Newborn screening for congenital adrenal hyperplasia. *Endocrinol Metab Clin North Am* 2001; **30:** 15–30.

26 New MI. Extensive clinical experience: nonclassical 21-hydroxylase deficiency. *J Clin Endocrinol Metab* 2006; **91:** 4205–14.

27 Hannah-Shmouni F, Morissette R, Sinai N, et al. Revisiting the prevalence of nonclassic congenital adrenal hyperplasia in US Ashkenazi Jews and Caucasians. *Genet Med* 2017; published online May 25. DOI:10.1038/gim.2017.46.

28 Finkielstain GP, Chen W, Mehta SP, et al. Comprehensive genetic analysis of 182 unrelated families with congenital adrenal hyperplasia due to 21-hydroxylase deficiency. *J Clin Endocrinol Metab* 2011; **96:** E161–72.

29 New MI, Abraham M, Gonzalez B, et al. Genotype-phenotype correlation in 1,507 families with congenital adrenal hyperplasia owing to 21-hydroxylase deficiency. *Proc Natl Acad Sci USA* 2013; **110:** 2611–16.

30 Fluck CE, Meyer-Boni M, Pandey AV, et al. Why boys will be boys: two pathways of fetal testicular androgen biosynthesis are needed for male sexual differentiation. *Am J Hum Genet* 2011; **89:** 201–18.

31 Miller WL, Auchus RJ. The molecular biology, biochemistry, and physiology of human steroidogenesis and its disorders. *Endocr Rev* 2011; **32:** 81–151.

32 White PC, Curnow KM, Pascoe L. Disorders of steroid 11 beta-hydroxylase isozymes. *Endocr Rev* 1994; **15:** 421–38.

33 Paperna T, Gershoni-Baruch R, Badarneh K, Kasinetz L, Hochberg Z. Mutations in CYP11B1 and congenital adrenal hyperplasia in Moroccan Jews. *J Clin Endocrinol Metab* 2005; **90:** 5463–65.

34 Costa-Santos M, Kater CE, Auchus RJ. Brazilian Congenital Adrenal Hyperplasia Multicenter Study G. Two prevalent CYP17 mutations and genotype-phenotype correlations in 24 Brazilian patients with 17-hydroxylase deficiency. *J Clin Endocrinol Metab* 2004; **89:** 49–60.

35 Auchus RJ. Steroid 17-hydroxylase and 17,20-lyase deficiencies, genetic and pharmacologic. *J Steroid Biochem Mol Biol* 2016; **165:** 71–78.

36 Krone N, Reisch N, Idkowiak J, et al. Genotype-phenotype analysis in congenital adrenal hyperplasia due to P450 oxidoreductase deficiency. *J Clin Endocrinol Metab* 2012; **97:** E257–67.

37 Bose HS, Sato S, Aisenberg J, Shalev SA, Matsuo N, Miller WL. Mutations in the steroidogenic acute regulatory protein (StAR) in six patients with congenital lipoid adrenal hyperplasia. *J Clin Endocrinol Metab* 2000; **85:** 3636–39.

38 Guran T, Buonocore F, Saka N, et al. Rare causes of primary adrenal insufficiency: genetic and clinical characterization of a large nationwide cohort. *J Clin Endocrinol Metab* 2016; **101:** 284–92.

39 White PC, Vitek A, Dupont B, New MI. Characterization of frequent deletions causing steroid 21-hydroxylase deficiency. *Proc Natl Acad Sci USA* 1988; **85:** 4436–40.

40 Speiser PW, White PC. Congenital adrenal hyperplasia. *N Engl J Med* 2003; **349:** 776–88.

41 Bidet M, Bellanne-Chantelot C, Galand-Portier MB, et al. Clinical and molecular characterization of a cohort of 161 unrelated women with nonclassical congenital adrenal hyperplasia due to 21-hydroxylase deficiency and 330 family members. *J Clin Endocrinol Metab* 2009; **94:** 1570–78.

Neurocrine EX1015
Page 14 of 17

42 Nandagopal R, Sinaii N, Avila NA, et al. Phenotypic profiling of parents with cryptic nonclassic congenital adrenal hyperplasia: findings in 145 unrelated families. *Eur J Endocrinol* 2011; **164:** 977–84.

43 Khattab A, Haider S, Kumar A, et al. Clinical, genetic, and structural basis of congenital adrenal hyperplasia due to 11beta-hydroxylase deficiency. *Proc Natl Acad Sci USA* 2017; **114:** E1933–40.

44 White PC. Congenital adrenal hyperplasia owing to 11beta-hydroxylase deficiency. *Adv Exp Med Biol* 2011; **707:** 7–8.

45 Reisch N, Hogler W, Parajes S, et al. A diagnosis not to be missed: nonclassic steroid 11beta-hydroxylase deficiency presenting with premature adrenarche and hirsutism. *J Clin Endocrinol Metab* 2013; **98:** E1620–25.

46 Geller DH, Auchus RJ, Mendonca BB, Miller WL. The genetic and functional basis of isolated 17,20-lyase deficiency. *Nat Genet* 1997; **17:** 201–05.

47 Idkowiak J, Randell T, Dhir V, et al. A missense mutation in the human cytochrome b5 gene causes 46,XY disorder of sex development due to true isolated 17,20 lyase deficiency. *J Clin Endocrinol Metab* 2012; **97:** E465–75.

48 Morel Y, Roucher F, Plotto I, Simard J, Coll M. 3B-hydroxysteroid dehydrogenase deficiency. In: New M, Lekarev O, Parsa A, O'Malley B, Hammer GD, eds. Genetic steroid disorders. Cambridge, MA: Elsevier, 2014: 99–109.

49 Chang YT, Zhang L, Alkaddour HS, et al. Absence of molecular defect in the type II 3 beta-hydroxysteroid dehydrogenase (3 beta-HSD) gene in premature pubarche children and hirsute female patients with moderately decreased adrenal 3 beta-HSD activity. *Pediatr Res* 1995; **37:** 820–24.

50 Mermejo LM, Elias LL, Marui S, Moreira AC, Mendonca BB, de Castro M. Refining hormonal diagnosis of type II 3beta-hydroxysteroid dehydrogenase deficiency in patients with premature pubarche and hirsutism based on HSD3B2 genotyping. *J Clin Endocrinol Metab* 2005; **90:** 1287–93.

51 Pang S. The molecular and clinical spectrum of 3beta-hydroxysteroid dehydrogenase deficiency disorder. *Trends Endocrinol Metab* 1998; **9:** 82–86.

52 Tomalik-Scharte D, Maiter D, Kirchheiner J, Ivison HE, Fuhr U, Arlt W. Impaired hepatic drug and steroid metabolism in congenital adrenal hyperplasia due to P450 oxidoreductase deficiency. *Eur J Endocrinol* 2010; **163:** 919–24.

53 Laue K, Pogoda HM, Daniel PB, et al. Craniosynostosis and multiple skeletal anomalies in humans and zebrafish result from a defect in the localized degradation of retinoic acid. *Am J Hum Genet* 2011; **89:** 595–606.

54 Otto DM, Henderson CJ, Carrie D, et al. Identification of novel roles of the cytochrome p450 system in early embryogenesis: effects on vasculogenesis and retinoic acid homeostasis. *Mol Cell Biol* 2003; **23:** 6103–16.

55 Miller WL. Disorders in the initial steps of steroid hormone synthesis. *J Steroid Biochem Mol Biol* 2016; **165:** 18–37.

56 Chen X, Baker BY, Abduljabbar MA, Miller WL. A genetic isolate of congenital lipoid adrenal hyperplasia with atypical clinical findings. *J Clin Endocrinol Metab* 2005; **90:** 835–40.

57 Bose HS, Sugawara T, Strauss JF 3rd, Miller WL, International Congenital Lipoid Adrenal Hyperplasia C. The pathophysiology and genetics of congenital lipoid adrenal hyperplasia. *N Eng J Med* 1996; **335:** 1870–78.

58 Sugawara T, Holt JA, Driscoll D, et al. Human steroidogenic acute regulatory protein: functional activity in COS-1 cells, tissue-specific expression, and mapping of the structural gene to 8p11.2 and a pseudogene to chromosome 13. *Proc Natl Acad Sci USA* 1995; **92:** 4778–82.

59 Baker BY, Lin L, Kim CJ, et al. Nonclassic congenital lipoid adrenal hyperplasia: a new disorder of the steroidogenic acute regulatory protein with very late presentation and normal male genitalia. *J Clin Endocrinol Metab* 2006; **91:** 4781–85.

60 Metherell LA, Naville D, Halaby G, et al. Nonclassic lipoid congenital adrenal hyperplasia masquerading as familial glucocorticoid deficiency. *J Clin Endocrinol Metab* 2009; **94:** 3865–71.

61 Fluck CE, Pandey AV, Dick B, et al. Characterization of novel StAR (steroidogenic acute regulatory protein) mutations causing non-classic lipoid adrenal hyperplasia. *PLoS One* 2011; **6:** e20178.

62 Rubtsov P, Karmanov M, Sverdlova P, Spirin P, Tiulpakov A. A novel homozygous mutation in CYP11A1 gene is associated with late-onset adrenal insufficiency and hypospadias in a 46,XY patient. *J Clin Endocrinol Metab* 2009; **94:** 936–39.

63 Sahakitrungruang T, Tee MK, Blackett PR, Miller WL. Partial defect in the cholesterol side-chain cleavage enzyme P450scc (CYP11A1) resembling nonclassic congenital lipoid adrenal hyperplasia. *J Clin Endocrinol Metab* 2011; **96:** 792–98.

64 Tee MK, Abramsohn M, Loewenthal N, et al. Varied clinical presentations of seven patients with mutations in CYP11A1 encoding the cholesterol side-chain cleavage enzyme, P450scc. *J Clin Endocrinol Metab* 2013; **98:** 713–20.

65 Parajes S, Kamrath C, Rose IT, et al. A novel entity of clinically isolated adrenal insufficiency caused by a partially inactivating mutation of the gene encoding for P450 side chain cleavage enzyme (CYP11A1). *J Clin Endocrinol Metab* 2011; **96:** E1798–806.

66 Janzen N, Riepe FG, Peter M, et al. Neonatal screening: identification of children with 11beta-hydroxylase deficiency by second-tier testing. *Horm Res Paediatr* 2012; **77:** 195–99.

67 van der Kamp HJ, Oudshoorn CG, Elvers BH, et al. Cutoff levels of 17-alpha-hydroxyprogesterone in neonatal screening for congenital adrenal hyperplasia should be based on gestational age rather than on birth weight. *J Clin Endocrinol Metab* 2005; **90:** 3904–07.

68 Janzen N, Peter M, Sander S, et al. Newborn screening for congenital adrenal hyperplasia: additional steroid profile using liquid chromatography-tandem mass spectrometry. *J Clin Endocrinol Metab* 2007; **92:** 2581–89.

69 New MI, Lorenzen F, Lerner AJ, et al. Genotyping steroid 21-hydroxylase deficiency: hormonal reference data. *J Clin Endocrinol Metab* 1983; **57:** 320–26.

70 Caulfield MP, Lynn T, Gottschalk ME, et al. The diagnosis of congenital adrenal hyperplasia in the newborn by gas chromatography/mass spectrometry analysis of random urine specimens. *J Clin Endocrinol Metab* 2002; **87:** 3682–90.

71 Azziz R, Hincapie LA, Knochenhauer ES, Dewailly D, Fox L, Boots LR. Screening for 21-hydroxylase-deficient nonclassic adrenal hyperplasia among hyperandrogenic women: a prospective study. *J Fertil Steril* 1999; **72:** 915–25.

72 Koyama Y, Homma K, Fukami M, et al. Two-step biochemical differential diagnosis of classic 21-hydroxylase deficiency and cytochrome P450 oxidoreductase deficiency in Japanese infants by GC-MS measurement of urinary pregnanetriolone/tetrahydroxycortisone ratio and 11β-hydroxyandrosterone. *Clin Chem* 2012; **58:** 741–47.

73 Reisch N, Idkowiak J, Hughes BA, et al. Prenatal diagnosis of congenital adrenal hyperplasia caused by P450 oxidoreductase deficiency. *J Clin Endocrinol Metab* 2013; **98:** E528–36.

74 Bornstein SR, Allolio B, Arlt W, et al. Diagnosis and treatment of primary adrenal insufficiency: an Endocrine Society clinical practice guideline. *J Clin Endocrinol Metab* 2016; **101:** 364–89.

75 Auchus RJ, Arlt W. Approach to the patient: the adult with congenital adrenal hyperplasia. *J Clin Endocrinol Metab* 2013; **98:** 2645–55.

76 Livadas S, Dracopoulou M, Dastamani A, et al. The spectrum of clinical, hormonal and molecular findings in 280 individuals with nonclassical congenital adrenal hyperplasia caused by mutations of the CYP21A2 gene. *Clin Endocrinol* 2015; **82:** 543–49.

77 Bidet M, Bellanne-Chantelot C, Galand-Portier MB, et al. Fertility in women with nonclassical congenital adrenal hyperplasia due to 21-hydroxylase deficiency. *J Clin Endocrinol Metab* 2010; **95:** 1182–90.

78 Trakakis E, Dracopoulou-Vabouli M, Dacou-Voutetakis C, Basios G, Chrelias C, Kassanos D. Infertility reversed by glucocorticoids and full-term pregnancy in a couple with previously undiagnosed nonclassic congenital adrenal hyperplasia. *J Fertil Steril* 2011; **96:** 1048–50.

79 Martinerie L, Pussard E, Foix-L'Hélias L, et al. Physiological partial aldosterone resistance in human newborns. *Pediatr Res* 2009; **66:** 323–28.

80 Muthusamy K, Elamin MB, Smushkin G, et al. Clinical review: adult height in patients with congenital adrenal hyperplasia: a systematic review and metaanalysis. *J Clin Endocrinol Metab* 2010; **95:** 4161–72.

81 Merke DP, Chrousos GP, Eisenhofer G, et al. Adrenomedullary dysplasia and hypofunction in patients with classic 21-hydroxylase deficiency. *N Engl J Med* 2000; **343:** 1362–68.

Neurocrine EX1015
Page 15 of 17

82 Sahakitrungruang T, Huan N, Tee MK, et al. Clinical, genetic, and enzymatic characterization of P450 oxidoreductase deficiency in four patients. *J Clin Endocrinol Metab* 2009; **94:** 4992–5000.

83 Bulsari K, Falhammar H. Clinical perspectives in congenital adrenal hyperplasia due to 11β-hydroxylase deficiency. *Endocrine* 2017; **55:** 19–36.

84 Mouriquand PD, Gorduza DB, Gay CL, et al. Surgery in disorders of sex development (DSD) with a gender issue: if (why), when, and how? *J Pediatr Urol* 2016; **12:** 139–49.

85 Fisher AD, Ristori J, Fanni E, Castellini G, Forti G, Maggi M. Gender identity, gender assignment and reassignment in individuals with disorders of sex development: a major of dilemma. *J Endocrinol Invest* 2016; **39:** 1207–24.

86 Merke DP, Poppas DP. Management of adolescents with congenital adrenal hyperplasia. *Lancet Diabetes Endocrinol* 2013; **1:** 341–52.

87 DiSandro M, Merke DP, Rink RC. Review of current surgical techniques and medical management considerations in the treatment of pediatric patients with disorders of sex development. *Horm Metab* 2015; **47:** 321–28.

88 Nordenskjold A, Holmdahl G, Frisen L, et al. Type of mutation and surgical procedure affect long-term quality of life for women with congenital adrenal hyperplasia. *J Clin Endocrinol Metab* 2008; **93:** 380–86.

89 Abdulhadi-Atwan M, Jean A, Chung WK, et al. Role of a founder c.201_202delCT mutation and new phenotypic features of congenital lipoid adrenal hyperplasia in Palestinians. *J Clin Endocrinol Metab* 2007; **92:** 4000–08.

90 Forest MG, David M, Morel Y. Prental diagnosis and treatment of 21-hydroxylase deficiency. *J Steriod Biochem Mol Biol* 1993; **45:** 75–82.

91 Hirvikoski T, Nordenstrom A, Lindholm T, et al. Cognitive functions in children at risk for congenital adrenal hyperplasia treated prenatally with dexamethasone. *J Clin Endocrinol Metab* 2007; **92:** 542–48.

92 Lajic S, Nordenstrom A, Hirvikoski T. Long-term outcome of prenatal dexamethasone treatment of 21-hydroxylase deficiency. *Endocr Dev* 2011; **20:** 96–105.

93 Wallensteen L, Zimmermann M, Sandberg MT, et al. Evaluation of behavioral problems after prenatal dexamethasone treatment in Swedish adolescents at risk of CAH. *Horm Behav* 2016; **85:** 5–11.

94 Wallensteen L, Zimmermann M, Thomsen Sandberg M, et al. Sex-dimorphic effects of prenatal treatment with dexamethasone. *J Clin Endocrinol Metab* 2016; **101:** 3838–46.

95 Tardy-Guidollet V, Menassa R, Costa JM, et al. New management strategy of pregnancies at risk of congenital adrenal hyperplasia using fetal sex determination in maternal serum: French cohort of 258 cases (2002–2011). *J Clin Endocrinol Metab* 2014; **99:** 1180–88.

96 New MI, Tong YK, Yuen T, et al. Noninvasive prenatal diagnosis of congenital adrenal hyperplasia using cell-free fetal DNA in maternal plasma. *J Clin Endocrinol Metab* 2014; **99:** E1022–30.

97 Hirvikoski T, Nordenstrom A, Wedell A, Ritzen M, Lajic S. Prenatal dexamethasone treatment of children at risk for congenital adrenal hyperplasia: the Swedish experience and standpoint. *J Clin Endocrinol Metab* 2012; **97:** 1881–83.

98 Dagalakis U, Mallappa A, Elman M, Quezado M, Merke DP. Positive fertility outcomes in a female with classic congenital adrenal hyperplasia following bilateral adrenalectomy. *Int J Pediatr Endocrinol* 2016; **2016:** 10.

99 Chabre O, Portrat-Doyen S, Chaffanjon P, et al. Bilateral laparoscopic adrenalectomy for congenital adrenal hyperplasia with severe hypertension, resulting from two novel mutations in splice donor sites of CYP11B1. *J Clin Endocrinol Metab* 2000; **85:** 4060–68.

100 Van Wyk JJ, Ritzen EM. The role of bilateral adrenalectomy in the treatment of congenital adrenal hyperplasia. *J Clin Endocrinol Metab* 2003; **88:** 2993–98.

101 Falhammar H, Frisen L, Norrby C, et al. Increased mortality in patients with congenital adrenal hyperplasia due to 21-hydroxylase deficiency. *J Clin Endocrinol Metab* 2014; **99:** E2715–21.

102 Reisch N, Willige M, Kohn D, et al. Frequency and causes of adrenal crises over lifetime in patients with 21-hydroxylase deficiency. *Eur J Endocrinol* 2012; **167:** 35–42.

103 Mushtaq T, Ahmed SF. The impact of corticosteroids on growth and bone health. *Arch Dis Child* 2002; **87:** 93–96.

104 Cordeiro GV, Silva IN, Goulart EM, Chagas AJ, Kater CE. Final height in congenital adrenal hyperplasia: the dilemma of hypercortisolism versus hyperandrogenism. *Arq Bras Endocrinol Metabol* 2013; **57:** 126–31.

105 Sarafoglou K, Addo OY, Turcotte L, et al. Impact of hydrocortisone on adult height in congenital adrenal hyperplasia—the Minnesota cohort. *J Pediatr* 2014; **164:** 1141–46.e1.

106 Manoli I, Kanaka-Gantenbein C, Voutetakis A, Maniati-Christidi M, Dacou-Voutetakis C. Early growth, pubertal development, body mass index and final height of patients with congenital adrenal hyperplasia: factors influencing the outcome. *Clin Endocrinol* 2002; **57:** 669–76.

107 Arlt W, Willis DS, Wild SH, et al. Health status of adults with congenital adrenal hyperplasia: a cohort study of 203 patients. *J Clin Endocrinol Metab* 2010; **95:** 5110–21.

108 Falhammar H, Frisen L, Hirschberg AL, et al. Increased cardiovascular and metabolic morbidity in patients with 21-hydroxylase deficiency: a Swedish population-based national cohort study. *J Clin Endocrinol Metab* 2015; **100:** 3520–28.

109 El-Maouche D, Collier S, Prasad M, Reynolds JC, Merke DP. Cortical bone mineral density in patients with congenital adrenal hyperplasia due to 21-hydroxylase deficiency. *Clin Endocrinol* 2015; **82:** 330–37.

110 Falhammar H, Filipsson Nystrom H, Wedell A, Brismar K, Thoren M. Bone mineral density, bone markers, and fractures in adult males with congenital adrenal hyperplasia. *Eur J Endocrinol* 2013; **168:** 331–41.

111 Finkielstain GP, Kim MS, Sinaii N, et al. Clinical characteristics of a cohort of 244 patients with congenital adrenal hyperplasia. *J Clin Endocrinol Metab* 2012; **97:** 4429–38.

112 Falhammar H, Filipsson H, Holmdahl G, et al. Fractures and bone mineral density in adult women with 21-hydroxylase deficiency. *J Clin Endocrinol Metab* 2007; **92:** 4643–49.

113 Khoury K, Barbar E, Ainmelk Y, Ouellet A, Lavigne P, LeHoux JG. Thirty-eight-year follow-up of two sibling lipoid congenital adrenal hyperplasia patients due to homozygous steroidogenic acute regulatory (STARD1) protein mutation. Molecular structure and modeling of the STARD1 L275P Mutation. *Front Neurosci* 2016; **10:** 527.

114 Albarel F, Perrin J, Jegaden M, et al. Successful IVF pregnancy despite inadequate ovarian steroidogenesis due to congenital lipoid adrenal hyperplasia (CLAH): a case report. *Hum Reprod* 2016; **31:** 2609–12.

115 Bianchi PH, Gouveia GR, Costa EM, et al. Successful live birth in a woman with 17alpha-hydroxylase deficiency through IVF frozen-thawed embryo transfer. *J Clin Endocrinol Metab* 2016; **101:** 345–48.

116 Idkowiak J, O'Riordan S, Reisch N, et al. Pubertal presentation in seven patients with congenital adrenal hyperplasia due to P450 oxidoreductase deficiency. *J Clin Endocrinol Metab* 2011; **96:** E453–62.

117 Jin HY, Choi JH, Lee BH, Kim GH, Kim HK, Yoo HW. Ovarian cyst torsion in a patient with congenital lipoid adrenal hyperplasia. *Eur J Pediatr* 2011; **170:** 535–38.

118 Roger M, Merceron RE, Girard F, et al. Dexamethasone-suppressible hypercorticosteronism in two 46,XX subjects with ambiguous genitalia and ovarian cysts. Partial defect of 17 alpha-hydroxylase or 17–20-desmolase. *Horm Res* 1982; **16:** 23–31.

119 Reisch N, Flade L, Scherr M, et al. High prevalence of reduced fecundity in men with congenital adrenal hyperplasia. *J Clin Endocrinol Metab* 2009; **94:** 1665–70.

120 Stikkelbroeck NM, Otten BJ, Pasic A, et al. High prevalence of testicular adrenal rest tumors, impaired spermatogenesis, and Leydig cell failure in adolescent and adult males with congenital adrenal hyperplasia. *J Clin Endocrinol Metab* 2001; **86:** 5721–28.

121 Labarta E, Martinez-Conejero JA, Alama P, et al. Endometrial receptivity is affected in women with high circulating progesterone levels at the end of the follicular phase: a functional genomics analysis. *Hum Reprod* 2011; **26:** 1813–25.

122 Mnif MF, Kamoun M, Kacem FH, et al. Reproductive outcomes of female patients with congenital adrenal hyperplasia due to 21-hydroxylase defi ciency. *Indian J Endocrinol Metab* 2013; **17:** 790–93.

Neurocrine EX1015
Page 16 of 17

123 Casteras A, De Silva P, Rumsby G, Conway GS. Reassessing fecundity in women with classical congenital adrenal hyperplasia (CAH): normal pregnancy rate but reduced fertility rate. *Clin Endocrinol (Oxf)* 2009; **70:** 833–37.

124 Lekarev O, Lin-Su K, Vogiatzi MG. Infertility and reproductive function in patients with congenital adrenal hyperplasia: pathophysiology, advances in management, and recent outcomes. *Endocrinol Metab Clin North Am* 2015; **44:** 705–22.

125 Claahsen-van der Grinten HL, Otten BJ, Stikkelbroeck MM, Sweep FC, Hermus AR. Testicular adrenal rest tumours in congenital adrenal hyperplasia. *Best Pract Res Clin Endocrinol Metab* 2009; **23:** 209–20.

126 Crocker MK, Barak S, Millo CM, et al. Use of PET/CT with cosyntropin stimulation to identify and localize adrenal rest tissue following adrenalectomy in a woman with congenital adrenal hyperplasia. *J Clin Endocrinol Metab* 2012; **97:** E2084–89.

127 Russo G, Paesano P, Taccagni G, Del Maschio A, Chiumello G. Ovarian adrenal-like tissue in congenital adrenal hyperplasia. *N Eng J Med* 1998; **339:** 853–54.

128 Falhammar H, Nystrom HF, Ekstrom U, Granberg S, Wedell A, Thoren M. Fertility, sexuality and testicular adrenal rest tumors in adult males with congenital adrenal hyperplasia. *Eur J Endocrinol* 2012; **166:** 441–49.

129 Yu MK, Jung MK, Kim KE, et al. Clinical manifestations of testicular adrenal rest tumor in males with congenital adrenal hyperplasia. *Ann Pediatr Endocrinol Metab* 2015; **20:** 155–61.

130 Martinez-Aguayo A, Rocha A, Rojas N, et al. Testicular adrenal rest tumors and Leydig and Sertoli cell function in boys with classical congenital adrenal hyperplasia. *J Clin Endocrinol Metab* 2007; **92:** 4583–89.

131 Aycan Z, Bas VN, Cetinkaya S, Yilmaz Agladioglu S, Tiryaki T. Prevalence and long-term follow-up outcomes of testicular adrenal rest tumours in children and adolescent males with congenital adrenal hyperplasia. *Clin Endocrinol (Oxf)* 2013; **78:** 667–72.

132 Chihaoui M, Kanoun F, Chaker F, et al. Testicular adrenal rest tumours in young adult males with congenital adrenal hyperplasia: prevalence and impact on testicular function. *Andrologia* 2016; **48:** 45–50.

133 Claahsen-van der Grinten HL, Duthoi K, Otten BJ, d'Ancona FC, Hulsbergen-vd Kaa CA, Hermus AR. An adrenal rest tumour in the perirenal region in a patient with congenital adrenal hyperplasia due to congenital 3beta-hydroxysteroid dehydrogenase deficiency. *Eur J Endocrinol* 2008; **159:** 489–91.

134 Stikkelbroeck NM, Hermus AR, Suliman HM, Jager GJ, Otten BJ. Asymptomatic testicular adrenal rest tumours in adolescent and adult males with congenital adrenal hyperplasia: basal and follow-up investigation after 2·6 years. *J Pediatr Endocrinol Metab* 2004; **17:** 645–53.

135 Walker BR, Skoog SJ, Winslow BH, Canning DA, Tank ES. Testis sparing surgery for steroid unresponsive testicular tumors of the adrenogenital syndrome. *J Urol* 1997; **157:** 1460–63.

136 Claahsen-van der Grinten HL, Otten BJ, Takahashi S, et al. Testicular adrenal rest tumors in adult males with congenital adrenal hyperplasia: evaluation of pituitary-gonadal function before and after successful testis-sparing surgery in eight patients. *J Clin Endocrinol Metab* 2007; **92:** 612–15.

137 Kavoussi PK, Summers-Colquitt RB, Odenwald KC, et al. Sperm retrieval and concomitant tumor resection in azoospermic men with congenital adrenal hyperplasia and bilateral testicular adrenal rest tumors: a case report. *J Assist Reprod Genet* 2016; **33:** 545–48.

138 Homma K, Hasegawa T, Nagai T, et al. Urine steroid hormone profile analysis in cytochrome P450 oxidoreductase deficiency: implication for the backdoor pathway to dihydrotestosterone. *J Clin Endocrinol Metab* 2006; **91:** 2643–49.

139 Kamrath C, Hochberg Z, Hartmann MF, Remer T, Wudy SA. Increased activation of the alternative "backdoor" pathway in patients with 21-hydroxylase deficiency: evidence from urinary steroid hormone analysis. *J Clin Endocrinol Metab* 2012; **97:** E367–75.

140 Pretorius E, Arlt W, Storbeck KH. A new dawn for androgens: novel lessons from 11-oxygenated C19 steroids. *Mol Cell Endocrinol* 2016; **441:** 76–85.

141 Pretorius E, Africander DJ, Vlok M, Perkins MS, Quanson J, Storbeck KH. 11-ketotestosterone and 11-ketodihydrotestosterone in castration resistant prostate cancer: potent androgens which can no longer be ignored. *PLoS One* 2016; **11:** e0159867.

142 Storbeck KH, Bloem LM, Africander D, Schloms L, Swart P, Swart AC. 11beta-hydroxydihydrotestosterone and 11-ketodihydrotestosterone, novel C19 steroids with androgenic activity: a putative role in castration resistant prostate cancer? *Mol Cell Endocrinol* 2013; **377:** 135–46.

143 Jones CM, Mallappa A, Reisch N, et al. Modified release and conventional glucocorticoids and diurnal androgen excretion in congenital adrenal hyperplasia. *J Clin Endocrinol Metab* 2016; published online Nov 5. DOI:10.1210/jc.2016-2855.

144 Turcu AF, Nanba AT, Chomic R, et al. Adrenal-derived 11-oxygenated 19-carbon steroids are the dominant androgens in classic 21-hydroxylase deficiency. *Eur J Endocrinol* 2016; **174:** 601–09.

145 Morel Y, Bristow J, Gitelman SE, Miller WL. Transcript encoded on the opposite strand of the human steroid 21-hydroxylase/complement component C4 gene locus. *Proc Natl Acad Sci USA* 1989; **86:** 6582–86.

146 Burch GH, Gong Y, Liu W, et al. Tenascin-X deficiency is associated with Ehlers-Danlos syndrome. *Nat Genet* 1997; **17:** 104–08.

147 Merke DP, Chen W, Morissette R, et al. Tenascin-X haploinsufficiency associated with Ehlers-Danlos syndrome in patients with congenital adrenal hyperplasia. *J Clin Endocrinol Metab* 2013; **98:** E379–87.

148 Morissette R, Chen W, Perritt AF, et al. Broadening the spectrum of Ehlers Danlos syndrome in patients with congenital adrenal hyperplasia. *J Clin Endocrinol Metab* 2015; **100:** E1143–52.

149 Gomes LG, Huang N, Agrawal V, Mendonca BB, Bachega TA, Miller WL. Extraadrenal 21-hydroxylation by CYP2C19 and CYP3A4: effect on 21-hydroxylase deficiency. *J Clin Endocrinol Metab* 2009; **94:** 89–95.

150 Kaupert LC, Lemos-Marini SH, De Mello MP, et al. The effect of fetal androgen metabolism-related gene variants on external genitalia virilization in congenital adrenal hyperplasia. *Clin Genet* 2013; **84:** 482–88.

151 Rocha RO, Billerbeck AE, Pinto EM, et al. The degree of external genitalia virilization in girls with 21-hydroxylase deficiency appears to be influenced by the CAG repeats in the androgen receptor gene. *Clin Endocrinol (Oxf)* 2008; **68:** 226–32.

152 White PC. Neonatal screening for congenital adrenal hyperplasia. *Nat Rev Endocrinol* 2009; **5:** 490–98.

153 Mallappa A, Sinaii N, Kumar P, et al. A phase 2 study of Chronocort, a modified-release formulation of hydrocortisone, in the treatment of adults with classic congenital adrenal hyperplasia. *J Clin Endocrinol Metab* 2015; **100:** 1137–45.

154 Bryan SM, Honour JW, Hindmarsh PC. Management of altered hydrocortisone pharmacokinetics in a boy with congenital adrenal hyperplasia using a continuous subcutaneous hydrocortisone infusion. *J Clin Endocrinol Metab* 2009; **94:** 3477–80.

155 Nella AA, Mallappa A, Perritt AF, et al. A phase 2 study of continuous subcutaneous hydrocortisone infusion in adults with congenital adrenal hyperplasia. *J Clin Endocrinol Metab* 2016; published online Sept 28. DOI:10.1210/jc.2016-1916.

156 Turcu AF, Spencer-Segal JL, Farber RH, et al. Single-dose study of a corticotropin-releasing factor receptor-1 antagonist in women with 21-hydroxylase deficiency. *J Clin Endocrinol Metab* 2016; **101:** 1174–80.

157 Merke DP, Keil MF, Jones JV, Fields J, Hill S, Cutler GB Jr. Flutamide, testolactone, and reduced hydrocortisone dose maintain normal growth velocity and bone maturation despite elevated androgen levels in children with congenital adrenal hyperplasia. *J Clin Endocrinol Metab* 2000; **85:** 1114–20.

158 Auchus RJ, Buschur EO, Chang AY, et al. Abiraterone acetate to lower androgens in women with classic 21-hydroxylase deficiency. *J Clin Endocrinol Metab* 2014; **99:** 2763–70.

159 Cheng Y, Kerppola RE, Kerppola TK. ATR-101 disrupts mitochondrial functions in adrenocortical carcinoma cells and in vivo. *Endocr Relat Cancer* 2016; **23:** 1–19.

160 Bry-Gauillard H, Cartes A, Young J. Mitotane for 21-hydroxylase deficiency in an infertile man. *N Eng J Med* 2014; **371:** 2042–44.

161 Ruiz-Babot G, Hadjidemetriou I, King PJ, Guasti L. New directions for the treatment of adrenal insufficiency. *Front Endocrinol* 2015; **6:** 70.

162 Balyura M, Gelfgat E, Ehrhart-Bornstein M, et al. Transplantation of bovine adrenocortical cells encapsulated in alginate. *Proc Natl Acad Sci USA* 2015; **112:** 2527–32.

Neurocrine EX1015
Page 17 of 17